

A Dissertation on
**FUNCTIONAL OUTCOME OF VARIOUS
MODALITIES OF MANAGEMENT OF
DISTAL TIBIAL FRACTURES**


Submitted to

**THE TAMILNADU DR. M.G.R. MEDICAL UNIVERSITY
CHENNAI**

In partial fulfillment of the regulations

For the Award of the Degree of

**M.S. DEGREE BRANCH -II
ORTHOPAEDIC SURGERY**



**KILPAUK MEDICAL COLLEGE
CHENNAI**

MARCH - 2007

This is to certify that **Dr. E.S.ARIVAZHAGAN** Post-Graduate student (2004 – 2007) in the Department of orthopaedics; Govt. Kilpauk Medical College Chennai has done this dissertation on “**FUNCTIONAL OUTCOME OF VARIOUS MODALITIES OF MANAGEMENT OF DISTAL TIBIAL FRACTURES**” under my guidance and supervision in partial fulfillment of the regulations laid down by The Tamil Nadu Dr. M.G.R Medical University, Chennai for M.S (Orthopaedics) degree examination to be held on March 2007.

**Prof. Dr. THIAGAVALLI
KIRUBAKARAN, M.D.,
D.Ortho.,
Dean,
Govt. Kilpauk Medical College and Hospital,
Orthopaedics,
Chennai – 600 010.**

**Prof. Dr. A. SIVAKUMAR,
M.S.(Ortho).,**
Professor – HOD,
Department of
Govt. Royapettah Hospital,
Kilpauk Medical College,
Chennai.

DECLARATION

I, **Dr. E.S.ARIVAZHAGAN** declare that dissertation titled **“FUNCTIONAL OUTCOME OF VARIOUS MODALITIES OF MANAGEMENT OF DISTAL TIBIAL FRACTURES”** is a bonafide work done by me at Kilpauk Medical College 2004-2007 under the guidance and supervision of my unit’s chief **Prof. Dr. A. SIVAKUMAR, M.S.(Ortho)., D.Ortho.,**

This dissertation is submitted to **The Tamil Nadu Dr.M.G.R. Univeristy** towards partial fulfillment of regulations for award of **M.S. Degree Branch II – Orthopaedic Surgery.**

(Dr. E.S.ARIVAZHAGAN)

ACKNOWLEDGEMENT

First and foremost I would like to thank **Prof. THIAGAVALLI KIRUBAKARAN M.D.**, Dean, Kilpauk Medical College for permitting me to use the resources and clinical materials of this hospital.

I offer my sincere thanks to **Prof. SOMASEKAR M.D.**, Superintendent of Govt. Royapettah Hospital Chennai – 14 for having permitted me to use the hospital materials for this study.

I express my profound thanks to my esteemed professor and Head of the department, **Prof. A. SIVAKUMAR** Govt. Royapettah hospital for his valuable suggestions and help for this study.

I thank **Prof. K. NAGAPPAN** and **Prof. K. SANKARALINGAM** for their encouragement and help for this study.

I thank **Dr. T.THOLGAPPIYAN** Assistant Professor Government Royapettah Hospital for encouraging and extending invaluable guidance as a guide to perform and complete this dissertation.

My sincere thanks to **Dr. R. BALACHANDRAN, Dr. P. ELANGOVAN, Dr. K. MOHAN KUMAR, Dr. V.THANIGAINATH** and **Dr. P.VEERANAN YADAV**, for encouragement throughout the period of this study.

Last but not the least my gratitude to the patients involved who were kind and cooperative.

CONTENTS

S.No	TITLE	Page No.
1.	INTRODUCTION	1
2.	AIM OF THE STUDY	4
3.	HISTORICAL REVIEW	5
4.	ANATOMY	7
5.	CLASSIFICATION	12
6.	CLINICAL FEATURES	19
7.	RADIOLOGICAL ASSESSMENTS	20
8.	TREATMENT	21
9.	BIOMECHANICS OF THE DEVICES	27
10.	MATERIALS AND METHODS	33
11.	ANALYSIS OF RESULTS	46
12.	DISCUSSION	53
13.	CONCLUSION	59
14.	CASE PROFORMA	60
	BIBLIOGRAPHY	
	MASTER CHART	

INTRODUCTION

Distal tibial fractures remain a challenge to orthopaedic surgeons. They usually occur as a result of high energy trauma in young patients, but in the elderly they can result from a simple fall. In the elderly, the problem is compounded by poor bone-stock, their limited ability to partially weight bear and co-morbid conditions.

The main challenges:²

1. The compromised skin and soft tissue envelope as in open fractures lead to a high incidence of complications following open reduction and internal fixation.

2. In the metaphysis, fixation is less rigid and early loosening is a frequent event as the cancellous bone is open and 'cell-like' and therefore ill equipped to support a screw thread.

3. Comminuted fracture patterns, which create difficulty in achieving rigid fixation since the purchase in trabecular bone is less than optimal to

permit weight bearing or even start early joint mobilization. These conditions that restrict mobility lead to decubitus ulcers, deep vein thrombosis, joint stiffness and secondary osteoarthritis.

4. These high energy fractures may be associated with extremely damaged soft tissue envelope, as well as comminuted metaphyseal region and articular surface making anatomical reduction difficult.

Following are various classical and conventional methods available to address such injuries, but each has its own set of advantages and disadvantages.

1. Non-operative management :

Closed, simple fractures in patients those are having associated co-morbid diseases rendering them unfit for anesthesia, leaving them to be managed conservatively.

2. Intramedullary nailing:

Simple fractures, those without associated soft tissue envelope damage and less comminution, can be managed with intramedullary nailing.

3. AO External fixators:

These fixations have been successful in reducing the fractures temporarily and attending the soft tissue injuries.

4. Plating devices:

Fractures not associated with significant soft tissue damage can be treated with open reduction and plating. This may be done with conventional, bridge plating technique or locking plating.

5. Hybrid External fixation:

In periarticular fractures wires are placed into the metaphyseal region and schanz pins into the diaphyseal region after reducing the fractures.

AIM OF THE STUDY

To analyze and individualize the choice of fixation in the management of distal tibial fractures.

HISTORICAL REVIEW

460-335 B.C - Hippocrates - Principle of Immobilization of a fracture and

use of splint for this purpose

1852 - Majhijson - The Ancient Egyptian anticipated the use of POP cast by impregnating bandages in resin.

1875 - Heine - Ivory pegs in experiments.

1907 - Lambotte - Intra medullary metal splints.

1916 - Heygroves - Solid intramedullary metal rods.

1940 -Gerhardt Kuntscher –Announced intramedullary nailing in Berlin in

German surgical congress.

1951 -Herzog -

Introduced rigid clover leaf nail.

1956 -Nicolle -

Stabilising the fragments with a plate ,

bridging the

gap with a pure cancellous bone or one

cortex of

the graft.

1961 -Kuntscher -

Documented the number of nails for

treating tibial

fractures.

1967 -Sarmiento -

Functional below knee cast and bracing.

1960-70- Klemm; Schelmann; Grosse-Kemp: Forerunners of current

generation

of interlocking nails.

1984 - Muller & Witzel - Basic idea to leave the fracture zone and its

fragments

undisturbed- Pioneers of bridge plating.

1995 – K.Wenda et. Al - First treated 12 cases with extensive segmental and comminuted fractures of the Femur – metaphyseal area successfully with bridge plating.

1995 -Ram Chaddha et. al –Coined new name as sliding or Interlocking plate.

ANATOMY

The distal end of the tibia is slightly expanded and has anterior, posterior, medial, lateral and distal articular surfaces. It projects inferomedially as the medial malleolus.

The distal end of the tibia when compared to the proximal end is laterally rotated (Tibial torsion). The tibial torsion begins in utero and progresses throughout childhood and adolescence to skeletal maturity. The tibial torsion is about 30 degrees in Caucasians and Oriental population and greater in Africans.

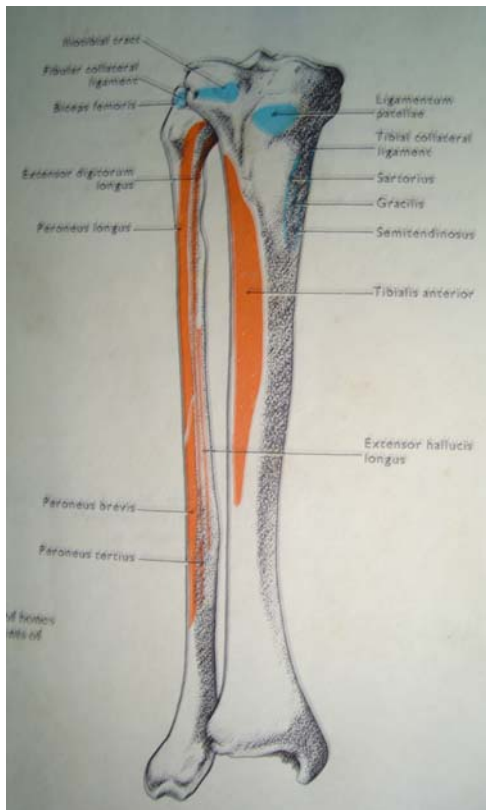
Distal end has a somewhat pronounced concavity on its medial surface. The medullary canal is significantly more round in cross section than the external appearance of the bone.

Tibia is divided into six anatomical zones based on **Carr J ; Sobba D &**

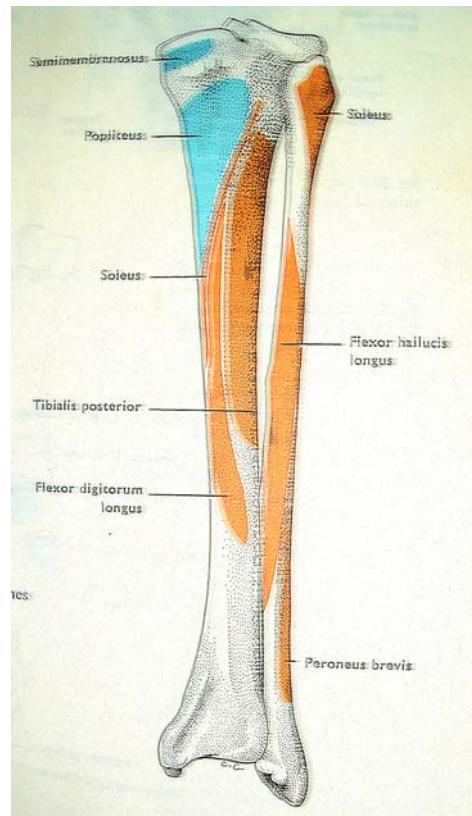
Bear L:

1. Tibial head
2. Proximal metaphyseal zone
3. Proximal mid diaphysis
4. Mid diaphysis
5. Distal metadiaphysis
6. Tibial plafond

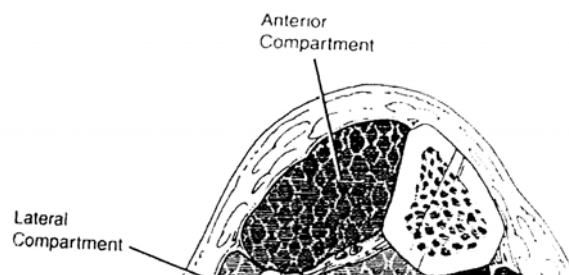
ANTERIOR



POSTERIOR



THE FOUR COMPARTMENTS OF THE LEG



Proximally the tibia is enveloped by sufficient amount of muscles except in the medial surface , whereas distally the tibial shaft flares and becomes more rounded as it meets metaphysis and is surrounded by tendons.

Asymmetric surrounding soft tissues determine the shape of the leg. The tibia serves as a conduit for neurovascular supply of foot.

Tibia is more prone for fractures because of the following peculiarities:-

1. The anteromedial surface of the tibia is subcutaneous.

2. The diaphysis becomes more thinner distally hence it is particularly at risk from torsion forces.
3. The distal tibia has a relative poor blood supply due to lesser muscular attachments, comparing to its remaining regions.

The leg is divided in to four compartments.

The compartments are surrounded by non-distensible fascia., hence compartment syndrome may supervene following injuries.

Anterior Compartment :

Contents are

1. Tibialis anterior
2. Extensor hallucis longus
3. Extensor digitorum
4. Peroneus tertius
5. Anterior tibial artery with it's venae cavae
6. Deep peroneal nerve

Lateral Compartment

Contents are

1. Peroneus Longus
2. Peroneus brevis
3. Superficial peroneal nerve

Posterior Compartment

It is sub divided in to

- A. Superficial
- B. Deep

Superficial Compartment : Contains gastrocnemius, soleus, plantaris muscles and posterior tibial nerve.

The gastrocnemius and soleus muscles are important for rotation flap cover technique by plastic surgeons for injuries with loss of soft tissue cover and exposing the distal tibia.

The posterior tibial nerve which innervates the muscles of sole of the foot, damage to which determines the discretion between limb salvage & sacrifice.

Deep Compartment :-

Contents are :-

Flexor hallucis longus , Flexor digitorum , Tibialis posterior , Posterior tibial artery and Posterior tibial nerve .

The nutrient artery is a branch of posterior tibial artery. The lower nutrient artery of the tibia in the lower third reaches the junction of middle third and lower third.

The periosteal vessels are branches from anterior tibial artery. The tibia has a rich blood supply from surrounding tissues. The vessels pierce the bone nearly perpendicular to it's surface and supply outer 1/3 of cortex.

Since the lower tibia is mainly surrounded by tendons, the blood supply is very poor and is dependent on nutrient vessel branch.

During weight bearing 80 – 90% of load is transmitted through the tibial plafond to the dome of the Talus and about 17% is transmitted through the fibula .

The surgical approaches to the tibia are straightforward. The basic rule is that all approaches should be longitudinal and never transverse. The skin overlying the anteromedial border should not be breached.

- .1 Spiral
- .2 Oblique
- .3 Transverse

A2 – Extra articular fracture, metaphyseal wedge

- .1 Postero lateral impaction
- .2 Anteromedial wedge
- .3 Extending into the diaphysis

A3 – Extra articular fracture, metaphyseal complex


- .1 three intermediate fragments
- .2 more than three intermediate fragments
- .3 extending into the diaphysis

B – Partial articular fracture

B1 – Partial articular fracture, pure split

- .1 Frontal
- .2 Sagittal
- .3 Metaphyseal multi fragmentary

A O CLASSIFICATION



B2 – partial articular fracture, split depression

.1 Frontal

.2 Sagittal

.3 Of the central fragment

B3 – partial articular fracture, multi fragmentary depression

.1 Frontal

.2 Sagittal

.3 Metaphyseal multi fragmentary

C – Complete articular fracture

C1 – Complete articular fracture, articular simple, metaphyseal simple

.1 without depression

.2 with depression

.3 Extending into the diaphysis

C2 – complete articular fracture, articular simple, metaphyseal multi fragmentary

.1 With asymmetric impaction

.2 without asymmetric impaction

.3 extending in to the diaphysis


C3 – complete articular fracture , multi fragmentary

.1 Epiphyseal

.2 Epiphyseo metaphyseal

.3 Epiphyseo metaphyseal diaphyseal

RUEDE & ALLGOWER'S CLASSIFICATION



Ruedi & Allgower's Classification:

This is divided into 3 groups depending on the displacement and comminution of the joint

Group 1 – Cleavage fractures of the articular surface without major dislocation of the articular surface.

Group 2 – Significant fracture and dislocation but without comminution.

Group 3 – The same fracture as group 2 but with significant comminution and impaction of the distal tibia.

Ovadia and Beals Extended classification of the distal tibia fractures:

Grade 1 – Non-displaced articular fractures.

Grade 2 – Minimally displaced articular fracture.

Grade 3 – Displaced articular fracture with several large fragments.

Grade 4 - Displaced articular fracture with multiple fragments and a large metaphyseal defect.

Mode of Injury

Five principle causes are

1. Motor vehicle accidents

2. Falls

3. Assault

4. Sports Injuries

5. Gun shot injuries

Among them motor vehicle accidents is the commonest mode of injury.

CLINICAL FEATURES

In conscious patients pain, swelling and deformity are conspicuous.

Physical examination should include the assessment of neurovascular status of the patient's injured limb, since compartment syndrome may be apparent within few hours. It is extremely important to examine the skin thoroughly and any open wound should be assessed.

Assessment

RADIOLOGICAL ASSESSMENT

Anteroposterior and lateral radiographs of the leg including knee and ankle joints must be taken.

Computed tomography is useful in cases of fractures extending into the distal articular surfaces.

The following features should be seen,

1. Location and pattern of the fracture

2. Secondary fracture lines, if any, which might get iatrogenically displaced if unnoticed
3. The presence of comminution signifying high energy trauma and associated soft tissue damage.
4. Bone loss
5. Articular extension of fractures
6. Status of the bone
7. Gas in the soft tissue region
8. Osteoarthritis and presence of knee arthroplasty

TREATMENT

Eventhough the treatment of distal tibial fractures remains controversial, the following principles should be significantly adhered to in order to achieve the goal of good functional out come.

Careful assessment and treatment of the entire patient and the injured limb leads in priority than the treatment of fracture alone.

The Basic principles in the management are

1. assurance of adequate blood flow.
2. Provisional reduction of marked deformity or dislocation.
3. Care of the open wound.
4. Precise reduction of the skeletal deformity.
5. maintenance of reduction till the healing is complete.
6. Rehabilitation.

CONSERVATIVE MANAGEMENT:-

. The results of non operative management of these injuries have historically been unsatisfactory with high rates of malunion, joint stiffness, deep vein thrombosis and early osteoarthritis.

But conservative management is to be considered when the patient is unwilling for surgery and where there are associated co-morbid conditions which render them unfit for anaesthesia.

We generally accept the following **Trafton**'s recommendations:

- 5 degrees valgus/ varus.
- < 10 degree anterior / posterior angulation.
- < 10 degrees rotation.
- < 15mm of shortening.

The techniques are

- ◆ cast immobilization
- ◆ Pin traction

Cast immobilization:-

Fractures with minimal displacement or severe comminution are reduced and above knee cast is applied.

Pin Traction :-

This is done by means of calcaneal pin traction with weight of 1/5th of the total body weight which allows early ankle mobilization and ligamentotaxis in cases of pilon fractures. This method is done for highly comminuted fractures or for fractures with open wounds or as a temporary measure before definitive treatment, but is seldom used for definitive treatment.

The results of operative treatment have been found to be more superior to that of non operative methods.

INTRAMEDULLARY NAILING

This is the standard method for stabilizing diaphyseal tibial fractures. This method spares extra – osseous blood supply, allows load sharing and avoids soft tissue dissection.

Additional techniques for obtaining and maintaining the distal metaphyseal fracture reduction during all aspects of the nailing included such as the use of femoral distractor, temporary fixation with a percutaneous clamp, percutaneous manipulation with schanz pins and open reduction and temporary fixation with a unicortical tibial plate.

PLATE OSTEOSYNTHESIS

Fractures with less degree of soft tissue damage can be treated with open reduction and plate osteosynthesis.

The methods were popularized by Reudi & Allgower for open reduction and internal fixation. The technique follows AO principles of anatomical reduction, stable internal fixation, preservation of blood supply and early active mobilization.

A 4.5mm Dynamic compression plate, limited contact compression plate (LC – DCP) or locking plate could be used.

The fracture should be exposed with minimum soft tissue and periosteal stripping.

When there is comminution, bridging the fragments by Bridge plating technique helps in not disturbing the fracture hematoma and also by damaging the periosteum or soft tissue envelope minimally..

The plate should be avoided in the subcutaneous anteromedial surface of the tibia.

Plates should be contoured in order to negotiate with the distal tibial flare and torsion.

HYBRID EXTERNAL FIXATION:

The specific definition of hybrid external fixation is quite ambiguous. The term hybrid denotes no single or universally accepted treatment strategy or device. It is called hybrid fixation because it combines wire fixation technique with pin fixation technique

In periarticular fractures the advantages of using a circular frame, tensioned small wires and external fixator are numerous. The articular wires are placed percutaneously with minimal additional devitalisation of the bone and it's periosteal and endosteal blood supplies. Small tensioned wires allow for the capture of very small metaphyseal and subchondral fragments. There this type of fixation is especially useful in comminuted fractures.

Rotational or Translational deformities also can be corrected as consolidation progresses.

In addition, small tensioned wire fixation allows for early partial weight bearing and mobilization of adjoining joints. It also promotes callus formation by continuous axial movements in the fixation frame.

In this method wires are placed percutaneously in such a way so as not to injure the neurovascular bundles according to Ilizarov's principle. External fixators applied in both sides of tibia are connected with circular frame holding the wires. .

BIO MECHANICS OF THE DEVICES

Intramedullary Nail :-

The nail acts as internal splint and serves as a load sharing device permitting weight bearing across fracture site and allows healing by peripheral callus. It allows axial loads to be transmitted to the opposed ends of fracture fragments.

It helps to regain temporary stiffness followed by callus formation at periphery. Finally a mature bony callus forms restoring the original stiffness. The nail serves to stabilize the fracture fragments and maintain alignments and permits micromotions at the fracture site during functional activities.

In distal tibia fractures, since the distal wider medullary canal allows the distal fragments to be unstable which may lead on to either non-union or angular deformity in coronal or sagittal planes. But the problem can be

overcome by using modified interlocking nailing where the distal locking screw is situated near the tip of the nail and using two distal locking screws in various planes or applying blocking screws or fibular plating. Statically locked interlocking nails do not allow gliding of nail within the bone and control both axial shortening and mal rotation.

Plating Devices :-

1. Conventional Plating
2. Bridge Plating
3. Locking plate

In the presence of comminution or defects in the bone where union is desired a plate attached to two fragments and bridging them can function to neutralize bending or torsional forces.¹⁴

Here union will depend on the formation of a bridging callus rather than the primary bone union. It is only an internal splinting but not a rigid fixation and in larger defects does not provide enough stability. But biplane fixation with plates applied in two planes can provide a rigid fixation preventing both rotational and angular deforming forces.

Bridge plating holds certain advantages over conventional plating

1. The fracture hematoma is not disturbed
2. There is no stripping of periosteum, soft tissues and blood supply to fragments are very minimally disturbed
3. The structure of the bone is homogenous

Plating techniques give a relative stability rather than an absolute stability¹⁴. Stability given by this non compressive technique demands a delayed post- operative rehabilitation programme. Use of removable splints may be necessary for a variable period of time.

All functionally imposed forces must be taken up by the plate alone without any bony contribution. Therefore the system is exposed to alternating tension bending and torsional movements. During the phase of bony consolidation, it can withstand those stresses only if strong plate is used.

Primary bone grafting may or may not be necessary. Occasionally secondary bone grafting may be required.

Hybrid External Fixation :-

Hybrid external fixation system presents mechanical characteristics that sets it apart, significantly from other systems of external fixation. The first fundamental characteristic of the apparatus concerns the type of fixation which may be called solid – elastic; i.e rigid enough for stabilization of fracture and still providing micromotions at the fracture site thus enhancing callus formation. . This technique provides ligamentotaxis, reduction force and maintains the reduction as a neutralization device.

The three theoretical and biomechanical formulations of hybrid external fixators are

1. Minimal damage to vascularity and soft tissues.
2. Solid and yet elastic stabilization of the fracture site .
3. Immediate resumption of functions.

The hybrid external fixators comprises of two separate components interconnected by unique system:

- a) Ring fixator or the ilizarov system
- b) AO external fixator system

Ilizarov Ring Fixator system ⁴

The most important factor governing rigidity of the frame is bone contact. The number of wires governs the torsional stiffness of the frame. The system relies on smooth 1.5 or 1.8 mm 'K' wires under tension to provide the stability needed. The amount of tension depends on the requirements for frame stiffness and weight of the patient. In general tensions of 100 to 130 kgs are recommended to provide sufficient stability and axial loading.

AO external fixator system:

This system allows greater flexibility in setup of a mechanical system to control fracture site motion. The most important factors affecting the rigidity of the frame are the number, diameter, threading and separation of pins across the fracture site, the material, diameter and distance of the side bar from the bone and geometry of the fixator.

The fixation of metaphyseal fragment with 'K' wires and ring fixator system is safer compared to the increased risk of pin pullout in linear fixator.

The fixation of diaphyseal fragment with half pin fixation is safer compared to the increased risk of neurovascular damage with multiple wires fixation.

MATERIALS AND METHODS

Materials:

The present study deals with the analysis of out come of various modalities of treatment of distal tibial fractures depending on the type of fracture, location of the fracture and the status of the soft tissue envelope.

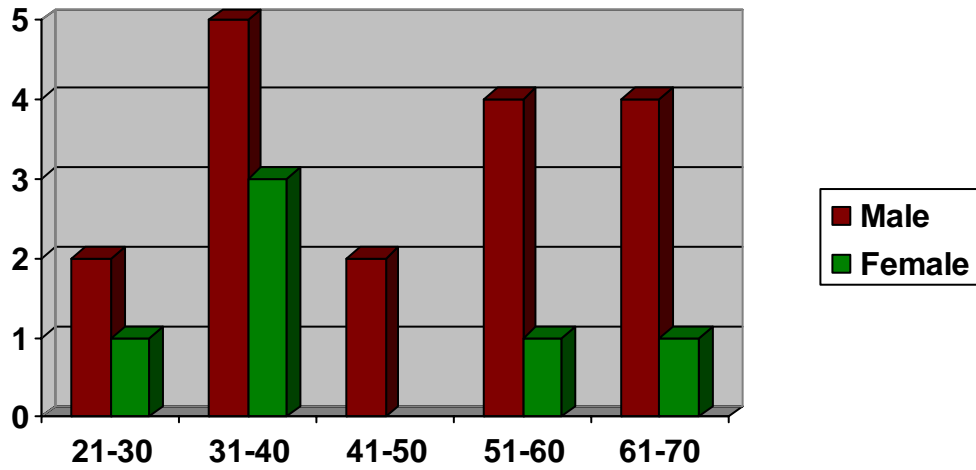
The Study was conducted in Government Royapettah Hospital, Kilpauk Medical College between 2004 – 2006.

Patients admitted with distal tibial fractures with or without intra articular extension and those having closed or open injuries were considered for this study .

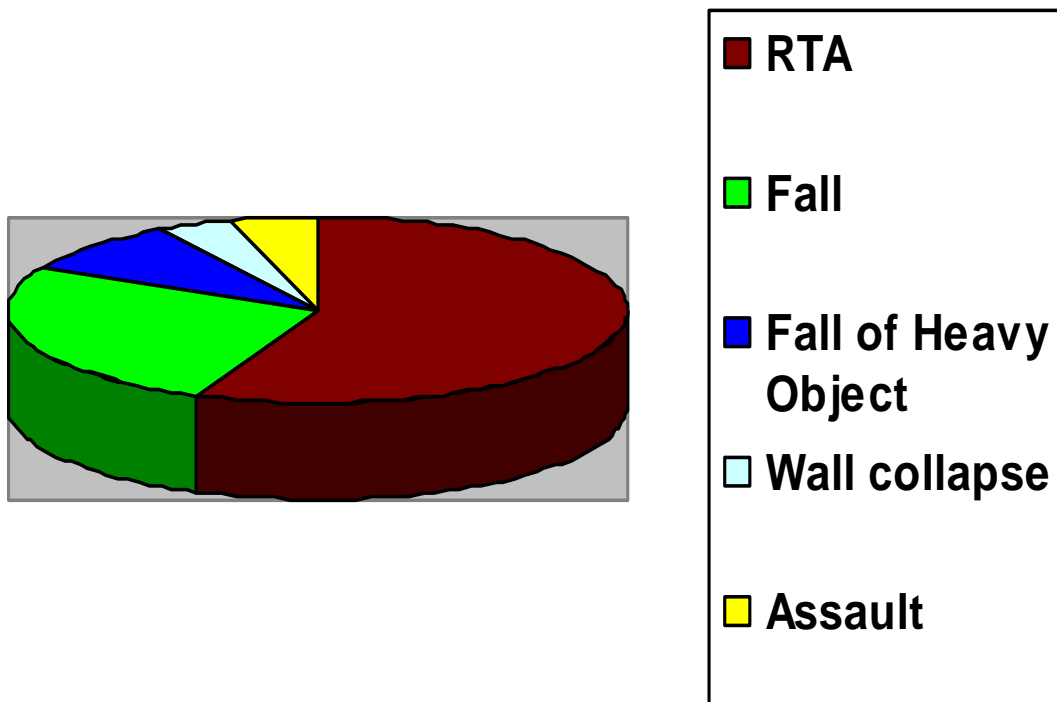
Age / Sex Distribution:

Age Group	Male	Female
21 – 30	2	1
31 – 40	5	3
41 – 50	2	-
51 – 60	4	1
61 - 70	4	1

Distribution of patients According to Age & Sex:



Mode of Injury:



The total number of patients in this study is 23 with their ages ranging from 21 – 70 years with an average of 46.91 years. 3 patients were lost to follow up. Hence, the total number of patients were 20. There were 17 males and 6 females.

Mode of Injury:

RTA	13	56.5%
Fall	6	26%
Fall of Heavy Object	2	8%
Wall Collapse	1	4.3%
Assault	1	4.3%

Associated Injuries:

- 1. Bimalleolar fracture 2
- 2. Hand Injuries 4

Incidence of Open Injuries according to

THE GUSTILO – ANDERSON System :

- 1. Grade I 6
- 2. Grade II 3
- 3. Grade III
 - A 1
 - B
 - C

The patients with symptoms suggestive of distal third tibial fractures are examined both clinically and radiologically after initial resuscitation.

Antero - Posterior radiographs of the affected leg with knee and ankle joints taken. All fractures were classified according to AO system. There were totally 13 patients in type A, 3 patients in type B and 7 patients in type C.

The open fractures were classified according to GUSTILO – ANDERSON System. Out of which 5 patients were grade 1, 3 were grade 2 and 1 was grade 3A.

Initially patients were immobilized in POP Splints.

In open injuries, thorough wound wash and debridement was done and calcaneal pin traction was applied.

Patients with open injuries, being received in the casualty was given intravenous antibiotics.

In five patients with open injuries and severe comminution, Hybrid external fixation was done; whereas, in another five patients with closed, simple fractures interlocking nailing⁵ was done.

Patients with closed injuries with severe comminution away from the tibial plafond were treated with Bridge plating technique.

Patients associated with medical diseases (not fit for anesthesia) and those not willing to undergo surgical procedures were treated conservatively either by POP immobilization or pin traction technique according to the soft tissue status of their lower legs.

The range of follow up varies from 6 months to 16 months

Associated Injuries:

Ankle injuries were commonly associated. 2 patients had bimalleolar fractures and 2 had closed hand injuries.

Case incidence according to AO Classification

A1	.1	3	B1	.1	1	C1	.1	3
	.2			.2			.2	
	.3			.3			.3	
A2	.1	3	B2	.1	2	C2	.1	3
	.2	1		.2			.2	
	.3			.3			.3	
A3	.1	6	B3	.1		C3	.1	1
	.2			.2			.2	
	.3			.3			.3	

Methods:

All patients having distal third tibial fractures were admitted and evaluated for co-morbid conditions.

Routine investigations are done for anesthetic fitness and also to rule out systemic illness. Associated medical conditions were treated by corresponding specialists.

The patients were maintained in POP and calcaneal pin traction in the case of compound fractures.

Patients with compound fractures were treated with broad spectrum antibiotics.

The time of surgery varied from 5 days to 25 days.

There were 10 open injuries, of which there were 6 – Grade 1; 3 – Grade 2 and 1-grade 3 open injuries.

Those 5 patients who were not willing to undergo surgical procedures were treated conservatively by applying POP after 3 weeks of pin traction and check x-ray.

6 patients with comminution (OA type A3.1/A2.2) in their diaphyseal metaphyseal region were treated with Bridge plating after their swelling subsided and wound healed. The range of period for taking the patient for surgery was 5 to 10 days. This was effectively done by means of limb elevation, ice packing in the immediate period after injury, good wound management and immobilization. 1 patient who was treated with conventional plate osteosynthesis lost to follow up.

6 patients with fractures of OA type A1.1 / A2.1 were treated with interlocking nailing. The range of preoperative period was 5 to 10 days. 1 patient not turned for follow up.

5 patients with OA type B.3.3 / C1.1 / C2.1 / C 3.2 were treated with Hybrid external fixation.

Surgical Procedures:

1. Interlocking nailing ;

Anesthesia : Spinal Anesthesia

Position : Supine with knee in 90⁰ flexion at the edge
of the table

Incision : Vertical midline incision extending from the inferior pole of the patella to the tibial tuberosity

Approach : Midline, patellar tendon splitting

Nail Entry : 1 – 1.5 cm below the joint line. After making entry point using a curved awl, guide wire inserted. After fracture reduction and serial reaming premeasured - size nail inserted. Guide wire withdrawn

Interlocking the nail : Two distal screws were applied by using a jigscrew position through the nail confirmed by using the guide wire and check x-rays. Proximal locking done through the jig.

Open reduction of the fracture done, when closed method fails.

Pre operative antibiotics :

1 gram of third generation cephalosporin antibiotic was given intravenously preoperatively and followed by three days of postoperative period twice in a day.

Vacuum suction drain was used for 2 days.

2. Plate Osteosynthesis;

Anesthesia : Spinal Anesthesia

Position : Supine with a sand bag beneath the ipsilateral buttock to facilitate to bring the lower limb into neutral / internal rotation position.

Conventional plating;

Incision : Vertical Incision just 1 cm lateral to the shin line centering the fracture site

Approach : 1 cm lateral to the shin line lateral compartment muscles separated from the tibia

Plating : After fracture reduction and alignment appropriate size contoured DCP or LC – DCP was applied and fixed with cortical screws.

Bridge Plating;

Incision : Two small vertical incisions proximally and distally to the fracture were made lateral to

the shin line, according to the length of the
plate

Approach : Through these two vertical small incisions,
by blunt dissection muscles from their
attachments with tibia were separated.

Plating : Fracture reduced in closed manner.
Plate fixed with the bone using
cortical screws and by making nicks
for their entry. Screws were placed little far
away from the fracture site.

Above knee cast was applied post operatively particularly in patients
treated with Bridge Plating technique.

3. Hybrid External Fixation;

Anesthesia : Spinal Anesthesia

Position : Supine Position

Procedure : Two cross 'K' wires not within 3 cms of the

Tibial plafond were inserted horizontally and connected

with a full ring and tensioned. On either sides of tibia two sets of external fixators were applied in the proximal tibial segment. After fracture reduction these two external fixators were connected with the ring fixator by using male posts,nuts and fixation bolts.⁶

In cases of fractures involving articular surfaces additional half ring is applied to the calcaneum by using a 'K' wire through it. Thus, ankle and subtalar movements immobilized.

All pin sites were dressed with gauze wicks soaked in betadine solution.

Post – Operative Mangement:

1. Interlocking nailing;

In non-compliant patients or patients with axially unstable fixation, AK Slabs were applied until enough healing occurs to ensure stability. In other patients knee and ankle mobilization were started from the next day. Weight bearing was restricted till callus appear. Then weight bearing was started as tolerated by the patient.

2. Plating:

All patients treated with Bridge plating technique were given AK Slabs. After 3 weeks when evidence of union begins to appear BK braces were applied and knee and ankle motion exercises were started in these cases. Weight bearing restricted till the callus was completed.

3. Hybrid External Fixation:

All patients treated with this technique were allowed to weight bear after 3 weeks as and when the callus is seen. Patients without articular fractures were given knee and ankle mobilization exercises from their first post operative day.

Complications:

Intra operatively two patients had hypotension and in one case instrumental failure because of which second distal interlocking screw was not applied. Post operatively we encountered mainly wound infection, pin site infection, malunion and knee and ankle joint stiffness.

Analysis
of
Results

ANALYSIS OF RESULTS

The outcome of treatment of distal tibial fractures, is most affected by the severity of injury, management of the fracture and occurrence of certain complications.

There are no uniformly accepted criteria for rating results. A number of factors are important for assessing results of tibial shaft fractures. Most reports omit one (or) more of them.

For example Anderson et al., used only shortening and angulation to classify results of treatment into categories of excellent, good, fair, and poor. He rejected range of motion of the ankle joint as a criteria.

However Horne and Colleagues with Hutching found ankle motion was a major determinant of functions.

Various Criterias

Bauer and Colleagues

They classified the outcome into two grades:

Good → Minimal (or) no complaints, full (or) slightly limited function

Fair → Major complaints: nonunion, wound discharge, amputation (or) poor function of knee or ankle.

EDWARDS expanded on this scheme and used eight different parameters plus non-union, osteomyelitis and amputation to classify results. His system considers pain, ability to work, gait, sports activity, motion of knee, foot and ankle. Notable absence is any reference to deformity.

Criteria which was proposed by JOHNER and WRUH (1983) has now become widely accepted. It includes the various criteria proposed by Edwards along with the reference to various deformities.

This criteria considers non union, osteitis, amputations, neuro vascular disturbances, deformity – varus / valgus, anteversion / recurvation, rotation, shortening, mobility of knee, ankle, subtalar joints, pain, gait and strenuous activity.

We have also followed this classification in our study.

		Excellent	Good	Fair	Poor
1.	Non union, Osteitis, amputations	None	None	None	Yes
2.	Neurovascular Disturbances	None	Minimal	moderate	Severe
3.	Deformity – varus / valgus	None	2 ⁰ – 5 ⁰	6 ⁰ - 10 ⁰	>10 ⁰
	Anteversion / Recurvation	0 ⁰ – 5 ⁰	6 ⁰ - 10 ⁰	11 ⁰ - 20 ⁰	>20
	Rotation	0 ⁰ – 5 ⁰	6 ⁰ - 10 ⁰	11 ⁰ - 20 ⁰	>20
	Shortening	0 – 5mm	6 - 10mm	11 – 20 mm	>20mm
4.	Mobility - Knee	Normal	> 80%	> 75%	>75%
	Ankle	Normal	>75 ⁰	<50 ⁰	<50 ⁰
	Subtalar joint	>75%	>50%	<50%	

5.	Pain	None	Occasional	Moderate	Severe
6.	Gait	Normal	Normal	Insignificant Limp	Significant Limp
7.	Strenuous Activities	Possible	Limited	Severely Limited	Impossible

Non union, Osteitis, Amputation:

No patient in our study had non-union or amputation. However two patients had osteitis and deep infection. In one patient infection settled after nail removal and anti biotics. Another patient is on treatment at present.

Neuro vascular Disturbances:

No patient had developed neurovascular complications in our study.

Deformity:

- 5 patients had varus / valgus deformity ranging $2^0 - 5^0$.
- 4 patients had varus / valgus deformity ranging $6^0 - 10^0$.
- No anteversion or recurvation deformity noted
- Shortening measuring 0.5cm found in 3 patients and 1cm shortening was noted in two patients.

Mobility:

Knee:

- 13 patients had full range of movements.
- 8 patients it was >80%.
- 1 patient had <75⁰ of knee mobility.

Ankle

- 8 patients had >75% of normal movements.
- 3 patients had <50% of Ankle movement.

Subtalar Joint:

- All patients had regained almost normal range of subtalar movement except for 3 patients who had <50% of normal.

Pain:

- Five patients with interlocking nailing had anterior knee pain.
- 10 patients had occasional pain at the fracture site for 2 months.
- 4 patients had moderate amount of pain at the fracture site for 1 month.

- 3 patients had severe pain at the fracture site, which disturbed their sleep and activities of daily life for 15 days.

Gait:

Gait was near normal in almost all patients except 3 patients who complained of significant Limp. 2 of them had been treated conservatively

Strenuous Activities:

16 patients were able to do strenuous activity and it was severely limited in 4 patients.

In comparing our results we have used general features like time to union and infection rate.

The incidence of deep infection rate in our study may be due to more numbers of open reduction performed and increased exposure of fracture site to the environment.

The mean time of union in many literatures is around 5 months (2 – 8 months) which is the same in our study.

WU cc, Shih C in their article in

J.Trauma 1993 June: 34(6) 792-796 reported union rate at 85.7%, 14.3% non union and 7.2% deep infection which is 70%, 0%, 8.2% in our study.

The variation in the results of functional out come in various modalities reflects the difficulties in distal third tibial fractures management.

In our study we observed 69.55% (16) excellent or good results, 17.39% (4) showed fair results and 13.04% (3) of poor results.

The poor out comes were associated with either technical difficulties
or the presence of other injuries (or) associated co-morbid conditions.

Discussi

on

DISCUSSION

In between August 2004 and November 2006, 23 fractures of distal tibia were treated.

In all cases, treatment was individualized depending on the type, nature of the wound, time of presentation, associated injury and the available facilities of treatment.²

The different modalities of treatment were interlocking nailing³ plating; Hybrid external fixation and conservative method.

In our study 25% of patients were in the age group between 31 – 40 years. There was also a higher percentage of involvement of males most probably due to their increased involvement in out door activities and also road traffic accidents.

The incidence of type A was found to be high and there was a higher incidence of open fractures associated with type C fractures which exposes the high velocity nature of this injury and this adds to the difficulty in the management of type C fractures. This is also shown by the higher incidence of type A3 fractures.

In most of the patients the initial management is closed reduction and POP slab application and few others were initially managed by calcaneal pin traction or by external fixation.

About fifty percent of the patients had open injuries which delayed the definitive surgical procedures. Conservative treatment included either closed manipulative reduction or POP application. POP was used for patients who were not willing to undergo surgical procedures or with associated co-morbid conditions which deferred them for anesthetic fitness. Conservative management is associated with high incidence of valgus / varus deformities due to incomplete reduction and to joint stiffness due to prolonged immobilization in Above knee cast.

Calcaneal pin traction had been advocated by Robert.E. Leach. We have found this procedure to be very usefull in our set up in cases of gross displacement and overlapping of fragments. It is also useful in holding the fracture which awaits soft tissue healing prior to bony surgery. We have found this useful in fractures of the tibial plafond and we have not seen any increase in the incidence of infection in any surgeries after calcaneal pin traction.

Regional anesthesia was preferred in all cases due to the decreased incidence of complications and extended post operative analgesia.

In our study we have found that surgical treatment considering soft tissue status and fracture pattern & location give better results than conservative management especially where the articular fragments cannot be well controlled.

We found that inter locking nailing gives better results in the presence of minimal soft tissue injury, minimal comminution and without articular involvement.

In the presence of minimal soft tissue injury, severe comminution and without articular involvement we preferred plate osteosynthesis especially Bridge plating technique, when the fracture location was well above the articular surface.

In the presence of extended articular comminution and severe soft tissue injury we had better results with application with Hybrid external fixation.

There were certain advantages and disadvantages when comparing others:

1. Less tissue damage during interlocking nailing and better stability was achieved. But, technical difficulty was encountered when there was comminution of fragments.
2. Bridge plating gives relative lesser stability, but the fracture hematoma was not disturbed. But this technique needed relatively prolonged immobilization than others, which might have resulted ankle joint stiffness in certain cases⁵.

Hybrid external fixation technique was unopposedly used in cases with severe soft tissue damage where plating is ruled out and cases with articular comminution. Here the fragments were held together by tensioned 'K' wires and stability was achieved by external fixation in the proximal tibial fragment.

In this method it was difficult to manage open injuries which needed split skin grafting or rotation flap covers which was

impeded by the crisscross wires. However, we had to resort to this method in the presence of open injuries.

In all cases sutures were removed by 10th post-operative day.

Patients were allowed to weight bear once callus appeared and then was progressed as tolerated.

Average time for partial weight bearing was 8 (6-10) weeks except in cases with plating where it is delayed by 14 (12-16) weeks and average time for clinical and radiological union was 5 (3-8) months.

Post operative infection noticed in 6 patients out of which 5 had superficial infection which settled after local dressing and appropriate antibiotics.

One patient had deep infection involving bone.

Average duration of hospital stay was 45 days (2 weeks-6 weeks).

Overall 60% patients had regained full range of movements of knee and ankle.

18% patients had varus/ valgus deformity 6-10 degrees –
Treated with interlocking nailing .

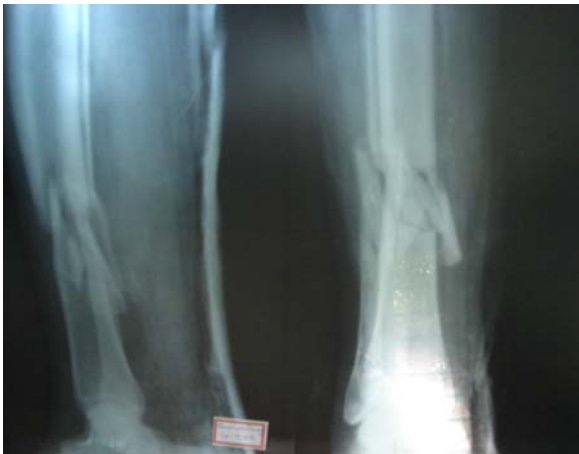11 patients had excellent or good outcome whereas 7 patients had fair outcome and 2 showed poor results.

CONCLUSION

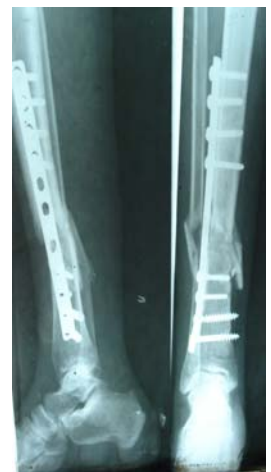A short series of results of various modalities of management of distal tibial fractures were analyzed and the overall results including quality of reduction, functional recovery and the presence or absence of complications have led to us to individualise the option of treatment according to the status of the soft tissue, fracture location; fracture pattern and articular involvement.

We are aware of the fact that the number of patients and duration of study may not give us the liberty to conclusively arrive at a protocol and might need a more elaborate study for standardization of the different methods available for the management of fractures of distal tibia.

PATIENT NO:1

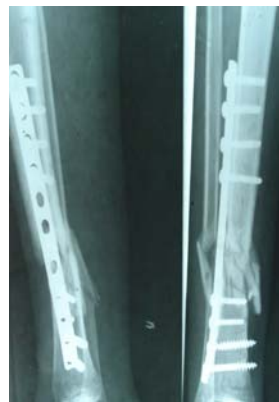

PRE - OP

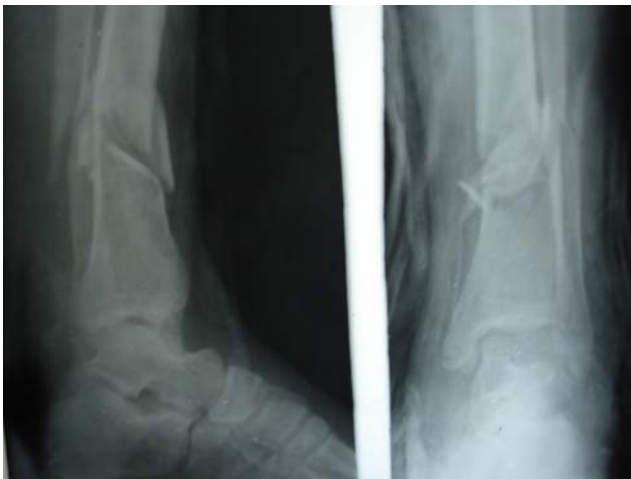

IMM.POST - OP

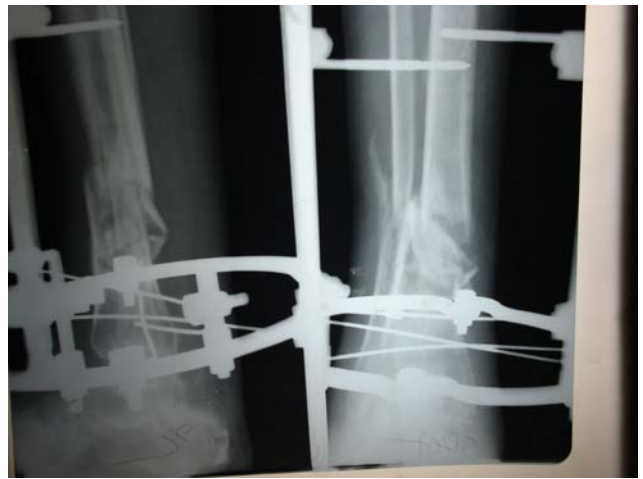3 MONTHS POST - OP



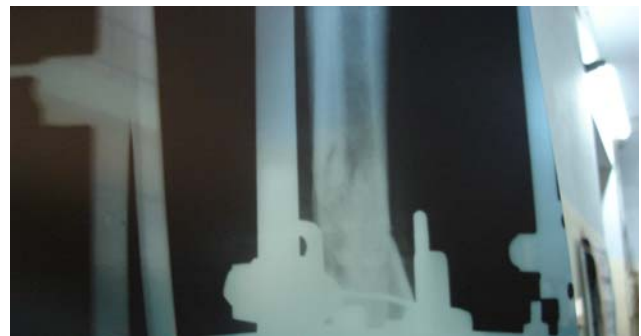PATIENT NO:2



PRE - OP

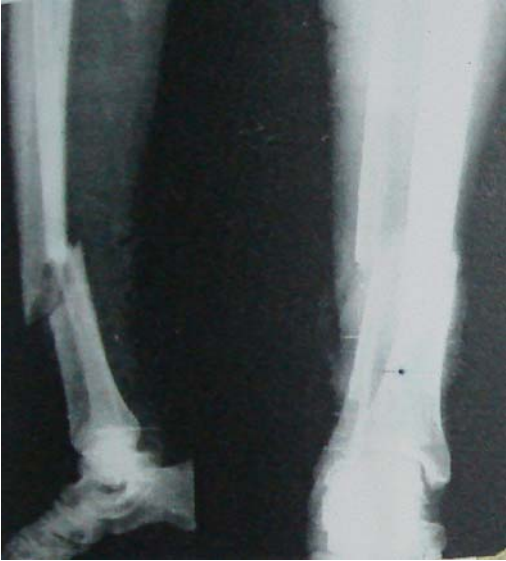

IMM.POST - OP

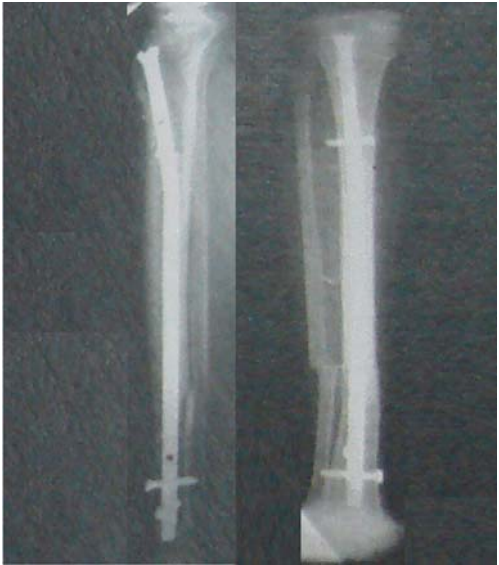

2 MONTHS POST - OP

PATIENT NO:3

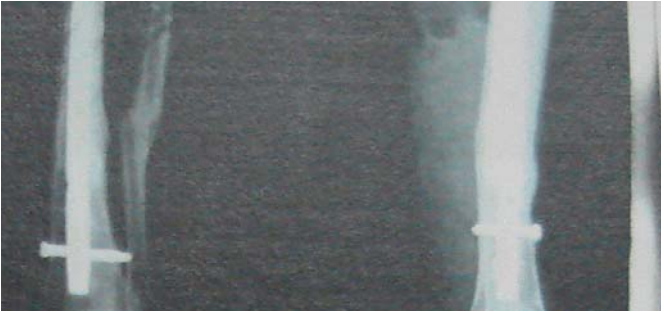

PRE - OP



IMM.POST - OP

3 MONTHS POST - OP



6 MONTHS POST - OP



CASE PROFORMA

1. CASE 3

NAME: Govindasamy **Age:** 36 **sex:** male

Occupation: Business

Mode of injury: Road traffic accident

Type of fracture: AO type -A 3.1

Associated injuries: NIL

Management:

Immediate: Closed manual reduction and AK slab application

Surgery: Bridge plating for tibia

Post operative period: Uneventful

Time to return to work: 5 months

Follow up period: 7 months

Result: Excellent

2. CASE 6

NAME: Latha **Age:** 33 **sex:** Female

Occupation: House wife

Mode of injury: Assault

Type of fracture: AO Type B 3.3

Associated injuries: -

Management:

Immediate: AK Slab / calcaneal pin traction

Surgery: Hybrid external fixation

Post operative period: Uneventful

Time to return to work: 5 months

Follow up period: 16 months

Result: Good

3. CASE 8

NAME: Ulakki **Age:** 60 **sex:** Female

Occupation: Labourer

Mode of injury: Fall

Type of fracture: AO type A 2.1

Associated injuries: -

Management:

Immediate: AK Slab / calcaneal pin traction

Surgery: Interlocking Nailing

Post operative period: Uneventful

Time to return to work: 5 months

Follow up period: 6 months

Result: Good

4. CASE 10

NAME: Subramani **Age:** 70 **sex:** Male

Occupation: Pensioner

Mode of injury: Road Traffic Accident

Type of fracture: AO type B 1.1

Associated injuries: -

Management:

Immediate: AK Slab / calcaneal pin traction

Surgery: -(Conservatively managed)

Post operative period: -----

Time to return to work: 9 months

Follow up period: 10 months

Result: Poor

2. Bedi A, Le TT, Karunakar MA, - Surgical treatment of non articular distal tibia fractures – J.Am. Acad. Orthop.Surg.; 2006 Jul;14(7): 406 – 416.
3. ZELLE Boris A; BHANDARI Mohit ; ESPIRITU Michael, KOVAL Kenneth J. ; ZLOWODSKI Michael – treatment of distal tibia fractures without articular involvement – J.Ortho. Trauma 2006; Vol 20 : P76 – 79.
4. Egol KA, Weisz R, Hiebert R; Tejwani Nc, Koval KJ; Sanders RW – Does Fibular plating improve alignment after intramedullary nailing of distal metaphyseal tibial fractures? – J.Ortho. Trauma 2006 ; Feb 20 (2) ; 94 – 103.
5. Im GI; Tae SK – Distal metaphyseal fractures of tibia : A prospective randomized trial of closed reduction and plate and screw fixation – J.Trauma 2005; Nov; 59 (5) 1219 – 1223.
6. Lee PT , Clarke MT; Bearcroft PW; Robinson AH – The proximal extent of the ankle capsule and safety for the insertion of percutaneous fine wires – JBJS 2005 May 87 (5); 668 – 671.
7. Antoci V; Voor MJ, Seligson D, Roberts CS – Biomechanics of external fixation of distal tibial extra articular fractures : Is spanning the ankle with a foot plate desirable? – J.Ortho. Trauma 2004 Nov – Dec 18(10) ; 665 – 673.

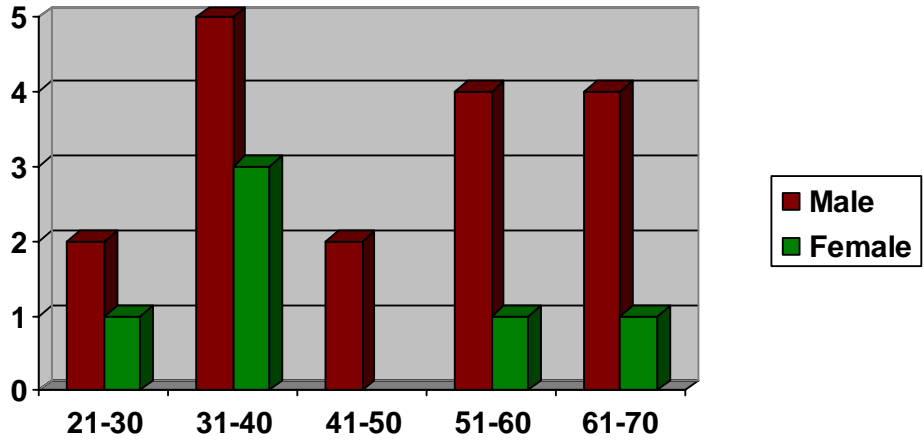
8. Vora AM; Haddad SL, Kadakia A, Lazarus ML; Merk BR – Extra capsular placement of distal tibial transfixation wires – JBJS . Am. 2004 May ; 86 – A(5) 988 – 993.
9. Kumar A, Charle bois SJ; Cain EL, Smith RA; Daniels AU; Crates JM – Effect of fibular plate fixation on rotational stability of simulated distal tibia fractures treated with intra medullary nailing – JBJS . Am. 2004 Jan 86 A(1); 604 – 608.
10. Gorczyca JT, Mckale J, Pugh K; Pienkovski D – Modified tibial nails for treating distal tibia fractures – J.Ortho. Trauma 2002 Jan 16 (1) ; 18 – 22.
11. Vives MJ; Abidi NA, Ishikawa SN; Taliwal RV, Sharkey PF – Soft tissue injuries with the use of safe corridors for transfixation wire placement during external fixation of distal tibia fractures – J.Ortho. Trauma 2001 Nov 15 (8) : 555 – 559.
12. Krettek C; Stephan C, Schandelmaier P, Richter M, Pape HC; Miclau T – The use of poller screws as blocking screws in stabilizing tibial fractures treated with small diameter intramedullary nails – JBJS Br. 1999 Nov 81(6) ; 963 – 968.
13. Hutson JJ Jr, Zych GA – Infection in Peri articular fractures of the lower extremity treated with tensioned wire hybrid fixators – J.ortho. Trauma 1998 Mar – Apr 12(3) ; 214 – 218.

14. Bone L; Stegemann P, McNamara K, Seibel R – Ext. Fixation of Severely communited and open tibial pilon fractures – Cl. Ortho 1993, Vol 292; No 101 – 107.
15. Enders T, Grass R, Biewener A, Barthel S, Zwipp H – Advantages minimally invasive reposition, retension and hybrid ilizarov fixation for tibial pilon fractures – Unfallchirurg ; April 2004 – Vol 107 (4) ; No. 273 – 284
16. Kevin J Pugh ; Philip R Wolinsky, Mar P Mc Andrew, Kenneth D Johnson ; Tibial pilon fractures a comparision of treatment methods - Journal of Trauma 1999, Vol 47, No. 937 – 941.
17. Rocco Barbieri; Richard Sahenk, Kenneth Koval, Kevin Anrori, Brian Aurori, Hybrid External fixation in the treatment of tibial plafond fractures – Cl. Orthopaedic & related research. 1996 Vol 332 , No. 16 to 22.
18. Reudi TP; Allgower M – The operative treatment of intra articular fractures of lower end of tibia Cl. Orthopaedic & related research 1979 Vol 138, No. 105 to 110.
19. Alexander, LeeMcGregor, D.J. Duplesis – A synopsis of surgical anatomy – blood supply to the bones page no. 412 to 415.
20. Results of locking intramedullary nailing in distal tibial shaft fractures – boos N, I. Unfallchirug, 1989, spe 92 (a), 453 – 458.

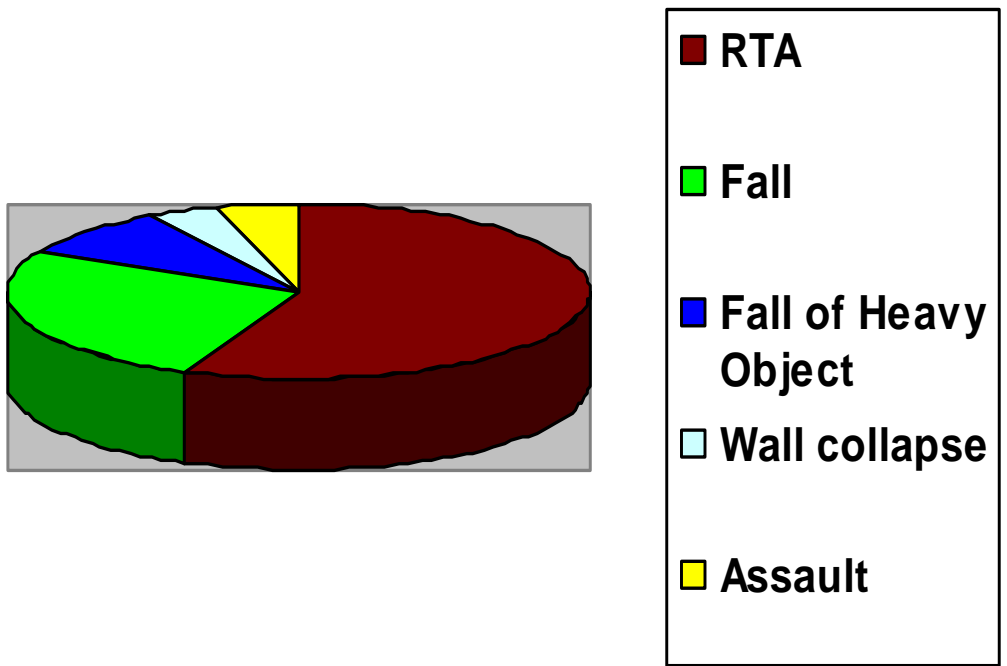
21. JBJS Br. 1995 sep. 77 (5) ; 781 – 7, “Distal metaphyseal fractures of the tibia with minimal involvement of the ankle classification and treatment by locked intramedullary nailing”.
22. Rockwood and Green- Charles M. Court Brown. Fractures in adults, Vol 2 , 1939 to 1994, fifth edition.
23. Bonneville P, Savoritt, Combes J.M., Rungieres M, Bellumore Y, Mansat M.R.V. Chr, Ortho. Reparatrice 1996, 82(9) 428 – 36 (Article in French)
24. Kempf, K.S. Leung – Editors. Practice of Intra medullary nailing principles. P. 5 – 49, 2002.
25. Thomas P. Ruedi, William M, Murphy – A.O. Principles of fracture management, 2000, P. 519 to 536.
26. Bourne R.B. Rorabeck, C; and Macnab, J, Intra articular fractures of the distal tibia – the pilon fracture J. Trauma 23:591 to 596, 1983.
27. Denham R.A. (1964): Internal fixation unstable ankle fractures, Journal of Bone & joint surg. 46-B, 206-211.
28. Franklin J.L. Johnson K.D. & Hansen S.T. Jr. : Immediate Internal Fixation open ankle fractures – JBJS (Am) 66 : 1349 to 1356 1984.
29. Muller M.E : Allgower M, Schneider R and Willengger H – manual of internal fixation.
30. Ram Chaddha et. al – sliding plate / interlocking plate in complex trauma – may 1995.

31. John Royal Moore MD. – Bridging of bone defects in compound wounds JBJS – volume 24 No.2, July 1944 P. 455 – 469.
32. Konrath G, Moed BR, Watson JT, Kaneshiro S, Karges DE, Cramer KE, Intramedullary nailing of unstable diaphyseal fractures of the tibia with distal intra articular involvement – J.Ortho Trauma. 1997 : 11 : 200 to 205
33. Kretek C, Miclau T, Schandelmaier P, Stephan C, Mohlmann U, Tscherme H. The mechanical effect of blocking screws in stabilizing tibia fractures with short proximal or distal fragments after insertion of small diameter intramedullary nails. J.Ortho Trauma 1999 : 13:550 – 553.

Distribution of patients According to Age & Sex:



Mode of Injury:



MASTER CHART

S.No	Name	AGE	SEX	Mode of Injury	SIDE	Occupation	AO type	Asso. Injuries	Skin Cond.	Initial treatment	T.I. between Injury & Surgery	Type of Definitive Treatment	P.O. Compl.	Hosp. Stay	P.O. Management	P.O. Rehabilitation (in Weeks)			T.I. to return to work (in Months)	Follow up Period (in Months)	Radiological & Clinical Evaluation
																NWB	PWB	FWB			
1.	Kadhirvel	22	M	RTA	R	Electrician	C 1.1	-	Gr. I Open Lateral	AK slab / CPT	5 Days	Fibular Plating & Hybrid fixation	-	10 Days		8	12	16	5	9	Fair
2.	Mannu	70	M	Wall Collapse	L	Pensioner	C 1.1	Bimall collar #	Fair	AK slab / CPT	15 Days	Fibular Plating & Hybrid fixation	Pin site infection	25 Days		6	12	16	7	10	Fair
3.	Govinda Samy	36	M	RTA	L	Business	A 3.1	-	Gr.I Medial	AK slab / CPT	10 Days	Bridge plating for tibia	-	20 Days	BK Slab	12	16	20	5	7	Good
4.	Chinna Kulandai	65	F	Fall	R	Labourer	A 1.1	-	Fair	AK slab / CPT	5 Days	IL nailing	-	18 Days	BK Slab	8	Lost to follow up				
5.	Sivandhi	35	F	Fall	R	Housewife	A 1.1	-	Fair	AK slab / CPT	7 Days	IL nailing	-	20 Days	-	8	12	16	4	6	Good
6.	Latha	33	F	Assault	R	Housewife	B 3.3	-	Fair	AK slab / CPT	8 Days	Hybrid fixation	-	20 Days		2	6	16	5	16	Good
7.	Ramesh	35	M	RTA	L	Business	A 3.1	-	Fair	AK slab / CPT	5 Days	Plate osteosynthesis	-	18 Days	BK Slab	Lost to follow up					
8.	Ulakki	60	F	Fall	L	Labourer	A 2.1	-	Fair	AK slab / CPT	10 Days	IL nailing	-	20 Days	-	8	16	20	5	6	Good
9.	Balu	33	M	RTA	L	Business	C 3.2	Bimall collar #	Gr.III Open Injury	AK slab / CPT	25 Days	Hybrid fixation	Pin site infection	40 Days		10	14	20	8	11	Poor

MASTER CHART

S.No.	Name	AGE	Sex	Mode of Injury	SIDE	Occupation	AO type	Asso. Injuries	Skin Condn.	Initial treatment	T.I. between Injury & Surgery	Type of Definitive Treatment	P.O. Compl.	Hosp. Stay	P.O. Management	P.O. Rehabilitation (in Weeks)			T.I. to return to work (in Months)	Follow up Period (in Months)	Radiological & Clinical Evaluation
																NWB	PWB	FWB			
10	Subramani	70	M	RTA	R	Pensioner	B 1.1	-	Fair	AK Slab / CPT	-	Conservative	-	22 Days	PTB Cast	20	24	28	9	10	Poor
11	Narayanan	58	M	Fall of Heavy Object	R	Labourer	C 1.1	-	Fair	AK Slab / CPT	-	Conservative	Pin site Infection	20 Days	PTB Cast	18	22	26	7	8	Fair
12	Jayabal	54	M	RTA	L	-	C 2.1	# Distal Radius - Lt	Gr.I Open Injury	AK Slab / CPT	-	Conservative	-	22 Days	PTB Cast	Lost to follow up					
13	Vasuki	28	F	RTA	R	House wife	A 3.1	-	Fair	AK Slab	7 Days	Plate osteosynthesis	-	15 Days	BK Slab	10	12	16	4	6	Good
14	Achudha Raman	62	M	RTA	R	Painter	A 2.1	-	Gr.I Open Injury	AK Slab	10 Days	IL nailing	-	16 Days	-	8	13	16	5	7	Good
15	Kalimuthu	50	M	RTA	L	-	C 2.1	-	Gr.I Open Injury	AK Slab / CPT	-	Conservative	-	10 Days	BK Slab	10	14	18	7	9	Fair
16	Subba Raj	30	M	RTA	L	-	A 2.1	# Base of 2 nd MC - Lt	Fair	AK Slab	7 Days	IL nailing	-	23 Days	-	8	12	16	5	7	Good
17	Rama chandran	70	M	Fall	r	Pensioner	B 2.1	-	Gr.II Open Injury (Medially)	AK Slab / CPT	-	Conservative	-	25 Days	-	10	14	20	8	10	Fair

MASTER CHART

S.No.	Name	AGE	Sex	Mode of Injury	SIDE	Occupation	AO type	Asso. Injuries	Skin Cond.	Initial treatment	T.I. between Injury & Surgery	Type of Definitive Treatment	P.O. Compl.	Hosp. Stay	P.O. Management	P.O. Rehabilitation (in Weeks)			T.I. to return to work (in Months)	Follow up Period (in Months)	Radiological & Clinical Evaluation
																NWB	PWB	FWB			
18	Muthu Krishnan	40	M	Fall of Heavy Object	R	-	A 3.1	-	Fair	AK Slab / CPT	10 Days	Bridge Plating	-	25 Days	BK Slab / Splint	10	14	20	6	7	Good
19	Sankaran	55	M	RTA	L	Business	C 2.1	-	Gr.II Open Injury	CPT	15 Days	Hybrid fixation	-	20 Days	-	10	14	20	5	8	Fair
20	Chandra	37	F	Fall	R	House wife	A 3.1	-	Fair	AK Slab	5 Days	Bridge Plating	-	17 Days	BK Slab	7	12	20	5	8	Fair
21	Shanmugam	60	M	Fall	R	-	A 2.2	-	Fair	AK Slab	7 Days	Plate osteosynthesis	-	19 Days	-	5	12	16	5	7	Good
22	Ramasamy	45	M	RTA	L	Business	A 3.1	# Distal Radius - Lt	Gr.I Open Injury (Medially)	AK Slab	7 Days	Bridge Plating	-	20 Days	BK Slab	10	14	20	5	8	Good
23	chidambaram	32	M	RTA	L	Carpenter	A 1.1	# 2 nd MC - Lt	Gr.II Open Injury (M / 3 Leg)	AK Slab	10 Days	IL nailing	-	22 Days	-	8	12	16	4	6	Good