



# Glandular Epithelium

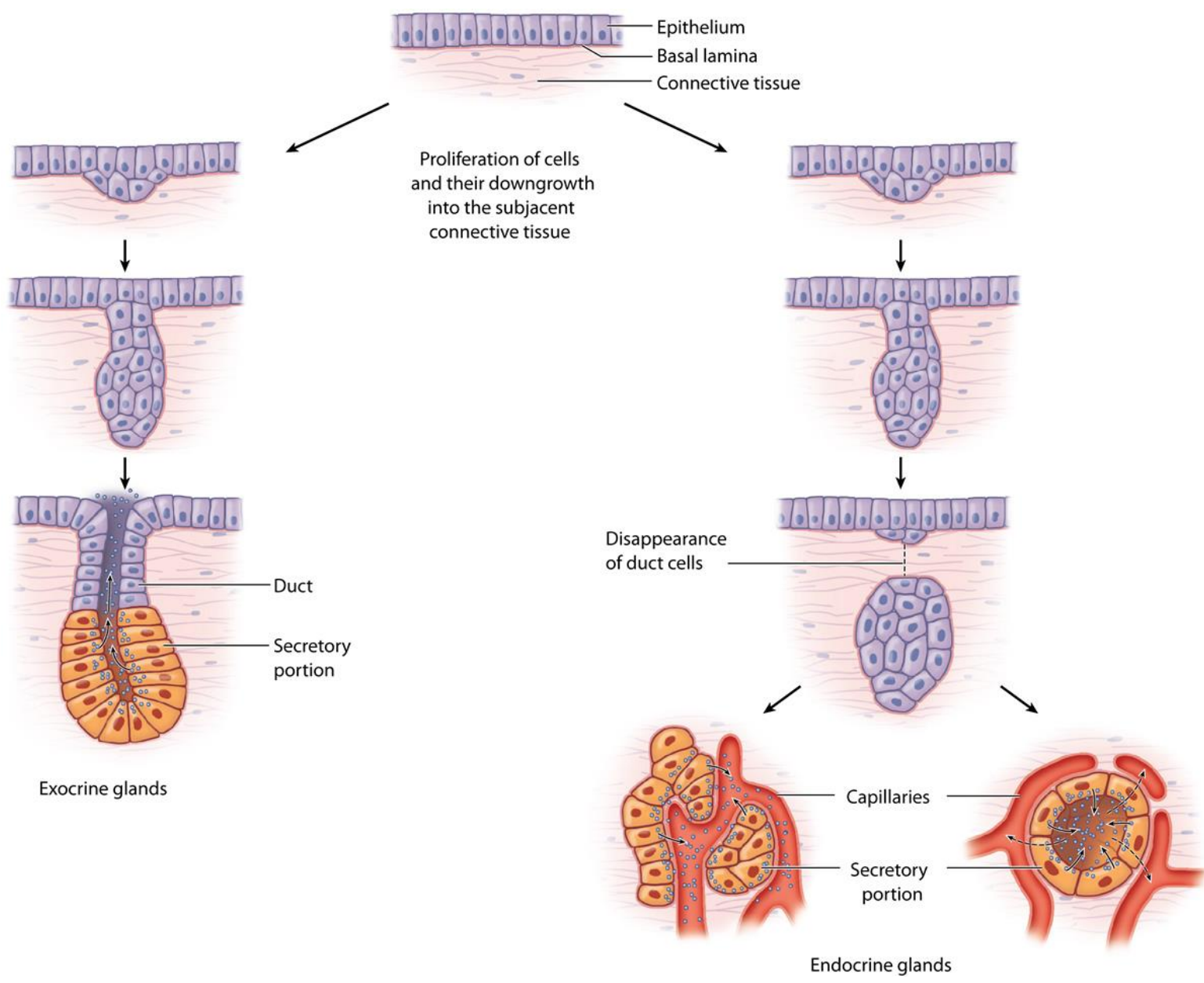
Hanan Jafar BDS.MSc.PhD

# Glands

- “Glandular epithelia are tissues formed by cells specialized to produce secretion.”
- **Secretion**: if substances produced are used elsewhere in the body, they are called secretions.
- **Excretion**: if products are discarded from the body, they are known as excretions.

# Glands

- Glandular epithelial cells may synthesize, store, and secrete proteins (e.g. pancreas), lipids (e.g. sebaceous glands), or complexes of carbohydrates and proteins (e.g. salivary glands).
- The mammary glands secrete all 3 substances.
- Some glands have low synthesizing activity (e.g. sweat glands). They secrete mostly substances transferred from the blood to the lumen of the gland.



# Development of glands:

- Glands develop as invaginations of covering epithelia. Epithelial cells proliferate and penetrate connective tissue. They may—or may not—maintain contact with the surface. When contact is maintained, **exocrine glands** are formed; without contact, **endocrine glands** are formed.

# Classification of glands:

- **Exocrine glands**

(Gr. Exo, outside,+ krinein, to separate) release their products onto an epithelial surface, either directly or through a duct e.g. the salivary glands.

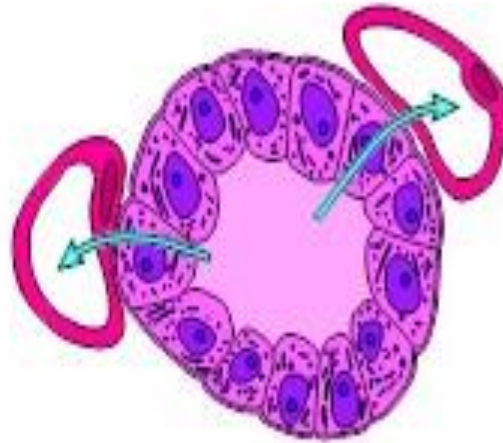
- **Endocrine glands**

(Gr, endon, within,+ krinein) release their products into the blood stream (ductless), e.g. thyroid gland.

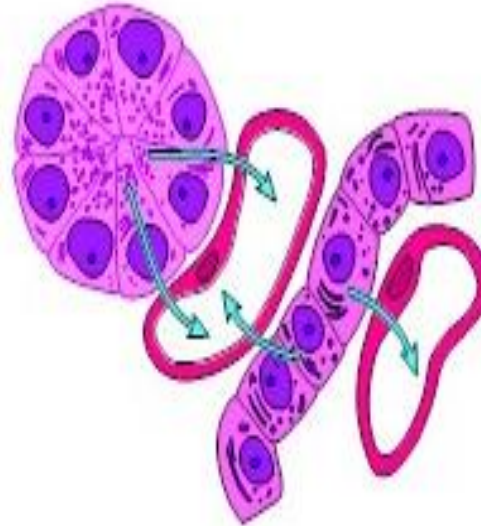
- Mixed variety: some glands possess both exocrine and endocrine function e.g; pancreas.

The cells of endocrine glands can be arranged in CORDS (e.g. adrenal, parathyroid, Ant pituitary) or in FOLLICLES (e.g. thyroid).

The lumens of the follicles accumulate large quantities of secretions; cells of the cords store only small quantities of secretions in their cytoplasm.



Follicular glands are found in the thyroid.



Cell mass and cell cord glands are found in the adrenal glands

# Exocrine glands

**They can be classified on the basis of:**

- Number of cells
- Mode of secretion.
- Morphology of ducts and secreting portions.
- Nature of secretory product.



Exocrine glands are classified according to number of cells into:

### A. Unicellular glands

e.g. Goblet cells which are present in •  
the lining epithelia of intestine and the  
respiratory tract

### B. Multicellular glands

- they form most of the glands of the body
- e.g. salivary gland.

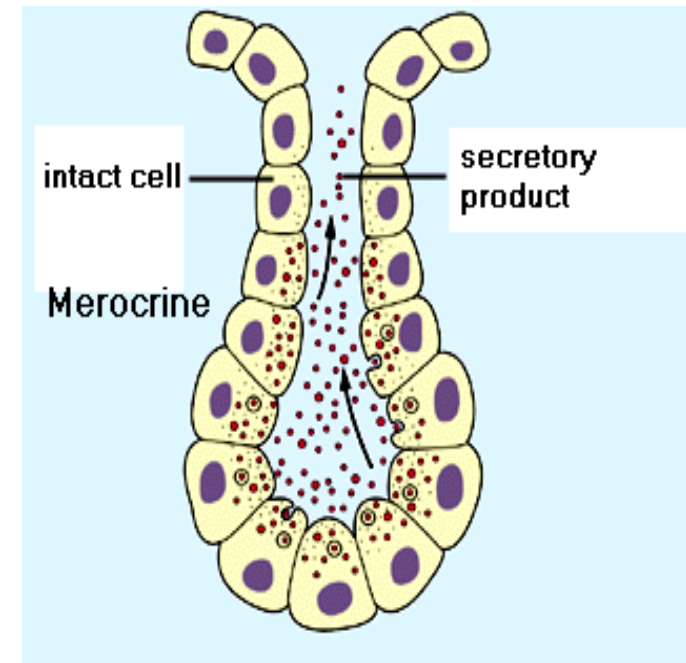
## Classification on the basis of the mode of secretion

- Depending on their mode of secretion i.e; the manner in which the secretory product is elaborated, the exocrine glands are classified into the following varieties:
  1. Merocrine glands
  2. Apocrine glands
  3. Holocrine glands

# Merocrine glands

The secretory product is delivered in membrane-bounded vesicles to the apical surface of the cell. Here, vesicles fuse with the plasma membrane and extrude their contents by **exocytosis**

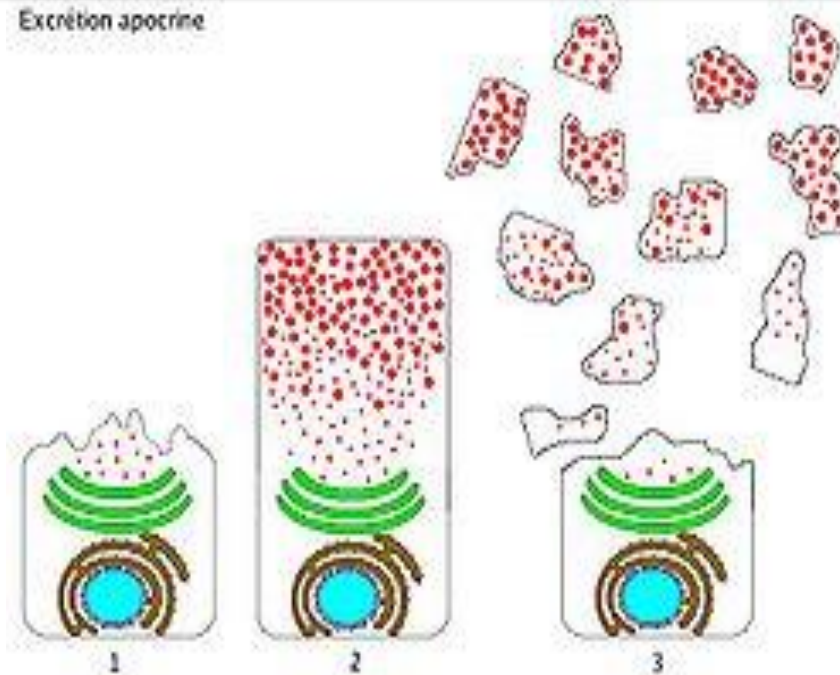
e.g; pancreas, salivary glands

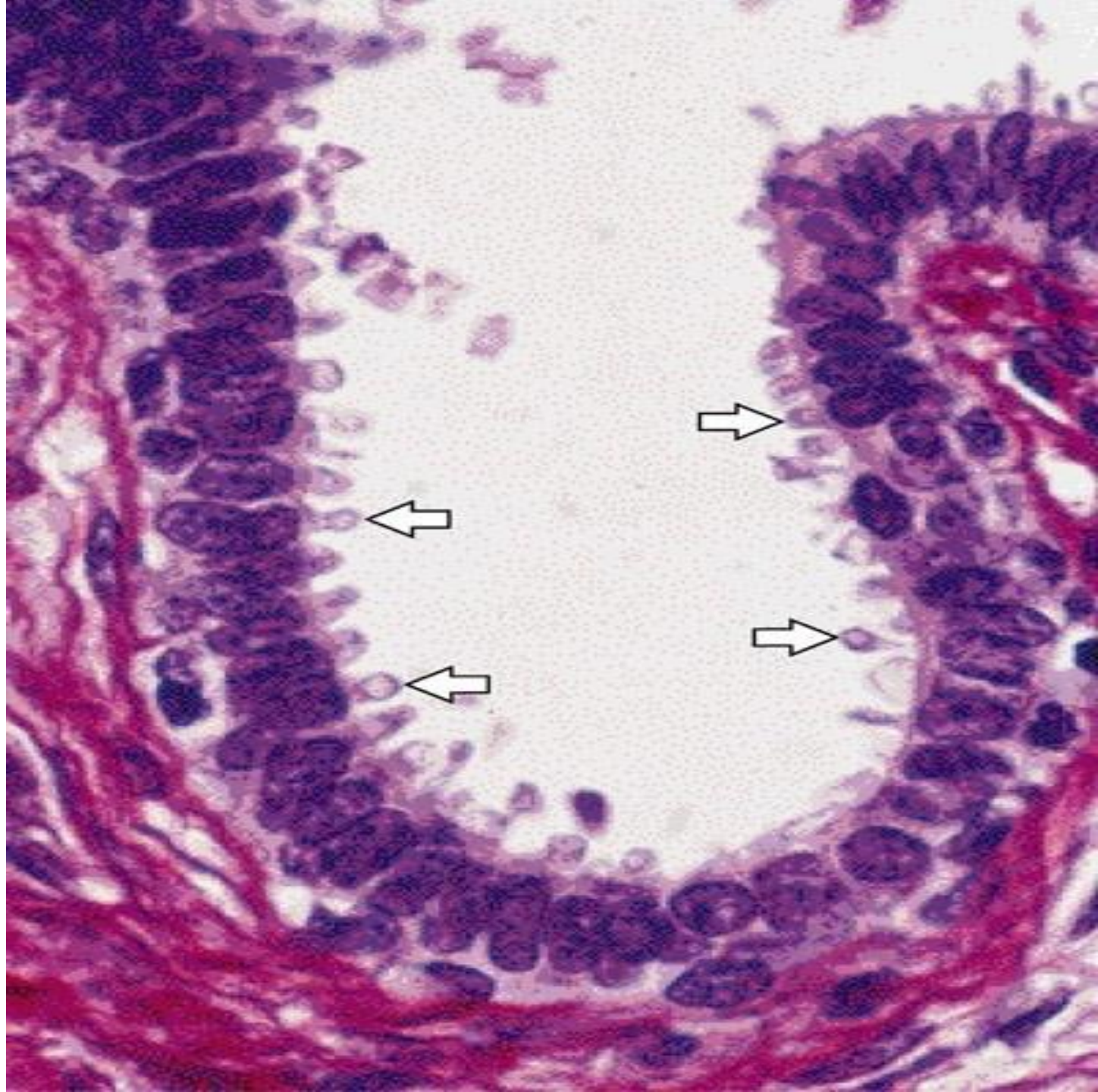


# Apocrine glands

In these glands part of the apical cytoplasm is lost along with the secretory material

e.g; lactating mammary glands, special sweat glands located in axilla and perianal area and the ceruminous glands of the external auditory meatus

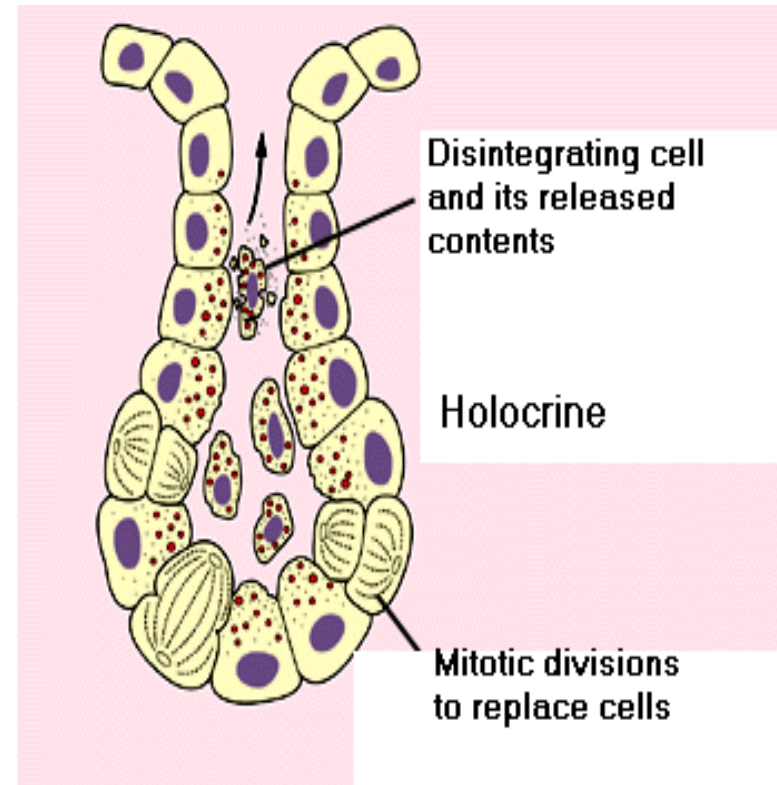




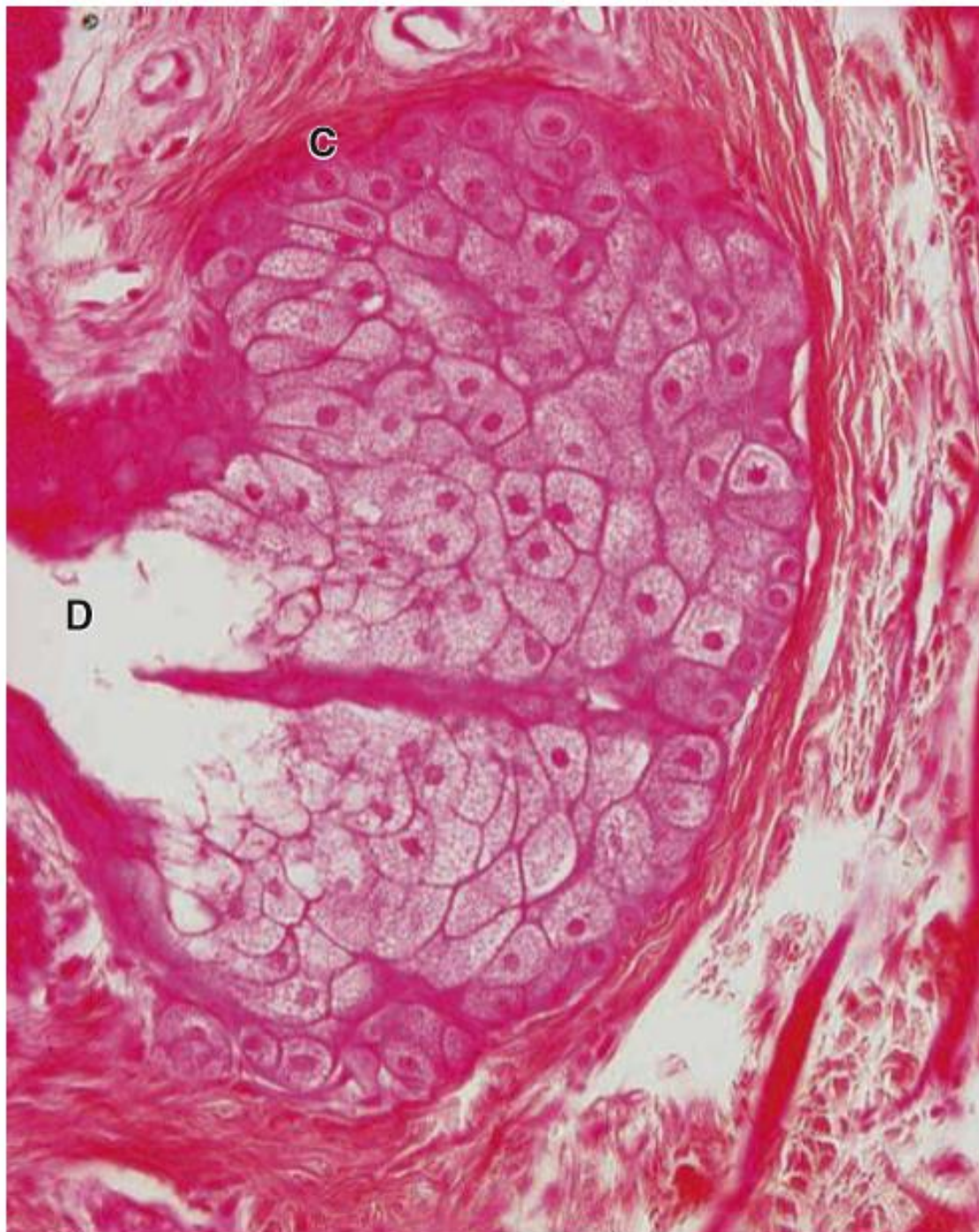
# Holocrine glands

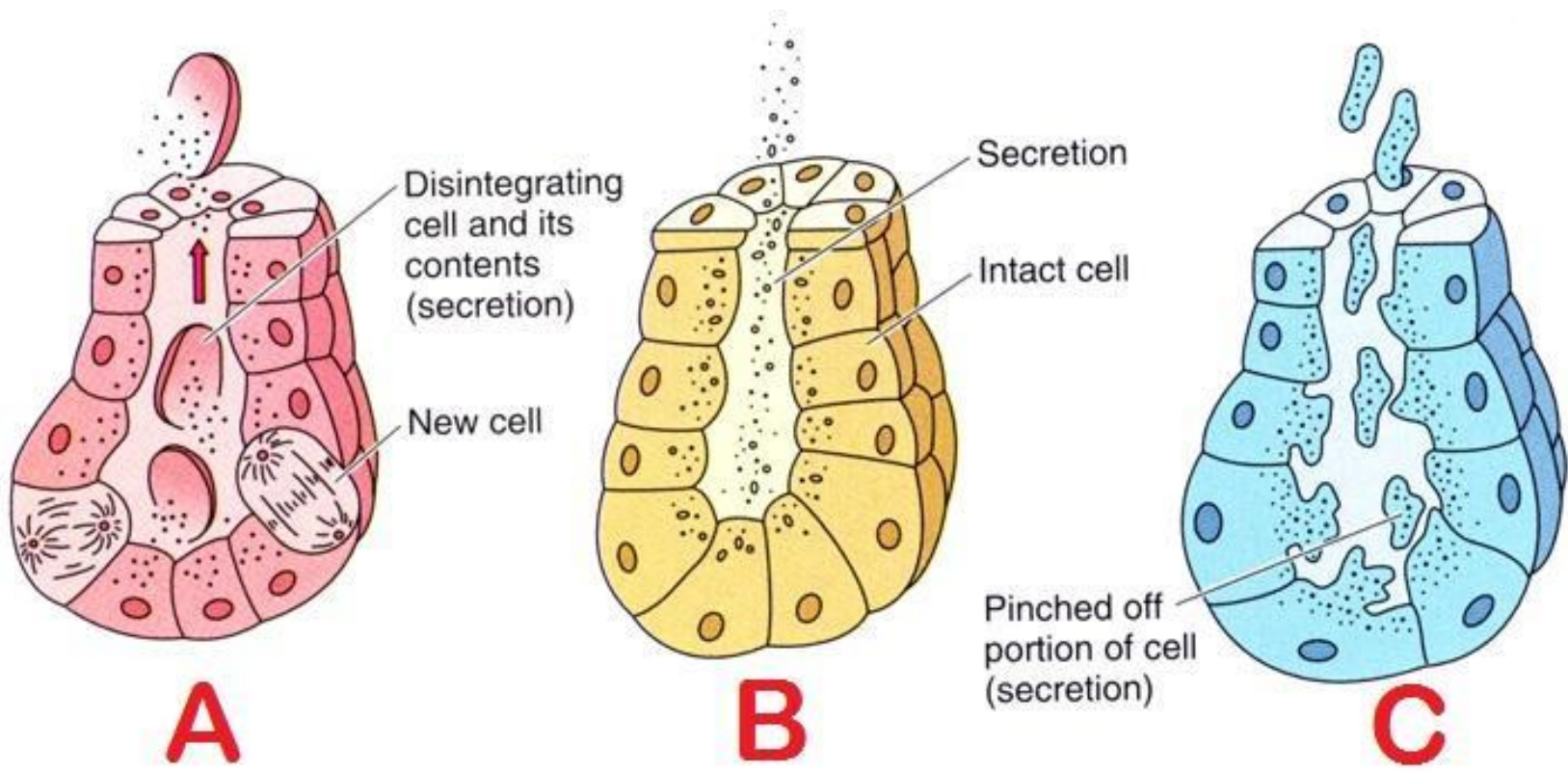
In these glands entire cells laden with secretory material disintegrate and all of the cellular contents are discharged from the gland as secretions

e.g; the sebaceous glands of skin

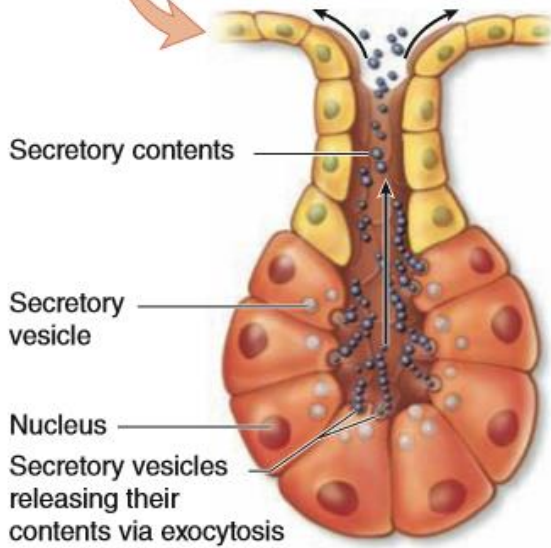
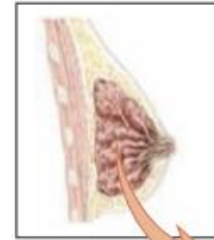
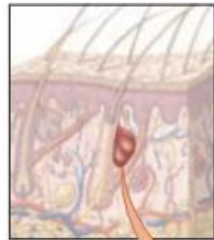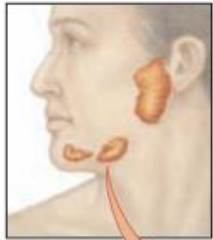




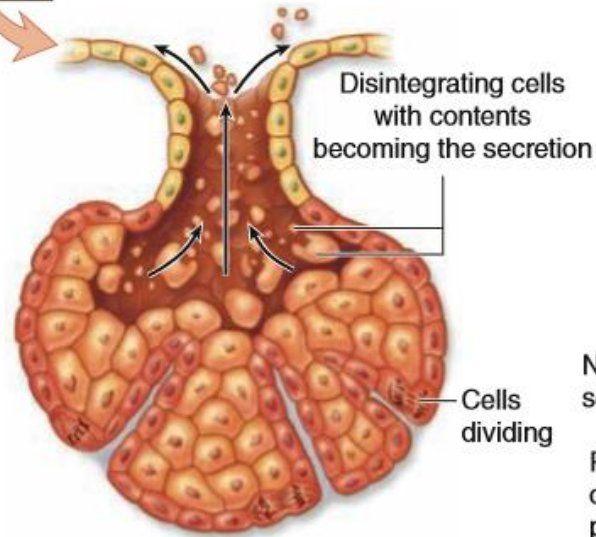




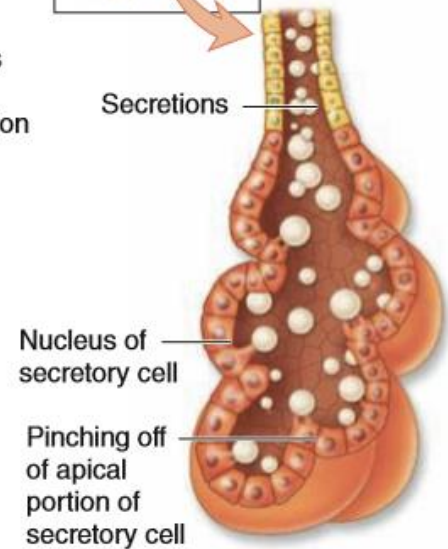




(a) Merocrine gland



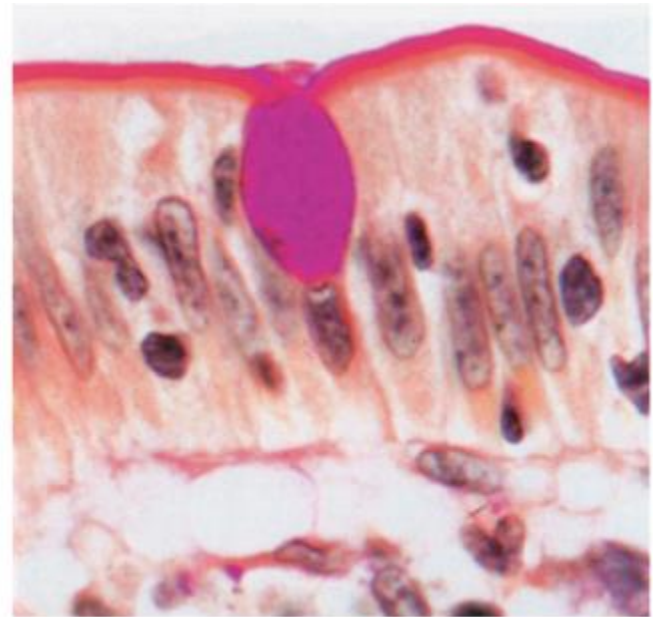
(b) Holocrine gland



(c) Apocrine gland

# Goblet cells

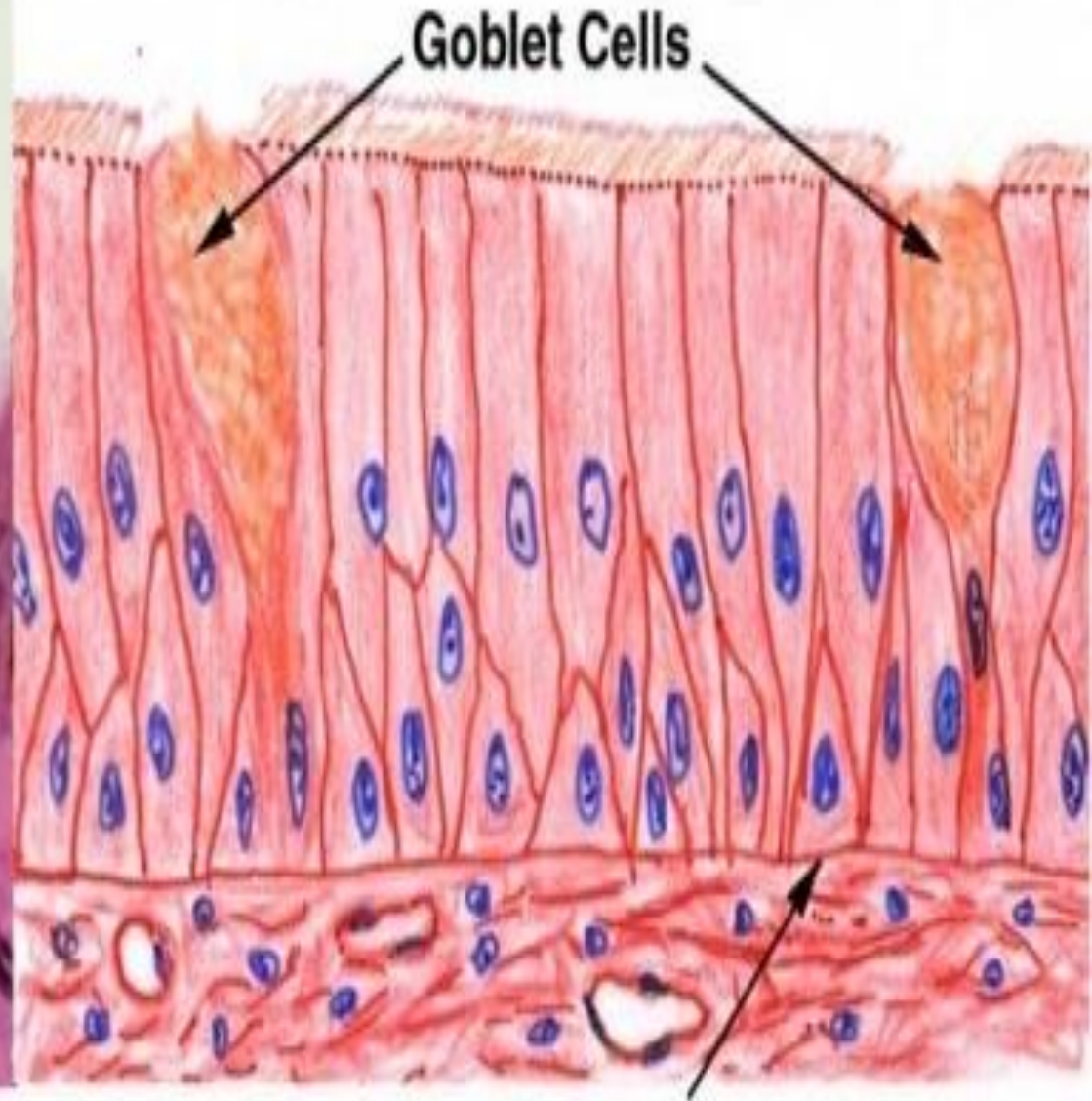
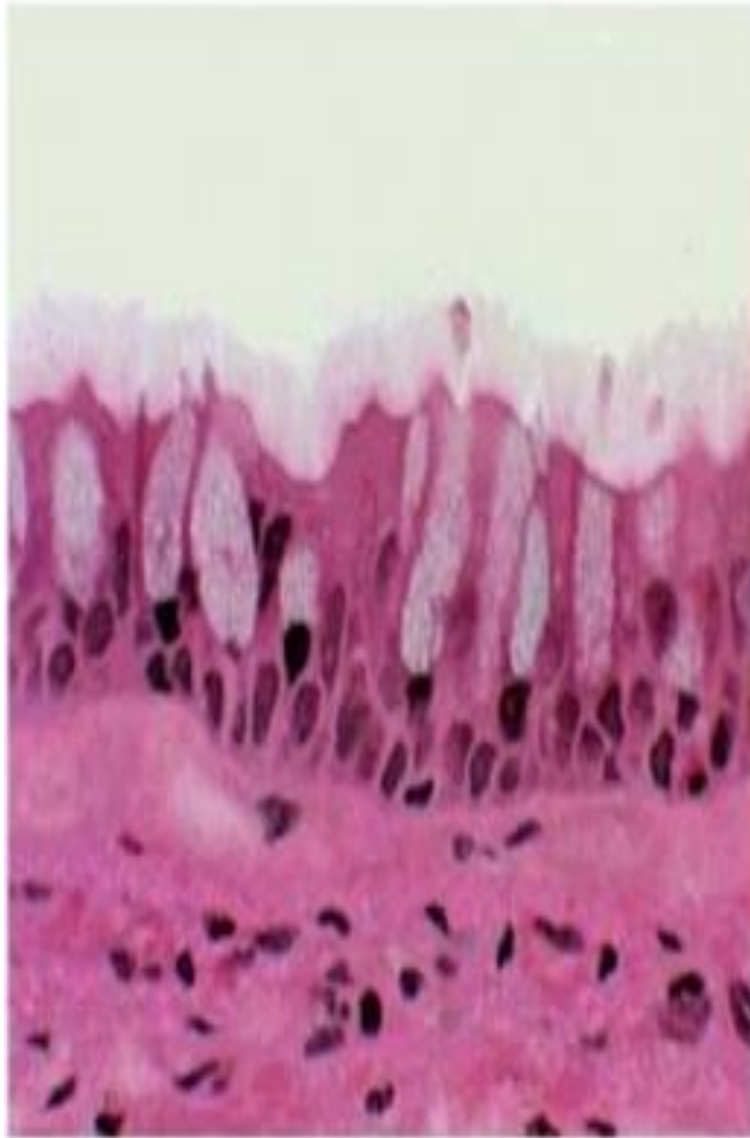
Goblet cell is a glandular simple columnar epithelial cell whose function is to produce and secrete strongly hydrophilic glycoproteins called mucins. When secreted, becomes highly hydrated mucous (an elastic protective lubricating gel)



© Elsevier. Young et al. Wheater's Functional Histology 5e - [www.studentconsult.com](http://www.studentconsult.com)

Scattered among cells of many simple epithelia, especially respiratory & GI tracts

Mainly use the merocrine method of secretion



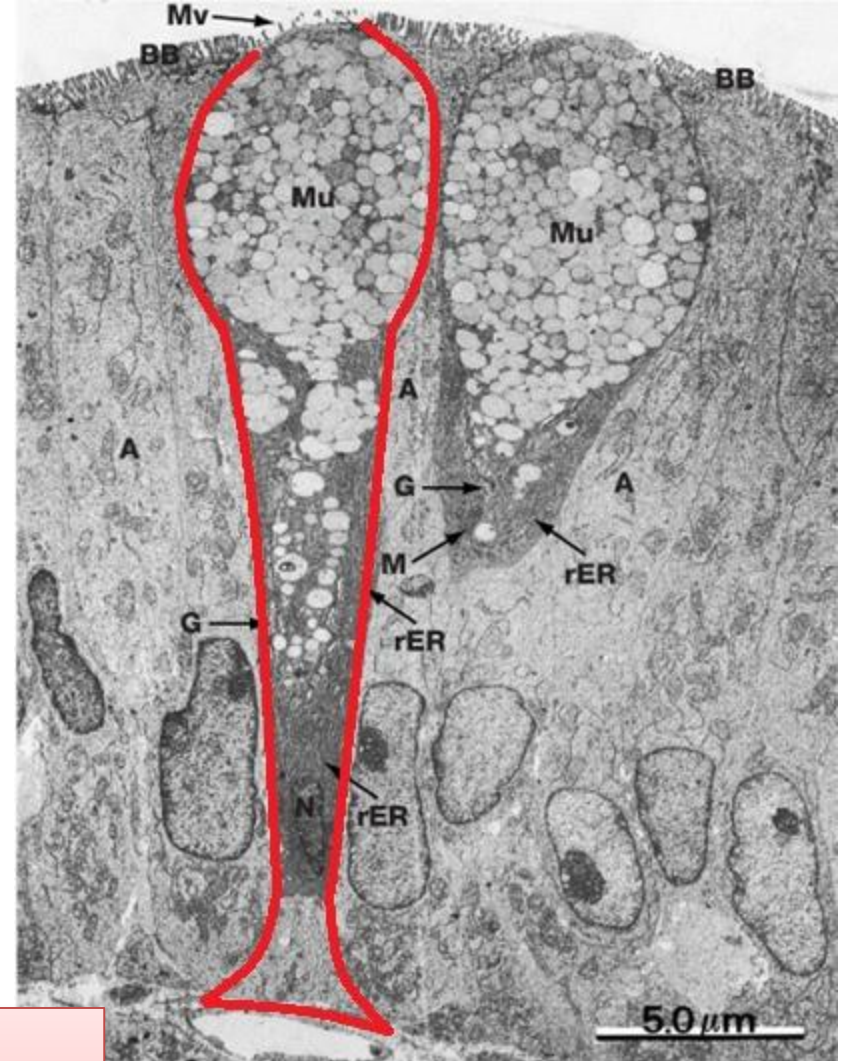
Basement Membrane



# Goblet cell

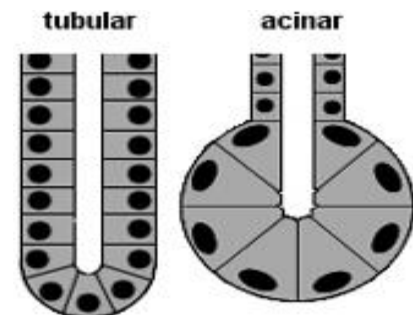
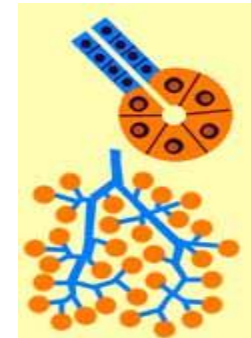
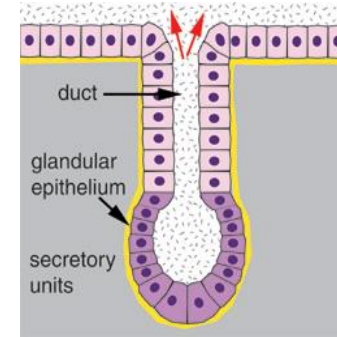
The goblet cell is **highly polarized** with the nucleus and other organelles concentrated at the base of the cell. The remainder of the cell's cytoplasm is occupied by membrane-bound secretory granules containing mucin.

Apical cytoplasm contains numerous secretory granules. Cell base has the nucleus and is rich in rER. Golgi, located above nucleus, exceptionally well-developed.



# Multicellular Exocrine Glands

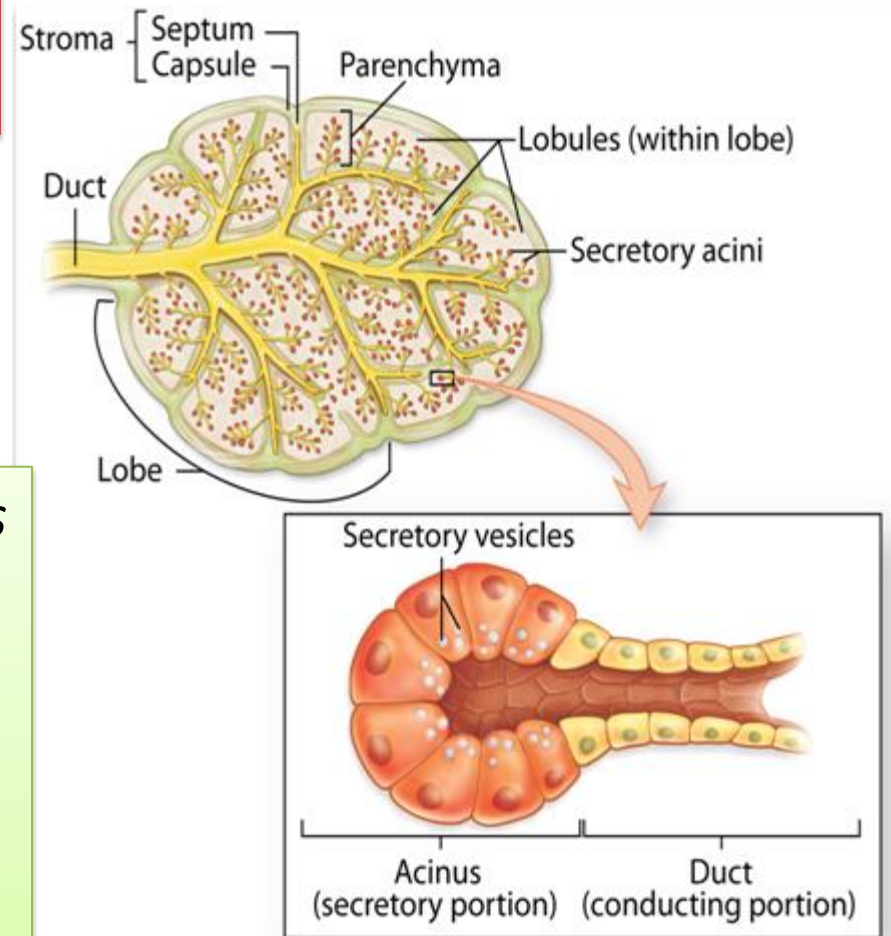
- Have two basic parts
  - Secretory unit
  - Epithelium-walled duct
- Classified by structure of duct
  - Simple
  - Compound
- Categorized by secretory unit
  - Tubular
  - Acinar (Alveolar)
  - Tubuloacinar



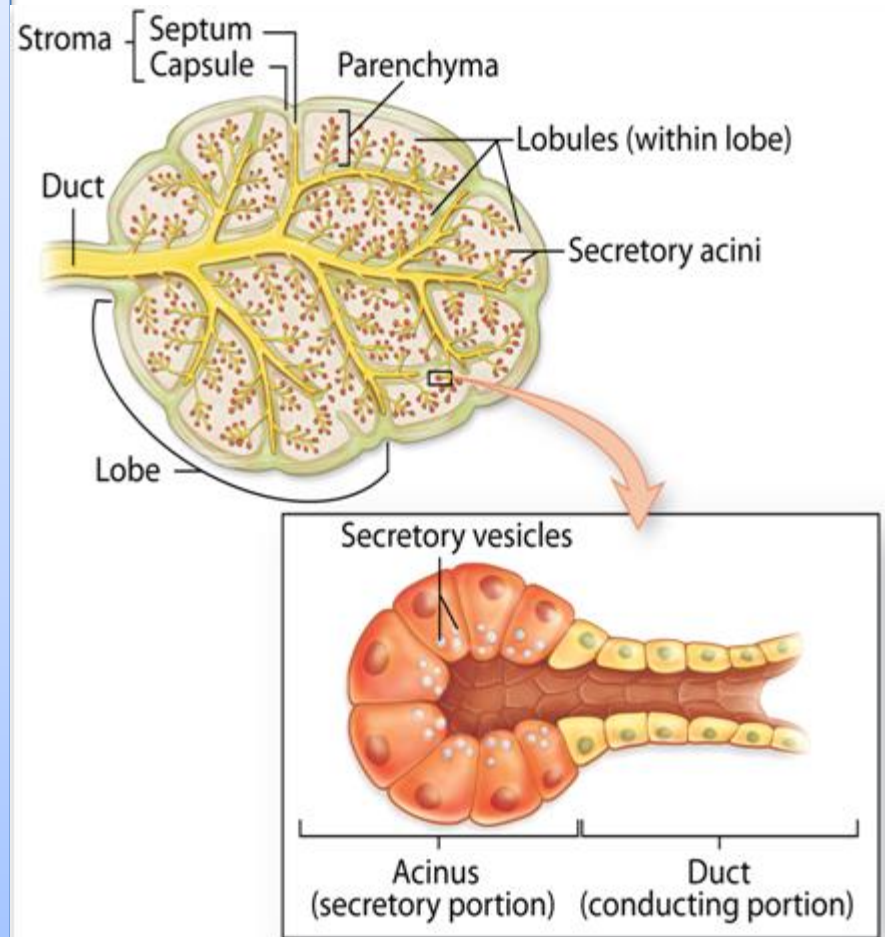
The secretory units are supported by a stroma of connective tissue

**Parenchyma:** composed of the cells responsible for the organ's specialized functions

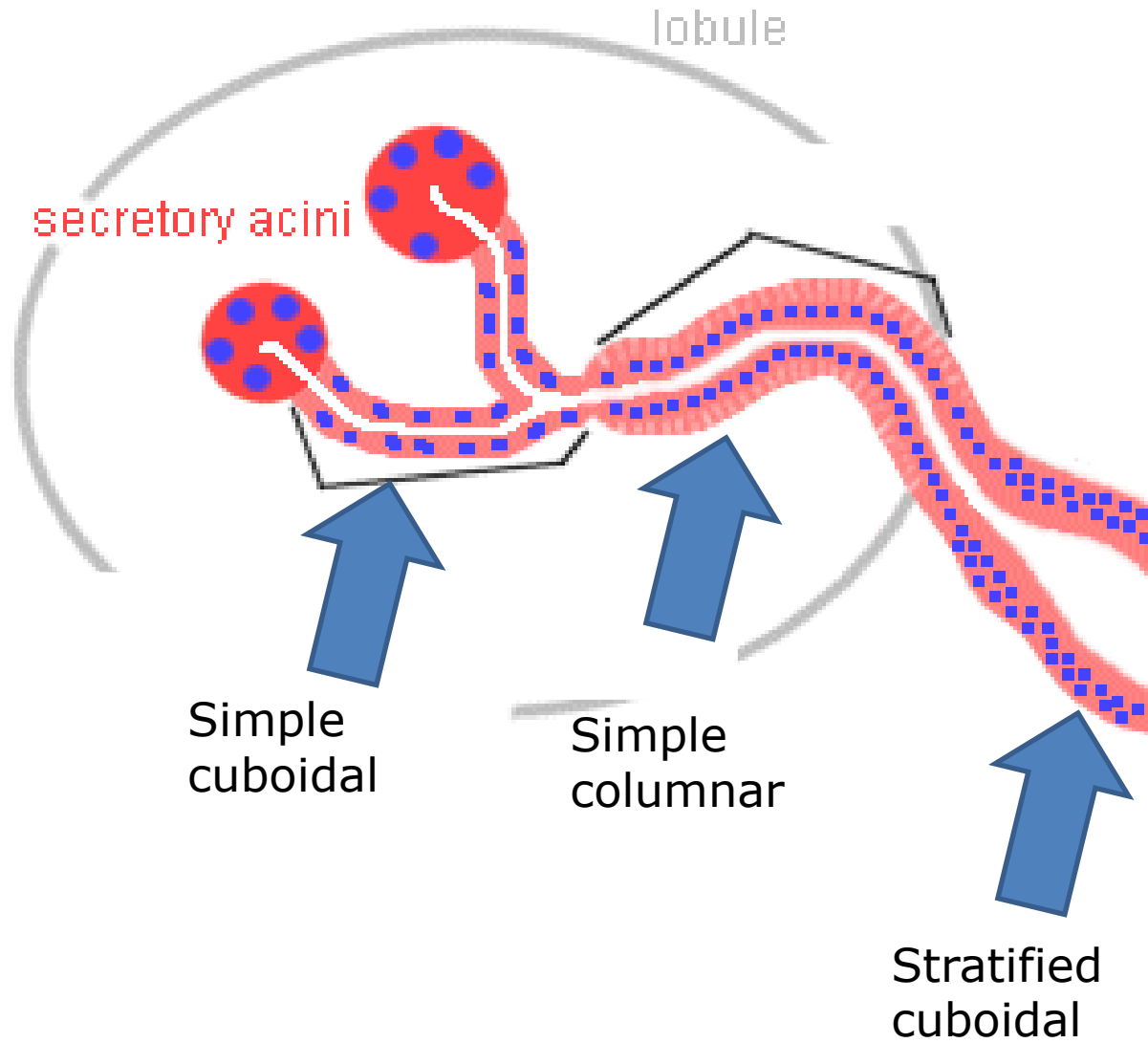
**Stroma:** the cells of which have a supportive role in the organ



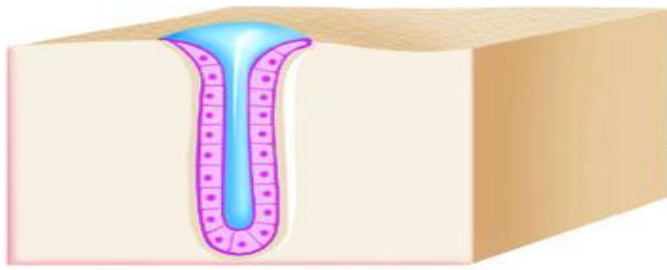
Generally the larger glands have the same structural pattern. Externally a gland is surrounded by a dense layer of connective tissue which forms **capsule** of the gland. From the capsule connective tissue septa extend into the gland, thereby dividing its substance into a number of **lobes**. Thinner septa subdivide each lobe into smaller **lobules**. Blood vessels and nerves pass along the connective tissue septa to reach the secretory elements



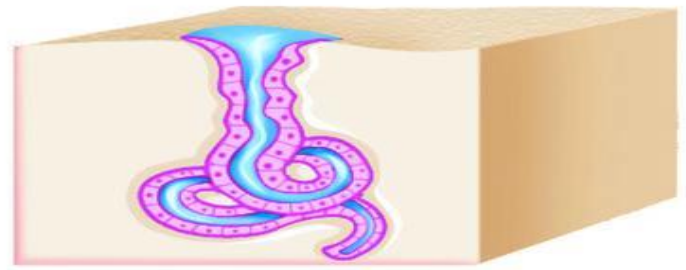
# Ducts



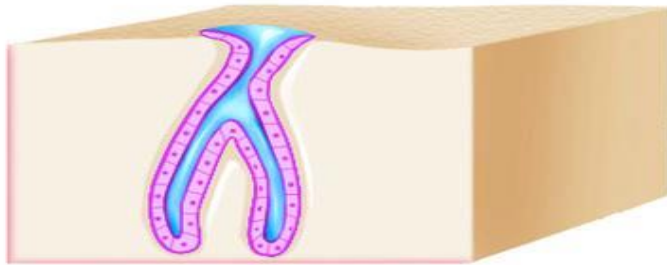




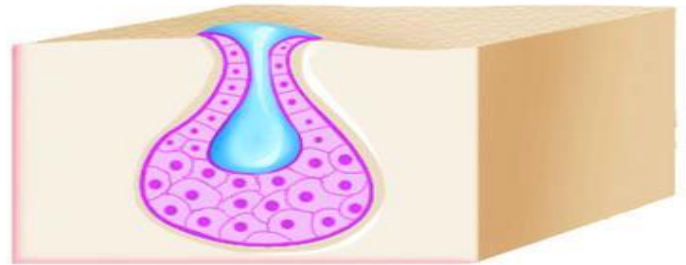
Simple tubular



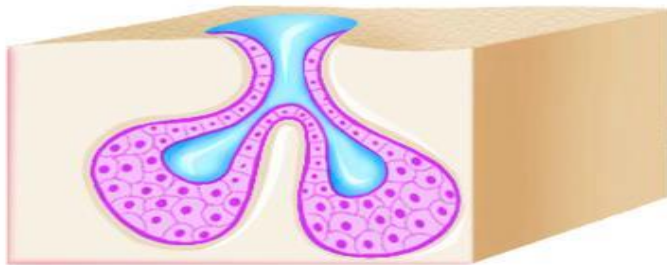
Simple coiled tubular



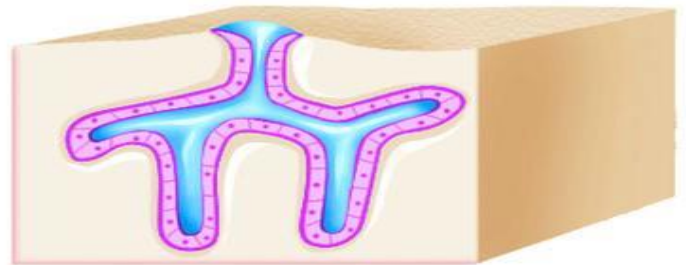
Simple branched tubular



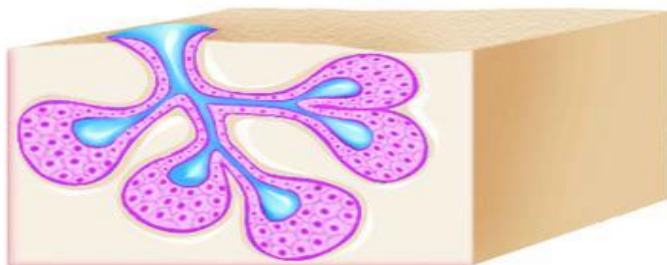
Simple alveolar



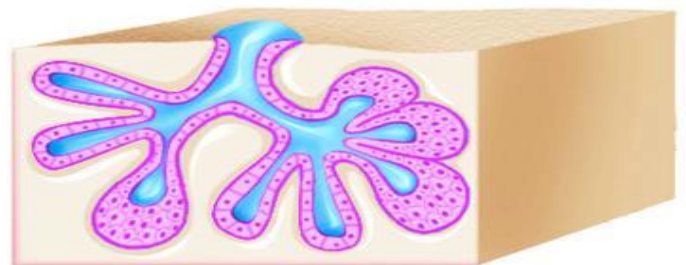Simple branched alveolar



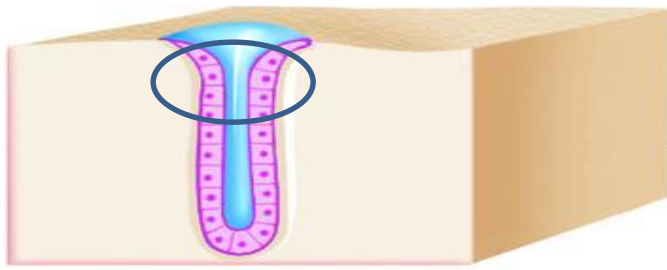
Compound tubular



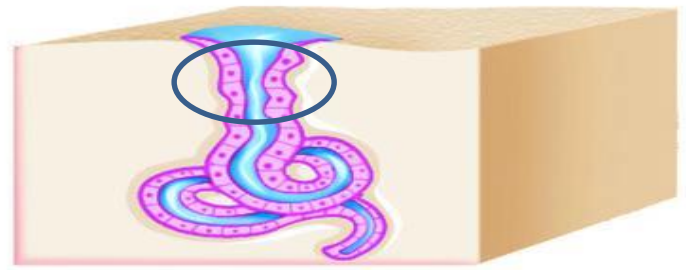
Compound alveolar



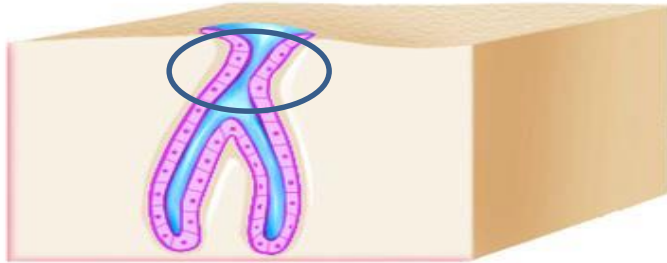
Compound tubuloalveolar



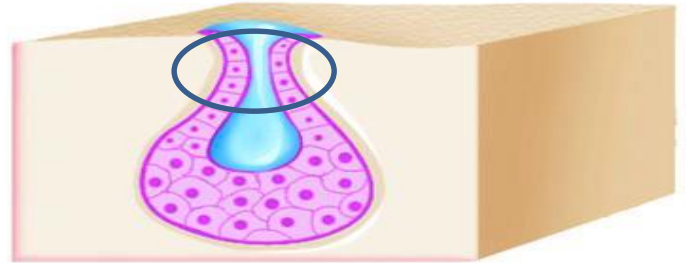
Simple tubular



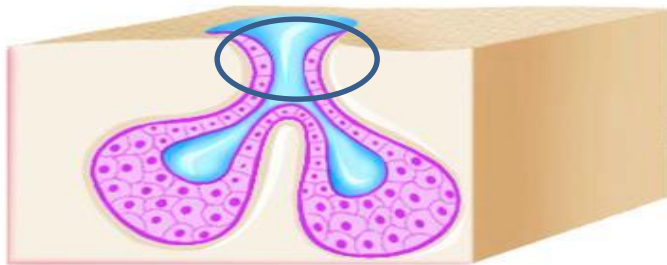
Simple coiled tubular



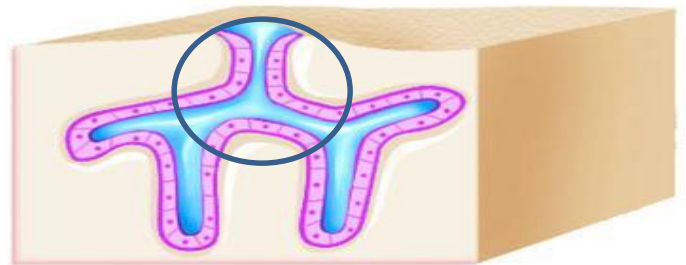
Simple branched tubular



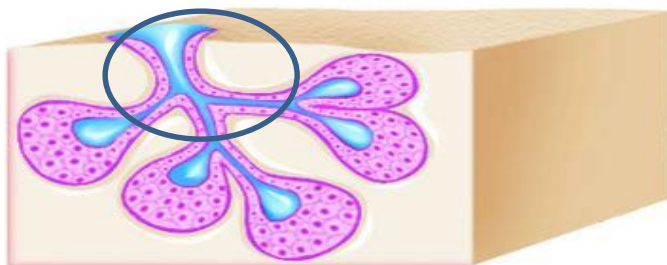
Simple alveolar



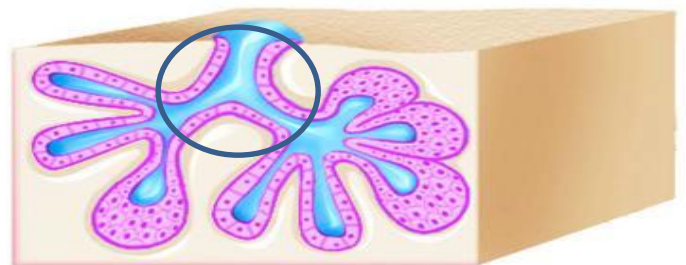
Simple branched alveolar



Compound tubular



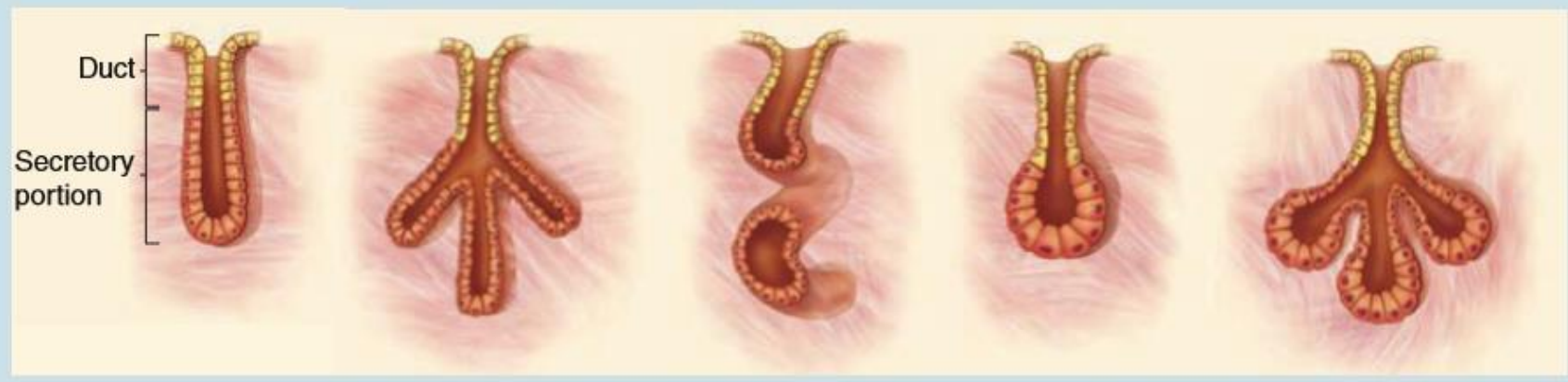Compound alveolar



Compound tubuloalveolar

**SIMPLE Glands (Ducts Do Not Branch)**

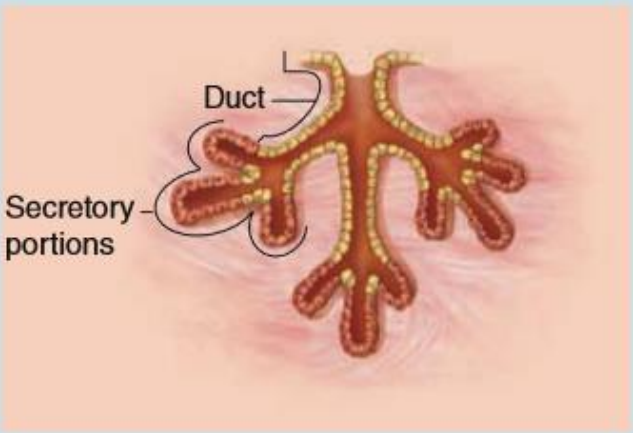


Class	Simple Tubular	Branched Tubular	Coiled Tubular	Acinar (or Alveolar)	Branched Acinar
-------	----------------	------------------	----------------	----------------------	-----------------



Features	Elongated secretory portion; duct usually short or absent	Several long secretory parts joining to drain into 1 duct	Secretory portion is very long and coiled	Rounded, saclike secretory portion	Multiple saclike secretory parts entering the same duct
Examples	Mucous glands of colon; intestinal glands or crypts (of Lieberkühn)	Glands in the uterus and stomach	Sweat glands	Small mucous glands along the urethra	Sebaceous glands of the skin

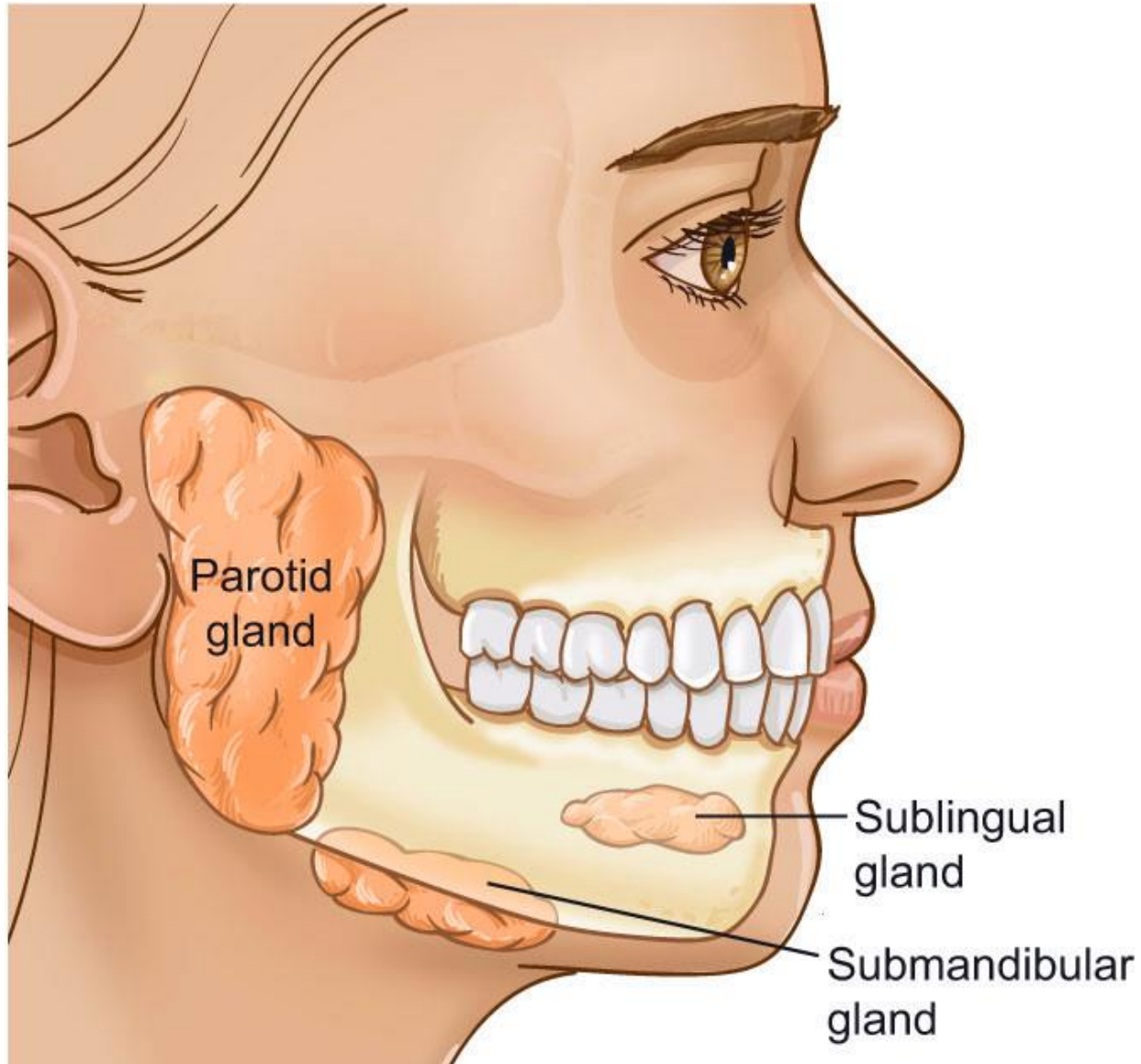


**COMPOUND Glands** (Ducts from Several Secretory Units Converge into Larger Ducts)

Class	Tubular	Acinar (Alveolar)	Tubuloacinar
			
Features	Several <i>elongated</i> coiled secretory units and their ducts converge to form larger ducts	Several <i>saclike</i> secretory units with small ducts converge at a larger duct	Ducts of both tubular and acinar secretory units converge at larger ducts
Examples	Submucosal mucous glands (of Brunner) in the duodenum	Exocrine pancreas	Salivary glands

# Classification on the basis of nature of secretory product:

1. **Mucous glands:** these glands produce a viscid, slimy, **carbohydrate-rich** secretion which is called mucus, e.g; the goblet cells, some glands in digestive tube, respiratory tract and genital tract
2. **Serous glands:** these glands produce a thin, watery, **protein-rich** secretions, often high in enzymatic activity e.g; the parotid salivary gland.
3. **Mixed (seromucous) glands:** these glands produce both mucous and serous secretions e.g; the sublingual and submandibular salivary glands.
4. **Steroid secreting cells:** endocrine cells specialized for synthesizing and secreting steroids with hormonal activity.

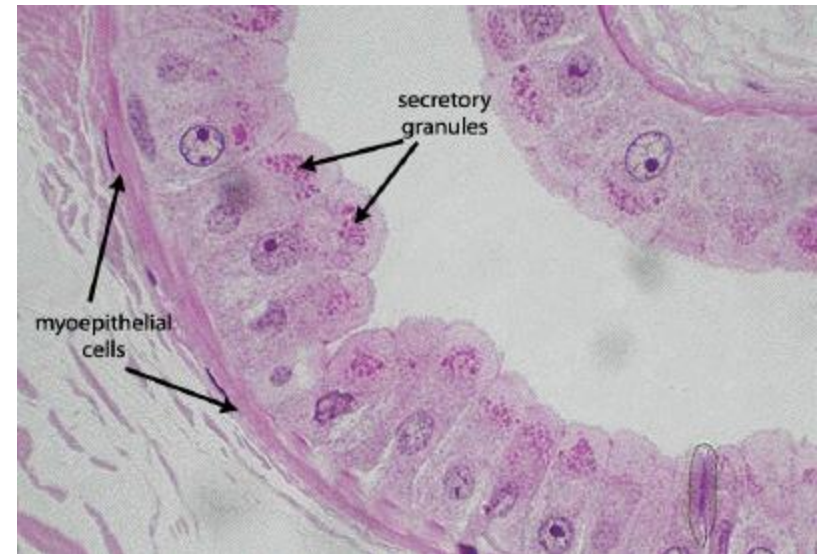
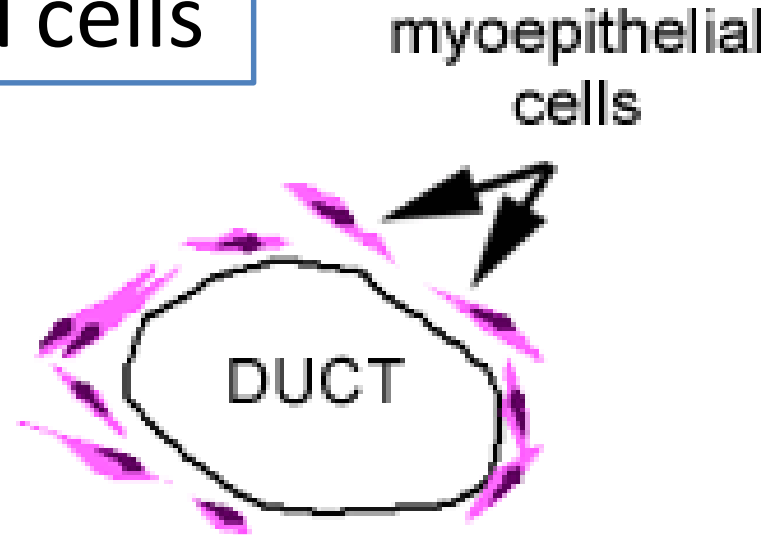


# Myoepithelial cells

Located between the secretory cells and the basement membrane

Rich in actin and myosin

When these cells contract, they squeeze the ducts, helping to extrude the contents





Each myoepithelial cell has long cytoplasmic processes which wrap around a secretory unit

