



# Glandular Epithelium

Dr. Heba Kalbouneh

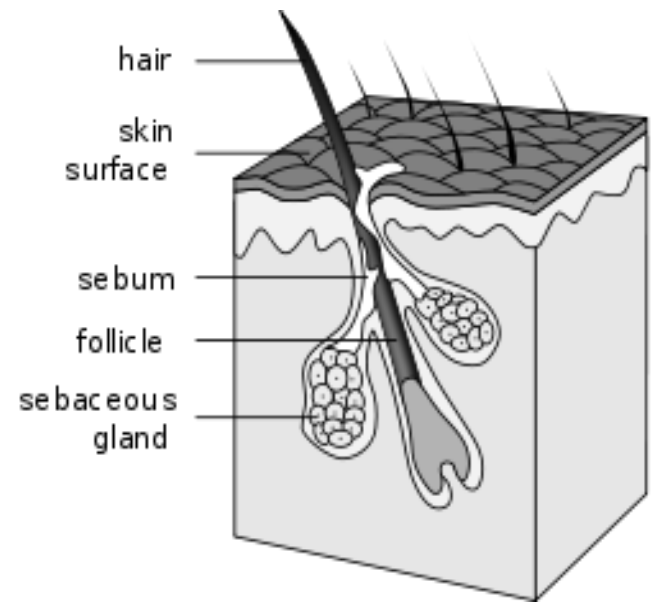
Associate Professor of Anatomy and Histology

# Glands

- “Glandular epithelia are tissues formed by cells specialized to produce secretion.”
- **Secretion**: if substances produced are used elsewhere in the body, they are called secretions.
- **Excretion**: if products are discarded from the body, they are known as excretions.

# Glands

- Glandular epithelial cells may synthesize, store, and secrete proteins (e.g; pancreas), lipids (e.g; sebaceous glands), or complexes of carbohydrates and proteins (e.g; salivary glands).
- The mammary glands secrete all 3 substances.
- Glands with low synthesizing activity (e.g; sweat glands) and that secrete mostly substances transferred from the blood to the lumen of the gland.



# Development of glands:

- Formation of glands from covering epithelia. Epithelial cells proliferate and penetrate connective tissue. They may—or may not—maintain contact with the surface. When contact is maintained, **exocrine glands** are formed; without contact, **endocrine glands** are formed.

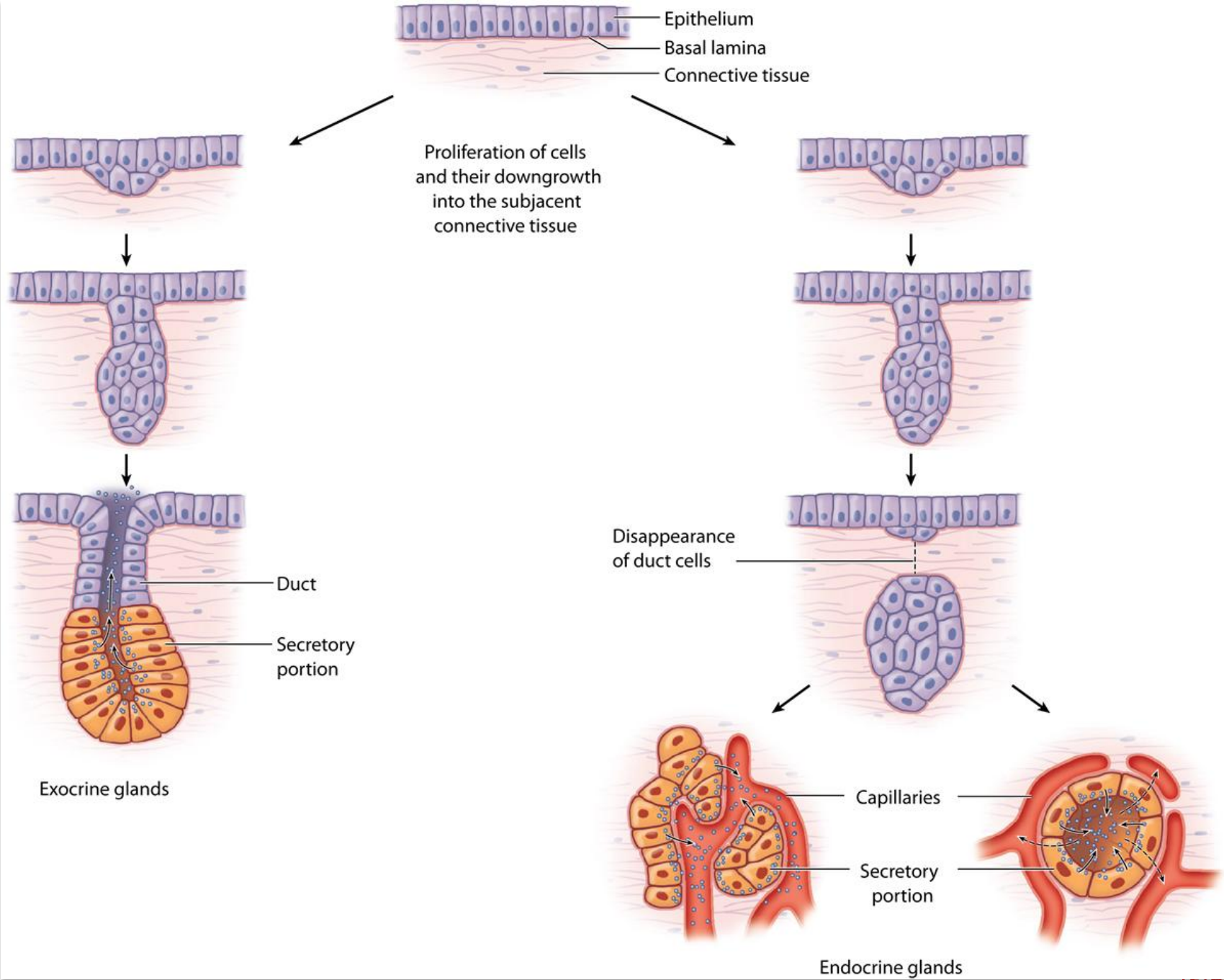
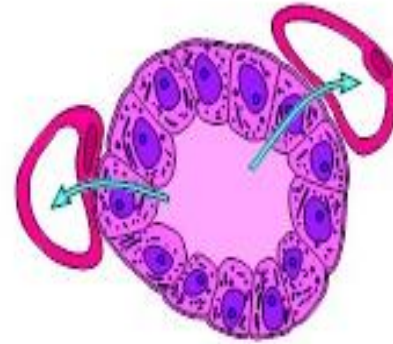


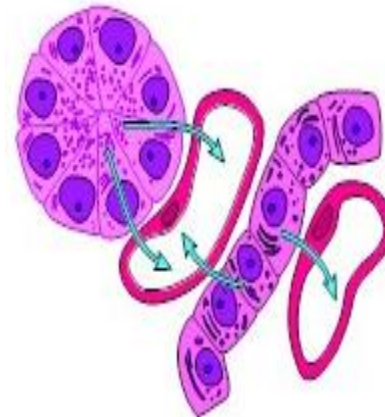
Figure 4-19

The cells of endocrine glands can be arranged in CORDS or in FOLLICLES.

The lumens of the follicles accumulate large quantities of secretions; cells of the cords store only small quantities of secretions in their cytoplasm.



Follicular glands are found in the thyroid.



Cell mass and cell cord glands are found in the adrenal glands

# Classification of glands:

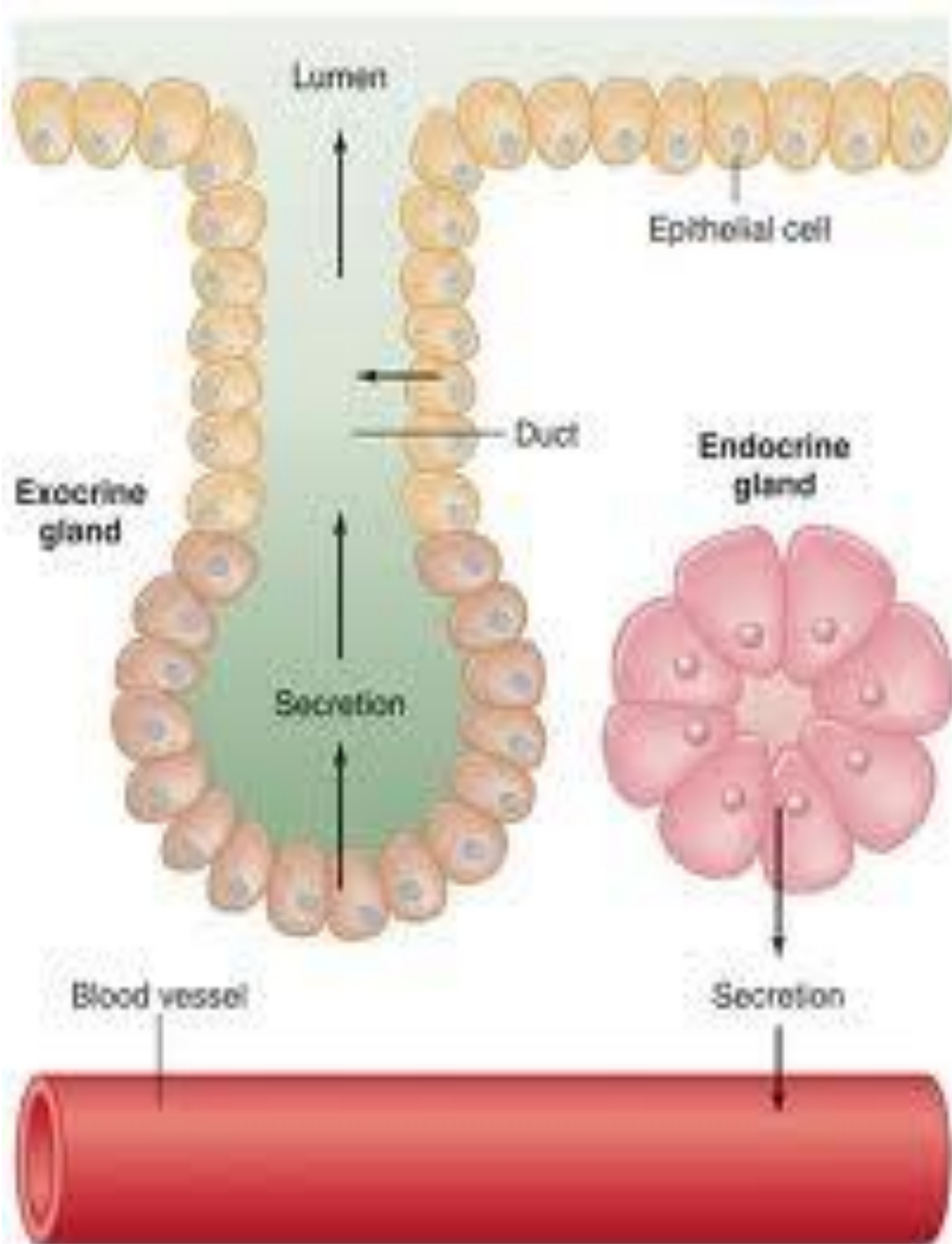
- **Exocrine glands**

(Gr. Exo, outside,+ krinein, to separate) release their products onto an epithelial surface, either directly or through a duct e.g; the salivary glands.

- **Endocrine glands**

(Gr, endon, within,+ krinein) release their products into the blood stream, e.g; thyroid gland.

- **Mixed variety:** some glands possess both exocrine and endocrine function e.g; pancreas.





Exocrine glands might be classified according the number of cells :

### A. Unicellular glands

- eg. Goblet cells which are present in the lining epithelia of intestine and the respiratory tract

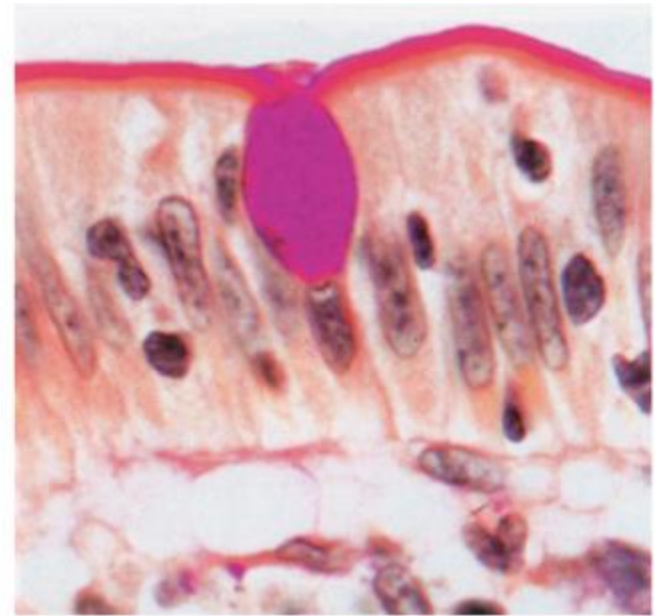
### B. Multicellular glands

- they form most of the glands of the body
- eg. salivary gland.

# Goblet cells

Goblet cell is a glandular simple columnar epithelial cell whose function is to secrete gel-forming mucins

Mainly use the **merocrine** method of secretion

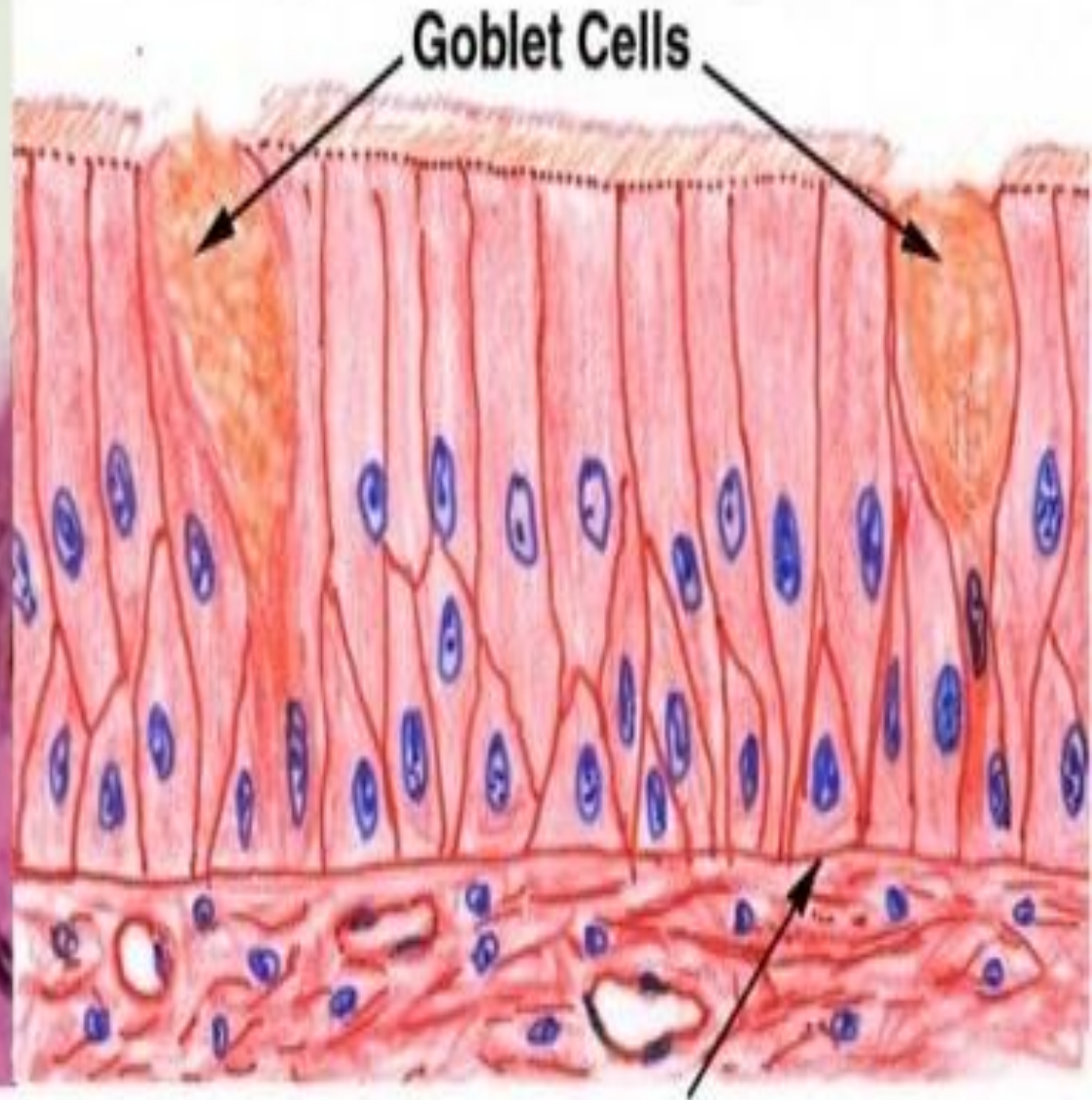
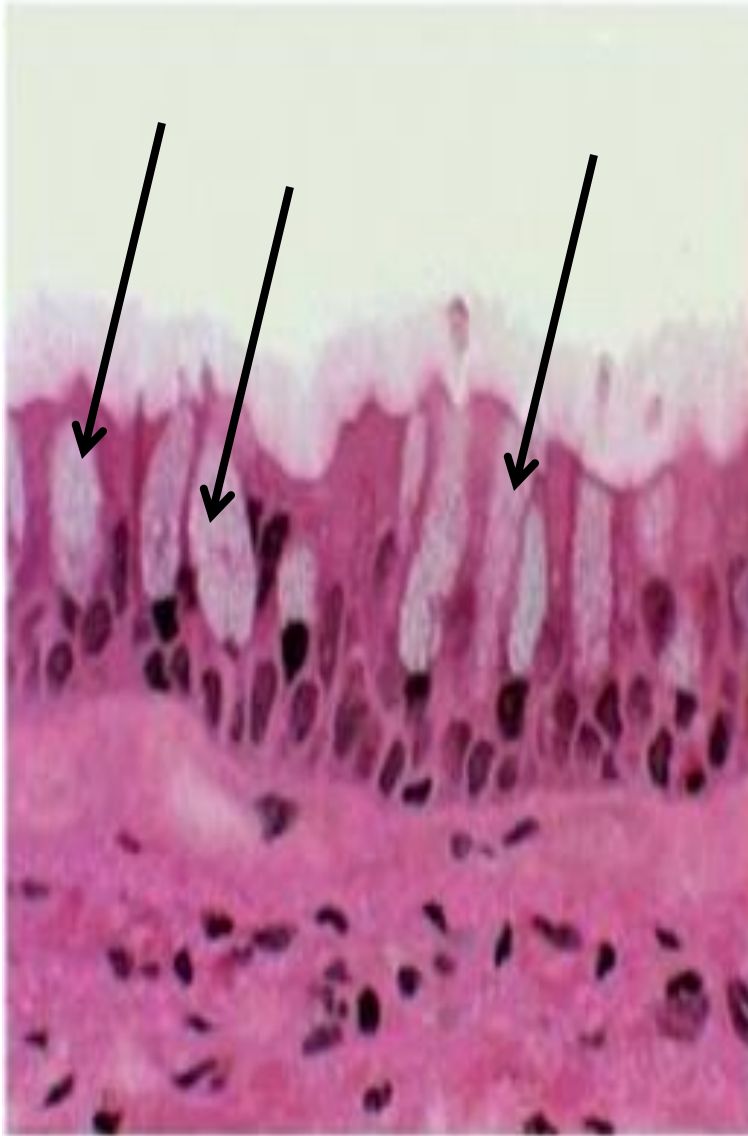


Rever. Young et al. Wheater's Functional Histology 5e - [www.studentconsult.com](http://www.studentconsult.com)

Scattered among cells of many simple epithelia, especially respiratory & GI tracts

Apical cytoplasm contains mucigen granules

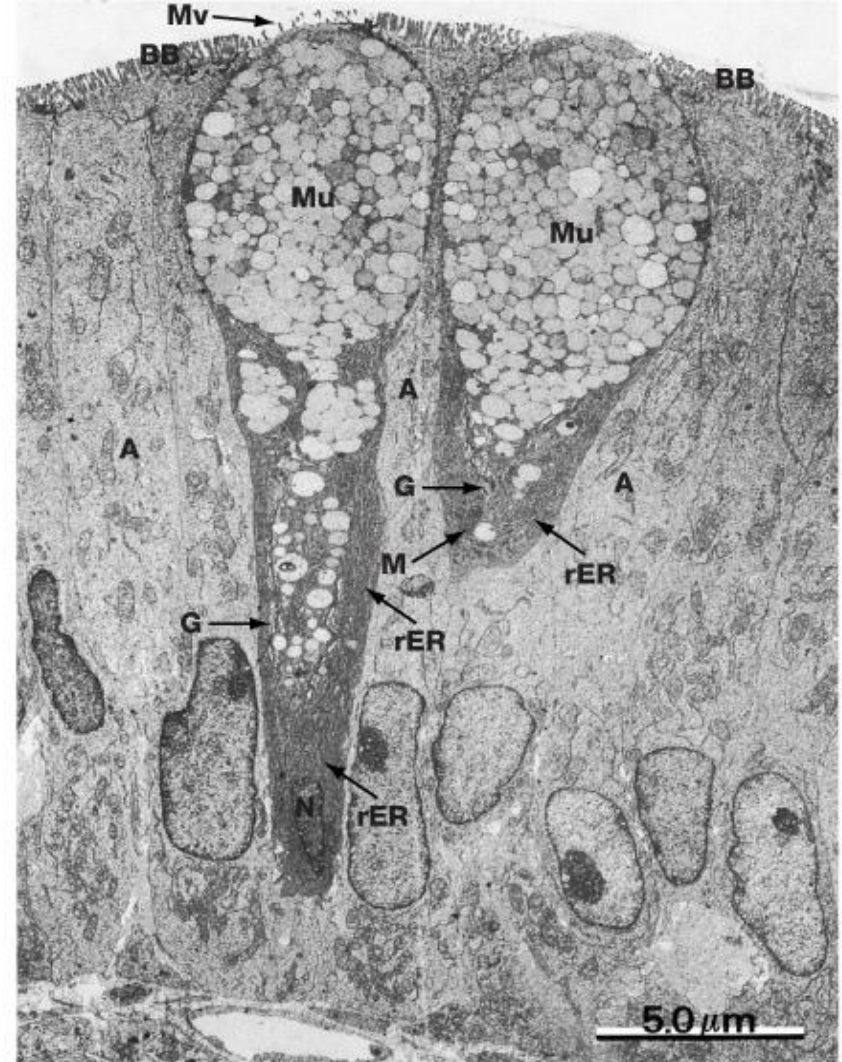
Mucigen is composed of neutral and acidic proteoglycans called mucopolysaccharides



Basement Membrane

# Goblet cell

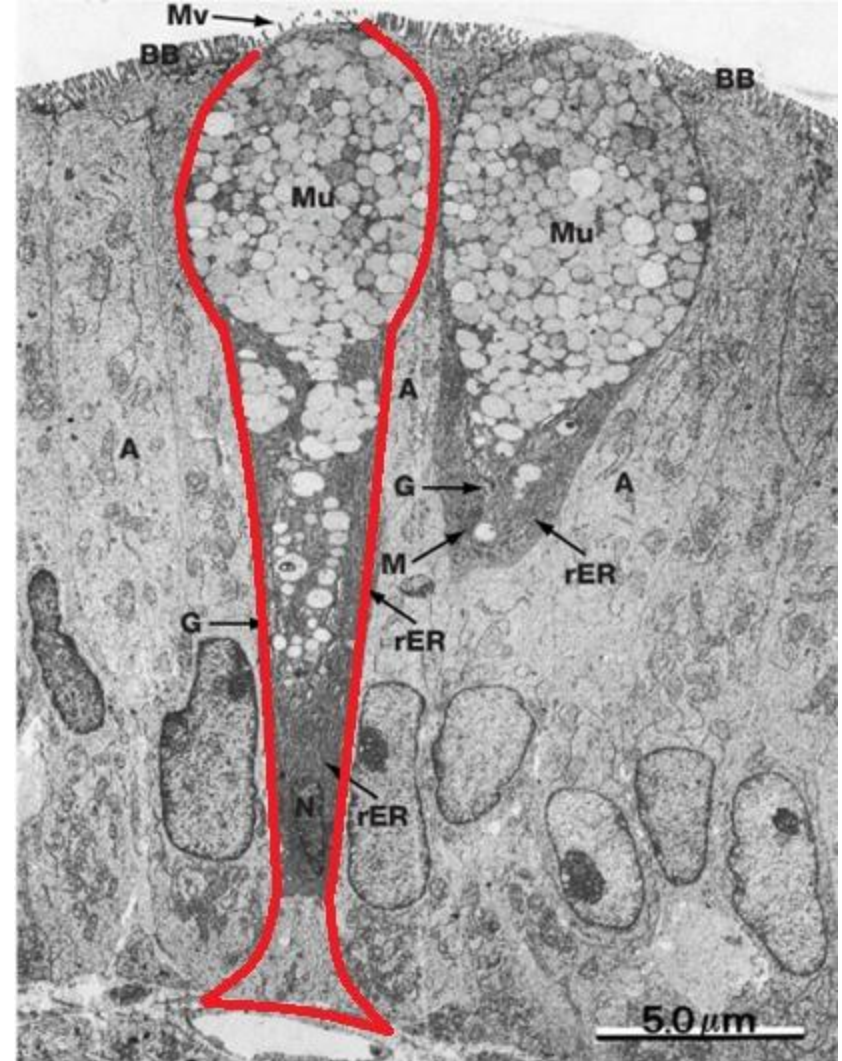
The goblet cell is **highly polarized** with the nucleus and other organelles concentrated at the base of the cell. The remainder of the cell's cytoplasm is occupied by membrane-bound secretory granules containing mucin





# Goblet cell

The goblet cell is **highly polarized** with the nucleus and other organelles concentrated at the base of the cell. The remainder of the cell's cytoplasm is occupied by membrane-bound secretory granules containing mucin



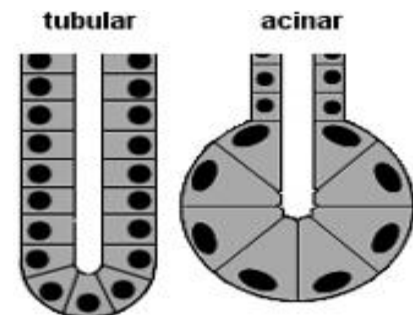
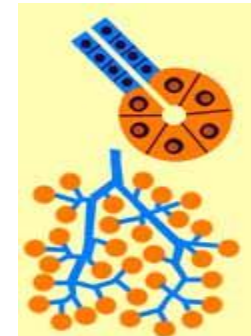
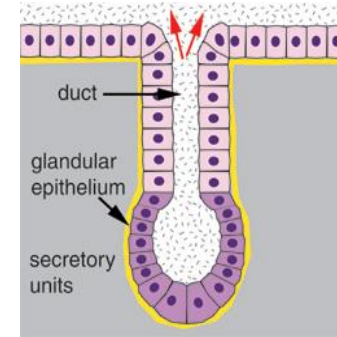
# Exocrine glands

**These can also be classified on the basis of:**

- Morphology of ducts and secreting portions.
- Nature of secretory product.
- Mode of secretion.

# Multicellular Exocrine Glands

- Have two basic parts
  - Epithelium-walled duct
  - Secretory unit
  
- Classified by structure of duct
  - Simple
  - Compound
  
- Categorized by secretory unit
  - Tubular
  - Acinar (Alveolar)
  - Tubuloacinar

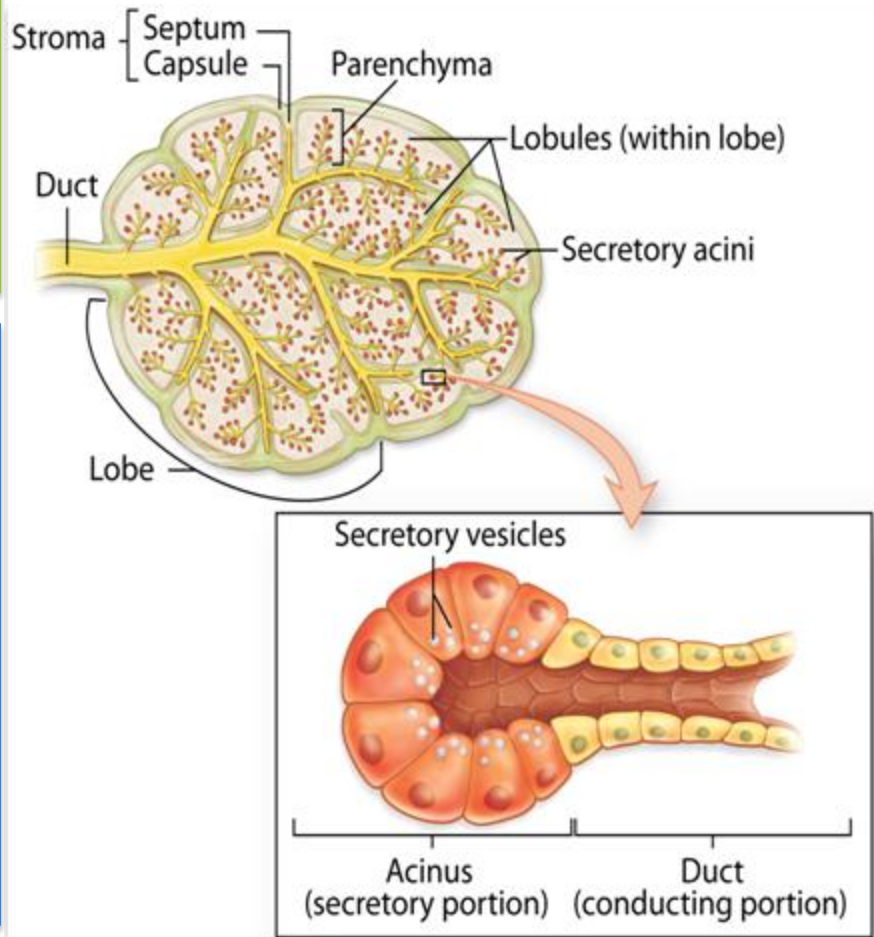


The secretory units are supported by a stroma of connective tissue

**Parenchyma:** composed of the cells responsible for the organ's specialized functions

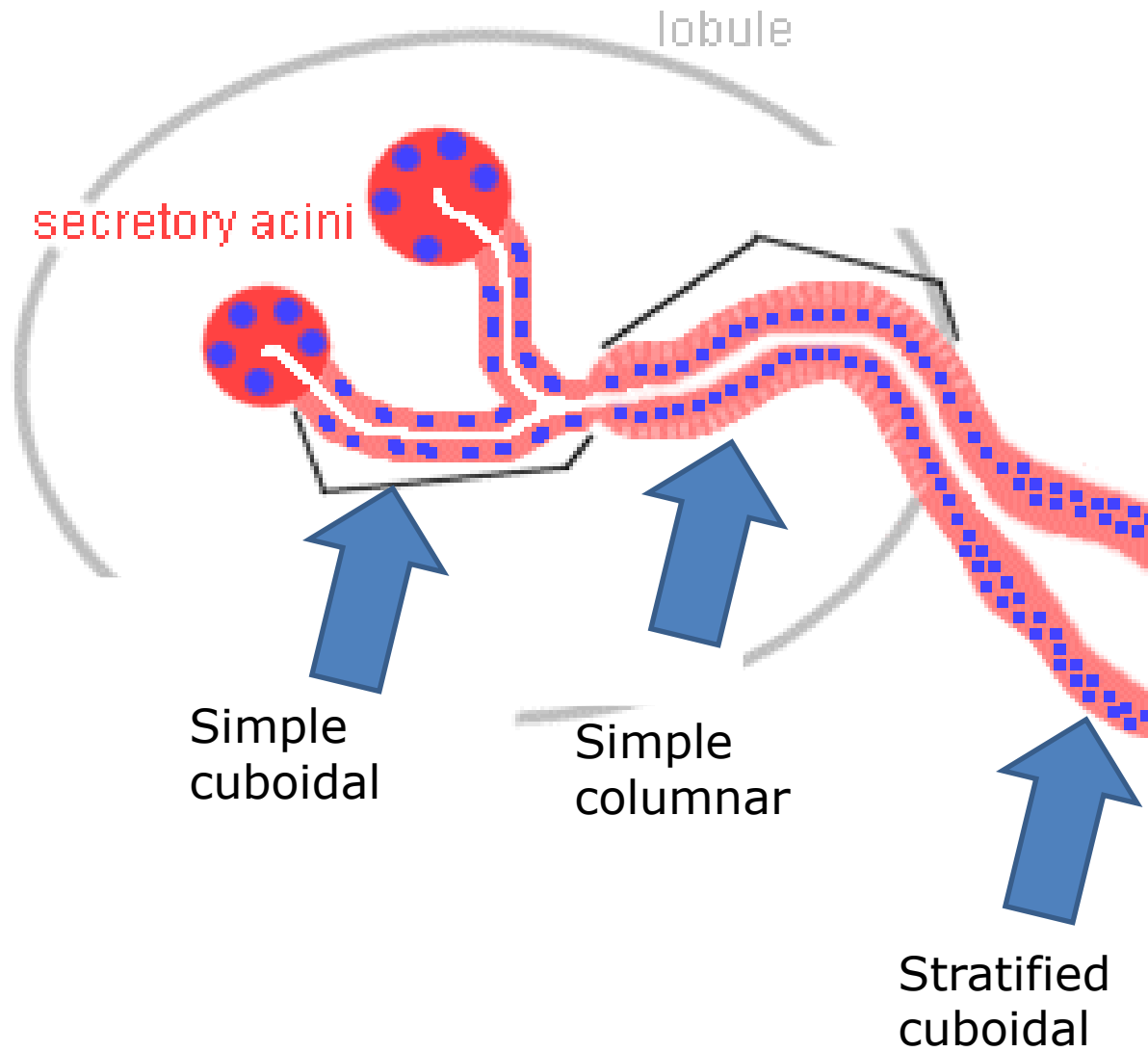
**Stroma:** the cells of which have a supportive role in the organ

Generally the larger glands have the same structural pattern. Externally a gland is surrounded by a dense layer of connective tissue which forms **capsule** of the gland. From the capsule connective tissue septa extend into the gland, thereby dividing its substance into a number of **lobes**. Thinner septa subdivide each lobe into smaller **lobules**. Blood vessels and nerves pass along the connective tissue septa to reach the secretory elements





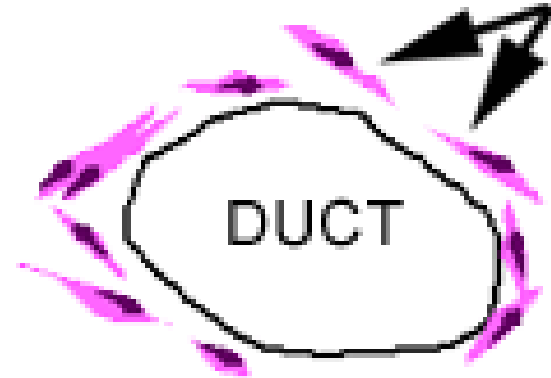# Ducts



# Myoepithelial cells

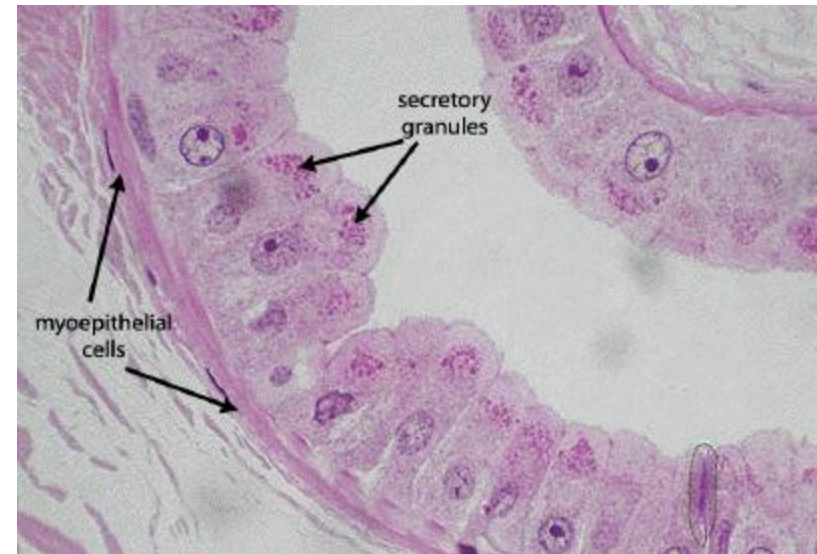
Located between the secretory cells and the basement membrane

myoepithelial  
cells

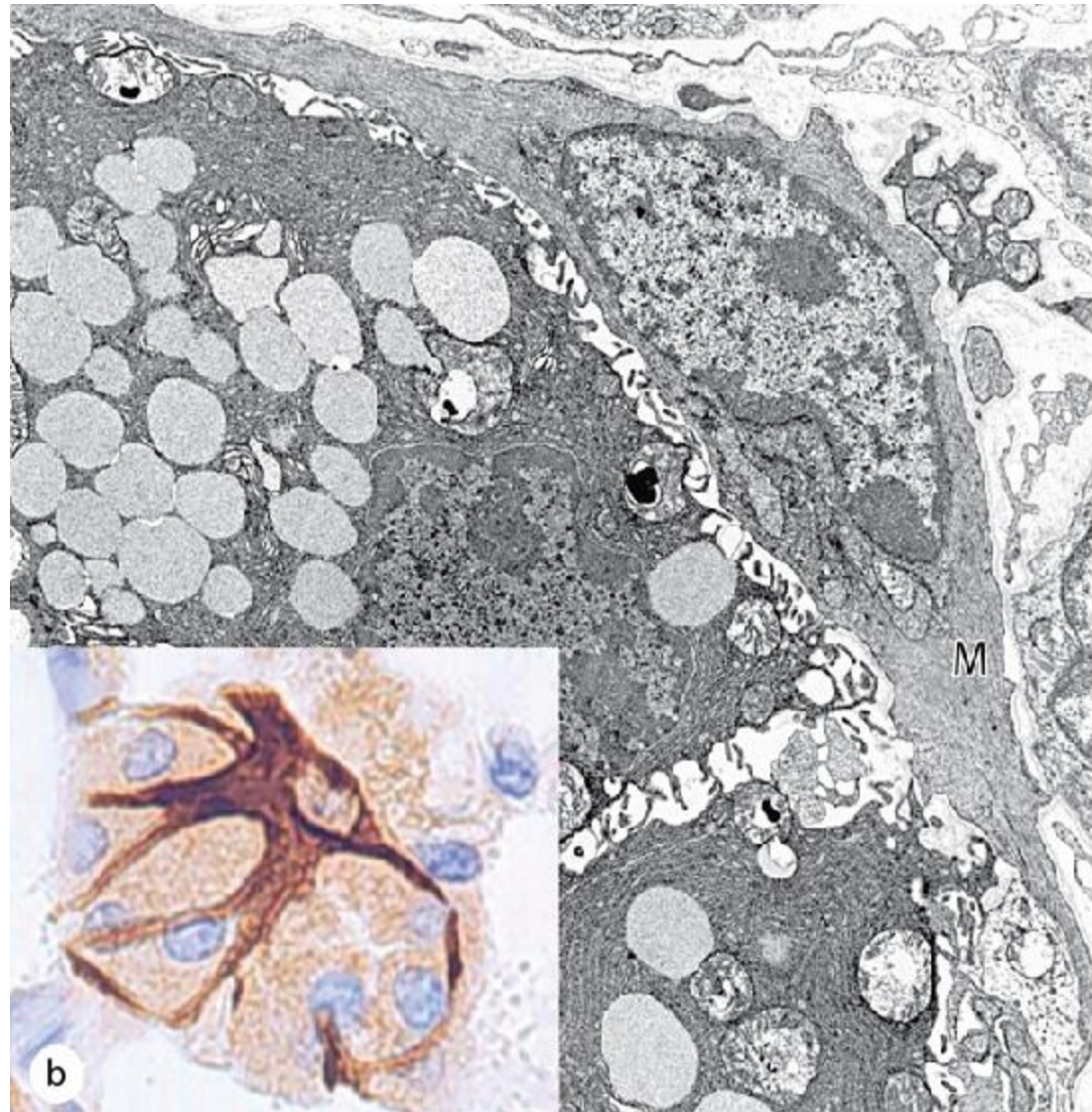


Rich in actin and myosin

When these cells contract, they squeeze the ducts, helping to extrude the contents



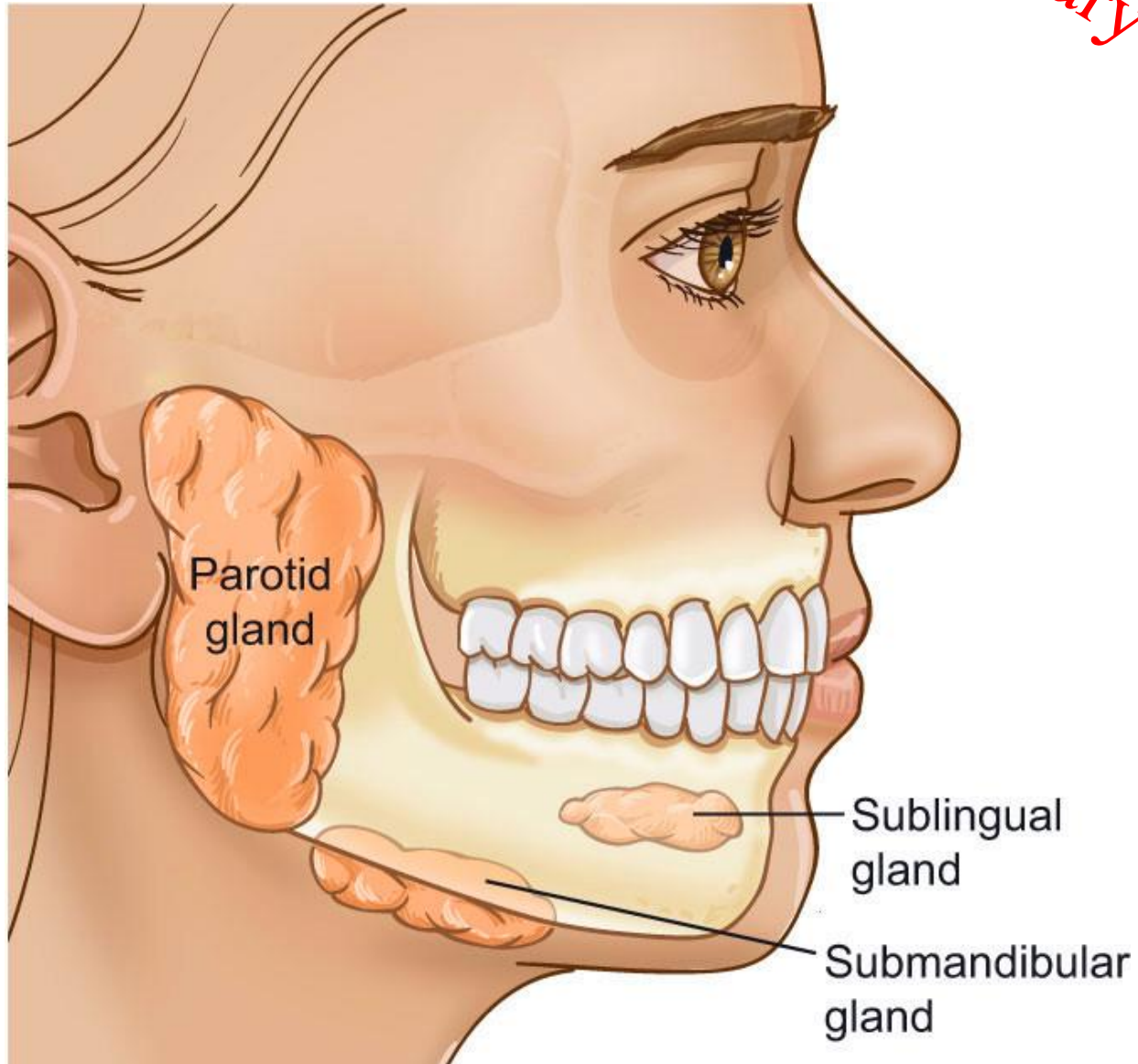
Each myoepithelial cell has long cytoplasmic processes which wrap around a secretory unit



# Classification on the basis of nature of secretory product:

1. **Mucous glands**: these glands produce a viscid, slimy, carbohydrate-rich secretion which is called mucus, e.g; the goblet cells
2. **Serous glands**: these glands produce a thin, watery, protein-rich secretions, often high in enzymatic activity e.g; the parotid salivary gland.
3. **Mixed** (seromucous/ mucoserous) glands: these glands produce both mucous and serous secretions e.g; the sublingual and submandibular salivary glands.

# Salivary glands



# Classification on the basis of the mode of secretion:

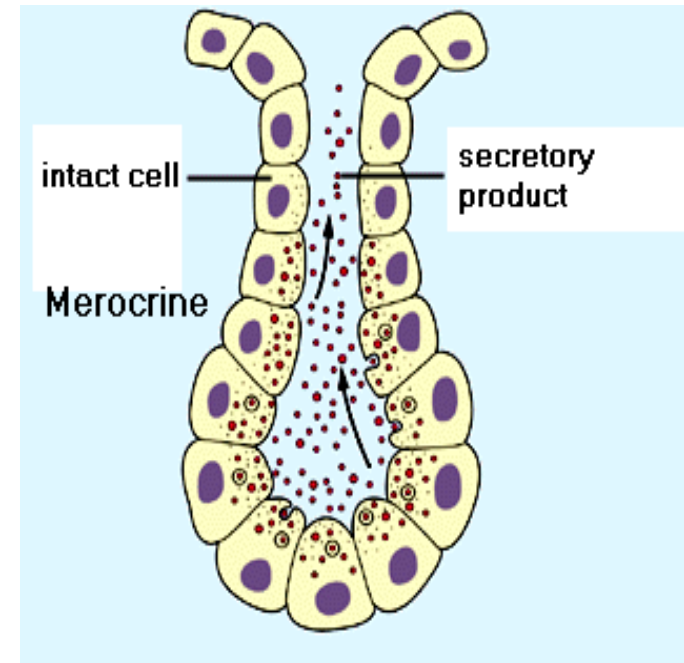
- Depending on their mode of secretion i.e; the manner in which the secretory product is elaborated, the exocrine glands are classified into the following varieties:
  1. Merocrine glands
  2. Apocrine glands
  3. Holocrine glands



# Merocrine glands

The secretory product is delivered in membrane-bounded vesicles to the apical surface of the cell. Here, vesicles fuse with the plasma membrane and extrude their contents by exocytosis

e.g; pancreas, salivary glands

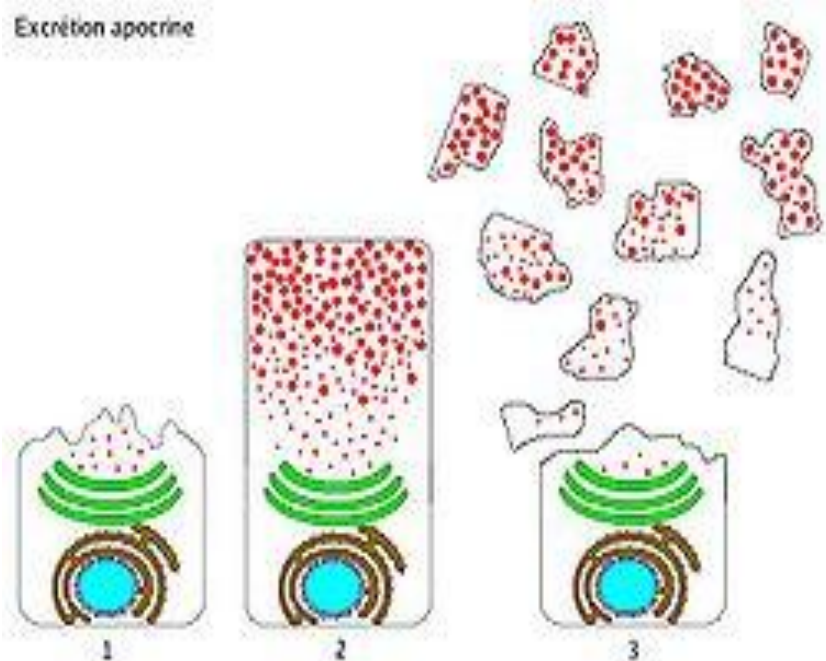


# Apocrine glands

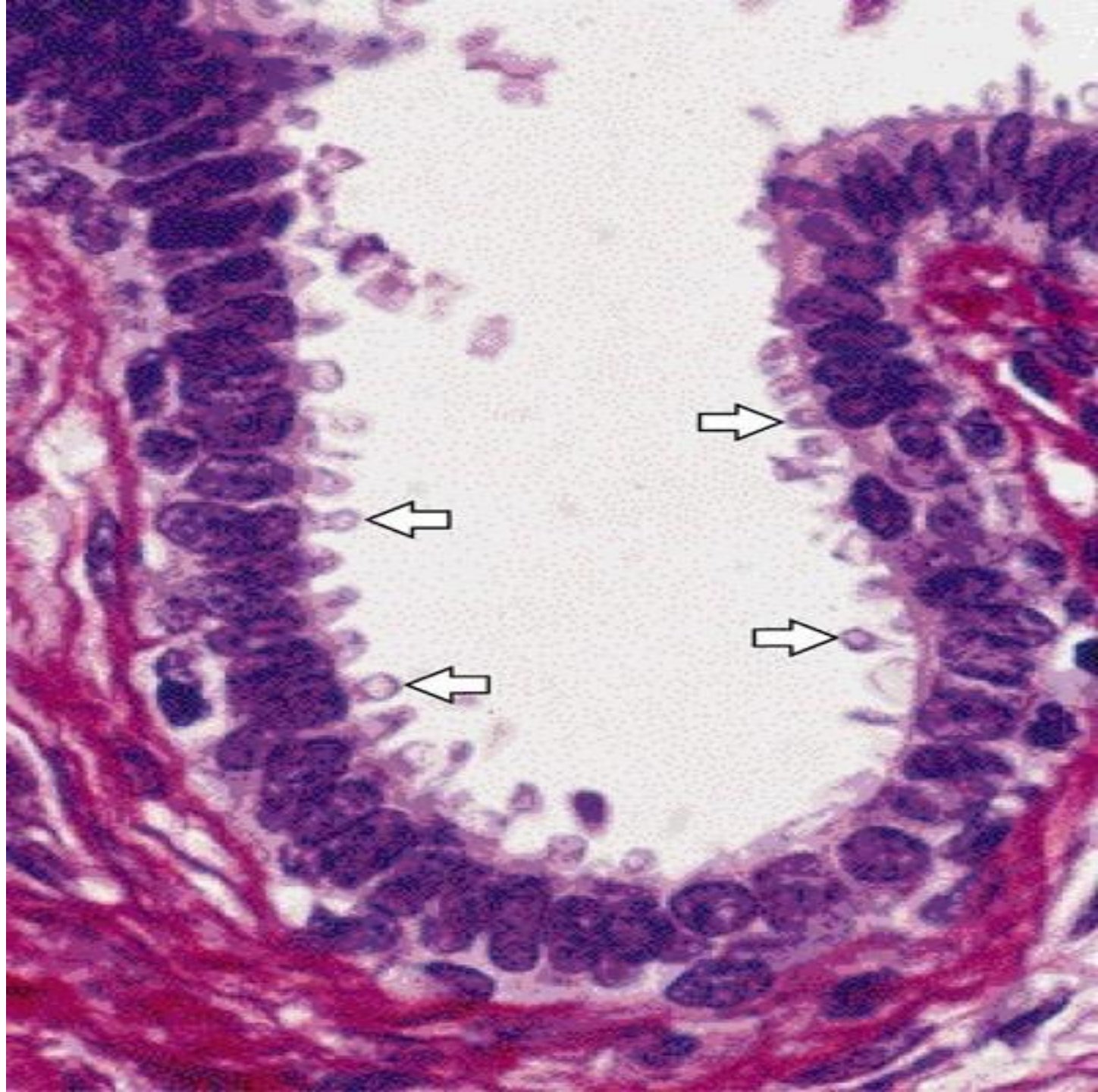
In these glands part of the apical cytoplasm is lost along with the secretory material

e.g; lactating mammary glands, special sweat glands located in axilla and perianal area and the ceruminous glands of the external auditory meatus

Excretion apocrine



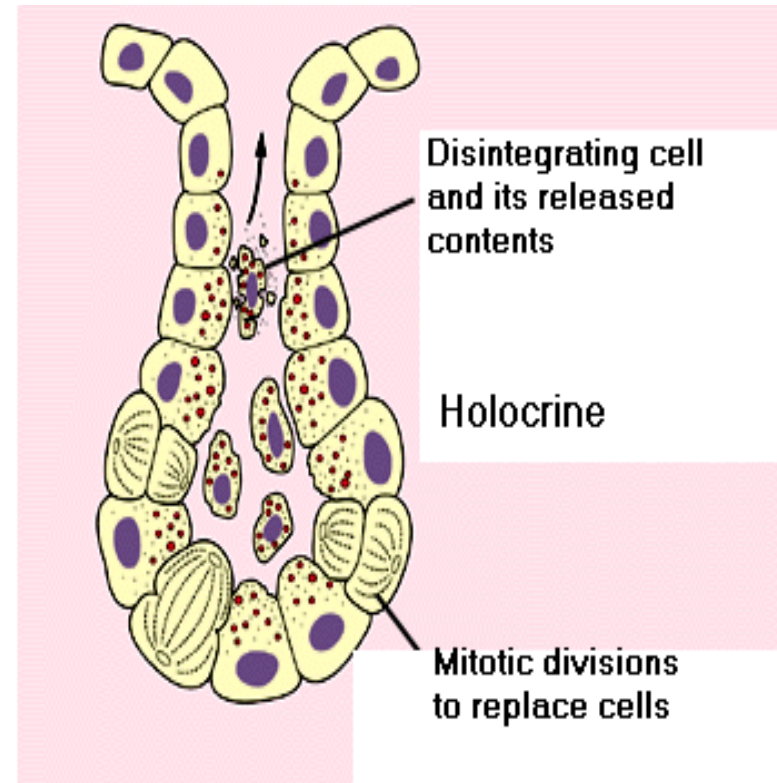
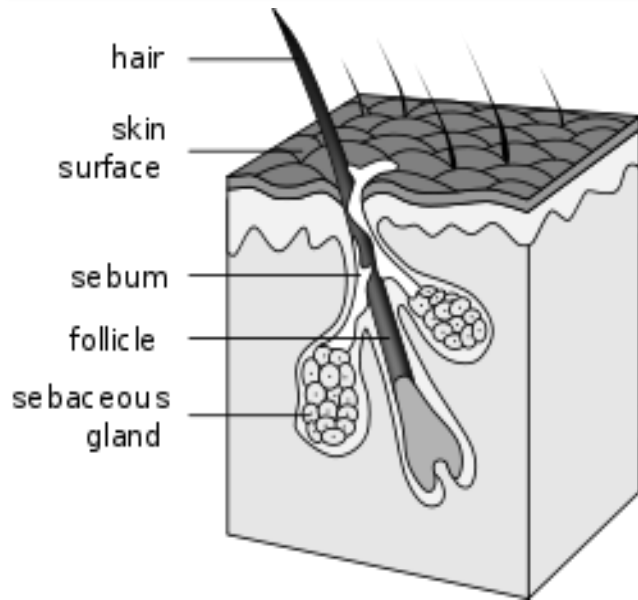




# Holocrine glands


In these glands entire cells laden with secretory material disintegrate and all of the cellular contents are discharged from the gland as secretions

e.g; the sebaceous glands of skin




# Mode of Secretion


merocrine



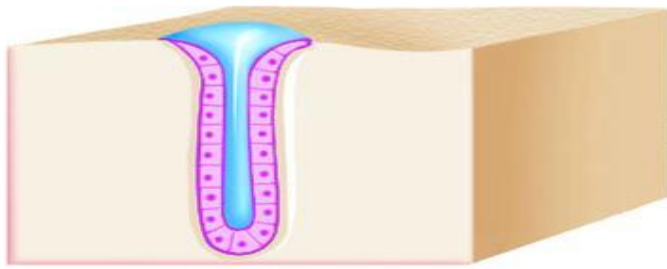
apocrine



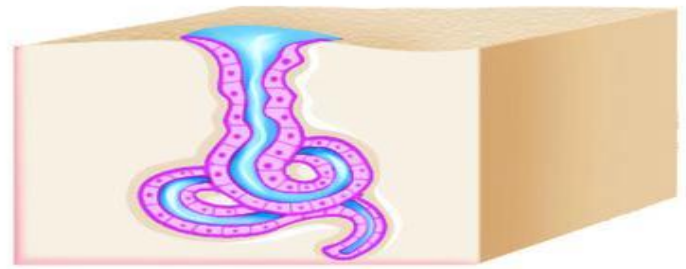
Holocrine



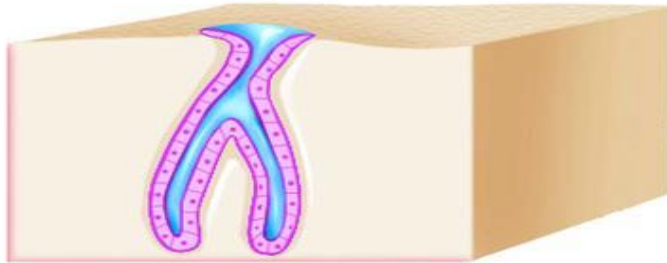




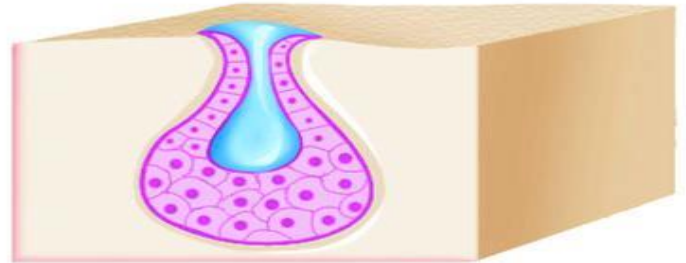
Simple tubular



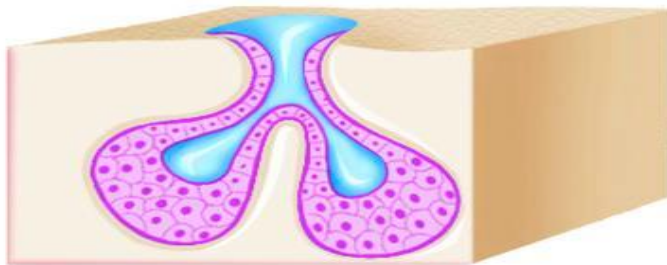
Simple coiled tubular



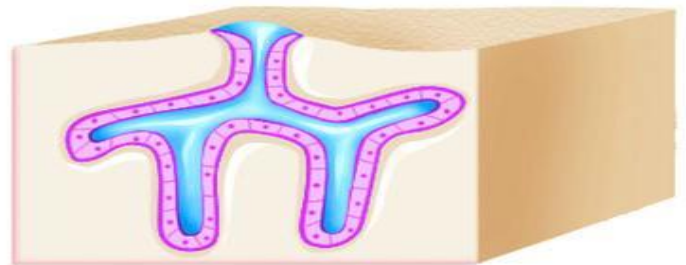
Simple branched tubular



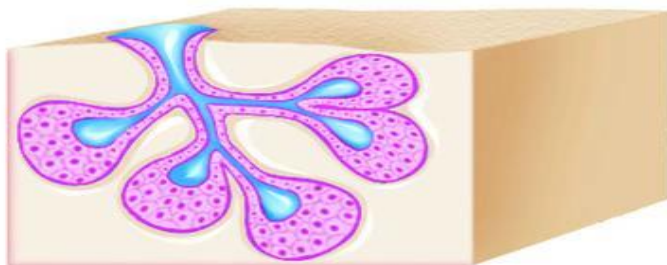
Simple alveolar



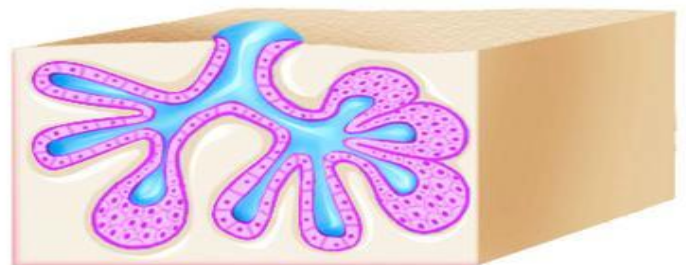Simple branched alveolar



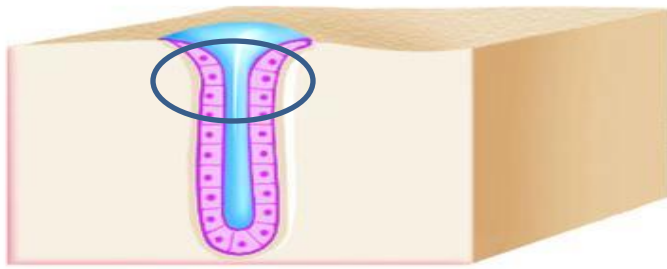
Compound tubular



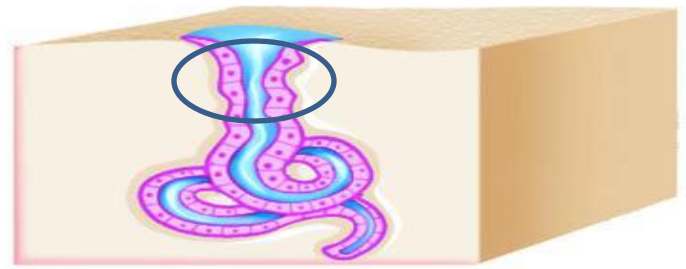
Compound alveolar



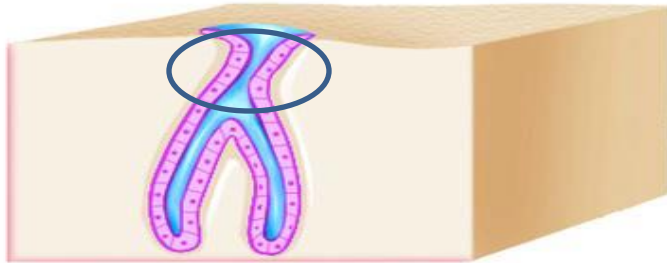
Compound tubuloalveolar



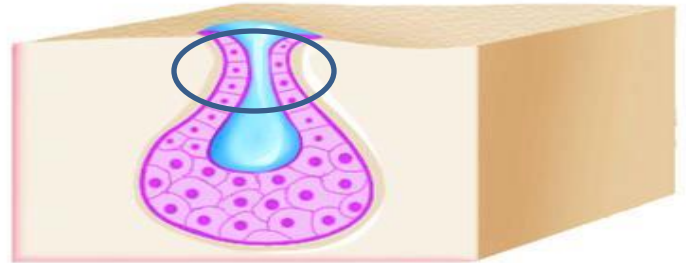
Simple tubular



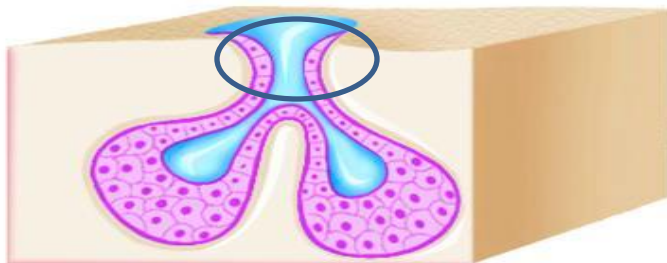
Simple coiled tubular



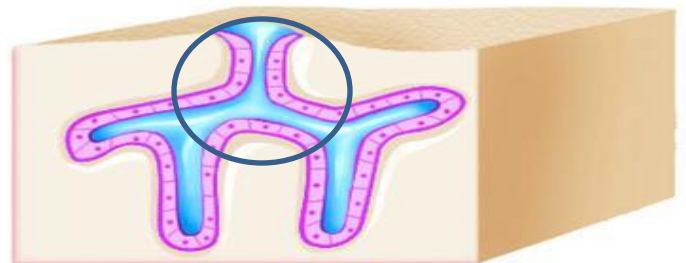
Simple branched tubular



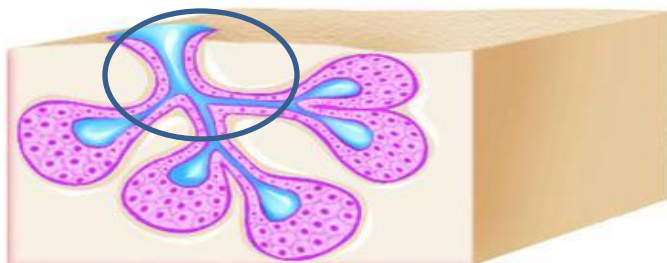
Simple alveolar



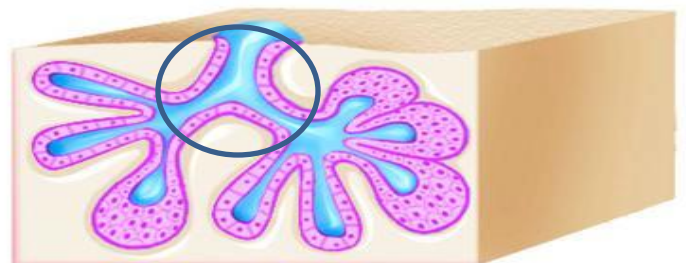
Simple branched alveolar



Compound tubular



Compound alveolar

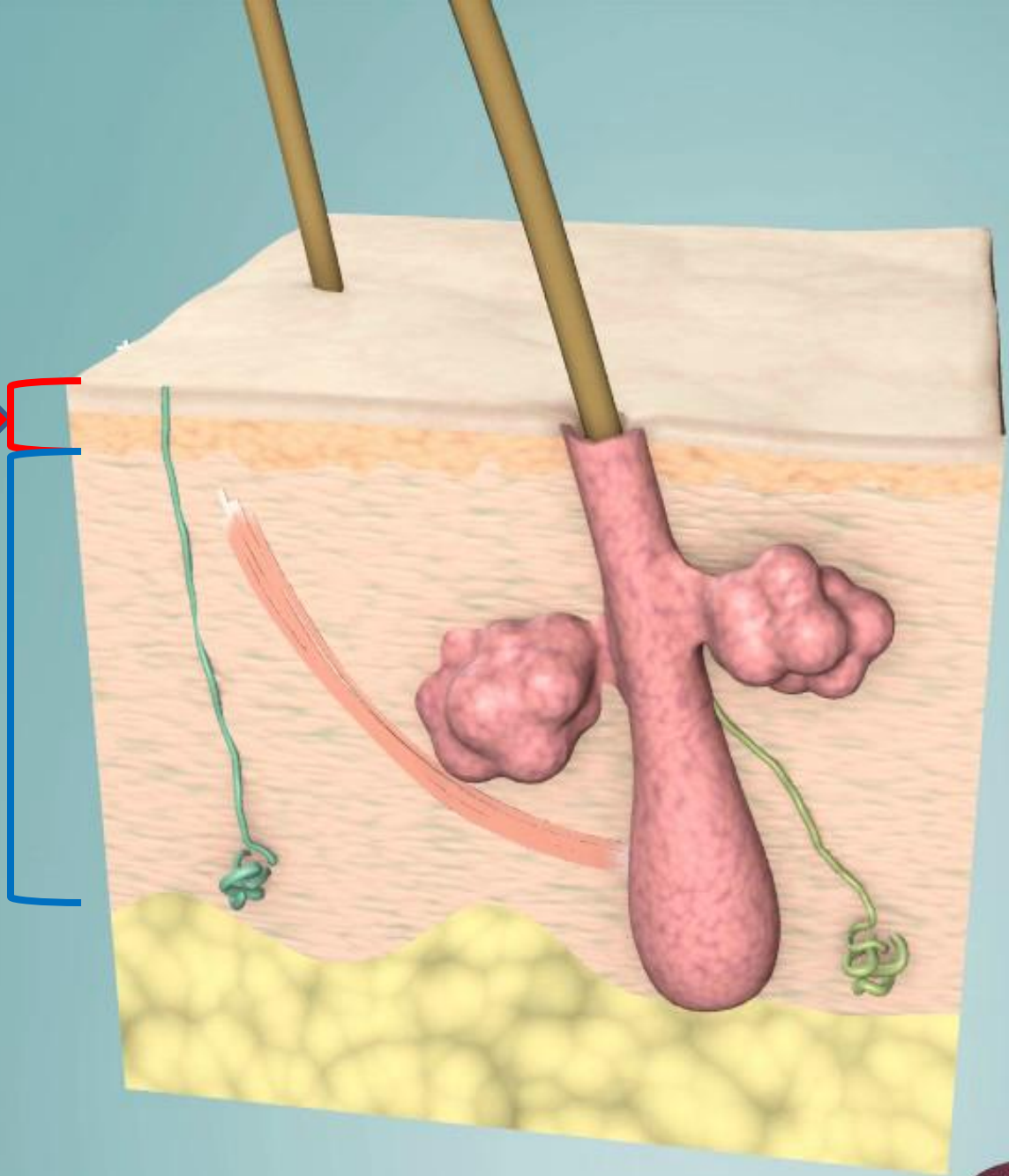


Compound tubuloalveolar

# Skin

**Epidermis:**  
keratinized  
stratified  
squamous  
epithelium


**Dermis:**  
connective  
tissue



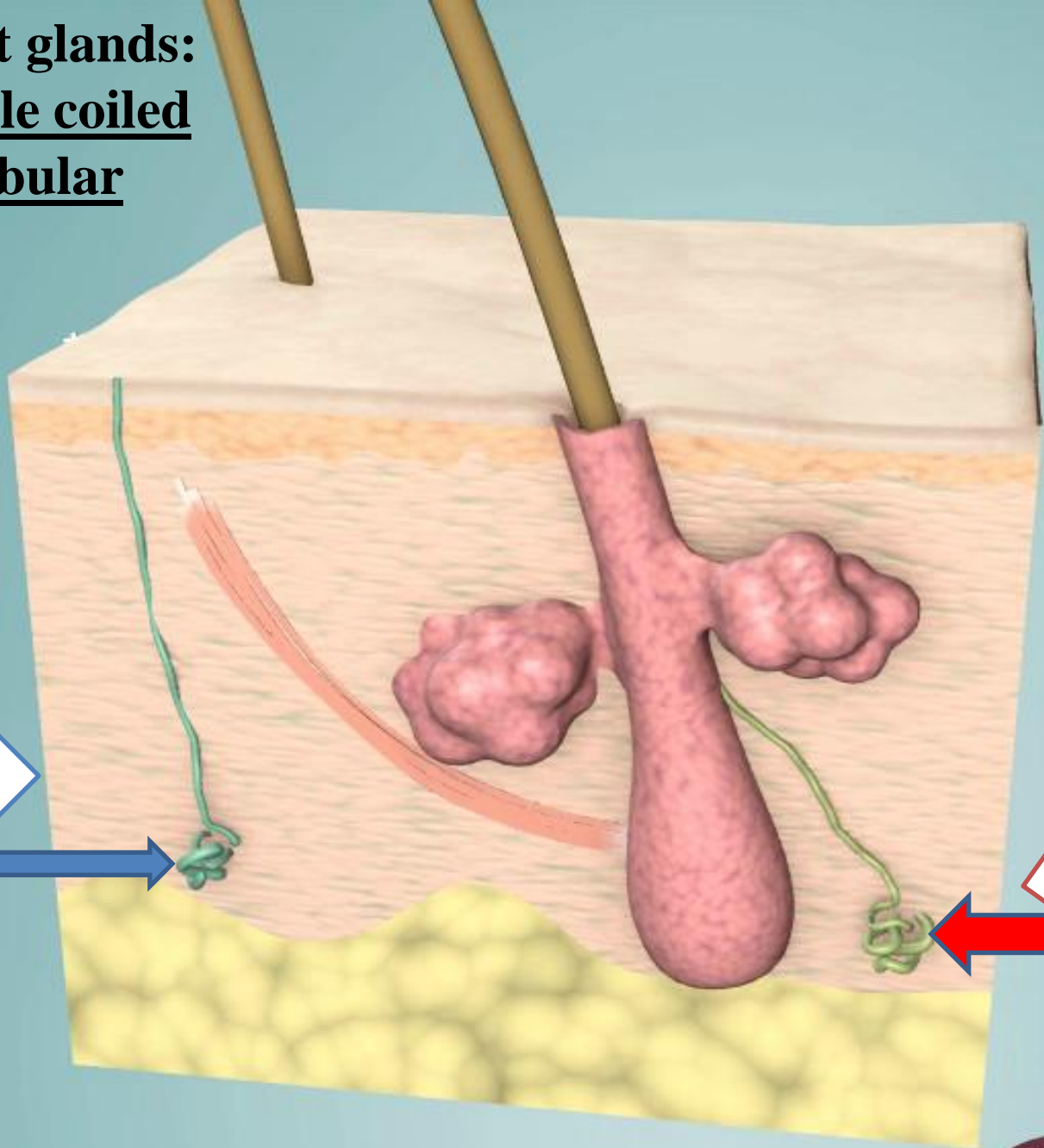


**Sweat glands:  
Simple coiled  
tubular**

Merocrine  
(eccrine) sweat  
gland



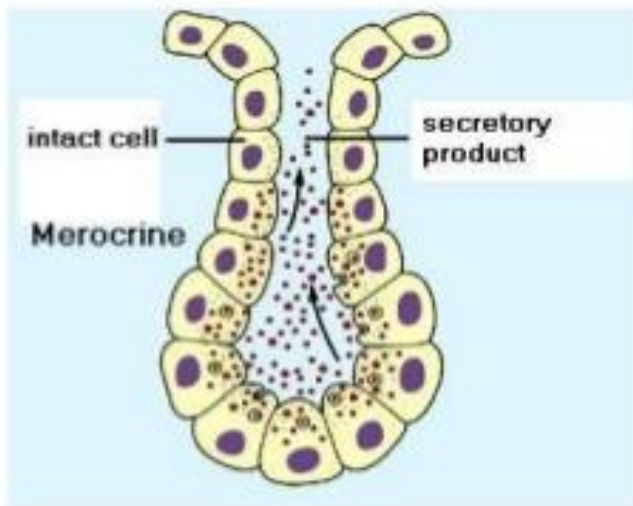
Apocrine  
sweat gland



# Types of sweat glands

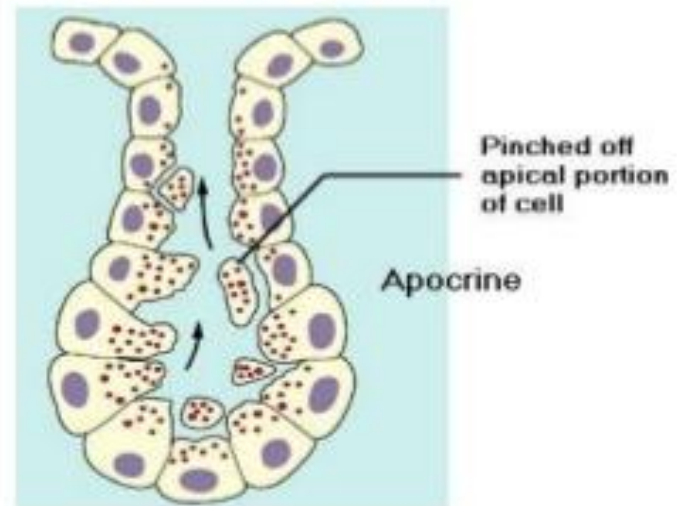
## Eccrine sweat gland

- Merocrine secretion
- Empty directly onto skin surface
- Location: most all over body (esp. abundant on palms & soles: ~ 500/cm<sup>2</sup>)
- Clear, watery secretion (99% H<sub>2</sub>O; rest NaCl + some waste products)



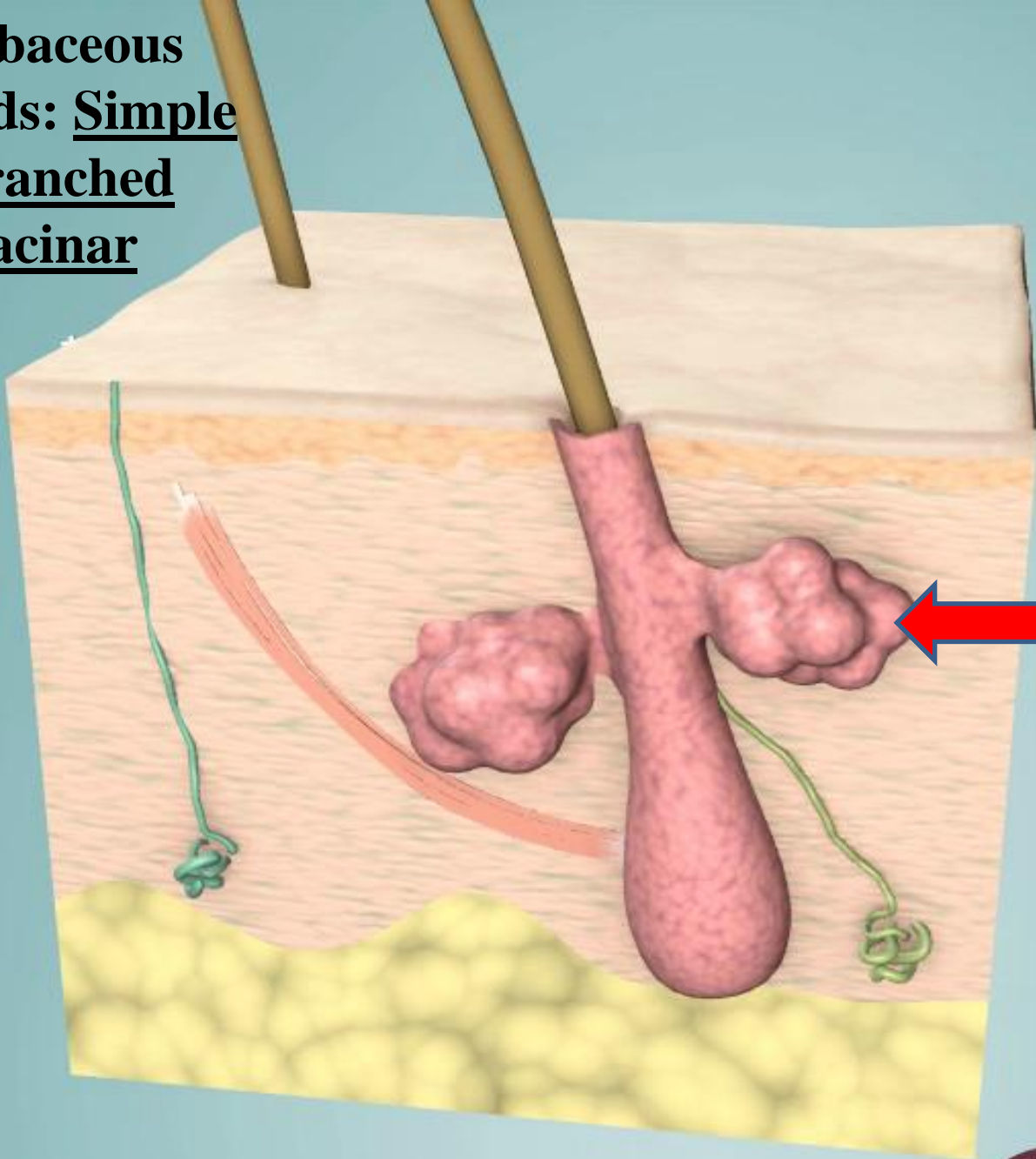
## Apocrine sweat gland

- Empty into hair follicle
- Location: armpits, groin, nipples
- Viscous, cloudy secretion → good nutrient source for bacteria (odor !!)
- Secretion may contain Pheromones
- Secretion begins at puberty and is stimulated during emotional distress





**Sebaceous glands: Simple  
branched  
acinar**




**Sebaceous gland**

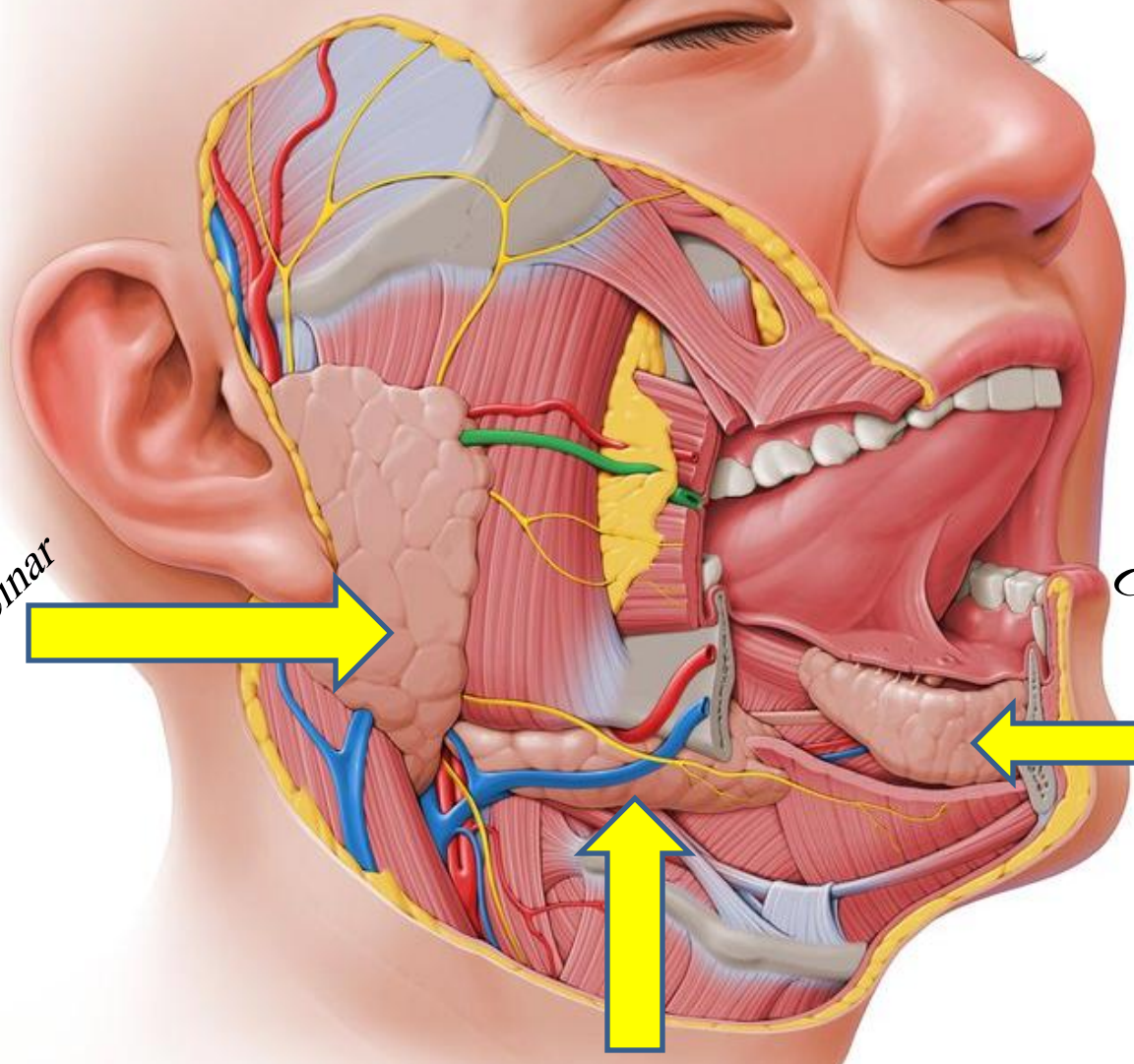
**Parotid gland**  
*Compound acinar*



**Sublingual gland**  
*Compound tubulo-acinar*



**Submandibular gland**  
*Compound tubulo-acinar*



# BODY MEMBRANES

- Epithelial Membranes = epithelial layer of cells plus the underlying connective tissue.

Three Types:

1. Mucous membranes
2. Serous membranes
3. Cutaneous membranes

# BODY MEMBRANES

1. Mucous membrane = mucosa; it lines cavities that open to the exterior, such as the GI tract.
  - The epithelial layer of the mucous membrane acts as a barrier to disease organisms.
  - The connective tissue layer of the mucous membrane is called the lamina propria.
  - Found as the lining of the mouth, vagina, and nasal passage.

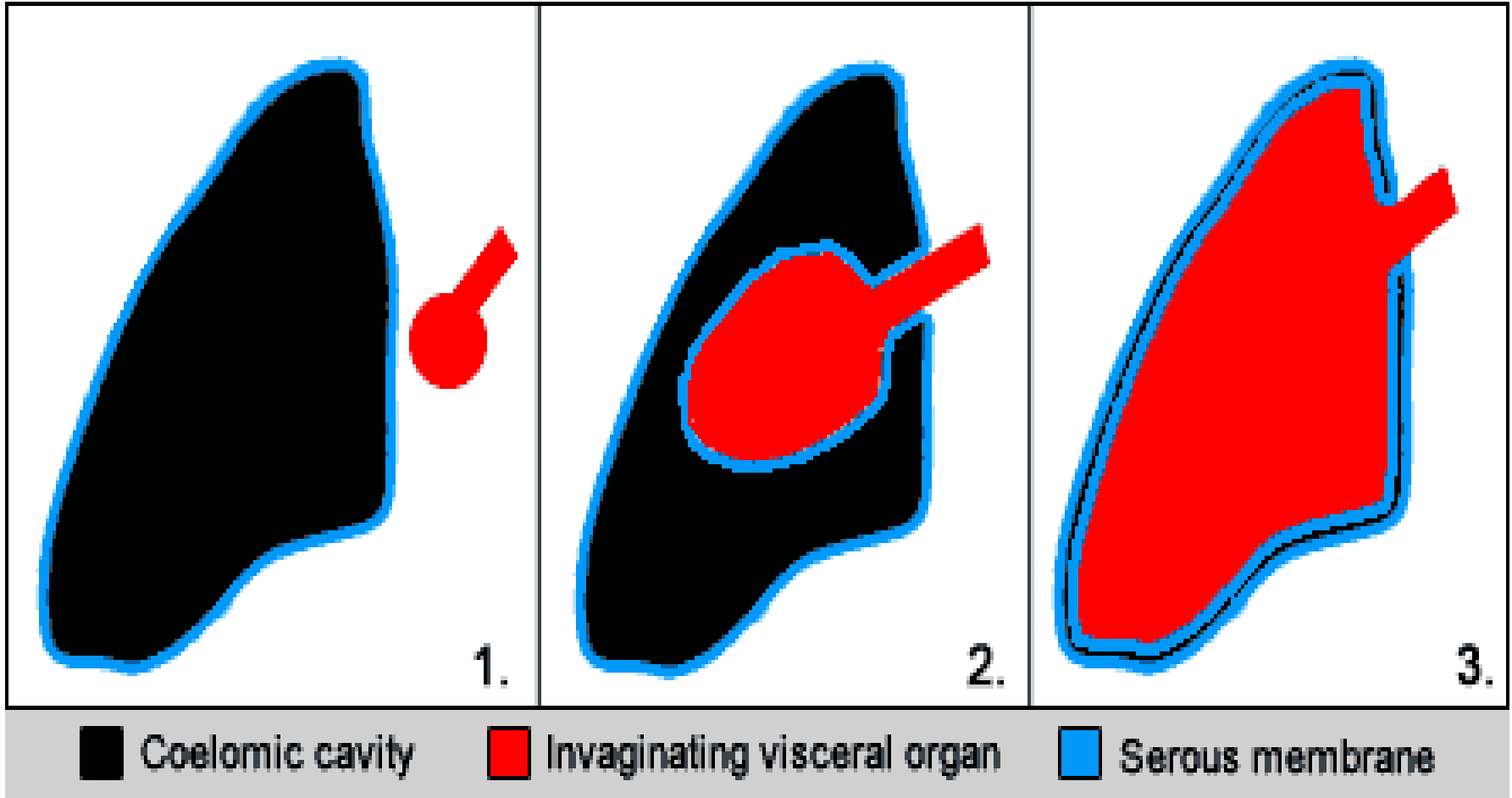
# BODY MEMBRANES

2. Serous membrane = serosa, membrane lines a body cavity that does NOT open to the exterior and it covers the organs that lie within the cavity.
    - a. pleura = lungs
    - b. pericardium = heart
    - c. peritoneum = abdomen
  - The serous membrane has two portions:
    1. parietal portion = lining outside the cavity.
    2. visceral portion = covers the organ.
- .

# BODY MEMBRANES

Serous membranes epithelial layer secretes a lubricating **SEROUS FLUID**, that reduces friction between organs and the walls of the cavities in which they are located.

- The serous fluid is named by location:
- Pleural fluid is found between the parietal and visceral pleura of the lungs.
- Pericardial fluid is found between the parietal and visceral pericardium of the heart.
- Peritoneal fluid is found between the parietal and visceral peritoneum of the abdomen.





# BODY MEMBRANES

