

GLUTEAL REGION

SKIN AND FASCIA OF THE GLUTEAL REGION

A) Skin of the Buttock (Gluteal region)

1-The upper medial quadrant
Supplied by

L1
L2
L3

S1
S2
S3

2-The upper lateral quadrant
Supplied by
Anterior primary rami of

Lateral cutaneous branch of iliohypogastric nerve

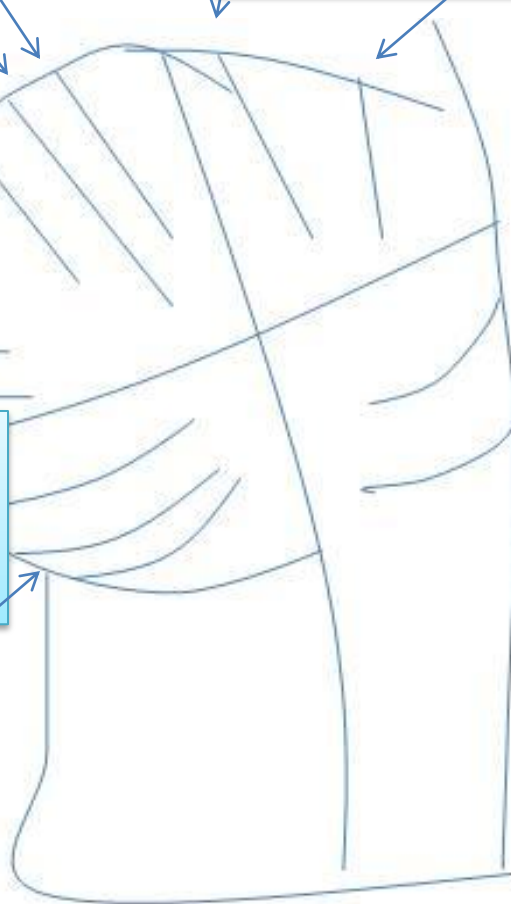
Lateral cutaneous nerve of the subcostal nerve T12

4-The lower lateral quadrant
Supplied by
Anterior primary rami of

Branches from lateral cutaneous nerves of the thigh

3-The lower medial quadrant
Supplied by
Anterior primary rami of

Branches from posterior cutaneous nerve of the thigh



Cutaneous Innervation of the gluteal region

B) Fascia of the Buttock (Gluteal region)

1- Superficial fascia; is **thick** especially in women . It contributes to the prominence of the buttock.

2- Deep fascia; continuous with the deep fascia of the thigh (fascia lata).

Fascia lata

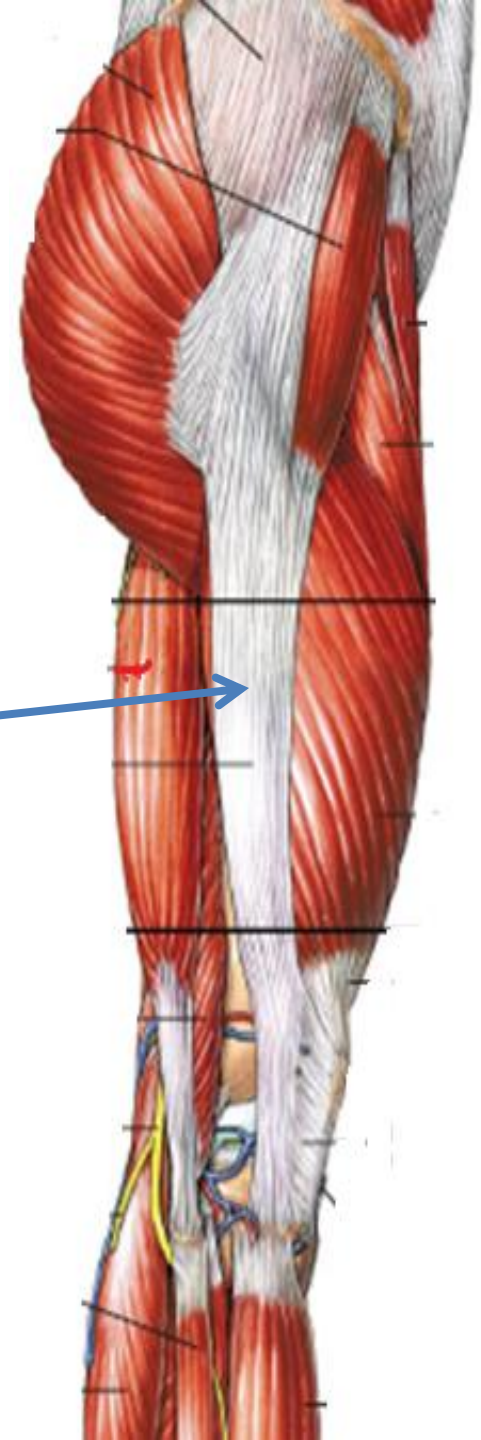
➤ Is a strong **fibrous sheet** that surrounds the whole of the thigh like a **tight trousers**.

➤ **Thin** on its **medial** side while it is getting **thicker** on its **lateral** side to form **the iliotibial tract**.

Iliotibial tract

Is a strong wide band (**thickening of the deep fascia (fascia lata)**) on the **lateral** side of the thigh) attached above to the tubercle of ilium and below to the lateral condyle of tibia.

Receives the insertion of tensor fascia latae and GM muscles.

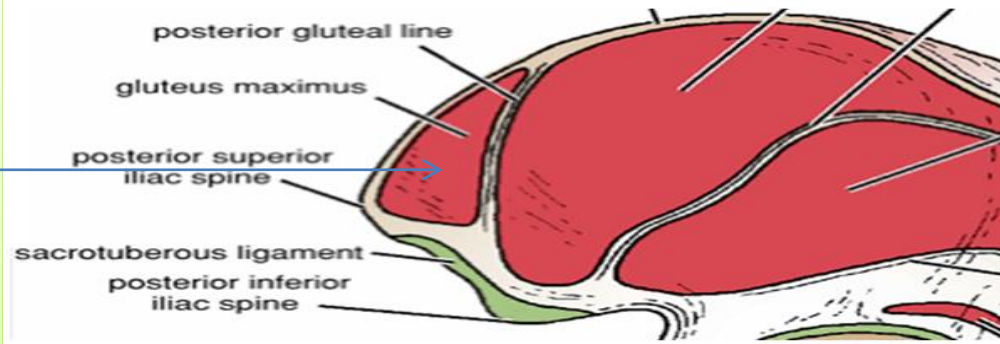


MUSCLES OF THE GLUTEAL REGION

Gluteus maximus

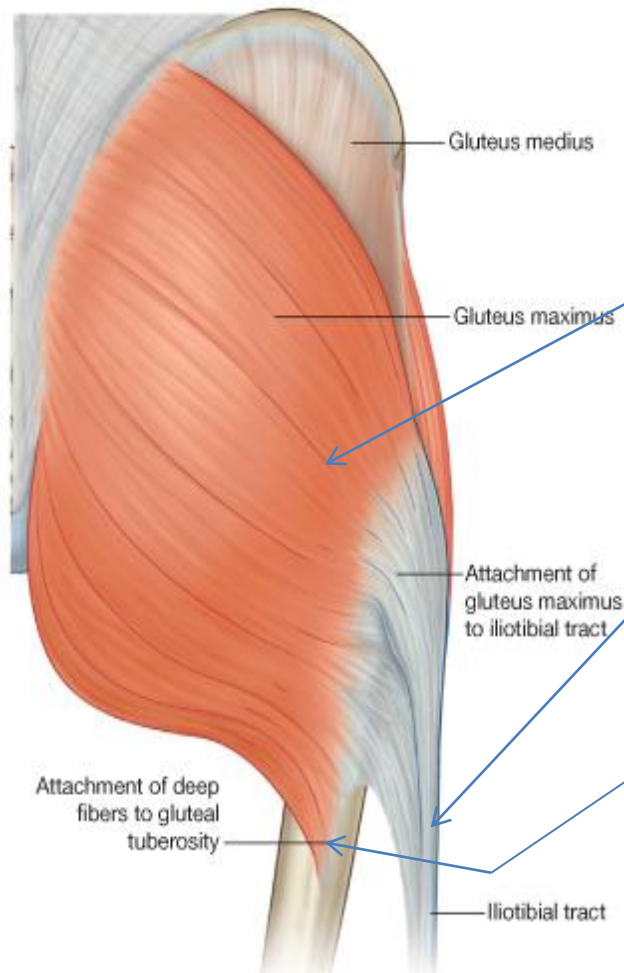
➤ Origin:

- 1- Ilium (area behind the *posterior gluteal line*)
- 2- Back of *sacrum* and *coccyx*
- 3- Back of *sacrospinous* ligament

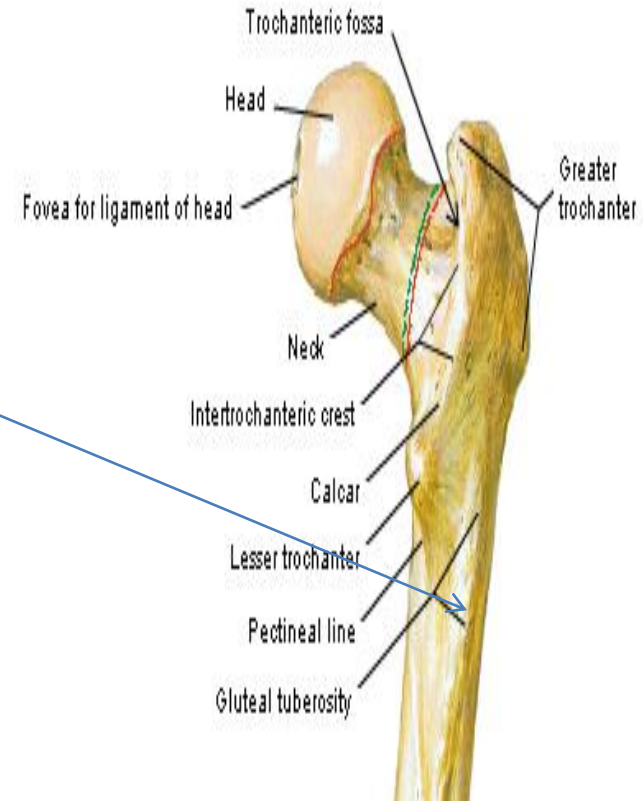


➤ Insertion

- 1- The *superficial three-fourths* are inserted into the *iliotibial tract*
- 2- The *lower deep part* is inserted into the *gluteal tuberosity of femur*



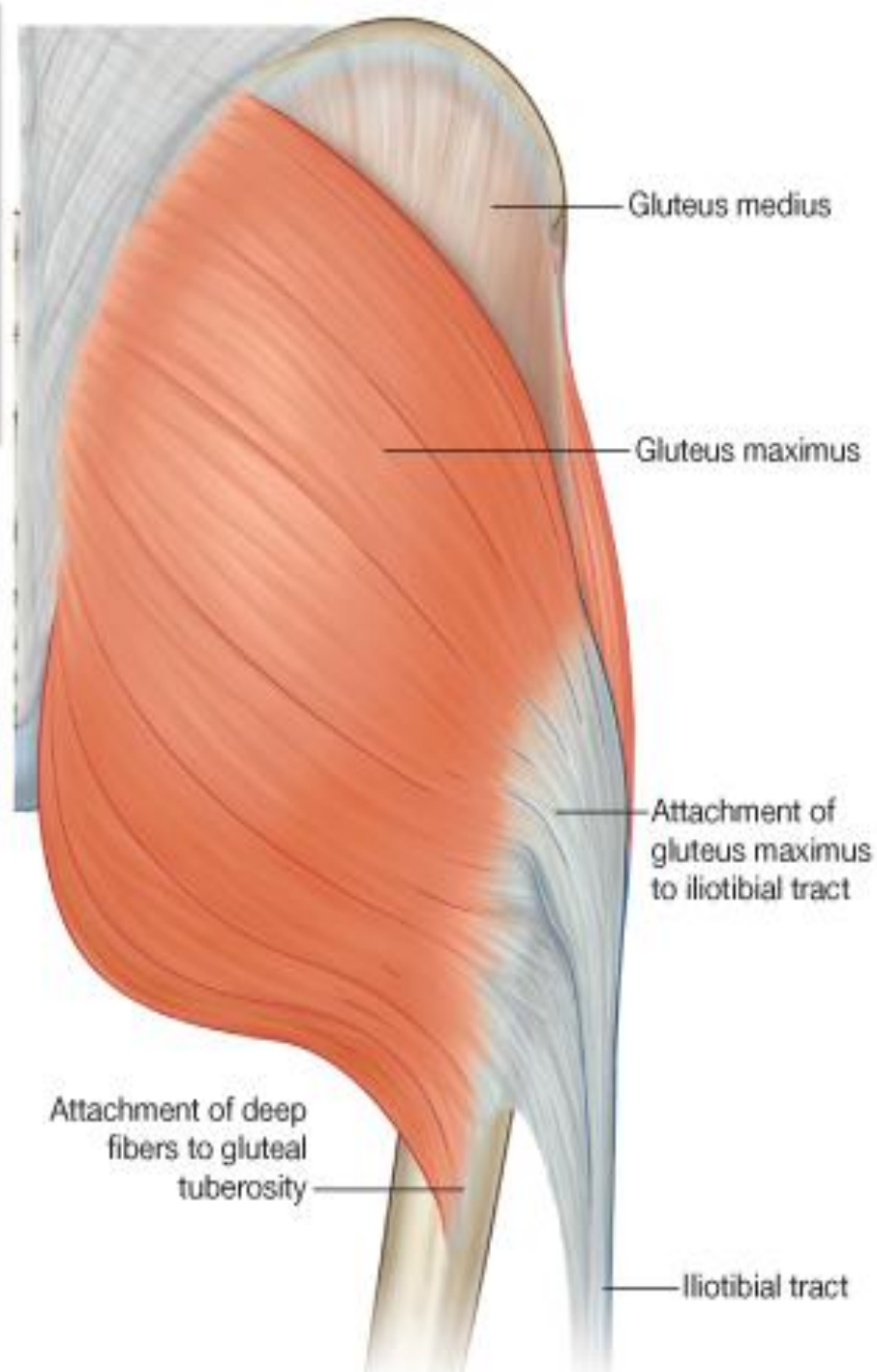
Femur Posterior View



➤ **Actions**

- 1- Extends thigh, some lateral rotation (**main extensor of the hip joint**)
- 2- Plays an important role in climbing upstairs and cycling
- 3- Supports the Extended knee joint through **Iliotibial tract**

➤ **Innervation** - Inferior gluteal nerve, L5;S1,2



STRUCTURES UNDER THE COVER OF GLUTEUS MAXIMUS MUSCLE

A- Bony structures

- 1-Greater trochanter and bursa
- 2-Gluteal tuberosity
- 3-Ischial tuberosity and bursa

B- Ligaments

- 1- Sacrotuberous ligament
- 2- Scrospinous ligament

C- Muscles

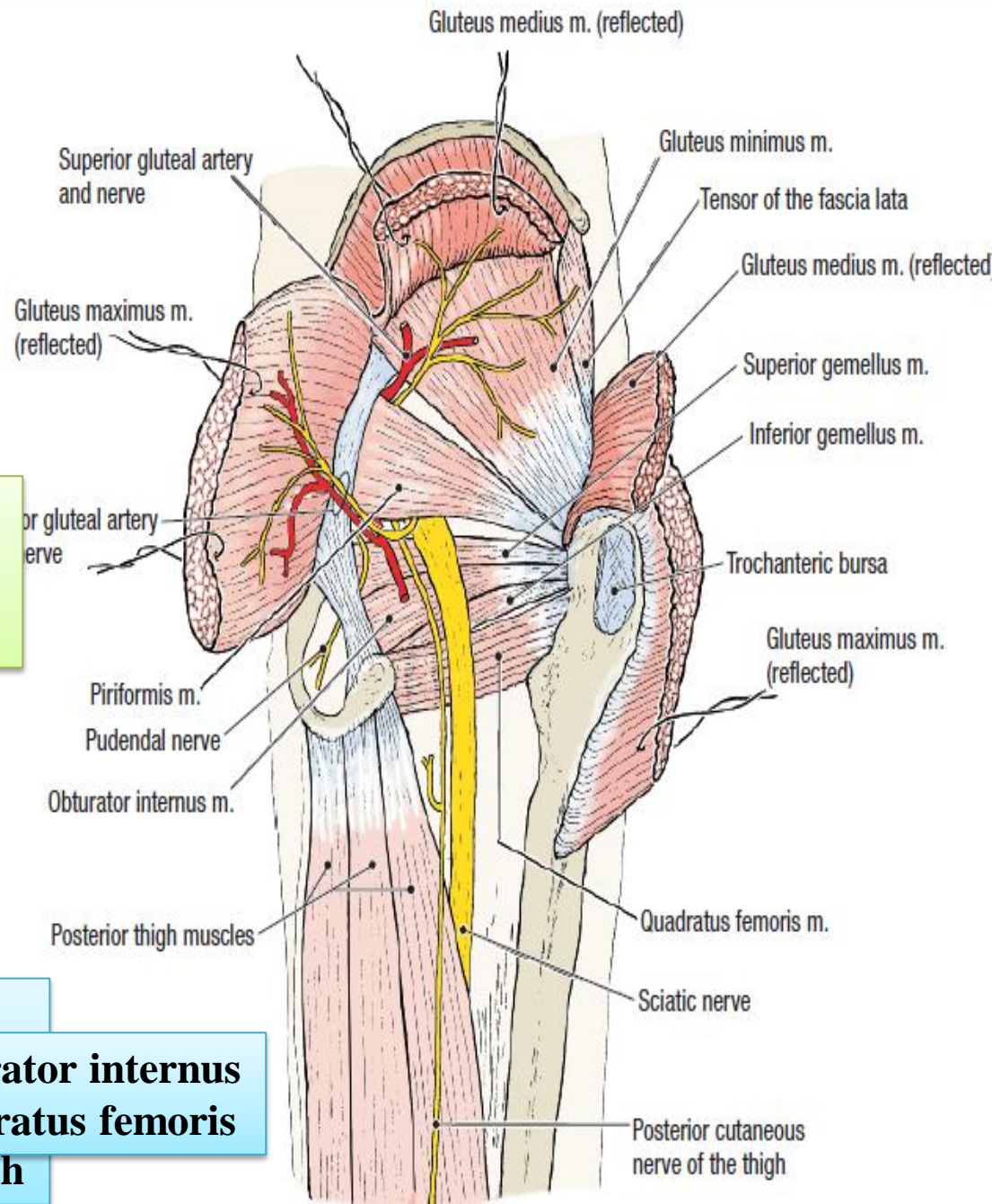
- 1- Gluteus medius and minimus
- 2-Short Lateral rotator muscles (6)
- 3- origin of the hamstring muscles

D- Vessels

- 1- Superior gluteal vessels
- 2- inferior gluteal vessels
- 3- Internal pudendal vessels

E- Nerves

- 1- Superior and inferior gluteal nerve
- 2- Sciatic nerve
- 3- Pudendal nerve
- 4- Posterior cutaneous nerve of the thigh
- 5- Nerve to obturator internus
- 6- Nerve to quadratus femoris



Tensor fasciae latae

➤ **Origin**

Iliac crest

➤ **Insertion**

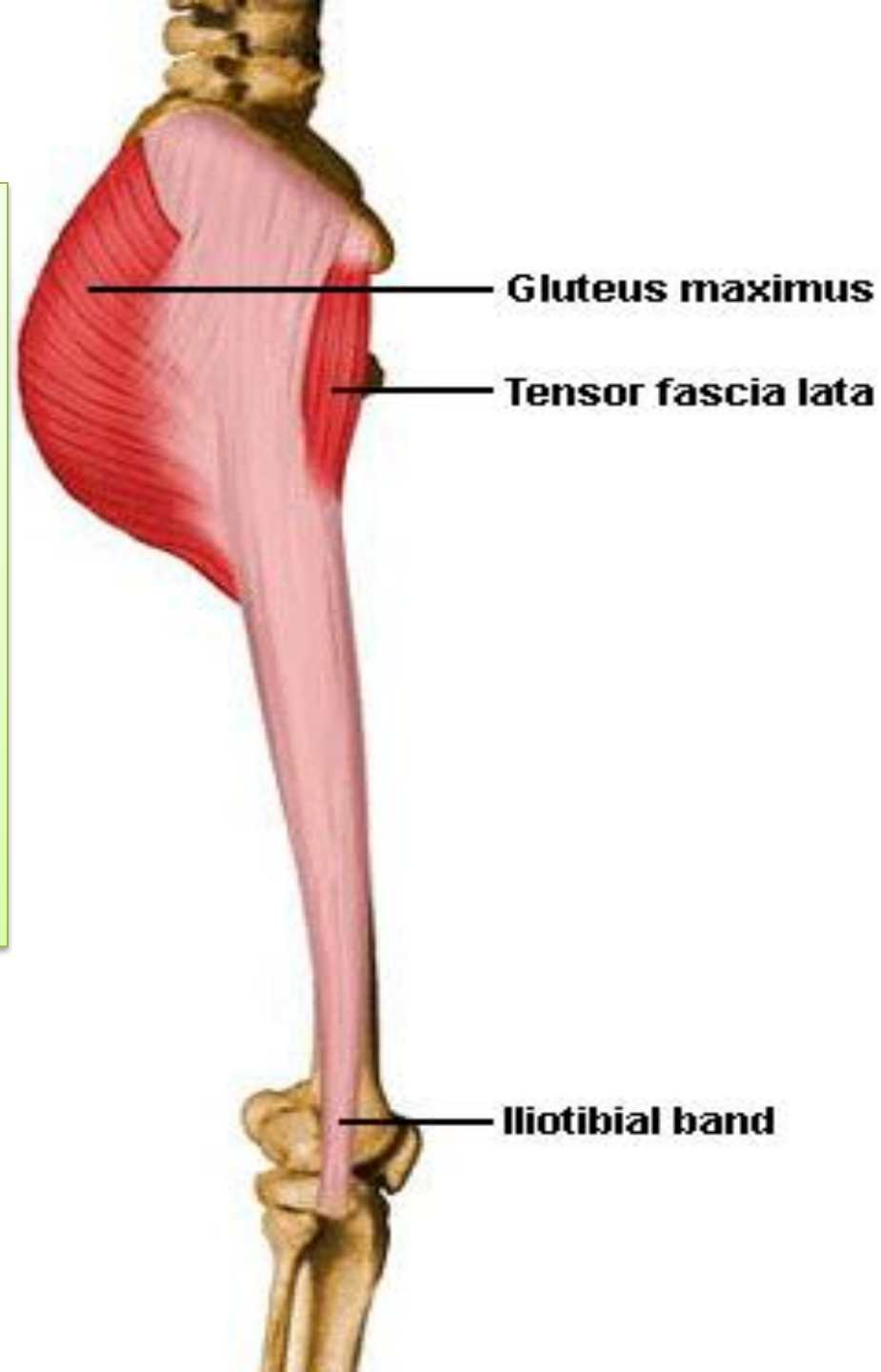
Iliotibial tract

➤ **Action**

Assist gluteus maximus in extending the knee joint

➤ **Nerve supply**

Superior gluteal nerve L4,5



- **Gluteus medius**
- **Gluteus minimus**

➤ **Origin**

Ilium ?

➤ **Insertion**

Greater trochanter of femur

➤ **Actions**

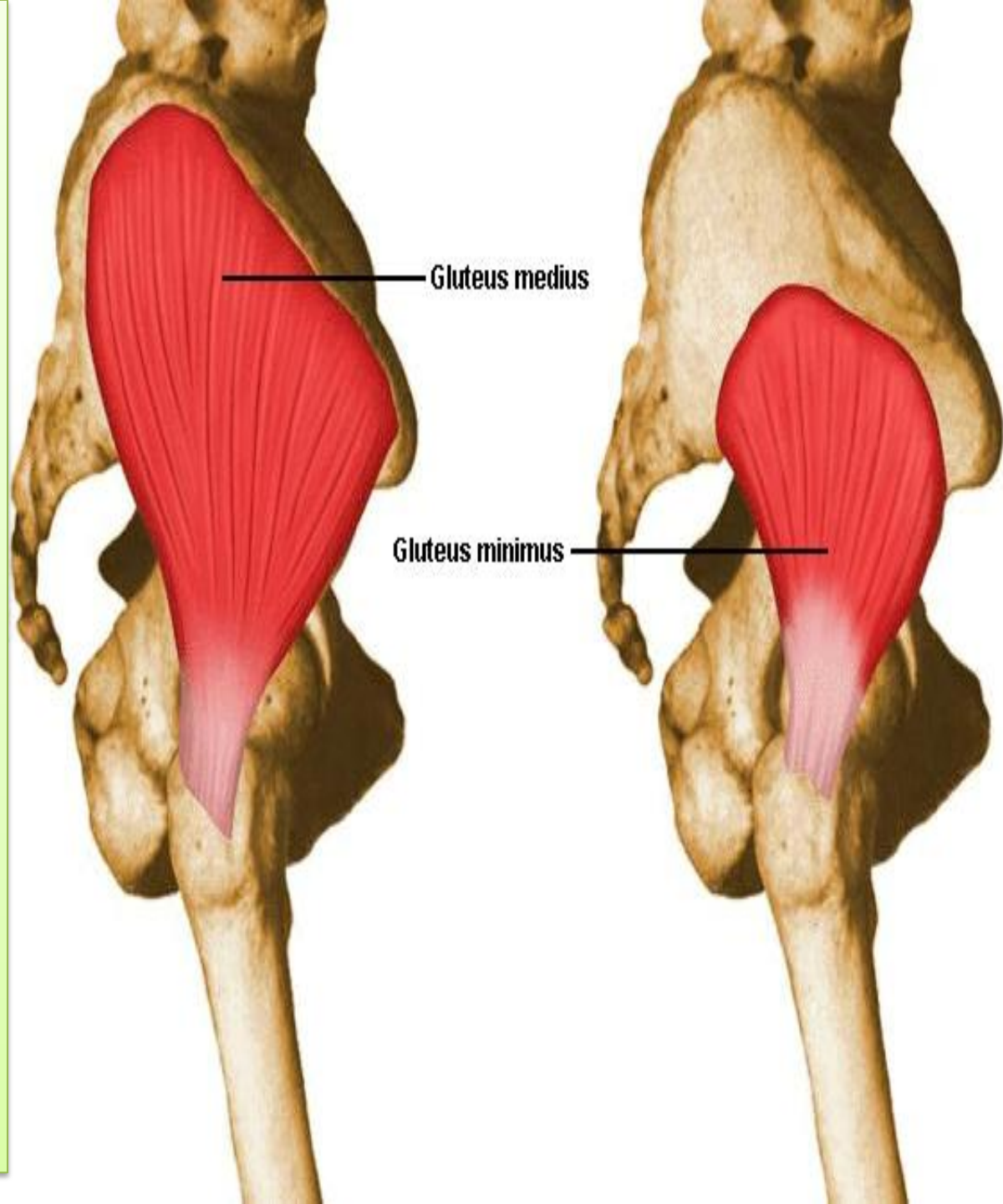
1-Abduction (*main abductor of the hip joint*)

2-Medial rotation (*anterior fibers*)

3-Both muscle contract reflexly on each side alternatively during walking to prevent tilting of the pelvis to the unsupported side

➤ **Innervation**

Superior gluteal nerve



Short Lateral rotator muscles

1-Piriformis

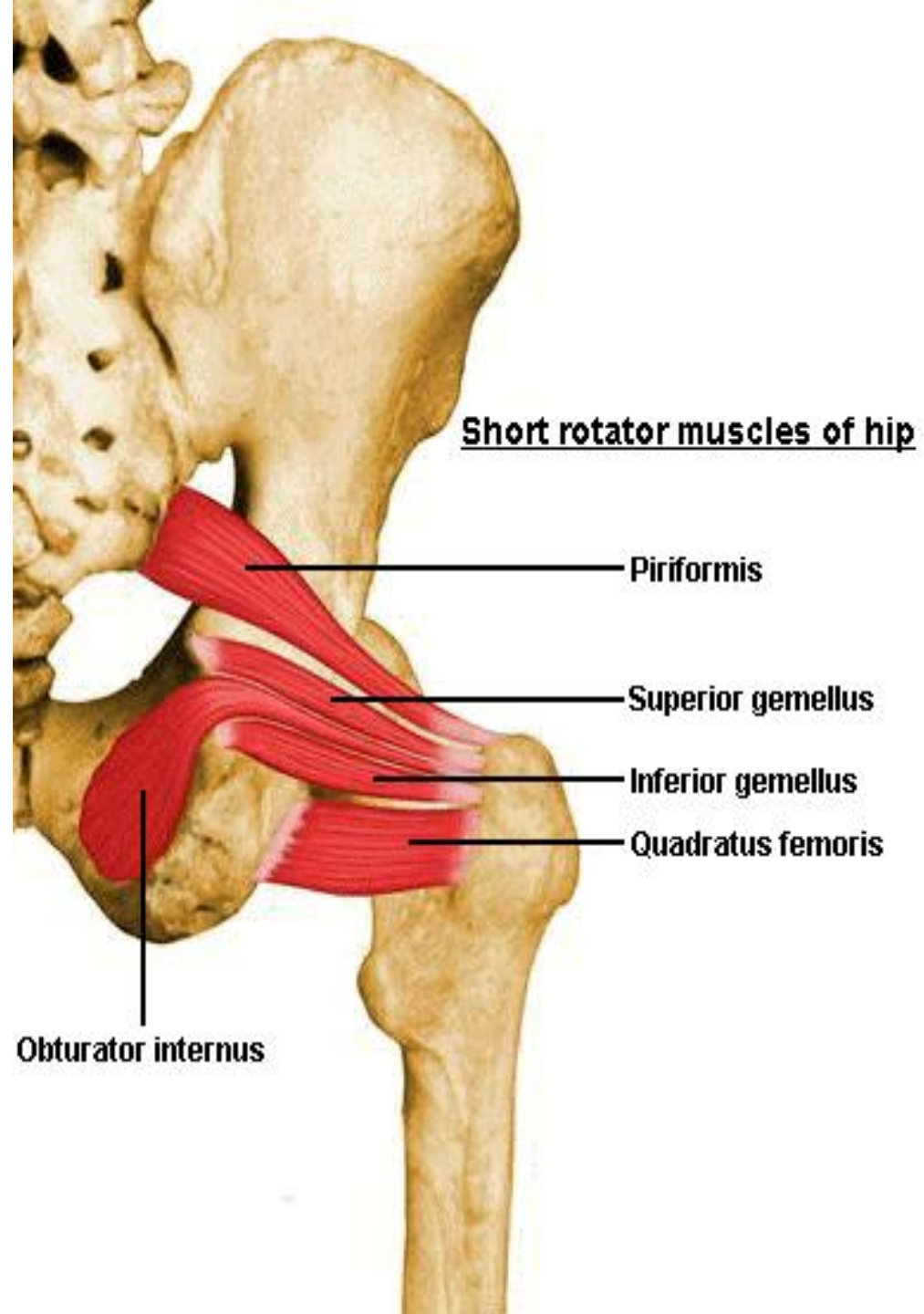
2-Quadratus femoris

3-Obturator internus

4-Superior gemellus

5-Obturator externus

6-Inferior gemellus



Read these muscles from this slide which can be found on page (566) Snell 8th edition

Short lateral rotator muscles of the hip joint

They have common function; **lateral rotation of the thigh at hip joint.**

Muscle	Origin	Insertion	Nerve supply
Piriformis	Anterior surface of sacrum	Upper border of greater trochanter of femur	First and second sacral nerves
Obturator internus	Inner surface of obturator membrane	Upper border of greater trochanter of femur	Sacral plexus
Gemellus superior	Spine of ischium	Upper border of greater trochanter of femur	Sacral plexus
Gemellus inferior	Ischial tuberosity	Upper border of greater trochanter of femur	Sacral plexus
Quadratus femoris	Lateral border of ischial tuberosity	Quadrate tubercle of femur	Sacral plexus

Make sure that you know where to find it on the femur

A) Structures passing through the greater sciatic foramen:

foramen:

1- **Piriformis:** *fills the foramen almost completely leaving some structures to pass either **above** or **below** it.*

Structures passing above Piriformis muscle:

1- Superior gluteal nerve and vessels

Structures passing below Piriformis muscle:

1- inferior gluteal nerve

2- inferior gluteal vessels

3- sciatic nerve

4- posterior cutaneous nerve of the thigh

5- nerve to quadratus femoris

6- pudendal nerve

7- internal pudendal vessels

9- nerve to obturator internus

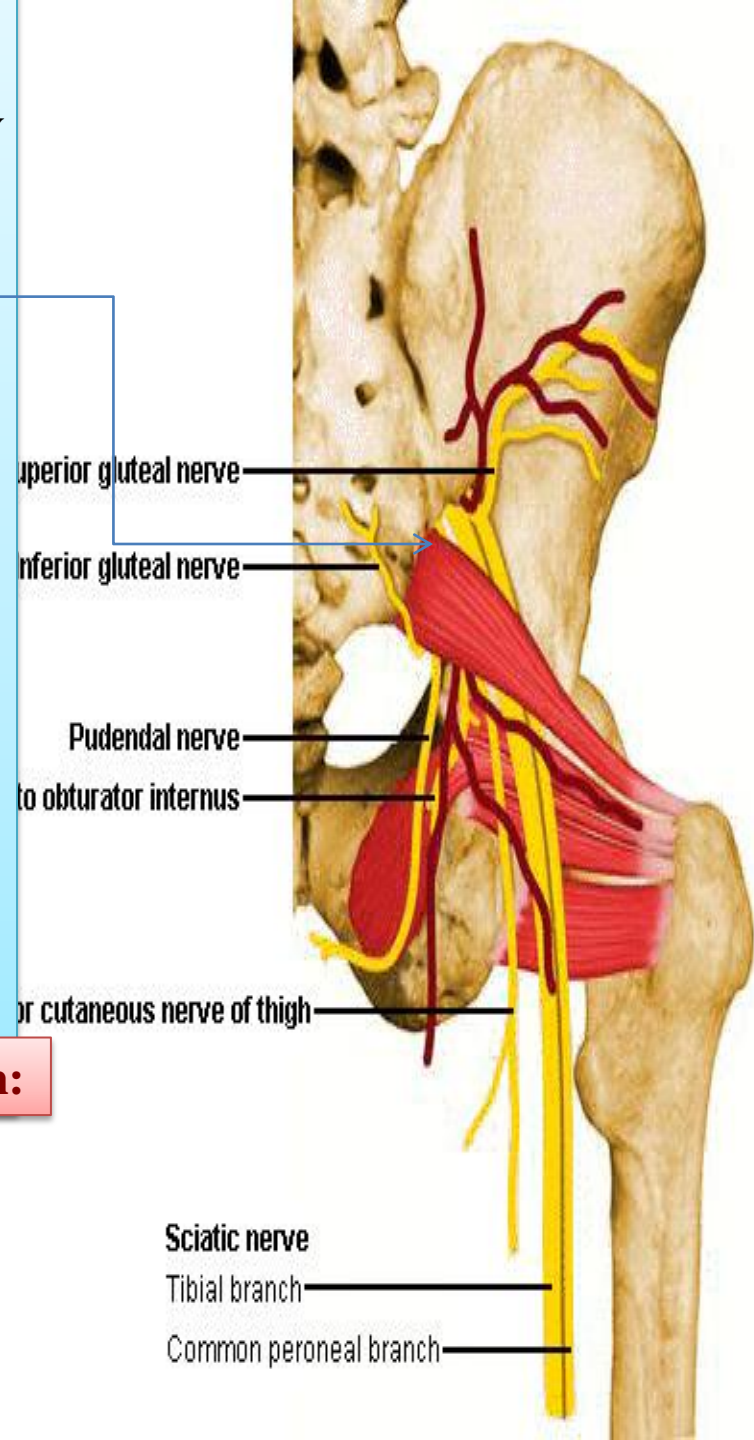
B) Structures passing through the lesser sciatic foramen:

1- tendon of obturator internus

2- pudendal nerve

3- internal pudendal vessels

4- nerve to obturator internus



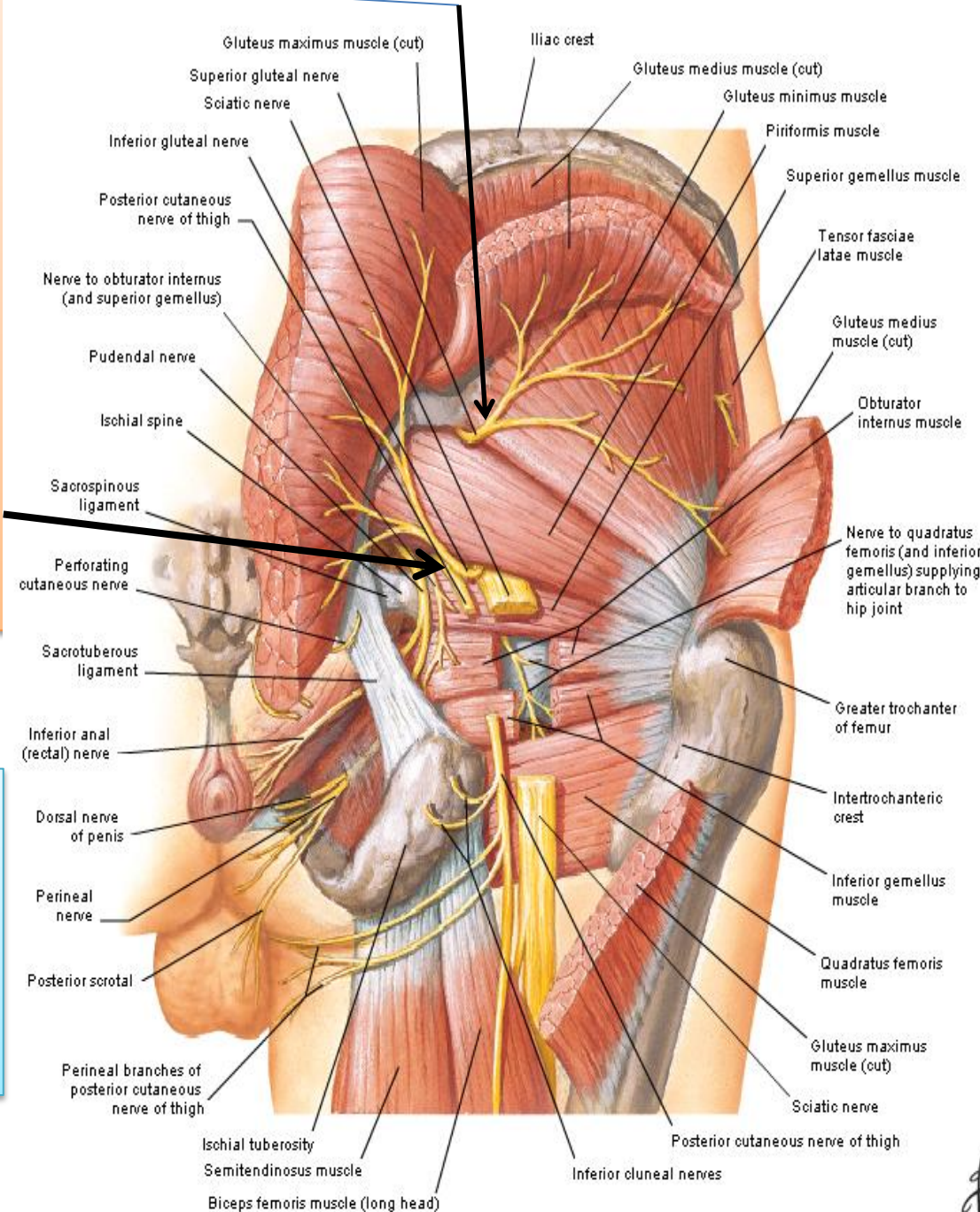
Superior Gluteal Nerve (L4, 5 and S1)

- a branch of the sacral plexus
- leaves the pelvis through the greater sciatic foramen **above the piriformis**
- It divides into **superior and inferior branches**
- The superior branch **supplies the gluteus medius muscle**
- The inferior branch **supplies the gluteus medius, minimus muscles** and ends by supplying the **tensor fasciae latae muscle**.

Inferior Gluteal Nerve (L5, S1, S2)

- a branch of the sacral plexus, leaves the pelvis through the greater sciatic foramen **below the piriformis**
- **It supplies the gluteus maximus muscle**

Nerves of Hip and Buttock



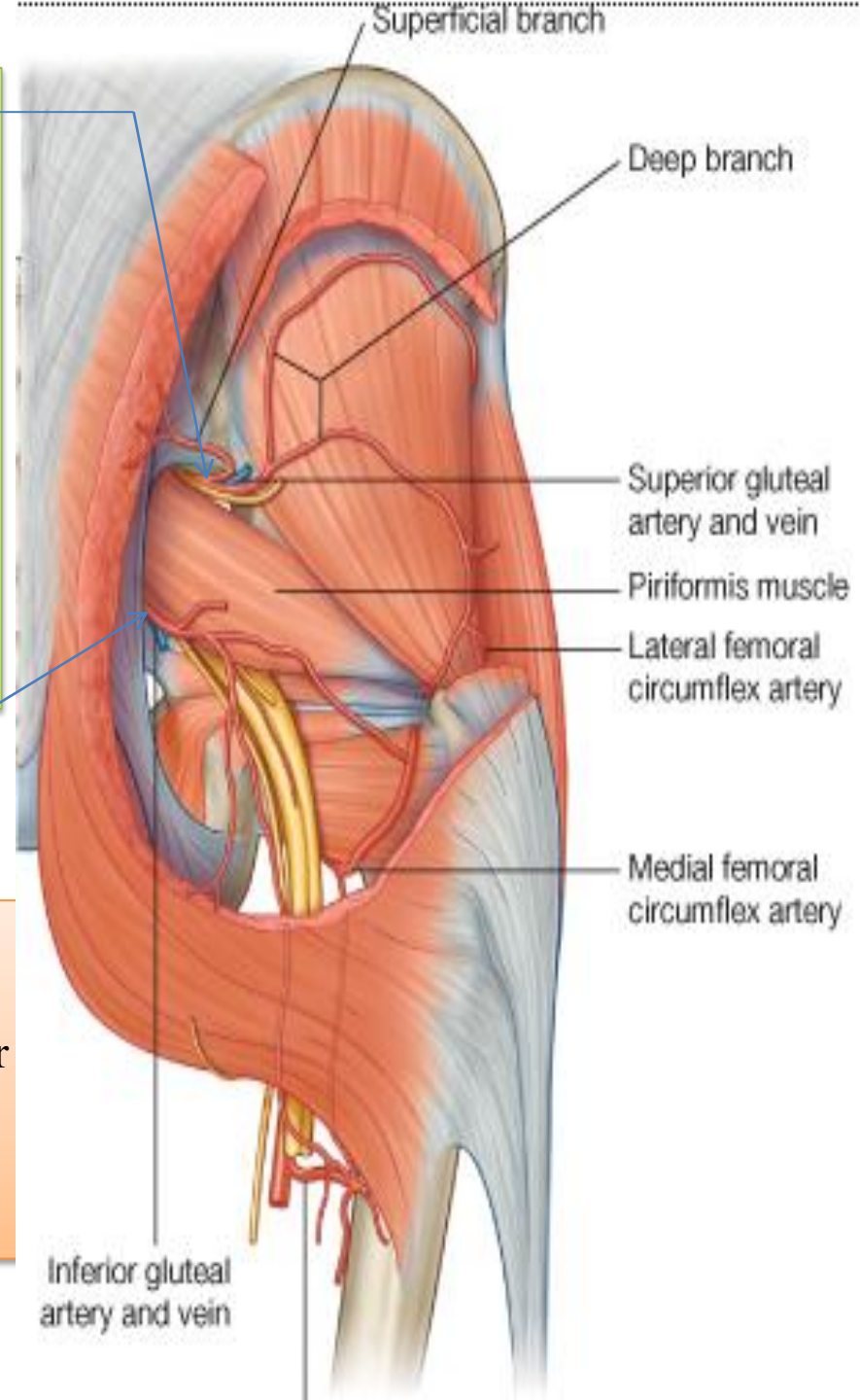
Arteries of the Gluteal Region

1-Superior Gluteal Artery

- is a branch from the internal iliac artery
- enters the gluteal region through the greater sciatic foramen **above the piriformis**
- It divides into superficial and deep branches.
- The **superficial branch** supplies **the gluteus maximus muscle**
- The deep branch supplies the glutei medius and minimus.

2-Inferior Gluteal Artery

- is a branch of the internal iliac artery
- enters the gluteal region through the greater sciatic foramen, **below the piriformis**
- It divides into numerous branches that are distributed throughout the gluteal region.



Branches from the internal iliac artery (superior and inferior gluteal arteries) anastomosis
With branches from the femoral artery to form

1-The Trochanteric Anastomosis

The trochanteric anastomosis :

provides the main blood supply to

THE HEAD OF THE FEMUR

The nutrient arteries pass along the femoral neck beneath the capsule

The following arteries take part in the anastomosis:

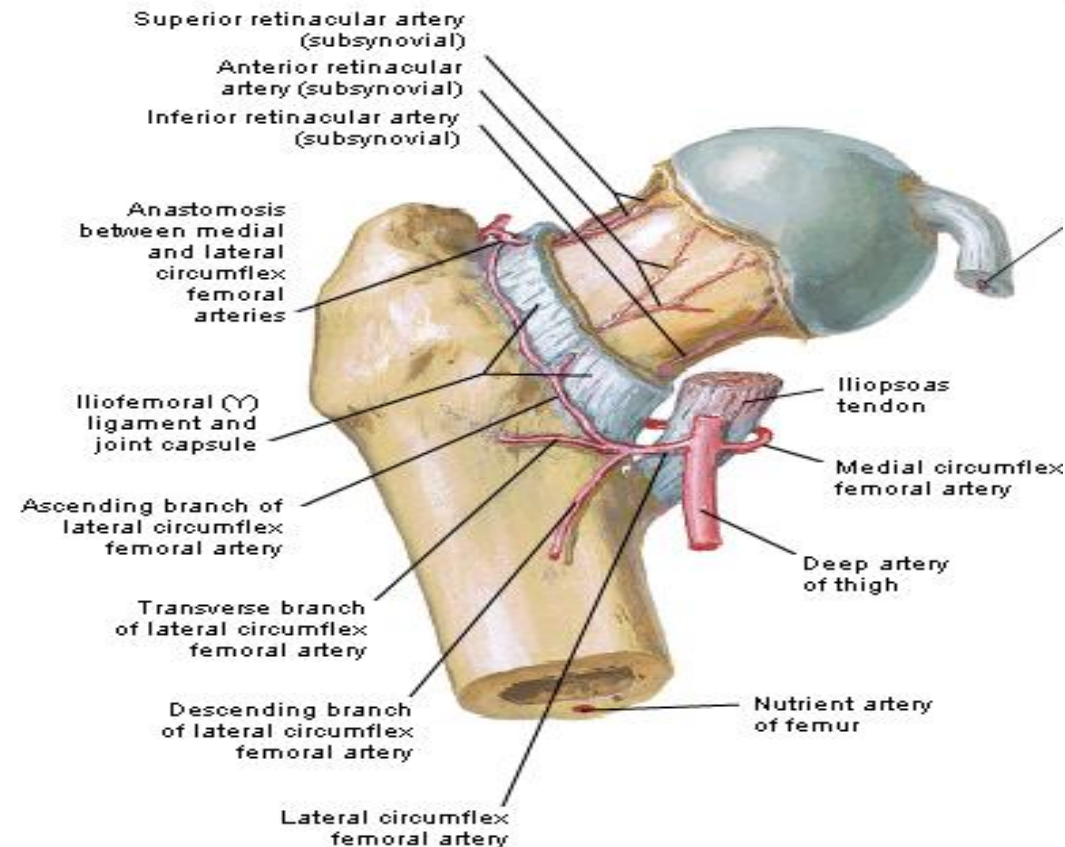
A) The superior gluteal artery, the inferior gluteal artery and the obturator artery (from the internal iliac artery)

B) The medial femoral circumflex artery, and the lateral femoral circumflex artery (from the femoral artery)

2-The Cruciate Anastomosis

The Cruciate Anastomosis

The cruciate anastomosis is situated at the level of the lesser trochanter of the femur and, together with the trochanteric anastomosis, provides a connection between the internal iliac and the femoral arteries



**The muscles of the gluteal region are acting on the hip joint
as different functional groups**

Gluteus maximus

Acts as the main extensor of the hip joint

Gluteus medius and minimus

**They act as the main abductors of the hip joint while
their anterior fibers act as medial rotators on the hip joint**

Short Lateral rotator muscles

They act as lateral rotators on the hip joint

**The muscles of the gluteal region, therefore, extend, abduct and rotate the hip joint
medially and laterally**

Leaving adduction and flexion to other groups of muscles, which ? Why?

Injury to the superior gluteal nerve

➤ On one side causes *Lurching gait*

➤ Both sides *Waddling gait*

The test indicates
'a defect in
the osseo-muscular
stability
of the hip joint'

Positive Trendelenburg's test

Note

Other conditions also may cause lurching and waddling gates such as:

Clinical Notes

Gluteus Medius and Minimus and Poliomyelitis

The gluteus medius and minimus muscles may be *paralyzed* when poliomyelitis involves the lower lumbar and sacral segments of the spinal cord.

They are supplied by **the superior gluteal nerve (L4 and 5 and S1)**

Paralysis of these muscles seriously interferes with the ability of the *patient to tilt the pelvis when walking.*

Trendelenburg's test

The stability of the hip in the standing position depends on two factors:

- 1- The strength of the surrounding muscles**
- 2-The integrity of the lever system of the femoral neck and head within the intact hip joint**

When standing on one leg, the abductors of the hip on this side (gluteus medius and minimus and tensor fasciae latae) maintain fixation at the hip joint. If, however, there is any defect in these muscles or lever mechanism of the hip joint, the weight of the body in these circumstances forces the pelvis to tilt downwards on the opposite side.

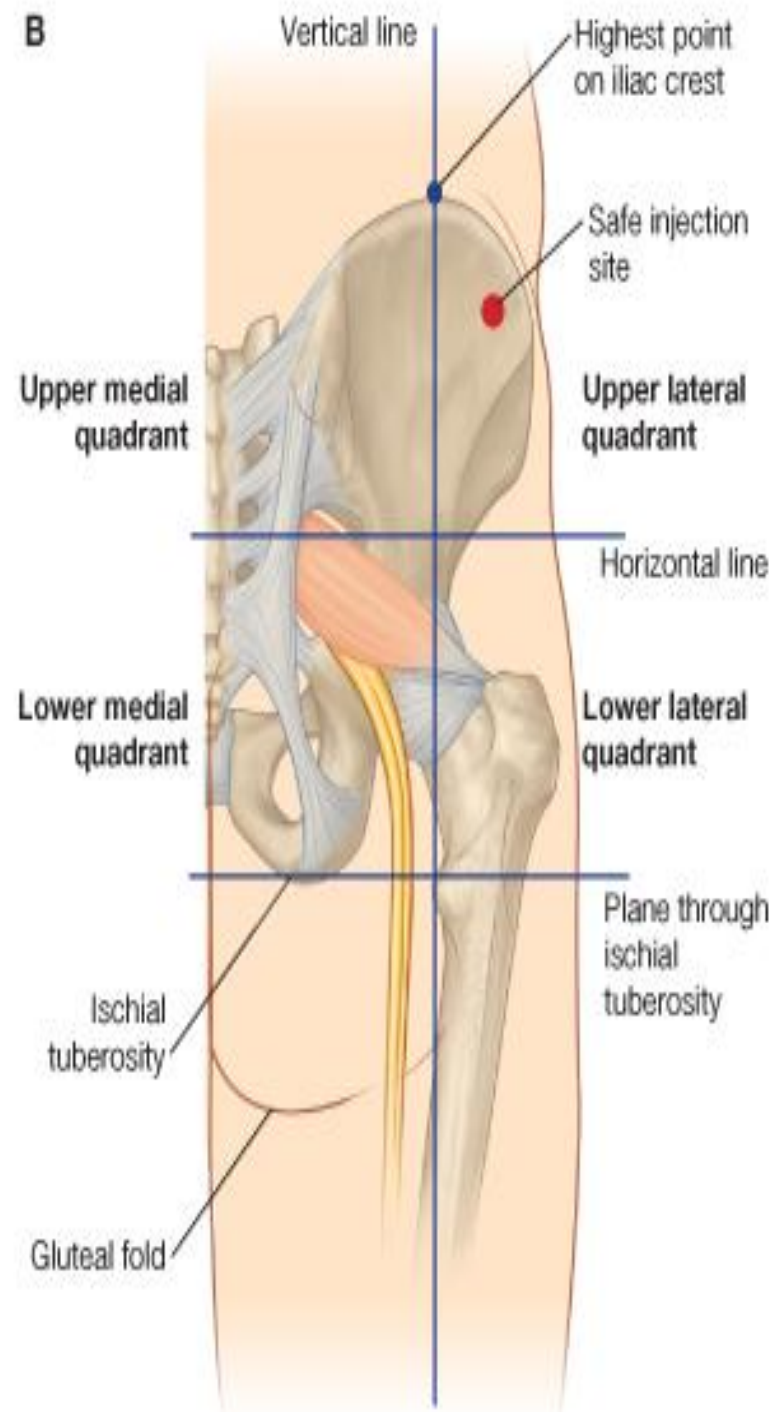
The positive Trendelenburg test is seen if:

- A- The hip abductors are paralysed (e.g. poliomyelitis)
- B-Congenital dislocation of the hip
- C-The head of the femur has been destroyed by disease or removed operatively (pseudarthrosis),
- D-There is an un-united fracture of the femoral neck
- E-There is a very severe degree of coxa vara

Clinical Notes

The great thickness of gluteus maximus muscle makes it ideal for intramuscular injections.

To avoid injury to the underlying sciatic nerve, the injection should be given well forward on the upper outer quadrant of the buttock.



However, the upper lateral quadrant, most likely to be made by the Gluteus medius muscle rather than the gluteus maximus muscle .

The gluteus maximus covers the posterior part only of the Gluteus medius while the anterior part (which makes the upper lateral quadrant)

is covered by skin and fascia only Therefore, the intramuscular injection will be injected into the gluteus medius muscle rather than gluteus maximus muscle

