Journal of Entomology and Zoology Studies

Available online at www.entomoljournal.com

E-ISSN: 2320-7078
P-ISSN: 2349-6800
JEZS 2018; 6(4): 728-733

Received: 22-05-2018
Accepted: 23-06-2018

Yogita Pandey
Assistant Professor & Scientist
Department of Veterinary, Anatomy and Histology, College of Veterinary Science and Animal Husbandry, Jabalpur, Madhya Pradesh, India

JS Taluja
Ret. Professor & head
Department of Veterinary, Anatomy and Histology, College of Veterinary Science and Animal Husbandry, Jabalpur, Madhya Pradesh, India

Rakhi Vaish
Associate Professor & Incharge
Department of Veterinary, Anatomy and Histology, College of Veterinary Science and Animal Husbandry, Jabalpur, Madhya Pradesh, India

A Pandey
Assistant Professor & Scientist
Department of Animal breeding and Genetics, College of Veterinary Science and Animal Husbandry, Jabalpur, Madhya Pradesh, India

Nidhi Gupta
Assistant Professor & Scientist
Department of Veterinary, Anatomy and Histology, College of Veterinary Science and Animal Husbandry, Jabalpur, Madhya Pradesh, India

D Kumar
Assistant Veterinary Surgeon,
Department of Veterinary, Anatomy and Histology, College of Veterinary Science and Animal Husbandry, Jabalpur, Madhya Pradesh, India

Correspondence
Yogita Pandey
Assistant Professor & Scientist
Department of Veterinary, Anatomy and Histology, College of Veterinary Science and Animal Husbandry, Jabalpur, Madhya Pradesh, India

Gross anatomical structure of the mammary gland in cow

Yogita Pandey, JS Taluja, Rakhi Vaish, A Pandey, Nidhi Gupta and D Kumar

Abstract
Mammary glands are the main site of milk synthesis and secretion and its ailments like mastitis is the common cause of decrease in milk production. The anatomical knowledge of mammary gland at different stages is desirable, to understand the background information in the physiology, pathology, surgery, medicine, livestock production and management and genetics. The mammary gland is a skin gland, and is therefore external to the body cavity. An average Holstein cow easily may have 50 kg (>100 lbs) of weight hanging from her body when she walks into the milking parlor to be milked. Hence a strong udder suspensory system is required to maintain proper attachments of the gland in the body. Milk is synthesized in the microscopic alveoli. As it accumulates in the alveolar lumen some milk oozes down into the smaller ducts and eventually into the large cisterns. This allows the cow to accumulate more milk in her udder between 2 milking or suckling by the calf.

Keywords: Mammary glands, milk, secretion, suspensory system

1. Introduction

Mammals appeared on earth about 150 million years ago and believed to have evolved from an advanced type of reptile. One of the most important characteristics common to all mammals is their ability to secrete milk. The mammary gland of the cow is the most advanced form from an evolutionary point of view. However, examples of a very primitive type of mammary glands also exist in nature. The pigeons produce a white slimy substance in their crop called pigeon milk, which they regurgitate in to mouth of their young one. The duckbill platypus possesses mammary glands similar to that of the cow morphologically but has no nipples. The milk exudes from 100-150 separate gland tubes that open at the base of the "mammary hairs" which the youngsters lap to obtain the milk, as mentioned by Banerjee in 1998 [3].



According to Sage 2002, mammary glands are the main site of milk synthesis and secretion and its ailments like mastitis is the common cause of decrease in milk production. The anatomical knowledge of mammary gland at different stages is desirable, to understand the background information in the physiology, pathology, surgery, medicine, livestock production and management and genetics. Since the mammary glands are very prone to traumatic injury, infection and other diseases, the basic anatomy play a crucial role in understanding to access the damage of tissue and approach in treating and restoring the normal condition of the udder

and teat. Hurley in 2010 [8] mentioned that the mammary gland of various species differs in number, location, size and shape but histology and cytology of secretory tissue appear similar.

1.1 Mammry Glands in Different Species

S. No.	Species	No.	Location of the gland
1	Cow and buffalo	4	Inguinal region
2	Sheep and goat	2	Inguinal region
3	Swine	8-18	Abdominal wall in form of 2 parallel gland areas
4	Bitch	10	4 pectoral, 4 abdominal and 2 inguinal region
5	Mare	2	Inguinal region
6	Elephant	2	Pectoral region

(Turner, 1952)

The mammary glands are specialized, compound, accessory glands. (Nalbandov, 1970; Bloom and Fawcett, 1975; Jacobson, 1996 and Ramkrishna and Gadre, 2004) [10, 17, 9, 14]. The growth rate of mammary gland increases following puberty, greatly accelerates during pregnancy, reaches its greatest development during lactation period and involutes after the lactation period is completed (Dellmann and Eurell, 2003) [4].

2. Gross Anatomy

2.1 Exterior of the Udder

Turner (1952) [21], Jacobson (1996) [9], Sisson (1975) [17] and Banerjee (1998) [3] have described the morphology of the mammary gland of cow and other animals of the class mammalian. They stated that the mammary glands of the cow are grouped together in a structure called the udder. The individual glands are arranged in two rows on either side of the median line of the body in the inguinal region. There are two normal functional glands (the quarters) each side.

There is no definite septum between the front and rear quarters as is found between the right and left halves of the udder. The right and left halves of the udder are separated by a longitudinal intermammary groove or sulcus intermammaricus. The skin covering the udder is usually of fine texture and covered with hair except on the teats.

2.2 Exterior of the Teat

The teat (papilla mammae) is cylindrical or conical in shape, elastic and is associated with each gland and serves as the exit for milk. Usually, only one teat drains one gland. Neither sebaceous nor sweat glands are found in the wall of teat (Hurley, 2010) [8]

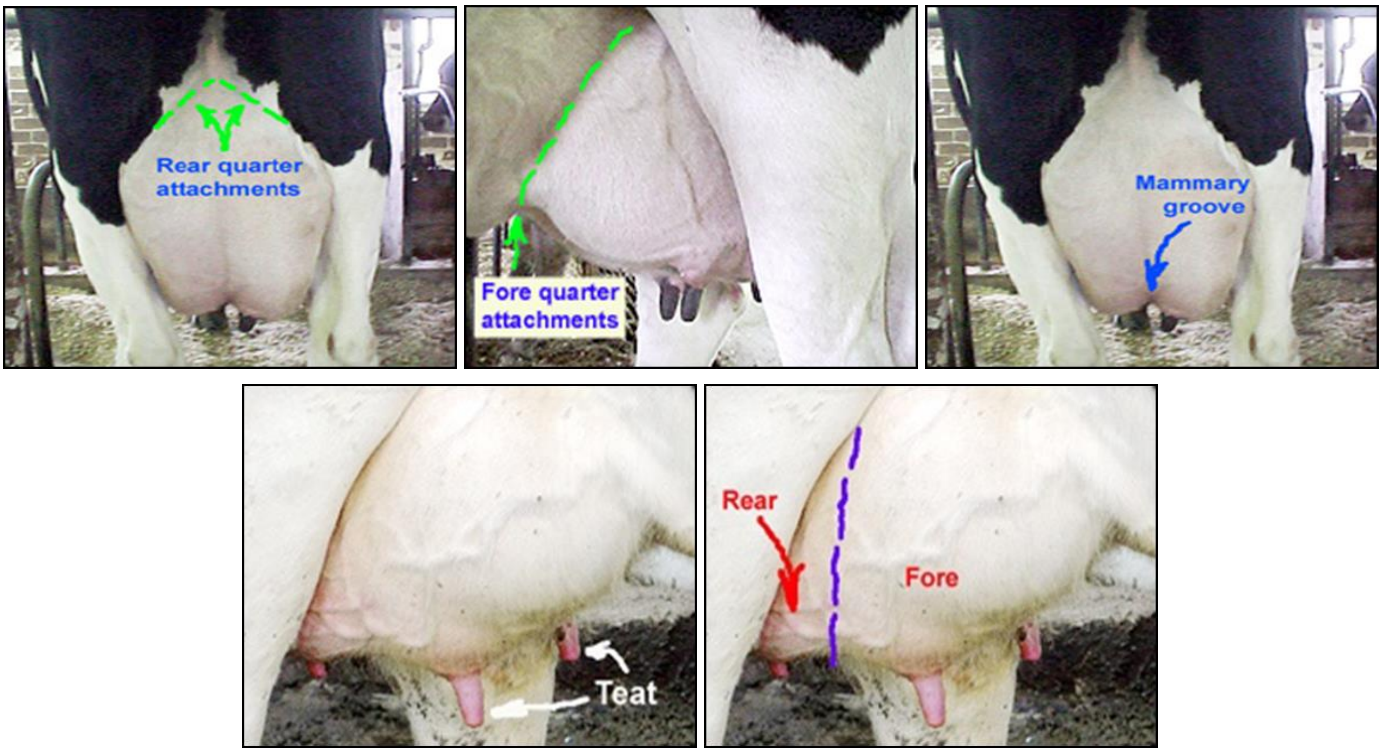

Teat size and shape are independent of the size, shape or milk production of the udder. The skin covering the teat is smooth when the udder is distended with milk, but becomes wrinkled after removal of the milk.

2.3 Supernumerary Teats

About 50% of all cows have extra teats, referred to as supernumerary teats. Some of these extra teats open into a "normal" gland, but many do not. Generally they are removed before 1 year of age. A pseudo-teat has no streak canal, and therefore, no connection to the internal structures of the gland. There may be from one to two supernumerary teats with or without functional glands.

2.4 Internal Structure of the Udder and Teat

To achieve the functional capacity of the cow's mammary gland, a number of supporting systems must exist.

2.4.1 Suspensory System

The mammary gland is a skin gland, and is therefore external to the body cavity. An average Holstein cow easily may have 50 kg (>100 lbs) of weight hanging from her body when she

walks into the milking parlor to be milked. Hence a strong udder suspensory system is required to maintain proper attachments of the gland to the body. The system of ligaments and other tissues which attach the udder to the cow are critical for successful lactation. The suspensory system comprised of:

2.4.1.1 Skin
Covering the gland is only of very minor support.

2.4.1.2 Superficial fascia or areolar subcutaneous tissue
This attaches the skin to the underlying tissue. It too is only of minor support for the cow's udder.

2.4.1.3 Coarse areolar or cordlike tissue
This tissue forms a loose bond between the dorsal surface of the front quarters and abdominal wall. Weakening of these causes the udder to break away from the abdominal wall. This is the part of the fore-quarter attachments when evaluating dairy cattle conformation. These tissues are important for keeping the fore quarter closely attached to the body wall, but are not the major support to the udder.

2.4.1.4 Subpelvic tendon
It is not actually part of the suspensory apparatus, but gives rise to the superficial and the deep lateral suspensory ligaments. It is not a continuous tissue sheet but is attached to the pelvis at several points.
It is not actually part of the suspensory apparatus, but gives rise to the superficial and the deep lateral suspensory ligaments. It is not a continuous tissue sheet but is attached to the pelvis at several points.

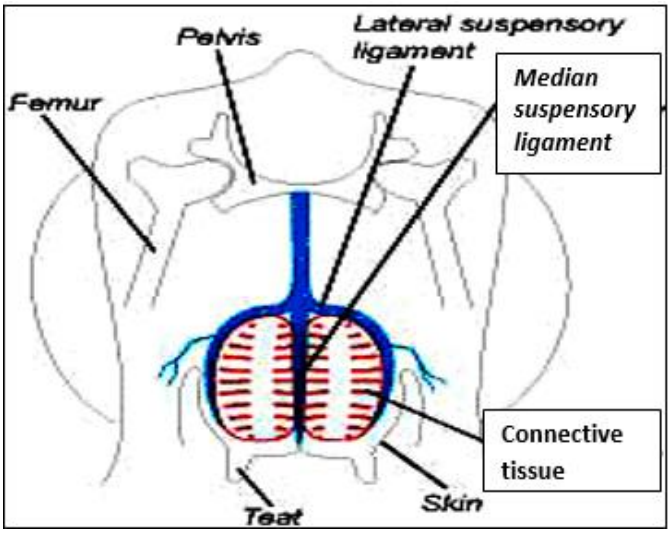

Suspensory structure of the udder

2.4.2 Superficial layers of lateral suspensory ligament
These are mostly composed of fibrous tissue (with some elastic tissue), arising from the subpelvic tendon. They extend downward and forward from the pubic area. When it reaches the udder it spreads out, continuing downward over the external udder surface beneath the skin and attaching to the areolar tissue.

2.4.3. Deep lateral suspensory ligament
The inner part of the lateral suspensory ligament also arises from the subpelvic tendon, but is thicker than the superficial layer, mostly fibrous tissue. It extends down over the udder and almost enveloping it. The ligament is attached to the convex lateral surfaces of the udder by numerous lamellae which pass into the gland and become continuous with the interstitial framework of the udder. Collectively, the lateral suspensory ligaments provide substantial support to the udder. The left and right lateral suspensory ligaments do not join under the bottom of the udder, and the fibrous nature of these ligaments means that they do not stretch as the gland fills with milk. So, the center of the udder tends to pull away from the body as the gland fills.

2.4.4 Median Suspensory Ligament
This is the most important part of the suspensory system in cattle. It is composed of two adjacent heavy yellow elastic sheets of tissue that arise from the abdominal wall and that attach to the medial flat surfaces of the two udder halves. The median suspensory ligament has great tensile strength. It is able to stretch somewhat as the gland fills with milk to allow for the increased weight of the gland. It is located at the center of gravity of the udder to give balanced suspension, so that even if rests of the layers are cut away except for the median suspensory ligament, the gland stays balanced under the animal. This ligament partially separates the left and right halves of the udder. Front and rear quarters are separated by a thin membrane and are not recognizable to the eye. There is no internal crossover of the milk duct system of the quarters (glands). One way to demonstrate this is to infuse a dye into the teat and duct system of one quarter of an udder from a cow that has been culled from the herd and killed. Then when the udder is cut open, the dye will be seen only in the infused quarter and will not be seen in the other quarters (Hurley, 2010) [8].

2.4.5 Gland and Teat cistern
A cistern is a large cavity where milk can be stored. Milk is synthesized in the microscopic alveoli. As it accumulates in the alveolar lumen some milk oozes down into the smaller ducts and eventually into the large cisterns. This allows the cow to accumulate more milk in her udder between 2 milking or suckling by the calf.

2.4.6 Gland Cistern (sinus lactiferous or udder cistern)
It opens directly into the teat cistern. Occasionally a septum forms between teat and gland cisterns and the quarter may be blind. This can be corrected surgically. The cisterns function for milk storage (holds ~100-400 ml). The gland cistern varies greatly in size and shape. There are often pockets formed in the cistern at the end of the larger ducts.

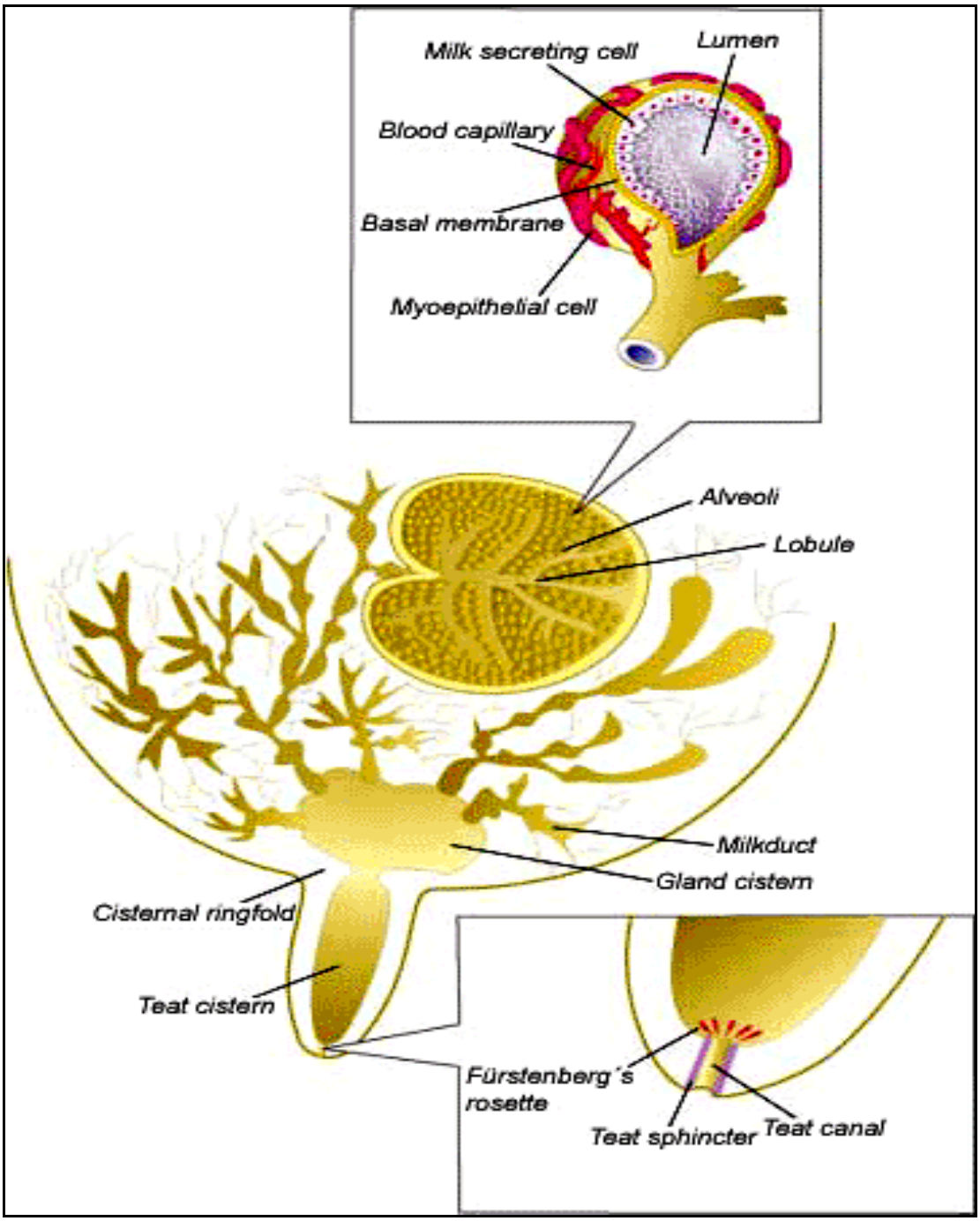

Schematic picture of anatomy of the udder

2.4.7 Teat cistern (Sinus papillaris)

The sinus papillaris is a cavity within the teat. It is continuous with the gland cistern. The teat cistern is lined with numerous longitudinal and circular folds in the mucosa, which form pockets on the inner lining of the teat. During milk letdown, the teat cistern fills with milk. It is this milk, and some of the milk in the gland cistern just above the teat cistern, that is removed with each suckling action of the calf. The region at the proximal end of the teat cistern that marks the boundary between the teat cistern and the gland cistern is called cricoid rings or annular folds. These are not always recognizable in the dissected gland (Hurley, 2010) [8].

2.4.8 Streak canal (Ductus papillaris)

It is the only orifice of the gland between internal milk secretory system and the external environment. The streak canal is the main barrier against intramammary infection. The streak canal is kept closed by sphincter muscles around the streak canal. Canal patency decreases and streak canal length increases with increasing lactation number. Furstenberg's rosettes are mucosal folds of the streak canal lining at the internal end of the canal. It may fold over the canal opening due to pressure when the udder is full. It may be a major point of entry for leukocytes leaving the teat lining and entering into the teat cistern. Furstenberg's rosette is involved in the local defense against mastitis. The teat canal is surrounded by bundles of longitudinal as well as circular smooth muscle fibers. Between milking the smooth muscles function to keep the teat canal closed. The teat canal is also provided with keratin or keratin like substances which acts as a barrier for the pathogenic bacteria (Riservati, 2009) [16]. When a cow is milked, the sphincter muscles relax allowing the orifice to open. The streak canal remains open for an hour or more after milking. This provides ready access of bacteria to the inside of the gland. Keeping cows standing for a time after milking, such as providing access to fresh feed, also helps to minimize

teat end contamination before the streak canal closes again. During dry period (non-lactating period), the keratin plug effectively seal off the canal.

3. Blood vascular system

The blood supply to the mammary gland is extremely important for mammary function. All of the milk precursors come from the blood. On avg. 400 - 500 units of blood passes through the udder for each unit of milk synthesized by a high producing dairy cow; that is ~280 ml per sec. Total udder blood volume for lactating cows about 8% of the total body blood volume, while for a non-lactating cow it is about 7.4%. There is a 2-6 fold increase in blood flow in the mammary gland starting 2-3 days prepartum. Decrease in production with advancing lactation is not due to decreased blood flow; rather it is due to the loss of secretory epithelial cells through a process programmed cell death (apoptosis) (Hurley, 2010) [8].

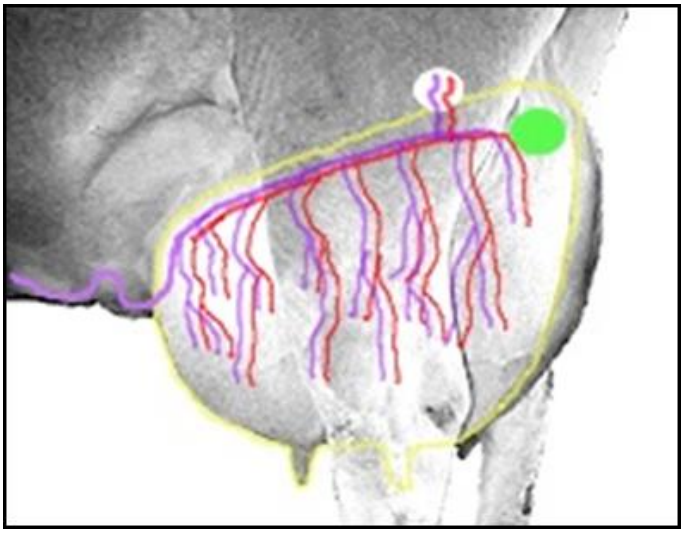

Location of arteries (red), veins (purple) and supramammary lymph nodes.

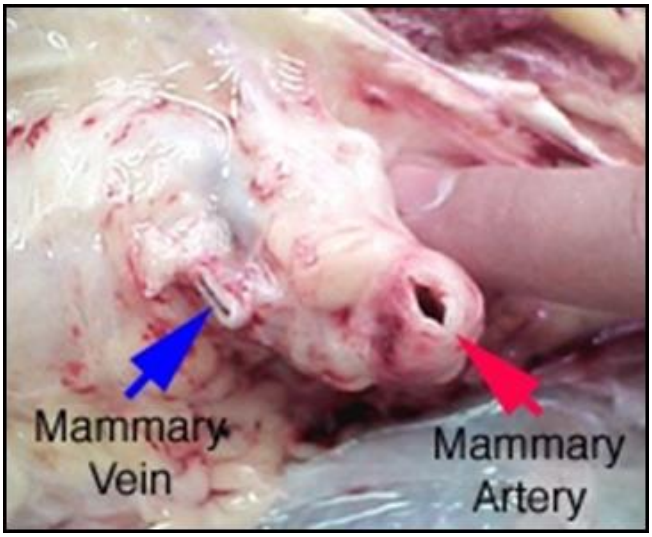

Mammary vein and mammary artery on the carcass of a cow.

Arterial supply to the Udder

To produce 1L of milk 500L of blood have to pass through the udder. When the cow is producing 60L of milk per day, 30,000L of blood are circulating through the mammary gland. Thus, the high producing dairy cow of today is exposed to very extreme demands (Riservati, 2009) [16].

Femoral artery which originated from external iliac artery gives rise to the external pudendal artery, which continues as mammary artery. This mammary artery divided into anterior, middle and posterior artery to supply the udder.

3.1.1 Perineal artery

A small amount of blood also reaches the mammary gland by the perineal artery (from the internal iliac), but this only supplies the upper rear portion of the gland.

Just below the inquinal canal, the pudic artery forms an S-shaped flexure, the Sigmoid flexure. This allows for downward distention of the udder as it fills with milk, without stressing the blood vessels. (In general there is no crossover of blood supply between udders (Hurley, 2010) [8].

3.2 Venous drainage from the Udder

The vein is 2-3 times as large as the artery. Veins leave the mammary gland anti-parallel to the arteries. There are three veins on each side that carry blood away from the gland:

External pudic vein (middle mammary vein) leaves the udder parallel to the external pudic artery (2-3 cm diameter).It ascends in the inguinal canal as satellite of artery and joins the external iliac vein. The external pudic vein is a satellite of the external pudic artery and follows a course similar to that of the artery except that the blood is flowing in the reverse direction.

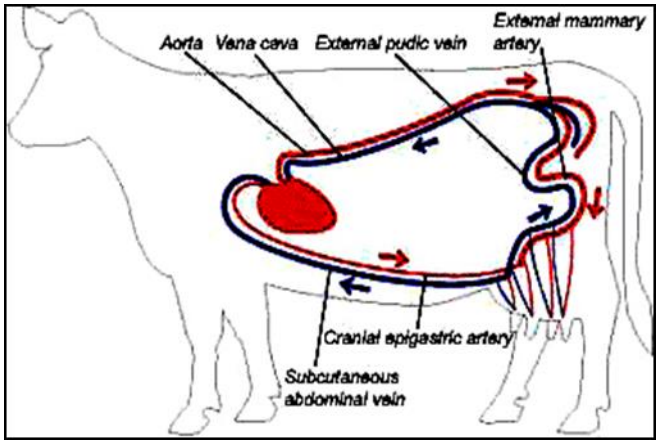

Schematic picture of vascular system of the udder, illustrating arteries supplying the udder with blood versus veins draining blood from the udder. (Riservati. 2009) [16]

3.2.1 Subcutaneous abdominal vein (milk vein/ anterior mammary): vein exits the gland at the anterior end of the front quarters and passes along the abdominal wall. This is the large vein that is visible under the skin on the belly of the cow. It enters the body cavity at the xiphoid process via "milk wells", and empties into internal thoracic vein.

Perineal vein (posterior mammary vein) leaves the rear of the gland parallel to the perineal artery, it runs upward and backward to the perinium turns around the ischial arch, and joins the internal pudic vein. Venous circle formed by anastomoses between anterior and posterior mammary veins, prevents pinching off of areas of venous outflow when the cow is lying down.

3.3 Lymphatic System of the Udder

The lymph channels of the Udder are as extensive as venous blood vessels and are parallel to them. The Supra Mammary lymph gland of the udder varying in number from 1-7 and in size 4-10 cm. are located above the caudal border of the base of the mammary gland. Most of the afferent lymph ducts of

the udder empty into the supra mammary lymph gland (Riservati, 2009) [16].

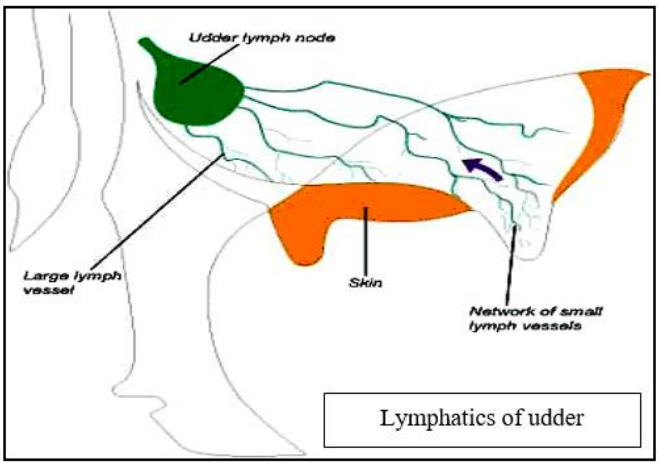

4. Nerve Supply of the Udder

Several aspects of the neural system of the mammary gland are important to mammary function. Innervation inside the udder is sparse compared with other tissues. Sensory nerves are found in the teats and skin. These are critical for initiating the afferent pathway (neural pathway) of the milk ejection reflex. The nerve supply to the udder consists of afferent or sensory fibers and efferent or sympathetic fibers. The afferent nerves originate from three different sources.

- 1st lumbar and 2nd lumbar
- 2nd lumbar, 3rd lumbar and 4th lumbar nerves grouped together as inguinal nerve.
- Perineal nerve is a branch of pudic nerve and is made up fibres from the 2nd, 3rd and 4th sacral spinal nerves.

The udder is also provided with nerves connected to the smooth muscles in the circulatory system and the smooth muscles in the milk ducts. However, there are no innervations directly controlling the milk producing tissue (Riservati, 2009) [16]. The motor supply to the udder is entirely autonomic or sympathetic. The neurons of the nerve fibres are located in the lateral horns of the spinal cord. The tissues of the udder are controlled by this dual mechanism. However, parasympathetic fibres have not been found in the sweat glands of the skin and similar cutaneous structures. Since the mammary gland develops as a cutaneous gland parasympathetic fibres have not been demonstrated in the udder.

5. Acknowledgement

Authors are greatly thankful to the department of Veterinary Anatomy, College of Veterinary Science and Animal Husbandry and University library of N.D.V.S.U., Jabalpur for providing necessary help in making this article.

6. References

1. Anderson RR, Harness JR, Snead AF, Salah MS. Mammary growth pattern in goats during pregnancy and lactation. J Dairy Sci. 1981; 64:427-432.
2. Arey LB. Developmental Anatomy. A Textbook of Embryology. W.B. Saunders Co., Philadelphia. 1965, 449-453.
3. Banerjee GC. Textbook of Animal Husbandry. 8th edn., IBH Publishing Co. Pvt. Ltd. New Delhi, 1998, 340-380.
4. Dellmann HD, Eurell J. Text Book of Veterinary Histology. Publ., Lippincott Williams and Wilkins, Philadelphia. 2003, 323-325.
5. Eckles CH, Anthony LE. Dairy Cattle and Milk Production 3rd Indian impression, Biotech book, Dehli. 2008, 27-43.
6. Ham AW. Histology. 6th edn., J.B. Lippincott Company, Philadelphia. 1969, 838-846.
7. Hovey RC, Trott JF, Vonderhaar BK. Establishing a framework for the functional mammary gland: from endocrinology to morphology. J. of Mammary Gland Biol. Neoplasia. 2002; 7:17-38.
8. Hurley WL. Lactation biology by University of Illinois, Urbana-Champaign. 2010, 213.
9. Jacobson NL. The Mammary Gland and Lactation. Dukes Physiology of Domestic Animals. 'Edited by Swenson, M.J. 11th edn., panima and William O.R. Publishing Corporation, New Dehli and Bangalore, 1996, 711-726.
10. Nalbandov AV. Reproductive Physiology. 2nd edn. D.B. Taraporevala Sons & Co., Bombay. 1970, 311-313.
11. Neville MC, McFadden TB, Forsyth I. Hormonal regulation of mammary differentiation and milk secretion. J Mammary Gland Biol. Neoplasia. 2002; **7**:49-66.
12. Panchal KM, Vyas YL. Anatomy of Udder of Buffalo: A complete monologue, Anand Agriculture University Gujrat. 2005, 313-319.
13. Pitelka DR, Hamamoto ST. Form and Function of Mammary Epithelium: The interpretation of ultrastructure. J Dairy Sci. 1997; 60(4):643-654.
14. Ramkrishna V, Gadre KM. Systemic Histology of Domestic Animals 2nd edn., Jaypee brothers Medical Publishers (P) Ltd. New Delhi, 2004, 55-57.
15. Reid IM, Chandler RL. Ultrastructural studies on bovine mammary gland with particular reference to glycogen distribution. Res. Vet. Sci. 1973; 14(3):334-340.
16. Riservati DT. The Mammary Gland. Dairy Knowledge. 2009; 6:22-24.
17. Sisson S. The Mammary gland. In Anatomy of the Domestic Animals. Edited by Getty, R. 5th edn., W.B. Saunders Company, Philadelphia. 1975, 950-953.
18. Thomas FF, Alvin FW. Mammary gland: Veterinary Developmental Anatomy. 2010, 42.
19. Tong QS, Zheng Li-Duan, Lu Peng, Jiang F chao, Chen Fang-Min, Zeng Fu-Qing *et al*. Apoptosis-inducing effects of curcumin derivatives in human bladder cancer cells. Anti-Cancer Drugs. 2006; 17(3):279-287.
20. Tucker HA. Hormones, mammary growth and lactation: a 41-year perspective. J. Dairy Sci. 2000; 83:874-884
21. Turner CW. The Mammary Gland. 1st edn., Lucas Brothers, Publishers, Missouri, Columbia. 1952, 383.