



FLORIDA  
INTERNATIONAL  
UNIVERSITY

# Hamsters



**Horatiu V. Vinerean DVM, DACLAM**  
**Director, Laboratory Animal Research**  
**Attending Veterinarian**

# Taxonomy

Order: Rodentia

- Suborder: Myomorpha

- Family: Cricetidae

- Sub-Family: Cricetinae

- Genus species:

- *Mesocricetus auratus*: Syrian (golden) hamster


- *Cricetulus griseus*: Chinese (striped-back) hamster

- *Cricetulus migratorius*: Armenian (gray) hamster

- *Cricetus cricetus*: European hamster

- *Phodopus campbelli*: Djungarian (Russian dwarf) hamster

- *Phodopus sungorus*: Djungarian (Siberian dwarf) hamster



Chinese

Armenian

Syrian



European



Djungarian

# Family Cricetidae

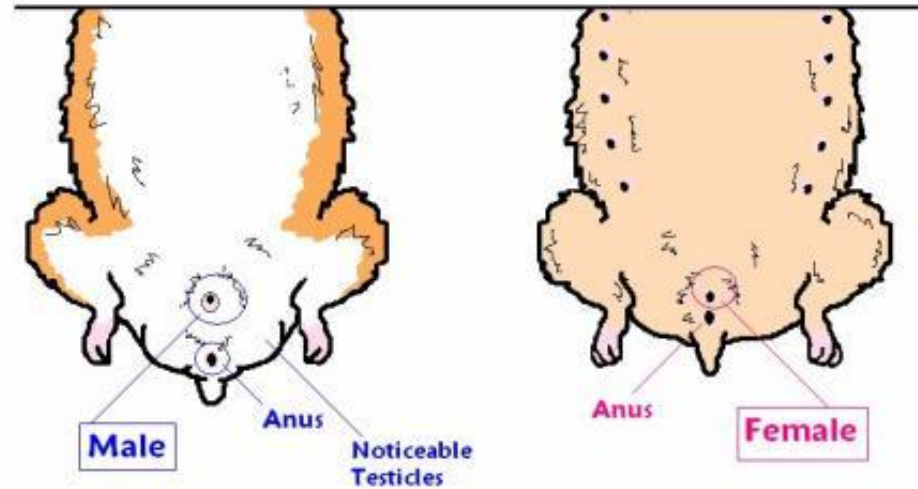
- Characterized by:
  - Large cheek pouches
  - Thick bodies
  - Short tails
  - Excess of loose skin
  - Continuously growing incisors
  - Cuspidate molars that do not continue to grow
- Fifth most commonly used lab animal in US behind mice, rats, rabbits and guinea pigs

# Description

- The Syrian hamster is native to southeast Europe and Asia Minor (northwest Syria).
- In 1930, a female and her 11 pups with eyes still closed were obtained near Aleppo, Syria and brought to the Hebrew University, Jerusalem, and, from the surviving four littermates, the entire domesticated world population of hamsters was developed.
- Syrian hamsters were brought to the United States in 1938.

# Description

## Syrian Sexing



- Syrian (*M. auratus*)
  - Nocturnal (or crepuscular)
  - Female larger than male and matures earlier
  - Reddish gold color with grayish white ventrum
    - Other coat colors include cream, albino, piebald, and cinnamon
  - Males have prominent flank glands and large, protruding testicles, resulting in a pointed and protuberant posterior
  - Diploid chromosome number = 44
  - Digits: 4 front and 5 rear

# Description

- In the wild, hamsters are nocturnal animals that live on brushy slopes and steppes.
- They generally live alone in deep tunnels (burrows) that insure a cooler temperature and higher humidity than that of a desert environment.



# Description

- Chinese (*C. griseus*)
  - Chromosome number = 22
- Armenian (*C. migratorius*)
  - Chromosome number = 22
- European (*C. cricetus*)
  - Chromosome number = 22
  - Nocturnal, Hibernate, Large size (3X larger than Syrian)
  - Very aggressive
- Djungarian (*P. campbelli* and *P. sungorus*)
  - Chromosome number = 28
  - Small, Dorsal fur gray with dark stripe dorsally along length of body
  - Feet and tail covered with fur (opposed to others that are hairless)



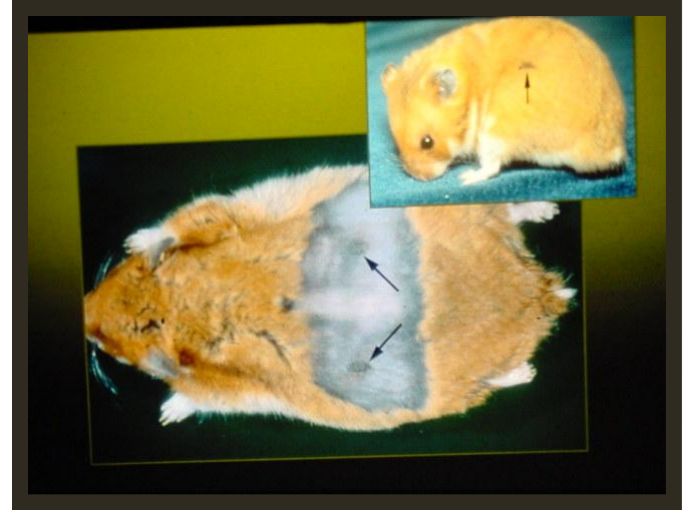# Description

- Dentition: typical rodent pattern:  $2 \times [I - 1/1, C - 0/0, P - 0/0, M - 3/3] = 16$ .
- The incisors are open-rooted, are erupted at birth, grow throughout life and there is no nerve in the incisor teeth except at the base.
- Molars are also erupted at birth. They are cuspidate and do not continue to grow.
- Dental caries are easily induced by altering the diet. Males are more susceptible than females to caries, molar crowns retain food and promote caries.

# Anatomical and physiological features

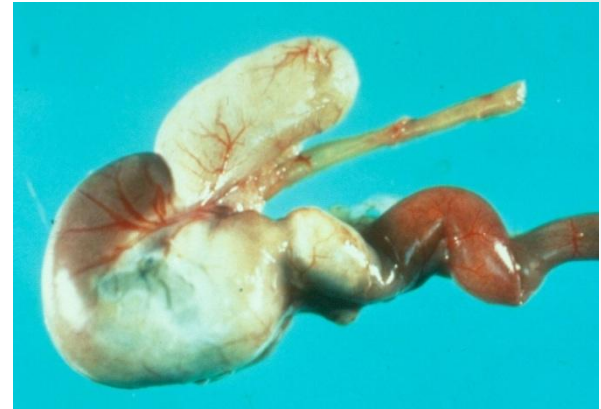- Hibernation
  - Exposure to cold stimulates food gathering
  - Often hibernate at 5°C
  - Do not fatten prior to hibernation, must awaken periodically to eat
- Radioresistance
  - Syrian and Chinese strains are most radioresistant mammals studied

# Anatomical and physiological features



- Flank Glands
  - Dermal structures covered by coarse hair over darkly pigmented skin in the hip area in males
  - Produce secretions in response to androgen production used for territorial marking
  - Female also has flank glands – not easily identifiable
- When the hamster is excited, the hair over these glands will become wet, and the animal will scratch and rub itself.

# Anatomical and physiological features



- GI system
  - Different from other rodents – esophagus enters between a forestomach and a glandular stomach compartment
  - Nonglandular forestomach similar to ruminants – elevated pH and microorganisms that ferment. However not critical to survival or well being of animal.
  - As a desert adaptation, the colon is relatively longer than other rodents to help increase water resorption. Hamsters are coprophagic.

# Anatomical and physiological features

- Cheek pouch – immunologically privileged: used for microvascular studies, tumor growth.
- Development of thymic system and cellular immunity is delayed related to short gestation period
- Only 4 of 5 immunoglobulin classes in hamster (IgM, IgG, IgA and IgE)



# Biology – Mating and Reproduction

- **Syrian**

- Recommend breeding withheld until hamsters reach 90-100 grams
- 4 day estrous cycle
- End of ovulation marked by copious postovulatory discharge
- Female successfully mated the evening of the third day after postovulatory discharge observed
- Gestation 15-18 days (16<sup>th</sup> day most common)
- Weaning at 21-28 days
- Estrous cycle resumes 1-8 days following parturition

# Biology – Mating and Reproduction

- Altricial (hairless) young, eyes & ears closed
- Born with incisors
- Ears open at 4 - 5 days, Hair at 9 days
- Eat solid food at 7 - 10 days
- Vagina open at 10 days
- Eyes open at 15 days
- Weaning at 21-28 days
- Only females have nipples
- Sexual maturity occurs in the male when it reaches about 90 to 100 gm in weight (approximately 12 weeks).
- Normal urine output is slight
  - Consistently use one corner of cage for elimination



# Biology – Mating and Reproduction

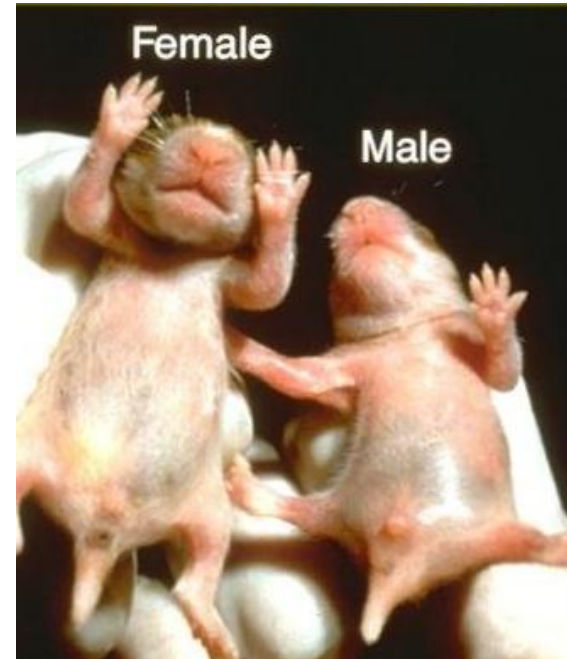- Females that are stressed or disturbed during the first week post-partum tend to cannibalize their young. She may stuff young into the cheek pouches along with food. The young may suffocate.



# Biology – Mating and Reproduction

## Sexing

- Anogenital distance
- Presence of mammae
- Posterior scrotum



# Biology - Nutrition

- Feeding - In nature, Syrian hamsters are granivorous, but also eat green plants, roots, insects and fruit.
- Fed commercial rodent chow +/- alfalfa cubes
- Due to forestomach, have different nutritional requirements than other rodents
- Hamsters show no circadian rhythm in their feeding habits. They exhibit a 5 minute feeding period followed by a 2 hour fast.
- Hamsters normally will hoard feed in a cage corner.

# Biology - Nutrition

- Due to broad muzzle, animals unable to eat through hoppers – placement of food on the floor is acceptable and preferred
- Water bottle sipper tube should be low as nursing pups need fluids in addition to milk from dam to prevent GI disturbances



# Management and Husbandry

- **All – Caging and Environment**
  - Usually housed individually due to aggressive nature
  - Cedar and pine shaving should be avoided due to aromatic hydrocarbons in these materials that may induce hepatic enzymes
  - Temp: 68 – 79 °F (20-26 °C)
  - Humidity: 30-70%

# Management and Husbandry

## Space requirements of both the Guide and the AWR

<b>Weight</b>	<b>Floor area/animal</b>	<b>height</b>
<b>g</b>	<b>sq. in.</b>	<b>in</b>
<b>&lt;60</b>	<b>10</b>	<b>6</b>
<b>up to 80</b>	<b>13</b>	<b>6</b>
<b>up to 100</b>	<b>16</b>	<b>6</b>
<b>&gt;100</b>	<b>&gt;19</b>	<b>6</b>

AWR also state:

“A nursing female hamster, together with her litter, shall be housed in a primary enclosure that contains no other hamsters and that provides at least 121 square inches of floor space: Provided, however, that in the case of nursing female dwarf hamsters such floor space shall be at least 25 square inches.”

# Management and Husbandry

## Handling and Restraint

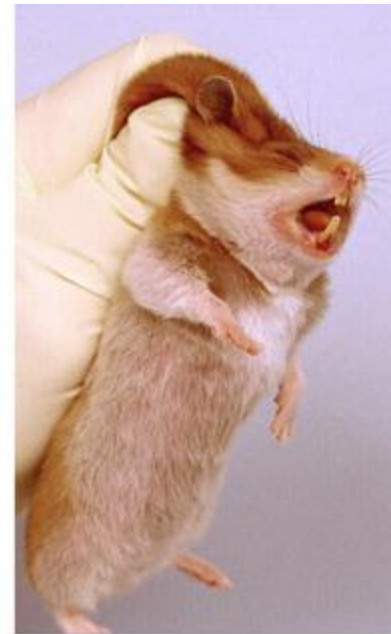- Males are more docile and easier to handle
- A startled or awakened hamster is likely to bite
- A hamster can be handled by cupping the hands gently under it or by picking it up in a small can.



# Management and Husbandry

## Handling and Restraint

- Another effective method is to place the animal on a flat surface. Then place your hand over the hamster with the thumb near the head. Next, slowly close the hand grabbing the loose skin. Grasp only the skin. This should immobilize the hamster sufficiently to allow injections to be given.



# Biology - Pharmacology

- All
  - More sensitive to metabolic effects of corticosteroids
  - Adrenal glands produce cortisol rather than corticosterone
  - Less responsive to histamines
  - Very resistant to morphine
    - No sedative or hypnotic effects

# Diseases – Bacterial & Viral

- Wet Tail – associated with *Lawsonia intracellularis* infection
- Tyzzer's Dz – Proliferative enteritis, *Clostridium piliforme*: weanlings
- *Clostridium difficile* – associated with inappropriate antibiotic use (OK to give tetracycline, metronidazole)
- Pneumonia: *Pasteurella pneumotropica*, Strep pneumonia, *Corynebacterium paulometabulum*, “chatter”
- Lymphocytic Choriomeningitis Virus (LCMV): wasting disease or subclinical infection, associated Glomerulonephropathy and vasculitis, ZOO NOTIC, ABSL-3 in hamsters
- Hamster Polyomavirus – spontaneous skin tumors virus shed in Epithelial cells, 4-8wks from infection to tumor development
- Parvovirus – disease in suckling and weanling hamsters

# Diseases - Parasitic

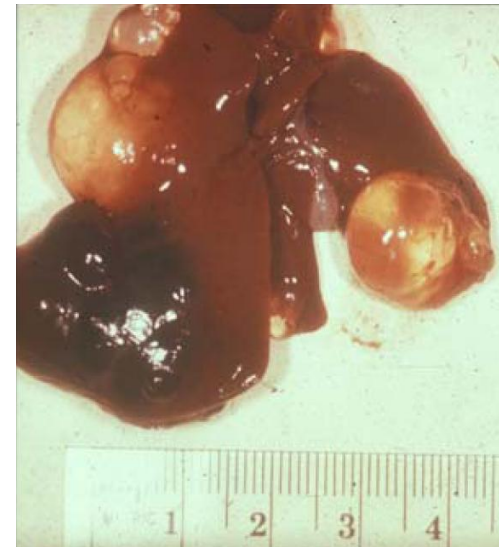- Protozoa
  - *Spiroplasma muris*, *Giardia* sp., *Tritrichomonas* sp., and *Entamoeba* sp. commonly inhabit the small and large intestine without causing clinical signs
    - Can cause secondary infection
- Nematodes
  - *Syphacia mesocricetus*,
- Cestodes
  - *Rodentolepis nana* - Zoonotic potential due to direct life cycle
- Ectoparasites
  - *Demodex criceti* (in epidermal pits)
  - *Demodex aurati* (in hair follicle)
  - Notoedres: Females – ears, Males – nose, genitalia, tail

# Disease - Neoplastic

- Benign neoplasms
  - Most common are intestinal polyps and adrenal cortical adenomas
- Malignant neoplasms
  - Most common are lymphomas and leukemias
    - Lymphomas have been linked to HaPV
  - Melanomas seen more in males than females (10:1)

# Disease - Miscellaneous

- **Polycystic disease**
  - Observed in 76% of hamsters >1yr of age
  - Liver is common site, also epididymis, pancreas, ovary, cecum, and others
  - Polycystic liver disease is believed to be congenital in origin. The cysts are considered an incidental finding in older hamsters.



# Research Use - General

- Specific uses in research have involved the:
  - cheek pouch,
  - immunologic tolerance,
  - radioresistance,
  - dental caries,
  - scent glands,
  - respiratory tract morphology similar to man,
  - unusual GI tract (fermentation),
  - Addison's disease,
  - renal and bladder cancer,
  - antibiotic sensitivity, and
  - susceptibility to tumor induction by viruses



# Research Use - Infectious Diseases

- **Syphilis** - They develop skin lesions after intradermal injection with either *Treponema pallidum* bosnia A (endemic syphilis) or *T. pallidum* pertenue (yaws). Only primary and secondary syphilitic infections occur (no tertiary disease develops).
- **Mycobacteria** - Hamsters are sensitive to human BCG vaccine and are used to test various strains of BCG vaccine.
- **Leprosy** - Hamsters were the first lab animal used to study lepromatous leprosy but armadillos (*Dasypus novemcinctus*), and sooty mangabeys (*Cercocebus torquatus atys*), etc., are used now.
- **Mycoplasma pneumoniae** - Hamster organs can support growth of *M. pneumoniae*.
- Other bacterial diseases that have been studied in hamsters include clostridial diseases, leptospirosis, and legionellosis.

# Research Use – Viral Diseases

- **VEE** - different serovars for blood clearance rate and lethality
- **St. Louis Encephalitis** - extraneural defects are possible
- **Pichinde** - strain variation in susceptibility
- **Yellow Fever, Vesicular Stomatitis, Newcastle** - asymptomatic infections
- **Vaccinia** - genetic restriction of cell-mediated cytotoxicity
- **Herpes** - lethal in adult hamsters which are used to study the effectiveness of Acyclovir
- **Machupo** and **Junin** - infant hamsters are the most sensitive laboratory animal for isolating agents of Bolivian and Argentine hemorrhagic fevers.

# Research Use – Protozoal Diseases

- **Toxoplasmosis** - Generalized infection, subclinical to fatal and acute to chronic.
- **Babesiosis** - clinical signs and pathologic changes similar to those in people after infection with *B. microti*.
- **Leishmaniasis** - first experimental infection studied in hamsters.
- **Malaria** - can be studied in the cheek pouch subsequent to intraperitoneal injection of parasitized red blood cells.

# Manipulations

## **Injections (consider doing under isoflurane anesthesia)**

- IM – 0.1 ml (quadriceps, caudal thigh or epaxial muscles)
- IV – 0.2 ml (saphenous, cephalic, jugular, lateral tarsal, penile or lingual vein)
- SC – 1.0 ml (intrascapular or inguinal areas)
- IP – 4.0 – 5.0 ml (same as for other rodents)

## **Fluid Administration**

- Intraosseous Fluid Administration

# Manipulations

## **Blood Collection (consider doing under isoflurane anesthesia)**

- Lateral tail artery
- Tip of tail
- Cranial vena cava
- Cephalic vein
- Lateral tarsal vein
- Toenail or tail clip
- Cardiac puncture (anesthetize; terminal)

# Anesthesia

- Premed with Atropine at 0.1-3 mg/kg S.C.
- Ketamine (80 - 200 mg/kg) + xylazine (10 - 16 mg/kg)
  - Only I.P. produces satisfactory muscle relaxation and analgesia for abdominal surgical anesthesia. Similar results have been shown with telazol/xylazine combinations delivered IM.
- Sodium pentobarbital given I.P. at a dose of 60 to 100 mg/kg has been suggested for surgical anesthesia lasting 30 to 45 minutes.
- Inhalant anesthesia (isoflurane) via nose cone to effect.
- Keep anesthetized hamsters warm

# Pain Recognition

## Signs of pain

- Depression,
- Reluctance to move,
- Anorexia,
- Rapid respiration,
- Licking or chewing a painful site,
- Failure to groom,
- Abnormal posture, and restlessness.



# Analgesia

- Buprenorphine (0.05 mg/kg S.C. q8-12h)
- Chlorpromazine (0.5 mg/kg I.M.)
- Diazepam (5 mg/kg I.P.)
- And many other controlled drugs.

# Antibiotic Therapy

- Several antibiotics have been associated with induced enterocolitis due to a reduction of gram-positive flora.
- The use of penicillin, ampicillin, vancomycin, erythromycin, cephalosporin, lincomycin, and oral gentamicin are reported to induce enterocolitis and death in hamsters
- Tetracycline (10 - 20 mg/kg q. 8 hr P.O.) and metronidazole (7.5 mg dose q. 8 hr P.O.) were not associated with the disease.
- Chloramphenicol palmitate (50-200 mg/kg orally q. 8 hr) seems to be the antibiotic of choice for treating hamsters.

# AVMA Guidelines on Euthanasia

Methods **acceptable** for rodents and other small mammals:

- Barbiturates, inhalant anesthetics, CO<sub>2</sub>, CO, potassium chloride in conjunction with general anesthesia, microwave irradiation

Methods **conditionally acceptable** for rodents and other small mammals:

- Methoxyflurane, ether, N<sub>2</sub>, Ar, cervical dislocation (rats < 200 g), decapitation