

Hand Surgery: A Guide for Medical Students

Trevor Carroll and Margaret Jain MD

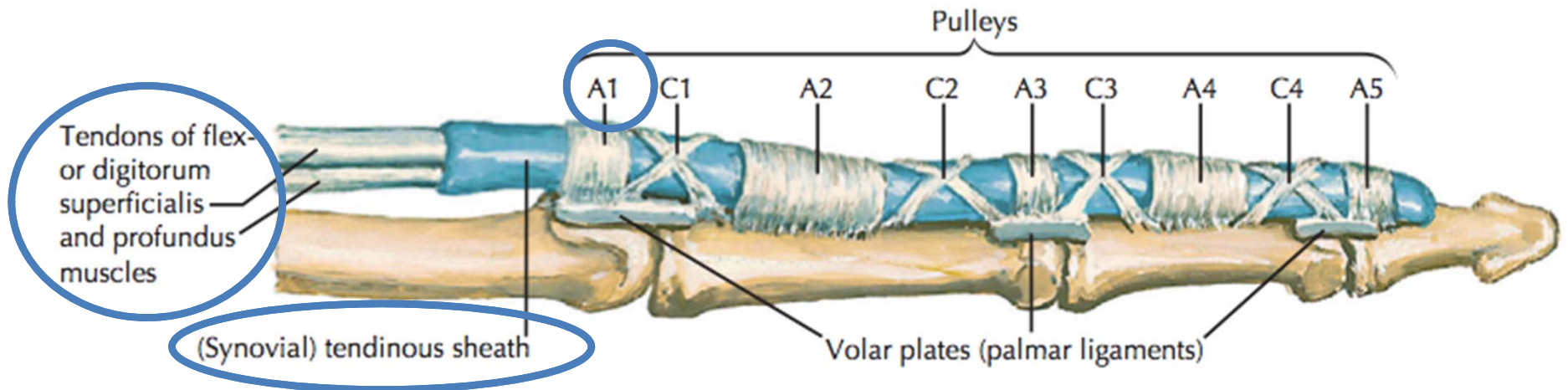
Table of Contents

Trigger Finger	3	
Carpal Tunnel Syndrome		13
Basal Joint Arthritis		23
Ganglion Cyst		36
Scaphoid Fracture		43
Cubital Tunnel Syndrome		54
Low Ulnar Nerve Injury		64

Trigger Finger (stenosing tenosynovitis)

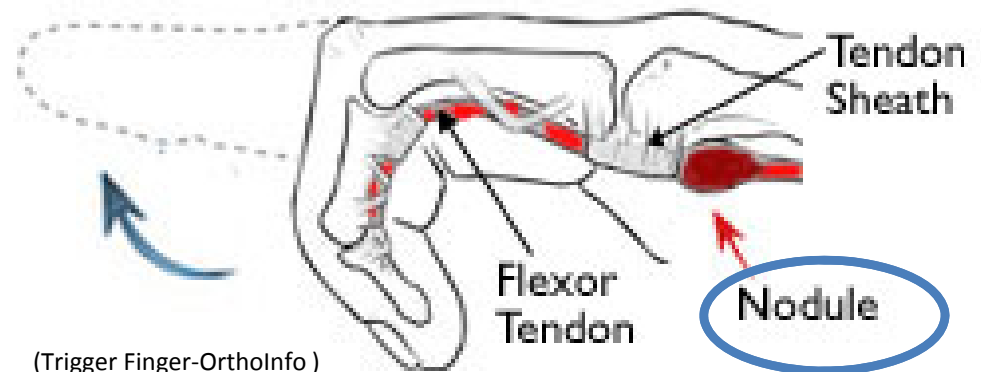
- Anatomy and Mechanism of Injury
- Risk Factors
- Symptoms
- Physical Exam
- Classification
- Treatments

Trigger Finger: Anatomy and MOI



(Thompson and Netter, p191)

- The flexor tendons run within the synovial tendinous sheath in the finger
- During flexion, the tendons contract, running underneath the pulley system
- Overtime, the flexor tendons and/or the A1 pulley can get inflamed during finger flexion.
- Occasionally, the flexor tendons and/or the A1 pulley abnormally thicken. This decreases the normal space between these structures necessary for the tendon to smoothly glide
- In more severe cases, patients can have their fingers momentarily or permanently locked in flexion usually at the PIP joint



(Trigger Finger-OrthoInfo)

Trigger Finger: Risk Factors

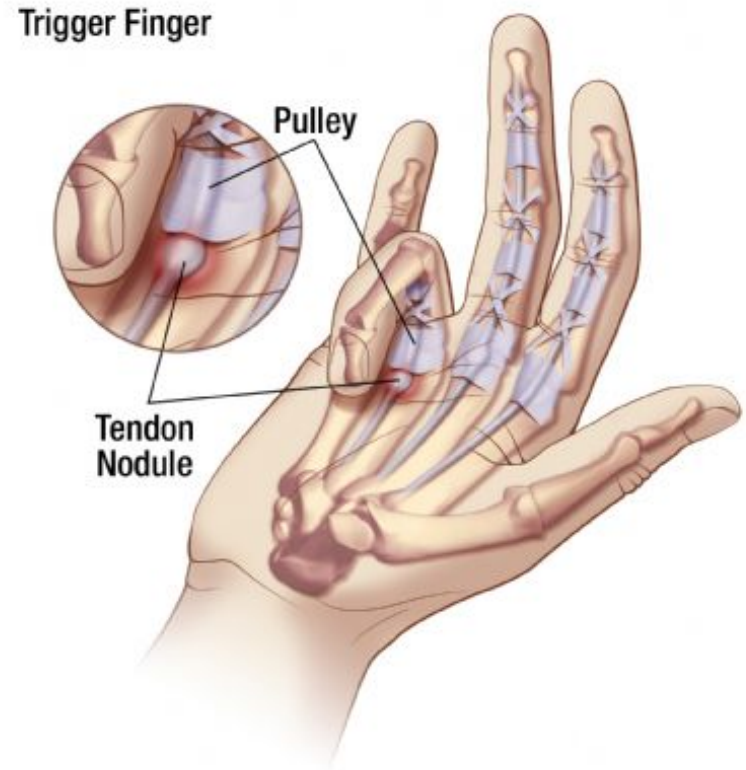
- Age: 40-60
- Female > Male
- Repetitive tasks may be related
 - Computers, machinery
- Gout
- Rheumatoid arthritis
- Diabetes (poor prognostic sign)
- Carpal tunnel syndrome (often concurrently)

Trigger Finger: Subjective

- C/O focal distal palm pain
- Pain can radiate proximally in the palm and distally in finger
- C/O finger locking, clicking, sticking—often worse during sleep or in the early morning
- Sometimes “snapping” during flexion
- Can improve throughout the day

Trigger Finger: Objective

- Focal tenderness to palpation at the finger base (at A1 pulley)
- May appreciate nodule in this location
- Tenderness may increase with finger extension
- Radiographs not necessary
- Beware snapping at MP joint may resemble trigger fingers
- Beware associated MP arthritis—pt will have dorsal joint tenderness



(Hubspot)

Trigger Finger: Classification

Green Classification

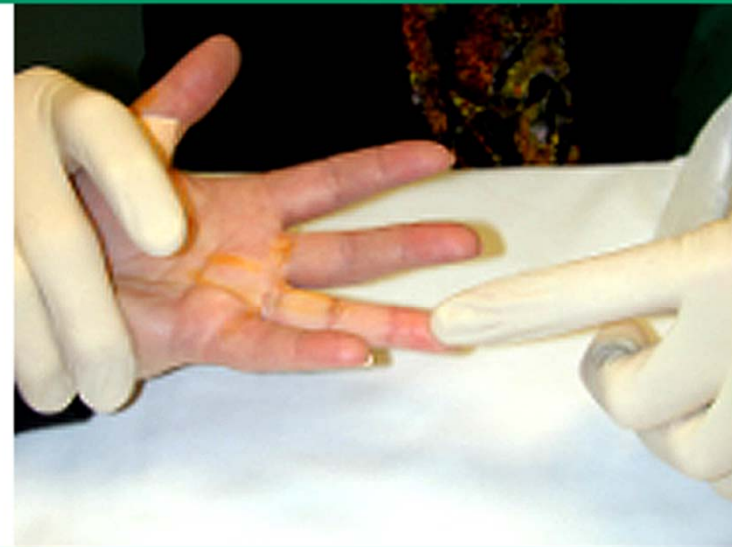Grade I	Palm pain and tenderness at A-1 pulley
Grade II	Catching of digit
Grade III	Locking of digit, passively correctable
Grade IV	Fixed, locked digit

(McKean)

Trigger Finger: Management

- 1st line
 - Stopping the offending activity
 - Night splinting
 - NSAIDS

Passive stretching sign for active tenosynovitis of the finger (trigger finger)



The hands are placed in the palms-up position, and the affected finger is passively stretched in the extended position.

Courtesy of Bruce C Anderson, MD.

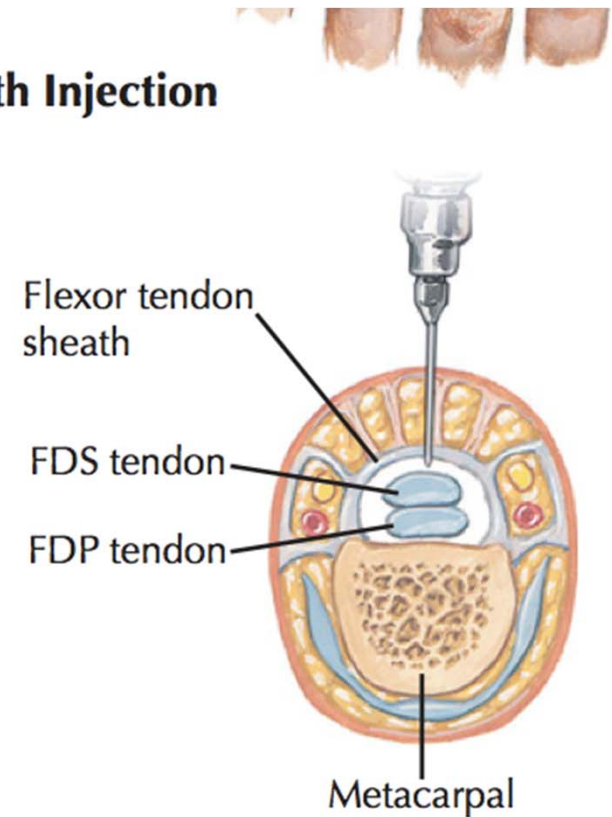
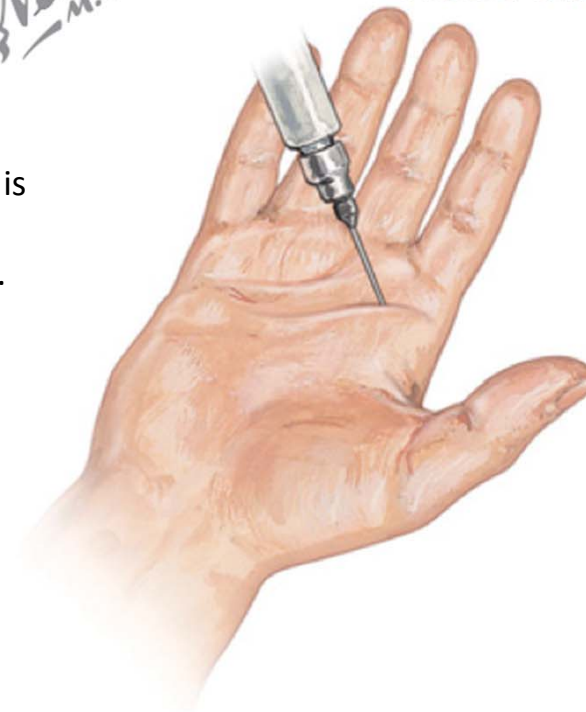
UpToDate®

Trigger Finger: Management

- 2nd line
- Steroid injection
 - Notice the steroid is placed within the tendonous sheath.

F. Netter M.D.

Flexor Sheath Injection



(Thompson and Netter, p199)

Trigger Finger: Management

3rd Line: Surgical release of A1 pulley

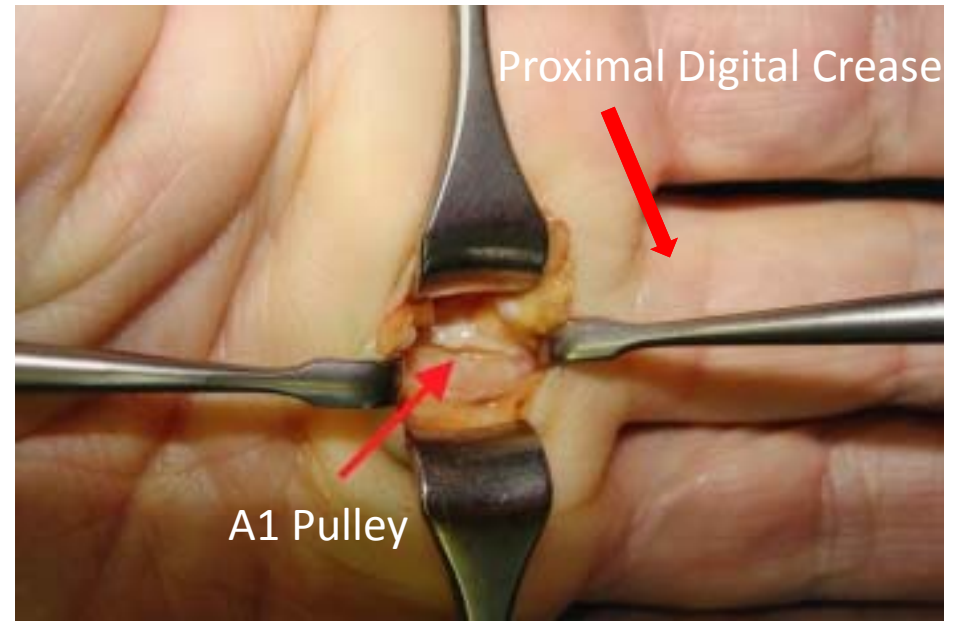
– Operation

- Surgical site: ~ 1 cm proximal to proximal digital crease.
- Incision centered over the metacarpal to avoid common digital arteries and nerve
- Sharp release of A1 pulley to restore smooth tendon gliding
- Have pt demonstrate smooth flexion before closing incision

– Postoperatively

Early passive and active ROM.

Complications: infection, PIP stiffness, digital nerve injury, bowstringing



(Steffens)

Works Cited

- Thompson, Jon C., and Frank H. Netter. *Netter's concise orthopaedic anatomy*. Philadelphia, PA: Saunders Elsevier, 2010. Print.
- "Trigger Finger-OrthoInfo - AAOS." *Trigger Finger-OrthoInfo - AAOS*. N.p., n.d. Web. 08 Mar. 2014.
<http://orthoinfo.aaos.org/topic.cfm?topic=a00024>
- <http://cdn2.hubspot.net/hub/30688/images//TriggerFingerlabel.jpg?t=1424796877421>
- McKean, Jason. "Trigger Finger." *Orthobullets*. N.p., n.d. Web. 08 Mar. 2014. <<http://www.orthobullets.com/hand/6027/trigger-finger>>.
- Steffens, Kurt. "Surgery of Trigger Finger (Snapping Finger)."
Surgery of Trigger Finger (Snapping Finger). N.p., n.d. Web. 08 Mar. 2014. <http://www.hand-arm.com/TVS/surgical_treatment.htm>.

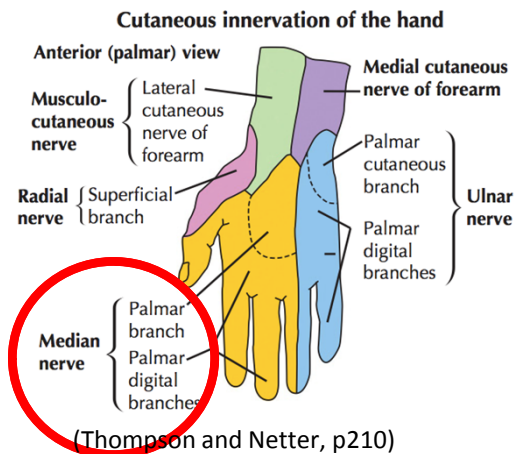
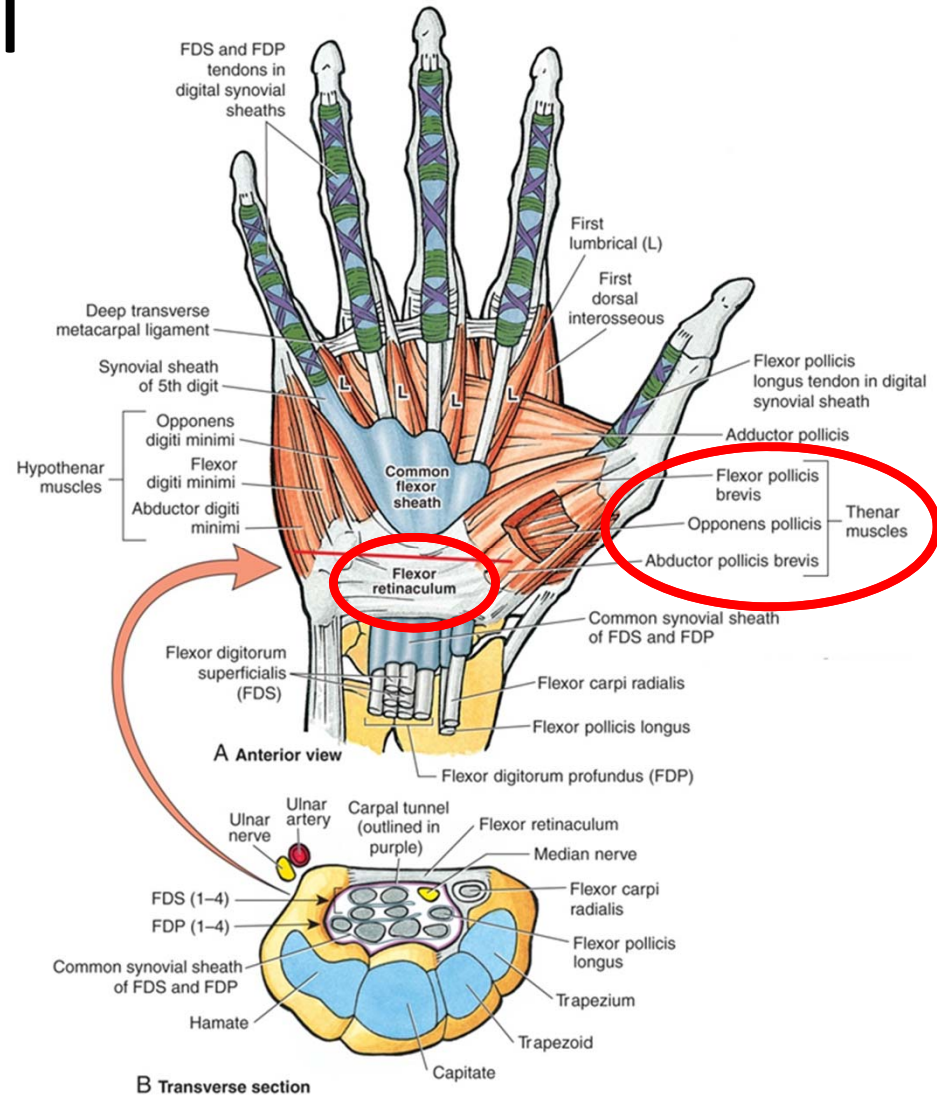
Carpal Tunnel Syndrome

The most common entrapment neuropathy

- Anatomy and Mechanism of Injury
- Risk Factors
- Symptoms
- Physical Exam
- Treatments

Carpal Tunnel Syndrome: Anatomy and MOI

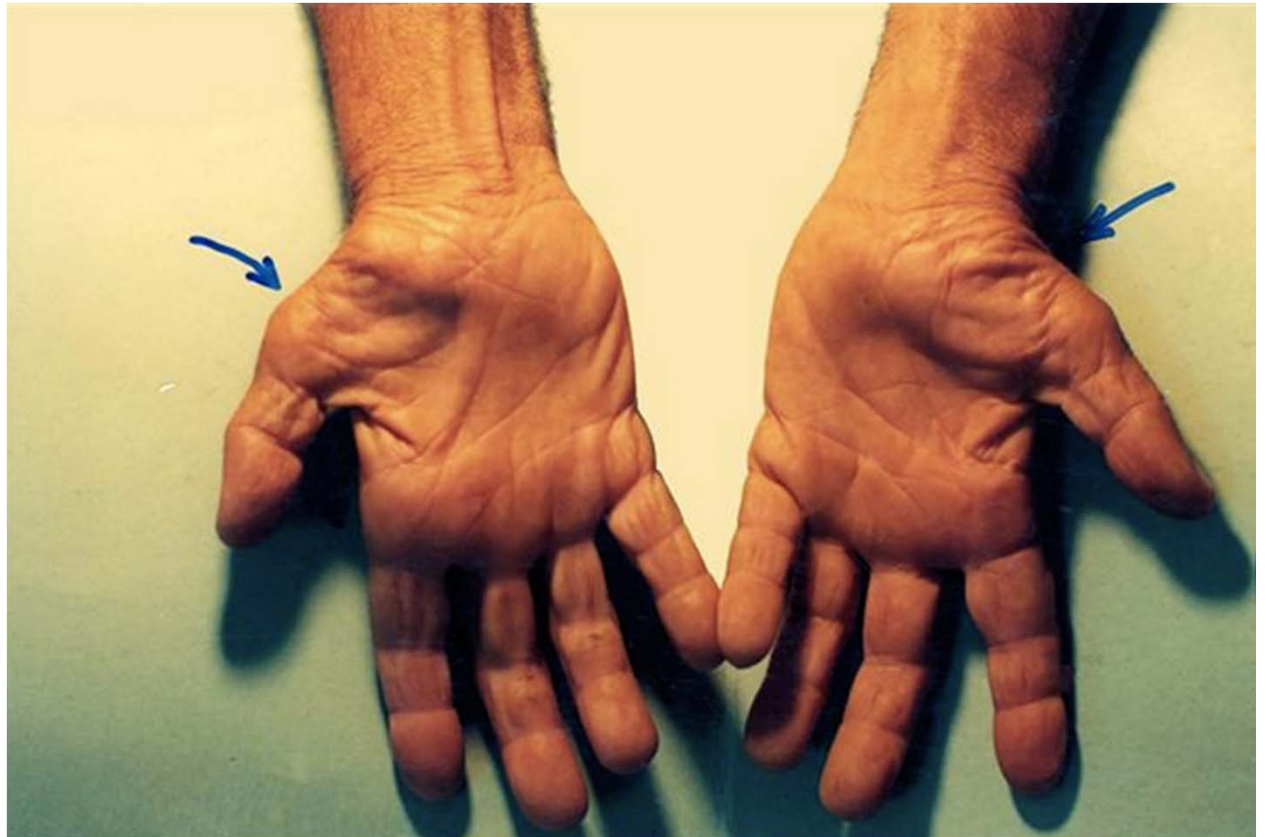
- Median nerve, FDS, FDP, FPL run within the carpal tunnel
- Volar CT boundary: flexor retinaculum (or transverse carpal ligament)
- Median nerve branches:
 - Palmar cutaneous b.- divides from median n. proximal to CT, spared in CTS
 - Recurrent motor b.—motor to opponens pollicis, APB, FPB – divides from median n. around level of CT
 - Common palmar digital b. - sensory to finger tips
 - Motor to 1st and 2nd lumbricals



(Carpal Tunnel Syndrome)

Carpal Tunnel Syndrome: Anatomy and MOI

- The median nerve is entrapped within the tunnel, which creates local nerve ischemia
- This creates numbness, tingling, and or pain in the median nerve distribution
- Chronic entrapment can produce thenar atrophy (seen at right)



(McKean)

Carpal Tunnel Syndrome: Risk Factors

- Females > Males
- Inheriting a smaller tunnel
 - Women tend to have smaller tunnels
- Older Age (mean ~54 years)
- Pregnancy (often resolves with delivery)
- Heavy work with hands and vibrational equipment
 - Machinery workers, auto industry
 - Using jackhammer
- Thyroid disease
- Trauma
- Rheumatoid arthritis
- Ganglion cyst
- Amyloidosis

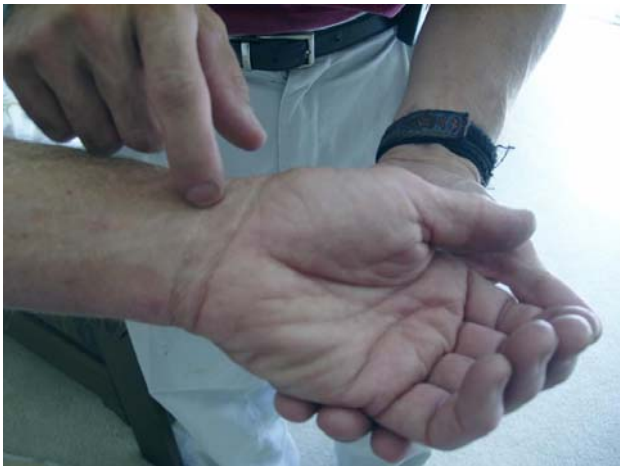Note: No good data to support typing or keyboarding as a cause

Carpal Tunnel Syndrome: Subjective

- Finger numbness or pain- usually spares palms
- Numbness, tingling, burning
- Radiating to first 3 digits and the radial ½ of the ring finger
- Sx are often at night, even waking patients up
 - Obligatory wrist flexion during sleep decreases cross sectional size of the tunnel, increases pressure on the nerve

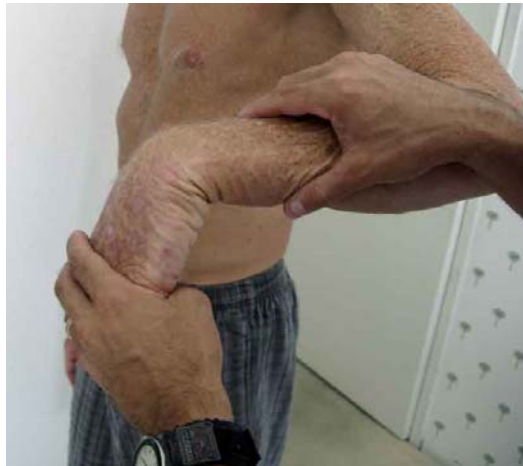Carpal Tunnel Syndrome: Objective

- Hand and wrist usually appear normal, but may show thenar atrophy
- Provocative tests: positive if they reproduce the pts symptoms
 - **Tinel's test**-tap over the median nerve at the wrist
 - **Phalen's Test**-hold forced flexion for 60 seconds
 - **Durkan's Test**- (Carpal compression test) press thumb over carpal tunnel for 30 seconds
- Radiographs not necessary
- EMG and NCV-objective test to quantify nerve injury



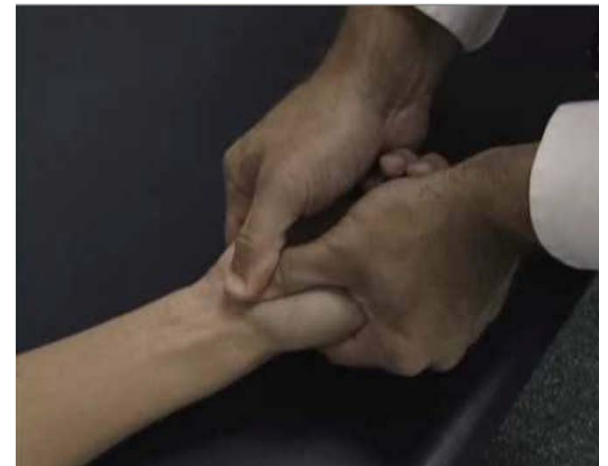Tinel's Test

(Musculo-Skeletal Examination)



Phalen's Test

(Musculo-Skeletal Examination)



Durkan's Test

(Mckean)

Carpal Tunnel Syndrome: Assessment

- Diagnosis is clinical
- EMG and NCV often obtained
 - not absolutely necessary for diagnosis
 - Generally recommended prior to surgical release

Carpal Tunnel Syndrome: Plan

1st line

- Night splints
- Activity modification- avoid wrist flexion and extension

2nd line

- Steroid injection
 - Most patients have some improvement with injection
 - Typically (~75%) Sx return
 - Useful in pregnancy and to confirm Dx
 - Most successful in mild CTS (>1 yr preserved sensation)

Carpal Tunnel Syndrome: Plan

- 3rd line-Carpal Tunnel Release
 - Surgical release of the transverse carpal ligament
 - increases size of the carpal tunnel
 - Decreases pressure on nerve
 - Keep incision just ulnar to thenar crease
 - This helps avoids injury to the recurrent motor branch.

Works Cited

- "Carpal Tunnel Syndrome." HEALTH, MEDICINE AND ANATOMY REFERENCE PICTURES. Health, Medicine and Anatomy Reference Pictures, 13 Oct. 2013. Web. <http://healthfavo.com/carpal-tunnel-syndrome-2.html>.
- Thompson, Jon C., and Frank H. Netter. *Netter's concise orthopaedic anatomy*. Philadelphia, PA: Saunders Elsevier, 2010. Print.
- "Musculo-Skeletal Examination." A Practical Guide to Clinical Medicine. University of California, San Diego, n.d. Web. 09 Mar. 2014. <<https://meded.ucsd.edu/clinicalmed/joints3.htm>>.
- McKean, Jason. "Carpal Tunnel Syndrome." Orthobullets. N.p., 8 Mar. 2014. Web. 09 Mar. 2014. <<http://www.orthobullets.com/hand/6018/carpal-tunnel-syndrome>>

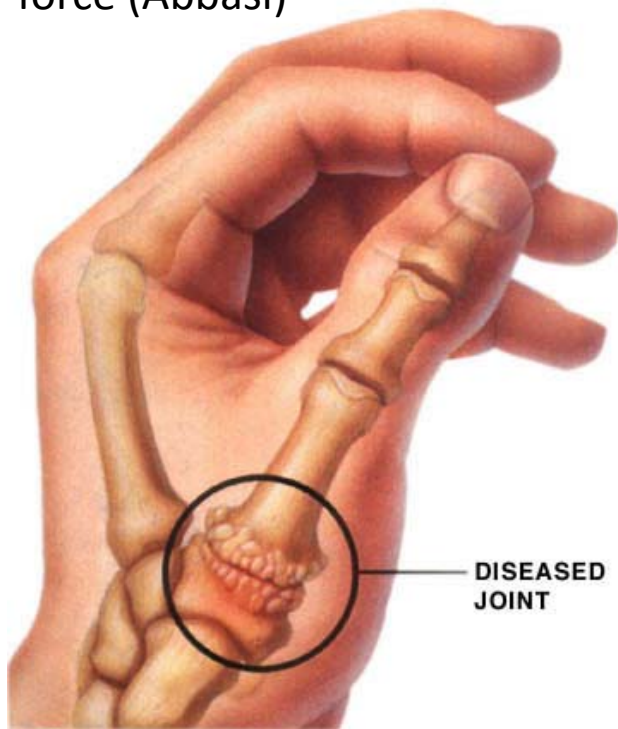
Basal Joint Arthritis

The 2nd most common hand osteoarthritis (after DIP OA)

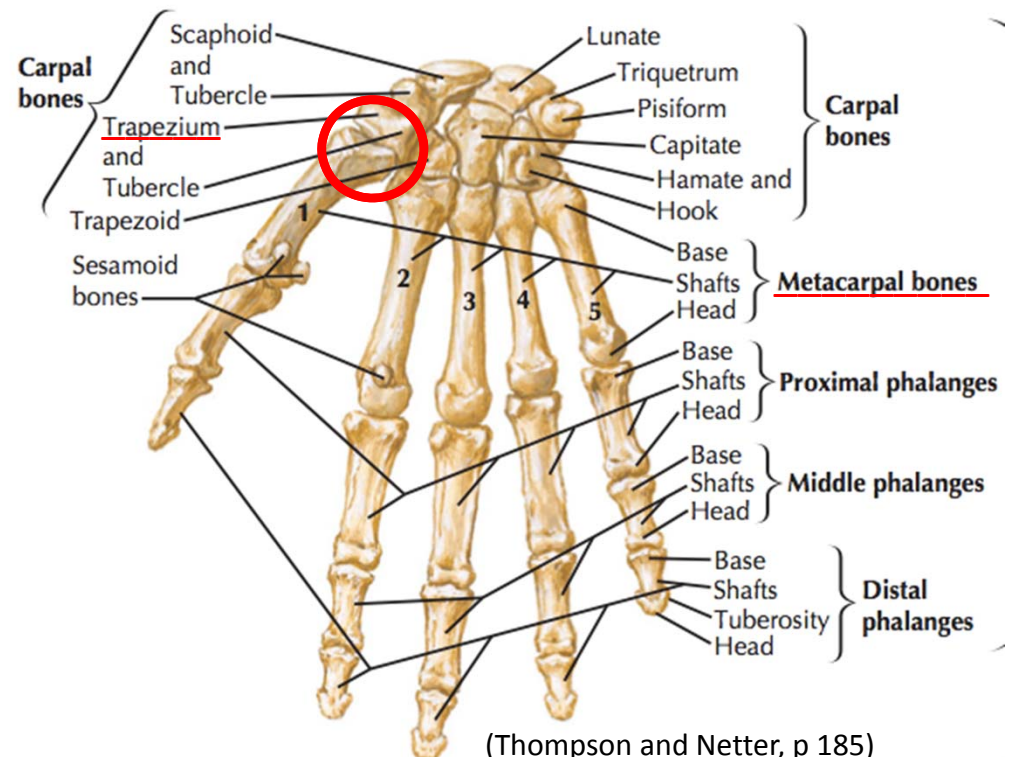
- Anatomy and Mechanism of Injury
- Risk Factors
- Symptoms
- Physical Exam
- Radiographs and Classification
- Treatments

Basal Joint Arthritis: anatomy and MOI

- Basal joint arthritis occurs between the trapezium and the base of the first metacarpal
- This is also called the carpal-metacarpal joint (CMC)
- Basal joint allows thumb opposition
- During pinching, CMC joint's reactive force is twelve times greater than the pinching force (Abbasi)



(DoctorRe)



(Thompson and Netter, p 185)

Basal Joint Arthritis: Risk Factors

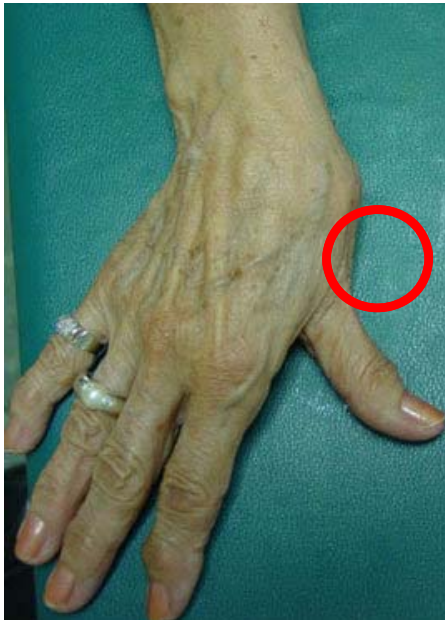- Female > Male
- Older than 40
- Prior injuries to the area (sprains)
- Rheumatoid arthritis

Basal Joint Arthritis: Symptoms

- Pain with grasping/pinching activities
- Worse with use
- Decrease range of motion in thumb
- Up to 40% have coexisting carpal tunnel syndrome, or will develop it over time

Basal Joint Arthritis: Exam

- Inspection may show:
 - “Bump” at dorsal thumb-- due to MC subluxing dorsally on the trapezium
 - Adduction deformity of 1st metacarpal in late stages of disease
 - If severe, MCP joint hyperextension (seen in red) occurs to compensate for decrease CMC motion
- Grind test: Axially load the first metacarpal and rotate at the joint, will reproduce pain.



1st metacarpal adduction deformity
(Badia)

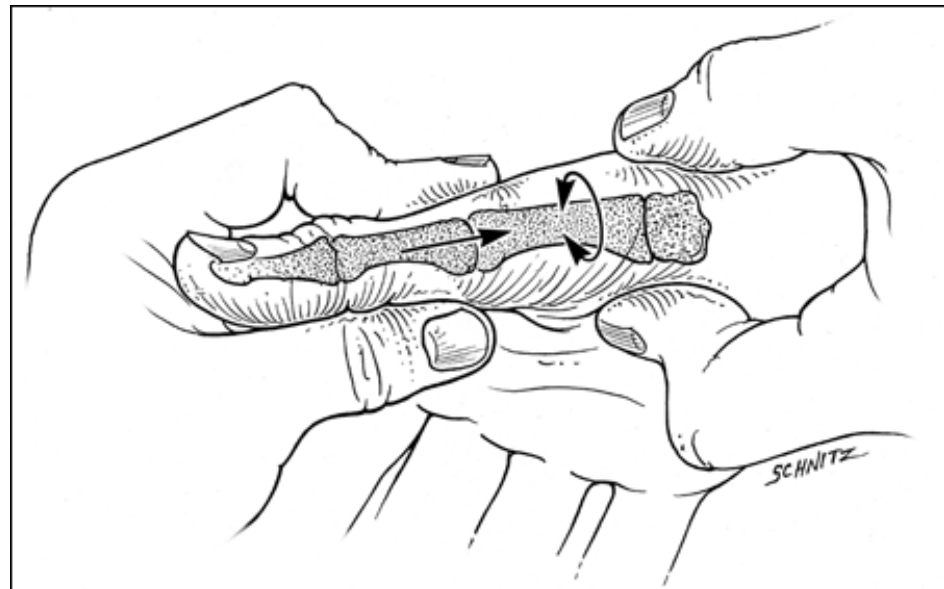


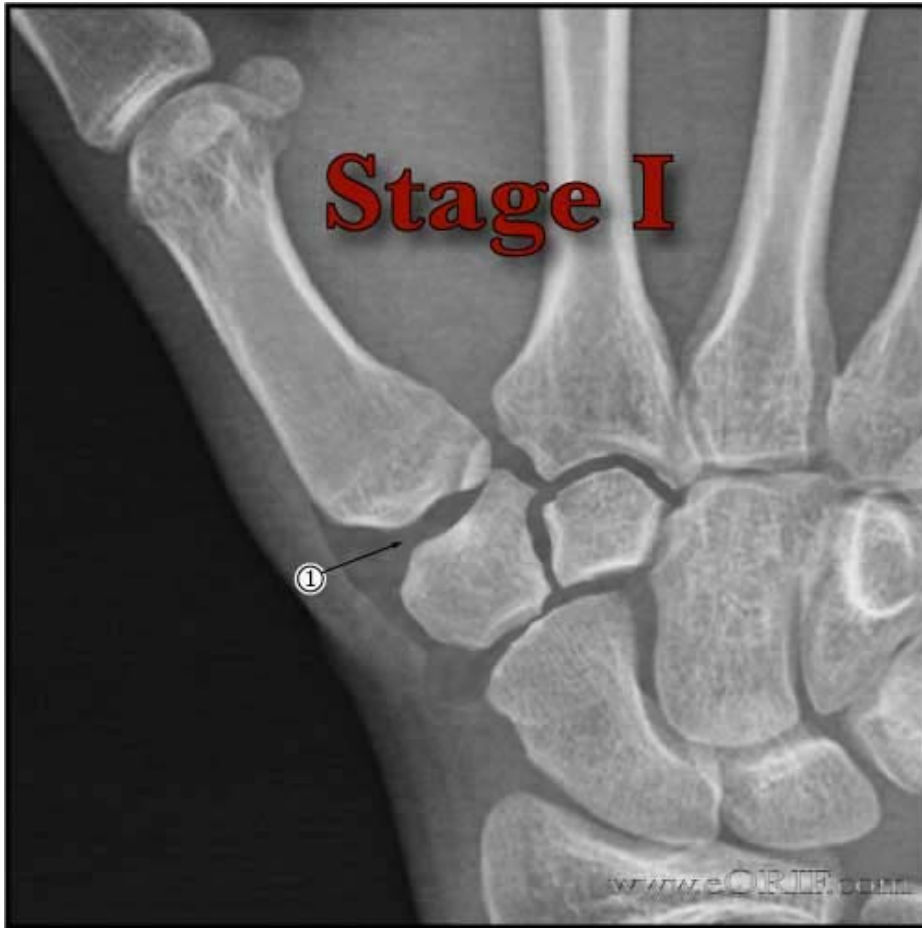Fig. 2: Grind test performed by your physician.
(Indianapolis Hand Surgeons)

Basal Joint Arthritis: Radiographs and Classification

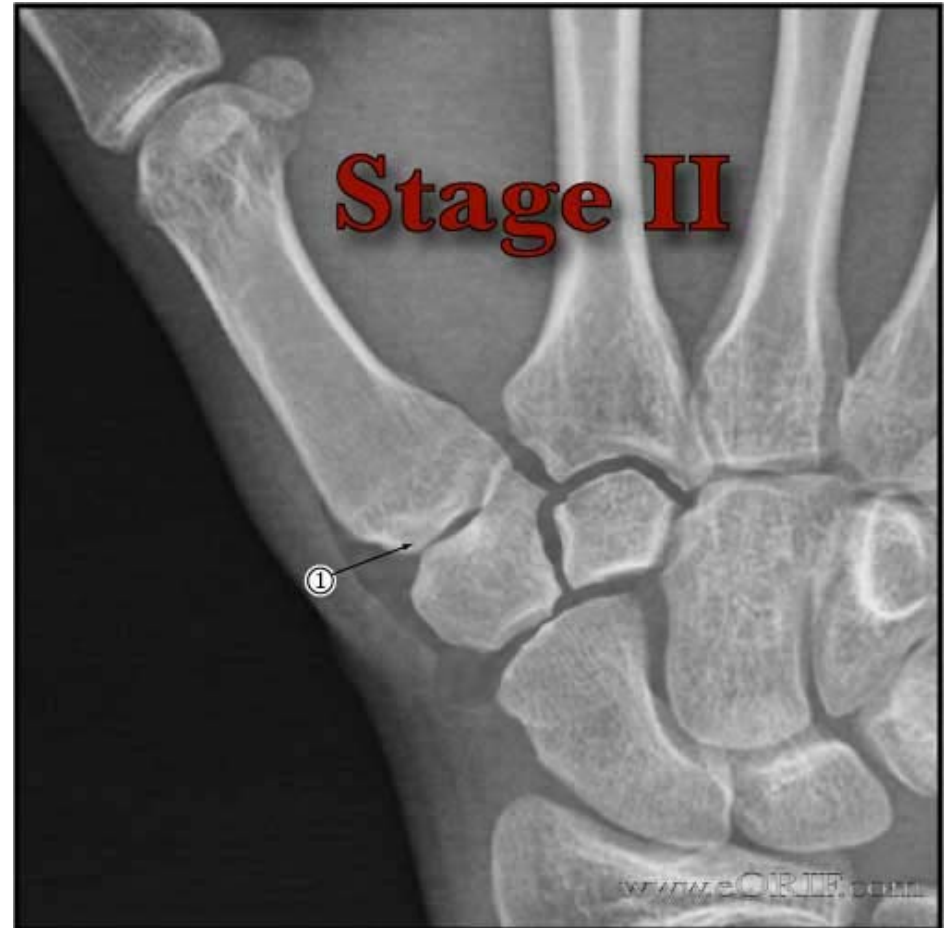Eaton and Littler Classification of Basilar Thumb Arthritis

Stage I	slight joint space widening (pre-arthritis)
Stage II	slight narrowing of CMC joint with sclerosis, osteophytes <2mm
Stage III	marked narrowing of CMC joint with osteophytes, osteophytes >2mm
Stage IV	pantrapezial arthritis (STT involved)

Basal Joint Arthritis: Radiographs and Classification

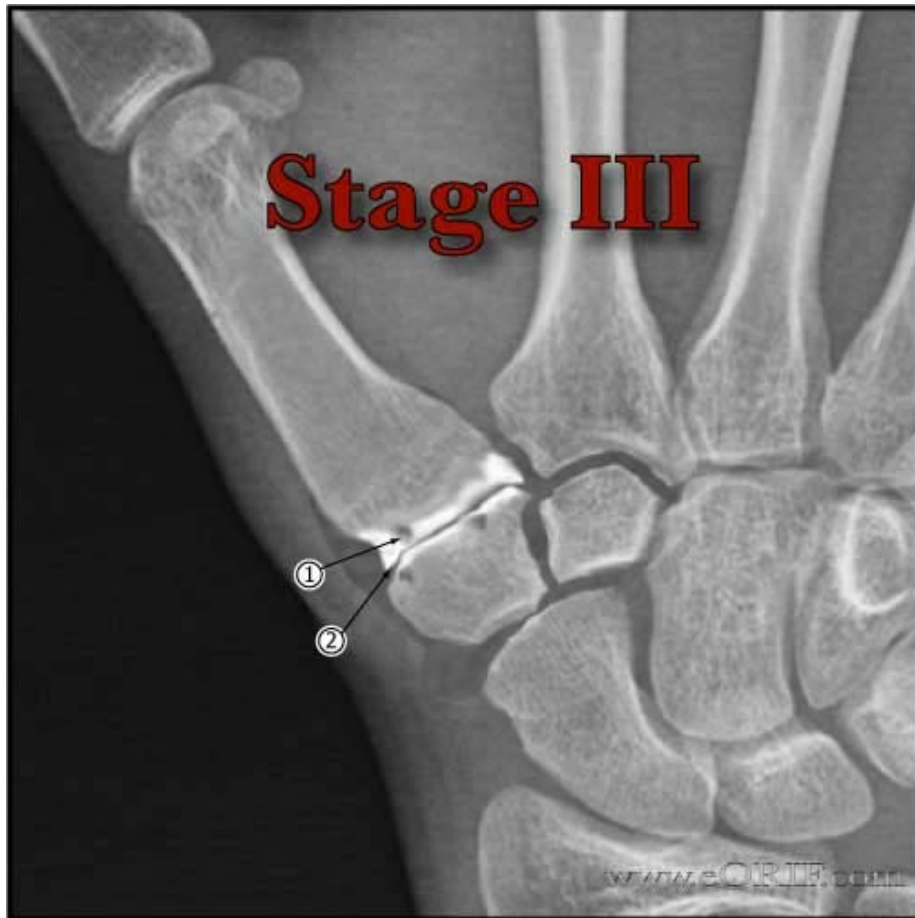

- Widened Joint Space (EORIF)

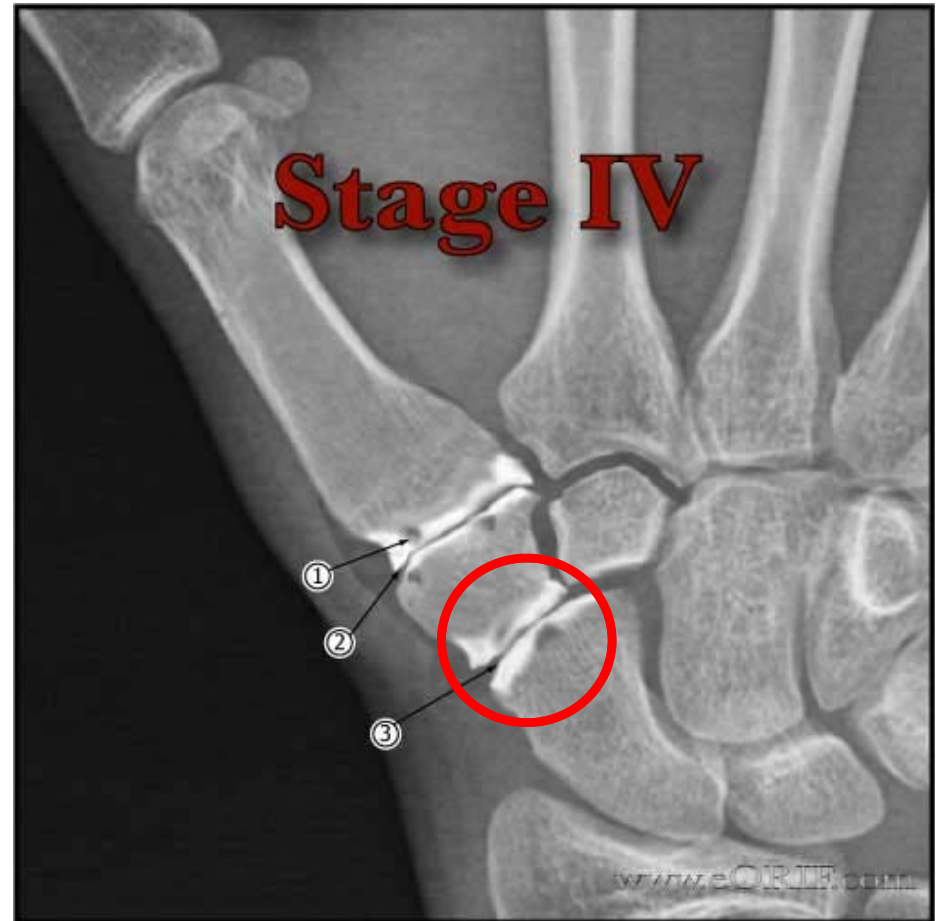

- Narrowed Joint Space (EORIF)
- Osteophytes smaller than 2 mm

Basal Joint Arthritis: Radiographs and Classification



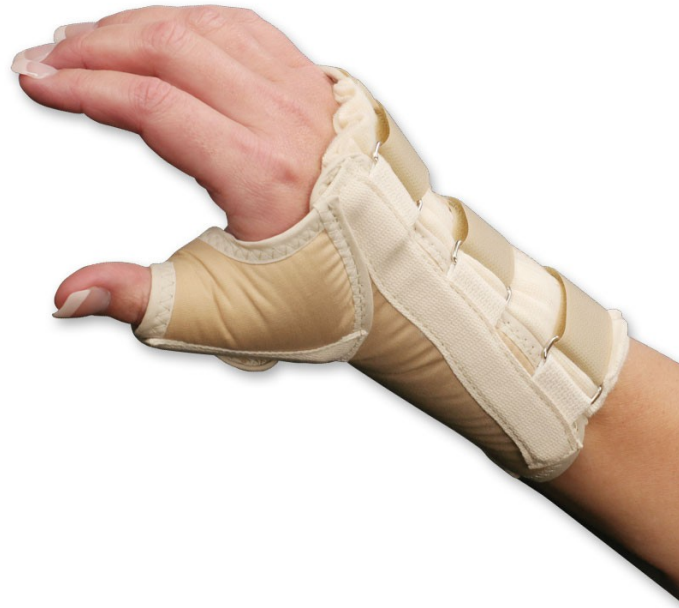- Sclerosis (EORIF)
- Cystic changes
- Osteophytes >2 mm



- Osteoporotic signs in the scaphotrapezoidal joint (EORIF)

Basal Joint Arthritis: Treatment

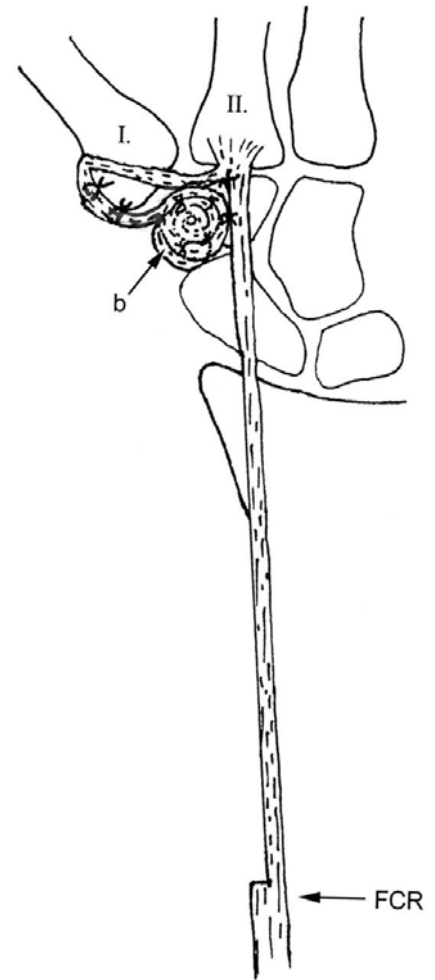
- 1st line
 - NSAIDS
 - Spica splint
 - thumb immobilization
- 2nd line
 - Corticosteroids
 - Rarely provided prolonged relief



Basal Joint Arthritis: Surgical Treatment

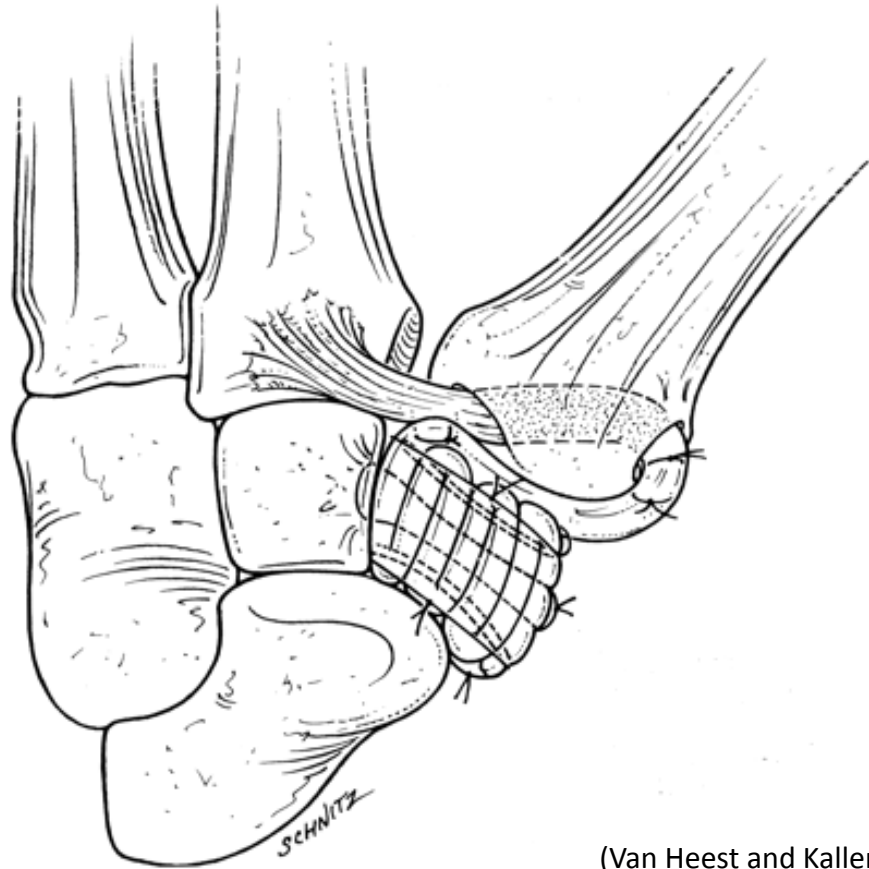
3rd line-Basal Joint Arthroplasty

- Always involves some excision of the articular surface of the trapezium
- Most common procedure: trapeziectomy + interposition of FCR tendon +/- reconstruction of the volar ligament (AKA LTRI or Burton's arthroplasty)
- Incision at dorsal thumb
- Anatomy to identify (above right)
 - I. 1st Metacarpal
 - II. 2nd Metacarpal with FCR insertion
 - b. Interposition graft of FCR tendon



Basal Joint Arthritis: Burton's Arthroplasty (LRTI)

- Excise trapezium
- Harvest all or ½ of FCR tendon proximally, leaving distal insertion at 2nd MC base intact
- Transfer FCR to the 1st MC base
- Interpose remained of coiled FCR into the space left by trapezium excision



(Van Heest and Kallemeier)

Trapezium removed and coiled FCR tendon occupying the space

Works Cited

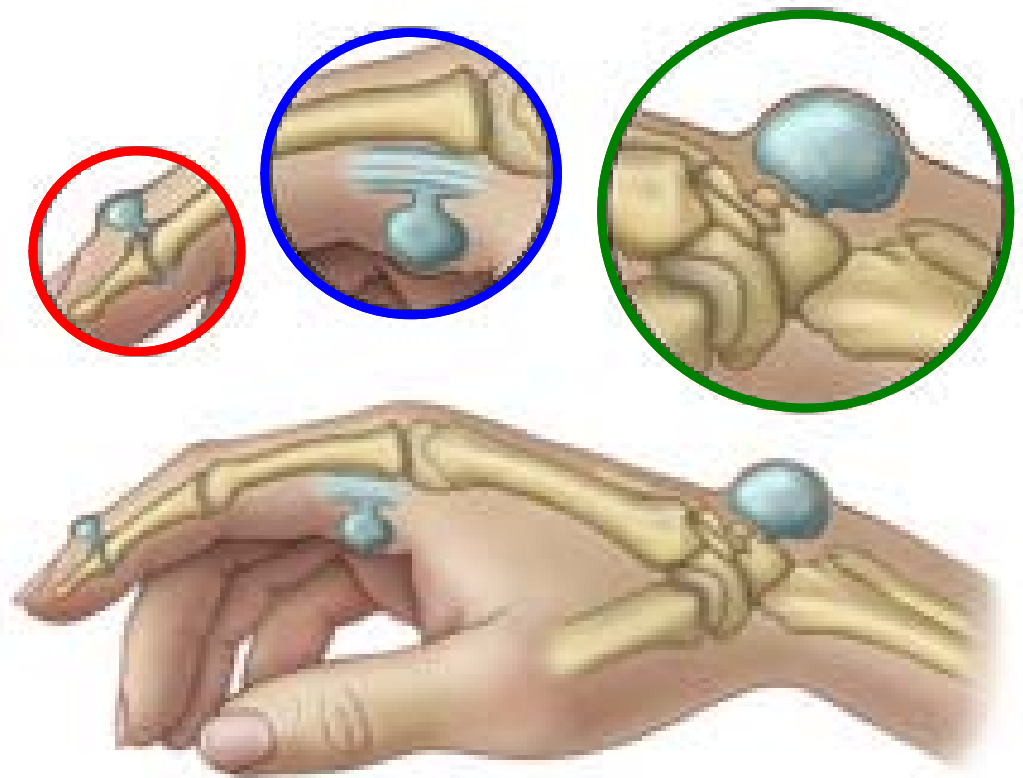
- Abbasi, David. "Basilar Thumb Arthritis." - *Hand. Orthobullets*, 10 Feb. 2014. Web. 15 Mar. 2014. <<http://www.orthobullets.com/hand/6054/basilar-thumb-arthritis>>.
- "DoctorRe.com | Common Injuries - Wrist & Hand." *DoctorRe.com | Common Injuries - Wrist & Hand*. N.p., n.d. Web. 15 Mar. 2014. <<http://www.doctorre.com/commoninjuries/wristandhand/>>.
- Thompson, Jon C., and Frank H. Netter. *Netter's concise orthopaedic anatomy*. Philadelphia, PA: Saunders Elsevier, 2010. Print.
- Badia, Alejandro. "Total Joint Arthroplasty in the Treatment of Advanced Stages of Thumb Carpometacarpal Joint Osteoarthritis." *Osteoarthritis Thumb Basal Joint Orthopedic Finger Surgeon Dr. Alejandro Badia Hand to Shoulder Center Hand Hospital Miami Thumb Carpometacarpal Joint Osteoarthritis*. Badia: Hand to Shoulder Center, 12 Apr. 2007. Web. 15 Mar. 2014. <<http://www.drbadia.com/para-mdicos-y-colegas-total-joint-arthroplasty-in-the-treatment-of-advanced-stages-of-thumb-carpometacarpal-joint-osteoarthritis-article-id-48-cat-7-eng.php>>.
- "Arthritis at the Base of the Thumb." *Indianapolis Hand Surgeons*. Indiana Hand to Shoulder Center, n.d. Web. 15 Mar. 2014. <http://indianahandtoshoulder.com/medical_education_hand_arthritis.html>.
- "Thumb Basilar Joint Arthritis 715.14." *EORIF*. N.p., n.d. Web. 15 Mar. 2014. <<http://www.eorif.com/thumb-basilar-joint-arthritis-71514>>.
- Mohanty, Satyajit. "Physiotherapy Blogging." : Differential Diagnosis of Anatomic (Radial) Snuffbox Pain: It Is Not Always DeQuervain's Tenosynovitis. N.p., 12 May 2012. Web. 16 Mar. 2014. <<http://physioindia.blogspot.com/2012/05/differential-diagnosis-of-anatomic.html>>.
- Van Heest, Ann and Kallemeier, Patricia, Thumb Carpal Metacarpal Arthritis. *J Am Acad Orthop Surg* March 2008 ; 16:140-151.

Ganglion Cyst

- Overview
- Dorsal Ganglion Cysts
- Volar Wrist Ganglions
- Volar Retinacular Cysts
- Symptoms and Physical Exam
- Treatments

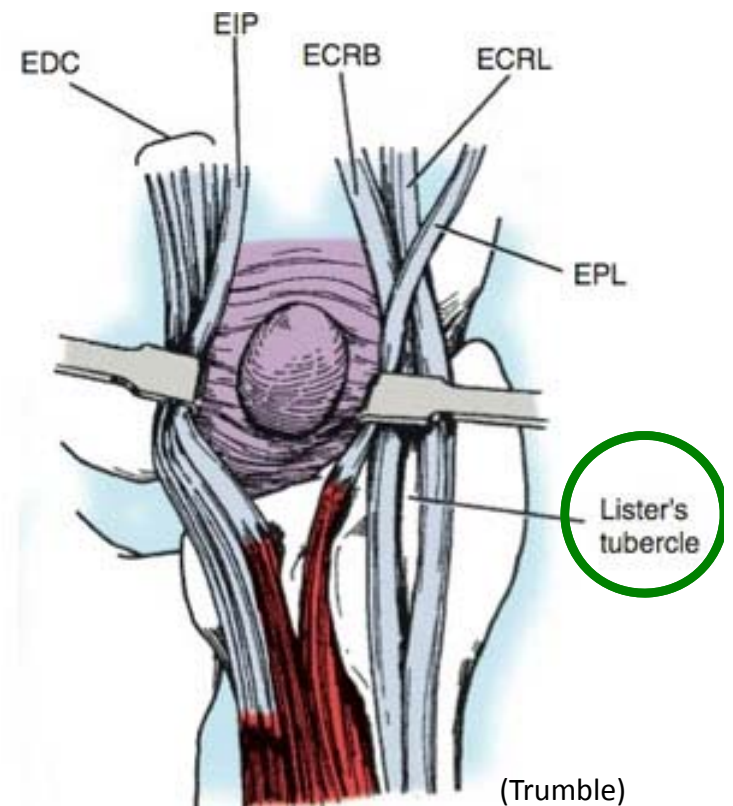
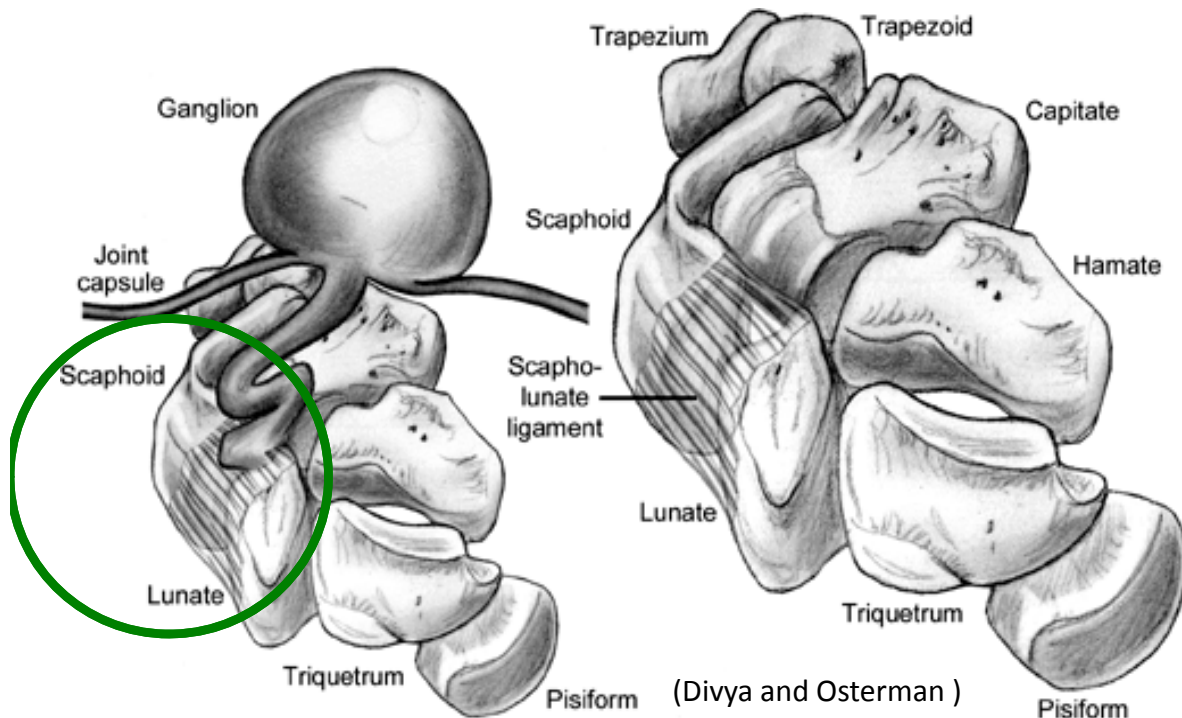
Ganglion Cysts: Overview

- Mucin filled synovial cyst attached by a stalk to the joint capsule (Hughes)
 - 70% dorsal carpal (green)
 - 20% volar carpal (not pictured)
 - 10% volar retinacular (red)
 - Occur at the A1 or A2 pulley commonly
- Slow Growing
- Benign tumor



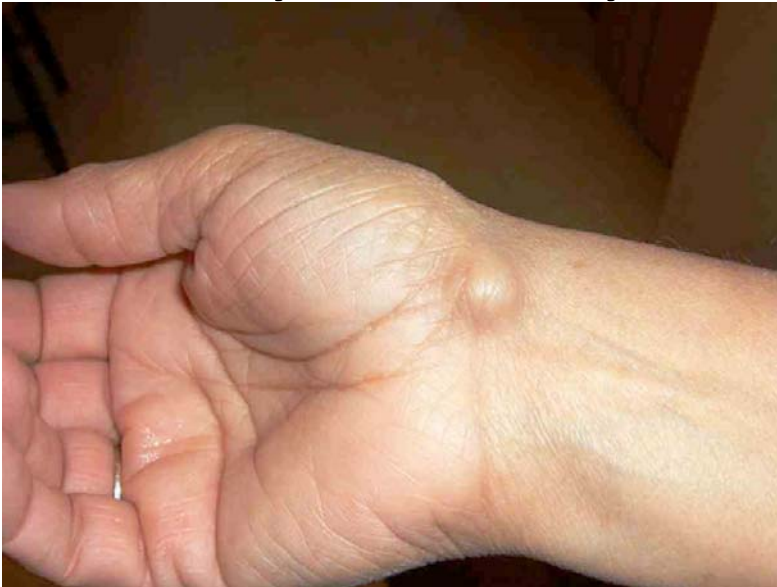Dorsal Ganglion Cysts

- Typically occur over the scapholunate ligament
- ~70% of all ganglion cysts
- Thought to occur from recurrent stress of scapholunate ligament
- 70% occur 2nd-4th decade
- Near Lister's tubercle of the distal radius

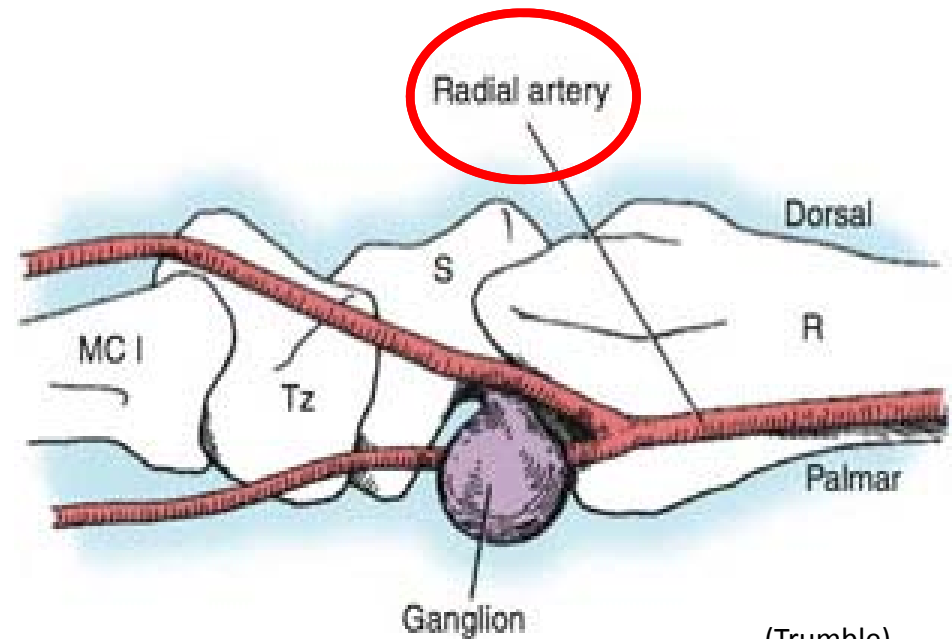


Volar Wrist Ganglions

- ~20% of all ganglia cysts
- Usually between the FCR and APL at the scaphotrapezoid joint
- Not recommended to aspirate b/c radial artery is nearby



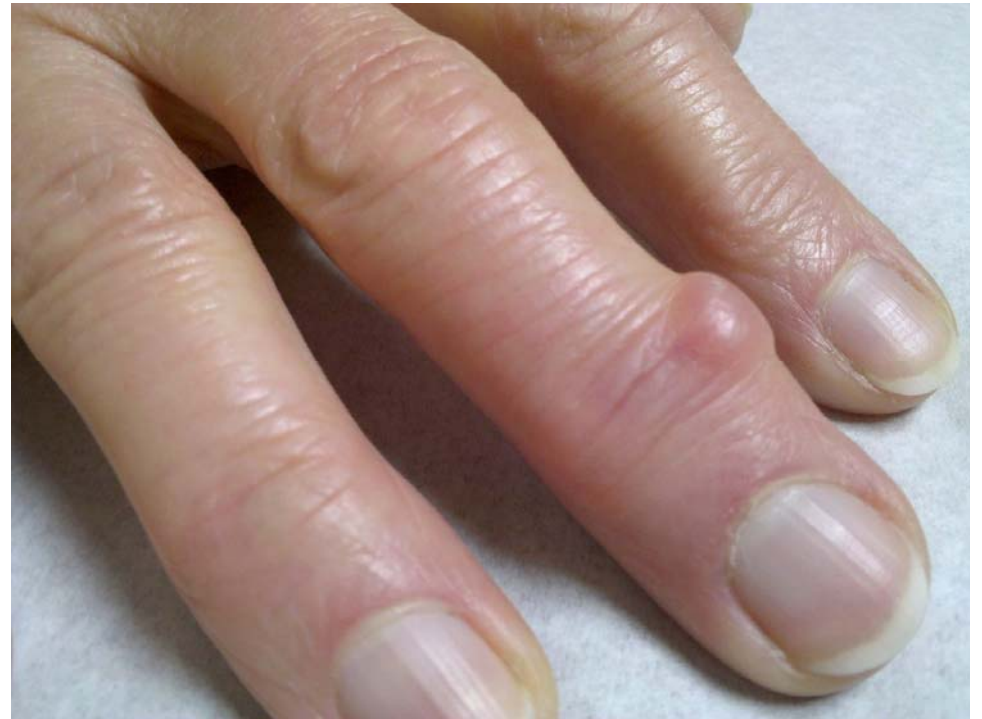(HSSH)



(Trumble)

Digital Mucous Cysts

- Occur at the distal interphalangeal joint
- 10% of hand cysts (Hughes)
- Associated w/osteoarthritis
 - usually an osteophyte at the DIP
 - Women
 - 50-70 years old
 - Often with Heberden's Nodes



Ganglion Cysts

Symptoms

- Usually asymptomatic
- Can be painful with wrist extension
- Cosmetic complaints

Physical Exam

- Firm
- Rubbery
- Well circumscribed
- Transilluminates with flashlight
- Radiographs normal (usually)

Ganglion Cyst: Treatment

1st line

- Observation, splint wear

2nd line

- Aspiration
 - Usually not recommended with volar cysts due to radial artery
 - 50%-90% recurrence rate
 - Can send sample for cytology to R/O malignancy if concerning characteristics/location

3rd line

- Surgical excision of the cyst and stalk to prevent recurrence

Works Cited

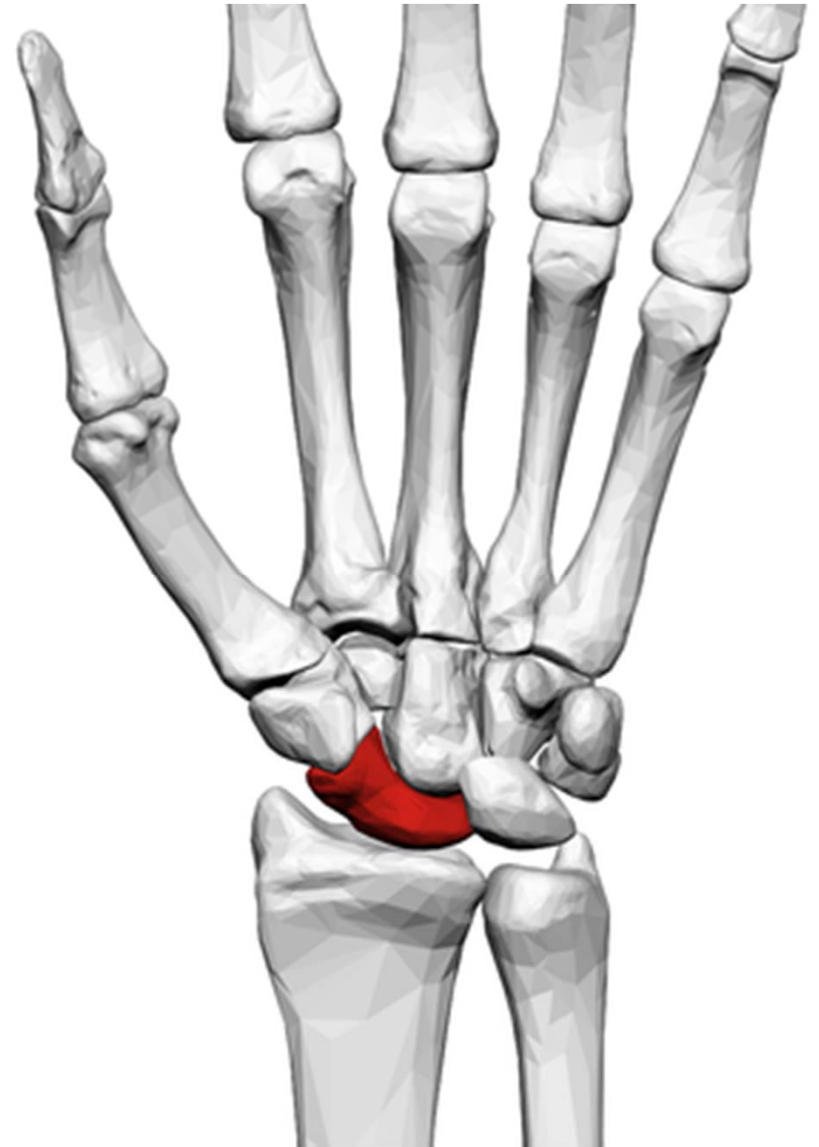
- Hughes, Michael. "Ganglion Cysts." *Orthobullets*. N.p., 06 Oct. 2013. Web. 23 Mar. 2014. <<http://www.orthobullets.com/hand/6086/ganglion-cysts>>.
- "Ganglion Cysts - Wrist And Hand Lumps And Bumps." *Ganglion Cysts*. IHealthSpot, Inc, n.d. Web. 23 Mar. 2014. <<http://ccf.eznetpublish.ihealthspot.com/Home/tabid/6851/ctl/View/mid/10838/Default.aspx?ContentPubID=90>>.
- Divya, Singh, and A. Lee Osterman. "Ganglionectomy." *Hand Surgery 1st Edition*. Lippincott Williams & Wilkins, n.d. Web. 23 Mar. 2014. <<http://www.msdlatinamerica.com/ebooks/HandSurgery/sid524185.html>>
- Trumble, Thomas. "Ganglion Cyst." *Ganglion Cyst*. BBPJ: Hand and Upper Extremity Institute, n.d. Web. 23 Mar. 2014. <<http://www.drtrumble.com/ganglion-cyst.html>>.
- "Ganglion Cyst Treatment | Hand Surgery Specialists of Houston." *HSSH*. Hand Surgery Specialists of Houston Dallas — Beverly Hills — Las Vegas, 6 Mar. 2013. Web. 23 Mar. 2014. <<http://carpaltunnelpros.com/portfolio-view/ganglion-cyst/>>.
- "Mucous Cyst." *Wheeless' Textbook of Orthopaedics*. N.p., 20 June 2010. Web. 23 Mar. 2014. <http://www.wheelessonline.com/ortho/mucous_cyst>.

Scaphoid Fractures

- Anatomy and Mechanism of Injury
- Risk Factors
- Symptoms
- Presentation
- Imaging
- Radiographs
- Classification & Treatments

Scaphoid Fracture: Anatomy and MOI

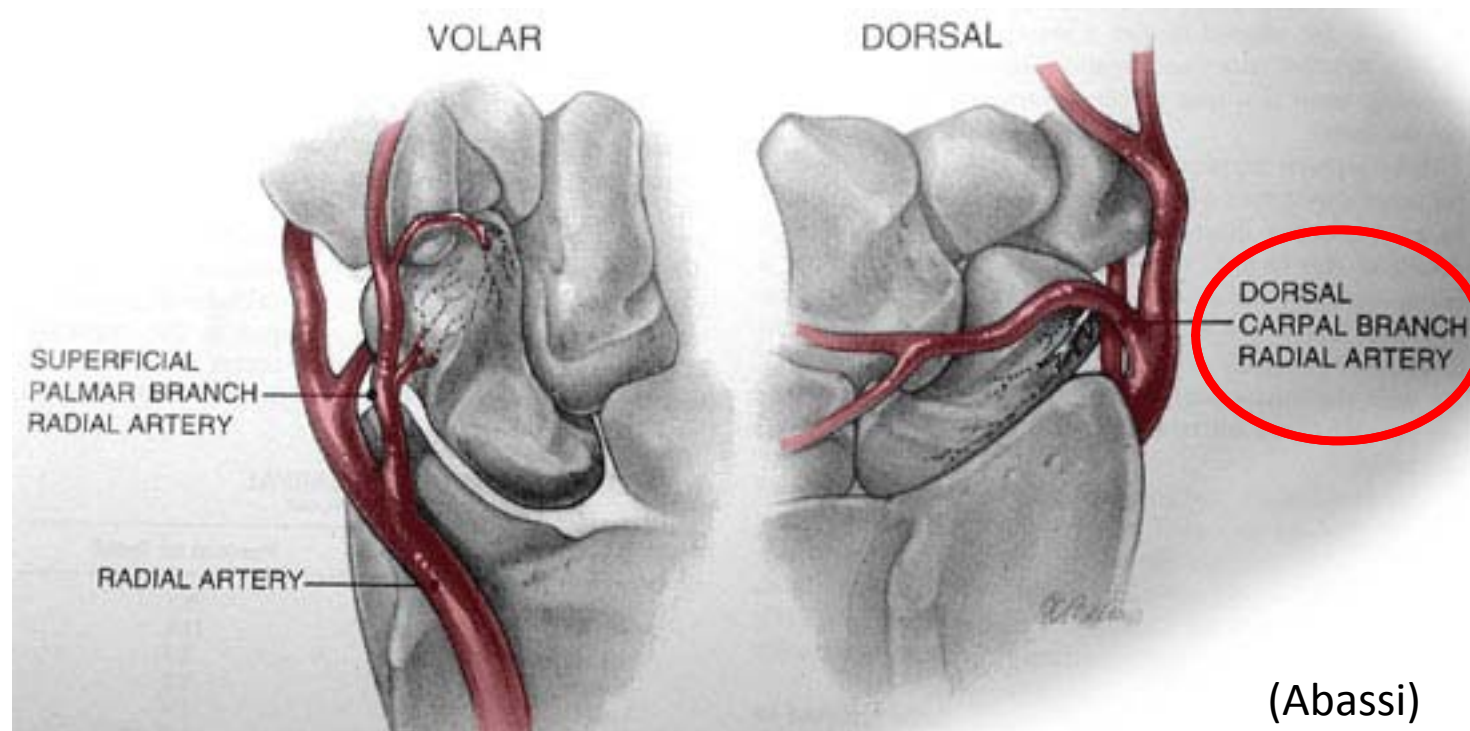
- The scaphoid is the radial border of the carpal bones
- Most commonly fractured carpal bone
- 75% of the bone is articular cartilage



Left Hand Palmar view (wikipedia)

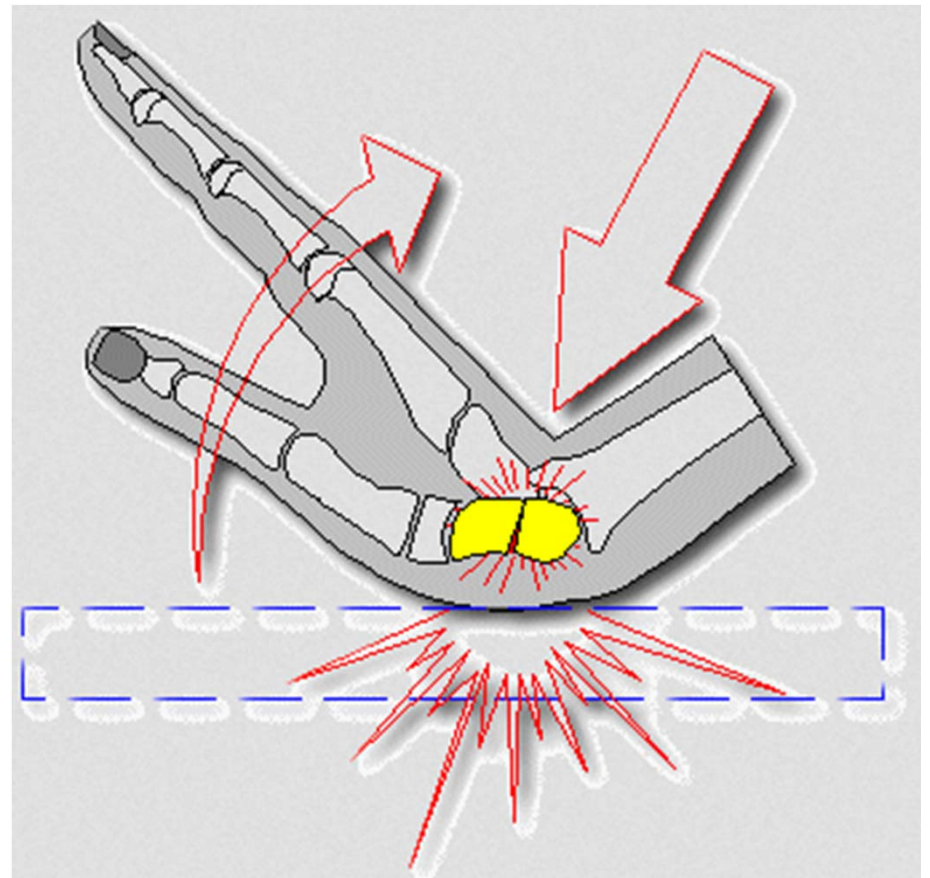
Scaphoid Fracture: Anatomy and MOI

- 80% of the scaphoid blood supply is from the dorsal carpal branch of the radial artery
- A minority of blood supply is from the superficial palmar arch via palmar branch
- The most proximal portion of the bone relies on retrograde flow.
 - implication for fractures is higher rates of AVN.
 - 100% AVN in fracture of proximal 5th and 33% AVN in fracture of proximal third



Scaphoid Fracture: Mechanism

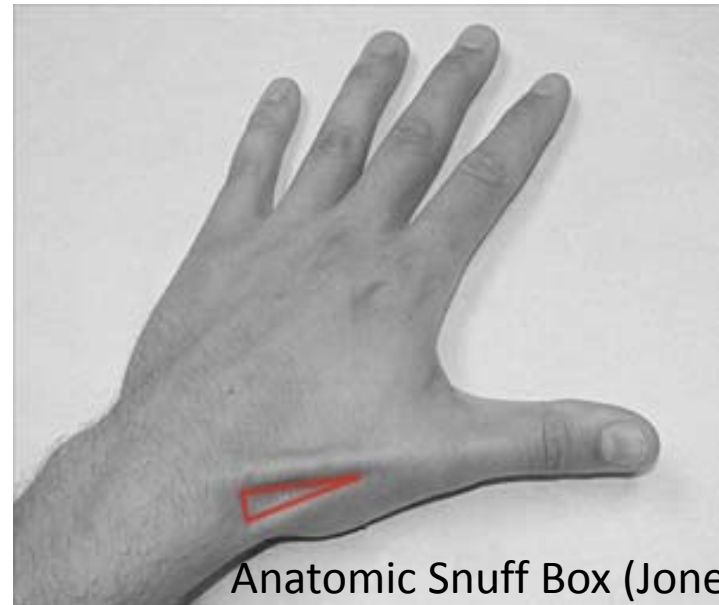
- Most commonly associated with low impact falls
- Young males most common
- Extreme dorsiflexion of the hand
 - Frequently occurs with falls backward



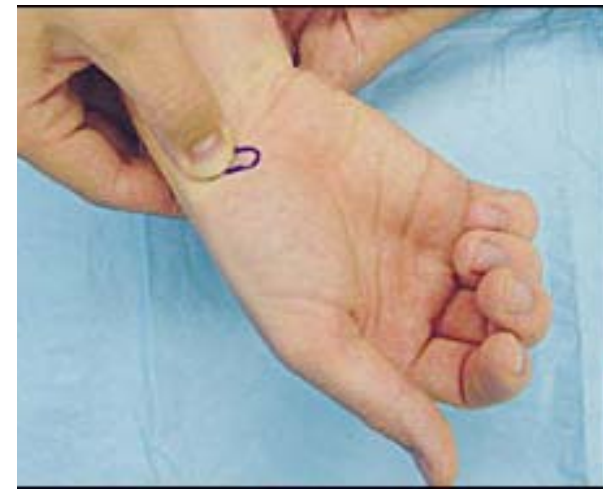
(FXRX)

Scaphoid Fracture: Presentation

- History:
 - Pts complain of wrist pain, reduced motion and/or grip weakness
 - Often give a history of sprained wrist not improving with time
- Exam:
 - Tender dorsal anatomic snuffbox
 - Scaphoid tubercle tenderness on volar aspect
 - Limited wrist extension



Anatomic Snuff Box (Jones)



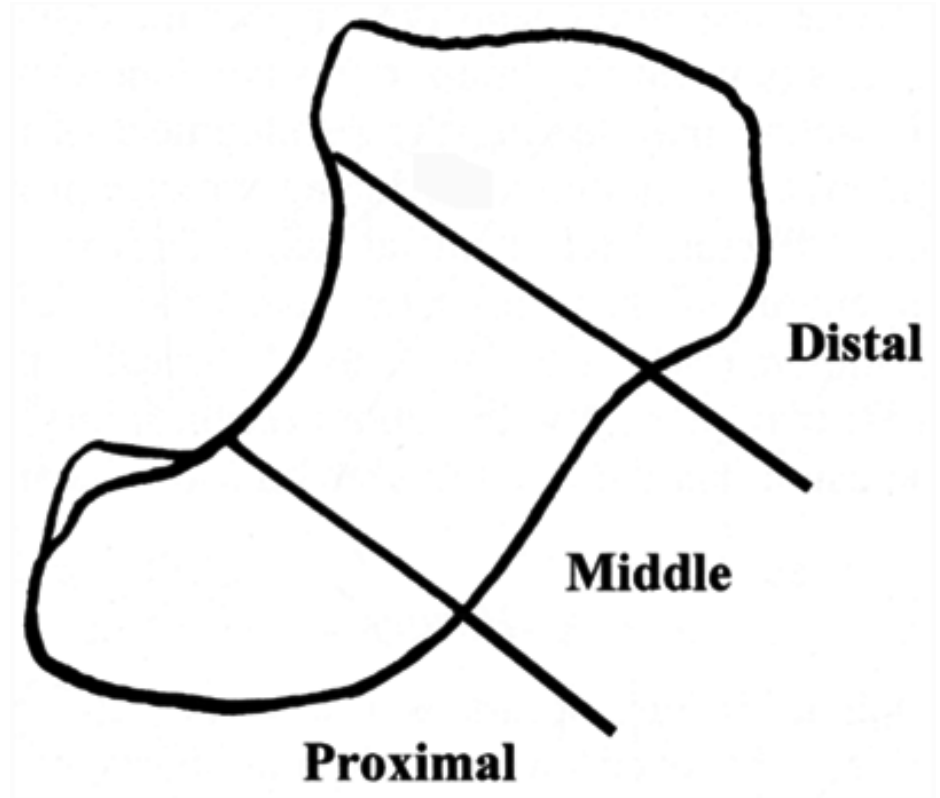
Scaphoid Tubercle Tenderness (Abassi)

Scaphoid Fracture: Imaging

- X-rays
 - AP, Lateral and Scaphoid view
 - If initial films are negative, cast and repeat in 1 week
- Bone scan
 - highest sensitivity and specificity within first 72 hrs.
- MRI
 - Generally preferred exam for occult fractures
 - Highest sensitivity within 1st 24 hrs
 - Useful for several weeks after injury
 - Shows ligamentous damage and vascularity
- CT
 - Ideal for determining fracture displacement
 - Often used for surgical planning or to evaluate healing

Scaphoid Fracture: Imaging

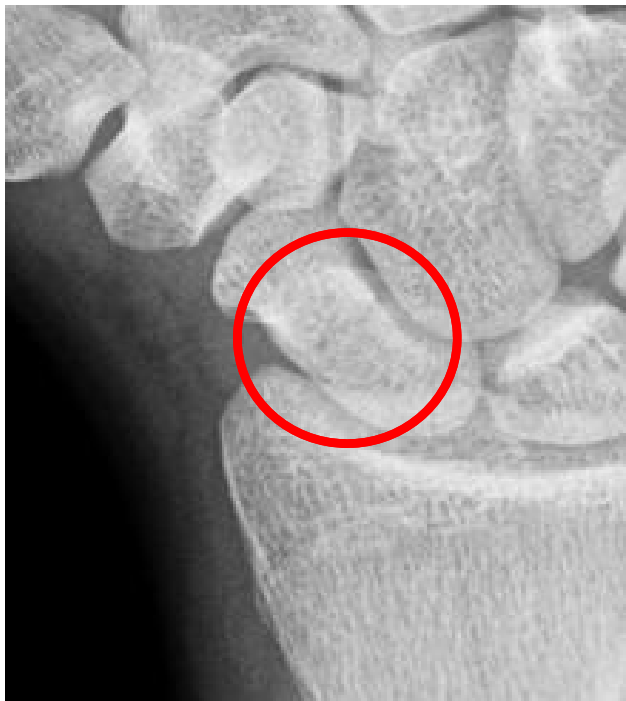- Fxs classified by location
- Most common fx is nondisplaced of the waist (middle)
- Distal fx tend to heal quickly due to blood supply
- Proximal fx have highest rate of non-union



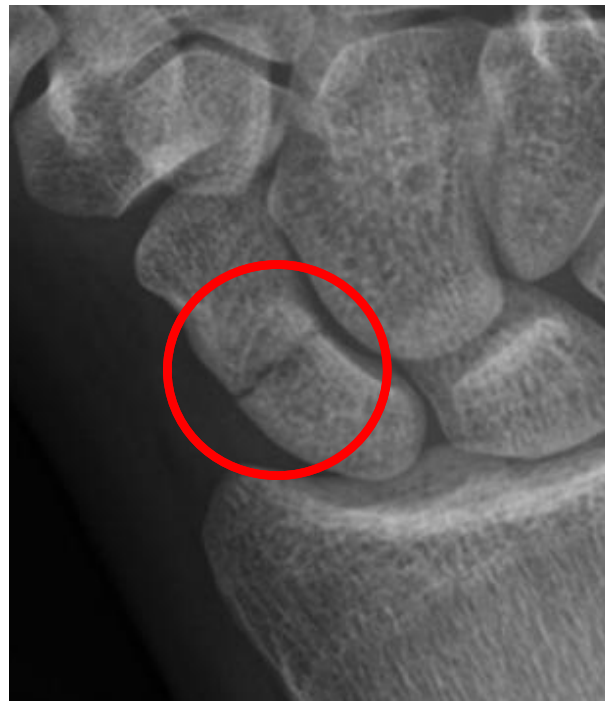(Seiler)

Scaphoid Fracture: Radiographs

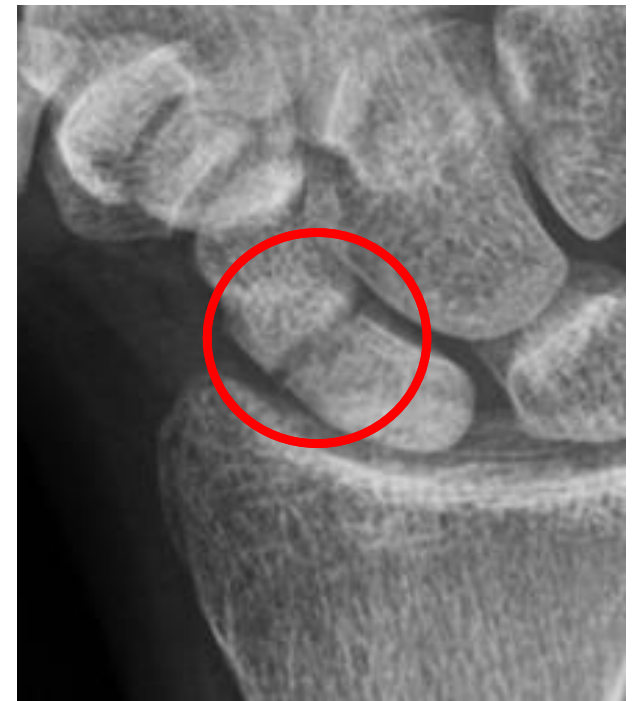Non-Displaced waist fracture—most common pattern



12 hrs post-injury
Slight lucency (Ren)



1 week post-injury
Greater spacing (Ren)

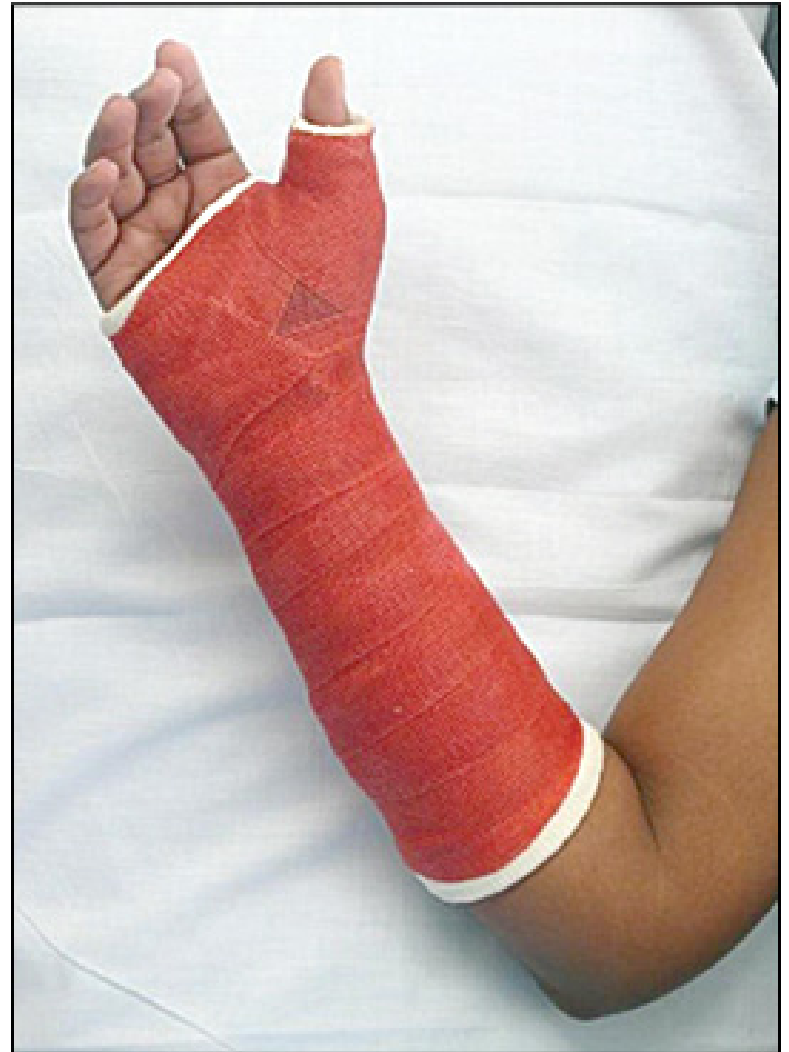

3 months post-injury
Non-Union with greater
lucency (Ren)

Scaphoid Fracture: Classification and Treatment

Non-Displaced Fractures

- Majority of the fractures
- Tx: Thumb Spica or short arm cast until union
- Casting can be prolonged– up to 4-5 months for proximal fractures

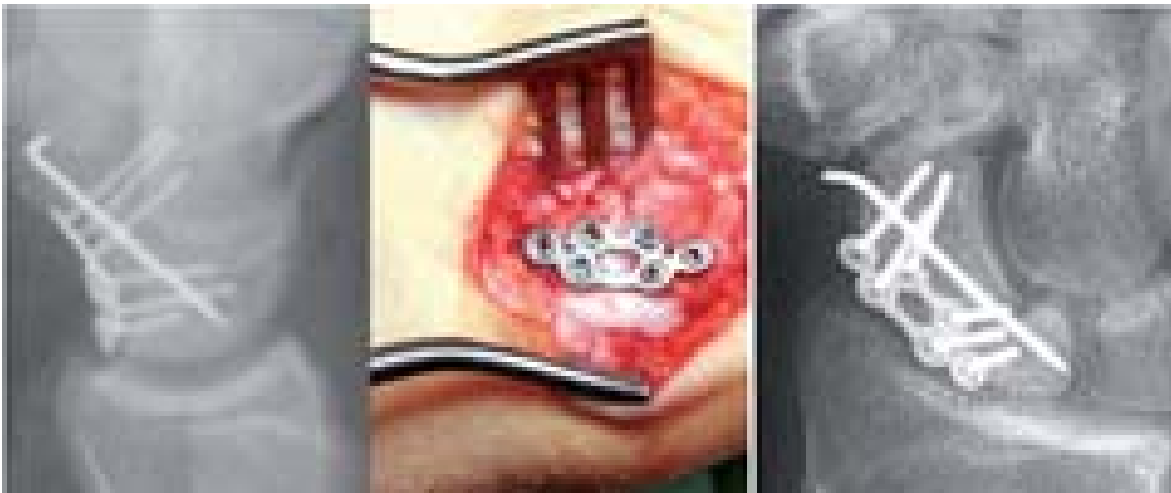


(Boyd)

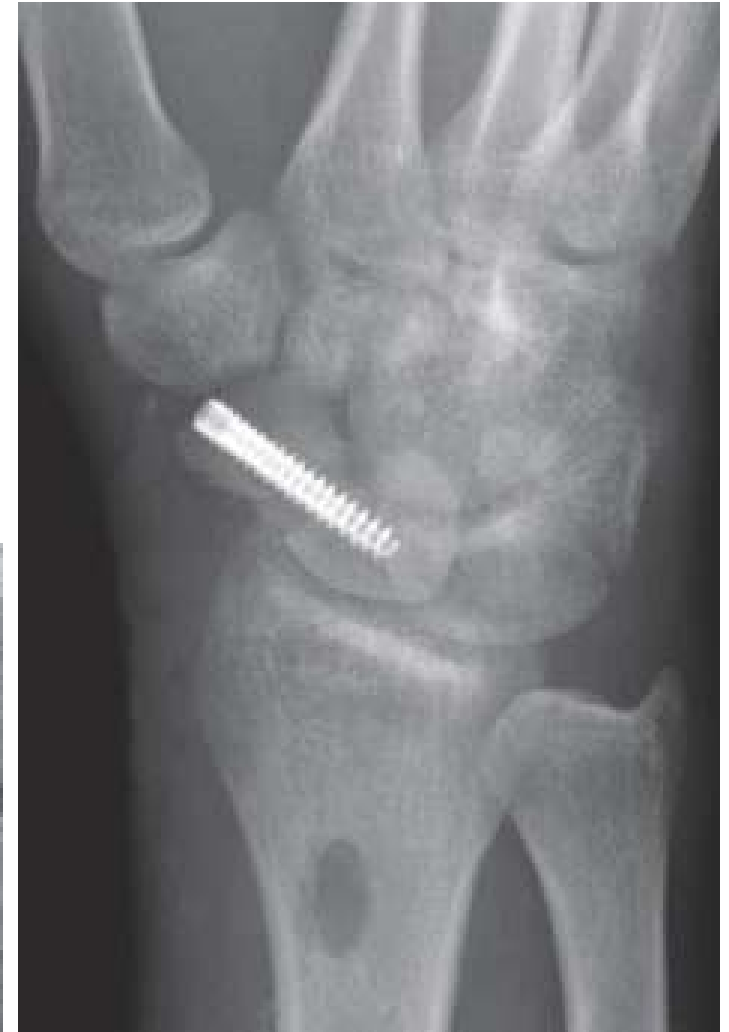Scaphoid Fracture: Surgery

Displaced Fractures

- Indications
 - > 1mm displacement
 - Comminuted
 - Pt preference to liberate from cast
- Generally treated with screw or pin fixation.
 - Cannulated screw most common (right)
- Plates rarely used (below)



Locking Plate (StratMed)



Percutaneous Screw (Boyd)

Works Cited

- "Scaphoid Bone." Wikipedia. Wikimedia Foundation, 24 Mar. 2014. Web. 28 Mar. 2014. <http://en.wikipedia.org/wiki/Scaphoid_bone>.
- Abassi, David. "Scaphoid Fracture." Orthobullets. N.p., 26 Mar. 2014. Web. 27 Mar. 2014. <<http://www.orthobullets.com/hand/6034/scaphoid-fracture>>.
- "Traumatic Injuries to the Hand & Wrist – Info from an AZ Orthopedic." Traumatic Injuries to the Hand & Wrist. FXRX: Orthopedics & Bracing, 26 May 2013. Web. 27 Mar. 2014. <<http://fxrxinc.com/blog/uncategorized/traumatic-injuries-to-the-hand-wrist-info-from-an-az-orthopedic/>>.
- Jones, Oliver. "The Anatomical Snuffbox." TeachMeAnatomy. N.p., 14 Mar. 2014. Web. 27 Mar. 2014. <<http://teachmeanatomy.info/upper-limb/areas/anatomical-snuffbox/>>.
- Seiler, John. "Essentials of Hand Surgery1st Edition." Carpal Fractures. Lippincott Williams & Wilkins, n.d. Web. 28 Mar. 2014. <<http://www.msdlatinamerica.com/ebooks/EssentialsofHandSurgery/sid113232.html>>.
- Ren, Jack. "Scaphoid Fracture." Radiopaedia Blog RSS. Radiopedia.org, n.d. Web. 29 Mar. 2014. <<http://radiopaedia.org/cases/scaphoid-fracture-12>>.
- Boyd, Anne S., Holly BENJAMIN, and Chad ASPLUND. "Splints and Casts: Indications and Methods." American Family Physician. American Academy of Family Physicians, 1 Sept. 2009. Web. 28 Mar. 2014. <<http://www.aafp.org/afp/2009/0901/p491.html>>.
- "Aptus Scaphoid Plate." Stratmed.co.za. N.p., n.d. Web. 28 Mar. 2014. <<http://www.stratmed.co.za/products/upper-extremity/hand/aptus-scaphoid-plate>>.

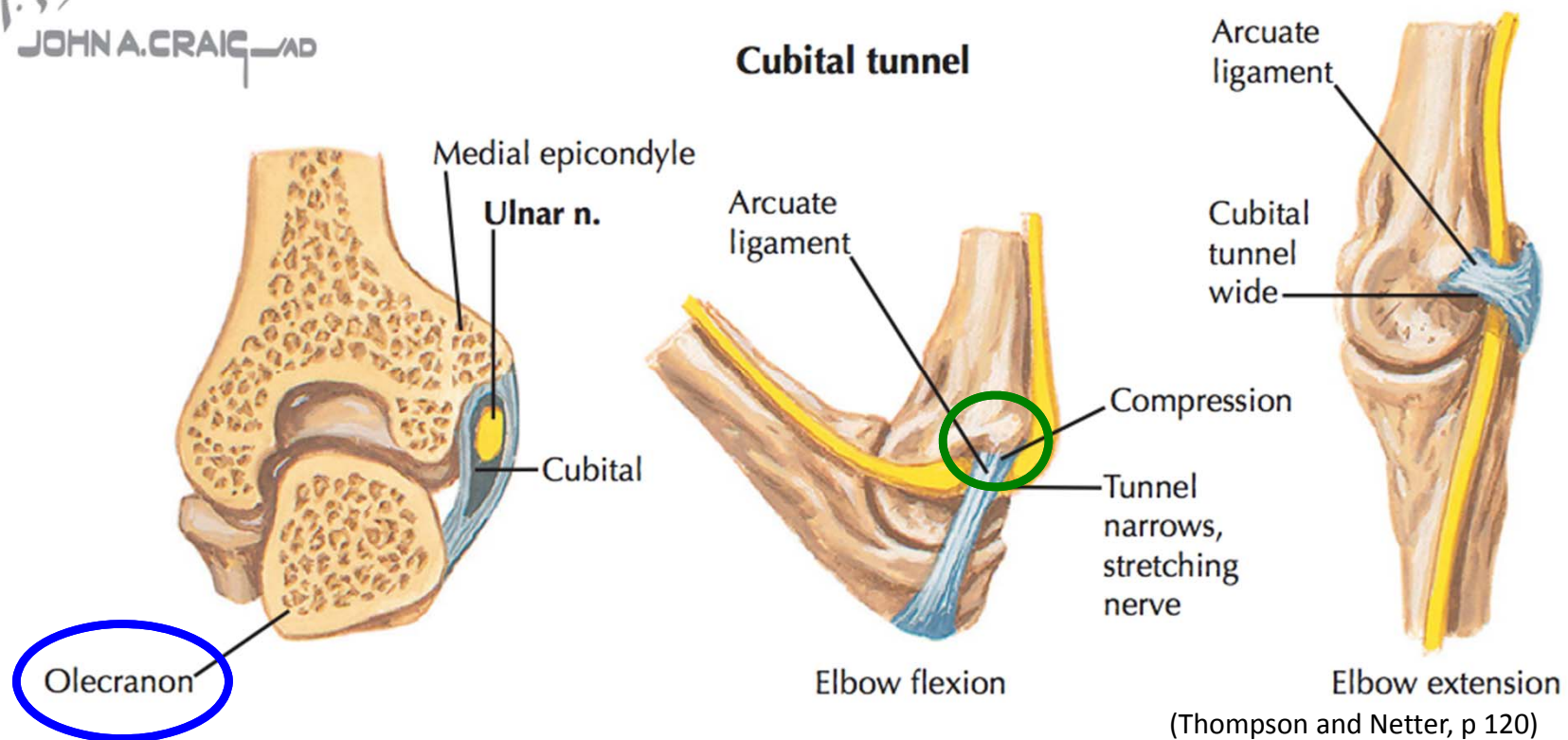
Cubital Tunnel Syndrome

- Anatomy
- Mechanism of Injury and Risk Factors
- Presentation
- Physical Exam
- Treatments

Cubital Tunnel Syndrome: Anatomy

- The ulnar nerve runs through the cubital tunnel at the elbow
- Borders of Cubital Tunnel
 - Medial epicondyle of the humerus (green)
 - Olecranon process of the ulna (blue)
 - Osborn's ligament runs between the medial epicondyle and the olecranon- may compress the ulnar nerve at the elbow

JOHN A. CRAIG, MD



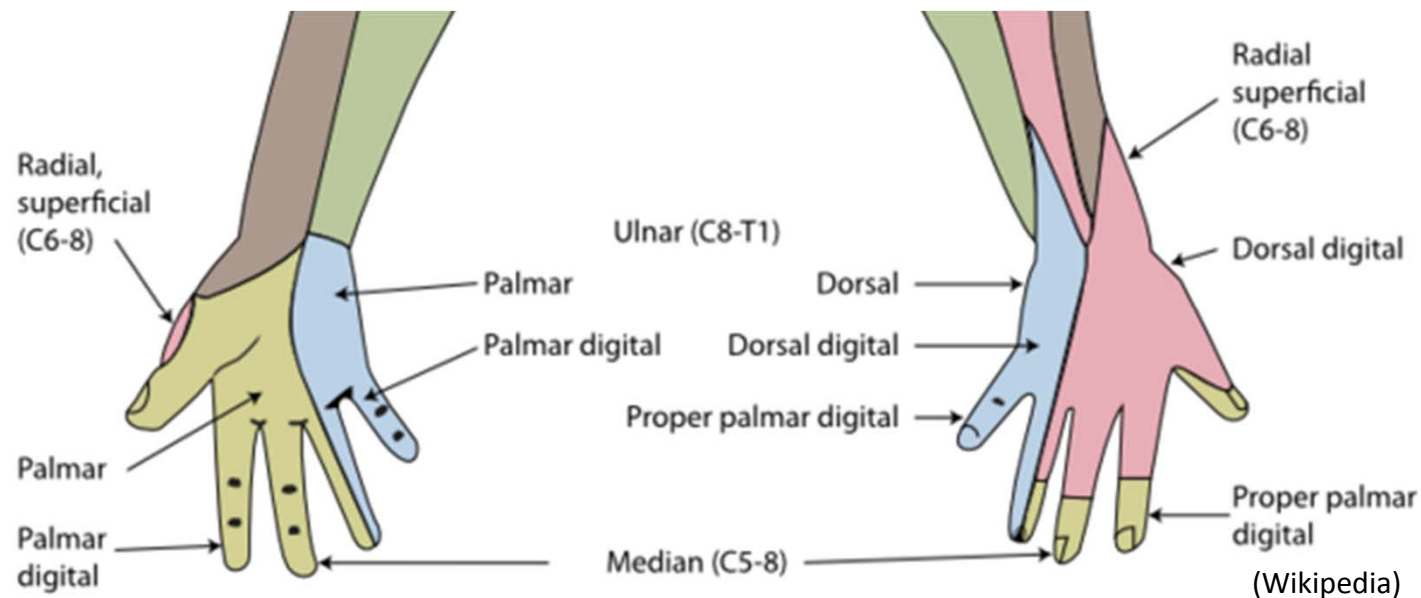
Cubital Tunnel Syndrome: Anatomy

Ulnar nerve

- Sensory to 4th and 5th digits
 - **Palmar digital sensory branches**
 - **Dorsal sensory branch** emerges 5cm proximal to the wrist. Differentiates it from a more distal neuropathy (blue)

Motor

- Flexor carpi ulnaris
- Flex digitorum profundus (4th and 5th digits)
- Hypothenar muscles
- Adductor pollicis



Cubital Tunnel Syndrome

MOI and etiology

- 2nd most common upper extremity compression neuropathy (after CTS)
- Can occur due to nerve rubbing over medial epicondyle during elbow flexion and extension

Risk Factors

- Repetitive elbow motion can exacerbate symptoms
 - Phone talking
- Diabetes
 - Micro-ischemia increases vulnerability
- Congenitally tight tunnel
- History of direct blow

Cubital Tunnel Syndrome: Presentation

- 4th and 5th digit numbness and tingling
 - Including dorsal aspect
- C/O hand clumsiness or dropping things
- Sx worse with elbow flexion
 - Repetitive activities
 - Prolonged positional activities– driving, resting arm on armrest
 - Sleep

Cubital Tunnel Syndrome: Physical Exam

Inspection

- Interosseous atrophy (in severe disease)

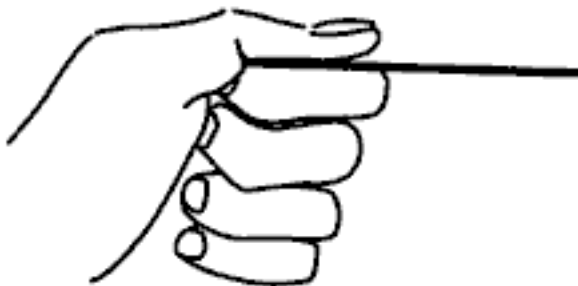Sensory

- Decreased in 4th and 5th digit

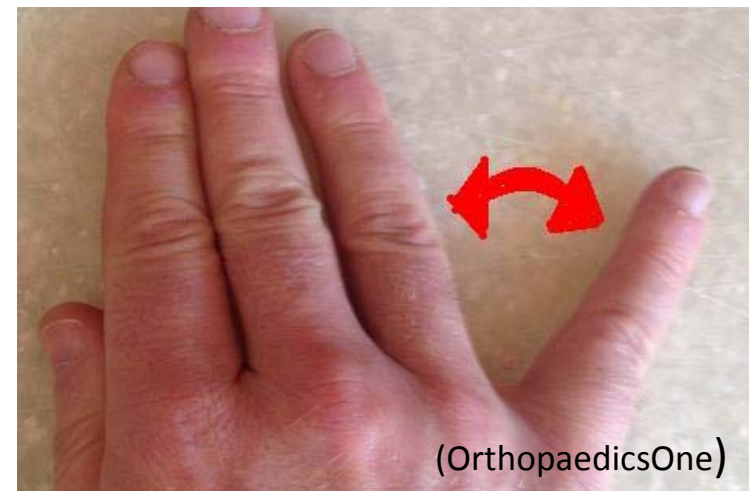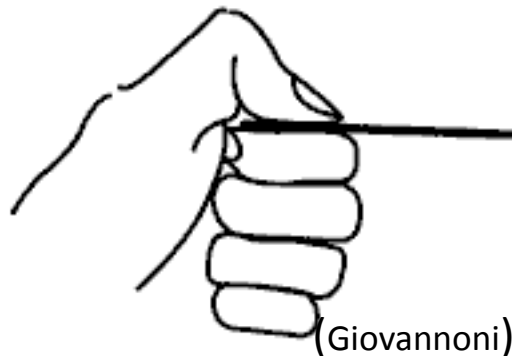Motor

- Weak pinch
- **Froment's sign**-the patient grasps the piece of paper and resists it being removed.
 - With ulnar palsy, weakened adductor pollicis compensated with flexing flexor pollicis longus (FPL)
- **Wartenberg sign**-5th digit abduction during attempted adduction.
 - From weak small finger lumbrical and 3rd palmar interosseous (Allen)
- Cannot cross index and middle fingers (DIO weakness)

Normal



Froment's positive



Wartenberg's Sign

Cubital Tunnel Syndrome: Physical Exam

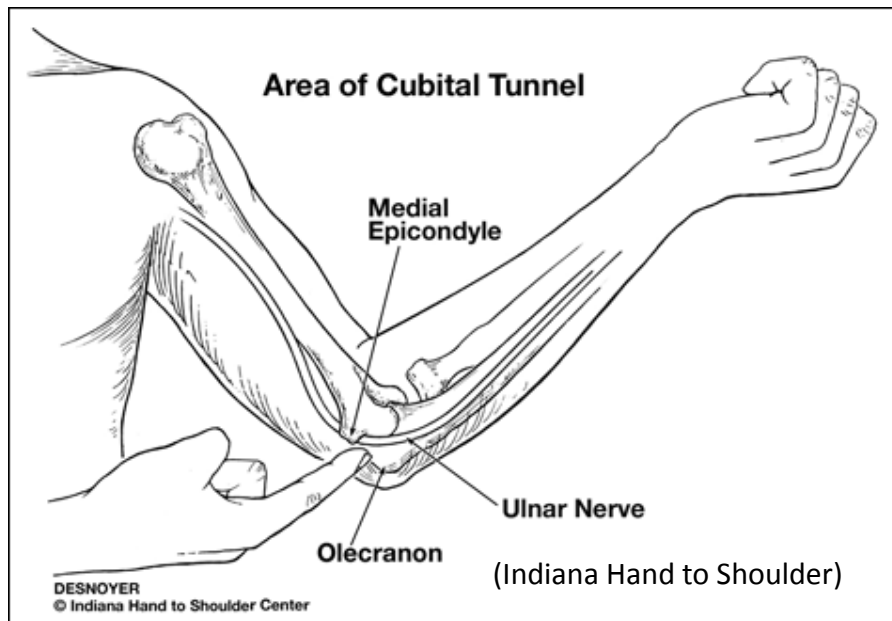
Provocative Tests

– Tinel’s Sign

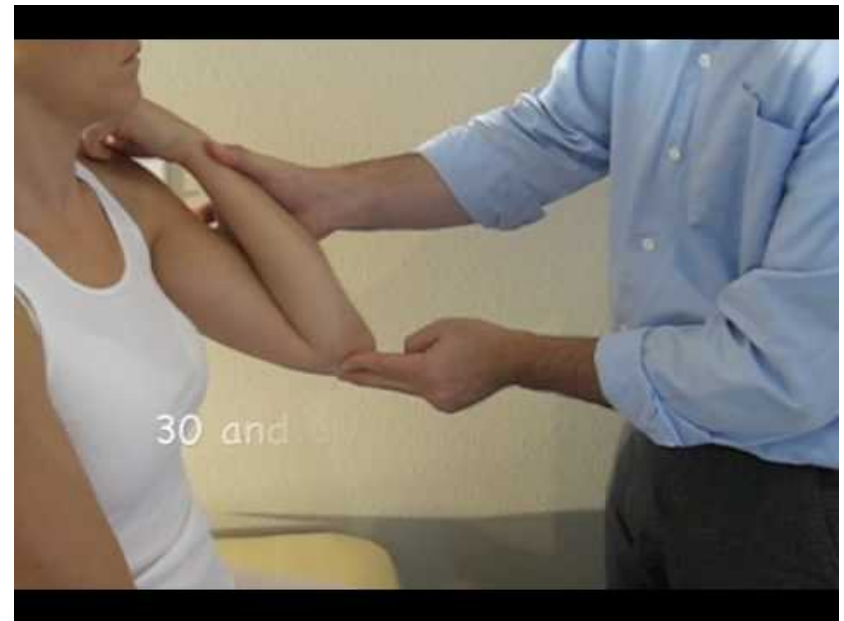
- Lightly tapping posterior to the medial epicondyle over the nerve—highly sensitive (often overly sensitive)

– Elbow flexion Test

- Hold for >60 sec



Tinel’s Sign

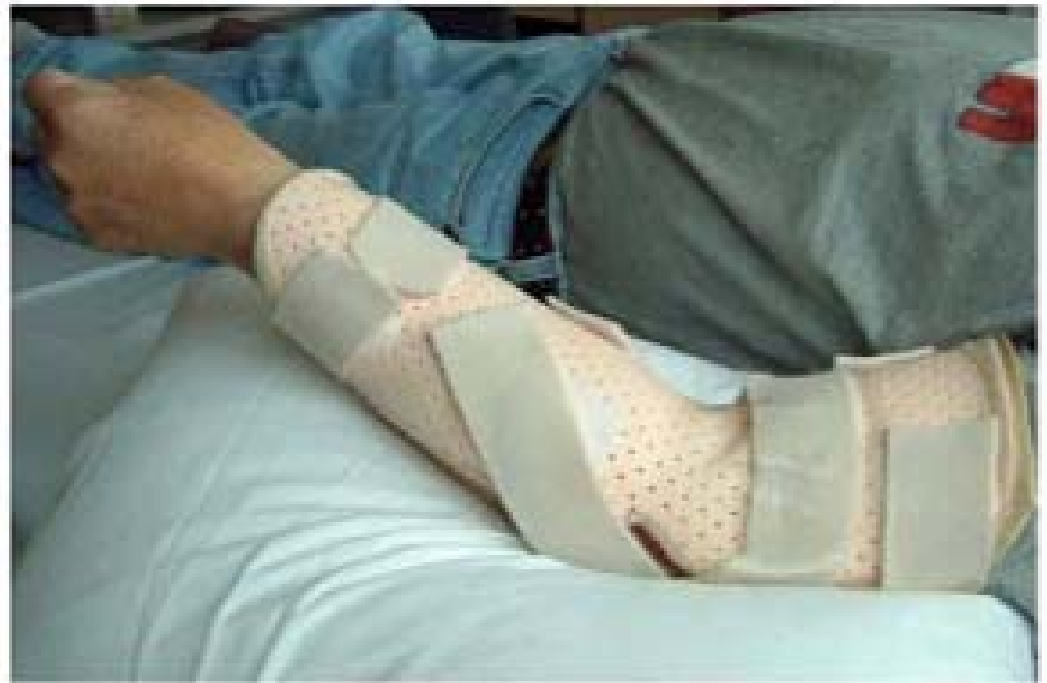

Elbow Flexion Test (CRTechnologies)

Cubital Tunnel Syndrome: Treatment

Non-Operative

- Activity modification
- NSAIDS
- Nighttime elbow extension splinting
 - At 45 degrees in a neutral position

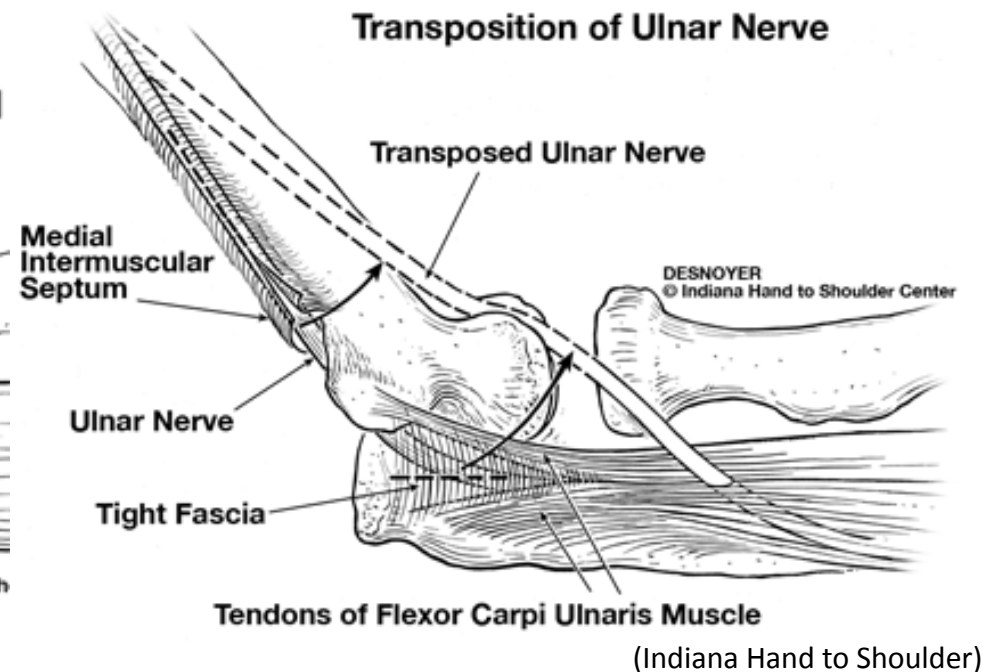
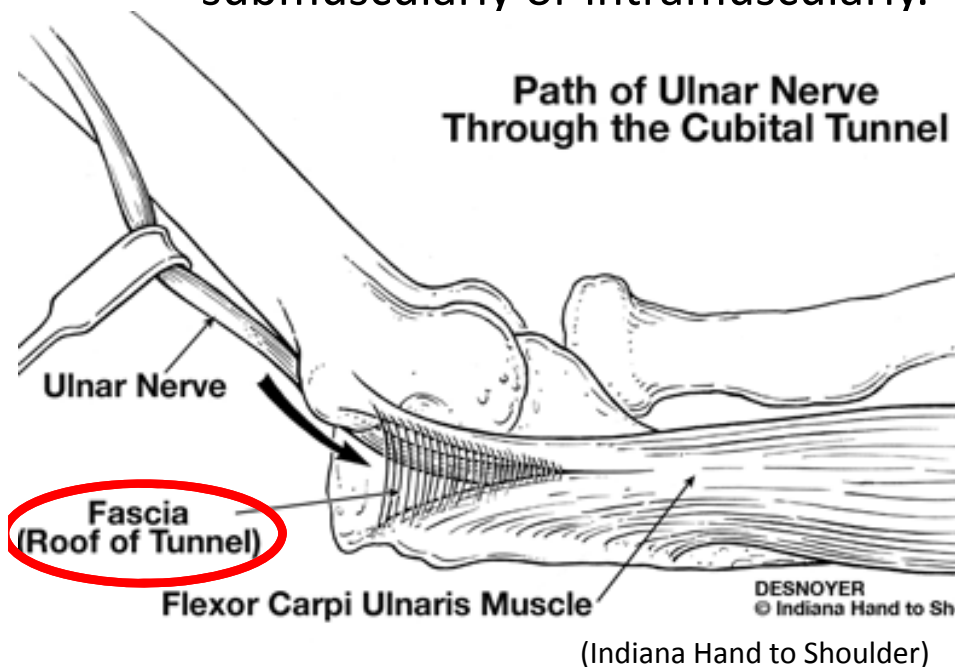


(Hand Therapy Canada)

Cubital Tunnel Syndrome: Treatment

Operative

- Ulnar nerve In-situ Decompression
 - Release cubital tunnel retinaculum (red)
- Ulnar nerve Decompression and with anterior transposition
 - Ulnar nerve is moved anterior in the arm– either subcutaneously, submuscularly or intramuscularly.



Works Cited

- "Ulnar Nerve." Wikipedia. Wikimedia Foundation, 24 Mar. 2014. Web. 29 Mar. 2014. <http://en.wikipedia.org/wiki/Ulnar_nerve>.
- "Compression Neuropathies of the Arm." - Musculoskeletal Medicine for Medical Students - OrthopaedicsOne. N.p., n.d. Web. 29 Mar. 2014. <<http://www.orthopaedicsone.com/display/MSKMed/Compression%2Bneuropathies%2Bof%2Bthe%2Barm>>.
- Giovannoni, Gavin. "Teach Neurology: Froment's Sign." Teach Neurology: Froment's Sign. N.p., n.d. Web. 29 Mar. 2014. <<http://teachneuro.blogspot.com/2012/04/froments-sign.html>>.
- Allen, Deborah. "Cubital Tunnel Syndrome." Orthobullets. N.p., 6 Feb. 2014. Web. 29 Mar. 2014. <<http://www.orthobullets.com/hand/6021/cubital-tunnel-syndrome>>.
- "Cubital Tunnel Syndrome." Indiana Elbow Surgeons. N.p., n.d. Web. 29 Mar. 2014. <http://indianahandtoshoulder.com/medical_education_elbow_cubital.html>.
- CRTechnologies. "Elbow Flexion Test." YouTube. YouTube, 12 Oct. 2009. Web. 29 Mar. 2014. <<https://www.youtube.com/watch?v=gBY1w82J9KI>>.
- "Hand Therapy Canada - The Canadian Hand Therapy Resource." Hand Therapy Canada - The Canadian Hand Therapy Resource. N.p., n.d. Web. 29 Mar. 2014. <<http://www.handtherapy.ca/elbow.php>>.

Low Ulnar Nerve Injury

- Anatomy
- Causes
- Presentation
- Physical Exam
- Testing
- Management

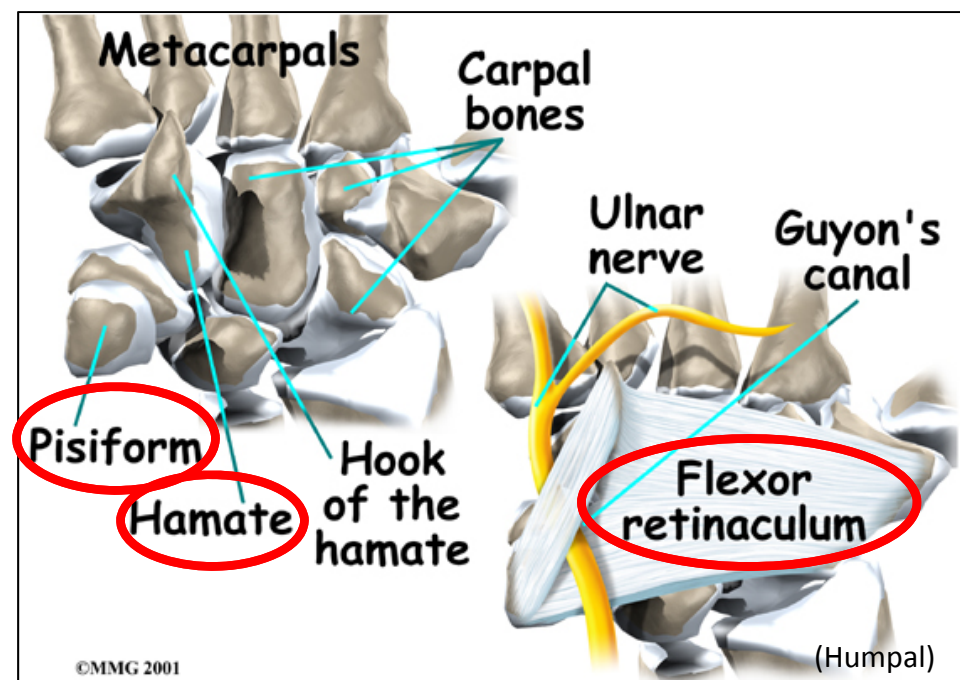
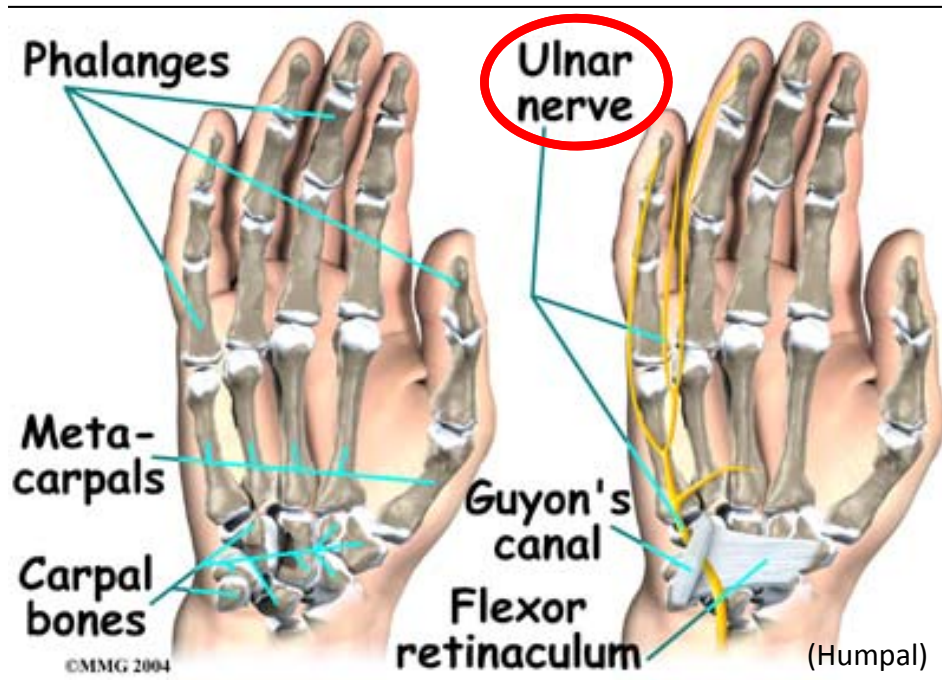
Low Ulnar Nerve Injury or compression:

Anatomy

Guyon's Canal

- Begins at flexor retinaculum
- Between pisiform and hamate
- Contains ulnar nerve and artery— ulnar nerve ulnar in the canal
- Ulnar nerve branches after exiting canal
 - Superficial branch of ulnar nerve—the sensory of **palmar** 4th and 5th digits
 - Deep branch of ulnar nerve-motor branch

Note: The dorsal branch of the ulnar nerve branches about 5 cm proximal to the wrist, so individuals with low ulnar injury will not have dorsal sensory complaints



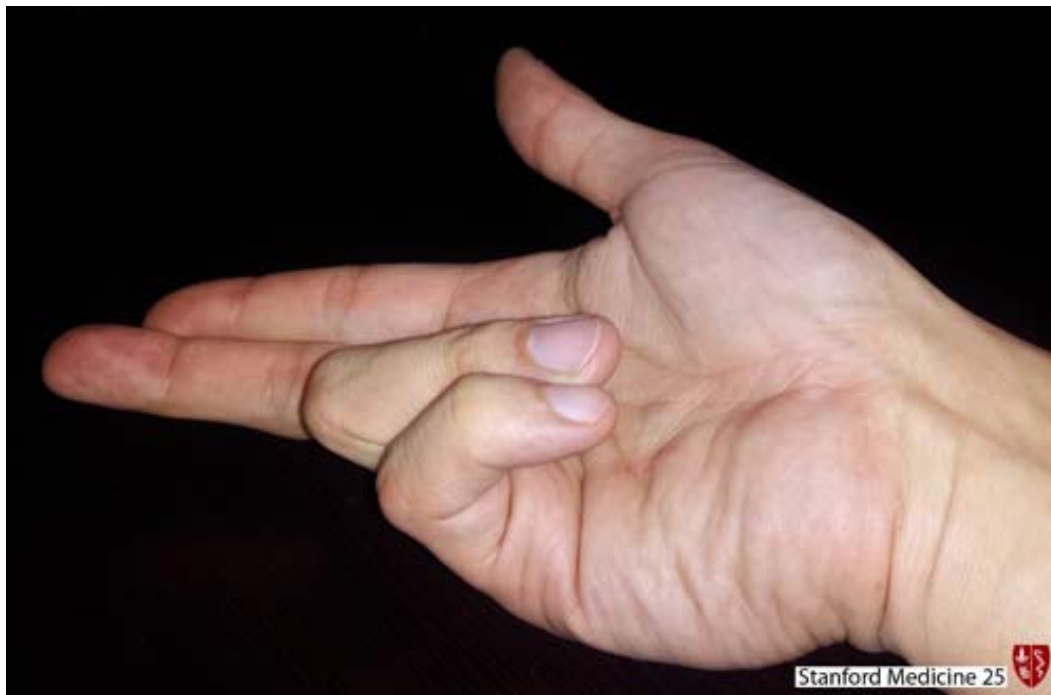Low Ulnar Nerve Injury: Causes

- Compression to Guyon's canal
 - Ganglion cyst
 - Cycling (handlebar palsy)
 - Repetitive Tasks
- Diabetic neuropathy
- Knife stab or gunshot wound

Low Ulnar Nerve Injury: Presentation

- Hand Wasting
- 4th and 5th digit palmar numbness
- 4th and 5th digit curling (ulnar claw) when trying to extend fingers
 - Shows Hyperextension at MCP and flexed at IP joint
 - From loss of lumbricals

Note: There is also loss of lumbrical fx in cubital tunnel (CTS), however the ulnar claw is not as pronounced in CTS, because there is also loss of flexor digitorum profundus to the 4th and 5th digits, decreasing IP joint flexion.



Low Ulnar Nerve Injury: Physical Exam

Similar to Cubital Tunnel Syndrome (see slide 59)

- Positive Froment's Sign
- Positive Wartenberg's Sign
- Weakness or inability to cross index and long finger
- Tinel's may be positive at the site of compression or injury

Differs from CTS in that

- Sensation intact on dorsal aspect of 4th and 5th
- Negative Tinel's sign at the elbow
- Negative Elbow Flexion Test

Low Ulnar Nerve Injury: Testing

Radiographs and X-rays

- Useful to examine hamate fracture, which can cause ulnar nerve compression if displaced

MRI

- Typically used in the workup of atraumatic ulnar nerve palsy
 - May show space occupying lesion (ganglion cysts) compressing the nerve

Nerve Conduction Test and Electromyogram

- Useful to objectively demonstrate neuropathy

Low Ulnar Nerve Injury: Management

Non-Operative

- Activity modification
- NSAIDS
- Wrist brace

Operative

- Decompression of Flexor Retinaculum—if compression occurs at Guyon's Canal
- Tendon Transfers—if nerve has poor recovery
 - Improves pinch strength
 - Ameliorates the claw hand

Works Cited

- "Guyon's Canal Syndrome." Humpal: Physical Therapy and Sports Medicine Center, n.d. Web. 30 Mar. 2014.
<<http://www.humpalphysicaltherapy.com/Injuries-Conditions/Hand/Hand-Issues/Guyon-s-Canal-Syndrome/a~286/article.html>>.
- "#19 The Hand in Diagnosis." The Hand in Diagnosis. Stanford School Of Medicine, n.d. Web. 31 Mar. 2014.
<<http://stanfordmedicine25.stanford.edu/the25/hand.html>>.