

Hepatoprotective and hepatocurative effects of *Spilanthes acmella* Murr against paracetamol induced hepatotoxicity

Syed Nisar Hussain Shah¹, Asma Mumtaz^{1,2} Muhammad Zabta Chaudary²,
Nauman Bashir³, Muhammad Mazhar Ayaz⁴, Faheem Ahmad Siddique⁵ and Khizar Abbas^{1*}

¹Faculty of Pharmacy, Bahauddin Zakariya University, Multan, Pakistan

²Multan Medical and Dental College, Multan, Pakistan

³SNS Pharmaceutical Laboratory, Multan, Pakistan

⁴Department of Pathobiology, Faculty of Veterinary Sciences, Bahauddin Zakariya University, Multan, Pakistan

⁵Faculty of Pharmacy, University of Central Punjab, Lahore, Pakistan

Abstract: Hepatotoxicity is appreciably escalating health dilemma worldwide and the degree of the problem has encouraged importance in the exploration for hepatotherapeutic agents from plants. In the current research work, the hepatoprotective/hepatocurative activity of methanolic extract of *Spilanthes acmella* Murr aerial parts in paracetamol induced hepatotoxicity was investigated in rabbits by the analysis of different liver enzymes including ALT, AST, ALP along with histopathological investigations. In first phase of the study, paracetamol toxicated rabbits were treated with extract and standard drug jateparTM. The hepatotoxicant (paracetamol) significantly increased the levels of aspartate transaminase, alanine transaminase, alkaline phosphatase compared to normal control. *Spilanthes acmella* Murr at (400 mg/kg) reversed the elevation in the level of ALP, AST and ALT caused by the hepatotoxicants and jatepar^R TM (standard) also reversed the deleterious effects of the hepatotoxicants. In second phase of this study, extract of *Spilanthes acmella* Murr was given to rabbits for ten days then paracetamol was administered in one group and level of liver parameters was paralleled with regular control group and the group that was receiving the extract. It is concluded that methanolic extract of *Spilanthes acmella* Murr aerial parts possesses hepatocurative and hepatoprotective activity.

Keywords: *Spilanthes acmella*, hepatocurative, hepatoprotective, hepatotoxic.

INTRODUCTION

Liver is the main body structure that plays an imperative function in metabolism, detoxification, biotransformation, excretion and provide protection from noxious by-products of metabolisms and endotoxins (Abbas *et al.*, 2016) but liver problems are considered as the most serious diseases and classified as acute or chronic hepatitis, hepatosis and cirrhosis (Kumar *et al.*, 2012). The dysfunction and liver injury is mainly caused by chemicals, certain drugs, microbes, prolonged alcohol consumption, auto immune diseases and environmental pollutants by lipid peroxidation and oxidative damage (Abbas *et al.*, 2016). Liver injury caused by the drugs is responsible for 50% cases of acute failure of liver and 5% of all cases that are admitted to the hospital (Rao, 2012). The severity of liver damage is measured by the performance of live enzymes alanine aminotransferase, alkaline phosphatase and aspartate aminotransferase concentration of serum bilirubin and histological studies (Abbas *et al.*, 2016). Medicinal plants comprises of different groups of easily available and exceedingly valuable resource of bioactive metabolites like flavonoids, alkaloids, tannins and essential oils (Rao *et al.*, 2012, Prachayasittikul *et al.*, 2008) which are used in medicinal practices since long time (Tiwari *et al.*, 2011). Due to

therapeutic efficiency and freely availability, medicinal plants are used as available source of alternative medicine in several ailments and conditions (Demarne and Passaro 2009, Abbas *et al.*, 2016). There is need of detailed examination of many medicinal plants for their pharmacological and therapeutic value.

Spilanthes acmella Murr. belong to family asteraceae known as akarkara in local language is a widely distributed perennial herb used to treat hemorrhoids, stomatitis, rheumatism, gum infections, tongue paralysis, sore throat, asthma inflammation, fever, headache, mouth ailments, locally against itching and psoriasis, have analgesic, larvicidal, immunomodulatory, antiseptic, antioxidant, sialagogue, antibacterial, stimulant, cytotoxic, diuretic, insecticidal, potential vasodilator, local anaesthetic property and is constituent of beauty care cosmetics (Singh and Chaturvedi 2012, Barbas *et al.*, 2016, Ratnasooriya *et al.*, 2004, Sharma *et al.*, 2011) contain alkaloids, amino acids and N-isobutylamides (spilanthol, undeca-2E-en-8,10-diynoic acid isobutylamide and undeca-2E,7Z, 9E-trienoic acid isobutylamide) (Ratnasooriya *et al.*, 2004). The aim of this study is to find out the hepatoprotective and hepatocurative effect of *Spilanthes acmella* Murr with the support of histo-pathological investigations.

*Corresponding author: e-mail: khizarabbas@bzu.edu.pk

MATERIALS AND METHODS

Collection, identification and extraction of plant material

Aerial part of *Spilanthes acmella* Murr was purchased from herbal store of the local market and was identified by a taxonomist from the Institute of Pure and Applied Biology, Bahauddin Zakariya University, Multan with voucher specimen no 1214/BZU/15. The plant material was purified from adulterated material and soil, dried in shade at temperature of 40°C and then grinded into coarse powder and passes through sieve 40. The powdered material was soaked into methanol for seven days at room temperature with occasional shaking then filtered and dried in rotary evaporator (Rota-vapor Buchii, Japan) under reduced pressure at 45°C with pressure of 0.07 MPA and rotation of 3.0 rpm to thick paste. Dried extract of plant was transferred in air tight container and preserved in biomedical freezer (Sanyo biomedical freezer, MDF-U333, Japan).

Chemicals

Paracetamol was gifted by Askari Pharmaceuticals (Lahore, Pakistan), Jatepar™ (100 ml syrup contain Betaine Glucuronate 3.75 g, Diethanolamine Glucuronate 1.00 g, Nicotinamide Ascorbate 0.50g) was obtained from Popular Chemical Works (Pvt.) Ltd. All other chemicals and glass ware used were of sigma company and was purchased from local agent.

Phyto-chemical screening

The methanolic extract of aerial parts of *Spilanthes acmella* Murr was subjected to qualitative test of alkaloid, tannins, flavonoids, saponin and anthraquinone glycoside using standard procedures to identify various constituents as described by Abbas *et al.* (2015).

Animals

Rabbits of local breed (*Oryctolagus cuniculus*) were purchased from University of Agriculture Faisalabad, of either sex having the age of 2-3 months and weight of 1-1.5 ± 0.05 Kg were used. All animals were kept in stainless steel cages at the animal house of Department of Pharmacy, Bahauddin Zakariya University, Multan under standard laboratory conditions [under 12-hr constant dark and light cycle at temperature (21–23°C) with relative humidity (35–60%)]. Green fodder and water were freely available at laboratory. These animals were used in experiment after one week acclimation with the available facilities. The experimental protocol was approved by Institutional Animal Ethics Committee of Faculty of Pharmacy, B.Z. University Multan vide letter No Pharm/12/1908/2017.

Hepatocurative studies

Hepatocurative activity of methanolic extract of aerial parts of *Spilanthes acmella* Murr was tested using the standard protocol with some modifications. In this study, total 24 rabbits were divided into four groups each having

six animals. On first day the liver parameters of all groups were measured then three groups were intoxicated with paracetamol at the dose of 1.5g/kg/oral route of body weight and one group were kept as normal control. After 72 hours the liver parameter of all groups were measured. Then group three were treated with extract at the dose of 400mg/kg/oral route and group four was treated with standard drug jatepar™ at the dose of 2.0 ml/kg of body weight. Blood samples for the liver parameters were collected on zero, 3rd, 6th and 13th days (Zahra *et al.*, 2012).

Hepatoprotective effect

Hepatoprotective effect of plant extract was carried out by using the standard protocol with few modifications. Total of 18 rabbits were divided in three groups. Group one was considered as normal control. Group two and three was considered as treated group receiving the extract at the dose of 400mg/ kg/oral of body weight for ten days. On eleventh day group third was treated with paracetamol with the dose of 1.5 g/kg/oral of body weight and group two was given extract at the dose of 400 mg/kg/oral for next six days. The blood sampling was carried out at the 0, 11, 13 and 19 days for the ALP, ALT and AST (Zahra *et al.*, 2012).

Histo-pathological study

At the end of 13th and 19th day for hepatocurative and hepatoprotective effect respectively the animal was sacrificed under chloroform anesthesia, liver was isolated, washed with normal saline and preserved in 10% solution of formalin. Then slides were made by using the standard protocol and were observed under microscope for the changes in the histology of liver (Luna, 1968).

Sample collection

Blood samples were taken at zero, 3rd, 6th and 13th in the case of hepatocurative and at 0, 11th, 13th and 19th day in the case of hepatoprotective study to determine the serum levels of Serum glutamic oxalo-acetic acid transaminase (AST), serum glutamic pyruvic transaminase (ALT) and alkaline phosphatase (ALP) levels with the help of enzymatic kits (Sigma Co) by using Spectrophotometer (Perkin Elmer UV 256) as these are major biochemical markers of hepatic status.

STATISTICAL ANALYSIS

One-way analysis of variance (ANOVA) followed by turkey test was used for the statistical analysis of experimental data. The value of P<0.05 is considered as significant.

RESULTS

The results of preliminary phytochemical analysis are shown in table 1 which shows the presence of alkaloid, glycoside, flavonoids and tannins. Fig.1 indicate that AST

Table 1: Preliminary phytochemical screening of aerial part of *Spilanthes acmella*

Sr. No	Phyto-constituent	Result
1.	Alkaloids	+++
2.	Anthraquinone glycoside	++
3.	Saponin glycoside	+
4.	Flavonoids	+++
5.	Tannins	++

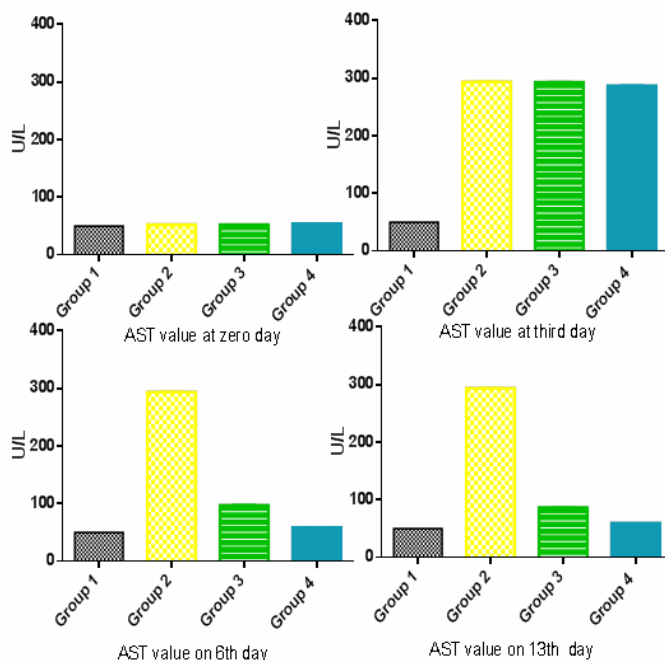


Fig. 1: Hepatocurative effect of *Spilanthes acmella* Murr on AST value on different days

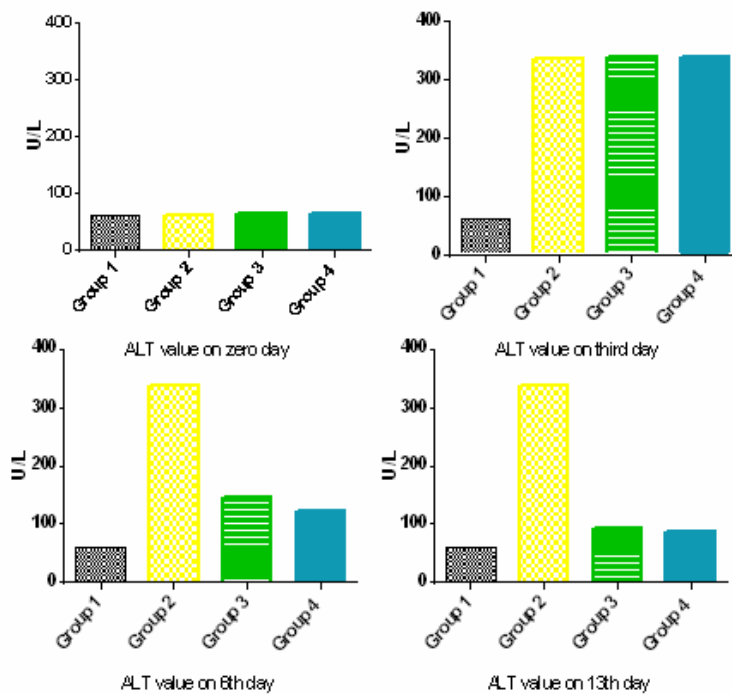


Fig. 2: Hepatocurative effect of *Spilanthes acmella* Murr on ALT value on different days

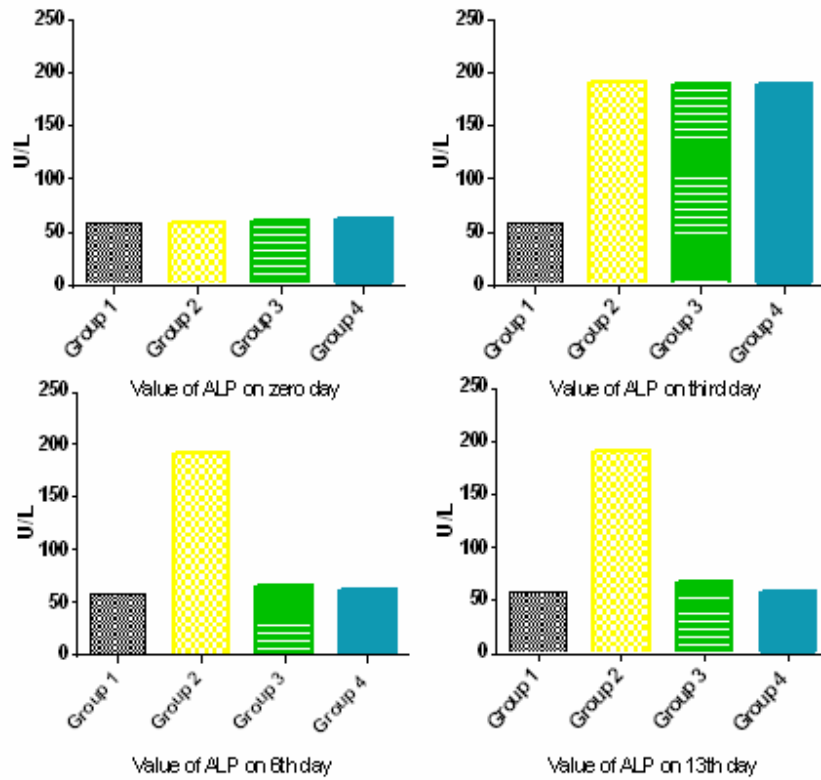


Fig. 3: Hepatocurative effect of *Spilanthes acmella* Murr on ALP value on different days

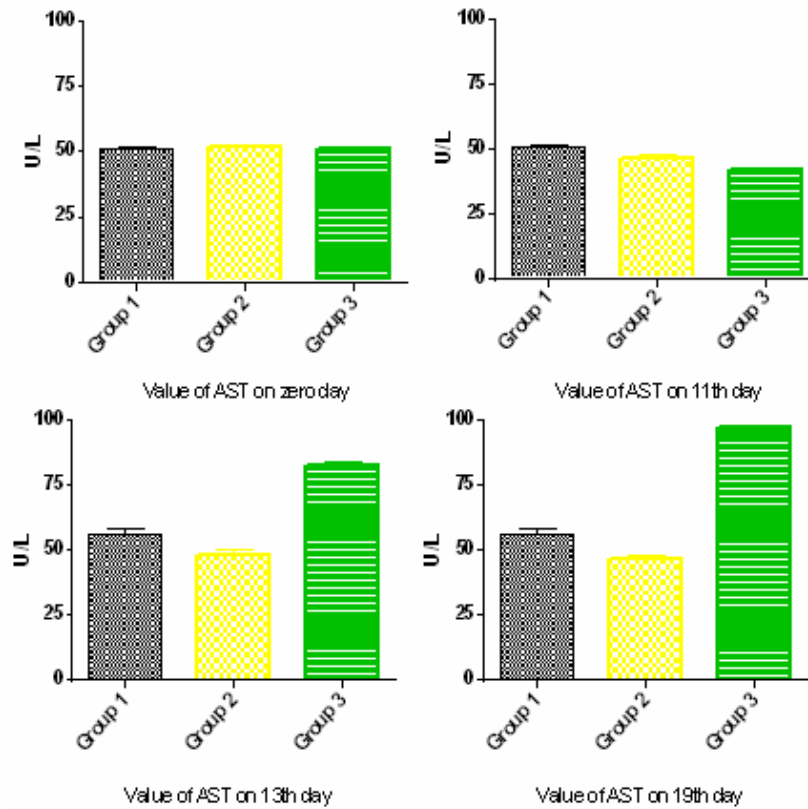


Fig. 4: Hepatoprotective effect of *Spilanthes acmella* Murr on AST value on different days

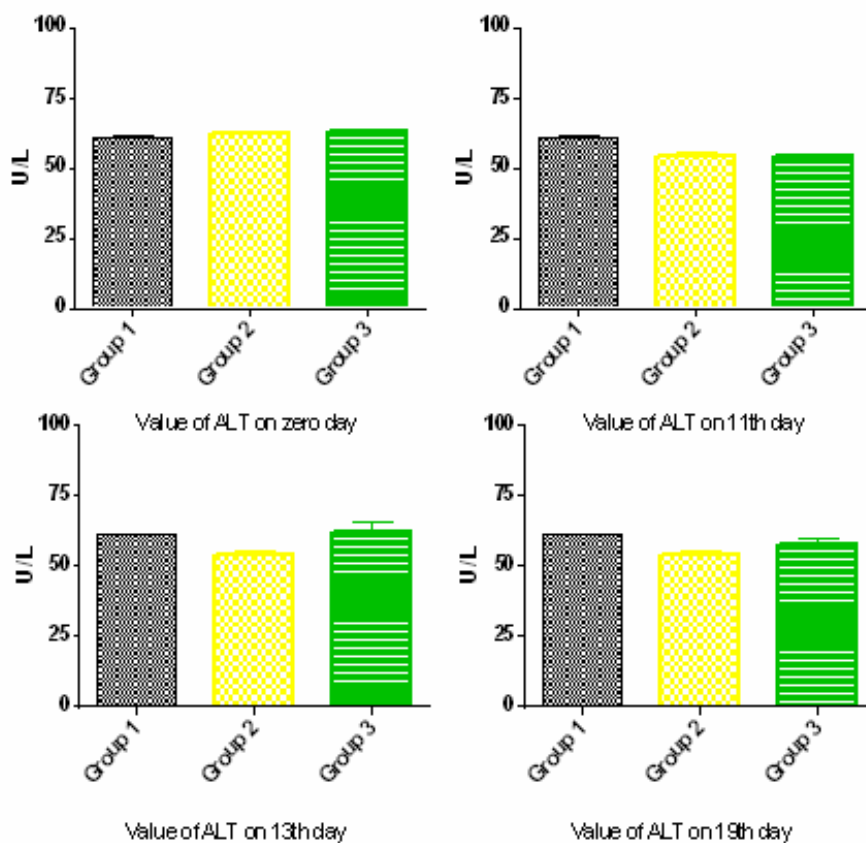


Fig. 5: Hepatoprotective effect of *Spilanthes acmella* Murr on ALT value on different days

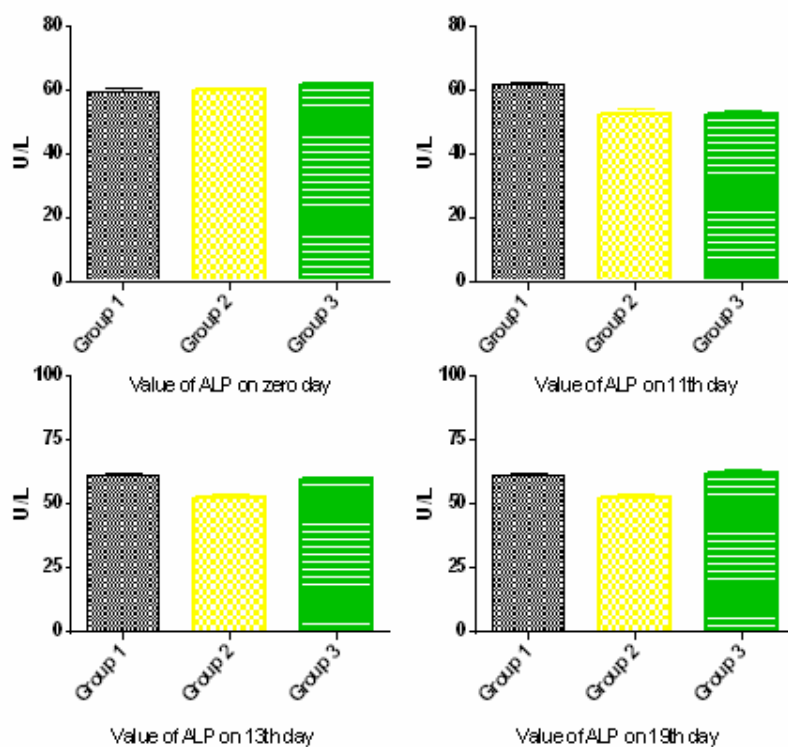


Fig. 6: Hepatoprotective effect of *Spilanthes acmella* Murr on ALP value on different days

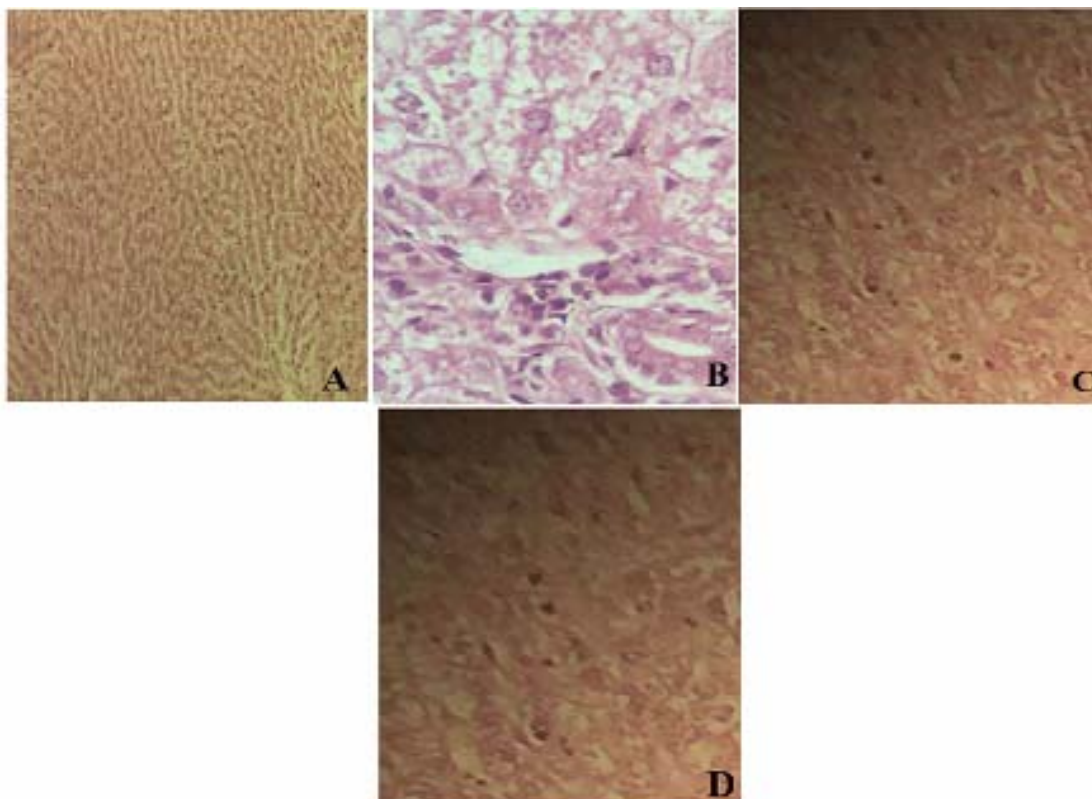


Fig. 7: Microphotograph showing the histopathology of liver (a) Normal control (b) Hepato-toxic control, (c) Hepatotoxic animal treated with extract at 400mg/kg body weight (d) Hepatotoxic animal treated with jatepar (x 100)

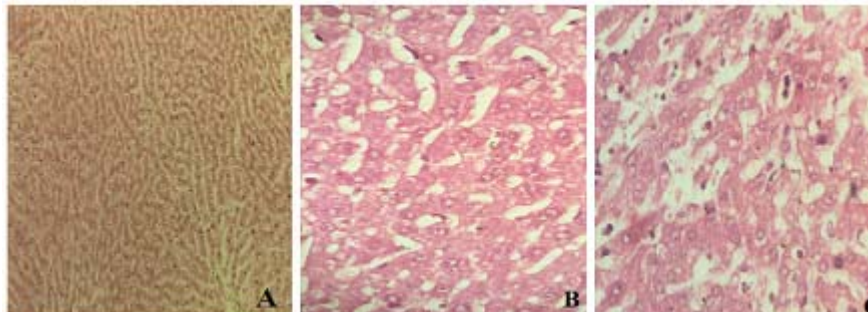


Fig. 8: Microphotograph showing the histopathology of liver (a) Normal control (b) Extract treated animal was treated with paracetamol (c) Hepatotoxic treated (magnification x 100)

level at zero day was normal while on third day level of AST in intoxicated groups was increased, on 6th day level of AST in treated groups decreases and on 13th day treated groups with standard drug and extract shows decreased level of AST. Fig. 2 and 3 shows the Hepatocurative effect of *Spilanthes acmella* Murr on, ALT and ALP value on different days in similar manner as was observed in the case of AST level respectively. Similarly, fig. 4 shows AST level which indicate that level of AST was normal at zero day which decreases to 10th day upon treatment, then the level increases in intoxicated group on 13th day and on 19th day. Figs. 5 and 6 show Hepatoprotective effect of *Spilanthes acmella* Murr on, ALT and ALP value on different days in similar pattern as was observed in the case of AST level. Fig. 7 shows the histopathology of liver in case of hepatocurative that

indicate the hepatocurative effect while fig. 8 shows the histopathology of liver in the case of hepatoprotective investigations that represent the hepatoprotective effect.

DISCUSSION

Exposure to physio pathological agents leads to disease condition. Liver is the major organ for drugs, chemicals and xenobiotics toxicity and high dose of these hepatotoxin leads to acute liver injury that is characterized by abnormal liver function, degeneration and necrosis of hepatocytes due to these reasons liver diseases considered as major cause of mortality and morbidity. This leads to increase in the interest in search of hepatocurative and hepatoprotective agents from natural sources that serves as important source for more effective and superior

tolerated drugs (Obogwu *et al.*, 2014). Paracetamol induced hepatotoxicity is used screening method for testing the hepatoprotective nature of the plants. The hepatic damage leads to the increased production of serum level of enzymes in blood stream such as ALP, ALT and AST was associated with central or submissive necrosis of liver leads to cellular damage and functional integrity of cell membrane in liver (Kiran *et al.*, 2012). In the present study AST, ALT and ALP levels decreased significantly in rabbits treated with methanolic extract of *Spilanthus acmella* Murr (400 mg/kg b.w.) in comparison with the toxic group. Necrosis in hepatic cells causes the increased levels of blood serum ALP, AST and ALT that enters into circulation from liver which was which was also observed in the Acetaminophen intoxicated group two rabbits in the case of hepatocurative effect. This high level of serum marker enzymes is the indication of loss of functional integrity of cell membrane and cellular leakage. In the present study, treatment with aerial parts methanolic extract of *Spilanthus acmella* Murr (400 mg/kg b.w.) decreased the increased serum level of AST, ALP ALT towards the respective normal value indicating that the plant extract has stabilized the plasma membrane as well as helped in curing the damaged hepatic tissue.

The ability of a hepatoprotective drug to decrease the injurious possessions or to conserve the ordinary hepatic physiological mechanisms, which have been disturbed by a hepatotoxin, is the key of its protective effects. Further, the associated administration of *Spilanthus acmella* Murr (400mg/kg b.w.) along with the administration of hepatotoxin drug decreases and kept the normal level of liver serum enzymes is the indication of hepatoprotective effect. the administration of *Spilanthus acemella* (400mg/kg) with hepatotoxic drug kept the liver enzyme level up to the normal level that is the indication of his hepatoprotective ability (Effiong *et al.*, 2013). Phytochemical screening of methanolic extract of *Spilanthus acmella* Murr revealed the presence of alkaloids, anthraquinone glycoside, saponin glycoside, flavonoids and tannins and these phytochemicals contribute the hepatoprotective and hepatocurative effect of *Spilanthus acmella* Murr. Hence it was concluded from this study that methanolic extract of *Spilanthus acmella* Murr possess the hepatocurative and hepatoprotective effect in paracetamol induced hepatotoxicity. the novelty of this research work is that aerial part hepatoprotective and hepatocurative effect was find out for the first time on the methanolic extract of *Spilanthus acmella* Murr.

CONCLUSION

These experimental findings confirmed the hepatocurative and hepatoprotective effect of *Spilanthus acmella* Murr which may be due the presence of alkaloids, flavonoids and tannins that are present in methanolic extract of aerial part of the plant.

REFERENCES

- Abbas K, Rizwani GH, Zahid H and Javed TM (2016). Evaluation of Hepatic activity of various morphological parts of *Musa paradisiaca* L. *Afr. J. Pharm. Pharmacol.*, **10**: 419-429.
- Barbas LAL, Stringhetta GR, De Oliveira Garcia L, Figueiredo MRC and Sampaio LA (2016). Jambu, *Spilanthus acmella* as a novel anaesthetic for juvenile tambaqui, *Colossoma macropomum*: Secondary stress responses during recovery. *Aquaculture*, **456**: 70-75.
- Demarne F and Passaro G (2009). Use of an *Acemella oleracea* extract for the botulinum toxin-like effect thereof in an anti-wrinkle cosmetic composition. Google Patents.
- Effiong G, Udoh I, Udo N, Asuquo E, Wilson L, Ntukidem I and Nwoke I (2013). Assessment of Hepatoprotective and antioxidant activity of nauclea latifolia leaf extract against acetaminophen induced hepatotoxicity in rats. *Inter. Res. J. Plant Sci.*, **4**: 55-63.
- Kiran PM, Raju AV and Rao BG (2012). Investigation of hepatoprotective activity of *Cyathia gigantea* (Wall. ex. Hook.) leaves against paracetamol-induced hepatotoxicity in rats. *Asian Pac. J. Trop. Biomed.*, **2**: 352-356.
- Kumar SV, Sanjeev T, Ajay S, Kumar SP and Anil S (2012). A review on hepatoprotective activity of medicinal plants. *Inter. J. Ad. Res. Pharma. & Bio. Sci.*, **1**: 31-39.
- Luna LG (1968). Manual of histologic staining methods of the Armed Forces Institute of Pathology, (U.S.) [Corporate Author]
- Obogwu MB, Akindele AJ and Adeyemi OO (2014). Hepatoprotective and *in vivo* antioxidant activities of the hydroethanolic leaf extract of *Mucuna pruriens* (Fabaceae) in antitubercular drugs and alcohol models. *Chin. J. Nat. Med.*, **12**: 273-283.
- Prachayasittikul S, Buraparungsang P, Worachartcheewan A, Isarankura-Na-Ayudhya C, Ruchirawat S and Prachayasittikul V (2008). Antimicrobial and antioxidative activities of bioactive constituents from *Hydnophytum formicarum* Jack. *Molecules*, **13**: 904-921.
- Rao AS, Ahmed Mohammed Fazil And Ibrahim Mohammed (2012). Hepatoprotective activity of *Melia azedarach* leaf extract against simvastatin induced Hepatotoxicity in rats. *J Appl Pharm Sci.*, **2**: 144-148.
- Rao NJ, Subash K and Kumar KS (2012). Role of phytotherapy in gingivitis: A review. *Int. J. Pharmacol.*, **1**: 1-5.
- Ratnasooriya W, Pieris K, Samaratunga U and Jayakody J (2004). Diuretic activity of *Spilanthus acmella* flowers in rats. *J Ethnopharmacol.* **91**: 317-320.
- Sharma V, Boonen J, Chauhan NS, Thakur M, De Spiegeleer B and Dixit VK (2011). *Spilanthus acmella* ethanolic flower extract: LC-MS alkylamide profiling

- and its effects on sexual behavior in male rats. *Phytomedicine*, **18**: 1161-1169.
- Singh M and Chaturvedi R (2012). Screening and quantification of an antiseptic alkylamide, spilanthol from *in vitro* cell and tissue cultures of *Spilanthes acmella* Murr. *Industrial Crops and Products*, **36**: 321-328.
- Tiwari KL, Jadhav SK and Joshi V (2011). An updated review on medicinal herb genus *Spilanthes*. *Zhong Xi Yi. Jie. He. Xue. Bao.*, **9**: 1170-1178.
- Zahra K, Malik M, Mughal M, Arshad M and Sohail M (2012). Hepatoprotective role of extracts of *Momordica charantia* L. in acetaminophen-induced toxicity in rabbits. *J. Anim. Plant Sci.* **22**: 273-277.