

How to Read Chest X-Rays

The physician must examine chest radiographs systematically and thoughtfully. To do less risks missing significant features, both positive and negative.

Kenneth D. Krone, MD

Sydne A. Weiner, MD

Although quite familiar to most physicians, chest x-rays remain among the most complex radiographic studies in terms of anatomic density. Novice readers can easily become overwhelmed by the myriad normal variations as well as by several possible interpretations of abnormal findings. They can miss substantial pathology if they don't view *all* the body systems represented -for example, focusing on a lung abscess and overlooking multiple rib fractures. Despite this initial frustration, practitioners who persevere can glean great amounts of information and establish definitive diagnoses by carefully exploring posteroanterior and lateral chest films.

First Steps

As simple as it sounds, begin by checking the patient's name and the date on the x-ray. You would not be the first to suffer the embarrassment of reading the wrong film. (*Primum o non nocere*: we do not want to label a patient with a disease he or she does not have.) Next, check for the "R" or "L" marker. Ignoring this may someday cause you to miss diagnosing a case of dextrocardia or, worse yet, sending a surgeon in on the wrong side for a lung tumor.

Gauge the quality of the inspiratory effort: a good effort exposes the sixth rib anteriorly or the tenth rib posteriorly at the middle of the right hemidiaphragm. You will marvel at how "cardiomegaly" and "bibasilar consolidation" on films taken with suboptimal inspiration become a "normal study" with the patient holding a deep breath.

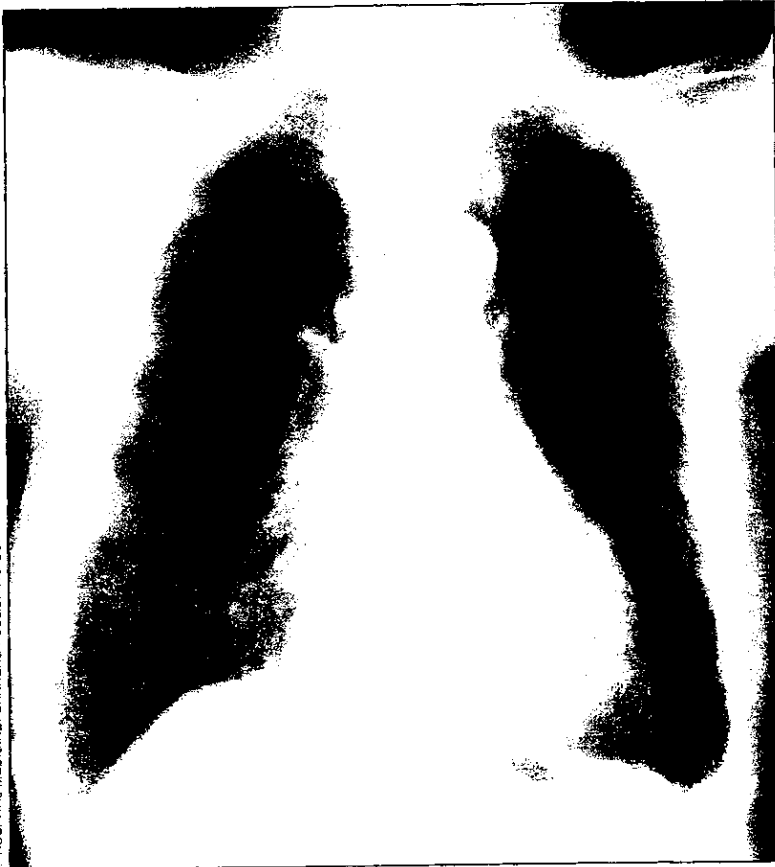Next, note body positioning. You can most easily evaluate this by measuring the distance from the medial end of each clavicle to the spinous process of the vertebra at the same level; these distances should be equal. Even slight rotation may distort normal anatomic imaging enough to create either "pathology " or confusion!

The PA View

Begin your reading with the posteroanterior x-ray (Figure 1). Remember that you are responsible for the *entire* film. The novice commonly explores the lungs and heart, ignoring the remainder of the anatomic structures displayed.

SOFT-TISSUE ABNORMALITIES

Examine soft tissues outside the rib cage first.
Next, look for the breast and pectoralis muscle shadows.



P. HOSPITAL MEDICINE, CAHNER'S PUBLISHING CO.

Areas of increased density are seen over both lung fields, but they are *skin* lesions of bullous pemphigus (seen clearly in the skin over the lateral chest walls).

Examine soft tissues outside the rib cage first, carefully searching for masses, swelling, air, foreign objects, etc (Figure 2). Next, look for the breast and pectoralis muscle shadows. Disparity in lucency of the "lung fields " might be due to mastectomy or congenital absence of the pectoralis muscle. A nipple shadow may be misinterpreted as a lesion in the lung parenchyma.

Survey the bones next. On most chest films, you can identify the proximal humeri, the clavicles, the scapulae, the ribs, the sternum, and many vertebrae. Paget's disease, for of example, may involve any of these bones. Osteoarthritis or rheumatoid disease may affect the acromioclavicular and glenohumeral joints. Look for lesions of multiple myeloma, primary osseous malignancies, or metastatic disease.

OSSEOUS ABNORMALITIES

Having carefully examined the soft tissues, study the bones next. On most chest films, you can identify the proximal humeri, the clavicles, the scapulae, the ribs, the sternum, and many vertebrae. Don't forget the corners of the film.



© HOSPITAL MEDICINE / CAHNER'S PUBLISHING CO.

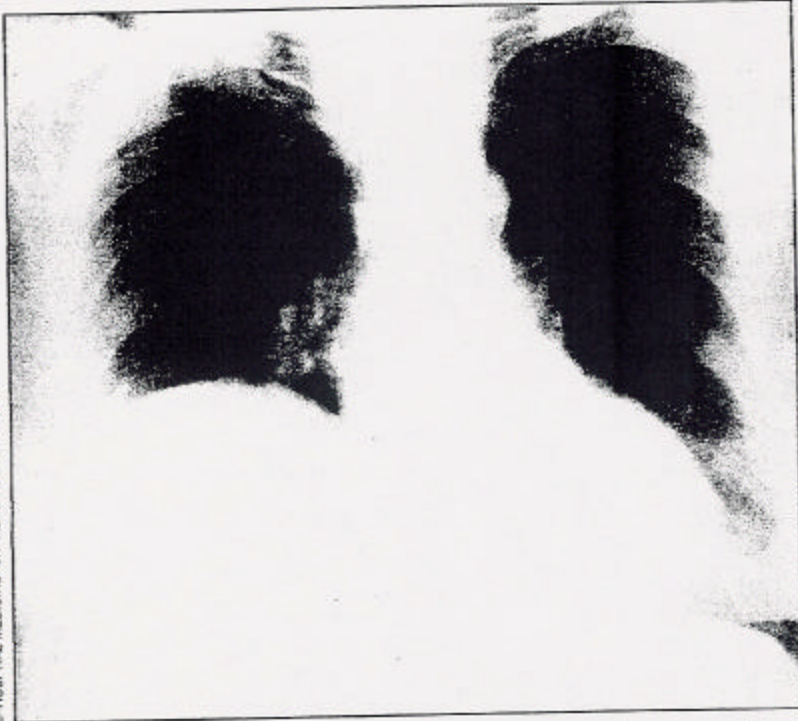
The oval density in the right upper lung field is actually not in the lung; it is a hemangioma of the second rib. Don't allow this to distract you from noting the elevation of the left hemidiaphragm, calcification in the aortic knob and descending aorta, and fracture of the neck of the left humerus.

Figure 3

The chest x-ray may reveal traumatic fractures and/or dislocations (Figure 3). Lateral osteophyte formation between two vertebrae sometimes resembles (on quick glance) a mass lesion. Avoid this pitfall by carefully noting the relationship of such a density to the vertebral column on both PA *and* lateral views.

ELEVATED RIGHT HEMIDIAPHRAGM

Observe the diaphragm next, paying attention to its shape and height. Don't forget to look *below* the domes of the diaphragm as well.



© HOSPITAL MEDICINE / OWNERS PUBLISHING CO.

Elevation of the right hemidiaphragm is noted here, in this case due to eventration. Other causes to consider include herniation, paralysis, right lower lobe collapse, loculated effusion, hepatomegaly, subphrenic abscess, and other abdominal pathology.

Figure 4

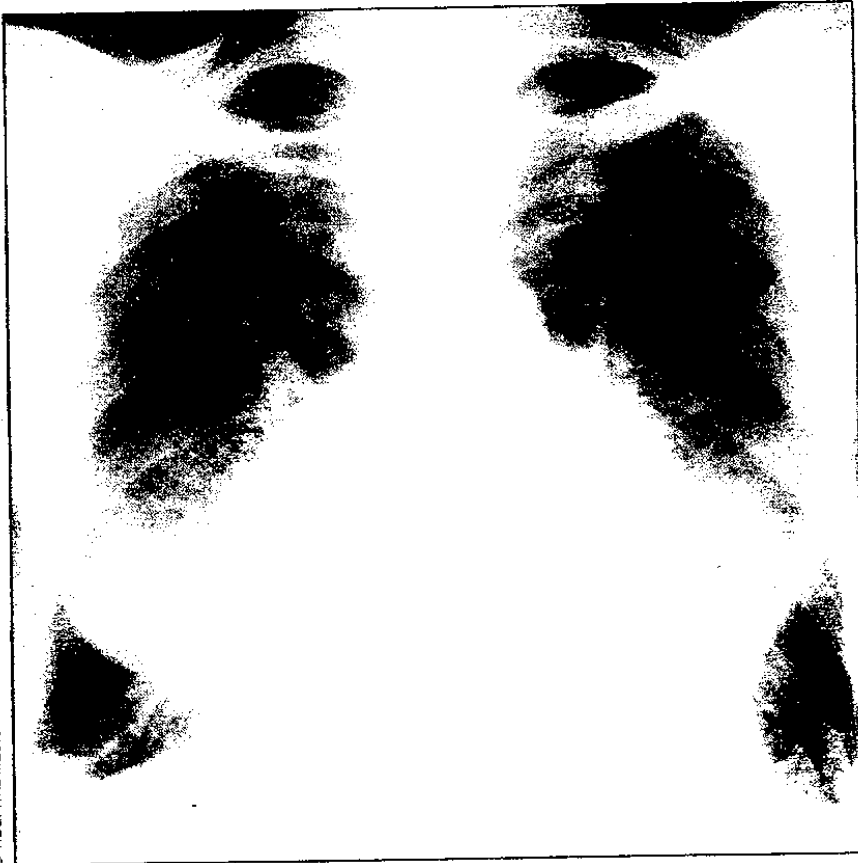
Observe the diaphragm next, paying attention to its shape and height (Figure 4). The right hemidiaphragm is normally higher than the left, but by no more than one rib interspace. Any area lacking the normal sharp margin of the diaphragm requires further consideration (Figure 5). Don't forget to look *below* the domes of the diaphragm as well. Large portions of both lung bases lie here and must be evaluated fully. Don't be caught missing a pneumonia or metastatic nodule hiding in this region. In addition, any visualized abdominal structures (stomach, colic flexures, etc) or abnormal intraperitoneal air collections should be assessed.

The mediastinum presents a great challenge because of its complex anatomy, resulting in multiple *normal* lumps and bumps on the film. Begin with a frequently neglected area: the main airway. Notice the normal narrowing of the air column . at the vocal cords, the deviation of the trachea to the right at the level of the transverse aortic arch, and the positions and angles of the carina and the main stem bronchi.

A filling defect or distortion or narrowing of the tracheobronchial air column may be the only indication of a tracheal carcinoma or adenoma or of metastatic breast cancer or melanoma. Any abnormal position of an airway must be noted. The right mainstem bronchus normally has a more vertical orientation than the left, with approximately a 60° angle between them. Left atrial

PLEURAL EFFUSION

Any area lacking the normal sharp margin of the diaphragm requires further consideration.



© HOSPITAL MEDICINE / CAHNER'S PUBLISHING CO.

Note the loss of sharpness of the right hemidiaphragm, in this case due to pleural effusion. Is the film otherwise normal? The enlarged cardiac silhouette, pulmonary vascular engorgement, interstitial edema, and Kerley B lines at both bases reveal the cause of the effusion: left ventricular failure.

Figure 5

enlargement, left upper lobe atelectasis, or enlargement of the carinal lymph nodes can elevate the left mainstem bronchus. Loss of volume of a lobe or lung due to an endobronchial lesion may also cause deviation of an airway from its normal position.

Learn to observe the overall orientation of the mediastinum. It may be pushed to one side (eg, by pleural effusion, air trapping, or tension pneumothorax) or pulled over (eg, by pneumonectomy, fibrosis, or atelectasis). Masses in the mediastinum may change its contour or may show through the cardiac silhouette.

Lymph node groups are abundant throughout the mediastinal compartments and extend into the lung parenchyma. Enlargement of these nodes may characterize many conditions. Within the lymph nodes, presence or absence of calcification provides a valuable, although not infallible, clue to malignancy or benignity. Peripheral ("eggshell") calcification suggests silicosis but also occurs in some cases of

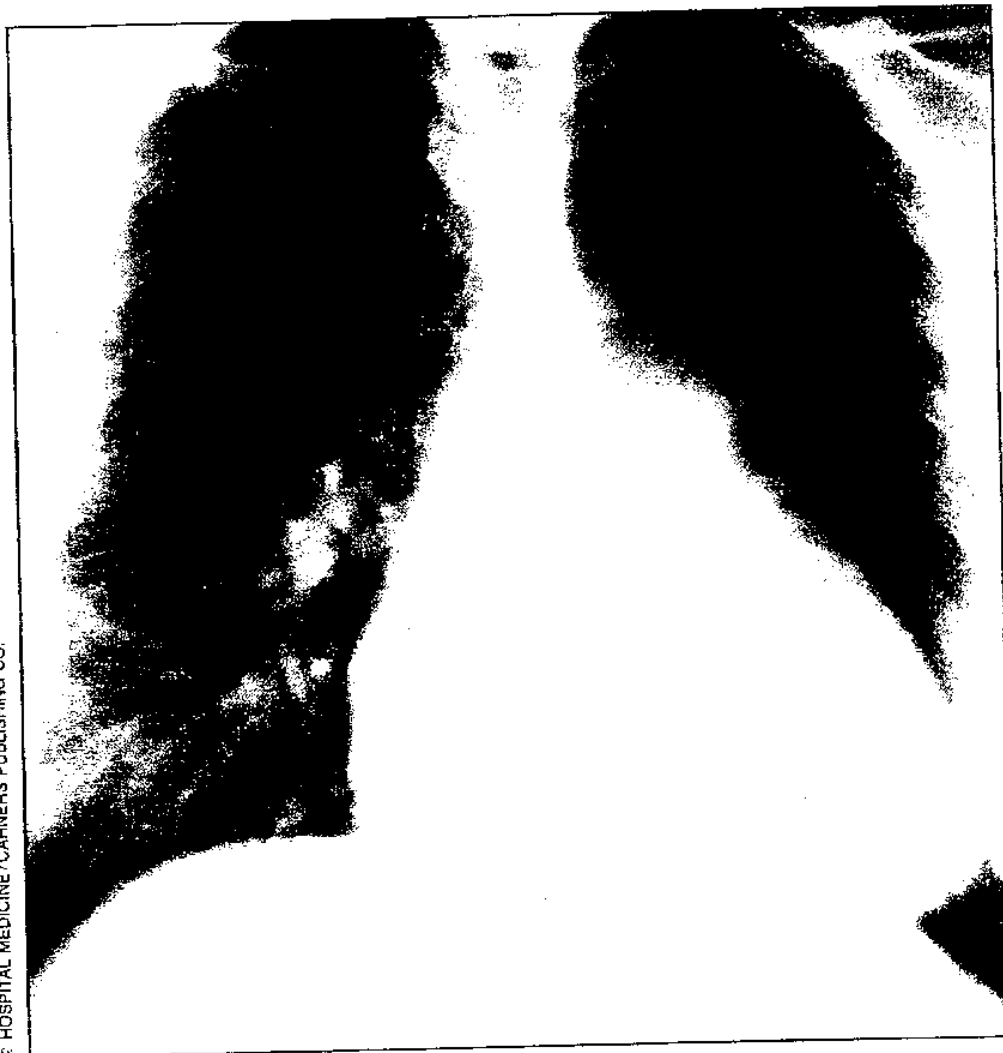
sarcoidosis. Central calcification suggests an old of granulomatous process. Eccentric of calcification, however, may be seen he in a scar carcinoma.

Several line shadows within the mediastinum represent normal pleural reflections. Familiarity with their usual positions permits detection of a deviation due to pathologic processes, which may also result in localized areas of increased density within the mediastinum.

Examination of the heart and great vessels rounds out our perusal of the mediastinum. Check the cardiac silhouette for size and contour. Normally, the heart spans less than half the transverse diameter of the rib cage. (Learn to use your eyes or, at most, two fingers to make this determination.) The right atrium forms the right heart border. Four structures (from top to bottom) make up the left heart border: the aortic knob , main pulmonary artery, left atrial appendage, and left ventricle. There is a normal concavity between the aortic knob and the left pulmonary artery- the aortcopulmonary window. Loss of this concavity or, especially, the development of a *con vex* density in this region raises the question of lymphadenopathy.

PROMINENT PULMONARY ARTERY

Prominence of the pulmonary artery occurs with increased flow states or increased pulmonary resistance but may also represent a normal variant in young adults.



© HOSPITAL MEDICINE / CAHNS PUBLISHING CO.

Enlargement of the cardiac silhouette and prominence of the pulmonary artery and pulmonary vasculature here reflect an atrial septal defect.

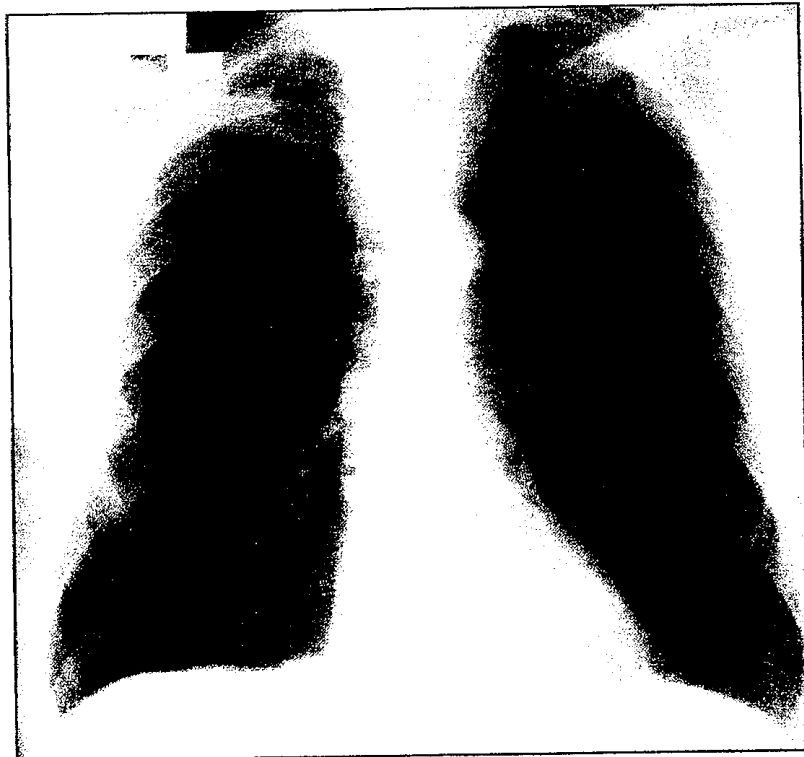Figure 6

Mural calcification frequently outlines the aortic knob as a lenticula (crescent-shaped) density in older patients. Prominence of the pulmonary artery occurs with increased flow states (Figure 6) or increased pulmonary resistance but may also represent a normal variant in young adults.

Lateral to the mediastinum lie the lung hila, the left one higher than or level with the right; a disparity of height greater than one rib space is pathologic. The major component of each hilar shadow is the respective pulmonary artery-with lymph nodes, the pulmonary veins, and the central bronchi making up the remainder. Not only should you evaluate the shape, position, density, and size of each hilum, but you must scrutinize the vessels extending from each.

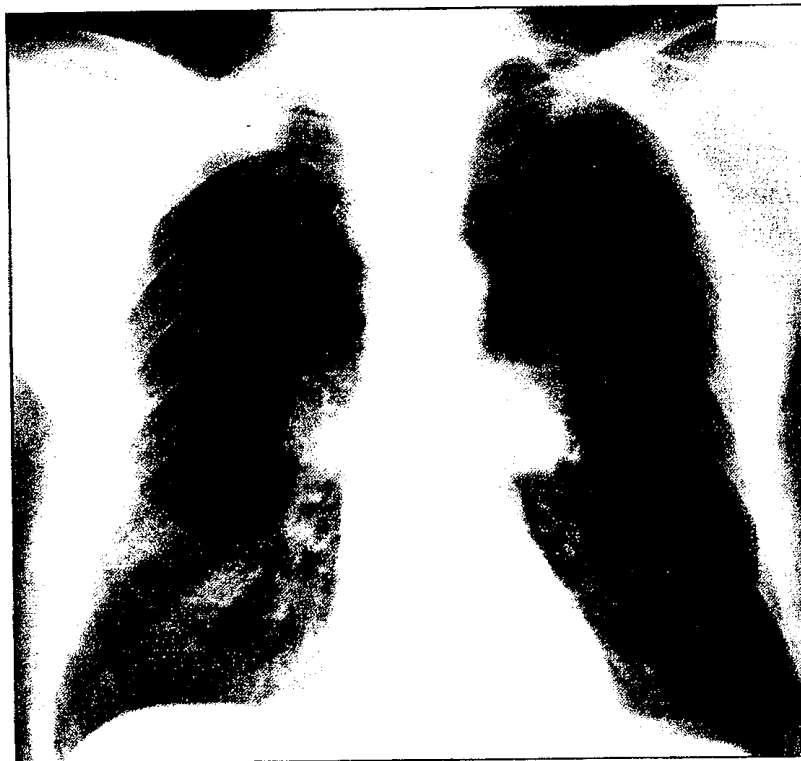HILAR ENLARGEMENT

The lung hila lie lateral to the mediastinum. The major component of each hilar shadow is the respective pulmonary artery—with lymph nodes, the pulmonary veins, and the central bronchi making up the remainder. A hilum that appears too large for its vessels suggests the presence of a mass.



This PA view shows hilar fullness, possibly consistent with an early bronchogenic carcinoma.

Both hili have changed in contour and density in 17 months, reflecting progression of this patient's malignancy.



© HOSPITAL MEDICINE / CAHNER'S PUBLISHING CO.

Figure 7

Differentiating between prominent vessels and a mass can be tricky. Observe the hilum on both PA and lateral views; if the prominence appears on only one view, it is most likely normal. Vessels should gradually taper as they branch out. A hilum that appears too large for its entering and exiting vessels suggests the presence of a mass (Figure 7).

We next proceed to the pleura, first examining each costophrenic angle for sharpness. True angle blunting represents fluid, fibrosis, or a mass, but this may be mimicked by the attachment of the diaphragm to the ribs seen during a very deep inspiratory effort. Trace the pleural reflection superiorly along the medial margin of the rib cage, looking for areas of thickening or calcification. One commonly sees a normal s pleural "companion shadow" along the first and second ribs laterally. Carefully observe the apices next. Although a small amount of bilateral pleural thickening is frequently noted here, *asymmetric* thickening raises the specter of malignancy until proven otherwise.

At long last, we are ready to examine the lungs, checking for symmetry of the lung fields. Relative densities of corresponding areas should be equal. Shift your eyes from one side of the film to the other, rather than examining one whole lung at a time. (By the way, what *are* all of those lung markings we see in a normal chest roentgenogram ? *Blood vessels!*)

Look for the outer borders of each lung. A linear margin with no vascular markings lateral to it may indicate a pneumothorax (Figure 8) . Pulmonary vessels normally taper as they branch and become more r peripheral .You will soon learn to a recognize both the dearth of lung markings that accompanies pneumothorax and the plethora of markings that accompanies vascular congestive states.

Once you identify a truly abnormal increase or decrease of density within the lung parenchyma (and not the "fortuitous superimposition of shadows"), try to classify the process. *Increased* density may result from many types of pathology, including (1) air space disease, which replaces or absorbs normal alveolar air, such as alveolar infiltrates or atelectasis, (2) interstitial disease, which increases the volume of tissues surrounding the air spaces, or (3) a combination of both. Airspace disease results in an alveolar pattern and air bronchograms. Interstitial disease may be described as nodular (multiple tiny round densities), reticular (branching lines), or reticulonodular. Nodules and masses also result in increased density .The term *nodule* is usually used to describe lesions 2 cm or less in diameter; the term *mass* describes larger lesions. Scar formation may also cause increased density due to atelectasis and fibrosis. Linear scars may mimic discoid atelectasis. Look for calcification, cavitation, homogeneity, and location of the density; these will all help you to narrow down the differential diagnosis for any given lesion. Destruction of lung parenchyma results in increased lucency (*decreased* density) due to air trapping and the formatin of bullae.

Remember that *not all pathology lacks symmetry* ; in particular, be alert for the small, discrete, bilateral nodules of early disseminated tuberculosis.

LUNG MARKINGS

After examining the pleura, we are ready to examine the lungs. Check for symmetry of the lung fields. Relative densities of corresponding areas should be equal.



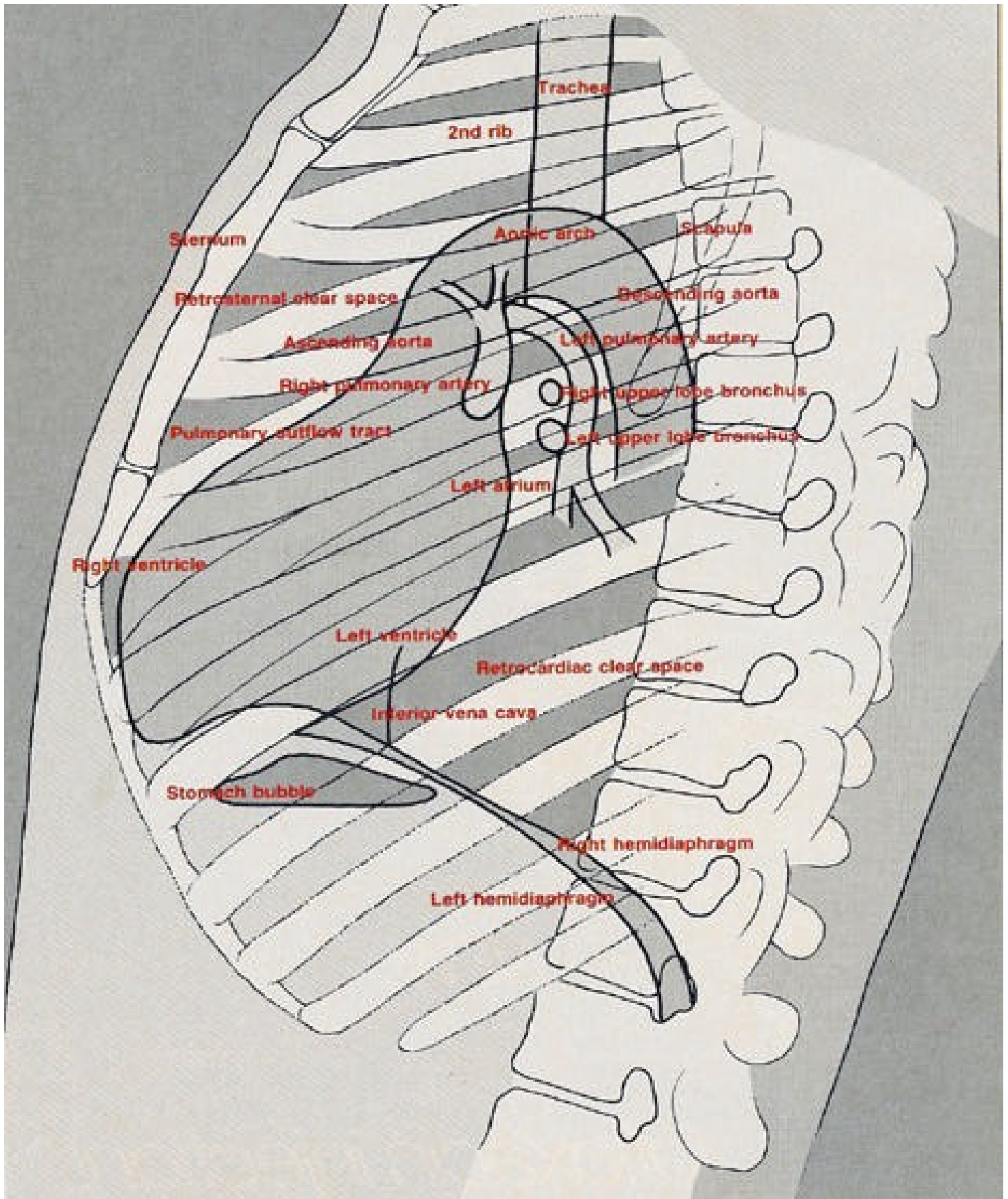
HOSPITAL MEDICINE, CAHNER'S PUBLISHING CO.

The apparent "mass" lateral to the left heart border is actually a collapsed left lung due to pneumothorax. Note the increased lucency of the entire left lung field, with no evidence of vascular markings. An air-fluid level also clearly indicates a left pleural effusion.

Figure 8

The Lateral View

Your study of the PA film is now complete; however, you must also carefully examine the lateral view (Figure 9). This projection helps to confirm and localize pulmonary, hilar, and mediastinal lesions; it occasionally demonstrates abnormalities not seen clearly on the PA film, as may occur in the retrosternal space.



Follow the same sequence as for the PA x-ray, examining the soft tissues and bones first. Follow the airway, looking for displacement, irregularity, or narrowing. You should encounter two small, round lucencies representing the upper lobar bronchi, the left lying lower than the right. At the same level, notice the pulmonary arteries; the right one should be anterior to the left (Figure 10).

Next, examine the retrosternal space above the heart border, where mediastinal masses may lie hidden. Check the retrocardiac area, where you should see the inferior vena cava on a good lateral film. Here you may also see basilar consolidation (lost behind the heart shadow in an underpenetrated PA film).

Study the remainder of the lung parenchyma, especially that which overlies the spine. As your gaze proceeds down the spine, the density should decrease; if it does not, you must review the PA film to determine the cause of this abnormality.

Observe the sharpness of the diaphragm and the posterior costophrenic angles. A disease process of the basal pulmonary segments hidden on the frontal projection may show up on the lateral view.

Conclusion

Although you have thoroughly read the chest films, they may not have answered all of your questions about the patient. Only occasionally will chest x-rays give you specific answers. More commonly you will find yourself confronted with a variety of possible interpretations. A roentgenogram represents only an instant of time in a patient's state of health.

At this point, you must seek additional clues. The history of the problem can frequently assist in narrowing down your list of possible diseases but may not reveal the length of time an x-ray abnormality has been present. Then you will want to consult the radiologist's most cherished friend, the "old film"-if you can lay your hands on it.

Suggested Reading

Fraser RG, Pare JAP, Pare PD, Genereux GP: Diagnosis of Diseases of the Chest. ed 3. Philadelphia, WB Saunders Co, 1988, vol 1; 1989, vol2; 1990, vol3; 1991, vol4.

Lange S: Radiology of Chest Diseases. Thieme Medical Publishers, Inc, 1990.

Reed JC: Chest Radiology: Plain Film Patterns and Differential Diagnosis. ed 3. St. Louis, Mosby-YearBook, Inc, 1991.

Sutton D: Textbook of Radiology. Churchill Livingstone Inc, 1987.