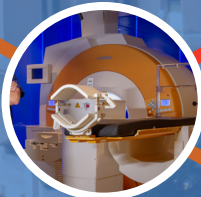
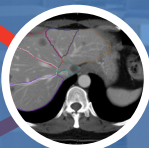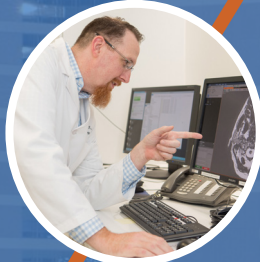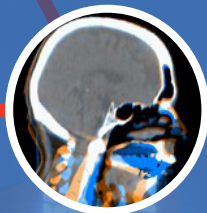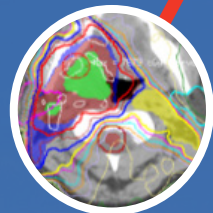


# Image-Guided Cancer Therapy

THE UNIVERSITY OF TEXAS

**MDAnderson**  
~~Cancer~~ Center

Making Cancer History®



Copyright The University of Texas  
MD Anderson Cancer Center 2020  
*All photos were taken prior to the COVID-19 pandemic.*

# Table of Contents

---



Program Overview  
Page 1



Mission  
Page 9




Strategic Goals  
Page 17



Targeted Anatomical Sites  
Page 21



Summary  
Page 31



# Vision

Local regional tumor control and reduced toxicities.


# Mission

Empower multidisciplinary teams of physicians and scientists to address clinical challenges and technology barriers enabling the translation of innovative science directly to patient care.

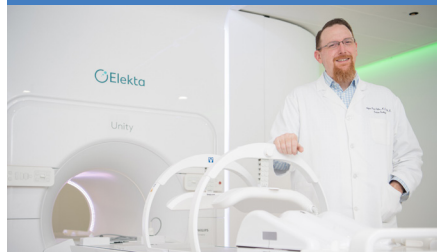# Program Overview

The Image Guided Cancer Therapy Research Program's vision to harness the synergy of multidisciplinary teams has enabled the acceleration of innovation and its translation to the clinical environment. The program relies heavily on the expertise of its members - interventional and diagnostic radiologists, imaging scientists, medical physicists, surgeons, radiation oncologists, pathologists, and more. Through increased 'clinical problem' focused interactions clinical limitations are identified, solutions designed, and clinical trials initiated. These initiatives make strides towards improving patient care.

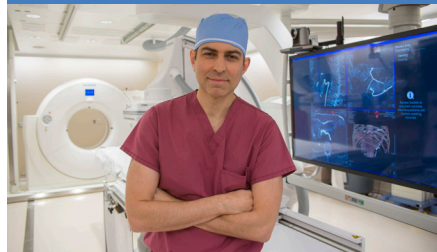We identified three strategic goals as we launched the program in 2017. These goals have been focused on 5 anatomical sites: brain, head and neck, lung, liver, and cervix.



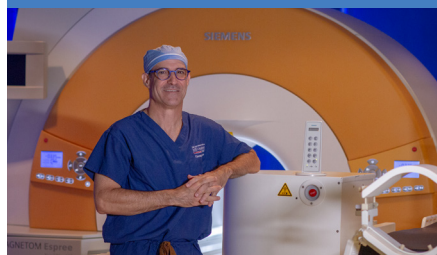**Kristy K. Brock, PhD, DABR, FAAPM**  
Director



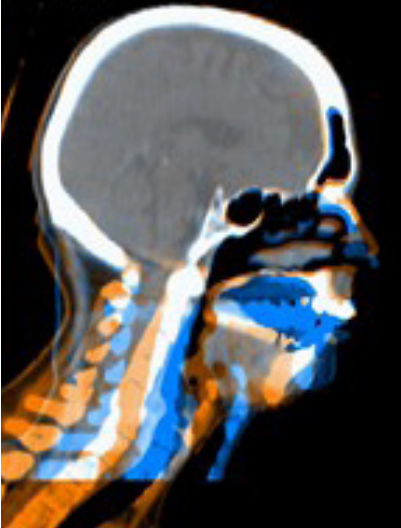
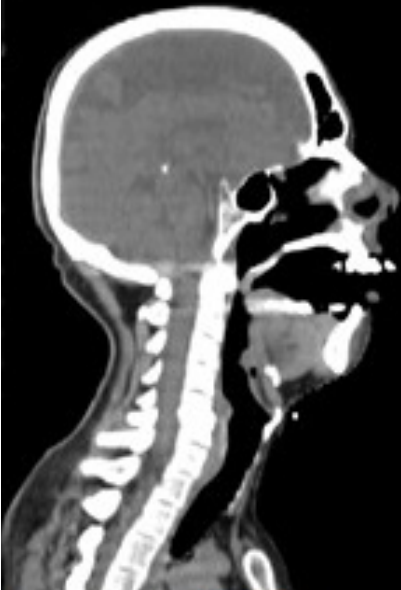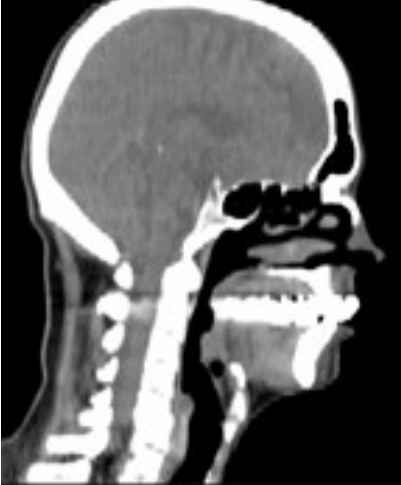**Clifton D. Fuller, MD, PhD, DABR**  
Medical Director, Radiation Oncology Branch



**Bruno C. Odisio, MD, DABR**  
Medical Director, Interventional Radiology Branch



**Jeffrey S. Weinberg, MD, FAANS, FACS**  
Medical Director, Surgical Oncology Branch



## Strategic Goals

---

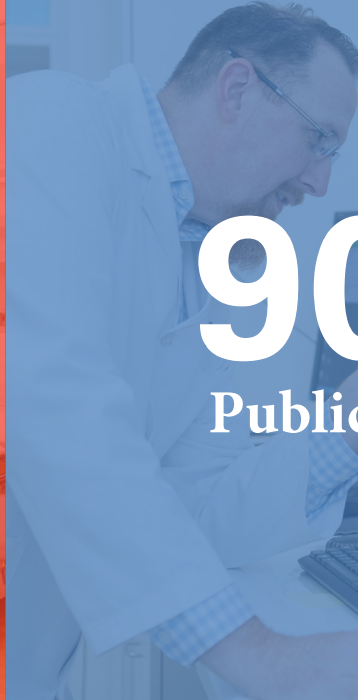1. Develop and validate novel imaging to identify and target the tumor while avoiding normal tissue.
2. Advance in-room integration of imaging to reduce uncertainties in executing the planned intervention.
3. Demonstrate a significant improvement in the local control and quality of life of cancer patients through image guided cancer therapy.





19

Departments



90

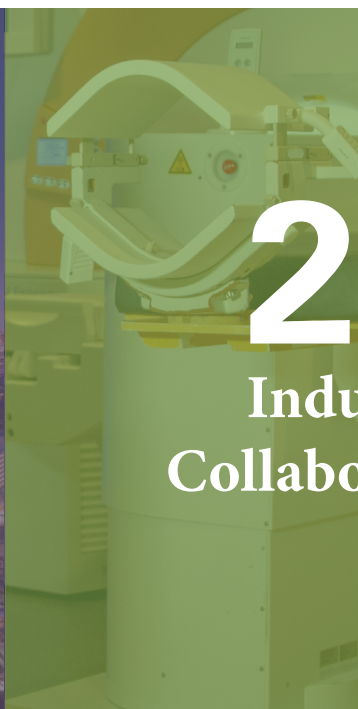Public

# Collaboration of High



54

Multidisciplinary  
Grants



2

Indu  
Collabo





**06**  
Publications

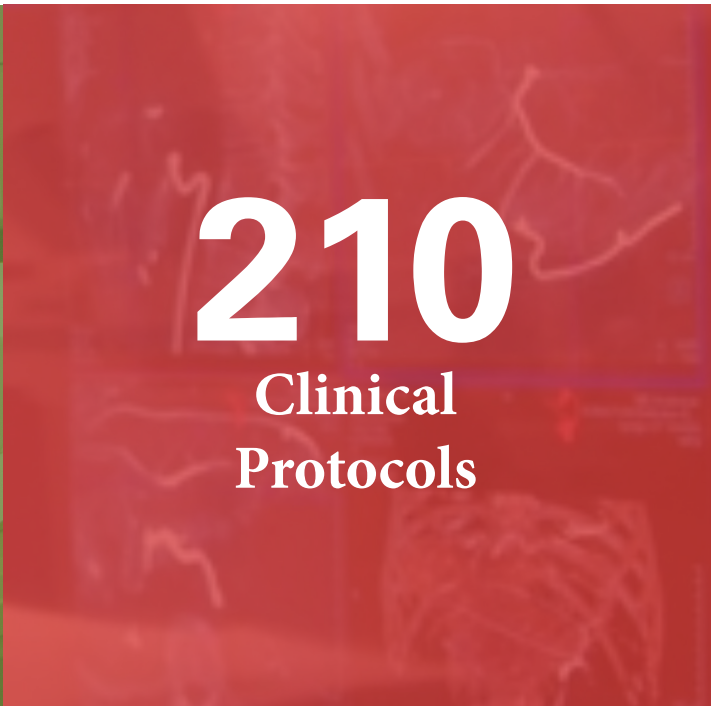


**50%**  
Higher Connectivity  
within MD Anderson

# Highly Successful Faculty



**7**  
Industry  
Collaborations



**210**  
Clinical  
Protocols

**IMAGING  
PHYSICS**

**CANCER SYSTEMS  
IMAGING**

**RADIATION ONCOLOGY**

**PATHOLOGY**

**SURGERY**

**RADIATION PHYSICS**

**RADIOLOGY**

**NUCLEAR  
MEDICINE**

**PULMONARY  
MEDICINE**

**INTERVENTIONAL  
RADIOLOGY**

## Imaging Physics

Jim Bankson  
Richard Bouchard  
Kristy Brock  
David Fuentes  
John Hazle  
Ken-Pin Hwang  
Kyle Jones  
Cheenu S. Kappadath  
Rick Layman  
Ho-Ling (Anthony) Liu  
Jingfei Ma  
Osama Mawlawi  
Tinsu Pan  
Konstantin Sokolov  
Jason Stafford  
Jia Wu

## Cancer Systems Imaging

Mark Pagel  
David Piwnica-Worms

## Radiology

Myrna C. B. Godoy  
Jason Michael Johnson  
Vikas Kundra  
Aliya Qayyum  
Gaiane M. Rauch  
Dawid Schellingerhout  
Aradhana M. Venkatesan  
Carol Wu

## Interventional Radiology

Rony Avritscher  
Stephen Chen  
Erik N. K. Cressman  
Sanjay Gupta  
Colin J. McCarthy  
Bruno C. Odisio  
Rahul A. Sheth  
Alda L. Tam

## Pathology

Alejandro Contreras  
Anirban Maitra

## Pulmonary Medicine

Roberto Casal  
George Eapen  
David Ost

## Radiation Oncology

Joe Chang  
Caroline Chung  
Steven Frank  
Clifton Fuller  
Amol Ghia  
Emma Holliday  
Ann Klopp  
Eugene Koay  
Albert Koong  
Sunil Krishnan  
Lillie Lin  
Steven Lin  
Jack Phan  
Chad Tang  
James Welsh

## Radiation Physics

Sam Beddar  
Carlos Cardenas  
Laurence Court  
David Jaffray  
Radhe Mohan  
Mohamed Salehpour  
Gabriel Sawakuchi  
Jihong Wang  
Jinzhong Yang

## Surgery

Thomas Aloia  
Hop Tran Cao  
Anne Gillenwater  
Niel Gross  
Stephen Lai  
Frederick Lang  
Jeffrey Lee  
Jeffery Meyers  
Ravi Rajaram  
David Rice  
Claudio Tatsui  
Jean-Nicolas Vauthey  
Jeffrey Weinberg

## Nuclear Medicine

Yang Lu  
Gregory C. Ravizzini  
Dao Le  
Homer A. Macapinlac

## Empowering Multidisciplinary Teams

‘Multidisciplinary collaboration’ is the heart of the Image Guided Cancer Therapy (IGCT) Research Program. From education, to new developments in research, to clinical trials, to interactive brainstorming sessions, the IGCT recognizes that diversity in perspectives around the table leads to more innovative solutions and leverages previous advances from specific disciplines.

Several large-scale multidisciplinary educational initiatives have been spearheaded by the IGCT Research Program, including the **submissions of an NIH Training Grant (T32)**. The T32 submission is a multi-PI effort spearheaded by Drs. Kristy Brock (Imaging Physics), Clifton Fuller (Radiation Oncology), and Stephen Lai (Head and Neck Surgery). The goal of this training program is to provide multi-disciplinary research training for tomorrow’s pioneering leaders in image guided cancer therapy, including surgery, interventional and diagnostic radiology, radiation oncology, and correlative pathology, using advanced imaging, navigation, and analysis techniques. This training program is unique in that it trains, within a single program, both scientists and clinician scientists working in image guided cancer therapy. The application will be reviewed in the fall of 2020; however, the development of the program is already underway. In the past year, the IGCT developed a course to provide multi-disciplinary education on image guided cancer therapy. Lectures included presentations by surgeons, radiologists, radiation oncologist, and clinical and research scientists in medical physics.

In addition, an NIBIB Research Education Program for Residents and Clinical Fellow (R25EB025787) was awarded to Drs. Clifton Fuller and Prajnan Das to develop a training program, in collaboration with a multi-disciplinary team of mentors, to provide intensive training in imaging and informatics to empower research careers.



*Photo: October 2019*

**“For technologists, it’s always helpful to know the “why” behind the imaging we perform. Knowing the Surgeon, Radiation Oncologist & Radiologist use the images helps them feel more involved as an integral part of the team and aids in providing them with quality imaging.”**

Brandy J. Willis, MBA (RT)(MR)  
Medical Imaging Technologists Supervisor,  
Diagnostic Imaging

### **IGCT Communication Events:**

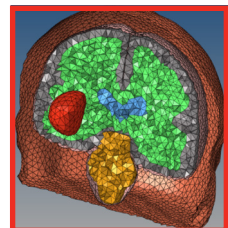
- Anatomical site-based brainstorming sessions
- Monthly IGCT Research Seminars
- IGCT Focused Educational Seminars
- Hands-on workshops
- Multi-disciplinary IGCT class for students and trainees

## Addressing Clinical Challenges and Technology Barriers

---

One of the primary motivations in the creation of the Image Guided Cancer Therapy Research Program is to ensure that scientific innovations get translated into clinical use, clinical problems get identified and described to scientists to develop multidisciplinary teams to address them, and technology barriers get broken down through strong collaborations between clinicians, scientists, and industry partners. Several industry collaborations have been advanced by the IGCT as well as supported by the IGCT faculty through institutional strategic alliances. Here are some highlights of the technology barriers being addressed to tackle clinical challenges in surgery, radiation oncology, and interventional radiology.

**Brain shift mapping for surgical guidance (PI: Kristy Brock, PhD, Jeffrey Weinberg, MD)** – The knowledge that the brain can shift by several millimeters when the skull is opened during neurosurgery has existed for years. The technology to accurately describe this motion and enable mapping of eloquent brain structures onto the updated geometry of the patient has been described in research publications on retrospective cases, however, the solution, in its current form, faces significant technology barriers and has not been translated into the clinic due to its complexity. This collaboration seeks to address these limitations and develop solutions, in close collaboration with neurosurgeons, to ensure the development of a technology that is accurate and efficient, enabling it to be directly translated into clinical practice. Funding: Apache Foundation.



**A Comprehensive fMRI Software Solution for the Clinic: Mapping Critical Functional Networks (PI: Ho-Ling Anthony Liu, PhD)** – Preoperative functional localization of eloquent areas for brain tumor patients undergoing surgical intervention is crucial to prevent post-surgical deficits and reduce morbidity. Resting-state fMRI, which maps all major brain networks while the patient is resting or lightly sedated can accurately localize these eloquent areas. However, there are no commercially available software tools. Dr. Liu, who has pioneered the development and clinical deployment of these tools at MD Anderson, is working to commercialize these tools to enable their use worldwide. Funding: NIH AIP grant under review.

**Automated Radiation Dose Accumulation (PI: Kristy Brock, PhD)** – The understanding that “what you plan is not what you deliver” has been around for over a decade, however the tools to perform dose accumulation in radiotherapy have not translated into a clinically usable platform. This strategic alliance addresses the technology barriers to using these tools in routine clinical practice. The tools are already being translated into the clinic to support the MRI-Guided Adaptive Radiotherapy trial for head and neck cancer patients. Funding: RaySearch Laboratories Co-Development and Collaboration Agreement.

**Development of Functional MRI-Guided Adaptive Radiotherapy for Head and Neck Cancer Patients (PI: Clifton Fuller, MD, PhD)** – Functional imaging with high field magnetic resonance imaging (MRI) provides non-anatomic information about tumor and normal tissue response to radiation therapy. This project creates an academic and industrial technology development partnership to develop functional imaging guided radiation therapy using a combination MRI/linear accelerator (MR-LinAc) device, allowing patients to have reduced side effects with equivalent or improved control of tumors of the head and neck. Funding: NIH R01 DE028290.

## Translation of Innovative Science

---

One of the IGCT's strategic goals is to demonstrate a significant improvement in the local control and quality of life of cancer patients through image guided cancer therapy. This requires innovative, multi-disciplinary clinical trials. Many of the IGCT faculty are actively involved in the 210 clinical protocols that are currently ongoing. Here, we highlight four clinical trials that were actively developed through the IGCT Research Program.

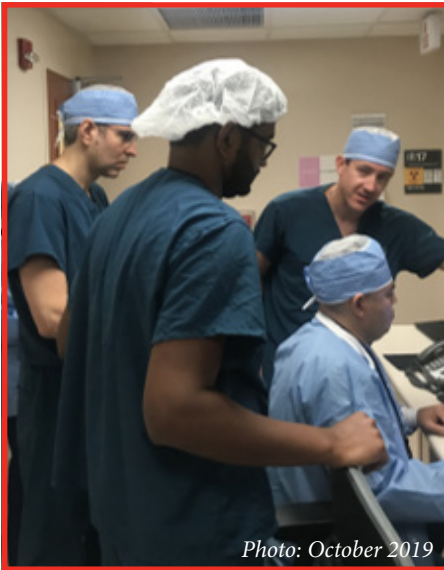### **Magnetic Resonance-based Response Assessment and Dose Adaptation in Human Papilloma Virus Positive Tumors of the Oropharynx treated with Radiotherapy (MR-ADAPTOR) (PI: Clifton David Fuller, MD, PhD)**

– In this R-IDEAL stage 2a-2b/Bayesian phase II trial, weekly radiotherapy dose-adaptation based on magnetic resonance imaging (MRI) will be used to evaluate tumor response. Individual patient's plan will be designed to optimize dose reduction to organs at risk and minimize loco-regional failure probability based on serial MRI during RT. The primary aim is to assess the non-inferiority of MRgRT dose adaptation for patients with low risk HPV-associated oropharynx cancer compared to historical control, as measured by Bayesian posterior probability of loco-regional control. Funding: Andrew Sabin Family Foundation

### **Serial Advanced Magnetic Resonance Imaging (MRI) for Guidance of Personalized Adaptive Radiotherapy for High Grade Glioma (PI: Caroline Chung, MD)**

– This is a prospective single-arm imaging trial that will acquire serial multi-parametric MRI in patients undergoing 6 weeks of radiotherapy for high grade glioma in order to investigate the benefit of serial MR imaging data to guide a personalized, adaptive therapeutic approach and provide prognostic information. Funding: Dr. Marnie Rose Foundation.





**Software-Aided Imaging (Morfeus) for Confirming Tumor Coverage With Ablation in Patients With Liver Tumors, the COVER-ALL Study (PI: Bruno Odisio, MD) –**

This prospective randomized phase II trial studies how well software-aided imaging works in confirming tumor coverage with ablation in patients with liver tumors. The current standard for targeting tumor cells and evaluating the outcome of a liver ablation procedure is a visual

inspection of the pre- and post-procedure CT scans. The primary objective is to evaluate if the intra-procedure feedback of a biomechanical deformable registration volumetric image method during percutaneous ablation will increase the minimal ablation margins on a three-dimensional computed tomography-generated analysis. Funding: NIH R01CA235564.

**MRI Guided Brachytherapy for HPV-Associated Cervical and Vaginal Malignancies (PI: Ann Klopp, MD, PhD) –**

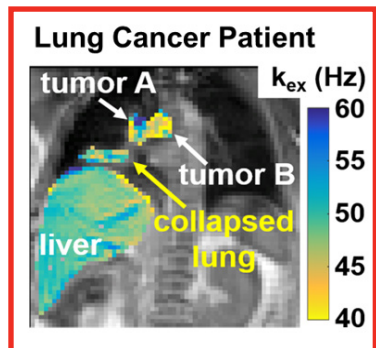
This prospective single-arm trial studies how well magnetic resonance imaging (MRI)-guided internal radiation therapy (brachytherapy) works in treating participants with human papillomavirus (HPV) associated stage IB2-IV cervical or stage II-IVA vaginal cancer. The primary object is to determine whether MRI guidance during brachytherapy applicator placement improves the dose to 90% of the high-risk clinical target volume compared to conventional guidance, with ultrasound and freehand technique, for patients with cervical and vaginal cancer. Funding: NIH P30CA016672.

## High Precision Tumor Targeting

Regardless of focal therapy intervention – radiation, surgical excision, or focal ablation – precisely identifying the target, developing a personalized treatment plan, and accurately executing the best possible treatment is crucial to ensuring local control and overall survival. Collaborations between imaging scientists and clinicians drive the development of innovative imaging techniques to identify the heterogeneity within the tumor and the precise boundaries of its extent. Multidisciplinary alliances between clinicians, scientists, and, in many instances industry partners, enable the translation of the information obtained on these high-precision targets into the treatment room through image guidance.

### Development and Dissemination of Clinical CEST MRI Acquisition and Analysis Methods for Cancer Imaging Applications (PIs: Jingfei Ma, PhD and Mark Pagel, PhD)

– The PIs are developing new acquisition and analysis methods to assess tumor acidosis with Chemical Exchange Saturation Transfer (CEST) MRI, using exogenous CEST agents and endogenous sources of CEST contrast. These new methods will be used to track tumor acidosis in response to chemotherapy and radiation therapy in patients with breast and head and neck cancers. In addition, the endogenous CEST MRI can improve the diagnosis of brain tumor recurrence vs pseudo-progression. Funding: NIH R01CA231513.



**DECT silicon image-guided therapy, monitoring and personalized dosimetry of Oncosil™ (PIs: Rick Layman, PhD)** – Dr. Layman is collaborating with a multidisciplinary team, including radiation oncologists and radiologists, to develop quantitative dual energy CT silicon imaging of silicon microparticles implanted with P-32 to improve delivery, monitor post-therapy efficacy and more accurately perform personalized dosimetry. Funding: MD Anderson Institutional Research Grant and collaboration with Oncosil Medical.

**Feasibility study of anatomical modeling for image-guided thoracic surgery (PIs: Guillaume Cazoulat, PhD and Ravi Rajaram, MD)** – This collaboration aims to expand the use of minimally invasive surgery through the use of biomechanical models to predict the deflation of the lung during the resection process, enabling the localization of the nodules in the deflated lung. If this predicted nodule localization is proven to be accurate, the criteria for enrollment in minimally invasive surgical resection can be expanded, reducing the morbidity and mortality to patients. Funding: MD Anderson Institutional Research Grant and Cao Thoracic Cancer Research Fund.

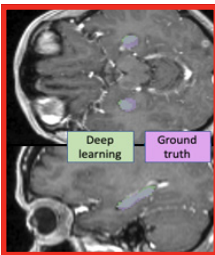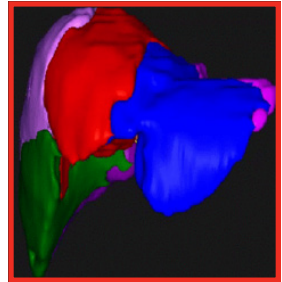
**An information-theoretic approach to understand advanced imaging for high-grade gliomas (PIs: James Bankson, PhD, David Fuentes, PhD, and Dawid Schellingerhout, MD)** – This multidisciplinary team has demonstrated that pathologic grade can be predicted with a high accuracy using clinical imaging data and machine learning. Recent funding by the NIH will expand this work to develop an information-theoretic approach to optimize the acquisition strategy for hyperpolarized pyruvate imaging to differentiate between low and high-grade malignant gliomas. Innovative methods will be employed to identify measurements that are information rich with respect to the biophysical model of the imaging signal. Funding: NIH R01 CA194391 and R01 CA160736 and a training fellowship from the Gulf Coast Consortia.

## Sparing Critical Normal Tissue

---

For the treatment of many tumors, avoidance of critical normal tissue is just as challenging – and important – as targeting the tumor. The development of novel imaging techniques to characterize the function of normal tissue is a key strategic aim of the IGCT Program. In addition, during image guided treatment planning and execution, the efficient and accurate identification of normal tissues is being accelerated through the development of 2D and 3D deep learning tools. Here are some examples!

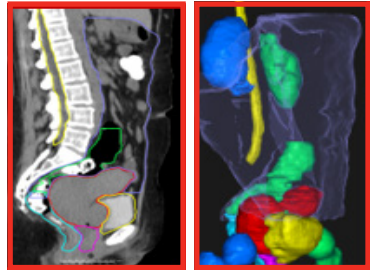
**Liver CT (PIs: Kristy Brock, PhD, Eugene Koay, MD, PhD, Bruno Odisio, MD)** – A multi-Division (DI, Surgery, and Radiation Oncology) effort has focused on the automatic segmentation of the liver and the individual liver segments on both contrast enhanced and non-contrast CTs. This algorithm, developed by GSBS student, Brian Anderson, has been commissioned and clinically deployed in Radiation Oncology, is used in an Interventional Radiology clinical trial, and is undergoing commissioning for use in surgery. Funding: NIH R01CA221971 and NIH R01CA235564



**Brain, MRI (PIs: Kristy Brock, PhD, Caroline Chung, MD)** – Work is underway to segment normal tissues on T1 post-contrast MR images to assist with radiation therapy, anatomical modeling for surgical guidance, and image guided biopsy. Funding: Marnie Rose Foundation

**Head and Neck, MRI (PIs: C. David Fuller, MD, PhD, Katherine Hutcheson, PhD, Stephen Lai, MD, PhD)** – The development of novel applications of dynamic contrast-enhanced MRI (DCE-MRI) to detect altered bone vascularity associated with bone healing, necrosis, and metastatic involvement for head and neck cancer patients is driven by a multi-disciplinary team collaboration. This translational research will evaluate the potential of DCE-MRI to identify patients at risk for mandibular osteoradionecrosis, which occurs in up to 16% of patients. In addition, the role of multi-parametric MRI to monitor response standard therapies, assess normal tissue toxicity, and assist in surgical planning will be investigated. Funding NIH R01 DE025248; R01 CA218148; and R01 CA214825

**Female Pelvis, CT (PIs: Kristy Brock, PhD, Laurence Court, PhD, Ann Klopp, MD, PhD)** – Two outstanding trainees, Bastien Rigaud, PhD, and DJ Rhee, have developed deep learning-based methods to segment the normal tissue in the female pelvis. The tools will be used to advance adaptive radiotherapy and expand the use of radiotherapy throughout the world. All 12 normal tissue structures in the pelvis can now be segmented with an accuracy consistent with inter-observer variability of manual segmentations. Funding: NIH UH3CA202665

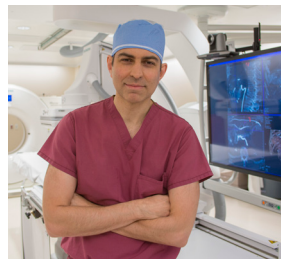
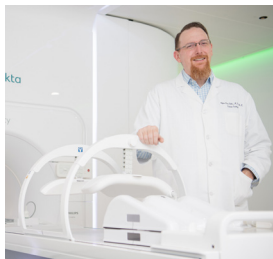
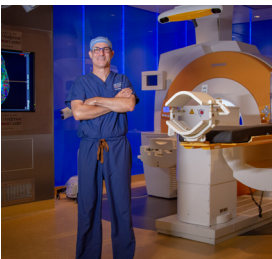**Male Pelvis, MR (PIs: Steven Frank, MD, Jingfei Ma, PhD)** – Jeremiah Sanders, PhD, under the mentorship of Drs. Frank and Ma, has developed a fully convolutional network to segment the prostate, seminal vesicles, external urinary sphincter, rectum, and bladder on MR images, in collaboration with a multi-disciplinary team. This technology will have clinical impact in the treatment of prostate cancer using MRI-guided brachytherapy. In addition to the pelvic anatomy, the team has also developed a sliding-window convolutional neural network to identify radioactive seeds on MRI after permanent implant brachytherapy. Funding: Pauline Altman-Goldstein Foundation Discovery Fellowship

## Demonstrating Significant Improvement in Local Control and Quality of Life

The ultimate goal of the Image Guided Cancer Therapy Research Program is to significantly improve local control and quality of life in cancer patients undergoing focal therapy. To accomplish this goal, not only must technology innovations be developed, they must be translated into clinical trials to objectively determine their impact on local control and quality of life. We must ensure that every innovation strives to develop innovative approaches that are more effective – improved local control, less invasive – improved quality of life, and more economical – ensuring widespread adoption to impact all cancer patients, so that we can improve cancer care, not only at MD Anderson, but around the world.

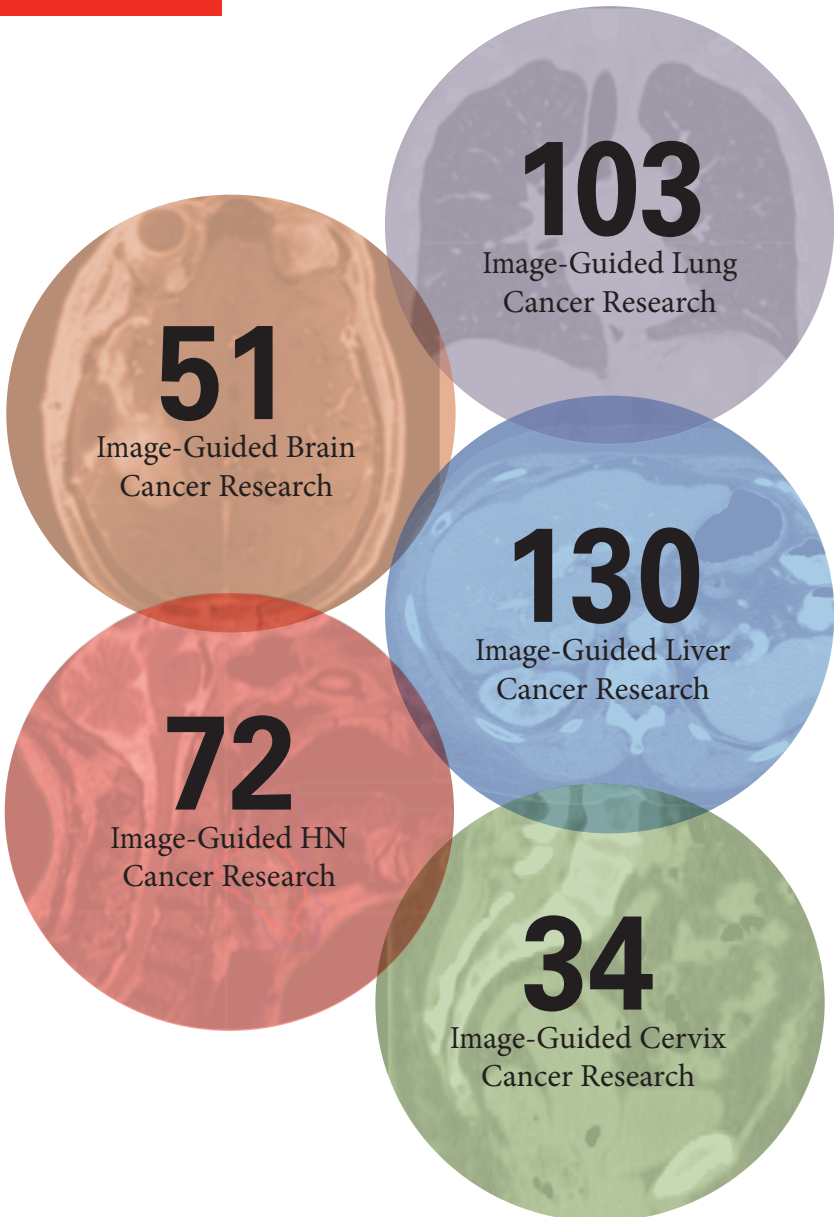
In the three years since the creation of the IGCT, several clinical trials have begun with primary and secondary endpoints to evaluate local control and quality of life. We eagerly await the conclusion of these trials within the next 3 – 5 years. In addition, numerous trials are under development to tackle additional tumor sites using image guided surgery, radiation therapy, and interventional radiology techniques.



*Photos: October 2019*

## Publications in the first 3 years

---



## Image-Guidance for Brain Cancer

Multi-disciplinary research in image-guided brain cancer has focused on integrating the imaging data throughout the multi-disciplinary treatment process. This includes validating the imaging data with the histopathology information to validate the imaging signals and translating this data to improve the surgical resection of the tumor; translating the surgical resection information to the radiation therapy treatment planning process and enabling personalized adaptive treatment; finally correlating the comprehensive treatment with the patient outcomes, including local control and normal tissue toxicities.

**Optimizing imaging for diagnosis, delineation, and staging** – An incredible amount of work has been done by IGCT members to harness the power of artificial intelligence and advanced imaging to diagnosis and delineate brain tumors and identify the heterogenous grade throughout the tumor. A strong collaboration between Imaging Physics, Diagnostic Radiology, and Radiation Oncology, led by Drs. Jing Li and Jingfei Ma was established to develop a computer aided detection algorithm for brain metastases for stereotactic radiosurgery (1). Sara Thrower, PhD, the first “IGCT Fellow” worked jointly with Drs. Kristy Brock and Caroline Chung to establish evidence-based guidelines for the minimum imaging slice thickness required for accurate delineation of brain tumors (2). Evan Gates, a Gulf Coast Consortia Training Fellow demonstrated that while local pathological grade can be predicted with a high accuracy using clinical images, advanced imaging data can further improve this accuracy, in a study led by Drs. David Fuentes and Dawid Schellingerhout (3).

**Improving treatment through image guidance** – An extensive multi-disciplinary team of clinicians and scientists have engaged in exciting translational research to improve the acquisi-



tion, analysis, and integration of imaging to guide the delivery of cancer treatment. A lively brainstorming session was hosted by the IGCT to capture the needs of clinicians to improve their ability to effectively treat brain cancer patients. This session led to several initiatives, some of which are highlighted here.

Sara Thrower, PhD, joined the IGCT program working jointly between surgery, radiation oncology, and diagnostic imaging. In her collaborative work with Drs. Rick Layman and Jeffrey Weinberg, she optimized the acquisition of vascular imaging to improve the surgical planning of brain tumors.

Funding from the Marnie Rose Foundation and the MD Anderson Institutional Research Grant has enabled Dr. Caroline Chung to investigate the use of serial multiparametric MRI to personalize radiation therapy to target the area of highest risk of tumor recurrence while sparing critical normal tissues by leveraging adaptive techniques. Collaborations with the IGCT Program is facilitating the development of the automated segmentation and deformable registration processes necessary to achieve the precision required for this personalized treatment (4).

Generous funding from the Apache Foundation has enabled research focused on understanding how the brain shifts during neurosurgery and the development of biomechanical models to describe this motion using an approach that is accurate and efficient enough to translate into the clinical environment.

Drs. Ho-Ling (Anthony) Liu, Kyle Noll, Sujit Prabhu and their team discovered that neurocognitive changes of patients following brain tumor resection are associated with changes in brain connectomics measured by functional MRI. This builds a strong foundation for our direction on developing a brain connectome-based virtual surgery system for predicting patient outcomes after neurosurgery (5).

1. Zhou Z, Sanders JW, Johnson JM, et al. Computer-aided Detection of Brain Metastases in T1-weighted MRI for Stereotactic Radiosurgery Using Deep Learning Single-Shot Detectors. *Radiology*. 2020;295(2):407-415. doi:10.1148/radiol.2020191479
2. Thrower SL, et al, The impact of slice thickness on contours of brain metastases for stereotactic radiosurgery, *Practical Radiation Oncology*, 2020, Submitted.
3. Gates EDH, Lin JS, Weinberg JS, et al. Imaging-Based Algorithm for the Local Grading of Glioma. *AJNR Am J Neuroradiol*. 2020;41(3):400-407. doi:10.3174/ajnr.A6405
4. M. McCulloch, et al, SSG15-09 Biomechanical model-based deformable image registration for glioma patients, presented at RSNA Annual Meeting, Chicago, IL, 2018
5. Noll KR, et al. Alterations in functional connectomics associated with neurocognitive changes following glioma resection. *Neurosurgery*. Accepted.

## Image-Guidance for Head and Neck Cancer

The primary focus of the multi-disciplinary team of Head and Neck Cancer clinicians and scientists has been to improve the detection, treatment, and prevention of therapy- and disease-related injury to normal tissue, improving outcomes by reducing sequelae while preserving or enhancing rates of cancer cure. This research has spanned from preclinical research to innovative clinical trials and brings together researchers from numerous divisions including diagnostic imaging, radiation oncology, surgery, and biostatistics.

**Optimizing imaging for diagnosis, delineation, and staging** – The multi-disciplinary IGCT team has successfully developed, optimized, and demonstrated the impact of advanced imaging for the detection of toxicity in head and neck cancer. Drs. Clifton Fuller and Stephen Lai led the investigation into the characterization and quantification of dynamic contrast enhanced (DCE)-MRI parameters associated with advanced mandibular osteoradionecrosis (ORN). Their recently published results confirmed a significantly higher degree of leakiness in the mandibular vasculature as measured using DCE-MRI parameters in advanced ORN, compared to healthy mandible. (1)

Dr. Carlos Cardenas, a recent graduate from the GSBS Medical Physics program and new Assistant Professor and member of the IGCT, demonstrated the power of convolutional neural networks to automatically segment the clinical target volumes for oropharyngeal cancer, under the mentorship of Dr. Laurence Court. The evaluation of their model on an independent test set demonstrated a high degree of overlap and a close surface distance agreement compared to the ground truth contours. (2)

### **Improving treatment through image guidance** –

Through a multi-disciplinary and multi-institutional collaboration, Dr. Molly McCulloch, a post-doctoral fellow under the mentorship of Dr. Kristy Brock, investigated the deviations between the planned and accumulated doses in head and neck cancers treated with radiation therapy to predict clinically significant dosimetric deviations during treatment to evaluate the potential need to adapt treatment. This study was the first to provide clinical guidance, validated through multi-institutional data, of this dose deviation threshold. (3)

As one of the first radiation oncology departments to have an MR-guided LINAC installed, Dr. Abdallah Mohamed investigated the feasibility and dosimetric advantages of MRI-guided dose adaptation for human papillomavirus positive oropharyngeal cancer patients compared with standard intensity modulated radiation therapy, under the mentorship of Dr. Clifton Fuller and in collaboration with the MD Anderson MRLinAc Development Working Group. This in silico study demonstrated that the proposed MRI-guided adaptive approach is technically feasible and advantageous in reducing dose to organs at risk, especially swallowing. This work has now been translated into a clinical trial. (4)

**Predicting toxicity using artificial intelligence** – Exciting early results are demonstrating use of convolutional layers joined by residual connection to extract features and feed into densely connected layers along with clinical factors to predict occurrence of ORN. This work, a collaboration between Drs. Kristy Brock, Clifton Fuller, and Stephen Lai, is being performed by GSBS graduate student Brandon Reber.

1. Mohamed ASR, He R, Ding Y, et al. Quantitative Dynamic Contrast-Enhanced MRI Identify Radiation-Induced Vascular Damage in Patients with Advanced Osteoradionecrosis: Results of a Prospective Study. *Int J Radiat Oncol Biol Phys.* 2020;S0360-3016(20)31448-6. doi:10.1016/j.ijrobp.2020.07.029
2. Cardenas CE, Anderson BM, Aristophanous M, et al. Auto-delineation of oropharyngeal clinical target volumes using 3D convolutional neural networks. *Phys Med Biol.* 2018;63(21):215026. Published 2018 Nov 7. doi:10.1088/1361-6560/aae8a9
3. McCulloch MM, Lee C, Rosen BS, et al. Predictive Models to Determine Clinically Relevant Deviations in Delivered Dose for Head and Neck Cancer. *Pract Radiat Oncol.* 2019;9(4):e422-e431. doi:10.1016/j.prro.2019.02.014
4. Mohamed ASR, Bahig H, Aristophanous M, et al. Prospective in silico study of the feasibility and dosimetric advantages of MRI-guided dose adaptation for human papillomavirus positive oropharyngeal cancer patients compared with standard IMRT. *Clin Transl Radiat Oncol.* 2018;11:11-18. Published 2018 May 5. doi:10.1016/j.ctro.2018.04.005

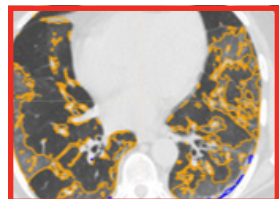
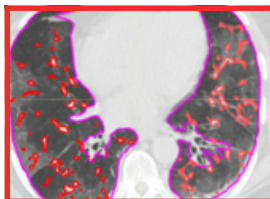
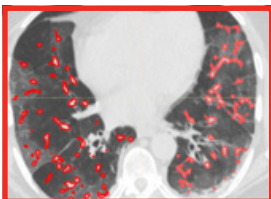
## Image-Guidance for Lung Cancer

---

Multi-disciplinary research in image-guided lung cancer has focused on expanding the use of minimally invasive surgery and improving our understanding of the delivered dose in radiation oncology, and the correlation of delivered dose with radiographic indications of normal lung toxicity. We have been fortunate to receive a generous donation to fund the pilot work in image-guided lung surgery. This work has also been leveraged to assist in the iD3CODE initiative for evaluating the CT images of COVID-19 positive patients.

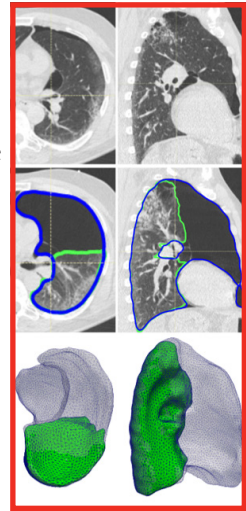
### Optimizing imaging for diagnosis, delineation, and staging

– A multi-disciplinary team of clinicians and scientists have partnered in the IGCT to advance the segmentation of the lung, especially in the presence of pathologies, the vascular structure within the lung, and the tumor. The importance of this work was amplified with the onset of the COVID-19 pandemic. The figure below demonstrates the automatic segmentation of lung vasculature (left) by Dr. Guillaume Cazoulat, the development of a convolutional neural network to segment the lung in the presence of complex pathologies (middle), by Dr. Bastien Rigaud and Brian Anderson under the mentor of Dr. Kristy Brock, and the identification of ground glass and consolidation (right) by Yulun He (GSBS graduate student under the mentorship of Dr. Brock), in collaboration with Drs. Myrna Godoy and Carol Wu and the iD3CODE team at MD Anderson.



### Improving treatment through image guidance

– Drs. Guillaume Cazoulat and Ravi Rajaram are pioneering an innovative strategy to expand the use of minimally invasive surgery. Using patients who presented with large pneumothorax following lung biopsy, shown on the right, they demonstrated the accuracy of biomechanical models to describe the deflation of the lung, as demonstrated through CT images. In these cases, large volume changes and deformation of the lung were observed, similar to the surgical scenario. In this initial evaluation, an accuracy of better than 1 cm could be achieved. Work is ongoing to further improve these models in preparation of the early phase clinical trial. (1)



**Advancing image-based outcomes assessment** – Understanding the relationship between a delivered focal therapy and any potential normal tissue toxicity is critical for the development and validation of novel methods to reduce or eliminate them. Yulun He, under the mentorship of Drs. Kristy Brock and Radhe Mohan, in collaboration with Drs. Zhongxing Liao and Carol Wu, is developing a novel approach to perform voxel-level dose accumulation of the delivered radiation therapy dose and precisely link this dose with the radiographic response of the normal lung. To date, his work has demonstrated that the deformation of average 4DCT images for dose accumulation should not be used when the breathing motion exceeds 10 mm, as the uncertainties exceed the recommendations set by the American Association of Physicists in Medicine. Building on this knowledge to accurately accumulate the delivered dose, his early work has indicated that there may be a meaningful difference between the planned and accumulated dose when evaluating the correlation between dose and radiographic evidence of lung toxicity.

1. Lesage AC, Rajaram R, Tam A, et al. Preliminary evaluation of biomechanical modeling of lung deflation during minimally invasive surgery using pneumothorax computed tomography scans, under review, Phys Med Biol, 2020.

## Image-Guidance for Liver Cancer

---

Research by the IGCT on image-guidance for liver cancer is an excellent demonstration of the collaborative nature of the program and the strong record of IGCT-technology translating directly to patient care. The IGCT liver team has focused on developing advanced image analysis techniques, advancing image guidance techniques to improve local control, understanding therapeutic response to focal therapy, and improving quality in image acquisition.

**Optimizing imaging for diagnosis, delineation, and staging** – An AI algorithm was developed by Brian Anderson, a graduate student mentored by Dr. Kristy Brock, in collaboration with Drs. Eugene Koay and Bruno Odisio. Three innovative algorithms automatically segment the liver, disease, and focal ablation region after therapy. The liver segmentation algorithm has been clinically commissioned and deployed in Radiation Oncology, where it has been used nearly 1000 times, and is currently being expanded to include segmentation of the liver lobes, which will enable its use for liver surgery. (1)

These automated segmentation technologies have enabled Dr. Moiz Ahmad to investigate the development of a system to automatically score the image quality of every diagnostic imaging exam performed. By using automatically extracted image quality metrics of image noise, blood vessel enhancement, blur due to patient motion, and the presence or artifact validated against observer assessments, this goal can be systematically applied in the clinic, eliminating the need for patient recalls and additional imaging.

Innovative research led by Dr. Eugene Koay in collaboration with Drs. Peter Park, Jingfei Ma, Eric Tamm, and Sam Beddar, is developing a novel enhancement pattern mapping technique to improve detectability of hepatobiliary tumors on CT. (2)

**Improving treatment through image guidance** – Current rates of local recurrence at lesions treated with liver ablation are reported to be around 25%. One of the main factors associated with this high recurrence rates is the inability to properly access intra-procedurally whether sufficient ablation tumor coverage was achieved. The use of advanced intra-procedure image guidance (Morfeus, a biomechanical model-based registration algorithm developed in Dr. Kristy Brock's lab) will allow the interventional radiologist to assess proper tumor targeting and whether sufficient ablation margins were achieved, potentially providing improved tumor coverage and reducing local recurrence rates. This hypothesis will be tested in a randomized Phase II clinical trial, which recently opened at MD Anderson. Dr. Brock and Dr. Odisio will work in close collaboration with other key personnel including Dr. Kyle Jones and Dr. Guillaume Cazoulat of Imaging Physics. The grant is an NIH funded Academic Industry Partnership with RaySearch Laboratories, which will help to ensure clinical translation.

**Advancing image-based outcomes assessment** – The development of a robust and accurate automatic segmentation of the liver has enabled the expansion of biomechanical model-based registration for evaluation of therapeutic response. In a collaboration between Drs. Kristy Brock and Eugene Koay, the evaluation of current, clinically available deformable registration algorithms was performed, demonstrating the need for improved algorithms. (3) These algorithms are critical to evaluate the correlation of delivered dose with image-based toxicity, such as changes in DCE-MRI parameters. A collaboration between Drs. Brock, Cazoulat, and Koay pursued the development of a vasculature-driven biomechanical model to accurately provide this correlation. This advanced algorithm provides improved results, even in cases are large and complex deformation. (4)

1. Anderson BM, et al. Automated Contouring of Contrast and Noncontrast Computed Tomography Liver Images With Fully Convolutional Networks, *Advances*, May 16, 2020, <https://doi.org/10.1016/j.adro.2020.04.023>
2. Park PC, et al. Enhancement pattern mapping technique for improving contrast-to-noise ratios and detectability of hepatobiliary tumors on multiphase computed tomography. *Med Phys.* 2020;47(1):64-74. doi:10.1002/mp.13769
3. Sen A, et al. Accuracy of deformable image registration techniques for alignment of longitudinal cholangiocarcinoma CT images. *Med Phys.* 2020;47(4):1670-1679. doi:10.1002/mp.14029
4. Cazoulat G, et al. Vasculature-Driven Biomechanical Deformable Image Registration of Longitudinal Liver Cholangiocarcinoma Computed Tomographic Scans. *Adv Radiat Oncol.* 2019;5(2):269-278. Published 2019 Oct 17. doi:10.1016/j.adro.2019.10.002

## Image-Guidance for Cervix Cancer

---

Multi-disciplinary research in image-guided lung cancer has focused on expanding the use of minimally invasive surgery and improving our understanding of the delivered dose in radiation oncology, and the correlation of delivered dose with radiographic indications of normal lung toxicity. We have been fortunate to receive a generous donation to fund the pilot work in image-guided lung surgery. This work has also been leveraged to assist in the iD3CODE initiative for evaluating the CT images of COVID-19 positive patients.

**Optimizing imaging for diagnosis, delineation, and staging** – The emergence of deep learning for segmentation and automation in treatment planning has been a focus of research in cervix cancer. The applications of this work focus on two critical areas: facilitating the treatment of cervical cancer patients in low- and middle-income countries with limited resources and enabling the investigation of personalized, high precision adaptive radiotherapy to reduce toxicities. Drs. Kristy Brock and Laurence Court have partnered in these initiatives.

DJ Rhee, a GSBS graduate student under the mentorship of Dr. Court, has developed a convolutional neural network for the automatic contouring of clinical treatment volumes and normal tissues. (1) These contours can then be used to automatically optimize beam weights for 3D conformal plans.

Dr. Bastien Rigaud, a post-doctoral fellow under the mentorship of Dr. Brock, developed a convolutional neural network to segment the normal tissues and primary target volume and integrated this into an automated process to perform online adaptive planning. Online adaptive radiotherapy can enable reduced uncertainty margins, which we hypothesize will lead to significantly lower rates of toxicity while maintaining local control. A randomized clinical trial is being planned to investigate. (2)



### **Improving treatment through image guidance** –

Drs. Ann Klopp and Aradhana Venkatesan have led a highly multi-disciplinary team in the development of an intraoperative 3T MRI-guided brachytherapy program within a diagnostic imaging suite. Careful development of the methods, process workflow, and value-based analysis demonstrates the feasibility of this approach, where clinical trials are now ongoing to evaluate the improvement in the therapeutic ratio for gynecologic cancers. (3)

Modeling the complex changes in anatomy in the pelvis, especially the sigmoid colon, between external beam radiotherapy and brachytherapy has limited the ability to quantify the total dose delivered to critical normal tissues. In a study by Dr. Bastien Rigaud, an innovative method was developed to preserve the topology of the sigmoid colon while accurately correlating the geometric location in both instances. The dosimetric analysis suggests that correctly accumulating the dose using these models could have a substantial impact on our understanding of the dose-toxicity relationship. (4)

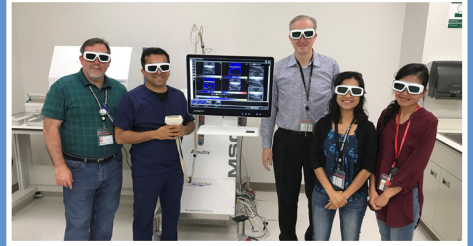
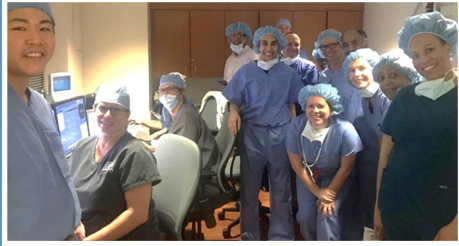

### **Advancing image-based outcomes assessment** –

Dr. Jennifer Ho, a resident under the mentorship of Dr. Klopp, investigated the utility of volumetric diffusion weighted MR imaging, relative to other clinical factors, in the ability to predict recurrence and survival following definitive chemoradiation in cervical cancer patients. In this retrospective study, apparent diffusion coefficient, determined from the MRI, was a significant predictor of both progression free survival and distant metastasis free survival, independent of standard clinical factors. These results, which must be confirmed in prospective trials, have the potential to identify patients which require treatment intensification. (5)

1. Rhee DJ, Jhingran A, Rigaud B, et al, Automatic contouring system for cervical cancer using convolutional neural networks, *Medical Physics* (Submitted 2020)
2. Rigaud B, Anderson B, Yu Z, et al, Automatic segmentation using deep learning for online dose optimization during adaptive radiotherapy of cervical cancer, *International Journal of Radiation Oncology, Biology, Physics* (Submitted 2020).
3. Ning MS, Venkatesan AM, Stafford RJ, et al. Developing an intraoperative 3T MRI-guided brachytherapy program within a diagnostic imaging suite: Methods, process workflow, and value-based analysis. *Brachytherapy*. 2020;19(4):427-437. doi:10.1016/j.brachy.2019.09.010
4. Rigaud B, Cazoulat G, Vedam S, et al. Modeling Complex Deformations of the Sigmoid Colon Between External Beam Radiation Therapy and Brachytherapy Images of Cervical Cancer. *Int J Radiat Oncol Biol Phys*. 2020;106(5):1084-1094. doi:10.1016/j.ijrobp.2019.12.028
5. Ho JC, Fang P, Cardenas CE, et al. Volumetric assessment of apparent diffusion coefficient predicts outcome following chemoradiation for cervical cancer. *Radiother Oncol*. 2019;135:58-64. doi:10.1016/j.radonc.2019.02.012

## Image-Guidance Cancer Therapy

It has been an exciting first 3 years for the Image Guided Cancer Therapy Research Program. We have made a substantial amount of progress toward our vision of **local regional tumor control and reduced toxicities**, but we still have a long way to go! The enthusiastic support for multi-disciplinary collaboration between physicians and scientists was clear – and the results have already enabled the translation of technology into the clinic and the initiation of clinical trials to improve patient care. The executive committee looks forward to expanding the targeted anatomical sites as we move forward to the next phase of the program. We will continue to focus on training the next generation of clinicians and scientists through this program. We are proud to demonstrate that IGCT research program achieves its mission to increase collaboration across the institution, with IGCT faculty having a 50% higher publication connectivity compared to the faculty as a whole. In the next 3 years, we look forward to seeing the results of the ongoing clinical trials and **achieve our strategic goal of demonstrating a significant improvement in the local control and quality of life of cancer patients**. The success of the program is the result of the involvement of innovative leaders in image-guided therapy, our members, combined with the support from our generous donors, foundations, and grant support. Together, we will continue to develop innovative, integrated imaging platforms that are more effective, less invasive, and economical for our patients here at MD Anderson and around the world. For more information please visit our website at [www.mdanderson.org/IGCT](http://www.mdanderson.org/IGCT)



All images were taken prior to the COVID-19 pandemic

