



# Imaging brain tumors with ferumoxtran-10, a nanoparticle magnetic resonance contrast agent

Tulio P Murillo,  
Chloe Sandquist,  
Paula M Jacobs,  
Gary Nesbit,  
Sandor Manning &  
Edward A Neuwelt<sup>†</sup>

<sup>†</sup>Author for correspondence  
Oregon Health & Sciences  
University, OR, USA  
Tel.: +1 503 494 5626  
Fax: +1 503 494 5627  
neuwelte@ohsu.edu

**Background:** Ultrasmall superparamagnetic particles of iron oxide are magnetic resonance contrast agents that are gaining use in the CNS. These agents accumulate in phagocytic cells such as reactive astrocytes and macrophages. **Aim:** We aimed to describe the use of ferumoxtran-10, an ultrasmall superparamagnetic particle of iron oxide, in brain tumor imaging and detail the results in a series of 55 patients with intracranial tumors. **Results:** In 19 out of 34 glial tumors, ferumoxtran-10 enhanced as much as (n = 9) or more than gadolinium (n = 10). In the nonglial tumors group, seven out of 22 tumors enhanced as much as (n = 2) or more than gadolinium (n = 5). **Conclusion:** Ferumoxtran-10-enhanced magnetic resonance can add information to gadolinium-enhanced magnetic resonance, especially in identifying the inflammatory component and blood-brain barrier compromise involved in infiltrating malignant brain tumors.

## Iron oxide contrast agents

Magnetic resonance imaging (MRI) of the CNS is usually performed with gadolinium (Gd; Magnevist<sup>®</sup>)-based contrast agents, which are low-molecular weight extracellular chelated agents with a short half-life, giving rapid and transient imaging of brain and spinal cord permeability. Superparamagnetic iron oxide (SPIO) and ultrasmall superparamagnetic iron oxide (USPIO) nanoparticle magnetic resonance contrast agents have also shown excellent potential for imaging in the CNS. These iron oxide-based agents include the clinically approved SPIO agent ferumoxides (Feridex IV, Endorem<sup>®</sup>) [1,2], the investigational USPIO agent ferumoxtran-10 (Combidex<sup>®</sup>; Sinerem<sup>®</sup>) [3,4], and the newer USPIO agent ferumoxytol [5,6]. The agents consist of an iron oxide core with a variable coating that determines cellular uptake and biologic half-life. In the CNS, ferumoxtran-10 has been most widely investigated in brain tumors [7–9]. It is completely coated with native dextran, which protects against opsonization and endocytosis, and bestows a long plasma half-life of 24–30 h [2,4]. On magnetic resonance (MR) scans, the iron oxide agents demonstrate concentration-related signal loss on T2- and T2\*-weighted sequences. On T1-weighted sequences, lower concentrations of ferumoxtran-10 increase signal intensities, similar to that seen on Gd enhancement, while higher concentrations of ferumoxtran-10 will cause profound signal loss on T1-weighted images [10]. In addition, iron oxide particles can be identified at the light and electron microscopic levels, allowing pathologic evaluation of these CNS MRI agents.

## MRI of brain tumors using iron oxide contrast agents: preclinical data

Initial studies evaluated iron oxide particle delivery to normal brain after direct inoculation or blood-brain barrier (BBB) disruption [10,11]. Transvascular delivery of ferumoxtran-10 with osmotic BBB opening resulted in increased T1 signal enhancement throughout the disrupted hemisphere [12]. These studies demonstrated global delivery of iron oxide particles throughout the disrupted hemisphere as well as neuronal uptake without evidence of toxicity. These studies also showed that dextran-coated iron particles could be imaged reliably by MRI and would have utility in demonstrating areas of BBB dysfunction.

Several studies demonstrated enhancement on MRI in rat glioma models after intravenous administration of iron oxide particles [9,13,14]. The authors evaluated ferumoxtran-10-enhanced MRI in several rat brain tumor models [12]. Significant enhancement was observed after intravenous administration of ferumoxtran-10 in the LX-1 small-cell lung cancer (SCLC) xenograft model. These tumors show significant uptake of iron particles into cells both within the tumor and in the brain around the tumor, and are particularly prominent around the necrotic areas. Most of the iron-loaded cells appear to be macrophages, but some cells show processes suggestive of astrocytes. In contrast, little enhancement was seen in either the U87 glioma model, or in a second SCLC intracerebral tumor model. Therefore, ferumoxtran-10 enhancement and uptake was dependent upon

**Keywords:** ferumoxtran-10, glioma, inflammation, magnetic resonance contrast agents, metastatic brain tumors, ultrasmall superparamagnetic iron oxide



Future Drugs Ltd

intracerebral tumor type. Based on the histopathology of each tumor it is hypothesized that areas of necrosis or even apoptotic cell death with macrophage or reactive astrocyte infiltration or gliosis, are necessary for ferumoxtran-10 imaging of brain tumors. The mechanism for ferumoxtran-10 MR enhancement appears to be leakage across a damaged BBB followed by intracellular trapping by phagocytic cells (astrocytes, macrophages) in and around the tumor rather than by tumor cells themselves [8,15,16].

#### *Clinical trials using ferumoxtran-10 to image brain tumors*

The superparamagnetic iron oxide agents, particularly ferumoxtran-10, are gaining clinical use for tumor imaging, both systemically and in the brain. They can be useful in differentiating between malignant and benign lymph nodes [3,4,17], as well as in MR angiography and perfusion imaging of the brain and heart [5,6,18–20]. In reactive brain lesions, the iron oxide agents may detect active inflammatory or demyelinating lesions after iron uptake in perivascular macrophages [21–23]. More recently, several studies have looked at ferumoxtran-10-enhanced MRI of brain tumors. Early studies demonstrated the prolonged enhancement of brain tumors after USPIO administration when compared with standard Gd [7]. Delayed MRI (24–48 h) following administration of ferumoxtran-10 has been reported to show additional areas of enhancement in brain tumors that were not observed with Gd, particularly in areas where reactive inflammatory cells were present [8,16]. Prolonged enhancement of brain tumors (up to 7 days) in patients was associated with progressive accumulation of ferumoxtran-10 in reactive astrocytes and macrophages rather than tumor cells [8,16]. In a companion study ferumoxtran-10 was compared with Gd-enhanced MR to assess its potential in the evaluation of a variety of CNS inflammatory lesions [24]. Ferumoxtran-10 showed different enhancement patterns in a variety of CNS inflammatory lesions in comparison with Gd. In particular, some cases of lymphomas and ischemic lesions became more clearly enhanced. These observations and preclinical data suggest that ferumoxtran-10-enhanced MR added to the usual Gd-enhanced MR may identify those part(s) of the lesion that contain both reactive inflammatory changes and a BBB defect, thereby helping differentiate portions of a lesion with and without inflammatory reaction. This may have implications for targeting of diagnostic biopsies and the planning of surgical resections [25].

The following exploratory study is the authors' most recent clinical trial, which evaluates the use of ferumoxtran-10-enhanced MRI of brain tumors.

## **Methods**

### *Patients*

This is a prospective descriptive study of 55 patients with 56 intracranial lesions collected from December 1999 to October 2004. The study was approved by the authors' Institutional Review Board and conducted with an Investigational New Drug from the US Food and Drug Administration (FDA). All patients provided informed consent. The inclusion criteria were patients who were stable and had an intracranial neoplasm (non-neoplastic lesions will be reported elsewhere). No patients were experiencing rapid progression of their tumors. Patients with a history of allergies to iron, iron overload or any advanced-stage diseases were excluded, as were pregnant or lactating females. Also excluded were patients with pacemakers, ferromagnetic aneurysm clips or psychiatric disorders. The patients were classified in two groups based on the type of tumor, glial tumors (n = 34) and nonglial tumors (n = 22).

### *Procedures*

Each patient had a complete physical exam with basic hematologic and metabolic blood work, as well as serum iron, serum ferritin and iron-binding capacity. The baseline Gd MRI was obtained within 28 days before the ferumoxtran-10 exam. Each patient then received an infusion of ferumoxtran-10 over 30 min and was monitored for 2 h. The post-ferumoxtran-10 MRI was obtained 24 h after the infusion; the imaging time was based on a previous timing study [8]. Patients undergoing surgical procedures had the infusion 24–48 h before surgery and the post-ferumoxtran-10 MR was obtained before surgery. One follow-up visit was scheduled 30 days after the infusion. In all cases where surgery was performed, tumor cells colocalized with iron staining; most of the iron particles were seen inside the inflammatory cells, some particles were seen in tumor cells.

### *Contrast agents*

Gd-DTPA or an equivalent was used at a standard clinical dose (0.1 mmol/kg). Ferumoxtran-10 was administered intravenously, at a dose of 2.6 mg/kg, diluted in 50 or 100 ml of normal saline infused over 30 min to minimize

**Table 1. Comparison of ferumoxtran-10 and gadolinium chelate.**

Feature	Ferumoxtran-10	Gadolinium (Magnevist®)
Basic element	Iron oxide [1]	Gadolinium
Molecular composition	Iron oxide coated with dextran [1]	Gadolinium chelated with diethylenetriamine pentaacetic acid
R1 (mmol-sec) <sup>-1</sup>	23 [1]	4.5
R2 (mmol-sec) <sup>-1</sup>	53 [1]	5.7
Elimination plasma half-life	24–30 h [1]	1.6 h
Relative size of the particle	Approximately 30 nm [1]	0.357 nm
Permeability to intact BBB	Minimal	Minimal
Clinical significance of the enhancing area	Imaging sites of BBB abnormality mainly in the presence of inflammatory cells	Detects abnormalities in BBB and vascularity
Signal change on T1 sequence	High signal at low concentrations, low signal at higher concentrations [10]	High signal
Signal change on T2 sequence	Low signal	
Distribution	Intracellular in macrophages and reactive astrocytes	Extracellular
Optimal contrast time	From 24 h to 7 days after the infusion [7,8]	Within 27 min after injection
Imaging dose	2.6 mg of Fe/kg diluted in 100 ml (infusion)	0.1–0.3 ml/kg (0.1–0.3 mmol/kg)
Rate of administration	Infused over 30 min	10 ml/min or as bolus at 10 ml/15 s
Excretion	Stored with the body's iron reserve	Renal

*Relevant features of the two contrast agents used in this study. There are differences in size, half-lives, clinical significance of the enhanced areas, distribution (plasma half-life) and side effects. Gd is safe and can be given in multiple doses. Ferumoxtran-10 is given slowly to avoid pseudo-allergic reactions. A particle of ferumoxtran-10 is almost 100-times bigger than a Gd chelate.*

*BBB: Blood-brain barrier; Fe: Iron; Gd: Gadolinium.*

the possibility of adverse events. The main characteristics of these two agents are summarized in Table 1.

#### **Imaging technique & image evaluation**

Images were obtained using the standard technique for brain imaging with a 1.5 T general electric magnet [8,16]. All patients underwent MRI with a Gd-based agent (Omniscan or an equivalent) at least 24 h but no more than 28 days before ferumoxtran-10 infusion. Before Gd administration, spin-echo (SE) T1-weighted, fast SE T2-weighted and proton density sequences were performed and the (SE) T1-weighted sequence was repeated after Gd contrast administration. Patients were imaged 24 h after ferumoxtran-10 administration with the same sequences as the unenhanced and Gd-enhanced studies. Additionally, gradient-recalled echo (GRE) T2\*-weighted and in some cases diffusion-weighted images (DWI) sequences were performed for the ferumoxtran-10 studies.

Images were obtained with a 23 cm field of view and a 256 × 192 matrix. A neuroradiologist (Gary Nesbit), a radiologist (Sandor Manning) and two neurosurgeons (Edward A Neuwelt and Tulio P Murillo) compared the ferumoxtran-10- and Gd-contrasted images in a consensus evaluation. All sequences were evaluated by each individual; however, the case presentations are all T1-weighted images since T1 images clearly delineate the borders of the tumor, and are therefore easier to compare with Gd images.

One or more region(s) of interest (ROI) were chosen from the T1 Gd-enhanced MR (the main lesion seen on the scan). ROIs were qualitatively, not quantitatively, chosen. The same ROI was examined on the T1 ferumoxtran-10 scan and compared visually in volume, signal intensity and additional lesions observed distant to the ROI. Based on this qualitative comparison, the ferumoxtran-10 images were classified as:

**Table 2. Demographic data and treatment history.**

	Median age	Gender		Prior radiation		Prior chemotherapy	
		Male	Female	Yes	No	Yes	No
<b>Glial tumors*</b>							
GBM	54	10	4	5	9	7	7
Oligodendrogliomas	52	10	1	1	10	7	4
Anaplastic astrocytoma	54	4	0	3	1	1	3
Oligoastrocytoma	45	1	1	0	2	1	1
Low-grade glioma	33	2	0	0	2	1	1
Intermediate-grade glioma <sup>†</sup>	57	1	0	0	1	0	1
<b>Nonglial tumors</b>							
Lymphoma	57.5	6	2	1	7	3	5
Metastases	47.5	1	3	2	2	3	1
PNET	35.5	1	1	1	1	1	1
Meningioma	47.5	0	2	1	1	0	2
Epidermoid	30	0	1	0	1	0	1
Hamartoma	47	0	1	0	1	0	1
Hemangioblastoma	36	1	0	1	0	0	1
Pineocytoma	27	0	1	0	1	1	0
Pituitary adenoma	54	1	0	0	1	0	1
Squamous cell carcinoma	50	1	0	0	1	0	1
Subtotal		39	17	15	41	25	31

\*One of the 55 patients had two lesions.

<sup>†</sup>The definite pathology of this case was not available, which is the reason why he was not put into one of the mentioned categories for gliomas.

GBM: Glioblastoma multiforme; PNET: Primitive neuroectodermal tumors.

- Less: if the signal intensity or volume of enhancement in the ROI was less compared with the Gd scan
- Equal: degree and pattern of enhancement was similar with both agents
- More: if ferumoxtran-10 showed a higher signal or a larger area of enhancement compared with Gd or additional areas not seen on the Gd MR

If a patient had two or more lesions each with different degrees of enhancement, then the lesion that best enhanced with ferumoxtran-10 was selected.

**Results**

In total, 56 intracranial tumors in 55 patients (38 males and 17 females) were classified in two groups – glial tumors (n = 34) and nonglial tumors (n = 22). Demographic and treatment history are presented in Table 2. One patient in the glial tumor group had two different tumors. All patients had a histologically proven diagnosis.

No adverse events related to ferumoxtran-10 were observed in any of these patients. The histologic description of some of these surgical cases has been published and therefore will not be discussed in this review [16]. Some of these patients were either receiving or had received radiation and or chemotherapy at the time of the study as detailed in Table 2. The 15 patients who received radiation therapy completed this therapy before they were enrolled in this study.

Overall, the authors found T2 and T2\* images were less informative in the brain than T1 images. The GRE T2\* scans show increased apparent volume of iron due to the iron-induced magnetic susceptibility artifact or blooming, and the T2 images gave a mottled appearance. T2\* images also tend to give a larger volume of tumor than seen histologically [8,15,16]. The T1 images more clearly delineated the borders of the tumor.

In the glial tumor group (Table 3) are; glioblastoma multiforme (GBM; n = 14), oligodendrogliomas with different degrees of malignancy

**Table 3. Composition of the T1 signal intensity obtained using ferumoxtran-10 and gadolinium in glial tumors\*.**

	Ferumoxtran-10 contrast compared with Gd.			Total
	Less	Same	More	
Total	15	9	10	34
<b>By tumor type</b>				
GBM	6	2	6	14
Oligodendrogliomas	5	4	2	11
Anaplastic astrocytoma	2	0	2	4
Oligoastrocytoma	0	2	0	2
Low-grade glioma	1	1	0	2
Intermediate-grade glioma	1	0	0	1
<b>By treatment history</b>				
None	5	5	4	14
RT only	3	0	0	3
CT only	5	4	2	11
Both RT and CT	2	0	4	6

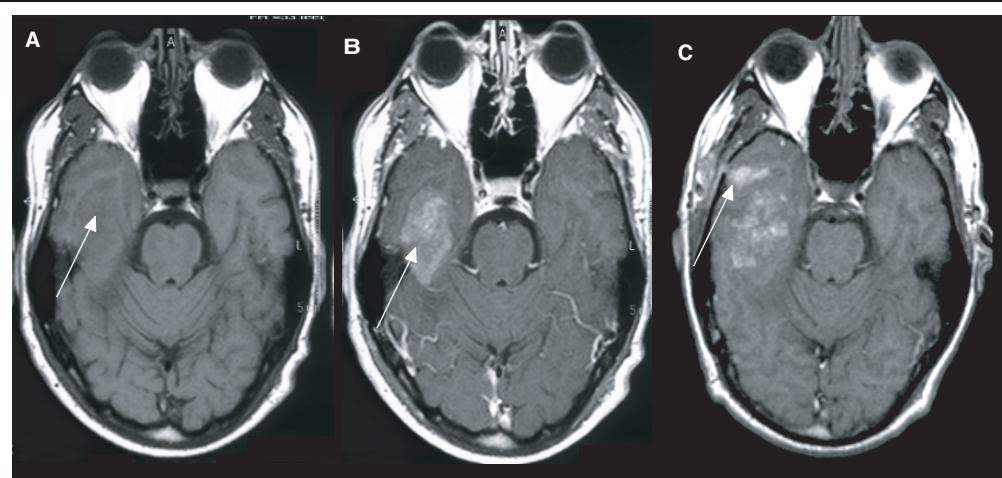
\*One patient in this series had both a pilocytic astrocytoma and an oligoastrocytoma. CT: Chemotherapy; GBM: Glioblastoma; RT: Radiotherapy.

(n = 11), anaplastic astrocytomas (n = 4), oligoastrocytomas (n = 2) and pilocytic astrocytomas (n = 2; referred to as low-grade glioma). One patient had two tumors, an oligoastrocytoma and a pilocytic astrocytoma. In 19 out of 34 cases in this group, ferumoxtran-10 enhanced the same or more than Gd; in ten of those, ferumoxtran-10 enhanced more. Furthermore, in four cases of GBM, ferumoxtran-10 enhanced additional areas that were not seen with Gd (Figure 1 shows a typical case). Figure 2 is a pilocytic astrocytoma that

enhanced less with ferumoxtran-10; the case illustrates the behavior of a tumor with a leaky BBB but few reactive inflammatory cells.

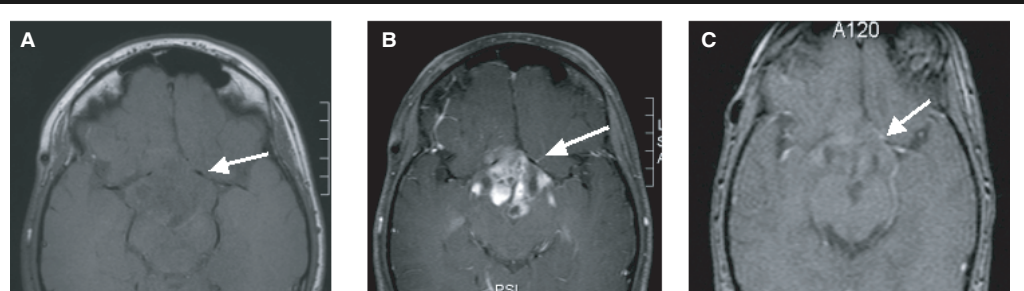
Of the 34 lesions in this group, 20 had been treated with chemotherapy and/or radiation, and 14 were not previously treated. Of the ten lesions that exhibited more enhancement with ferumoxtran-10, two had been managed with chemotherapy alone, four with chemotherapy and radiation and four with neither (40%). Of the nine lesions where both contrast agents showed similar degree of enhancement, four had been treated with chemotherapy only and five had not been treated with either chemotherapy or radiation (55%). Finally, of the 15 lesions where ferumoxtran-10 showed less enhancement than Gd, five had been treated with chemotherapy only, three with radiation alone, two with both modalities and five had not been treated with either (33%).

In the nonglial tumor group (Table 4), there was more histologic variation than the other series (ten types of tumors). The tumors that enhanced more (five out of 22) with ferumoxtran-10 were lymphoma (three out of eight cases of lymphoma), a primitive neuroectodermal tumor and a brain metastasis from breast carcinoma (Figure 3). Two other lesions, one lymphoma and one squamous cell carcinoma, enhanced about the same as Gd. The remaining patients (15 out of 22), including both meningiomas, three of the metastases and the other primitive neuroectodermal tumors (PNET), all showed less enhancement with ferumoxtran-10 than Gd.

**Figure 1. A 53-year-old man with a right temporal lobe glioblastoma multiforme (white arrow).**

(A) T1-weighted. (B) T1-weighted with gadolinium. (C) T1-weighted 24 h post ferumoxtran-10 infusion. Additional lesions are observed (white arrow). This is an example of more enhancement.

**Figure 2. A 14-year-old male, with a pilocytic astrocytoma of the optic chiasma (white arrows).**



**(A)** T1-weighted. **(B)** T1-weighted with Gd. **(C)** T1-weighted 24 h post-ferumoxtran-10 infusion. Since there is almost a complete absence of blood–brain barrier, pilocytic astrocytomas enhance with Gd; because these lesions lack reactive cells, they only enhance modestly with ferumoxtran-10. Meningiomas and pituitary adenomas are similar. Gd: Gadolinium.

Of these 22 lesions, ten had prior treatment with chemotherapy and/or radiation; two of these had radiation alone, four chemotherapy alone and four with both modalities. The remaining 12 lesions (55%) did not receive either radiation or chemotherapy. Of the five lesions that enhanced more with ferumoxtran-10, two had been treated with chemotherapy alone and three with both chemotherapy and radiation. The two lesions that enhanced similarly with both agents had not been irradiated or treated

with chemotherapy. The 15 lesions that were seen to enhance less with ferumoxtran-10 compared with Gd were predominately cases where no treatment had been administered (ten out of 15); in two out of 15 cases radiation had been administered, in two out of 15 chemotherapy and in one case both treatments had been given.

**Discussion**

CNS lesions such as malignant brain neoplasms, strokes, demyelinating diseases and infections often exhibit inflammatory reactions in and around the affected brain. The reactive area usually has a defective BBB, as well as macrophages and reactive astrocytes between the degenerated, necrotic and/or neoplastic cells. Histologic evaluation of brain tissue from areas with inflammatory reaction can demonstrate variable and nonspecific changes, and can complicate the diagnosis by making tumors appear as demyelinating processes, infection or degenerative lesions [16]. Gd-enhanced MR will detect those areas with abnormal BBB, but the presence of reactive cells and astrocytes cannot currently be evaluated with imaging studies. The USPIO agent ferumoxtran-10 permits the visualization of the inflammatory (phagocytic) components of lesions on delayed MRI and can also be detected in the tissue from surgical specimens using stains for iron.

In this study, 56 intracranial lesions diagnosed with Gd-enhanced MR (1.5 T scanner) were imaged 24 h following ferumoxtran-10 administration. The scans were compared with particular focus on selected regions where ferumoxtran-10 showed additional enhancement compared with Gd, indicating an inflammatory component associated with the lesion. **Figure 4**

**Table 4. Comparison of the T1 signal intensity obtained using ferumoxtran-10 and gadolinium in nonglial tumors.**

	Ferumoxtran-10 contrast compared with Gd.			
	Less	Same	More	Total
Total	15	2	5	22
<b>By tumor type</b>				
Lymphoma	4	1	3	8
Metastases	3	0	1	4
Meningioma	2	0	0	2
PNET	1	0	1	2
Epidermoid	1	0	0	1
Hamartoma	1	0	0	1
Hemangioblastoma	1	0	0	1
Pineocytoma	1	0	0	1
Pituitary adenoma	1	0	0	1
Squamous cell carcinoma	0	1	0	1
<b>By treatment history</b>				
None	10	2	0	12
RT only	2	0	0	2
CT only	2	0	2	4
Both RT and CT	1	0	3	4

CT: Chemotherapy; PNET: Primitive neuroectodermal tumors; RT: Radiotherapy.

showed ferumoxtran-10 enhancement were the more aggressive histologies: lymphoma, PNET and metastasis. Malignant tumors in general enhanced the same or more than Gd but different patterns were observed. Malignant CNS tumors are highly infiltrative and promote the development of abnormal vasculature as they proliferate. This abnormal vasculature, added to variable degrees of BBB leakiness that allow macromolecules into the interstitial space, make these lesions amenable to enhancement with ferumoxtran-10. In malignant brain tumors the Gd MR study should be cautiously interpreted because the enhancing areas on MR may not represent the limits of the lesion. Histologic observations in patients with GBM have shown that some areas have a tumor but do not enhance with Gd, that neoplasms can be present in tissue obtained from areas with T2 abnormalities around the enhancing tumor, and that malignant cells can be found distant to the enhancing tumor [30]. The GBM, anaplastic gliomas and oligodendrogliomas in this case series were observed to be variably enhancing. Of the 56 lesions in the series, 15 showed greater enhancement with ferumoxtran-10; ten of these were glial and five nonglial tumors. The fact that ferumoxtran-10 images showed additional pathologic areas not detectable in Gd-contrasted MR in malignant gliomas supports the hypothesis that these tumors extend outside areas of Gd enhancement and appropriate therapies need to aim at large areas, even the brain as a whole, rather than focal abnormalities [16].

### Expert commentary

Ferumoxtran-10 is a promising agent in neurologic diagnosis and surgery. The findings in this study suggest that in malignant gliomas and lymphomas, ferumoxtran-10 can demonstrate additional pathologic areas not seen in Gd-enhanced MR. Such an enhancement likely represents an inflammatory reaction with BBB leakiness, due to both BBB abnormality and phagocytic cells. Ferumoxtran-10 could be useful in surgical interventions for malignant tumors in three ways. First, image-guided neurosurgery or stereotactic biopsy may be better directed with the combined information provided by the two contrast agents. Second, additional targets (lesions) may be visualized in less compromising locations for stereotactic biopsy or resection. And finally, if gross resection is performed, the prolonged enhancement (up to 7 days) of ferumoxtran-10 can aid intra- and

postoperative assessment by MR during or after surgery without further administration of the contrast agent [15].

The clinical potential of iron oxide contrast to assist in the diagnosis of neurologic disease is based on its ability to identify biologic events that cannot be distinguished with Gd. Two conditions are required to view enhancement with ferumoxtran-10; an abnormal BBB and the presence of phagocytic inflammatory and reactive cells to endocytose the contrast (i.e., macrophages and reactive astrocytes). Since different mechanisms produce the MR signal changes, Gd- and ferumoxtran-10-enhanced MR scans may complement each other to identify more lesions and/or characterize an inflammatory component in tumors, vascular and demyelinating disease. Therefore, MRI with ferumoxtran-10 is potentially useful for differential diagnosis of clinically ambiguous patients. Inflammatory reactions exist, not only in brain tumors [8,13], but in demyelinating lesions [31,32] and also ischemic CNS lesions [33,34]. These conditions show variable degrees of BBB damage, and factors such as the onset and evolution of the disease have a considerable impact on the barrier's permeability. An acute demyelinating process, for example, will exhibit more of a change in the barrier's permeability than a subacute or chronic demyelination, even in the same patient. Demyelinating lesions [35,36], strokes [37], infections and some neoplasms may share similar clinical [38] and radiologic features [39,40] especially during the acute phase due to the presence of inflammatory reactions [37,41,42]. These similarities can complicate accurate diagnosis and therapeutic decisions. Despite the high sensitivity of the current imaging tests and cerebrospinal fluid analyses, many patients still require an invasive stereotactic biopsy for a definite diagnosis. Even needle biopsies may be inconclusive if the sample is small or the target chosen was not the most pathologic part of the lesion [43]. The authors have observed in related studies that some demyelinating lesions did not enhance after ferumoxtran-10 or enhanced less compared with Gd [24]. This observation has also been reported in preclinical models of demyelination [44,45] and may be helpful for differential diagnosis.

### Outlook

Although these clinical trials are promising, more extensive and focused trials should be undertaken to define where this new agent could provide the most clinically important



information, such as during image-guided neurosurgery and stereotactic biopsies. Future clinical studies of ferumoxtran-10 in CNS lesions should also stratify patients who have or have not had any kind of radio- or chemotherapy (including steroids) to avoid the confounding the results of natural lesion characteristics with therapy related changes.

An exciting new USPIO agent is ferumoxytol. It is an iron oxide monocrystalline nanoparticle coated with a semisynthetic modified carbohydrate with low-molecular weight and formulated with mannitol. The main difference between ferumoxytol and ferumoxtran-10 is the coating. The modified carbohydrate design makes ferumoxytol better tolerated for bolus injections. Due to this modification and the fact that USPIO particles can serve as blood pool

agents, it may be used for MR angiography and perfusion of the brain. Ferumoxytol can be used at early time points (seconds to minutes) to image the vasculature by MRI without the rapid vascular leak into CNS lesions that limit MRI with Gd-based contrast agents. The authors are currently accruing patients to a National Cancer Institute-sponsored pilot clinical trial of ferumoxytol MRI and MR angiography in brain tumors. This agent will hopefully allow the authors to assess the tumor, inflammatory component and abnormal vasculature. This would aid in developing new therapies targeted at tumor angiogenesis.

Another exciting future direction would be imaging with a cellular contrast agent consisting of labeling inflammatory cells with ferumoxides in conjunction with protamine sulfate [26,46,47]. Labeling inflammatory cells would allow tracking of their migration using MRI, and may lead to earlier detection and/or different treatment modalities in subjects with inflammatory, ischemic, and/or demyelinating lesions. Although tracking of labeled inflammatory cells has more clinical relevance for nontumor CNS lesions, the ability to label tumor cells with iron oxide particles and track their migration using MRI would aid in developing animal models of CNS metastases and new treatment modalities.

### Highlights

- Ferumoxtran-10 is an ultrasmall superparamagnetic iron oxide nanoparticle that has shown excellent potential for imaging in the CNS.
- Iron oxide nanoparticles can also be identified at the light and electron microscopic levels.
- Preclinical data and clinical results suggest that ferumoxtran-10 magnetic resonance enhancement in brain tumors is due to leakage across a damaged blood–brain barrier followed by intracellular trapping by phagocytic cells (astrocytes, macrophages) in and around the tumor rather than tumor cells themselves.
- Initial clinical trials demonstrate that in approximately 10% of subjects, additional areas of enhancement with ferumoxtran-10 in brain lesions can be observed that were not seen with gadolinium, particularly in areas where reactive inflammatory cells were present.
- Potential uses for ferumoxtran-10 magnetic resonance imaging in brain tumors include targeting additional areas for biopsy, aiding intra- and postoperative magnetic resonance imaging without additional contrast, and diagnosing clinically ambiguous lesions.
- More extensive and focused trials should be undertaken.
- Ferumoxytol is a new ultrasmall superparamagnetic iron oxide that will permit magnetic resonance angiography and perfusion imaging of CNS lesions.

### Acknowledgements

The author would like to thank Shannan Walker-Rosenfeld for technical assistance. This project was funded by a Veterans Administration Merit Review Grant (Edward A Neuwelt), grant NS034608 from the National Institute of Neurological Diseases and Stroke (Edward A Neuwelt), and PHS Grant 5 M01 RR000334, and by the Portland VA Medical Center. Ferumoxtran-10 (Combidex®) was provided by Advanced Magnetics (MA, USA).

### Bibliography

Papers of special note have been highlighted as of interest (•) or of considerable interest (••) to readers.

1. Jung C, Jacobs P. Physical and chemical properties of superparamagnetic iron oxide MR contrast agents: ferumoxides, ferumoxtran, and ferumoxsil. *Magn. Reson. Imaging* 13, 661–674 (1995).
2. Ros PR, Freeny PC, Harms SE *et al.* Hepatic MR imaging with ferumoxides: a multicenter clinical trial of the safety and efficacy in the detection of focal hepatic lesions. *Radiology* 196, 481–488 (1995).
3. Hoffman HT, Quets J, Toshiaki T *et al.* Functional magnetic resonance imaging using iron oxide particles in characterizing head and neck adenopathy. *Laryngoscope* 110, 1425–1430 (2000).
4. Anzai Y, Piccoli CW, Outwater EK *et al.* Evaluation of neck and body metastases to nodes with ferumoxtran 10-enhanced MR imaging: Phase III safety and efficacy study. *Radiology* 228(3), 777–788 (2003).
5. Ersoy H, Jacobs P, Kent CK, Prince MR. Blood pool MR angiography of aortic stent-graft endoleak. *Am. J. Roentgenol.* 182, 1181–1186 (2004).
6. Prince MR, Zhang HL, Chabra SG, Jacobs P, Wang Y. A pilot investigation of new superparamagnetic iron oxide (ferumoxytol) as a contrast agent for cardiovascular MRI. *J. X-Ray Science Technology* 11, 231–240 (2003).
7. Enochs WS, Harsh G, Hochberg F, Weissleder R. Improved delineation of human brain tumors on MR images using a long-circulating, superparamagnetic iron oxide agent. *J. Magn. Reson. Imaging* 9, 228–232 (1999).
8. Varallyay P, Nesbit G, Muldoon LL *et al.* Comparison of two superparamagnetic viral-sized iron oxide particles ferumoxides



- and ferumoxtran-10 with a gadolinium chelate in imaging intracranial tumors. *Am. J. Neuroradiol.* 23(4), 510–519 (2002).
- **Results from first clinical trial evaluating ferumoxtran-10 enhanced magnetic resonance imaging of brain tumors.**
9. Zimmer C, Weissleder R, Poss K, Bogdanova A, Wright SC, Enochs WS. MR imaging of phagocytosis in experimental gliomas. *Radiology* 197, 3533–3538 (1995).
  10. Neuwelt EA, Weissleder R, Nilaver G *et al.* Delivery of virus-sized iron oxide particles to rodent CNS neurons. *Neurosurgery* 34, 777–784 (1994).
    - **Describes the magnetic resonance characteristics of iron oxides in the brain and the CNS distribution.**  11. Muldoon LL, Pagel MA, Kroll RA, Roman-Goldstein S, Jones RS, Neuwelt EA. A physiological barrier distal to the anatomic blood–brain barrier in a model of transvascular delivery. *Am. J. Neuroradiol.* 20(2), 217–222 (1999).
    - **Describes the differences between incompletely coated iron oxides and completely coated iron oxides (ferumoxides and ferumoxtran-10).**  12. Muldoon LL, Manninger S, Pinkston KE, Neuwelt EA. Imaging, distribution and toxicity of superparamagnetic iron oxide magnetic resonance agents in rat brain and intracerebral tumor. *Neurosurgery* (2005) (In Press).
  13. Moore A, Marecos E, Bogdanov A Jr, Weissleder R. Tumoral distribution of long-circulating dextran-coated iron oxide nanoparticles in a rodent model. *Radiology* 214(2), 568–574 (2000).
  14. Egelhof T, Delbeck N, Hartmann M *et al.* Can superparamagnetic contrast media improve MRI-tomographic images of experimental gliomas? *Radiologe* 38(11), 943–947 (1998).
  15. Hunt MA, Bago AG, Neuwelt EA. Single-dose contrast agent for intraoperative mr imaging of intrinsic brain tumors using ferumoxtran-10. *Am. J. Neuroradiology* 26(5), 1084–1088 (2005).
  16. Neuwelt EA, Varallyay P, Bago AG, Muldoon LL, Nesbit G, Nixon R. Imaging of iron oxide nanoparticles by MR and light microscopy in patients with malignant brain tumors. *Neuropath. Applied Neurobiol.* 30, 456–471 (2004).
    - **Correlates imaging results using ferumoxtran-10 with histology.**  17. Nguyen BC, Stanford W, Thompson BH *et al.* Multicenter clinical trial of ultrasmall superparamagnetic iron oxide in the evaluation of mediastinal lymph nodes in patients with primary lung carcinoma. *J. Magn. Reson. Imaging* 10, 468–473 (1999).
  18. Taylor AM, Panting JR, Keegan J *et al.* Safety and preliminary findings with the intravascular contrast agent NC100150 injection for MR coronary angiography. *J. Magn. Reson. Imaging* 9, 220–227 (1999).
  19. Anzai Y, Prince MR, Chenevert TL *et al.* MR angiography with an ultrasmall superparamagnetic iron oxide blood pool agent. *J. Magn. Reson. Imaging* 7, 209–214 (1997).
  20. Bonnemain B. Superparamagnetic agents in magnetic resonance imaging: physicochemical characteristics and clinical applications: a review. *J. Drug Target* 6, 167–174 (1998).
  21. Corot C, Petry KG, Trivedi R *et al.* Macrophage imaging in central nervous system and in carotid atherosclerotic plaque using ultrasmall superparamagnetic iron oxide in magnetic resonance imaging. *Invest. Radiol.* 39, 619–625 (2004).
  22. Douset V, Delalande C, Ballarino L *et al.* *In vivo* macrophage activity imaging in the central nervous system detected by magnetic resonance. *Magn. Reson. Med.* 41(2), 329–333 (1999).
  23. Xu S, Jordan Ek, Brocke S *et al.* Study of relapsing remitting experimental allergic encephalomyelitis SJL mouse model using MION-46L enhanced *in vivo* MRI: early histopathological correlation. *J. Neurosci. Res.* 52, 549–558 (1998).
  24. Manninger SP, Muldoon LL, Nesbit G, Murillo T, Jacobs PM, Neuwelt EA. An exploratory study of ferumoxtran-10 as a blood–brain barrier imaging agent targeting phagocytic cells in CNS inflammatory lesions. *Am. J. Neuroradiology* (2005) (In Press).
  25. McLachlan SJ, Morris MR, Lucas MA *et al.* Phase I clinical evaluation of a new iron oxide MR contrast agent. *J. Magn. Reson. Imaging* 4(3), 301–307 (1994).
  26. Arbab AS, Yocum GT, Kalish H *et al.* Efficient magnetic cell labeling with protamine sulfate complexed to ferumoxides for cellular MRI. *Blood* 104(4), 1217–1223 (2004).
    - **Demonstrates the potential of ferumoxides as a cellular contrast agent.**  27. Kamiryo T, Lopes MB, Kassell NF, Steiner L, Lee KS. Radiosurgery-induced microvascular alterations precede necrosis of the brain neuropil. *Neurosurgery* 49(2), 409–414 (2001).
  28. Uematsu Y, Fujita K, Tanaka Y *et al.* Gamma knife radiosurgery for neuroepithelial tumors: radiological and histological changes. *Neuropathology* 21(4), 298–306 (2001).
  29. Griem ML, Robotewskyj A, Nagel RH. Potential vascular damage from radiation in the space environment. *Adv. Space Res.* 14(10), 555–563 (1994).
  30. Silbergeld DL, Chicoine MR. Isolation and characterization of human malignant glioma cells from histologically normal brain. *J. Neurosurg.* 86(3), 525–531 (1997).
  31. Bjartmar C, Kinkel RP, Kidd G, Rudick RA, Trapp BD. Axonal loss in normal-appearing white matter in a patient with acute MS. *Neurology* 57(7), 1248–1252 (2001).
  32. Nesbit GM, Forbes GS, Scheithauer BW, Okazaki H, Rodriguez M. Multiple sclerosis: histopathologic and MR and/or CT correlation in 37 cases at biopsy and three cases at autopsy. *Radiology* 180(2), 467–474 (1991).
  33. Doerfler A, Engelhorn T, Heiland S, Knauth M, Wanke I, Forsting M. MR contrast agents in acute experimental cerebral ischaemia: potential adverse impacts on neurologic outcome and infarction size. *J. Magn. Reson. Imaging* 11(4), 418–424 (2000).
  34. Haraldseth O, Jones RA, Muller TB, Fahlvik AK, Oksendal AN. Comparison of dysprosium DTPA BMA and superparamagnetic iron oxide particles as susceptibility contrast agents for perfusion imaging of regional cerebral ischaemia in the rat. *J. Magn. Reson. Imaging* 6(5), 714–717 (1996).
  35. Brex PA, O’Riordan JI, Miszkil KA *et al.* Multisequence MRI in clinically isolated syndromes and the early development of MS. *Neurology* 53(6), 1184–1190 (1999).
  36. Clifford DB, Gado MH, Levy BK. Osmotic demyelination syndrome. Lack of pathologic and radiologic imaging correlation. *Arch. Neurol.* 46(3), 343–347 (1989).
  37. Iizuka T, Sakai F, Kan S, Suzuki N. Slowly progressive spread of the stroke-like lesions in MELAS. *Neurology* 61(9), 1238–1244 (2003).
  38. Yapici Z, Eraksoy M. Bilateral demyelinating tumefactive lesions in three children with hemiparesis. *J. Child. Neurol.* 17(9), 655–660 (2002).
  39. Butteriss DJ, Ismail A, Ellison DW, Birchall D. Use of serial proton magnetic resonance spectroscopy to differentiate low grade glioma from tumefactive plaque in a patient with multiple sclerosis. *Br. J. Radiol.* 76(909), 662–665 (2003).
  40. Galanaud D, Nicoli F, Le Fur Y *et al.* Multimodal magnetic resonance imaging of the central nervous system. *Biochimie* 85(9), 905–914 (2003).
  41. De Groot CJ, Bergers E, Kamphorst W *et al.* Post-mortem MRI-guided sampling of multiple sclerosis brain lesions: increased yield of active demyelinating and reactive lesions. *Brain* 124(Pt 8), 1635–1645 (2001).

42. Nathoo N, Barnett GH, Golubic M. The eicosanoid cascade: possible role in gliomas and meningiomas. *J. Clin. Pathol.* 57(1), 6–13 (2004).
43. Jackson RJ, Fuller GN, Abi-Said D *et al.* Limitations of stereotactic biopsy in the initial management of gliomas. *Neurooncology* 3(3), 193–200 (2001).
44. Rausch M, Hiestand P, Baumann D, Canner C, Rudin M. MRI-based monitoring of inflammation and tissue damage in acute and chronic relapsing EAE. *Magn. Reson. Med.* 50(2), 309–314 (2003).
45. Dousset V, Ballarino L, Delalande C *et al.* Comparison of ultrasmall particles of iron oxide (USPIO)-enhanced T2-weighted, conventional T2-weighted, and gadolinium-enhanced T1-weighted MR images in rats with experimental autoimmune encephalomyelitis. *Am. J. Neuroradiol.* 20(2), 223–227 (1999).
46. Frank JA, Miller BR, Arbab AS *et al.* Clinically applicable labeling of mammalian cells and stem cells by combining (FDA)-approved superparamagnetic iron oxides and commonly available transfection agents. *Radiology* 228, 480–487 (2003).
- **Demonstrates the ability to label stem cells using superparamagnetic iron oxides.**

47. Arbab AS, Bashaw LA, Miller BR *et al.* Characterization of biophysical and metabolic properties of cells labeled with superparamagnetic iron oxide nanoparticles and transfection agent for cellular MR imaging. *Radiology* 229, 838–846 (2003).
- **Demonstrated no short- or long-term toxic effects on tumor or stem cells after labeling with superparamagnetic iron oxide nanoparticles.**

#### Website

101. Magnevist®. Gadopentetate Dimeglumine: Contrast Enhancement Agent for Magnetic Resonance Imaging (MRI). [www.berleximaging.com](http://www.berleximaging.com) (Accessed October 2005)

#### Affiliations

*Tulio P Murillo, MD*  
*Hospital Escuela Tegucigalpa,*  
*Department of Neurosurgery,*  
*Honduras, HI, USA*  
*Tel.: +1 504 232 2322*  
*tuliomurillo@hotmail.com*

*Chloe Sandquist, MD,*  
*General Surgery Resident*  
*Oregon Health & Sciences University,*  
*OR, USA*  
*Tel.: +1 503 494 5626*  
*Fax: +1 503 494 5627*  
*sandquic@ohsu.edu*

*Paula M Jacobs, PhD,*  
*Vice President Development*  
*Advanced Magnetics, Inc, Cambridge,*  
*MA, USA*  
*Tel.: +1 617 497 2070*  
*Fax: +1 617 547 2445*  
*pjacobs@advancedmagnetics.com*

*Gary Nesbit, MD,*  
*Associate Professor,*  
*Director of Neuroradiology and MRI*  
*Oregon Health & Sciences University,*  
*OR, USA*  
*Tel.: +1 503 494 7576*  
*Fax: +1 503 494 7126*  
*nesbitg@ohsu.edu*

*Sandor Manning, MD,*  
*Fellow Neuroradiology*  
*Oregon Health & Sciences University,*  
*OR, USA*  
*Tel.: +1 503 494 5626*  
*Fax: +1 503 494 5627*  
*manninge@ohsu.edu*

*Edward A Neuwelt, MD*  
*Oregon Health & Sciences University,*  
*OR, USA*  
*Tel.: +1 503 494 5626*  
*Fax: +1 503 494 5627*  
*neuwelte@ohsu.edu*