

# Impacted Maxillary Canines: Facilitating Eruption or Surgical Uncovering

## Abstract

A 11y10m female presented in the late mixed dentition stage, as the premolars were beginning to erupt. There was severe anterior crowding in both arches, and the maxillary canines were impacted. One year later the right maxillary canine erupted in a high, blocked out position. After extracting the deciduous canines and opening space as needed, the right canine spontaneously erupted into an acceptable alignment, but the left canine remained impacted. Cone-beam computed tomography (CBCT) accurately displayed the position of the impaction, and the overlying tissue was surgically removed to allow the upper left canine to erupt. The Discrepancy Index (DI) for this complex malocclusion was 15, and the Impaction Specific Assessment System (iSAS) score was an additional 15 points, for a total DI of 30.

A passive self-ligating appliance, supplemented with bite turbos on the lower first molars, was used to alleviate the cross-bite of both upper lateral incisors. After 40 months of active treatment, the cast-radiograph evaluation (CRE) score was a marginal 31 points, primarily due to buccolingual inclinations and lack of intermaxillary occlusal contacts. Superimposition of cephalometric tracings showed that the ANB was reduced 1° but the mandibular plane angle increased ~1.5°. The latter resulted in a more feminine facial pattern. Follow-up photographs 1 year and 10 months after treatment revealed that both facial esthetics and occlusion were stable. (*J Digital Orthod* 2018;49:52-71)

### Key words:

Impacted upper canine, open window surgery, impaction's Specific Assessment System (iSAS), iDI, iCRE

## History and Etiology

An 11-year-10-month-old female presented with a severely crowded dentition (Figs. 1-3). Intraoral examination revealed a recently erupted upper left first premolar, but the other primary maxillary molars and a left canine were retained. The anterior dentition was severely crowded, both upper lateral incisors were in cross-bite, and the upper canines were unerupted. In the absence of obvious anomalies and pathology in the maxillary arch, the assumed etiology for the impactions was crowding and abnormal paths of eruption.

There was no evidence of contributing oral habits or temporomandibular dysfunction. A pleasing alignment was achieved, as shown in Figs. 4-9.

## Diagnosis

### Skeletal:

- Skeletal Class I: SNA 80°, SNB 76°, ANB 4°
- Mandibular Plane Angle: SN-MP 37.5°, FMA 30.5°


### Dental:

- Molar Relationships: End-on Class II on both sides

**Dr. Linda Tseng,**  
Lecturer, Beethoven Orthodontic Course (Left)

**Dr. Chris Chang,**  
Founder, Beethoven Orthodontic Center  
Publisher, Journal of Digital Orthodontics (Center)

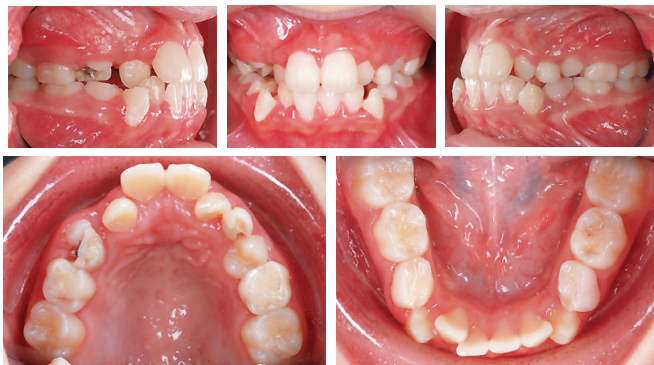**Dr. W. Eugene Roberts,**  
Editor-in-chief, Journal of Digital Orthodontics (Right)



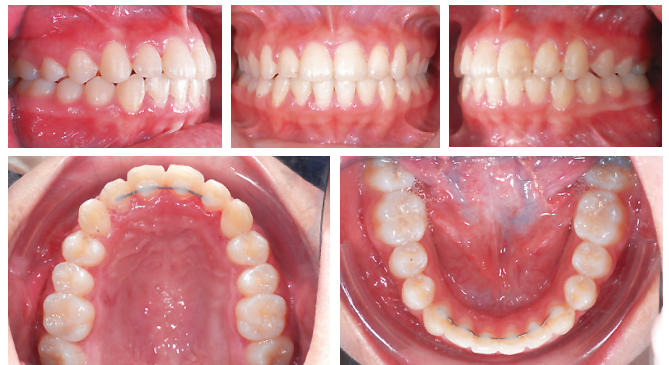■ Fig. 1: Pre-treatment facial photographs



■ Fig. 4: Post-treatment facial photographs



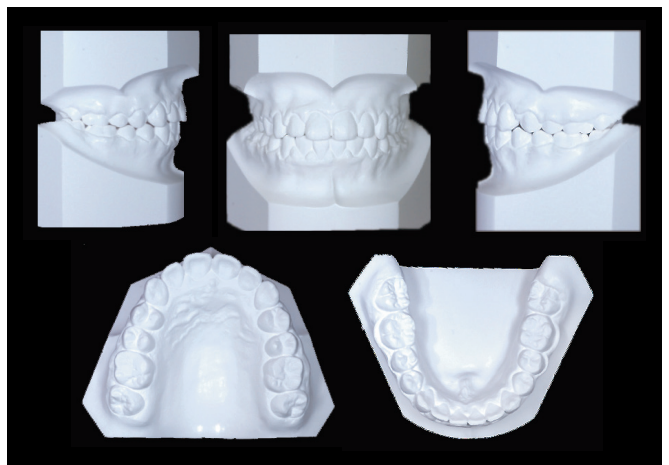■ Fig. 2: Pre-treatment intraoral photographs



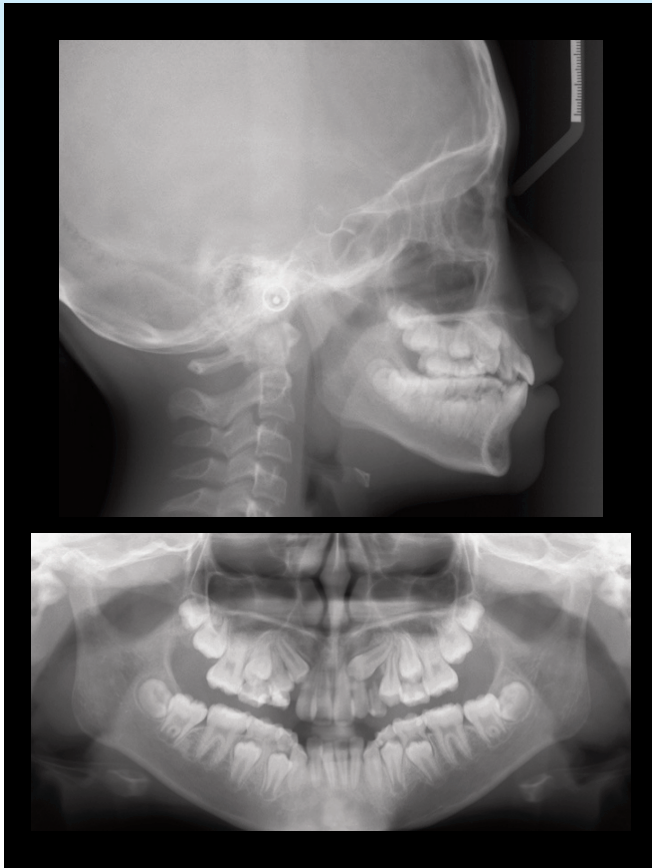
■ Fig. 5: Post-treatment intraoral photographs



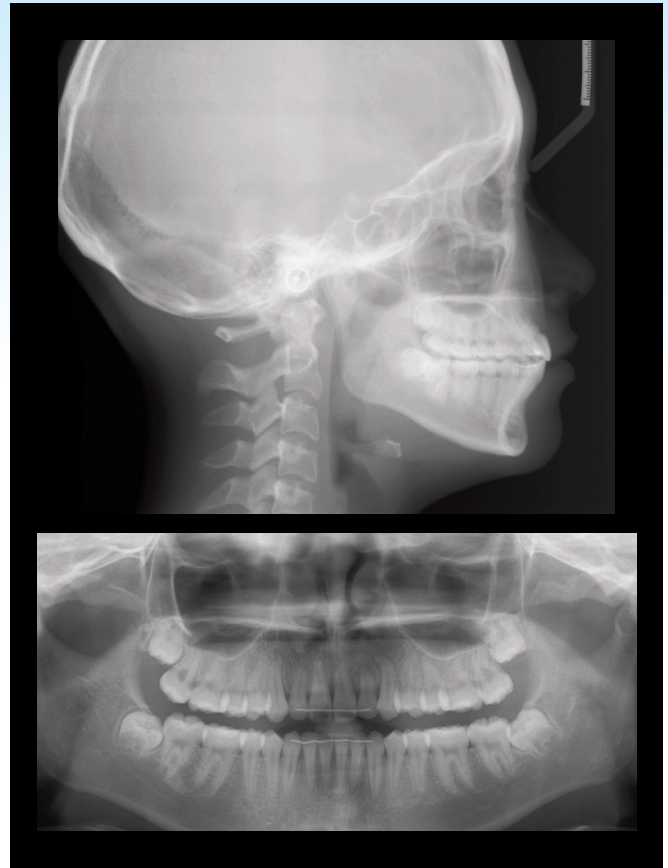
■ Fig. 3: Pre-treatment study models (casts)



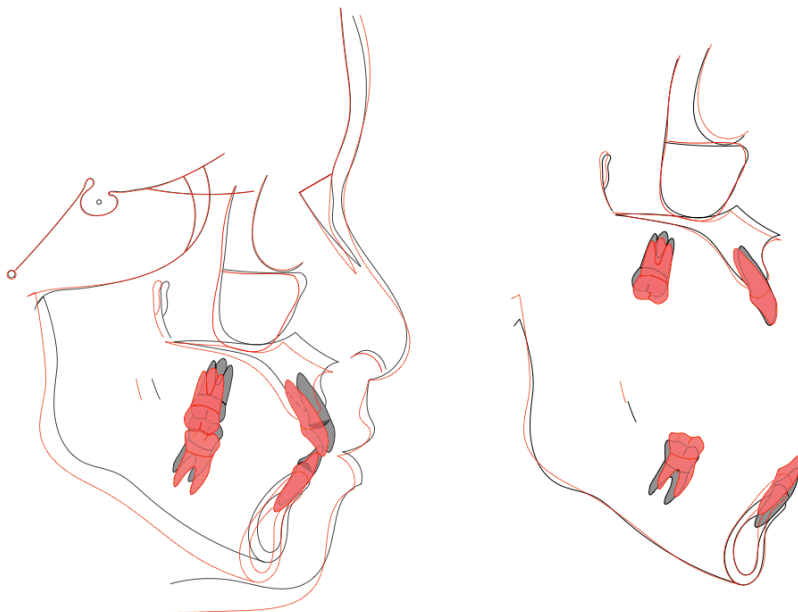
■ Fig. 6: Post-treatment study models (casts)



■ **Fig. 7:**  
Pre-treatment cephalometric (above) and panoramic (below) radiographs



■ **Fig. 8:**  
Post-treatment cephalometric (above) and panoramic (below) radiographs



■ **Fig. 9:**  
Superimposed tracings of the pre-treatment (black) and post-treatment (red) cephalometric radiographs show the dental and skeletal changes during treatment. See text for details.

- Crowding: >10mm space deficiency for the upper arch, ~7mm in the lower arch.
- Cross-Bite: Both maxillary lateral incisors
- Impactions: Both maxillary canines

**Facial:**

- Profile: Convex but within normal limits (WNL)
- Summary: Symmetry
- Incisal Exposure: WNL when smiling

The ABO Discrepancy Index (DI) was 15, and an additional 15 points were scored for the difficult position of the canine impaction, so the total DI was 30 as shown in the subsequent worksheet.

CEPHALOMETRIC SUMMARY			
SKELETAL ANALYSIS			
	PRE-Tx	POST-Tx	DIFF.
SNA° (82°)	80°	78°	2°
SNB° (80°)	76°	75°	1°
ANB° (2°)	4°	3°	1°
SN-MP° (32°)	37.5°	39°	1.5°
FMA° (25°)	30.5°	32°	1.5°
DENTAL ANALYSIS			
U1 To NA mm (4 mm)	3 mm	4 mm	1 mm
U1 To SN° (104°)	104°	109°	5°
L1 To NB mm (4 mm)	6 mm	6 mm	0 mm
L1 To MP° (90°)	95°	95°	0°
FACIAL ANALYSIS			
E-LINE UL (2-3 mm)	0 mm	-1 mm	1 mm
E-LINE LL (1-2 mm)	1.5 mm	0 mm	1.5 mm

■ Table 1: Cephalometric summary

**Specific Objectives of Treatment**

The principal treatment objectives were: 1. Correct intermaxillary anterior crowding, 2. Open space for the impacted maxillary canines, 3. Expose and align the impactions, and 4. Achieve an ideal intermaxillary alignment.

**Maxilla (all three planes):**

- A - P: Allow for normal expression of growth
- Vertical: Allow for normal expression of growth
- Transverse: Maintain

**Mandible (all three planes):**

- A - P: Allow for normal expression of growth
- Vertical: Allow for normal expression of growth
- Transverse: Maintain

**Maxillary Dentition:**

- A - P: Retract incisors to correct overjet
- Vertical: Maintain
- Inter-molar / Inter-canine Width: Expand as needed to relieve crowding

**Mandibular Dentition:**

- A - P: Maintain
- Vertical: Extrude
- Inter-molar / Inter-canine Width: Expand as needed to relieve crowding

**Facial Aesthetics:**

- Maintain

## Treatment Plan

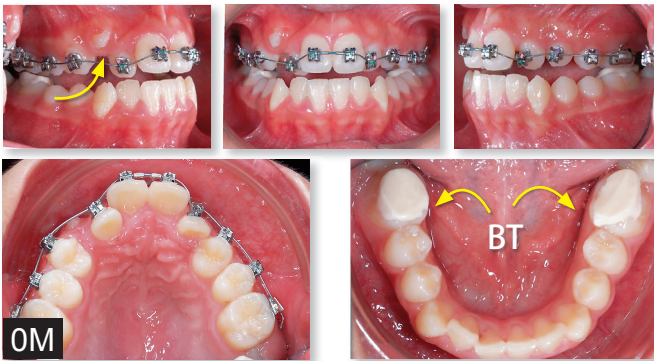Serial extraction was recommended, but the patient and her parents declined the procedure, so she was placed on recall and orthodontic treatment was postponed until the permanent premolars erupted. A non-extraction strategy with a full fixed orthodontic appliance was planned to align and level both arches. Low torque brackets were selected for the anterior segments of both arches to prevent incisal flaring (Fig. 10). Bite turbos (BTs) were constructed on the lower first molars to open the bite for correction of the anterior crossbite of the maxillary lateral incisors. An open window surgical procedure was planned to expose the impacted canine. Cone Beam Computed Tomography (CBCT)

images were used to precisely assess the position and orientation of the impacted left canine.

## Appliances and Treatment Progress

A 0.022-in slot Damon D3MX® bracket system (Ormco, Glendale, CA) was selected. Low torque brackets were bonded on the maxillary anterior teeth to resist the tendency for flaring as the crowding was corrected. To correct the crossbite of the maxillary lateral incisors, bite turbos were constructed with Fuji II type II glass ionomer cement (GC America, Alsip IL), on the occlusal surfaces of both mandibular 1<sup>st</sup> molars to open the bite and reduce the occlusal interference (Fig. 10). Opening the bite with bite turbos facilitated crossbite correction, and may have contributed to increasing the vertical dimension of occlusion (VDO) as noted in Fig. 9.

One month later, open coil springs were inserted between lateral incisors and first premolars bilaterally to open space for the impacted canines (Fig. 11). In the 4<sup>th</sup> month, the arch wire was changed



■ Fig. 10:

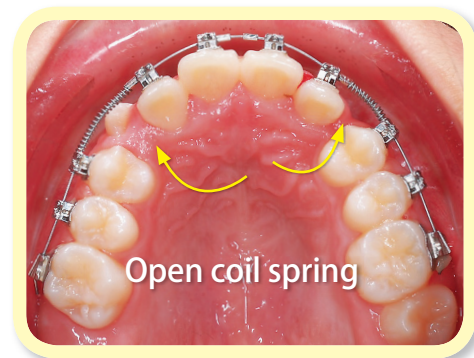**Upper Left:** The right maxillary cuspid erupted spontaneously, but was blocked out due to inadequate space (arrow).

**Upper Center:** Low torque brackets were bonded on the maxillary anterior teeth to resist the tendency for flaring as the crowding was corrected. The arch wire was 0.014-in CuNiTi.

**Upper Right:** Left buccal view at the start of treatment.

**Lower Left:** The occlusal view of the maxillary arch is shown at the start of treatment (OM).

**Lower Right:** Bite turbos (BT) were constructed on the lower first permanent molars (arrows) to open the bite for correction of the anterior crossbite involving both maxillary lateral incisors.



■ Fig. 11:

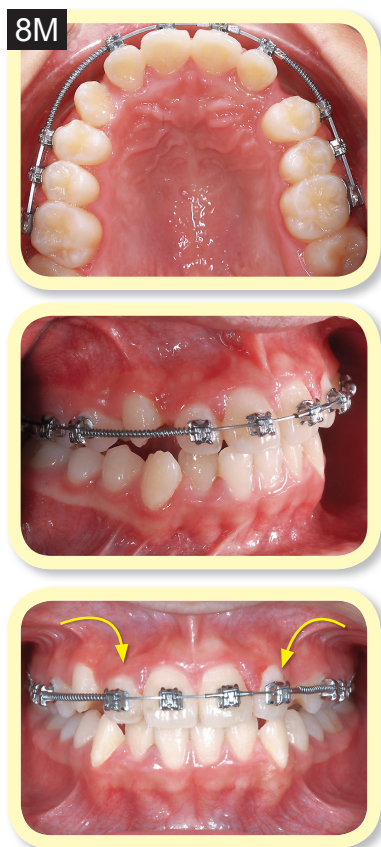Two segments of open coil spring (arrows) were inserted between the lateral incisors and first premolars bilaterally, to open space for the impacted canines.

to 0.014x0.025-in NiTi. After 8 months of treatment, the blocked out right canine gradually erupted to a normal position, and the crossbite was corrected (Fig. 12).

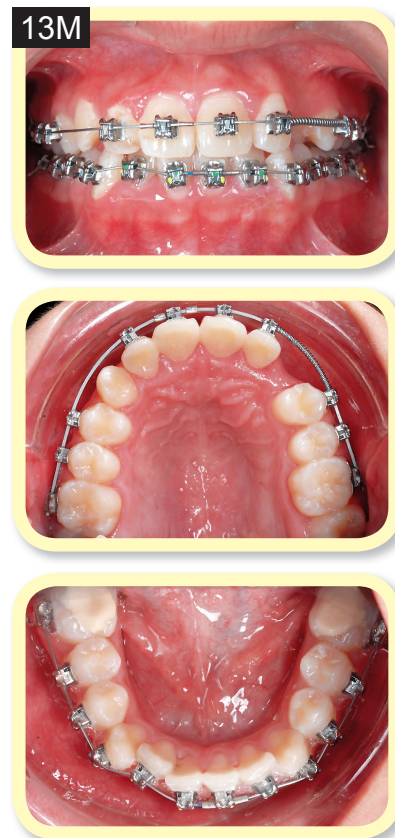
In the 13<sup>th</sup> month, the lower arch was bonded with low torque brackets to prevent incisal flaring. Adequate space was available for the impacted left canine (Fig. 13). CBCT imaging was scheduled to

evaluate the impaction.

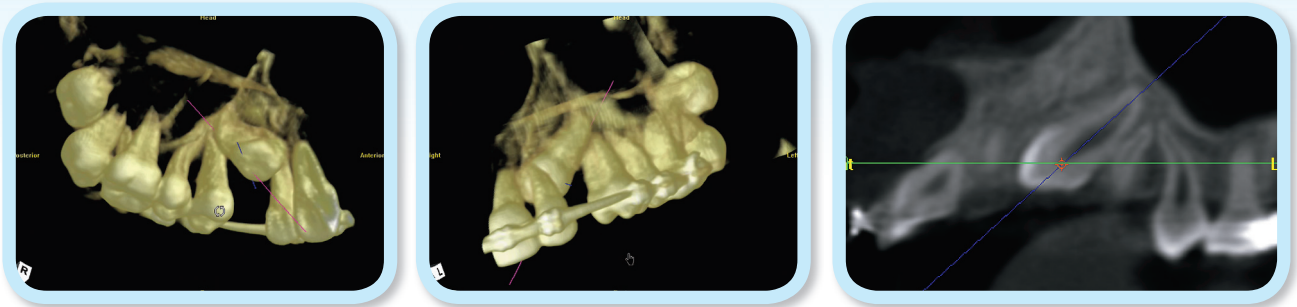
In the 18<sup>th</sup> month, a panoramic radiograph and CBCT scan were taken to assess progress and identify the position of the impaction. The 3D image with bone density tuned out was evaluated prior to surgery to accurately confirm the location of the impaction relative to adjacent teeth (Figs. 14 and 15). Surgical exposure of the impacted canine was



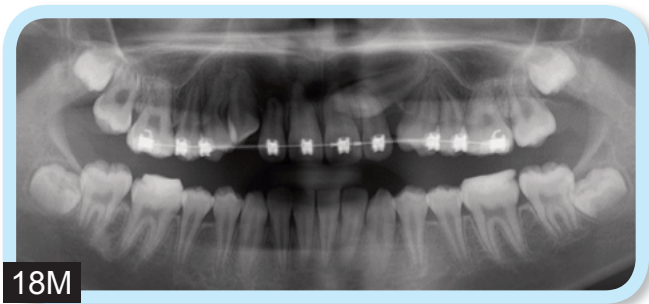
■ **Fig. 12:**  
 After 8 months (8M) of active treatment, progress is shown in three intraoral maxillary views:  
**Upper:** Arch form reveals inadequate space for the upper left canine.  
**Center:** The cusp tip of the canine has erupted past the archwire.  
**Lower:** The crossbite of the upper lateral incisors was corrected (arrows).



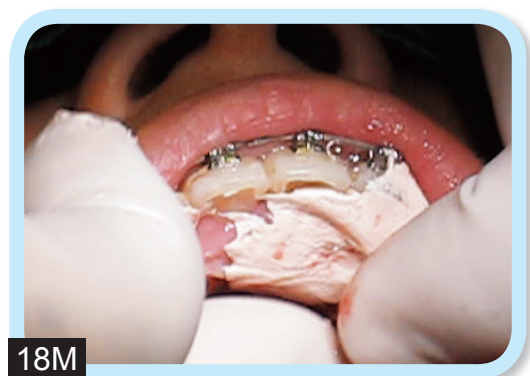
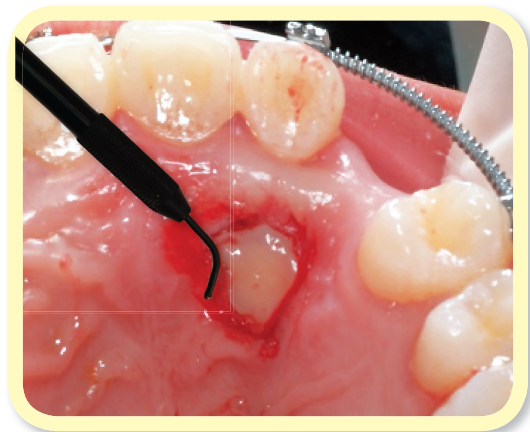■ **Fig. 13:**  
 After 13 months (13M) of active treatment:  
**Upper:** Frontal view  
**Center:** Upper arch-form shows space opening for the impacted canine.  
**Lower:** The lower arch was bonded with low torque brackets in the anterior segment to prevent incisal flaring.



■ **Fig. 14:**  
**Left and Center:** 3D imaging with bone density tuned-out documents the position of the impaction to adjacent teeth.  
**Right:** Slice views are useful for determining the thickness of the bone covering the impaction.

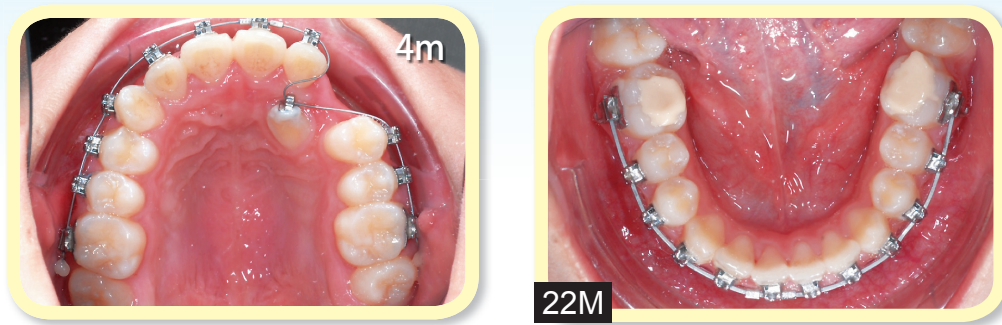


■ **Fig. 15:**  
 At 18 months (18M) a panoramic radiograph documents progress prior to uncovering the impaction.

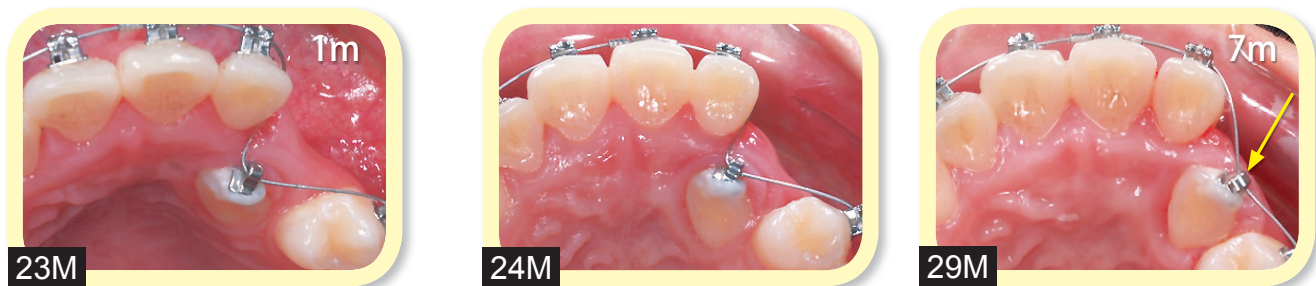

■ **Fig. 16:**  
 At 18 months (18M) soft tissue covering the impaction was removed with electrosurgery (upper). The wound was covered with surgical dressing (lower).

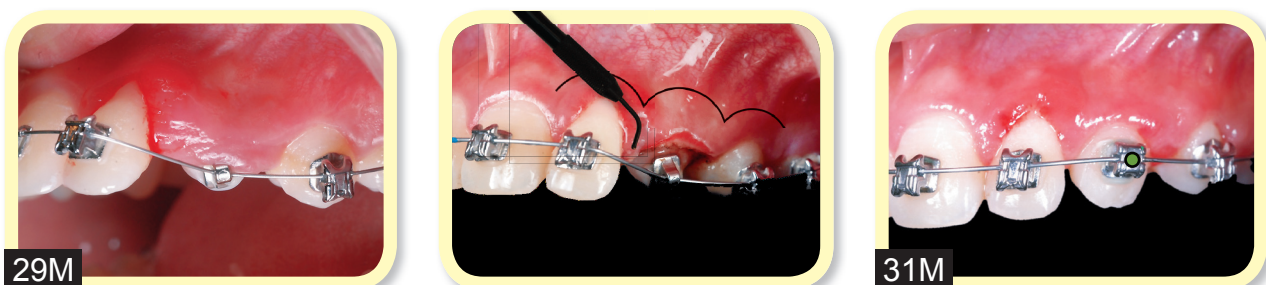
performed by removing the overlying soft tissue, and the wound was covered with surgical dressing (Fig. 16). Three months after surgery, the upper left canine erupted spontaneously, and an eyelet was bonded onto the labial surface. A 0.013-in NiTi arch wire aligned the previously impacted tooth (Fig. 17), and the movement was documented with a series of intraoral photographs (Fig. 18). After seven months of traction, soft tissue accumulated on the buccal surface of the canine, and a gingivectomy was performed with a diode laser. One month later, a low torque bracket was bonded on the maxillary left canine (Fig. 19). In the 33<sup>rd</sup> month, the upper



**Fig. 17:**  
 At 22 months (22M) into treatment and 4 months (4M) after surgical uncovering, an eyelet was bonded on the erupted canine and traction was applied with an 0.013-in NiTi arch wire (left). Arch alignment is near complete and bite turbos were bonded on the lower first molars (right).



**Fig. 18:**  
**Left:** At 23 months (23M) and 1 month (1M) after initiation traction  
**Middle:** At 24 months (24M) the canine is uprighting into its proper position in the arch.  
**Right:** At 29 months (29M) and 7 months (7M) after initiation of traction the previously impacted canine is entering the arch-form (arrow).

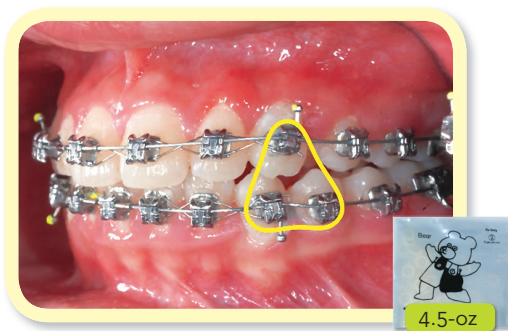


**Fig. 19:**  
 At 29 months (29M) of treatment and seven months of buccal traction on the upper left canine, soft tissue accumulated on the buccal side of the tooth (left). A diode laser was used to remove excessive gingiva relative to the mucogingival junction (black line, center). One month later, a low torque bracket was bonded on the maxillary left canine (right).

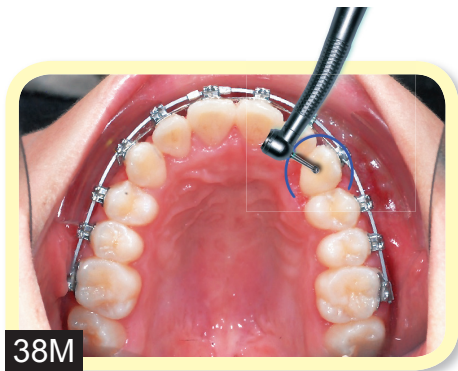


arch wire was changed to 0.014x0.025-in NiTi. A panoramic radiograph was exposed to evaluate bracket positions relative to axial inclinations of all teeth, and they were repositioned as needed. In the 37<sup>th</sup> month, a 0.017x0.025-in TMA archwire was placed in the upper arch. An elastic (*Bear 1/4-in, 4.5-oz*) was applied from the upper left canine to the lower left canine and the adjacent first premolar to close the open contact (*Fig. 20*). One month later, wire bending and palatal reduction was performed on the maxillary left canine for detailing the occlusion during the final stage of treatment

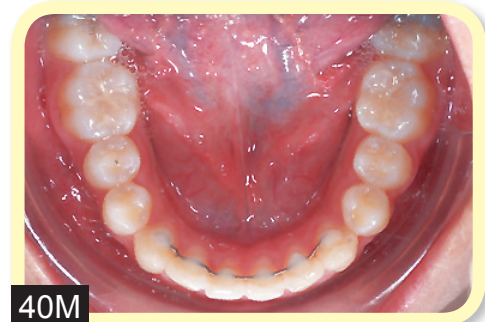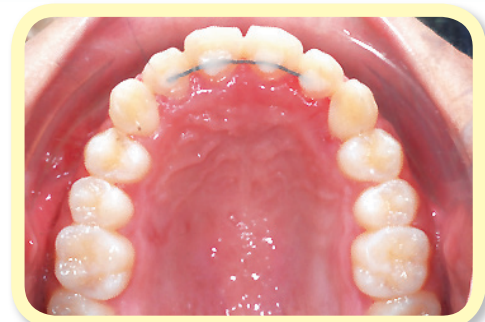(*Fig. 21*). After 40 months of active treatment, all appliances were removed. Fixed anterior retainers and clear overlays were delivered for both arches (*Fig. 22*).



■ **Fig. 20:**  
A triangular elastic (*Bear 1/4-in, 4.5-oz*) was used to close the open contact in the left canine area.



■ **Fig. 21:**  
Palatal reduction of the palatal enamel surface was performed on the upper left canine. Archwire adjustment was utilized to finish the intermaxillary detailing.



■ **Fig. 22:**  
After 40 months (40M) of active treatment, all appliances were removed, fixed anterior retainers were bonded on the lingual surfaces of individual teeth in both arches.

## Results Achieved

### Maxilla (all three planes):

- A - P: Retracted
- Vertical: Maintained
- Transverse: Maintained

### Mandible (all three planes):

- A - P: Retracted
- Vertical: Increased (posterior rotation)
- Transverse: Maintained

### Maxillary Dentition

- A - P: Anterior incisors retracted and slightly flared
- Vertical: Molars extruded
- Inter-molar / Inter-canine Width: Crowding corrected with arch expansion

### Mandibular Dentition

- A - P: Maintained
- Vertical: Molars and incisors were extruded
- Inter-molar / Inter-canine Width: Maintained

### Facial Aesthetics:

- Facial convexity and lip protrusion WNL

### Retention

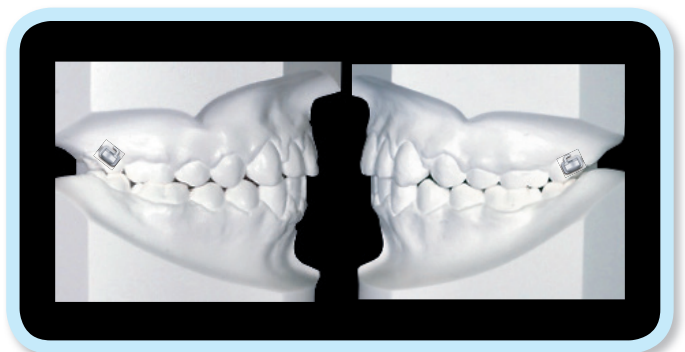Fixed lingual retainers were bonded on all maxillary incisors, and from canine to canine in the mandibular arch. Clear overlays were delivered for each arch. The patient was instructed to wear them full time for the first month and nights only thereafter. Instructions were provided for the home hygiene as well as for maintenance of the retainers.

### Final Evaluation of the Treatment

Cephalometric superimpositions (Fig. 9) and analysis (Table 1) document vertical growth and posterior rotation of the mandible. The mandible increased in length about 10mm (Fig. 9), and the upper dentition was retracted. The upper incisor to SN angle increased from 104° to 109°. That flaring effect resulted from correction of the crowding and the space-opening effect of the coil springs. Extruded molars in both arches and the lower incisors were

related to expression of mandibular growth, and possibly due to the posterior bite turbos. Posterior rotation of mandible resulted in a 1.5° increase in the mandibular plane angle. Although lower facial height increased, photographs after treatment (Fig. 4) show lip competence, as well as similar facial convexity and lip protrusion, compared to the pre-treatment records. Overall, the posterior rotation of the mandible was advantageous for maintaining a more feminine profile.

The ABO Cast-Radiograph Evaluation (CRE) score was 30 points, which slightly exceeds the ideal range (upper limit of 26 points). The major discrepancies were occlusal contacts (10 points), buccolingual inclination (7 points), marginal ridges (4 points), alignment/rotations (3 points), and distal tipping of the upper second molars (Fig. 23). If these discrepancies had been discovered with prefinish records,<sup>1</sup> the finish CRE score could have been substantially improved with bracket repositioning and archwire adjustments. Overall, the dentition was well aligned, and the patient was satisfied with the result.



■ Fig. 23:

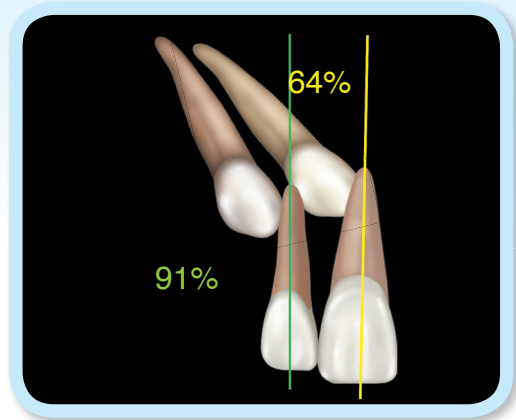
Distal tipping of the upper second molars were noted after debonding. This problem could be corrected by repositioning the brackets as shown.

## Discussion

### 1. Impacted Maxillary Canine

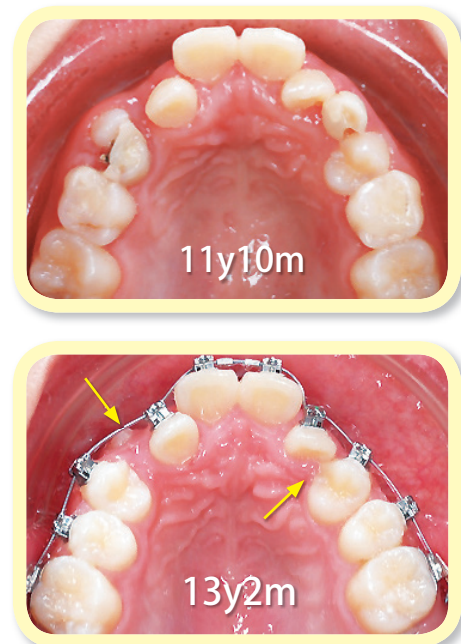
Other than the mandibular third molar, the maxillary canine is the most commonly impacted tooth with an incidence from 1-2.5%.<sup>2</sup> Conventional radiography in 2D requires two or three conventional intraoral films, exposed at different projections, to reliably assess the position and eruption pathway of impacted canines in most children. The optimal age for radiologic investigation is 10 to 13 years.<sup>3</sup> Genetics is thought to be the primary factor, but delayed exfoliation of the primary canine, lack of space and ectopic path of eruption may also contribute. The prevalence of labial or palatal impaction is 15% and 85% respectively. The incidence rate in females is 3.2 times that of males. Palatally impacted canines are five times more common in Europeans compared to Asians.<sup>2-5</sup>

Root resorption of permanent incisors may be related to ectopic eruption of the maxillary canines<sup>4</sup> and cysts have also been reported for untreated impactions. Extraction of the primary canine may favorably influence the path of eruption. The success rate differs according to the impacted canine position at the start of treatment, mesial or distal to the midline of the lateral incisor in the panoramic radiograph (Fig. 24). With late diagnosis, crowding, root resorption and/or horizontal path of eruption, surgical exposure with active orthodontic extrusion is the treatment of choice.<sup>5</sup> For the patient in the present study (Figs. 10 and 25), the right upper canine was positioned distal to the midline of the lateral incisor. It erupted spontaneously, but was subsequently blocked out. The left upper canine was



■ Fig. 24:

The success rate for normalization for the maxillary permanent canine eruption by extracting the deciduous canine and opening space for the impaction is related to the overlap of the unerupted canine relative to the incisor roots at the start of treatment: 91% if the overlap involves only the distal aspect of the lateral incisor root, and drops to 64% if the overlap is more than half of the central incisor root.



■ Fig. 25:

Relative to the pretreatment view of the maxillary arch pretreatment (11y10m), the right canine erupts in a high position because it is blocked-out, but the left canine is impacted and its space is closed.

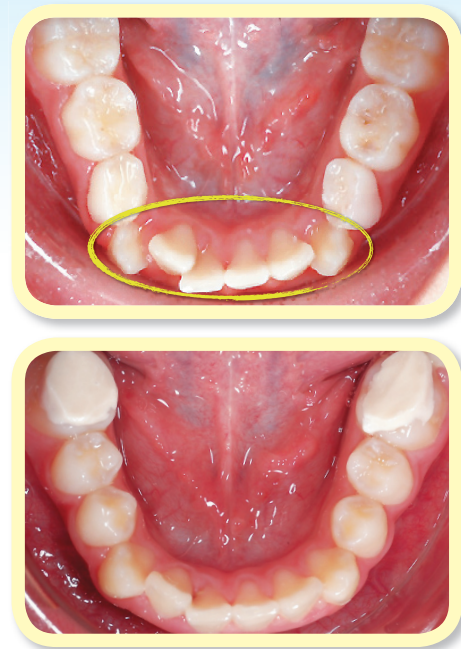positioned mesial to the midline of the lateral incisor, and thus deeply imbedded in the palate. After the primary canine was lost, the space closed due to distal shift of the lateral incisor and mesial shift of the posterior teeth. Fixed orthodontic appliances were the optimal option.<sup>5,6</sup>

## 2. Leeway Space

Leeway space is the arch-length difference between the combined mesiodistal width of the deciduous cuspid and molars and their successors.<sup>7</sup> Usually the total width of these three primary teeth is greater than that of their permanent successors by ~1.6-2.5mm per side in the lower arch and ~0.7-1.5mm per side in the upper arch. Girls usually have larger Leeway spaces than boys, probably because males usually have larger crown dimensions for all teeth.<sup>7</sup> Preserving Leeway space helps relieve crowding.<sup>8</sup> During late mixed dentition, a 5mm space deficiency was measured in the lower anteriors of the present patient. The crowding was relieved spontaneously after the lower permanent premolars erupted, but this phenomenon was not observed in maxillary dentition (Figs. 25 and 26). The space for the maxillary left canine was probably lost due to a mesial shift of maxilla buccal segment. Baccetti et al.<sup>9</sup> found significant mesial movement of the upper first molars (about 2.5mm) occurred both in untreated and primary canine extraction patients when the canines were palatally displaced.

## 3. Bracket Selection

Non-extraction leveling and aligning of a crowded dentition usually results in incisal flaring, which is



■ Fig. 26:

*Crowding in lower anterior region corrected spontaneously after the permanent premolars erupted (circle), apparently due to favorable utilization of Leeway space.*

intensified by the use of open coil springs to regain space for impacted canines.<sup>10</sup> Bonding low torque brackets in the anterior segments of both arches decreases the flaring tendency. Lateral force to move a palatally impacted canine into the arch is likely to tip the crown labially, so a low torque bracket is indicated to upright the canine once it is aligned in the arch.

## 4. Surgical Exposure

Another approach to facilitate autonomous eruption of the ectopically positioned maxillary cuspid is to open space orthodontically by separating the lateral incisor and premolar.<sup>10</sup> If the impacted canine does not begin to erupt (Fig. 13), surgical exposure is needed. There are three important issues to

guarantee a successful result: accurate diagnosis, proper surgery and precise mechanics.

**Accurate Diagnosis**

With conventional apical films, the buccal object rule is used to identify the labiolingual position of the impaction,<sup>2,3</sup> but 3D imaging with a CBCT scan is the only common procedure for precisely locating the impaction relative to the adjacent teeth. The slice views are useful for determining the thickness of the bone covering the impaction (Fig. 14). These useful insights can help avert injury to adjacent structures.





**Proper Surgery**

A well defined surgical procedure produces efficient alignment of a previously impacted tooth.<sup>11</sup> The precise location of the impaction was identified on the CBCT image. Crown position was marked with a sharp explorer that penetrated the soft tissue. Instead of a scalpel, a dental electrosurgical unit (ESU) was used to remove the covering soft tissue (Fig. 16) to control bleeding and provide a more

clear surgical field. The most expedient way to align a previously impacted canine is to remove bone in the planned path of traction.<sup>11</sup> The “osteobur” is more efficient than osteoclasts. However, for the present patient, bone was not removed in the path of traction. Nine months was required to align the left maxillary canine. Removing bone in the path of traction would have saved time.

**Precise Mechanics**

If the soft tissue and bone covering the crown of an upper canine impaction are carefully removed, the tooth will spontaneously erupt into the oral cavity.<sup>6</sup> Furthermore, the bone level and periodontal attachment of the adjacent teeth are more healthy compared with the closed eruption technique. However, spontaneous eruption of an impaction in adults may take more than one year. To control treatment time, the present authors prefer active traction with a palatal screw to erupt the impaction into the palate, and then apply lateral force to move the tooth into the arch. It is important to initiate traction before the canine crown passes the level

	Open Window Chang		Pre-ortho. Uncovering Tech Kokich	
Flap elevation	N		Y	
Tooth uncovering	cut a hole over the crown		cut a hole on the flap	
Suture	N		Y	
surgical dressing	3 days		3 months	

■ Table 2: Comparison of the Chang and Kokich methods for uncovering impactions. The crown signifies the superior procedure at each step.

of the occlusal plane to avoid excessive tipping of the root in the opposite direction which may result in a cross-bite and/or enhance the chance of root resorption.<sup>12</sup>

## Conclusions

If a palatal impaction is diagnosed at an early age (10-13 years), and the crown of the ectopic cuspid is not past the root of the lateral incisor, extraction of the primary canine is an effective approach for redirecting the path of eruption. Extracting the primary canine and opening the space orthodontically may also facilitate autonomous eruption of palatally impacted maxillary canines. If these two methods fail, surgery exposure is necessary. With accurate diagnosis, proper surgical procedures and precise mechanics, esthetic and

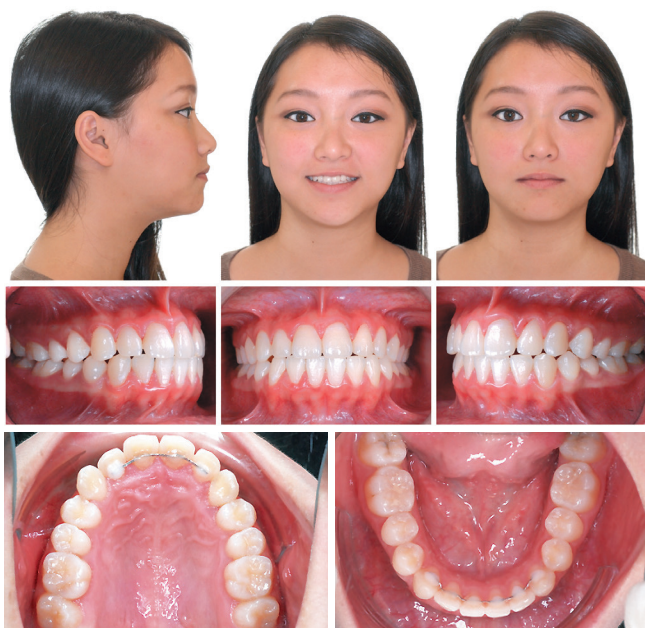satisfying periodontal outcomes of impacted maxillary canines can be achieved.

## Acknowledgment

Thanks to Mr. Seth T. Pankhurst for proofreading this article.

## References

1. Knierim K, Roberts WE, Hartsfield Jr JK. Assessing treatment outcomes for a graduate orthodontics program: follow-up study for classes of 2001-2003. *Am J Orthod Dentofacial Orthop* 2006;130(5):648-655, 655 e. 1-3.
2. Ericson S, Kurol J. Radiographic assessment of maxillary canine eruption in children with clinical signs of eruption disturbance. *Eur J Orthod* 1986;8(3):133-140.
3. Ericson S, Kurol J. Radiographic examination of ectopically erupting maxillary canines. *Am J Orthod Dentofacial Orthop* 1987;91:483-492.
4. Ericson S, Kurol J. Resorption of maxillary lateral incisors caused by ectopic eruption of the canines. A clinical and radiographic analysis of predisposing factors. *Am J Orthod Dentofacial Orthop* 1988;94:503-513.
5. Ericson S, Kurol J. Early treatment of palatally erupting maxillary canines by extraction of the primary canines. *Euro J Orthod* 1988;10:283-295.
6. Kokich V. Preorthodontic uncovering and autonomous eruption of palatally impacted maxillary canines. *Seminars in Orthodontics* 2010;16(3):205-211.
7. Nance HN. The limitation of orthodontic treatment. *Am J Orthod* 1947;33:177-253.
8. Dugoni S. Comprehensive mixed dentition treatment. *Am J Orthod Dentofacial Orthop* 1998;113:75-84.
9. Baccetti T, Leonardi M, Armi P. A randomized clinical study of two interceptive approaches to palatally displaced canines. *Euro J Orthod* 2008;30:381-385.
10. Olive RJ. Orthodontic treatment of palatally impacted maxillary canines. *Aust Orthod J* 2002;18:64-70.
11. Chang A, Chang CH, Roberts WE. Simplified open-window technique for a horizontally impacted maxillary canine with a dilacerated root. *Int J Orthod Implantol* 2015;39:76-84.
12. Thavarungkul R. Correcting deep-bite with fixed bite ramps. *News & Trends in Orthodontics* 2009 Oct;16:68-71.



■ **Fig. 27:** Follow-up photographs 1 year and 10 months after treatment document the stability of the result.

# Discrepancy Index Worksheet

**TOTAL D.I. SCORE**     15+15=30

**OVERJET**

- 0 mm. (edge-to-edge) =
- 1 – 3 mm. = 0 pts.
- 3.1 – 5 mm. = 2 pts.
- 5.1 – 7 mm. = 3 pts.
- 7.1 – 9 mm. = 4 pts.
- > 9 mm. = 5 pts.

Negative OJ (x-bite) 1 pt. per mm. per tooth =

Total = 4

**OVERBITE**

- 0 – 3 mm. = 0 pts.
- 3.1 – 5 mm. = 2 pts.
- 5.1 – 7 mm. = 3 pts.
- Impinging (100%) = 5 pts.

Total = 0

**ANTERIOR OPEN BITE**

0 mm. (edge-to-edge), 1 pt. per tooth  
then 1 pt. per additional full mm. per tooth

Total = 0

**LATERAL OPEN BITE**

2 pts. per mm. per tooth

Total = 0

**CROWDING** (only one arch)

- 1 – 3 mm. = 1 pt.
- 3.1 – 5 mm. = 2 pts.
- 5.1 – 7 mm. = 4 pts.
- > 7 mm. = 7 pts.

Total = 7

**OCCLUSION**

- Class I to end on = 0 pts.
- End on Class II or III = 2 pts. per side 4 pts.
- Full Class II or III = 4 pts. per side pts.
- Beyond Class II or III = 1 pt. per mm. pts.  
additional

Total = 4

**LINGUAL POSTERIOR X-BITE**

1 pt. per tooth     Total = 0

**BUCCAL POSTERIOR X-BITE**

2 pts. per tooth     Total = 0

**CEPHALOMETRICS** (See Instructions)

ANB  $\geq 6^\circ$  or  $\leq -2^\circ$  = 4 pts.

Each degree  $< -2^\circ$  \_\_\_\_\_ x 1 pt. = \_\_\_\_\_

Each degree  $> 6^\circ$  \_\_\_\_\_ x 1 pt. = \_\_\_\_\_

**SN-MP**

$\geq 38^\circ$  = 2 pts.

Each degree  $> 38^\circ$  \_\_\_\_\_ x 2 pts. = \_\_\_\_\_

$\leq 26^\circ$  = 1 pt.

Each degree  $< 26^\circ$  \_\_\_\_\_ x 1 pt. = \_\_\_\_\_

l to MP  $\geq 99^\circ$  = 1 pt.

Each degree  $> 99^\circ$  \_\_\_\_\_ x 1 pt. = \_\_\_\_\_

Total = 0

**OTHER** (See Instructions)

- Supernumerary teeth \_\_\_\_\_ x 1 pt. = \_\_\_\_\_
- Ankylosis of perm. teeth \_\_\_\_\_ x 2 pts. = \_\_\_\_\_
- Anomalous morphology \_\_\_\_\_ x 2 pts. = \_\_\_\_\_
- Impaction (except 3<sup>rd</sup> molars) 1 x 2 pts. = \_\_\_\_\_
- Midline discrepancy ( $\geq 3$ mm) @ 2 pts. = \_\_\_\_\_
- Missing teeth (except 3<sup>rd</sup> molars) \_\_\_\_\_ x 1 pts. = \_\_\_\_\_
- Missing teeth, congenital \_\_\_\_\_ x 2 pts. = \_\_\_\_\_
- Spacing (4 or more, per arch) \_\_\_\_\_ x 2 pts. = \_\_\_\_\_
- Spacing (Mx cent. diastema  $\geq 2$ mm) @ 2 pts. = \_\_\_\_\_
- Tooth transposition \_\_\_\_\_ x 2 pts. = \_\_\_\_\_
- Skeletal asymmetry (nonsurgical tx) @ 3 pts. = \_\_\_\_\_
- Addl. treatment complexities \_\_\_\_\_ x 2 pts. = 15

Identify:

**iDI = 15**

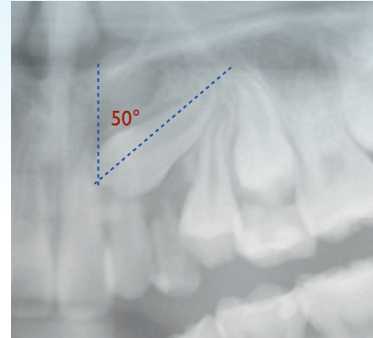
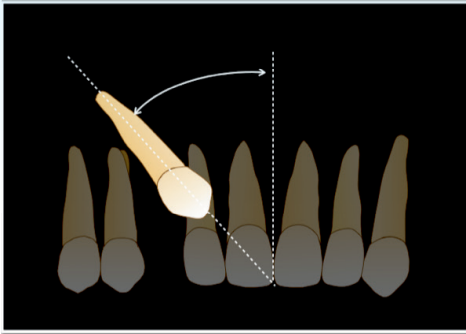
Total = 15

## iDI impaction Discrepancy Index

Total Score: = 15

### 1. Angulation of the impaction to the midline in degree

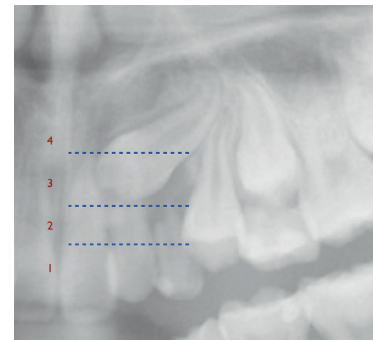
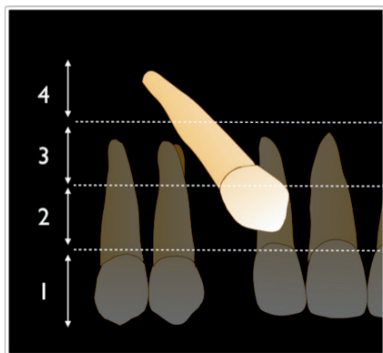
Total = 3



- Grade 1 :  $0^\circ \sim 15^\circ = 1$  pt.
- Grade 2 :  $16^\circ \sim 30^\circ = 2$  pts.
- Grade 3 :  $\geq 30^\circ = 3$  pts.

### 2. Vertical distance from the occlusal plane

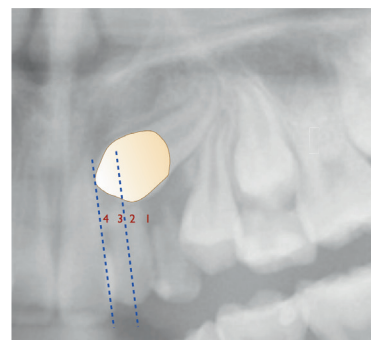
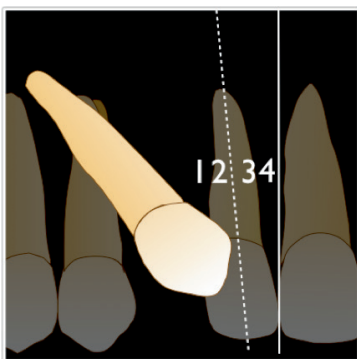
Total = 3



- Grade 1 : Below the level of the CEJ = 1 pt.
- Grade 2 : Above the CEJ, but less than halfway up the root = 2 pts.
- Grade 3 : More than halfway up the root, but less than the full root length = 3 pts.
- Grade 4 : Above the full length of the root = 4 pts.

### 3. Mesiodistal position of the impaction tip

Total = 4



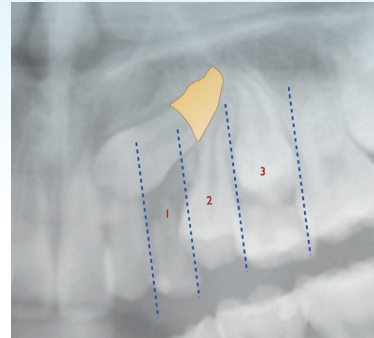
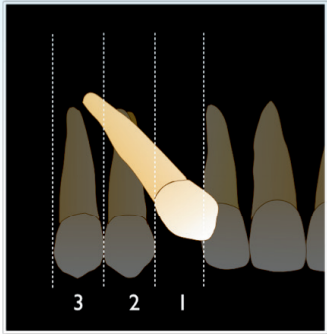
- Grade 1 : No horizontal overlap = 1 pt.
- Grade 2 : Less than half the root width = 2 pts.
- Grade 3 : More than half, but less than the whole root width = 3 pts.
- Grade 4 : Complete overlap of root width or more = 4 pts.



## iDI impaction Discrepancy Index

### 4. Anterior-posterior position of the impaction root apex

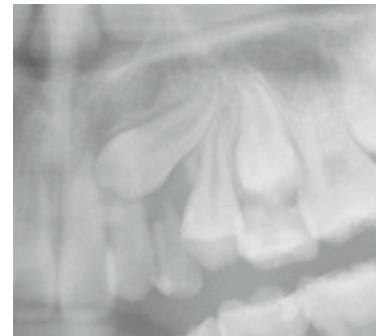
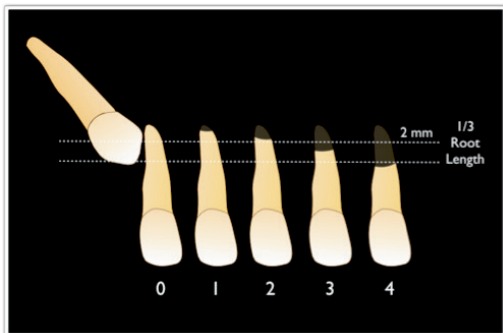
Total = 2



Grade 1 : Above the region of the canine position = 1 pt.  
 Grade 2 : Above the upper first premolar region = 2 pts.  
 Grade 3 : Above the upper second premolar region = 3 pts.

### 5. Root resorption of the adjacent tooth

Total = 0



Normal apical contour = 0 pt.  
 Apical irregularity, same length as pretreatment = 1 pt.  
 Apical root resorption of less than 2 mm = 2 pts.  
 Apical root resorption more than 2 mm, less than one third original root length = 3 pts.  
 Apical root resorption more than one third original root length = 4 pts.

### 6. Age relative to the completion of root formation

Total = 2

< 9 y/o ( Before Central incisor root completed ) = 0 pt.  
 9 ~ 11 y/o ( Before Lateral incisor root completed ) = 1 pt.  
 12~13 y/o ( Before 1<sup>st</sup> premolar root completed ) = 2 pts.  
 > 13 y/o ( Canine root completed ) = 3 pts.

### 7. Labial or palatal position of the impaction

Total = 1

Palatal impaction = 1 pt.  
 Labial impaction = 2 pts.

# Cast-Radiograph Evaluation

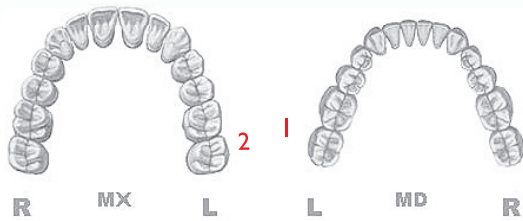
Total CRE Score

30+1=31

iCRE=1

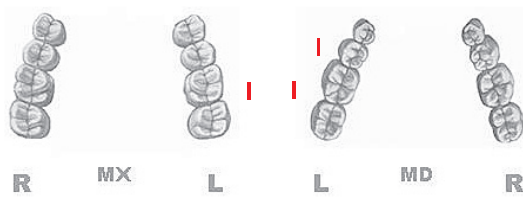
## Alignment/Rotations

3



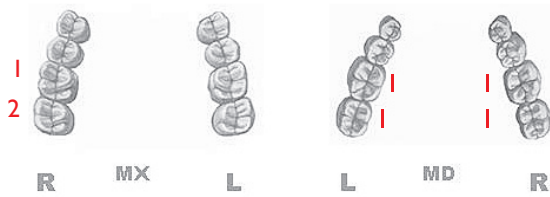
## Marginal Ridges

4



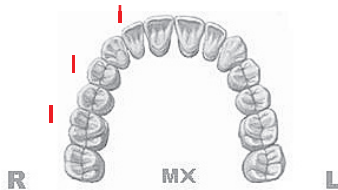## Buccolingual Inclination

7



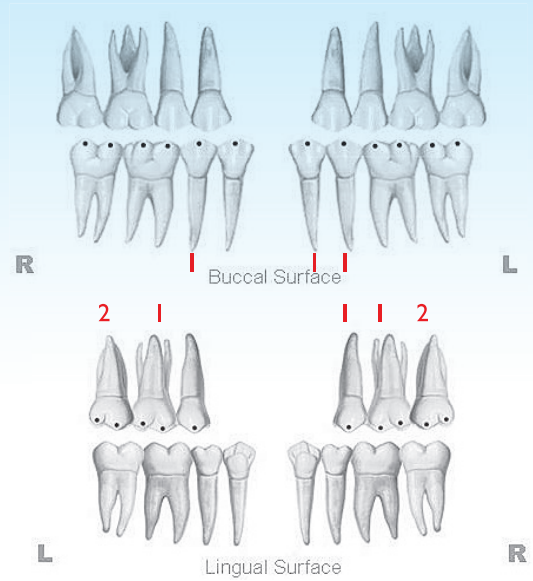
## Overjet

3



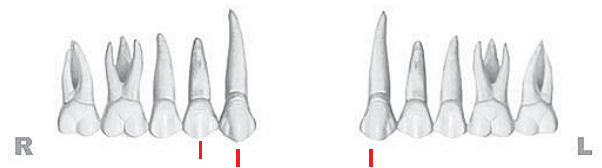
## Occlusal Contacts

10



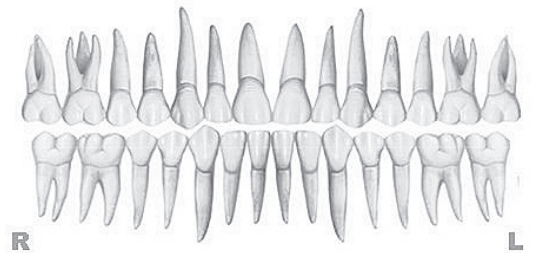
## Occlusal Relationships

3



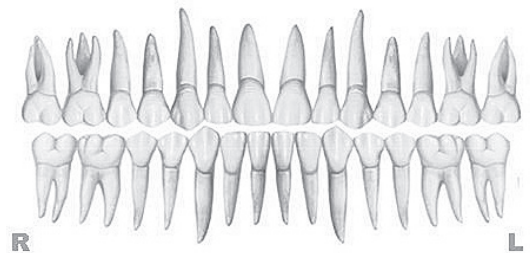
## Interproximal Contacts

0



## Root Angulation

0



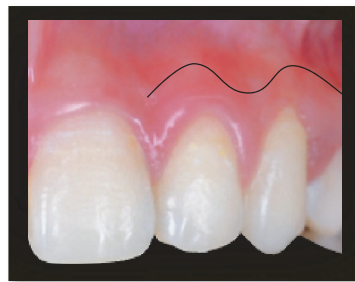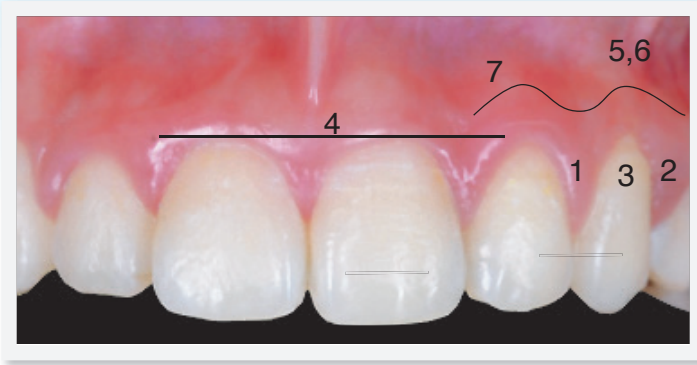**INSTRUCTIONS:** Place score beside each deficient tooth and enter total score for each parameter in the white box. Mark extracted teeth with "X". Second molars should be in occlusion.

## iCRE **impaction** Cast-Radiograph Evaluation

Total Score: = 1

### 1. Gingival esthetic score

Total = 1

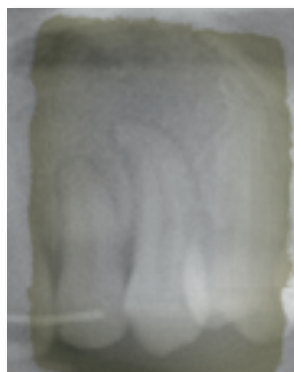
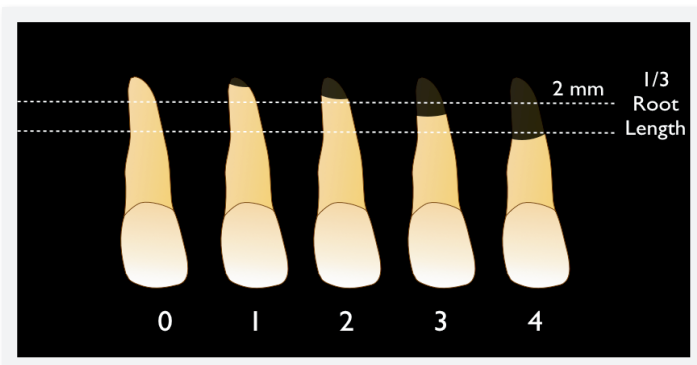


1. M & D Papillae	0	1	2
2. Keratinized Gingiva	0	1	2
3. Curvature of Gingival Margin	0	1	2
4. Level of Gingival Margin	0	1	2
5. Root Convexity ( Torque )	0	1	2
6. Scar Formation	0	1	2
7. Keratinized Gingival Exists	0	1	2

1. M & D Papilla	0	1	2
2. Keratinized Gingiva	0	1	2
3. Curvature of Gingival Margin	0	1	2
4. Level of Gingival Margin	0	1	2
5. Root Convexity ( Torque )	0	1	2
6. Scar Formation	0	1	2
7. Keratinized Gingival Exists	0	1	2

### 2. Root resorption of the recovered and adjacent teeth

Total = 0



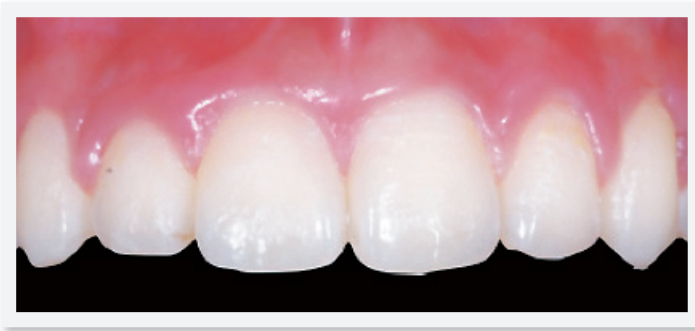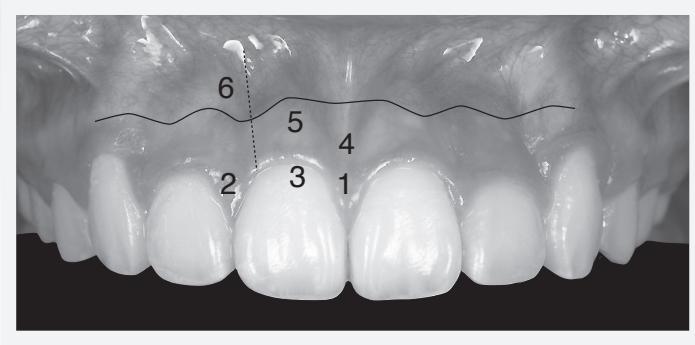
Normal apical contour	0
Apical irregularity, same length as pretreatment	1
Apical root resorption of less than 2 mm	2
Apical root resorption more than 2 mm, less than one third original root length	3
Apical root resorption more than one third original root length	4

Normal apical contour	0
Apical irregularity, same length as pretreatment	1
Apical root resorption of less than 2 mm	2
Apical root resorption more than 2 mm, less than one third original root length	3
Apical root resorption more than one third original root length	4

## IBOI Pink & White Esthetic Score (Before Surgical Crown Lengthening)

Total Score: = 5

### 1. Pink Esthetic Score

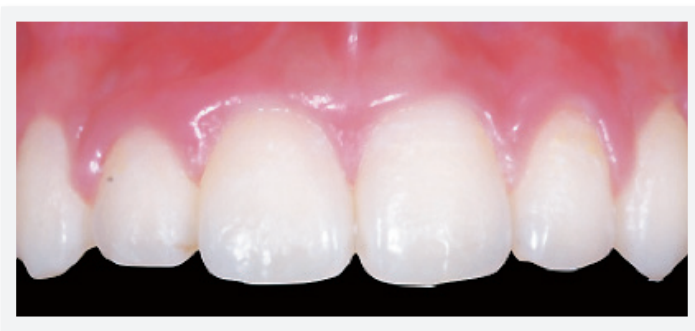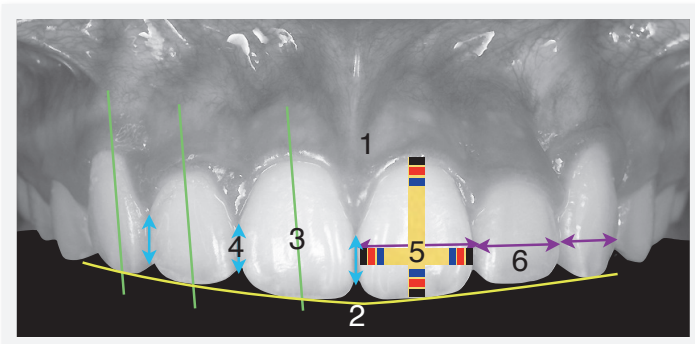


1. M & D Papillae	0	1	2
2. Keratinized Gingiva	0	1	2
3. Curvature of Gingival Margin	0	1	2
4. Level of Gingival Margin	0	1	2
5. Root Convexity ( Torque )	0	1	2
6. Scar Formation	0	1	2

Total = 2

1. M & D Papilla	0	1	2
2. Keratinized Gingiva	0	1	2
3. Curvature of Gingival Margin	0	1	2
4. Level of Gingival Margin	0	1	2
5. Root Convexity ( Torque )	0	1	2
6. Scar Formation	0	1	2

### 2. White Esthetic Score ( for Micro-esthetics )



1. Midline	0	1	2
2. Incisor Curve	0	1	2
3. Axial Inclination (5°, 8°, 10°)	0	1	2
4. Contact Area (50%, 40%, 30%)	0	1	2
5. Tooth Proportion (1:0.8)	0	1	2
6. Tooth to Tooth Proportion	0	1	2

Total = 3

1. Midline	0	1	2
2. Incisor Curve	0	1	2
3. Axial Inclination (5°, 8°, 10°)	0	1	2
4. Contact Area (50%, 40%, 30%)	0	1	2
5. Tooth Proportion (1:0.8)	0	1	2
6. Tooth to Tooth Proportion	0	1	2