

Orthodontic treatment with a series of removable appliances

DAVID A. CHENIN, D.D.S.; ANDREW H. TROSIEN, D.D.S., M.S.; PATRICIA F. FONG, D.D.S.; ROBERT A. MILLER, D.M.D.; RODNEY S. LEE, D.D.S.

Adults often desire an aligned dentition for cosmetic reasons. However, alignment of the adult dentition can provide other advantages as well, such as improved function, reduced tendency for enamel wear, elimination of traumatic occlusion and improved maintenance of periodontal health.¹⁻⁷ Simply stated, properly aligned teeth permit better access for home care oral hygiene.¹⁻⁸ People who are concerned about the overall esthetics of their smile may be reluctant to spend one or two years

with a decrease in their smile's cosmetic appeal owing to the treatment appliance itself. For patients with esthetic interests, options such as clear brackets still may be seen as large fixed appliances and irritating to the cheeks and gums. Lingual fixed appliances offer an esthetic advantage, but may be irritating to the periodontium and soft tissue. Spring retainers, while removable and esthetic, typically are not used for more complex orthodontic cases.

In this article, we present case reports involving three patients treated without the use of bands, brackets or wires. We used a series of nearly invisible appliances, Invisalign (Align Technology, Santa Clara, Calif.), to incrementally move the teeth from their crowded initial position to their final straightened position.⁹⁻²² The fact that patients are permitted to remove the appliances for meals, brushing and flossing allowed for excellent maintenance of oral hygiene.^{9,23,24}

Use of this appliance by treating clinicians offers an alternative procedure to restorative or fixed appliance therapy for an array of malocclusions.

Background. In the United States, the demand for straight white teeth has never been more important to patients. Crowded, poorly aligned teeth are not esthetically pleasing and are difficult to keep clean. However, until recently, the process of straightening the teeth typically has involved appliances involving bands, brackets and wires that also can be difficult to clean. The desire for a cosmetic solution to misaligned teeth has led to an increase in the number of patients seeking veneers, crowns and other laboratory-fabricated cosmetic restorations. Some clinicians are not aware that there are other ways to align teeth without either significant enamel reduction or conspicuous fixed orthodontic appliances.

Description of Technique. An alternative method of treatment, involving a series of clear removable appliances, circumvents this shortcoming and enables tooth alignment while avoiding deterioration in the cosmetics of the smile during treatment. This article describes a method of treatment, Invisalign (Align Technology, Santa Clara, Calif.), that clinicians can use in conjunction with 3-D computer models to accomplish the esthetic and oral hygiene objectives during and after treatment.

Case Descriptions. The authors present three case reports, all involving a chief concern of crowding. The first case involved treatment of both arches by interproximal reduction, alignment of teeth and leveling the curve of Spee. The second case involved treatment of both arches by proclination, expansion and minor interproximal reduction. The final case shows relief of lower-arch crowding via lower-incisor extraction.

Clinical Implications. In addition to satisfying the patient's chief concern of desiring straight teeth, this method of treatment satisfies additional objectives of esthetic treatment and esthetic results with significant oral hygiene benefits. Clinicians can address a patient's chief concern effectively without requiring an inventory of appliances (such as bands, brackets, wires and instruments). Furthermore, the use of 3-D computer models can give clinicians additional information to make more complete decisions regarding treatment.

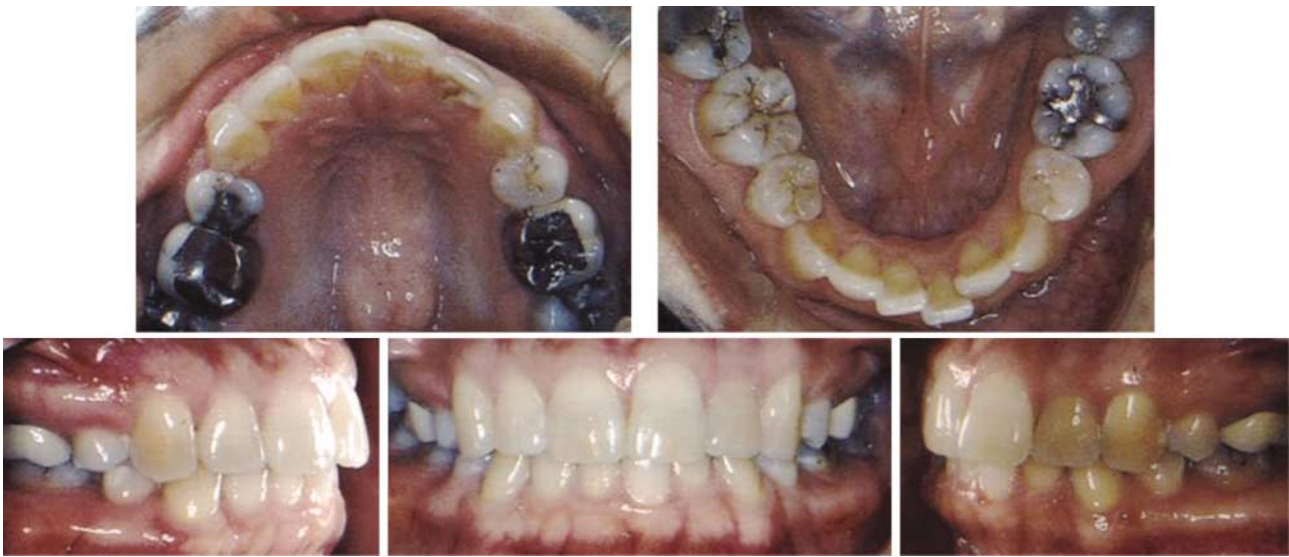

Figure 1. Case report 1: pretreatment photographs showing Class I occlusion with mild maxillary arch crowding, moderate mandibular arch crowding and deep bite.

CASE REPORT 1

Examination. The patient was a 41-year-old woman with the chief complaint of lower-arch crowding. As a teen-ager, she had had orthodontic treatment that included four premolar extractions. Her medical history was not relevant, and she had received routine dental care since her teen-aged years. The patient had symmetrical facial features and a Class I crowded malocclusion (Figure 1). Crowding was mild in the upper anterior arch and moderate in the lower anterior arch; the patient had a deep overbite, and the incisors had mild lingual crown torque. The patient had an otherwise healthy periodontium and maintained good oral hygiene. Radiographic survey found the full eruption of all teeth except for the first premolars and third molars that had been extracted. Fixed restorations were evident on many posterior teeth.

Treatment objective. The goal of treatment was to align the teeth on the lower arch and eliminate crowding by opening the deep bite via leveling the curve of Spee and by accomplishing interproximal reduction. The teeth in her upper arch also were to be aligned. Additionally, the clinician (P.F.F.) planned home bleaching to lighten the chroma of the teeth.

Treatment. The clinician took polyvinyl siloxane, or PVS, impressions of the upper and lower arches. She sent these impressions with a centric occlusion PVS bite registration to Align

Technology. She reviewed the virtual 3-D setup, then the manufacturer created a series of Aligners (16 upper and 23 lower) and sent them to the clinician. At the initial appliance delivery appointment, the clinician bonded attachments (small composite bars), using a supplied template, to the buccal surface of the mandibular second premolars and first molars to assist in Aligner retention during the leveling of the curve of Spee. The lower anterior teeth were reduced about 0.25 millimeters at each interproximal location by means of diamond-coated finishing strips used for interproximal reduction. The clinician carried out this reduction at varying stages of treatment, depending on the degree of access to the interproximal areas at any given stage.

The patient was given the first two Aligners of the series and was instructed to change to the next set of Aligners in the series every two weeks, removing them only for eating, drinking and oral hygiene. Appointments were scheduled every four weeks for observation, interproximal reduction and delivery of the next series of Aligners. The total treatment time was eight months for the upper arch and 12 months for the lower arch. After completion of treatment, the patient used Hawley retainers. She was instructed to wear them full-time for one year, followed by nighttime wear for an indefinite period.

Results and discussion. The Class I molar and canine relationships were maintained, the deep bite was improved and the incisors were

TABLE

PRETREATMENT AND POSTTREATMENT MEASUREMENTS COMPARED WITH THE 3-D VIRTUAL SETUP GOAL MEASUREMENT.

CASE	MEASUREMENT POINTS	MEASUREMENT AT EACH CHECKPOINT (mm*)				DISCREPANCY (GOAL - ACTUAL)†‡	
		Initial	Goal	Final	Achieved (Actual - Initial)		
Case 1 Upper arch	1st molar to 1st molar	49.4	50.7	50.7	1.3	0.0	
	2nd premolar to 2nd premolar	43.5	44.6	40.6	2.9	0.0	
	1st premolar to 1st premolar	N/A§	N/A	N/A	N/A	N/A	
	Canine to canine	36.6	38.0	38.0	1.4	0.0	
	Lower arch	1st molar to 1st molar	38.7	39.1	39.1	0.4	0.0
		2nd premolar to 2nd premolar	33.9	34.0	34.1	0.2	-0.1
		1st premolar to 1st premolar	N/A	N/A	N/A	N/A	N/A
		Canine to canine	24.9	25.8	25.8	0.9	0.0
Case 2 Upper arch	1st molar to 1st molar	42.6	45.7	45.7	3.1	0.0	
	2nd premolar to 2nd premolar	36.3	41.2	41.1	4.8	0.1	
	1st premolar to 1st premolar	32.3	36.7	36.6	1.3	0.1	
	Canine to canine	28.5	30.6	30.6	2.1	0.0	
	Lower arch	1st molar to 1st molar	33.4	36.7	36.6	3.2	0.1
		2nd premolar to 2nd premolar	26.4	33.3	33.3	6.9	0
		1st premolar to 1st premolar	23.2	29.1	29.2	6.0	-0.1
		Canine to canine	21.5	22.0	22.0	0.5	0.0
Case 3 Upper arch	1st molar to 1st molar	51.1	51.1	51.1	0.0	0.0	
	2nd premolar to 2nd premolar	45.7	45.7	45.7	0.0	0.0	
	1st premolar to 1st premolar	39.1	40.2	40.3	1.2	-0.1	
	Canine to canine	31.6	32.3	32.3	0.7	0.0	
	Lower arch	1st molar to 1st molar	42.0	42.0	42.0	0.0	0.0
		2nd premolar to 2nd premolar	37.5	37.5	37.5	0.0	0.0
		1st premolar to 1st premolar	30.2	30.6	30.5	0.3	0.1
		Canine to canine	24.3	22.1	22.1	-2.2	0.0

* mm: Millimeters.
† Buccal cusp tip to buccal cusp tip, in millimeters.
‡ A negative value in the Discrepancy column indicates a final measurement that was greater than the goal measurement.
§ N/A: Not applicable.

aligned. Interproximal reduction allowed the posterior arch width to be maintained (Table). The upper midline was moved into alignment with the lower midline (Figure 2, page 1235). The clinician found no significant changes in the posttreatment panoramic radiograph. The curve of Spee was leveled, showing reduced overbite as planned in the virtual 3-D setup. Throughout treatment, the patient maintained good oral hygiene and exhibited no increase in gingival inflammation. At two years after treatment, the results appear to be very stable and the long-term prognosis is good.

CASE REPORT 2

Examination. A 42-year-old woman had a chief complaint of upper-arch and lower-arch crowding. Clinical examination revealed a symmetrical face with misaligned dental midlines. Dentally, moderate upper and lower crowding was evident on

the initial study models (Figure 3). Initial photographs are not presented owing to their low diagnostic quality. The posterior occlusion was Class I, with the premolars and first molars exhibiting excessive lingual crown inclination. An impacted upper left third molar was evident on the radiographs. The remaining dentition appeared healthy with adequate bone support. Cephalometrically, the lower incisors were significantly retroclined compared with the standard Steiner analyses (Figure 4, page 1236). This manifested an obtuse interincisal angle, resulting in a lack of incisal support.

Treatment objectives. The clinician (R.A.M.) planned upper-arch treatment to relieve the crowding by minor interproximal reduction, advancing the anterior teeth, and expanding and uprighting the posterior teeth. Lower-arch objectives were to relieve the crowding by minor inter-

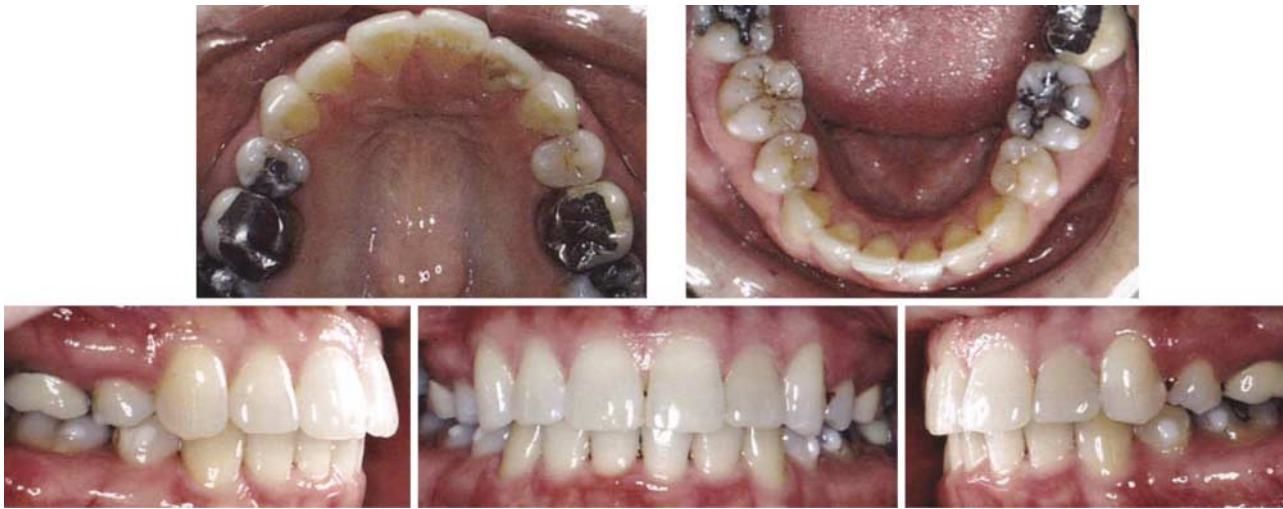

Figure 2. Case report 1: posttreatment photographs.

proximal reduction, advancing the anterior teeth, and expanding and uprighting the posterior teeth. Another goal of treatment was achieving incisal guidance and cuspid rise during functional excursions while maintaining good oral hygiene. The clinician planned to leave the impacted third molar in place for the duration of treatment.

Treatment. The clinician took PVS impressions of the upper and lower arches. He sent these impressions with a centric occlusion PVS bite registration to Align Technology. He reviewed a virtual 3-D setup, then the manufacturer created a series of Aligners (32 upper and 43 lower) and sent them to the clinician. At the initial appliance delivery appointment, the clinician bonded attachments to the buccal surface of the mandibular canines to assist in Aligner retention during the leveling of the curve of Spee. Then he performed air-rotor stripping on the upper right canine and the lower canines to allow them to rotate and to assist in reducing the crowding of the upper and lower arch. This was done in a manner similar to the interproximal reduction discussed in Case 1. However, in this instance, the clinician used a slow-speed handpiece and metallic diamond-coated disks.

The clinician gave the patient the first three Aligners of the series and instructed her to change to the next set of Aligners in the series every two weeks, removing them only for eating,

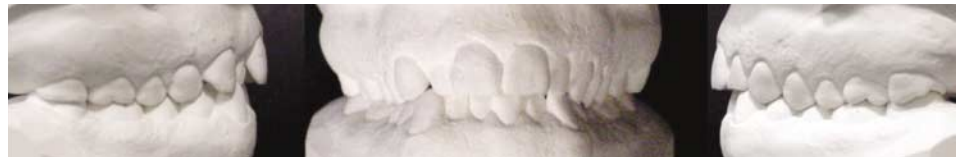

Figure 3. Case report 2: pretreatment models showing Class I occlusion with mild maxillary arch crowding, moderate-to-severe mandibular crowding and anterior single-tooth crossbite.

drinking and oral hygiene. Appointments were scheduled every six weeks for observation and delivery of the next series of Aligners. The patient's total treatment time was 16 months for the upper arch and 21 months for the lower arch. After treatment, the clinician bonded a fixed lingual retainer to the mandibular anterior teeth. The maxillary teeth were retained with a plastic (vacuum-formed) retainer. The clinician instructed the patient to wear it full-time for one year, followed by nighttime wear for an indefinite period.

Results and discussion. The posterior sagittal relationship was maintained (Figure 5). Superimposition of the virtual 3-D setup with initial and final positions shows that inclination of the posterior teeth was planned to be corrected to an extended and more upright position (Figure 6, page 1237) (Table). Approximately 4 to 6 mm of expansion, measured from buccal cusp tip to buccal cusp tip, was achieved in the posterior arches (Table). The lower incisors were proclined 13 degrees, as measured on the headfilm (Figure 4), to result in a proper overbite and overjet relationship. Incisal guidance, canine rise during functional excursions and good oral hygiene were achieved. At 1½ years after treatment, the results

appear to be very stable and the long-term prognosis is good.

CASE REPORT 3

Examination. The patient was a 25-year-old woman with the chief concern of upper-arch and lower-arch crowding. Her medical history was

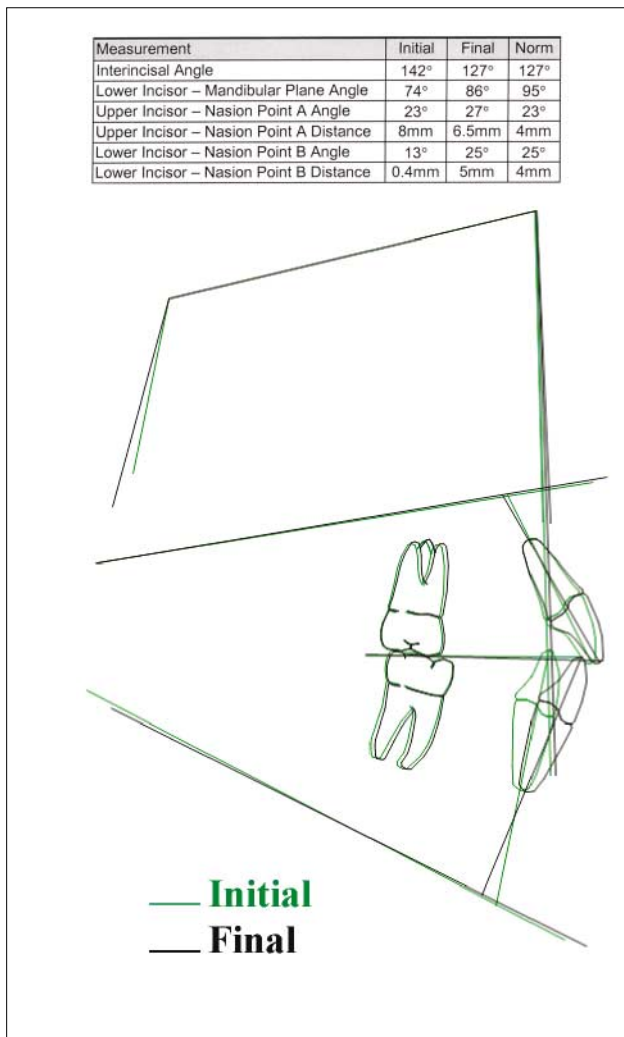


Figure 4. Case report 2: pretreatment and posttreatment cephalometric tracings illustrating movement of incisors.

unremarkable and she had a history of routine dental care. The patient had Class I dental occlusion with a moderately crowded mandibular arch and a mildly crowded maxillary arch (Figure 7). The upper right lateral incisor was in crossbite with the lower right canine. There was a clinically significant tooth size discrepancy owing to the narrow maxillary lateral incisors. Periodontally, the patient had a mucogingival problem owing to minimal attached tissue on the facial aspect of teeth nos. 25 and 27. Radiographic survey found full eruption of all teeth except for the third molars, which were not present. Cephalometrically, the patient exhibited mild incisor proclination.

Treatment objective. The goals for the lower arch were to alleviate crowding by extracting one lower incisor and then to properly align the lower anterior teeth. The clinician (R.S.L.) also planned to align the maxillary incisors. Another objective was maintenance of the posterior sagittal and transverse relationship. Additionally, the plan included improvement in the mucogingival problem of teeth nos. 25 and 27, along with maintenance of good oral hygiene.

Treatment. The clinician took PVS impressions of the upper and lower arches. These impressions were sent with a centric occlusion PVS bite registration to Align Technology. The clinician reviewed a virtual 3-D setup, then the manufacturer created a series of Aligners (11 upper and 24 lower) and sent them to the clinician. At this point, the clinician extracted tooth no. 25. Then at the initial appliance delivery appointment, the clinician bonded attachments to the buccal surface of the mandibular premolars to assist in Aligner retention during the leveling of the curve of Spee. Also, he bonded attachments to the mandibular right canine and to each of the mandibular incisors adjacent to the extraction site to assist in canine uprighting and in the planned translational movements of incisors

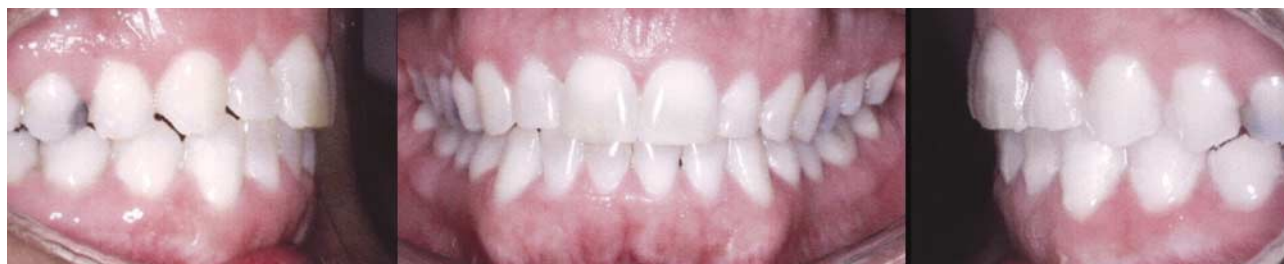

Figure 5. Case report 2: posttreatment photographs.

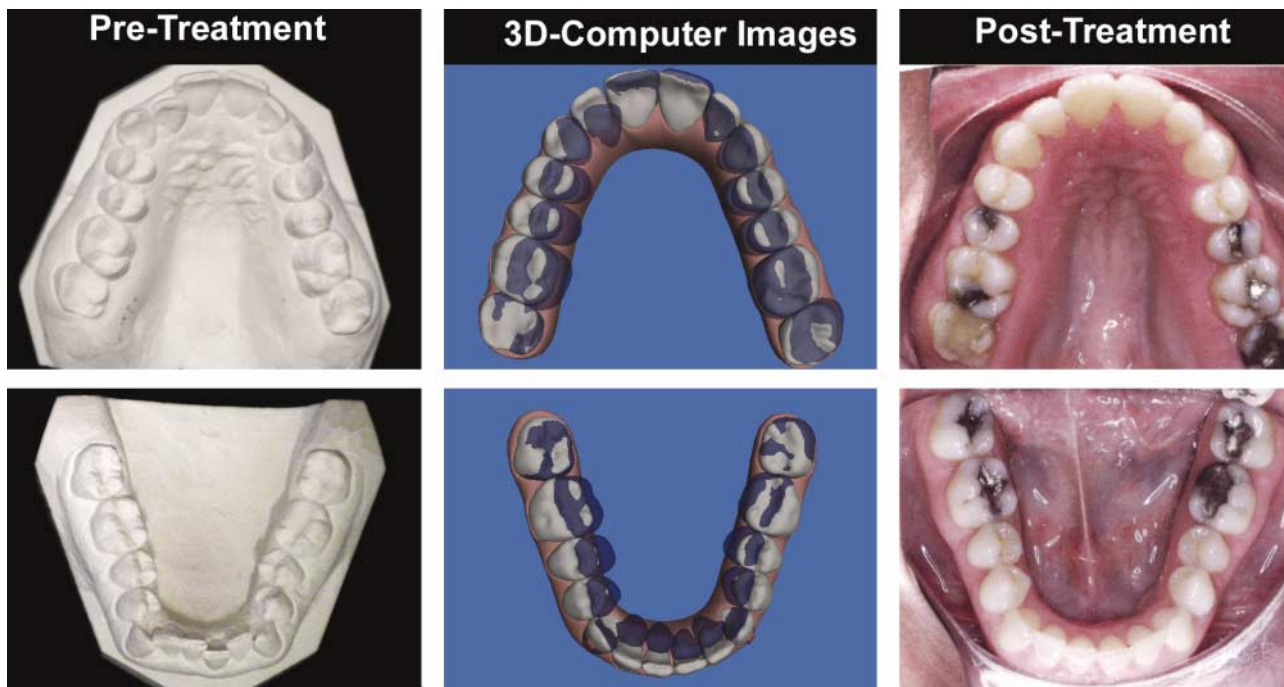


Figure 6. Case report 2: pretreatment and posttreatment photographs and 3-D computer images demonstrating the expansion and advancement of the incisors (blue shadow indicates initial position and white tooth indicates planned final position).

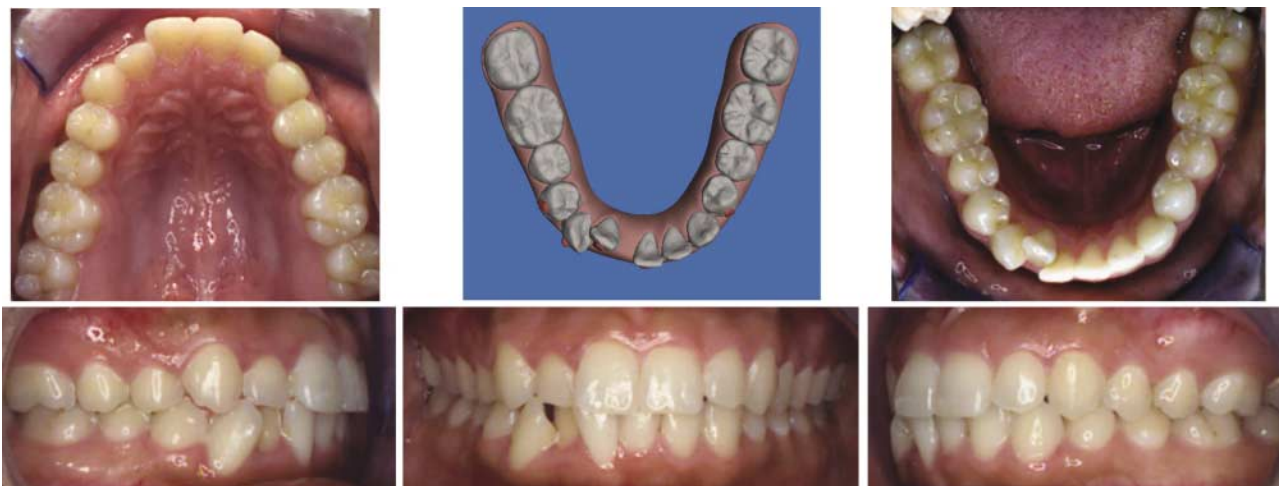

Figure 7. Case report 3: pretreatment photographs showing mild maxillary arch crowding and moderate mandibular arch crowding and 3-D computer image showing extraction plan.

during space closure.

The clinician gave the patient the first three Aligners of the series and instructed her to change to the next set of Aligners in the series every two weeks, removing them only for eating, drinking and oral hygiene. Appointments were scheduled every six weeks for observation and delivery of the next series of Aligners. The patient's total treatment time was six months for the upper arch and 12 months for the lower arch.

After treatment, both arches were retained with plastic (vacuum-formed) retainers. The clinician instructed the patient to wear them full-time for one year, followed by nighttime wear for an indefinite period.

Results and discussion. Class I molar and canine relationships as well as upper and lower arch widths were maintained (Table). Tooth no. 27 was aligned within the arch, thereby improving the mucogingival situation in that

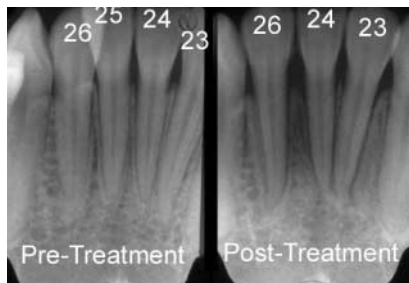


Figure 8. Case report 3: pretreatment and posttreatment periapical radiographs of extraction region.

area. The area of the incisor extraction exhibited the same amount of root proximity as initially present (Figure 8). Retrospectively, more distal root tip could have been

incorporated into the original plan to reduce the root proximity in the final result. When comparing the final alignment of incisors clinically with the final alignment of the incisors virtually, one can see that the incisor alignment is reflective of the virtual 3-D setup (Figure 9). More proclination of tooth no. 26 and distal rotation of tooth no. 23 could have been incorporated into the treatment for a more ideal alignment. At 1½ years after treatment, the results appear to be very stable, and the long-term prognosis is good.

DISCUSSION

These cases demonstrate in a variety of ways how the Invisalign appliance was used to treat crowding of upper and lower arches. Minor crowding of the arch can be resolved by simple alignment of teeth as demonstrated in the upper arches in Cases 1 and 3. In cases involving more crowding, in which the goal is to maintain posterior arch width, crowding can be resolved primarily with interproximal reduction or a lower

incisor extraction to avoid excessive advancement of the incisors, as seen in the lower arches in Cases 1 and 3. In contrast, when posterior width and incisor position can be improved, as shown in Case 2, the appliance effectively used posterior expansion and incisor proclination, thus increasing arch width and length (Table).

Alternative treatment options offered to these patients at consultation included a variety of fixed appliances or restorative therapy, but all three patients opted for the esthetic and convenient benefits of these clear removable appliances. The degree of crowding of the arches in these cases likely would have precluded treatment with other existing options of removable appliances. This clear removable appliance is advantageous in treating patients with many restorations (such as multiple crowns) because it eliminates the difficulty of bonding fixed appliances to such restorations. Additionally, potential metal allergy reactions associated with fixed appliances were avoided.

Another advantage of this appliance is the ability it offers the clinician to direct each stage from the outset with 3-D computer simulations. Conversely, a disadvantage is that once the treatment is started, changes to the treatment may require additional time, documentation or both. Doctors who initially take time and care in planning the appropriate treatment may minimize such occurrences. Another potential disadvantage of this type of appliance is that it is highly dependent on patient compliance. However, current data suggest that this rarely is an issue.^{9-12,23,24}

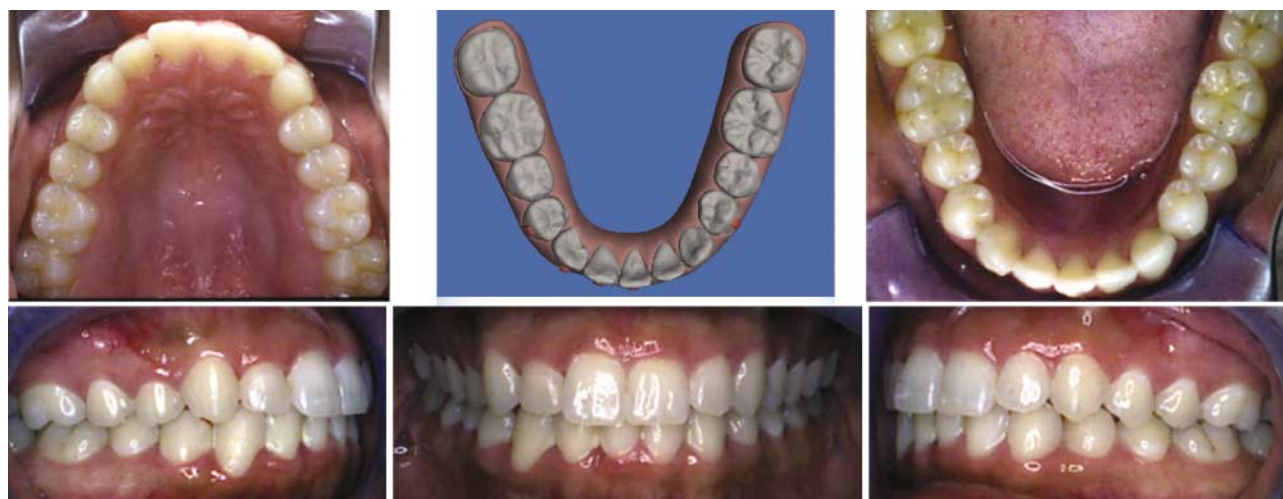

Figure 9. Case report 3: pretreatment and posttreatment photographs and 3-D computer images demonstrating the closure of the extraction space.



Dr. Chenin holds a part-time faculty position, Restorative Department, University of the Pacific School of Dentistry, San Francisco. He also is the manager, Clinical Process Development in Manufacturing Operations, Align Technology, Santa Clara, Calif., and maintains a practice in Las Vegas. Address reprint requests to Dr. Chenin at 4306 S. Eastern Ave., Las Vegas, Nev. 89119, e-mail "DrDavidChenin@aol.com".



Dr. Trosien is in private practice in Tracy, Calif., and is an orthodontic consultant at Align Technology, Santa Clara, Calif.



Dr. Miller is in private practice in Culpeper, Va., and Park City, Utah.



Dr. Lee is a clinical professor at the University of the California at San Francisco, Orthodontic Department, and is in private practice in San Francisco.

There were no compliance issues with these patients and treatment times appear to be on par with what might be expected with fixed appliances. Treatment cost to the patient is comparable with costs of other types of orthodontic treatment.

CONCLUSION

In all three cases reported here, the Invisalign appliances successfully relieved the patients' crowded arches. Furthermore, the patients' gingival health was maintained throughout treatment and decalcification of the enamel surface of the teeth was avoided. None of the three patients noted discomfort during any part of the treatment. Overall, use of this appliance by treating clinicians offers an alternative procedure to restorative or fixed appliance therapy for an array of malocclusions.⁹⁻²³ ■

Dr. Fong is in private practice in Sacramento, Calif.

Authors Dr. Chenin and Dr. Trosien are shareholders of and affiliated with Align Technology, Santa Clara, Calif., manufacturer of Invisalign.

The authors thank Drs. Mitra Derakhshan and Ayse Noganer-Turley for their review of the manuscript of this article.

Authors' note: Readers interested in additional images of the treatment of the cases described in this article may find them at "www.invisalign.com", where they should click on the link to the "Case Studies" section.

1. Kessler M. Interrelationships between orthodontic and periodontics. *Am J Orthod* 1976;70:154-77.
2. Ashley FP, Usiskin LA, Wilson RF, Wagaiyu E. The relationship

between irregularity of the incisor teeth, plaque, and gingivitis: a study in a group of schoolchildren aged 11-14 years. *Eur J Orthod* 1998;20(1):65-72.

3. Poulton D, Aaronson SA. The relationship between occlusion and periodontal status. *Am J Orthod* 1961;47:690-9.

4. Bilimoria KF. Malocclusion: its role in the causation of periodontal disease: an epidemiologic study. *J Indian Dent Assoc* 1963;35:293-300.

5. Buckley LA. The relationship between malocclusion and periodontal disease. *J Periodontol* 1972;43:415-7.

6. Buckley LA. The relationships between irregular teeth, plaque, calculus and gingival disease. *Br Dent J* 1980;148:67-9.

7. Diedrich P. Periodontal relevance of anterior crowding. *J Orofac Orthop* 2000;61(2):69-79.

8. Nelson PA, Artun J. Alveolar bone loss of maxillary anterior teeth in adult orthodontic patients. *Am J Orthod Dentofacial Orthop* 1997;111:328-34.

9. Boyd RL, Miller RJ, Vlaskalic V. Invisalign system in adult orthodontics: mild crowding and space closure cases. *J Clin Orthod* 2000;34:203-12.

10. Boyd RL, Vlaskalic V. Three-dimensional diagnosis and orthodontic treatment of complex malocclusions with the Invisalign appliance. *Semin Orthod* 2001;7(4):274-93.

11. McNamara Jr. JA, Brudon WL. Invisible retainers and Aligners. In: McNamara JA Jr., Brudon WL, eds. *Orthodontics and dentofacial orthopedics*. Ann Arbor, Mich.: Needham; 2001:475-86.

12. Miller RJ. Using the Invisalign system. Available at: "www.oc-j.com/june01/Invisalign.htm". Accessed Aug. 4, 2003.

13. Miller RJ, Derakhshan M. The Invisalign system: case report of a patient with deep bite, upper incisor flaring, and severe curve of Spee. *Semin Orthod* 2002;8(1):43-50.

14. Miller RJ, Duong T, Derakhshan M. Lower incisor extraction treatment with the Invisalign system. *J Clin Orthod* 2002;36(2):95-102.

15. Silverstein LH, Kurtzman D, Cohen R, Witkin G. Adjunctive orchestrated orthodontic therapy: a new trend in cosmetic dentistry. *Dent Today* 2001;20(11):74-81.

16. Silverstein LH, Witkin G. Adjunctive orchestrated orthodontic therapy. *J Gen Orthod* 2001;12(3):19-22.

17. Vlaskalic V, Boyd RL. Orthodontic treatment of a mildly crowded malocclusion using the Invisalign system. *Aust Orthod J* 2001;17(1):41-6.

18. Wong BH. Invisalign A to Z. *Am J Orthod Dentofac Orthop* 2002;121(5):540-1.

19. Bishop A, Womack WR, Derakhshan M. An esthetic and removable orthodontic treatment option for patients: Invisalign. *Dent Assist* 2002;71(5):14-7.

20. Norris RA, Brandt DJ, Crawford CH, Fallah M. Restorative and Invisalign: a new approach. *J Esthet Restor Dent* 2002;14(4):217-24.

21. Miller RJ, Kamisugi A, Derakhshan M. Two patients treated with Invisalign: crowding resolved via expansion and an anterior openbite case with a discussion on overcorrection. Available at: "www.oc-j.com/sept02/Invisalign.htm". Accessed Aug. 1, 2003.

22. Womack WR, Ahn JH, Ammari Z, Castillo A. A new approach to correction of crowding. *Am J Orthod Dentofacial Orthop* 2002;133(3):310-6.

23. McNamara JA, Kramer KL, Juenker JP. Invisible retainers. *J Clin Orthod* 1985;19:570-8.

24. Lindauer SJ, Shoff RC. Comparison of Essix and Hawley retainers. *J Clin Orthod* 1998;32:95-7.