



# INTEGRA™ BILAYER WOUND MATRIX



## TREATMENT GUIDELINES

Collagen Soft Tissue Technology



## Product and Procedure Overview

**INTEGRA™ Bilayer Wound Matrix** is an advanced wound care device comprised of a porous matrix of cross-linked bovine tendon collagen and glycosaminoglycan and a semi-permeable polysiloxane (silicone layer). The semi-permeable silicone membrane controls water vapor loss, provides a flexible adherent covering for the wound surface and adds increased tear strength to the device. The collagen-glycosaminoglycan biodegradable matrix provides a scaffold for cellular invasion and capillary growth.

These guidelines have been developed based on the collective best practices of experienced users of the INTEGRA™ Bilayer Wound Matrix (IBWM). They are intended to be a quick reference to important information on the use of the IBWM and as a supplement to the Physician Training Modules and your unit's own protocols. For additional information contact your Reconstructive Sales Specialist or a Technical Representative at 877-444-1122 or 609-275-9004.



# TABLE OF CONTENTS

<b>PROCEDURE #1: EXCISION AND APPLICATION</b> .....	<b>6</b>
<b>I. Pre-Operative Guidelines</b> .....	<b>6</b>
Operating Room Supplies .....	6
Outpatient Clinic Supplies .....	6
Estimating Number of Sheets .....	7
<b>II. Intraoperative Guidelines</b> .....	<b>9</b>
Preparing for Application of IBWM .....	9
Product Preparation .....	9
Wound Bed Preparation .....	10
Application of IBWM .....	12
<b>III. Post-Operative Care Guidelines</b> .....	<b>15</b>
Dressing Changes .....	15
Inspection .....	15
Positioning and Moving the Patient .....	16
Physical Therapy/Occupational Therapy .....	16
Neodermis Formation .....	17
Home Health .....	17
Negative Pressure Wound Therapy (NPWT) .....	18
Complications and Interventions .....	20
<b>PROCEDURE #2: SILICONE REMOVAL AND EPIDERMAL AUTOGRAFTING</b> .....	<b>23</b>
Planning for Epidermal Grafting (if necessary) .....	23
Removal of Silicone .....	23
Inspect and Prepare the Neodermis .....	23
Harvesting the Thin Epidermal Autograft .....	24
Placing the Epidermal Graft .....	24
Epidermal Autograft Dressings and Care .....	24
<b>APPENDIX</b> .....	<b>26</b>
<b>Photographs and Illustrations</b> .....	<b>26</b>
Clinical Sequence .....	27
Product Preparation .....	29
Dressing Regimen .....	31
Tissue Remodeling .....	33
Tissue Remodeling Timeline .....	35
Silicone Removal and Epidermal Grafting .....	37

# TABLE OF CONTENTS

<b>COMPLICATIONS</b> .....	<b>39</b>
Large Hematoma .....	39
Small, Late-Forming Hematoma .....	39
Fluid Accumulation .....	40
Non-Take/Shearing of IBWM .....	40
Infection .....	41
<b>CASE STUDIES</b> .....	<b>42</b>
Achilles Wound.....	42
Heel Wound .....	43
Traumatic Degloving Calcaneal Fracture .....	44
Leg Ulceration.....	45
Hypercoagulable Disorder.....	47
<b>Package Insert</b> .....	<b>48</b>

# Procedure #1: EXCISION AND APPLICATION

## I. Pre-Operative Guidelines

### Operating Room Supplies

In addition to standard OR supplies for a procedure, the following supplies should be available in the OR:

- Electrocautery instrumentation (i.e., bovie, double plug, bipolar) for pin-point coagulation
- Excisional Devices (i.e., scalpel, Versajet® Hydrosurgery System, curettes, Dermabrader)
- Antimicrobial agents/dressings\*
- Compression dressings/wraps
- “Non-crushing” Mesher\*\* (if planning to mesh IBWM 1:1); Note: “pie-crusting” is also acceptable
- Splints and braces

### Outpatient Clinic Supplies

In addition to standard supplies for a procedure, the following supplies should be available in the clinic:

- Hemostatic agents (i.e., epinephrine soaked gauze, electrocautery, thrombin spray)

---

\* (i.e., Acticoat® silver impregnated dressing, Sulfamylon® Solution 5%, silver nitrate solution 0.5%)

---

\*\* A non-crushing mesher refers to a fixed ratio mesher that is known not to crush or tear the matrix. (i.e., Brennen™ Mesher)

---

- Excisional devices (i.e., scalpel, Versajet® Hydrosurgery System, curettes)
- Antimicrobial agents/dressings\*
- Compression dressings/wraps
- “Non-crushing” Mesher\*\* (if planning to mesh IBWM 1:1);  
Note: “pie-crusting” is also acceptable
- Immobilization/off-loading devices (i.e., bolsters, splints, boots, casts, braces)

### Estimating Number of Sheets

Estimate the number of sheets of IBWM you will need using the following guidelines and chart:

1. Determine size of area to be covered.(i.e., 9% TBSA for an adult or approx.1750 cm<sup>2</sup>).
2. Determine product size (i.e., 20 x 25 cm). The following chart provides size suggestions based on anatomical site. If you are planning to mesh the IBWM, it is suggested that you use the 10 x 25 cm (4 x 10 inch) or smaller size.
3. Calculate number of sheets by dividing **Surface Area** by **Sheet Area** (i.e., 1750 cm<sup>2</sup> / 500 cm<sup>2</sup> = 3.5 sheets).
4. Due to difficulties in estimating surface area and losses due to trimming, it is often advisable to allow for an additional 10% (i.e., 3.5 sheets X 1.10 = 3.85 sheets).

---

\* (i.e., Acticoat® silver impregnated dressing, Sulfamylon® Solution 5%, silver nitrate solution 0.5%)

---

\*\* A non-crushing mesher refers to a fixed ratio mesher that is known not to crush or tear the matrix. (i.e., Brennen™ Mesher)

---



**Approximate surface area per sheet of IBWM**

2 x 2 inches = 25 sq. cm.

4 x 5 inches = 125 sq. cm.

4 x 10 inches = 250 sq. cm.

8 x 10 inches = 500 sq. cm.

**Estimated number of IBWM sheets needed per adult anatomy**

Face = 1-2, 8 x 10's

Neck = 2-3, 4 x 10's

Anterior trunk = 4, 8 x 10's; 1-3, 4 x 10's

Posterior trunk = 4-5, 8 x 10's; 1-3, 4 x 10's

Upper extremities = 3-4, 8 x 10's; 1-4, 4 x 10's

Buttocks = 2-4, 8 x 10's

Lower extremities = 4-8, 8 x 10's; 1-6, 4 x 10's

Hands/feet = 1-3, 4 x 10's; 1-3, 4 x 5's

## II. Intraoperative Guidelines

---

### Preparing for Application of IBWM

- In the outpatient setting, a local anesthetic or nerve block may be required prior to wound preparation.
- Remove all excised tissue and contaminated OR equipment from the sterile patient field before application begins.
- Re-drape area and re-gown as needed. Change gloves before handling IBWM. New sterile instruments are required for IBWM placement, shaping and cutting.

### Product Preparation

- Fill a basin with 1 liter of sterile saline. The circulating nurse opens the outer Tyvek® pouch. The foil pouch is placed in a sterile field.

#### **Always handle IBWM using aseptic technique.**

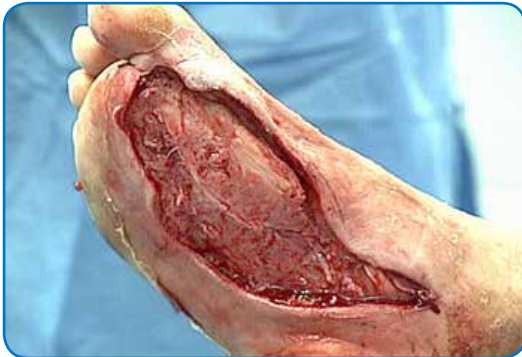- On a sterile surface, the foil pouch is peeled open by the scrub nurse.

#### **Note: IBWM is packaged between 2 polyethylene sheets and an attached center tab.**

- While holding the tab, gently peel off one of the polyethylene sheets from IBWM.
- Gently peel off the other polyethylene sheet from IBWM.
- While holding the tab, the product can now be placed into a basin containing the sterile saline solution. Carefully remove IBWM from the tab.
- Rinse IBWM for 1-2 minutes. Keep the IBWM in the saline bath until application.

## Wound Bed Preparation

- Complete excision to viable tissue. Fascia, fat, dermis, muscle and avascular structures are all suitable if the wound bed meets the following requirements:
  - Free from contamination and infection
  - Adequate vascular supply
  - Dry with no signs of bleeding (meticulous hemostasis)
  - Uniform and flat to ensure intimate contact with IBWM
- Prior to placing IBWM, the wound bed may be prepped with a surgical prep/wound cleaner or “Betadine®- type” solution scrub. Do not use Dakins solution to prep the wound bed.



## **GRAFT BED REQUIREMENTS**

### **Free from contamination and infection:**

- Remove all non-viable tissue from wound bed — eschar, necrotic, devitalized and contaminated tissue.
- If wound infection is detected, treat topically and/or systemically according to unit protocols.
- For staged burn excision, it is preferable to have a “zone” between the IBWM and the remaining burn eschar. This “safety zone” should be 2-4 centimeters wide and the excised zone is then covered with one of the following: allograft, xenograft, Biobrane®, Acticoat®, 5% Sulfamylon® soaked gauze, 0.5% silver nitrate soaked gauze. The safety zone is left in place until the patient is brought back and the remaining eschar is excised.

### **Adequate vascular supply:**

- Adequate vascular supply is required prior to IBWM application.
- Punctate, uniform capillary bleeding indicates adequate excision of non-viable tissue.
- In certain situations (i.e., obese patients), incising to viable fat may not provide an adequate blood supply.
- Avascular structures should be debrided down to viability (i.e., tendon decortication, bone planing down to punctate bleeding).

### **Dry with no signs of bleeding (meticulous hemostasis):**

- Meticulous hemostasis needs to be achieved to prevent hematomas or excessive fluid accumulation.
- To achieve, utilize epinephrine, pinpoint electrocautery, thrombin spray, thrombin-soaked gauze or other topical hemostats. Avoid broad area cauterization which can lead to devitalized tissue.

**Uniform and flat wound bed to ensure intimate contact with IBWM:**

- Achieve level tissue planes.
- When necessary, marsupialize edges to avoid large step-offs between the wound bed and normal skin.

**If meshing IBWM:**

- Use maximum 4x10 inch sheets to avoid folding.
- Sheets can be meshed before or after rinsing.
- Run sheets through a “non-crushing” mesher (i.e., Brennen™ Mesher).
- Handle sheets with gloved hands, do not use instruments.
- Mesh sheets 1:1 but do not expand.

## Application of IBWM

**1. Getting Started:**

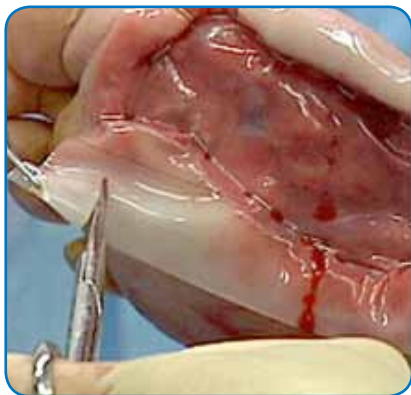- Silicone side is identified by black threads.
- Start at edge of wound bed.
- Do not allow IBWM to come in contact with un-excised necrotic tissue.

**2. Anatomical Site Considerations:**

- IBWM may be used on all anatomical sites.
- Joints should be in a full extension position.
- Avoid applying sheets too tightly.
- Joints and pressure areas may have an increased risk of mechanical dislodgement.

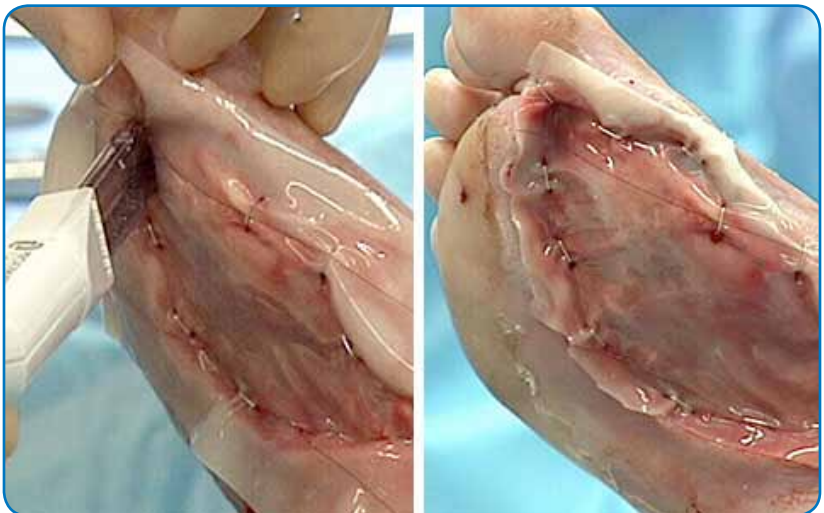
### 3. Sheet Placement, Shaping, and Cutting:

- Gently “scoop out” sheets from the holding basin with gloved hands and place directly onto wound bed.
- Do not try to move or “float” sheets like a split-thickness skin graft (STSG). Instead, lift sheets up and reposition.
- There are two basic application techniques:
  - (1) Place sheets on excised wound bed, staple parallel to inside edge of wound bed and trim excess; or
  - (2) Place sheet on excised wound bed, trim sheet to fit site, and staple perpendicular to seam (this allows staples to be placed across seams).
- Cut sheets to avoid gaps.
- Place seam lines along Langer’s Lines to reduce risk of contracture.
- Make sure IBWM lays flat with no wrinkles or bubbles.
- In a staged procedure, do not place IBWM in contact with unexcised necrotic tissue, rather maintain a safety margin (2 - 4 cm) between the excised wound bed and any non-excised necrotic tissue.



## 4. Sheet Fixation

- Stapling/Suturing
  - Staples or sutures may be used.
  - Fix sheets independently and/or staple sheets together with a 2-3 mm overlap to minimize gaps, reducing granulation tissue formation.
  - Interrupted stapling (i.e., leaving a 1-2 centimeter space between staples) can be used to seal edges.
- Elastic Net Dressing
  - Place an elastic net dressing over the IBWM site.
  - When applied correctly, the expanded interstices will be open about 1-2 cm and the silicone will have slight indentations from the elastic net dressing.



## 5. Dressing the IBWM in the OR

- Build dressings in layers. Each layer has an important function:
  1. Fixation Layer — Elastic net dressing for intimate contact.
    - a. Compression Layer — Compression bandage for protection and anti-shear properties.
    - b. Bulky Dressing Layer — Bulky gauze for protection and antimicrobial retention.
  2. Anti-Shear (Optional) — An additional anti-shear layer is sometimes used.
- Antimicrobial Layer — Acticoat®, Silver Nitrate 0.5% or Sulfamylon® Solution 5% soaks to prevent infection.
- Do not let Dakins Solution, petroleum-based products (i.e., Xeroform), or enzymatic debridement agents (i.e., Collagenase), come in contact with the IBWM grafted sites.
- Use splints or bolsters, per unit protocols, during first 5-7 days. Splints should be applied in the OR and should stay on at all times (except when performing wound care).
- Negative Pressure Wound Therapy (NPWT) may be used over unmeshed or meshed IBWM sites, in particular, as a bolster dressing for difficult anatomical sites or wound beds, such as the axilla.

## III. Post-Operative Care Guidelines

---

### Dressing Changes

- Dressings should be changed approximately every 2-3 days, or more often based on patient's condition.

### Inspection

- If an elastic net dressing is used, do not remove staples/sutures.
- Take down all dressings to inspect IBWM sites, seams, and



edges for evidence of hematomas, fluid accumulation, infection/purulence, premature silicone layer separation, and areas of non-take. Inspection may be performed through interstices of elastic net dressing - do not remove unless necessary.

- Remoisten antimicrobial dressing after IBWM inspection.
- Remoisten or reapply antimicrobial dressing as needed, typically every 6-8 hours, or more often for dry climates.
- Replace or change new antimicrobial dressings at least every three days.

## Positioning and Moving the Patient

- The goal when positioning or moving the patient is to minimize shear forces on IBWM sites.
- Common methods used to move the patient include log rolling, use of bed sheet to position patient, use of board to move patient, and use of plastic-coated surfaces (i.e., plastic bag, Mayo Stand cover) designed to reduce friction on the IBWM.
- When using your hands to move patient, care should be taken to reduce stress on the IBWM.
- If the IBWM is used on the back, place patients in prone position. Care should be used when IBWM is on a location that may receive pressure (i.e., back).
- Use of air fluidized, intermittent zero pressure specialty beds, or low air loss beds may be appropriate.
- For outpatient care, special care should be taken to minimize shear of the IBWM.
- Patients should be taught positioning techniques based on where the IBWM is placed.

## Physical Therapy/Occupational Therapy

- Range of motion exercises can be started on Post-operative day (POD) 5-7, providing that IBWM take has been achieved.
- Gentle range of motion (ROM) exercises can begin between POD

5-7, progressing according to your physical therapy/occupational therapy protocol. If complications have delayed healing or the IBWM sheets are not firmly adhered to the wound bed, delay ROM accordingly.

- The decision to remove bulky dressings, bolsters or splints to perform ROM exercises must be made on a case-by-case basis under consultation with PT/OT.
- Care must be taken during PT/OT to minimize the risk of shearing.

### Neodermis Formation

- Beginning POD 1 and extending to POD 14 to 28 or longer, the appearance of the IBWM will vary. The rate and progression of the color change depends on the patient and rate of healing.
- Generally, neodermis color will change through a progression from red to pink to orange/peach to vanilla.
- Neodermis must be inspected for darkened areas or white/gray areas that may result from complications (see “Complications and Interventions” for more info on how to recognize and treat).
- Silicone is typically ready for removal around POD 21 (possibly sooner with use of NPWT); signs that neodermis formation is complete include:
  - Neodermis blanches to the touch; and returns to previous color indicating capillary refill.
  - Silicone wrinkles and may begin to detach from the wound.
  - Granulation tissue (deep red color and granular surface that bleeds easily) has formed at seam lines.

### Home Health

If Home Health is used for dressing changes, please follow the below procedure:

- Supplies that should be available for dressing change in the home environment

- Sterile gloves
- Syringe for irrigation
- Sterile normal saline solution
- Syringe and large bore needle
- Sterile cotton applicators
- Sterile dressing change supplies
- All dressing changes should be performed in accordance with the written physician order
- Dressing change procedure
  - Caution should be used when removing intact dressing (minimizing shear force)
  - Contaminated dressings should be discarded from the field as removed
  - Visual inspection of the IBWM should be completed after dressing removal
    - Inspection is used to identify seroma and hematoma formation as well as to identify potential infection or areas of non-take
    - See “Complications and Interventions” Section for complete listing of techniques used
  - Discard gloves and re-apply new sterile gloves
  - Interventions should be made based on visual findings and written physician orders
  - Rebuild dressing according to physician order, taking care not to apply pressure in a manner that may shear IBWM from wound bed
- Document all findings and report to physician any interventions that were required

## Negative Pressure Wound Therapy (NPWT)

- Negative pressure wound therapy
- Multiple function dressing
  - Bolster effect based on subatmospheric pressure helps to minimize shear forces

- Removes fluid from the wound
  - Improve local blood flow<sup>1</sup>
  - Enhances neovascularization<sup>1</sup>
  - Minimizes frequency of dressing change
  - Application technique
    - Cut the NPWT foam dressing (away from the wound) to fit the size and shape of the wound
    - Trim the drape to cover the foam, plus 3-5 cm border of intact skin
    - Make a small hole in the drape and apply the T.R.A.C. pad
  - Therapy should be set based on physician order
    - Anatomical location and patient tolerance should be considered when prescribing pressure setting
  - NPWT dressing should be removed and IBWM should be visualized every 3 days
    - Dressing change times may vary by prescribing physician
  - Antimicrobials may be used with the NPWT dressing
- Note:** Due to healing time variables, color changes to the matrix at various stages may differ when utilizing the NPWT dressing over IBWM.

---

<sup>1</sup> Acceleration of Integra Incorporation in Complex Tissue Defects with Subatmospheric Pressure. Joseph A. Molnar, M.D., Ph.D., Anthony J. DeFranzo, M.D., Anoush Hadaegh, M.D., Michael J. Morykwas, Ph.D., Perry Shen, M.D., and Louis C. Argenta, M.D. Plastic and Reconstructive Surgery: Volume3 113, No. 5, April 2004, pgs. 1339-1346.

## Complications and Interventions

### **Hematoma POD 0-3** (See pictures on page 39)

Hematomas usually develop in the first 48 hours. Hematomas need to be removed and any bleeding/drainage must be stopped to allow cellular ingrowth into the matrix.

- If hematoma is still in fluid state: evacuate hematoma by inserting an 18-20 gauge hollow point needle with syringe or cotton tip applicator under surface of IBWM and aspirate fluid.
- If hematoma is no longer in fluid state: incise IBWM with a #15 blade, then evacuate clot using a gentle rolling motion with a sponge or tongue blade, or use cotton tip applicator to remove hematoma.
- Control drainage/bleeding by irrigating with diluted epinephrine and reattaching IBWM.
- For a large, persistent hematoma or continued bleeding:
  - Remove necessary staples
  - Lift IBWM using the blunt end of forceps
  - Remove clot
  - Obtain hemostasis with epinephrine, electrocautery, or surgical ligature
  - Return the IBWM gently to original position and re-secure

### **Fluid Accumulation POD 1-5** (See picture on page 40)

In unmeshed IBWM sheets, clear or amber fluid may accumulate under the matrix. Although fluid drainage is a normal part of the healing process, fluid accumulation can lead to infection and/or formation of granulation tissue and should therefore be removed.

Evacuate by aspirating, rolling or “wicking” with a cotton-tip applicator or gauze pad and a 18-20 gauge hollow point needle with syringe or cotton tip applicator under surface on IBWM and aspirate fluid.

**Purulence/Infection POD 0-12** (See picture on page 41)

Infection is the most common cause for loss of IBWM. Common sources are non-viable tissue in the wound bed, or contamination through seams or staple holes. If purulence and infection are promptly dealt with, loss of IBWM sheets can be avoided.

- Remove all signs of possible purulence irrigate, then
  - Aspirate or evacuate by incising/rolling
  - Treat with topical antimicrobials — Irrigate IBWM sites at seams/edges and beneath the silicone layer with a topical antimicrobial such as Sulfamylon® 5% solution/slurry, G-U irrigant, or silver nitrate 0.5% solution. Irrigate frequently (2-6 times daily)
  - Culture and initiate systemic antibiotic therapy
- If aggressive treatment of purulence is not successful as evidenced by increasing purulence/pus, non-take of IBWM (i.e., a “floating” sheet) or silicone separation, then the affected area needs to be removed.
  - Remove only the affected area using a “windowing” (remove silicone over area to be treated, creating a “window” effect), treat with topical antibiotics.
  - Treat as open wound until infection is resolved. Once infection is resolved, apply new IBWM sheet or treat with temporary covers (i.e., allograft) until ready to autograft. If new IBWM sheet is applied then, at time of epidermal autograft, the granulation tissue should be removed, revealing neodermis underneath ready for grafting.

**Areas of Incomplete IBWM Take (i.e., inadequate neodermis formation) POD 5 or higher**

Areas of incomplete take or detachment of the IBWM can result from mechanical dislodgement (due to shear, improper splinting, PT), infection, hematoma, premature silicone separation or damaged matrix.

- There are several options for treating areas of incomplete take

depending on the size of the area, the amount of neodermis formed and timing (i.e., POD).

- Areas under 2 sq.cm. should be monitored for infection but not removed until time of epidermal grafting.
- Areas over 2 sq.cm. should be removed and treated by either (1) reapplication of new IBWM or (2) STSG.
- Identification of poor IBWM take is identified by poor color and lack of adherence (lateral movement of matrix under finger pressure).

### **Premature Silicone Separation POD 1-21**

The silicone layer can be left in place for extended periods without detrimental effects to the underlying neodermis. Premature separation of the silicone is not a problem if it stays in contact with the neodermis.

#### **• *Early Silicone Separation POD 1-9***

- Inspect wound for signs of shearing, fluid collection, hematoma, or infection. Detect loose areas of IBWM by using your finger to slide loose silicone.
- Remove the source of the separation and re-attach.
- If the IBWM is engrafted with evidence of neodermis, then cover exposed neodermis with allograft, xenograft, or epidermal autograft to prevent desiccation.

#### **• *Late Silicone Separation POD 10 or higher***

- Remove source of non-adherence. Remove silicone if unable to re-secure. Apply new adherent if silicone becomes soiled or completely separated.
- If IBWM is not engrafted and there is no evidence of neodermis, remove and replace with new IBWM and/or other graft material.
- If IBWM is engrafted, then cover with allograft, xenograft or epidermal autograft to preserve the neodermis.
- In the event that the silicone layer becomes detached, gently remove the silicone from the IBWM and discard the silicone layer. Place a new non-adherent dressing gently over the IBWM prior to replacing the outer dressing.

## Procedure #2: SILICONE REMOVAL and EPIDERMAL AUTOGRAFTING

---

Epidermal cells migrate from the wound edges to complete wound closure. For large wounds, a thin epidermal autograft may be considered to facilitate wound closure.

### Planning for Epidermal Grafting

- Prior to removal of silicone, assess availability of donor sites:
  - Estimate size of epidermal graft, based on amount of tissue required.
  - Do not remove and expose more neodermis than expanded epidermal graft will cover. The silicone layer may be left in place for extended periods if the staging of the epidermal autograft procedure is required.

### Removal of Silicone

- Remove staples or sutures.
- Use forceps to gently remove silicone; while lifting from edges, peel back carefully (use spatula or blunt instrument to separate if necessary).
- Difficult separation may indicate that neodermis has not fully matured.

### Inspect and Prepare the Neodermis

- Inspect the neodermis carefully.

Remove the following:

- Any excessive granulation tissue at seams, edges, interstices and staple sites.
- Any necrotic tissue.
- Areas of incomplete take.



- Prepare a flat, clean surface using scalpel, scissors, or curettes.
- In preparation for skin graft placement lightly debride the surface of the neodermis with a gauze pad or surgical scrub brush.
- Although neodermis does not bleed easily, if bleeding occurs, control bleeding with an epinephrine-soaked gauze pad.

### Harvesting the Thin Epidermal Autograft

- Expand the site by infusing with saline to facilitate harvesting.
- Harvest a thin epidermal autograft at approximately 0.006 inches:
  - Grafts taken thinner than 0.004 inches may result in poor engraftment due to an insufficient transfer of the basement membrane.
  - Grafts taken thicker than 0.008 inches may result in a residual meshed appearance (if meshing) or a greater risk of donor site scarring.

### Placing the Epidermal Graft

- Place and attach the epidermal graft according to unit protocols.
- Thin epidermal grafts are more fragile than conventional STSG, making handling more difficult:
  - Thinness of graft makes orientation easy to confuse (curl under indicates correct orientation).
  - Use saline to float graft into position.
  - Interstices should be of uniform size and no more than 2 millimeters.

### Epidermal Autograft Dressings and Care

- Dress the donor site per surgical unit protocol.
- Dress and care for epidermal graft sites using the protocols typically used for thick split-thickness skin grafts.
- Similar to dressing IBWM sites, build dressings in layers and immobilize joints in a flexed position.

- Change dressings every third day, unless positive cultures require daily changes.
- If the epidermal graft seems to “disappear,” obtain cultures. In some cases, this is typically the result of the graft being too thin or the presence of infection:
  - If negative, continue to dress normally. Engraftment and confluence should occur within 21 days.
  - If positive, administer antibiotics and continue to monitor closely.

**NOTE:** Certain locations, such as the bottom of the foot or hand, are exposed to increased levels of pressure and general wear; therefore, they have an increased risk of injury and breakdown. Due to this, an epidermal graft greater than 0.008 inches may be needed.

---

Acticoat and Versajet are a registered trademarks of Smith and Nephew, Inc.

Betadine is a registered trademark of Purdue Products L.P.

Biobrane is a registered trademark of UDL Laboratories, Inc.

Brennen is a trademark of Brennen Medical, Inc.

Sulfamylon is a registered trademark of Mylan Bertek Pharmaceuticals, Inc.

Tyvek is a registered trademark of E.I. DuPont.

All other trademarks are the property of their respective owners.

# APPENDIX

## Photographs and Illustrations

---

Clinical Sequence .....	27
Product Preparation .....	29
Dressing Regimen .....	31
Tissue Remodeling .....	33
Tissue Remodeling Timeline .....	35
Silicone Removal and Epidermal Grafting .....	37

### COMPLICATIONS

Large Hematoma .....	39
Small, Late-Forming Hematoma .....	39
Fluid Accumulation .....	40
Non-Take of IBWM .....	40
Infection .....	41

### CASE STUDIES

Achilles Wound .....	42
Heel Wound .....	43
Traumatic Degloving Calcaneal Fracture .....	44
Leg Ulceration .....	45
Hypercoagulable Disorder .....	47

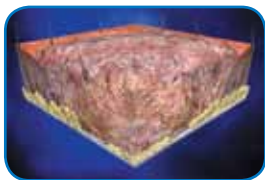## Clinical Sequence

When INTEGRA™ Bilayer Wound Matrix is placed on a surgically debrided or excised wound, it provides the needed framework for the blood vessels and dermal skin cells to remodel the damaged site.

As skin cells migrate into the matrix, the collagen is slowly absorbed into the body and replaced with protein that is naturally produced by the skin. In approximately 14 to 21 days, the scaffold is eventually remodeled as the patient's cells rebuild the damaged site and the silicone layer is removed. Complete wound closure occurs as epidermal cells migrate from the wound edges. For larger wounds, a thin skin graft of the person's epidermis may be applied to the wound area to facilitate complete wound closure.

Wound closure is typically complete within 30 days.

A person is left with a healed wound created from their own tissue.



**DAY 0: PRE-TREATMENT**

All chronic wound patients must have accurate diagnosis and treatment of underlying disease and risks. There must be thorough pre-operative control of inflammation, ulceration, debris and bioburden, and edema (as best as the disease and available treatments permit).



**DAY 1: DEBRIDEMENT**

Prepare wound bed using standard methods to ensure wound is free of debris and necrotic tissue. Regardless of how well the wound has been prepared and how healthy it looks, INTEGRA™ Bilayer Wound Matrix must not be placed on an existing wound surface. The entire existing wound must be completely excised or surgically debrided to ensure the wound bed and edges contain viable tissue.



**DAY 1: APPLICATION**


INTEGRA™ Bilayer Wound Matrix is applied to the excised wound bed. Fluids invade the matrix within minutes of application, adhering it to the wound. The IBWM must conform to and contact the wound surface. Tension within the material will shear the matrix from the silicone, so the material must not be stretched. It can be affixed with sutures, staples, or any suitable alternative.

Dermal cells begin migrating into the matrix and establish a new vascular network. The scaffold is eventually remodeled as the patient's cells rebuild the damaged site.



**DAY 7-14: CELLULAR  
INVASION AND  
CAPILLARY GROWTH**

The silicone layer is removed. The collagen template biodegrades and is absorbed into the body.



**DAY 21+: SILICONE  
REMOVAL**

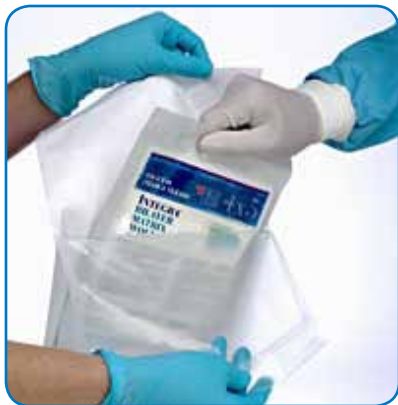Epidermal cells migrate from the wound edges to complete wound closure. For larger wounds, a thin epidermal autograft may be considered to facilitate wound closure. A thin 0.004 – 0.006 in. (0.1016 - 0.1524 mm) epidermal autograft may be applied over the new remodeled skin.

Epidermal coverage over the wound yields a permanent and lasting wound closure.



**DAY 21-56+: WOUND  
CLOSURE**

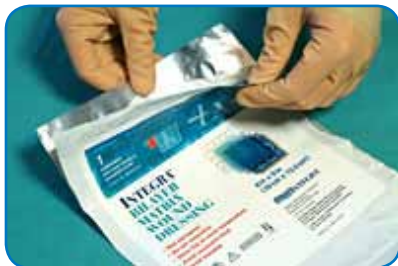## Product Preparation



### Step 1


Fill a basin with 1 liter of sterile saline. Open the outer Tyvek pouch. Place the foil pouch in a sterile field.

Always handle INTEGRA™ Bilayer Wound Matrix using aseptic technique



### Step 2

On a sterile surface, peel open the foil pouch



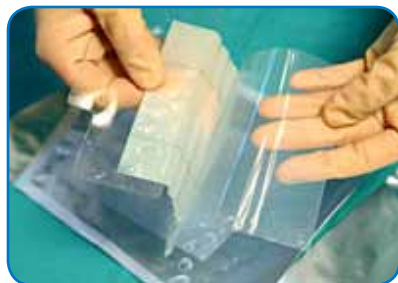### Note:

INTEGRA™ Bilayer Wound Matrix is packaged between 2 polyethylene sheets and an attached center tab



### Step 3

While holding the tab, gently peel off one of the polyethylene sheets from INTEGRA™ Bilayer Wound Matrix




### Step 4

Gently peel off the other polyethylene sheet from INTEGRA™ Bilayer Wound Matrix



### Step 5

While holding the tab, the product can now be placed into a basin containing the sterile saline solution. Carefully remove INTEGRA™ Bilayer Wound Matrix from the tab



### Step 6

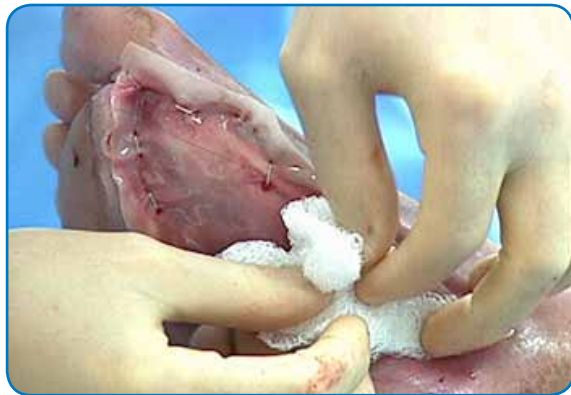Rinse INTEGRA™ Bilayer Wound Matrix for 1-2 minutes, changing saline after every 1-2 sheets, or as needed. Keep the INTEGRA™ Bilayer Wound Matrix in the saline bath until application.

## Dressing Regimen

Fixation and compression are of significant importance. Elastic bandages, padded “tie-over” dressings, vacuum devices, splints and other methods, depending on the circumstances should be used. This ensures that the INTEGRA™ Bilayer Wound Matrix adheres to and is in complete contact with the wound bed and prevents shearing and hematoma or seroma formation.

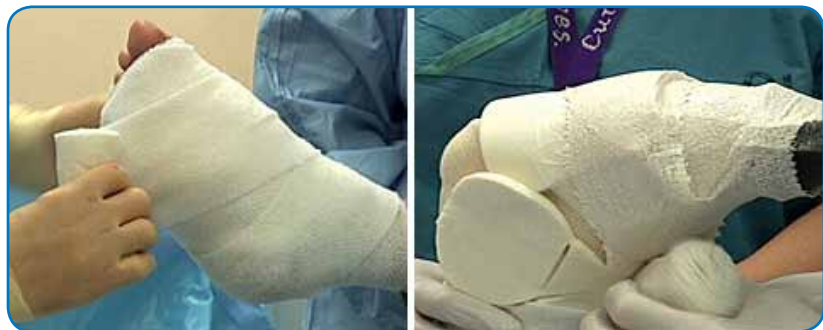### TIPS:

- Apply non-adherent absorbent dressings as the inner dressing layer
- Use topical antimicrobials such as silver impregnated dressings to help maintain a bacterial barrier over IBWM
- Apply outer absorbent dressings
- Use anti-shear dressings
- Use bolsters where appropriate
- Use bandages to apply slight pressure over outer dressings
- Immobilize joints and limbs (e.g., by splints, casts) to prevent dislodgement




Kerlix fluffs are being used to ensure INTEGRA™ Bilayer Wound Matrix is in complete contact with the wound bed



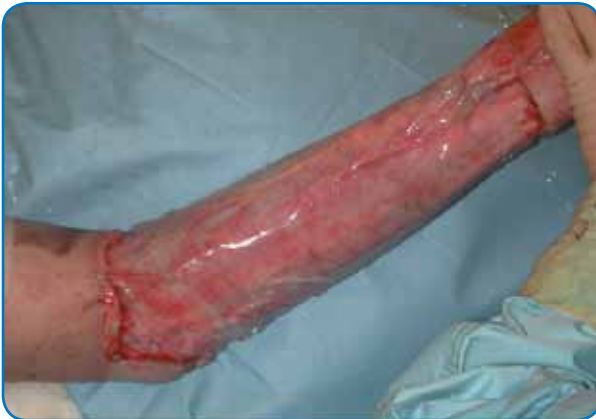

In this case, cotton cast padding followed by a bias stockinet and total contact cast was used to ensure INTEGRA™ Bilayer Wound Matrix remained in contact with the wound bed

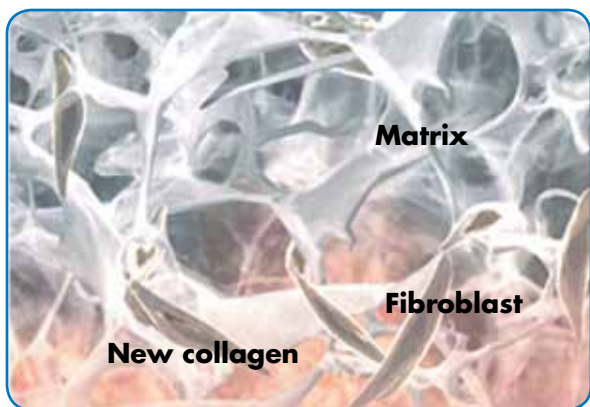
## Tissue Remodeling



Scaffold for cellular invasion and capillary growth.  
Scaffold is remodeled as patient's cells rebuild  
the damaged site

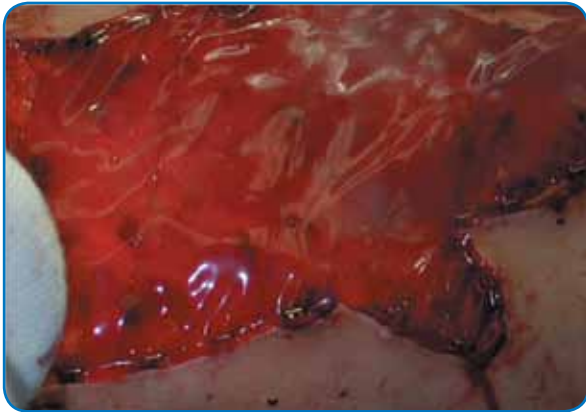


Engraftment and confluence of the epidermal graft  
complete the process

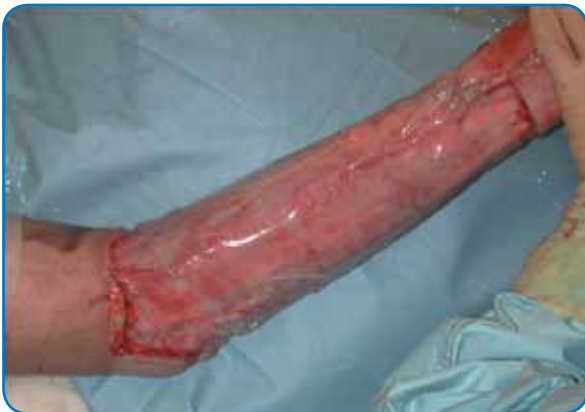

Cellular infiltration of matrix

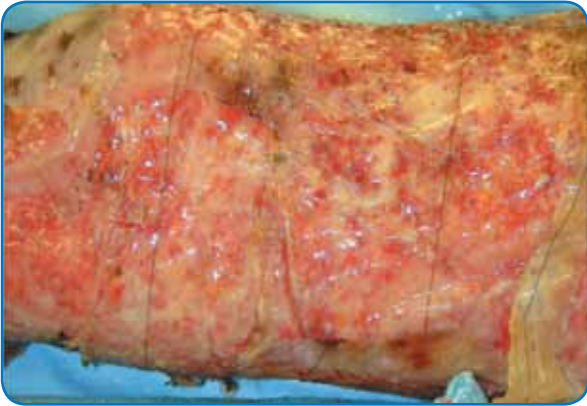
## Tissue Remodeling Timeline



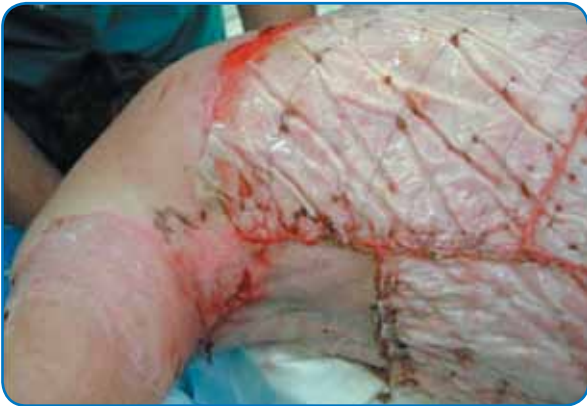**Day 0**



**Day 7**

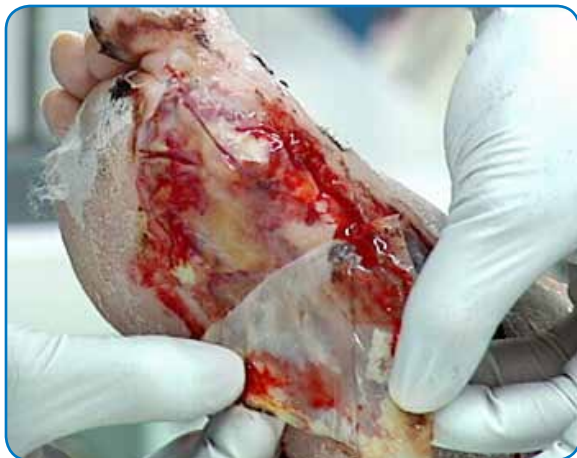

**Day 14**

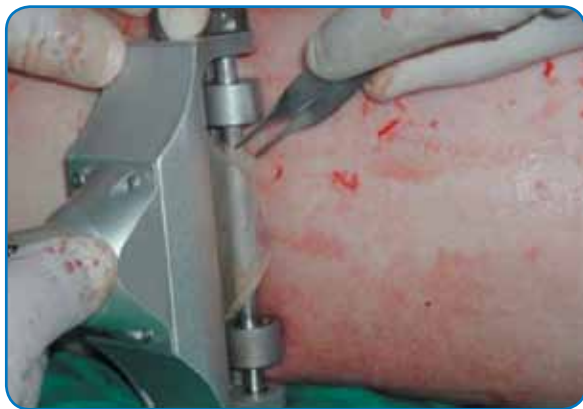

**Day 21**

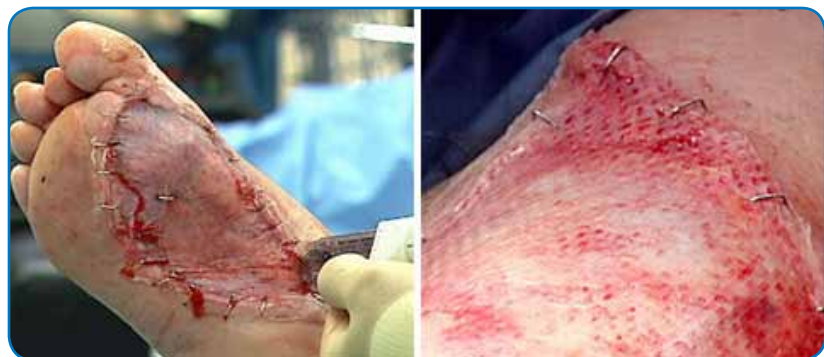
## Silicone Removal and Epidermal Grafting



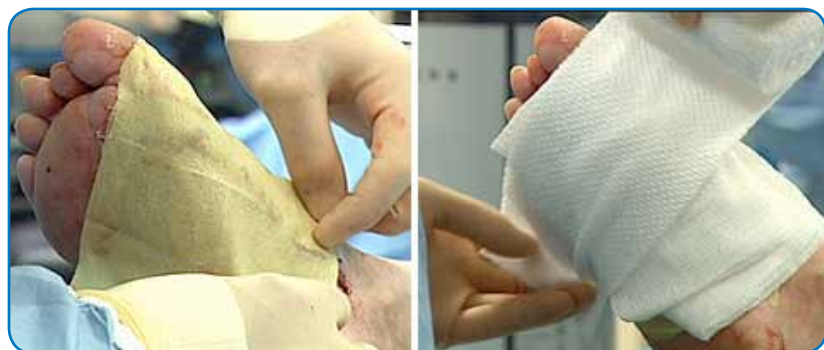**Removal of silicone layer**



**Using dermatome to harvest thin epidermal autograft from donor site**



**Application and fixation of thin epidermal autograft**

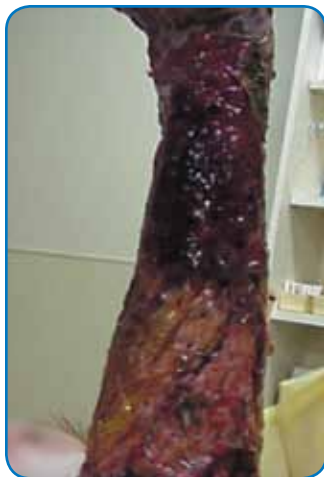

**Bacitracin was added to Xeroform then covered with Kerlix followed by a total contact cast**

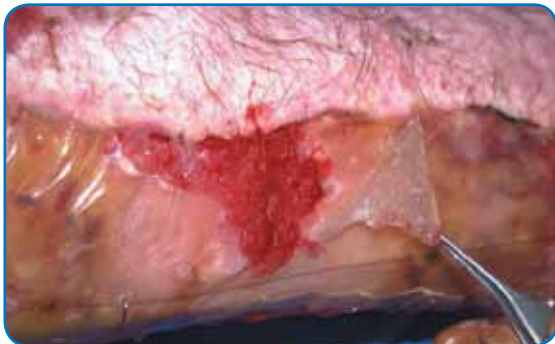

## COMPLICATIONS

### Large Hematoma



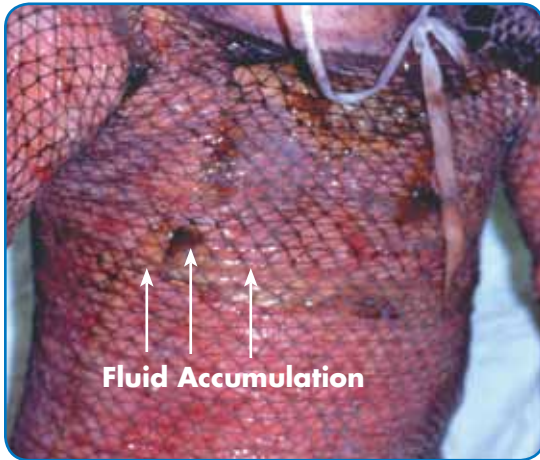
### Small, Late-Forming Hematoma



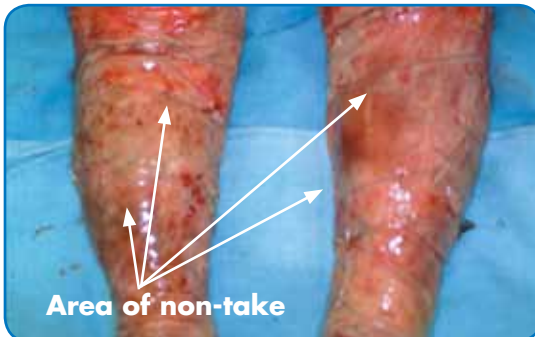


## COMPLICATIONS

### Fluid Accumulation

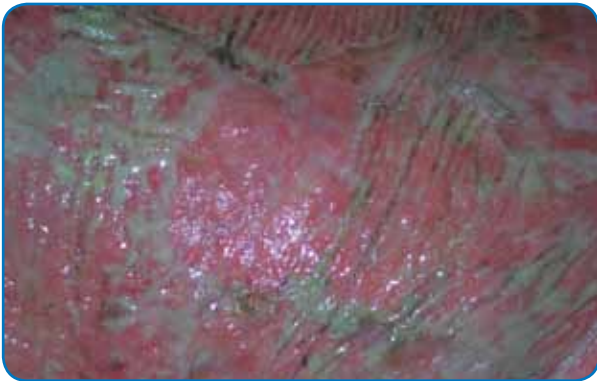
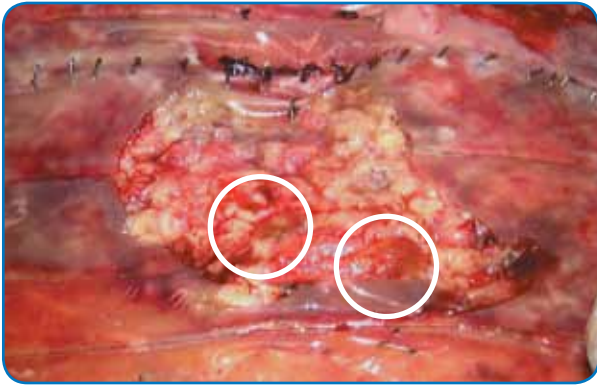


### Non-Take/Shearing of IBWM



## COMPLICATIONS

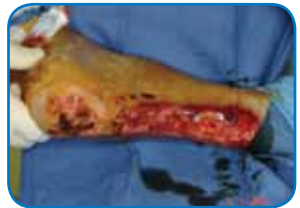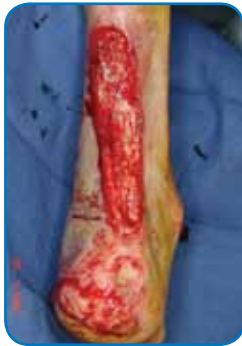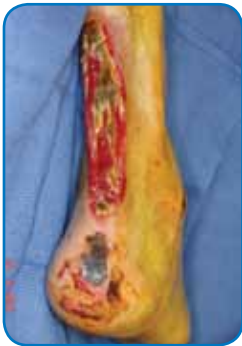### Infection



## CASE STUDIES

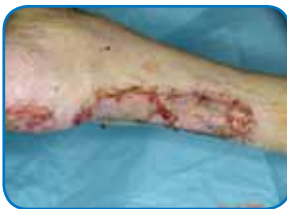### ACHILLES WOUND

- **Exam:** Posterior right leg wound exposed to necrotic achilles tendon measuring 12 x 2.5 cm. Mixed granular and fibrous wound case with concern for bacterial contamination.
- **Treatment:** Patient was admitted for comprehensive management and limb salvage. Angiogram demonstrated patent arterial bypass graft to right leg and serial debridements to achilles site provided viable wound base. Integra IBWM applied over tendon and used to progress site toward closure.



IBWM placed with VAC dressing for deep coverage

Debridement and Wound Bed Preparation

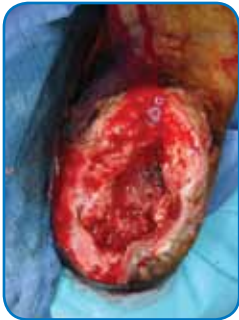

Early epithelialization noted and wound viable with functional soft tissue coverage of achilles tendon

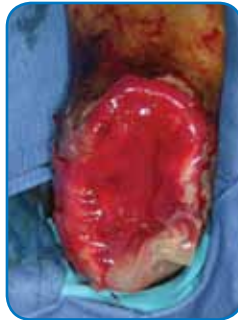## CASE STUDIES

### HEEL WOUND

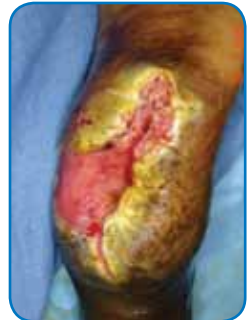- **Exam:** Necrotic heel wound with gangrene and osteomyelitis. Patient has wound site exposed to bone and deep soft tissues after partial calcaneectomy.
- **Treatment:** Patient was treated with aggressive serial debridement and combination antibiotic therapy until infection was cleared. The site then was treated with Integra and VAC. After viable bone and deep coverage was achieved, the site was covered with a STSG.



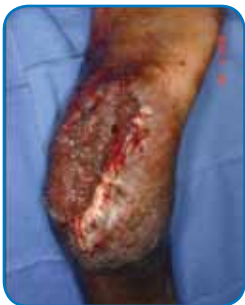Plantar heel defect with exposed bone s/p partial calcaneectomy



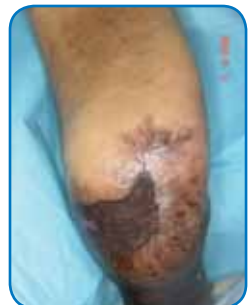IBWM placed with VAC dressing for deep coverage



Wound base granular with viable dermal layer covering bone and deep soft tissues



Site closed with STSG

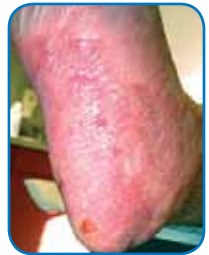
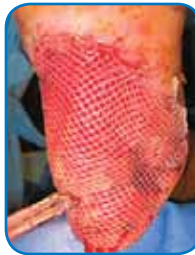
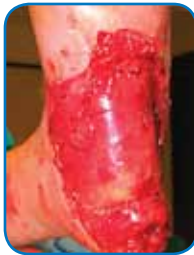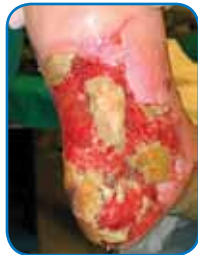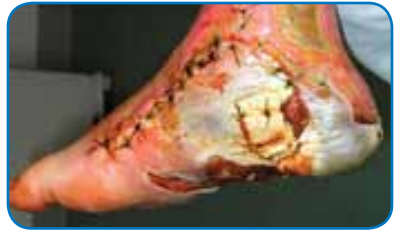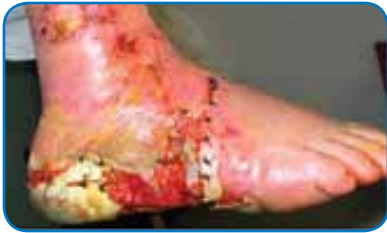Long term follow up (8 months) with stable coverage of heel

## CASE STUDIES

### TRAUMATIC DEGLOVING CALCANEAL FRACTURE

- A 40-year-old white male patient experienced a traumatic degloving calcaneal fracture while at work. The calcaneus was reduced at a local trauma center, while a plastic surgeon was consulted to manage the degloved skin. An attempt was made to salvage as much of the remaining skin as possible.



Application of a wound VAC to the remaining exposed tissue. One month later, the patient was taken to the operating room for debridement of all non-viable skin

Application of INTEGRA™ Bilayer Wound Matrix

Three weeks after application of INTEGRA™ Bilayer Wound Matrix, a split thickness skin graft was applied

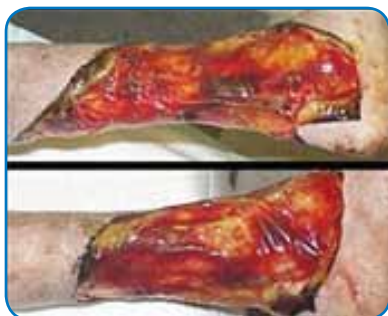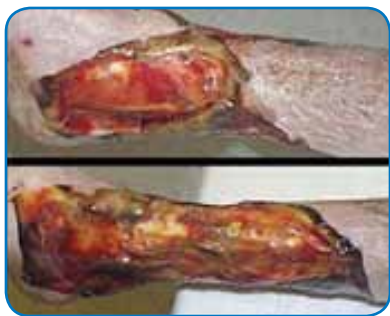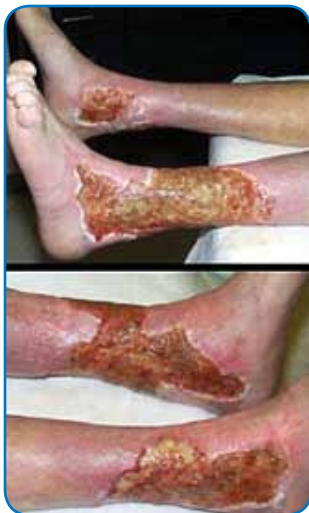Currently, more than four months post skin graft, the patient is full weight bearing without breakdown of the graft

*Case Courtesy of: Dave Granger D.P.M., Kevin Roberts D.P.M., Richard Jay D.P.M., Mark Mantell M.D., Paul Glat, M.D. The Graduate Hospital Wound Care Center, Philadelphia, PA*

## CASE STUDIES

### LEG ULCERATION

- A 77-year-old woman had a 40-year history of continuous leg ulceration and progressive systemic illness. In spite of classic symptoms of Sjogren's disease, the diagnosis was missed countless times. When seen in consultation, the diagnosis was made, anti-inflammatory and antimetabolic treatments were started, and the patient's general health status improved substantially. The leg ulcers are shown just prior to excision. Proper excision means thorough fasciectomy, removing all pathological tissues, including the fibrotic, ulcerated, and inflamed sural fascia. This means that muscles, tendons, retinacular ligaments and other structures will all be exposed when excision is complete.

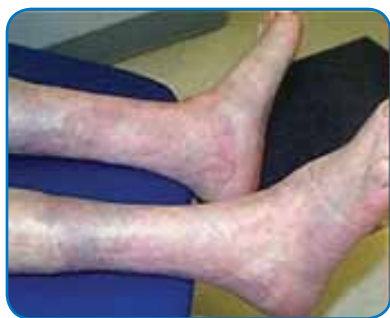
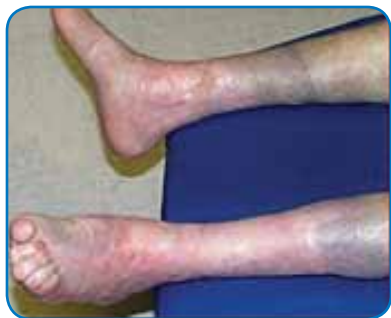
The legs and ankles are shown one week after excision and application of IBWM. Note the wrinkling in the IBWM, a common occurrence due to control of inflammation and edema, thereby decreasing limb volume and surface. All care was outpatient.

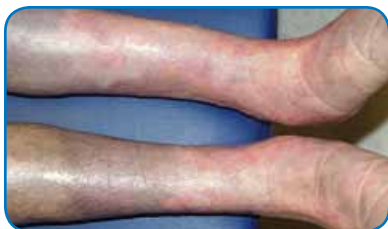

## CASE STUDIES

### LEG ULCERATION



The legs healed and have stayed stable, shown here two years later. Note the bandaging imprints, attesting to the patient's diligent efforts to control edema and care for her skin. Consistent rheumatology management has kept the patient healthy, and lifestyle has been restored.



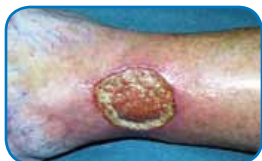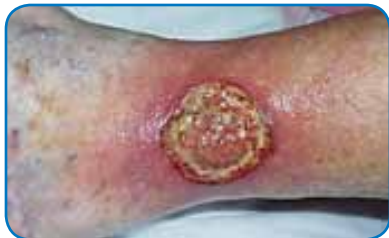A close-up view shows the quality and texture of the healed wound and how comparable it is in appearance to normal skin.

*Cases Courtesy of: Marc E. Gottlieb, M.D., Jennifer Furman;  
Journal of Burns and Wounds, Vol 3, #2*

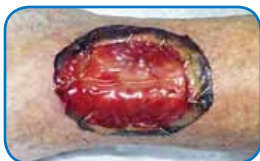## CASE STUDIES

### HYPERCOAGULABLE DISORDER

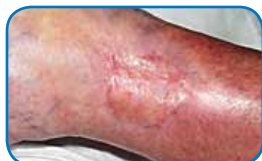- A 61-year-old woman had left leg ulceration of many years duration and a history of multiple venous thrombosis, pulmonary embolism, and warfarin resistance. These are hallmark features of a hypercoagulable disorder, but long standing warfarin therapy precluded making the exact pre-thrombotic diagnosis. In spite of the history, the usual stigmata of venous disease, pigment, edema, and dermatosclerosis, were not very severe, and there was never any improvement by compression and topical care alone. This was a hypercoagulable rather than a venous ulcer, further confirmed histologically by microthrombi. Granulation tissue at the base of the wound indicated intrinsic wound healing competence, but there was chronic active dermatitis, panniculitis, and necrosis in the margins and periwound soft tissues.



After a few weeks of hygiene, good topical care, compression, and increased warfarin, the wound and periwound were improved, but nevertheless, inflammation and active necrosis-ulceration persisted at the margins.



In surgery, the ulcer was excised, including a tangential fibular osteotomy for hyperplastic osteophytes. The wound was closed with IBWM. Seen here at 6 days, periwound inflammation, erythema, and edema have completely subsided.



The ulcer remained healed during a 4-year follow-up period, seen here 9 months after skin grafts.



## INTEGRA™ Bilayer Wound Matrix

### BRIEF SUMMARY – CONSULT PACKAGE INSERT FOR FULL PRESCRIBING INFORMATION

#### DESCRIPTION

INTEGRA™ Bilayer Wound Matrix is an advanced wound care device comprised of a porous matrix of cross-linked bovine tendon collagen and glycosaminoglycan and a semi-permeable polysiloxane (silicone) layer. The semi-permeable silicone membrane controls water vapor loss, provides a flexible adherent covering for the wound surface and adds increased tear strength to the device. The collagen-glycosaminoglycan biodegradable matrix provides a scaffold for cellular invasion and capillary growth.

#### INDICATIONS

INTEGRA™ Bilayer Wound Matrix is indicated for the management of wounds including: partial and full-thickness wounds, pressure ulcers, venous ulcers, diabetic ulcers, chronic vascular ulcers, surgical wounds (donor sites/grafts, post-Moh's surgery, post-laser surgery, podiatric, wound dehiscence), trauma wounds (abrasions, lacerations, second-degree burns, and skin tears) and draining wounds. The device is intended for one-time use.

#### CONTRAINDICATIONS

- This device should not be used in patients with known sensitivity to bovine collagen or chondroitin materials.
- The device is not indicated for use in third-degree burns.

#### PRECAUTIONS

- Do not resterilize. Discard all opened and unused portions of INTEGRA™ Bilayer Wound Matrix.
- Device is sterile if the package is unopened and undamaged. Do not use if the package seal is broken.
- Discard device if mishandling has caused possible damage or contamination.
- INTEGRA™ Bilayer Wound Matrix should not be applied until excessive exudate, bleeding, acute swelling and infection are controlled.
- Debridement or excision must be done thoroughly to remove any remaining necrotic tissue that may cause infection.
- The following complications are possible with the use of wound dressings. If any of the conditions occur, the device should be removed: infection, chronic inflammation (initial application of wound dressings may be associated with transient, mild, localized inflammation), allergic reaction, excessive redness, pain or swelling.

#### INSTRUCTIONS FOR USE

##### *Application*

1. Always handle INTEGRA™ Bilayer Wound Matrix using aseptic technique.
2. Peel open the outer pouch and remove the inner foil pouch.
3. Place foil pouch flat on sterile surface and peel it open.
4. Remove product, including the protective polyethylene sheets.

5. While holding the product with the tab remove one polyethylene cover sheet. Turn the product and remove the second polyethylene cover sheet.
6. Using the tab the product can now be placed into a basin containing a sterile saline solution. Carefully remove the tab from the product while rinsing for 1–2 minutes.
7. Keep product in the basin until application.
8. Prepare wound bed using standard methods to ensure wound is free of debris and necrotic tissue. If necessary, surgically debride the wound to ensure the wound edges contain viable tissue.
9. Cut the device to size and apply immediately following wound bed preparation.
10. **Note:** It is critical that the collagen layer be in direct contact with the prepared wound. The silicone layer, identified by the black threads, must be placed out (away from the wound bed). Do not apply upside down; the black threads must be clearly visible.
11. INTEGRA™ Bilayer Wound Matrix should be firmly secured using surgical tapes, or other mechanical means. Any air bubbles should be carefully removed by moving them to the edge of the sheet.
12. After application, use appropriate secondary dressings to maintain dressing adherence and protect the wound area. The optimum secondary dressing is determined by wound location, size, depth and user preference.

#### *Post-Application*

1. Change the secondary dressing as needed. Frequency of secondary dressing change will be dependent upon volume of exudate produced, type of dressing used and the clinician's need to inspect the wound bed for signs of infection or healing.

**Note:** If hematoma or excess exudate collect under the sheet, small openings can be cut in the sheet to allow fluid to drain.

#### *Removal*

1. If edges are loose before full healing has occurred, the silicone can be trimmed away from the loose areas until the entire wound has healed.
2. Remove the silicone layer of the INTEGRA™ Bilayer Wound Matrix when the tissue underneath is healed, typically 14 to 28 days. The dressing may be loose in spots.
3. Remove by starting at one corner and pull gently. The silicone layer will peel off healed tissue relatively easily.

**Caution:** If bleeding occurs, or if patient complains of excessive pain, stop and wait 1 to 2 additional days. Forced removal may result in wound reinjury.

**HOW SUPPLIED**

INTEGRA Bilayer Wound Matrix is supplied sterile, in single use, double peel packages containing phosphate buffer. INTEGRA™ Bilayer Wound Matrix is available in the following sizes:

<b>Product Codes</b>	<b>Size</b>	<b>Quantity</b>
BMW2021	2 inch x 2 inch (5 cm x 5 cm)	1 unit/box
BMW202	2 inch x 2 inch (5 cm x 5 cm)	5 units/box
BMW4051	4 inch x 5 inch (10 cm x 12.5 cm)	1 unit/box
BMW405	4 inch x 5 inch (10 cm x 12.5 cm)	5 units/box
BMW4101	4 inch x 10 inch (10 cm x 25 cm)	1 unit/box
BMW410	4 inch x 10 inch (10 cm x 25 cm)	5 units/box
BMW8101	8 inch x 10 inch (20 cm x 25 cm)	1 unit/box
BMW810	8 inch x 10 inch (20 cm x 25 cm)	5 units/box

**STORAGE**

Store flat at room temperature. Avoid excessive heat. Avoid freezing.

**PRODUCT INFORMATION DISCLOSURE**

INTEGRA LIFESCIENCES CORPORATION HAS EXERCISED REASONABLE CARE IN THE SELECTION OF MATERIALS AND THE MANUFACTURE OF THESE PRODUCTS. INTEGRA LIFESCIENCES EXCLUDES ALL WARRANTIES, WHETHER EXPRESSED OR IMPLIED, INCLUDING BUT NOT LIMITED TO, ANY IMPLIED WARRANTIES OF MERCHANTABILITY OR FITNESS FOR A PARTICULAR PURPOSE. INTEGRA LIFESCIENCES SHALL NOT BE LIABLE FOR ANY INCIDENTAL OR CONSEQUENTIAL LOSS, DAMAGE, OR EXPENSE, DIRECTLY OR INDIRECTLY ARISING FROM USE OF THIS PRODUCT. INTEGRA LIFESCIENCES NEITHER ASSUMES NOR AUTHORIZES ANY PERSON TO ASSUME FOR IT ANY OTHER OR ADDITIONAL LIABILITY OR RESPONSIBILITY IN CONNECTION WITH THESE PRODUCTS.

**CAUTION:** Federal law restricts this device to sale by or on the order of a physician or practitioner with appropriate training.

Please refer to the clinical training materials for complete instructions for use.

For product ordering information, technical questions, or reimbursement issues please call 877-444-1122 or 609-275-9004.

For product training, please visit [www.ilstraining.com](http://www.ilstraining.com).



Integra LifeSciences Corporation  
311 Enterprise Drive  
Plainsboro, NJ 08536  
[www.Integra-LS.com](http://www.Integra-LS.com)

INTEGRA and the Integra wave logo are trademarks of Integra LifeSciences Corporation.  
©2010 Integra LifeSciences Corporation. All Rights Reserved.