

Case Report

Open Access

Comparison of Two Methods for Canine Retraction Depending on Direct Skeletal Anchorage System (CR-DSAS)

Mahmoud Al Suleiman*, Manal Shehadah
Department of Orthodontics, University of Aleppo, Syria

Corresponding Author: Mahmoud Al-Suleiman, Department of Orthodontics, University of Aleppo, Syria

Citation: Mahmoud Al-Suleiman et al. (2015), Comparison of Two Methods for Canine Retraction Depending on Direct Skeletal Anchorage System (CR-DSAS). Int J Dent & Oral Heal. 1:1, 21-32. DOI: [10.25141/2471-657X-2015-1.0007](https://doi.org/10.25141/2471-657X-2015-1.0007)

Copyright: ©2015 Mahmoud Al-Suleiman et al. This is an open-access article distributed under the terms of the Creative Commons Attribution License, which permits unrestricted use, distribution, and reproduction in any medium, provided the original author and source are credited

Received: November 19, 2015; **Accepted:** December 18, 2015; **Published:** December 31, 2015

Abstract

Introduction:

Various anchorage techniques have been used for canine retraction. Traditional anchorage techniques have not always been very efficient. Recently, Temporary anchorage devices such as miniscrews are considered to be an effective source of anchorage for canine retraction. The purpose of this study was to compare between elastic chain and closed coil in retracting upper canines when using miniscrews as skeletal anchorage in class 2 division1 cases.

Methods:

Twenty-two patients with class 2 division 1 were treated with preadjusted appliances. Depending on miniscrews as direct skeletal anchorage, elastic chain and closed coil were used to retract upper canines after first premolar extraction. Cephalometric radiographs and cast models were been used to evaluate canine retraction. Results were analyzed by SPSS 15 using T student test.

Results:

Upper canines were retracted in 5-5.5 month; Canine crowns were retracted 6.97mm by elastic chain and 7.08 mm by closed coil. Canine apices were retracted 1.06mm by elastic chain and 1.43mm by closed coil. Anchorage loss with miniscrews was 0.07-0.2 mm.

Conclusions:

Miniscrews provide absolute skeletal anchorage, Canine movement with skeletal anchorage is faster than traditional techniques, Canines tipped distally when retracted depending on direct skeletal anchorage, and there was no statistical differences between elastic chain and closed coil in retracting canines.

keywords: Canine Retraction, Skeletal Anchorage System, Orthodontics

Introduction:

Teeth are being extracted in orthodontic treatment moreover to align crowded incisors without increasing protrusion and to allow camouflage jaw relationships when correction by growth modification is not possible [1].

Space closure after premolars extraction is an important stage in comprehensive orthodontic treatment and can be done either by en mass anterior retraction (in one stage) or canine retraction followed with incisors retraction (in two stages) [1,2]

Canine can be retracted either by friction or frictionless mechanics [3], friction mechanics are used in sliding techniques such as

edgewise and preadjusted techniques either by tie back, elastic chain [4], laceback [5,6] intermaxillary elastic [4], coil springs [4], or headgear with j-hook [4,7].

Many in vivo and in vitro studies compared between elastic chain and coil spring.[8-13] Elastic chain lose 50-70% of its force in the first 24 hour after application and will continue after that but with less rate [14,15]. Close coil springs also lose its force but in less rate than elastic [15].

Anchorage is a big issue in space closure and sometimes it is necessary to apply maximum anchorage procedures [16]. Recently temporary skeletal anchorage such as miniscrews[17],

microscrews[18], onplants[19], zygomatic wires[20] and miniplates [21,22] are being used to solve traditional anchorage problems.

Mini/Micro-screw are considered the most skeletal anchorage devices were used; as they are easy to use, not expensive, do not need

surgery procedures, and do not need time for bone consolidation. There small size make them suitable to be used elite in anywhere in the oral cavity especially in intra-dental spaces within alveolar bone [23,24]. Mini-implant can use as direct and/or indirect anchorage. To use as direct absolute anchorage, the line of action of the force has to pass through the mini-implant. When the line of action of the force does not pass through the mini-implant, a moment of force is generated resulting in shearing force.

The aim of our study was to evaluate efficiency of miniscrews as skeletal anchorage for retracting upper canines when using elastic

chain and closed coil, to analyze the canine retraction movement depending on direct skeletal anchorage system (CR-DSAS), and to record dental-alveolar and soft tissues changes associated to CR-DSAS.

Material And Methods:

This study approved by the scientific research board (based on decision No 486). Twenty-two patients with class 2 division I malocclusion, with normal facial type (according to Bjork analysis), who attended orthodontic department in Aleppo Dental Faculty, were selected for this study after they assigned on approval documentations to be part of this study. The sample was consists of 12 males and 10 females with mean age 18.32 ± 2.626 years. Preadjusted fixed orthodontic appliances (0.18 inch from Forestadent®) were been applied; canine brackets with vertical slots were used to fix T formed hook

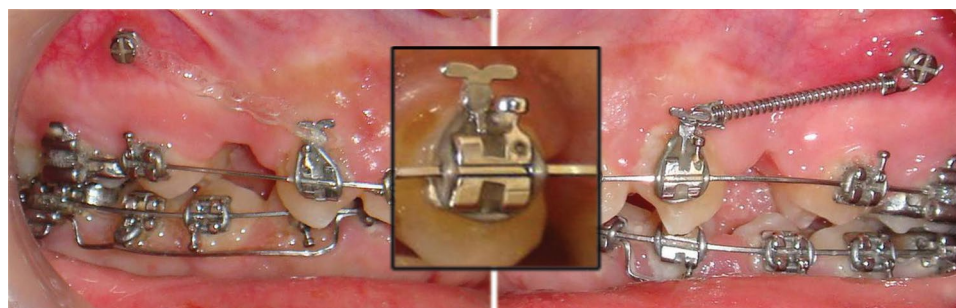


Fig.1: T- hooks/pins were been inserted in the vertical slots of the

canine brackets to be near the center resistance of canine, which reduce the moment of the force allowing translating movement.

Upper first premolars were been extracted at the end of leveling and alignment stage. Mini-screws (9mm length and 1.6 mm diameter titanium mini-screws from Forestadent®) were been applied in a week after premolars extraction.

Mini-screws inserted between second upper premolar and first molar and at 8mm away from brackets slots, wire guides and periapical radiographs were been used to determine the mini-screws' suitable position (Fig 2).

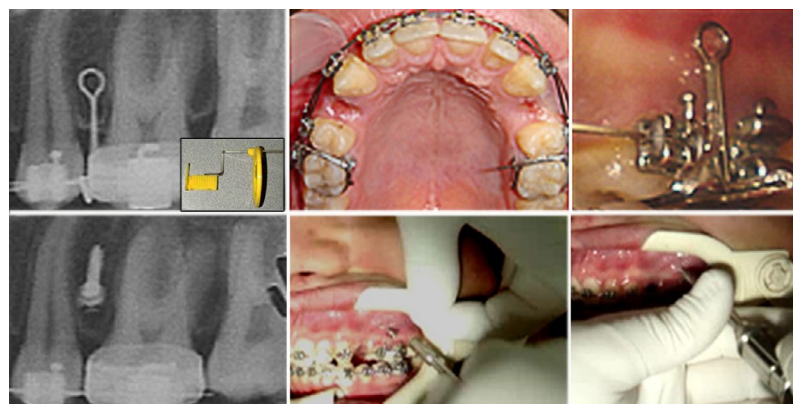


Fig.2: Wire guides and periapical radiographs (depending on paralleling technique for dental radiography) were been used to put

the miniscrews in interradicular bone/alveolar process between second upper premolar and first molar and at 8mm away from brackets slots.

Canine retraction began after one week from mini-screws application (2weeks from premolar extraction) using elastic chain on one side and closed coil spring on the other side. Half of the sample used elastic chain on the right side and closed coil spring on the left side, where the other half used closed coil spring on the right side and elastic chain on the left side to eliminate the effect of the jaw sides on tooth movement. A 100g force have been used

to retract upper canines, the force line extended from the canine T hook to mini-screws as a direct skeletal anchorage system. Every visit (3weeks) force measured and elastic chain replaced to maintain force at 100g.

Canine retraction evaluated by clinical measurements, cast models and cephalometric radiographs. To distinguish right and left upper canines and molars orthodontic wires as a metallic marks were being used (Fig 3).

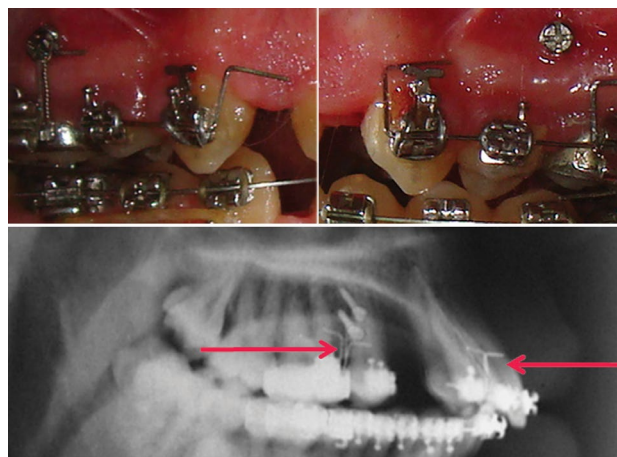


Fig.3: Orthodontic wires were been used as a metallic marks to

distinguish right and left upper canines and molars on the cephalometric radiographs

Clinical measurements performed by measuring the distance from the mesial wing of canine bracket to the mesial end of the tube band of first molar.

The speed of canine retraction (measured by mm/mo) calculated by the following equation:

$$\text{Canine retraction speed} = \frac{\text{Distance (mm)}}{\text{Time (day)}} \times 30$$

Where is:

Distance: is the difference between the last and the first recorded distance between mesial end of canine bracket and the mesial end of the first upper molar in the same side, measured by millimeter.

Time: is the recorded time which canine consumed during retraction, measured by day.

The changes in position of upper retracted canine and upper first molar on the cast models evaluated, including the changes in mesial (C1) and distal (C2) margins of upper retracted canine in transpalatal direction, and the changes in mesial (M1) and distal (M2) margins of upper first molar in transpalatal direction. Moreover, the changes in the width of upper dental arch between the first molars, and the changes in the length of upper dental arc were studied.

Three reference planes, Y plane, X plane, and palatal plane, on the cephalometric radiographs to study canine retraction movement have been chose. The type of canine movement evaluated by changes of the apex and the crown tip of the retracted canine according to sagittal (anterior-posterior) and vertical planes. The axial changes of the retracted canines also evaluated to determine the type of the canine movement

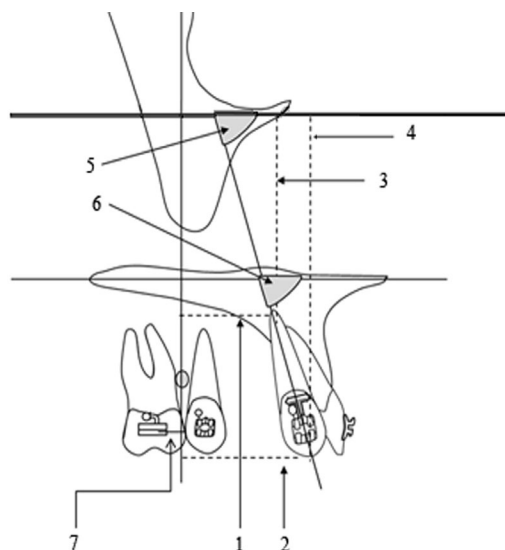


Fig.4: The cephalometric measurements according to 3 The reference planes (Y plane represents the line perpendicular to Frankfort plane through miniscrew, X plane represents Frankfort plane (FH) the line horizontal plane running through Po and Or points, SPp

represents horizontal palatal plane from anterior nasal spine and posterior nasal spine) used to evaluate canine retraction: 1-Sagittal apex movement 2-Sagittal crown movement 3-Vertical apex movement 4-Vertical crown movement 5-Canine axial - FH 6-Canine axial - SpP 7-Sagittal molar movement

C.ap-Y (Canine apex – Y plane)	The horizontal distance between Canine apex and the Y plane
C.c-Y (Canine Crown tip– Y plane)	The horizontal distance between Canine crown tip and Y plane
C.ap- X (Canine apex – X plane)	The vertical distance between Canine apex and the FH plane
C.c-X (Canine Crown – X plane)	The vertical distance between Canine crown tip and the FH plane
Canine axis –FH	The interior angle between Canine axis and FH plane
Canine axis –SPp	The interior angle between Canine axis and palatal plane

Table.1: The cephalometric measurements used to evaluate canine retraction

The cephalometric measurements according to 3 The reference planes (Y plane represents the line perpendicular to Frankfort plane through miniscrew, X plane represents Frankfort plane (FH) the line horizontal plane running through Po and Or points, SPp

represents horizontal palatal plane from anterior nasal spine and posterior nasal spine) used to evaluate canine retraction: 1-Sagittal apex movement 2-Sagittal crown movement 3-Vertical apex movement 4-Vertical crown movement 5-Canine axial - FH 6-Canine axial - SpP 7-Sagittal molar movement

The anchorage losing were measured by value of molar distal movement according to Y plane (Fig 4) (Table I). The dental-al-

veolar and profile changes associated with canine retraction on the cephalometric radiographs recorded

SNA	Angle formed by SN and NA
Maxillary Depth	Interior angle formed by FH and NA.
A/Na- FH	Horizontal distance from A to line perpendicular to FH through Na.
I / A- Pog angle	Interior angle formed by upper incisor axis and line from A to Pog.
I / A- Pog mm	Horizontal distance from upper incisor to from A to Pog
Ui / Li	angle formed by upper incisor axis and lower incisor axis
I / S.N	Posterior angle formed by upper incisor axis and line from S to Na
l Angle	lower anterior angle between upper incisor axis and palatal plane
Z angle	Angle formed by esthetic line (pass through tip off the nose and most protrusion lip point) and FH plane
Upper lip	Ui – Ul: Horizontal distance between the most protrusion upper lip point and the anterior upper incisor surface
Upper Lip-E line (Ricketts)	Horizontal distance between the most protrusion upper lip point and E line from Pn to Pog
Nasolabial angle	angle formed by Sn (subnasal) -Pn (pronasl)line and Sn-Ls (most anterior point of upper lip)
a1	upper section of the Nasolabial angle
a2	lower section of the Nasolabial angle
Upper Lip prominence Ls(pog-sn)	The horizontal distance between the most protrusion upper lip point (Ls) and the line from Pog to sn.

Table:2 The cephalometric measurements used to evaluate the dental-alveolar and profile changes associated to canine retract-

Two mini-screws failed and removed before ending canine retraction, attached canines excluded from the study. Results analyzed by SPSS 15 using independent T student test.

Results:

Clinical measurements: show that canines retracted 6.97 ± 1.34 mm

ed with skeletal direct anchorage (Cephalometric landmarks and measurements used to evaluate profile changes.)

in 5months by elastic chain and 7.08 ± 2.04 mm in 5.5months by closed coil spring. The speed of canine retraction was 1.42 ± 0.42 mm/mo by elastic chain and 1.34 ± 0.43 mm/mo by closed coil spring without significant differences between the two methods

	Elastic chain		Closed coil		P	Sig
	Mean	S. D	Mean	S. D		
Time (days)	155.1429	52.01854	167.0476	62.01732	.504	NS
Distance (mm)	6.9795	1.34996	7.0890	2.04402	.839	NS
Speed (mm/mo)	1.4288	.42880	1.3418	.46237	.531	NS

Table.3: The total clinical measurements of the speed of canine retraction

	E. chain		Closed coil		P	Sig
	Mean	S. D	Mean	S. D		
T1	1.5484	1.27169	1.4388	1.11051	.793	NS
T2	.6546	.49575	.8459	.49550	.256	NS
T3	1.5506	1.06786	1.3600	.76454	.517	NS
T4	1.1898	.73988	1.2821	.76850	.736	NS
T5	1.0926	.49987	1.2986	1.06056	.535	NS
T6	1.0155	1.03192	.7525	.68625	.484	NS
T7	1.0575	.85874	.9509	.70558	.819	NS
T8	.9388	.79404	1.0079	.85228	.918	NS

Table.4: The serial clinical measurements of the speed of canine retraction throughout the study

	Total				P	Sig
	E. chain		Closed coil			
	Mean	S. D	Mean	S. D		
Sagital apex movement	- 1.9000	.78807	- 2.5714	1.39898	.066	NS
Sagital crown movement	- 6.8864	3.01556	- 7.0682	2.45093	.827	NS
Vertical apex movement	- 1.4091	2.48153	- 2.2619	2.39593	.258	NS
Vertical crown movement	- 1.6136	1.34458	- 1.1818	1.22032	.271	NS
Canine axial - FH	14.0952	5.86434	13.7000	4.79144	.815	NS
Canine axial - SpP	13.9048	6.04901	13.6000	4.72841	.859	NS
Sagital molar movement	-.2727	.55048	-.0714	.63808	.276	NS

Table.5: The total cephalometric measurements of canine retraction

	T1-T2				T2-T3				T3-T4			
	E. chain		Closed coil		E. chain		Closed coil		E. chain		Closed coil	
	Mean	S. D	Mean	S. D	Mean	S. D	Mean	S. D	Mean	S. D	Mean	S. D
Sagital apex movement	-.650	.745	- 1.078	1.157	-.714	1.055	-.750	.771	2.25	.500	- 3.00	.707
Sagital crown movement	2.475	1.601	- 3.473	1.866	4.175	1.961	3.638	1.483	.500	1.048	1.50	2.516
Vertical apex movement	1.450	1.669	- 1.315	2.286	.050	2.523	-.583	2.568	1.50	2.880	- 2.125	3.375
Vertical crown movement	.700	1.341	- 1.052	.911	.625	1.645	-.055	1.392	.833	1.329	1.20	1.303
Canine axial - FH	6.650	5.742	9.368	4.536	7.750	5.627	5.444	3.822	.333	4.226	-.400	7.765
Canine axial - SpP	6.450	6.793	9.210	5.050	8.000	6.274	5.444	3.883	1.66	1.861	- 3.00	3.741
Sagital molar movement	.100	.5281	-.026	.539	-.100	.660	-.111	.814	.333	.816	.500	.577

Table.6: The serial cephalometric measurements of the speed of canine retraction throughout the study

Results of Cephalometric measurements have been show in Tables V, VI. The canine apex retracted 1.9 ± 0.78 mm by elastic chain and the canine tip 6.88 ± 3.01 mm; while the canine apex retracted 2.5 ± 1.39 mm by closed coil spring and the canine tip 7.06 ± 2.45 mm. canine apex and canine tip intruded by Elastic chain and closed coil spring; although canine apex and canine tip intruded by elastic chain 1.4 ± 2.48 mm and 1.61 ± 1.34 mm

respectively; wherever both canine apex and canine tip intruded by closed coil spring 2.26 ± 2.39 mm and 1.18 ± 1.22 mm respectively. During retraction the canine tipped by Elastic chain and closed coil spring $14.09 \pm 5.86^\circ$ and $13.7 \pm 4.79^\circ$ respectively. There were no significant differences between the two methods. Upper first molar moved mesially by Elastic chain and closed coil spring 0.2 ± 0.5 mm and 0.07 ± 0.6 mm respectively

	T1		T4		T1.T4		P	Sig
	Mean	S. D	Mean	S. D	Mean	S. D		
SNA	83.1053	3.31486	82.4211	3.06079	-.8333	2.00734	.096	NS
Maxillary Depth	92.4211	2.83462	91.3158	3.59092	-1.1667	2.47933	.062	NS
A/Na- FH	2.9737	3.07983	1.5263	3.85311	-1.5278	2.81525	.034	S
I / A- Pog angle	31.7895	5.21301	28.4737	6.92314	-3.0556	5.10446	.021	S
I / A- Pog mm	9.4737	2.45783	7.2632	2.23214	-5.4737	8.23521	.000	S
Ui / Li	122.0000	7.04746	126.5263	9.94635	4.3889	5.99155	.006	S
I / S.N	100.6842	6.19186	96.5263	7.61846	-3.6667	5.94089	.018	S
l Angle	70.7368	5.10819	74.8947	7.45278	3.6667	5.25805	.009	S
Z angle	62.2632	6.52212	63.9474	6.20460	1.7778	4.25034	.094	NS
Upper lip: Ui – Ul	14.0000	1.97203	14.3158	2.13574	.5556	1.04162	.037	S
Upper Lip-E line (Ricketts)	-.2368	2.14326	-1.3947	2.23966	-1.0000	1.13759	.002	S
Nasolabial angle	105.6316	9.32863	107.9474	8.24940	2.4444	5.26053	.065	NS
a1	27.9474	7.24549	24.2105	7.92029	-3.4444	5.69026	.020	S
a2	78.7368	8.31893	83.7368	7.33214	4.7778	9.30879	.044	S
Upper Lip prominence	4.9737	1.87434	4.1842	2.28041	-.1667	1.46528	.636	NS

Table.7: The dental-alveolar and profile changes associated to/with canine retraction

has been show that there were statistical differences in the following selected cephalometric measurements after canine retraction:

- A/Na- FH
- I / A- Pog angle
- I / A- Pog mm
- Ui / L
- I / S.N
- l Angle

- Upper lip: Ui – Ul
- Upper Lip-E line (Ricketts)
- a1
- a2

Cast models: Canine retraction was associated with mesial labial rotation as there was a difference between the amounts of changes of point C1 and C2 without a significant difference between the two methods in this aspect

	E. chain		Closed coil		P	Sig
	Mean	S. D	Mean	S. D		
C1	3.3158	1.41628	3.4286	1.28730	.793	NS
C2	1.1053	1.04853	1.3810	.97346	.394	NS
M1	-.0588	.88180	-.3750	.87170	.282	NS
M2	-.1765	1.05979	-.1250	1.07453	.885	NS

Table.8: VIII The total cast model measurement of canine retraction

Molars showed no rotation or tipping, as there were no statistical

differences between the changes in the M1 and M2 values before and after canine retraction (Table IX).

	mean	S. D	P	Sig
Changes in the point M1 values	-.2000	.79097	.822	NS
Changes in the point M2 values	-.2250	.97369		

Table.9: The mean and standard deviation of upper molar movement associated canine retraction which measured on cast models

Both the width and the length of the dental arch reduced (1.05±1.07mm and 2.05±0.84mm) respectively, as there were significant differences between their values before and after canine retraction

	Before		After		Difference		P	Sig
	Mean	S. D	Mean	S. D	Mean	S. D		
Arch width	45.5663	2.14078	44.5153	2.18715	- 1.0511	1.07760	.000	S
Arch length	31.0526	2.24781	29.0000	1.88562	- 2.0526	.84811	.000	S

Table.10:The mean and standard deviation of upper arch width and length associated canine retraction which measured on cast models

Discussion:

Differences between Elastic chain & closed coil spring in CR-DSAS:

Speed of retraction: There were no statistical differences between the two methods, although they were faster than the previous studies that compared between the two methods depending on traditional anchorage systems (Table III).

Our findings go with Herman et al. who reported that the speed of CR-DSAS ranged from 1.5 to – 1.6 mm/mo[25], and with Garfinkle et al. who reported that we can expect having a dental movement between 0.75 and 1.0 mm/mo when depending on direct skeletal anchorage with miniscrews [26].

Thiruvengkatachari et al reported that canine retraction with skeletal anchorage was 0.93 mm/mo and was faster than canine retraction with molar anchorage (0.81 mm/mo)[27].

Type of movement: Both groups showed that the amount of movement canine apex and tip not equally; as crown was retracted more than apex causing canine controlled tipping, but there were no statistical differences between the two methods of retraction.

The canine retraction was associated with intrusion as result of the difference between force application level and mini-screws positions and companied with a rotation movement, as there was a meso-labial rotation in both methods without statistical differences between the two groups.

These notes are similar to canine retraction in sliding technique with traditional anchorage procedures which was reported by Ziegler and Ingervall [28], Sueri and Turk [6], and Hyashi et al [29]

Rate of miniscrews success:

We think that there is some difference between the two methods regarding their affect on miniscrews, as the miniscrews failure was noticed in cases were elastic chain had been used (2cases) but that did not cause a statistical difference between the two methods.

We think that colsed coil springs, connected to miniscrews, allow more oral hygiene control than elastic chain, and as we know from previous studies that infection and oral hygiene control have a big role in miniscrews success [30-33].

We agree with Mah and Bergstrand suggestion; that it is better to use closed coil with minscrews than elastic chain as the former provides continuous force for longer time and it doesn't impede oral hygiene procedures [34].

This could demand another studies to discover the effect of force application methods on the miniscrew success.

Miniscrews efficiency as anchorage devices: As we know, maximum traditional anchorage procedures allow posterior teeth to move mesially and close 1/3 of the extraction space, While Miniscrews (in our study) provided an absolute anchorage for canine retraction as the recorded amount of mesial upper molar movement was very tiny (0.2mm, 0.07mm) and may neglected.

As there isn't obvious changing in the upper first molar position neither in the anterior-posterior direction (no tipping) nor labial-palatal direction (no rotation), both chephalometric and model cast data showed no statistical difference in the position of upper first molar after canine retraction depending on direct skeletal anchorage. However, there is a noticeable change in the transverse plane in the upper first molar position appeared as a contraction in the arch width at this region (Table X).

We should keep in mind that direct skeletal anchorage has a different force system than traditional anchorage. These findings agree with Thiruvengkatachari et al [27,35] that miniscrews provide absolute anchorage for canine retraction CR-DSAS.

Force analyzing system for CR-DSAS: In the first stage of canine retraction the canine crown retracted much more than root as a result of applying force away from center of canine resistance causing a moment (Fig 5a) which tipped the crown distally, this distal tipping bent the arch wire forming a couple moments in bracket slot.

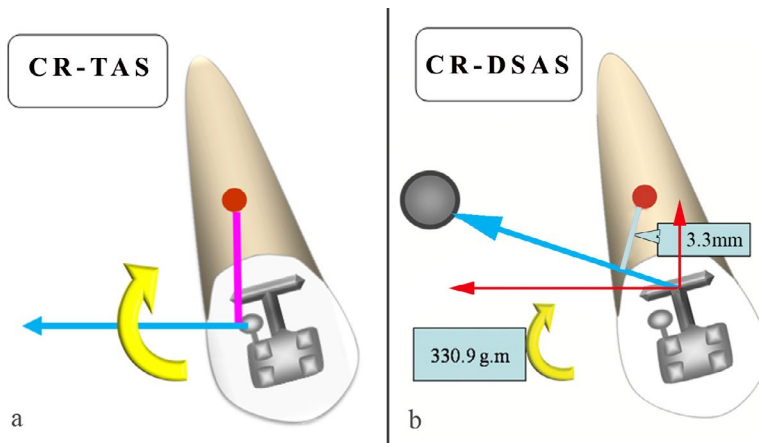


Fig.5a: Applying force away from center of canine resistance will cause a moment equal multiplication of force and the distance between force application point and center of resistance.

Fig.5b: The retraction force has two components; the horizontal component will move the canine distally while the vertical component will intrude the canine as canine

As the crown tipped distally, the distance, which chain or close coil was been stretched, would decreased. This will in turn reduce the force applied for canine retraction allowing to the counter moment (depending on bracket slot, arch wire...etc) to upright, the canine axis as the ratio M/F changed at this point. This is similar to our notice in later stages especially in the last stage as the root retraction increased as crown retraction minimized. These findings are similar to previous reports about canine retraction in

sliding technique with traditional anchorage procedures. [36,37] We believe that more time must be given to allow root movement to take a place and it is wrong to reactivate force too much which keep high level of force and doesn't allow for M/F ratio to be modified and to upright canine axis.

The retraction force also has two components; horizontal and vertical, the horizontal component will move the canine distally while the vertical component will intrude the canine as canine retracted (Fig 5b).

The initial distal tipping pushed the upper mesial and distal lower sections of the bracket slot toward the arch wire, which caused increasing the friction between the wire and the bracket leading

to push the arch wire distally (Fig 6a). In the traditional sliding technique, this action would counteracted by friction in the molar tube, which pushes the arch wire mesially (Fig 6b).

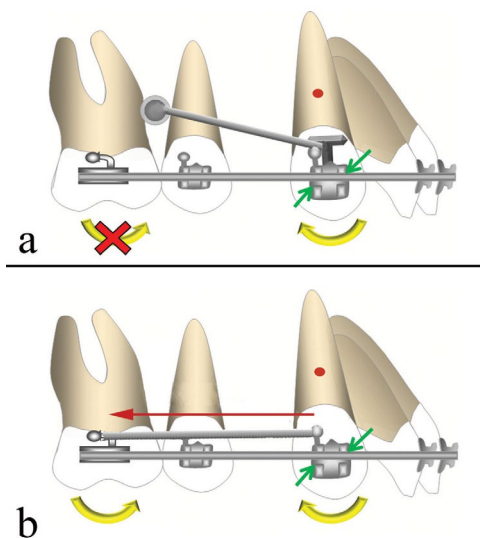


Fig.6: The initial distal tipping pushed the upper mesial and distal lower sections of the bracket slot toward the arch wire, which caused increasing the friction between the wire and the bracket

leading to push the arch wire distally (a). In the traditional sliding technique, this action is been counteracted by friction in the molar tube, which pushes the arch wire mesially (b)

In the CR-DSASA the friction in the molar tube is highly minimized which allow the arch wire to move distally causing the retraction of incisors spontaneously.

Occlusally: The force applied on the labial side of canine surface away from center of resistance causing rotation moment leading

to labio-mesial rotation of canine, in the traditional sliding technique this action counteracted by labio-distal rotation of molar. In the CR-DSASA the moment rotation at canine will push the distal end of the arch wire toward mid palatal line causing reduction in the arch width (Fig 7a), and it could cause posterior cross bite as Cornelis and De clerk described [38]

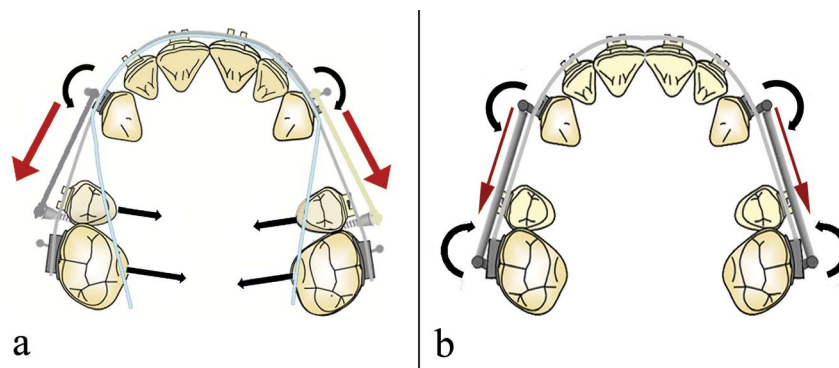


Fig.7: a: labial mesial rotation of the canine in the CR-DSASA will push the distal end of the arch wire toward mid palatal line causing reduction in the arch width.

b: labial mesial rotation of the canine in the traditional sliding technique is counteracted by labial distal rotation of molar.

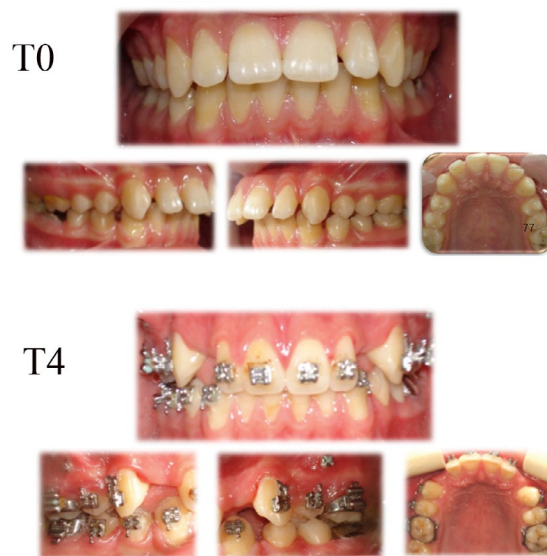

Fig.8: A clinical case of canines retracted depending mini-screw anchorage from T0 to T4

Consequent results to CR-DSAS: it included dental-alveolar changes and profile changes.

Dental-alveolar changes:

Upper Incisors retraction: The decrease in some cephalometric measurements addition to the decrease in arch length shows the spontaneous Upper Incisors retraction that associated to CR-DSAS.

Contraction of dental arch: The CR-DSAS was associated with contraction of dental arch in the posterior region.

Profile changes:

There were some changes in profile after CR-DSAS as upper lip retrusion and increase nasolabial angle because of extraction and spontaneous incisor retrusion.

Conclusion:

Mini-screws offer absolute anchorage for canine retraction.

Canine movement was controlled tipping (crown more than root) than at the end it was more in root than crown, and there was labial mesial rotation.

Intrusion force component associated canine retraction as a result of the difference between the levels of application force and mini-screw anchorage system.

No significant differences between elastic chain and closed coil spring in sliding canine retraction techniques depending on direct skeletal anchorage.

Contraction dental arch width in the molar region associates canine retraction with direct skeletal anchorage.

Spontaneous upper incisor retraction occurs simultaneously with canine retraction depending on direct skeletal anchorage.

References:

1. Proffit WR, Fields HW [2000] [contemporary orthodontics](#).
2. Heo W, Nahm DS, Baek SH [2007] [En masse retraction and two-step retraction of maxillary anterior teeth in adult Class I women. A comparison of anchorage loss](#). *Angle Orthod* 77: 973-978.
3. Rhee JN, Chun YS, Row J [2001] [A comparison between friction and frictionless mechanics with a new typodont simulation system](#). *Am J Orthod Dentofacial Orthop* 119: 292-299.
4. Bennett JC, McLaughlin RP [1990] [Controlled space closure with a preadjusted appliance system](#). *J Clin Orthod* 24: 251-260.
5. McLaughlin RP, Bennett JC [1991] [Anchorage control during leveling and aligning with a preadjusted appliance system](#). *J Clin Orthod* 25: 687-696.
6. Sueri MY, Turk T [2006] [Effectiveness of laceback ligatures on maxillary canine retraction](#). *Angle Orthod* 76: 1010-1014.
7. Ayala Perez C, de Alba JA, Caputo AA, Chaconas SJ [1980] [Canine retraction with J hook headgear](#). *Am J Orthod* 78: 538-547.
8. Samuels RH, Rudge SJ, Mair LH [1993] [A comparison of the rate of space closure using a nickel-titanium spring and an elastic module: a clinical study](#). *Am J Orthod Dentofacial Orthop* 103: 464-467.
9. Samuels RH, Rudge SJ, Mair LH [1998] [A clinical study of space closure with nickel-titanium closed coil springs and an elastic module](#). *Am J Orthod Dentofacial Orthop* 114: 73-79.
10. Sonis AL [1994] [Comparison of NiTi coil springs vs. elastics in canine retraction](#). *J Clin Orthod* 28: 293-295.
11. Nattrass C, Ireland AJ, Sherriff M [1997] [An investigation into the placement of force delivery systems and the initial forces applied by clinicians during space closure](#). *Br J Orthod* 24: 127-131.
12. Elsyed F. A-AH, [2000] [Alveolar bone density change during canine retraction](#), Egyptian Dental Association, 46 (Jan).
13. Bokas J, Woods M [2006] [A clinical comparison between nickel titanium springs and elastomeric chains](#). *Aust Orthod J* 22: 39-46.
14. Baty DL, Storie DJ, von Fraunhofer JA [1994] [Synthetic elastomeric chains: a literature review](#). *Am J Orthod Dentofacial Orthop* 105: 536-542.
15. Nattrass C, Ireland AJ, Sherriff M [1998] [The effect of environmental factors on elastomeric chain and nickel titanium](#)

[coil springs](#). *Eur J Orthod* 20: 169-176.

16. Nanda R [2005] [Biomechanics and esthetic strategies in clinical orthodontics](#): Elsevier Inc. ,
17. Kanomi R [1997] [Miniscrew implant for orthodontic anchorage](#). *J Clin Orthodontic Cyberjournal* 11:763.
18. Park H, Kwon O, Sung J [2005] [Micro-screw implant anchorage sliding mechanics](#). *World J Orthod* 6:265.
19. Hong H, Ngan P, Li GH, Qi LG, Shy W [2005] [Use of onplants as stable anchorage for facemask treatment: a case report](#). *Angle Orthod* 75: 453-460.
20. Melsen B, Petersen JK, Costa A [1998] [Zygoma ligatures: an alternative form of maxillary anchorage](#). *J Clin Orthod* 32: 154-158.
21. Erverdi N, A [2005] [Zygomatic anchorage for en masse retraction in the treatment of severe Class II Division 1](#). *Angle Orthod* 75:483-490.
22. Unemori M, Sugawara J, Mitani H, Nagasaki H, HK [1999] [Skeletal anchorage system for open-bite correction](#). *Am J Orthod Dentofacial Orthop* 115: 166-174.
23. Koo D, Cal-Neto J, Noronha M, Á.Fernandes, Júnior J [2007] [Alternatives of Skeletal Anchorage in Orthodontics - Principles and applications](#). *Orthodontic Cyber journal*,
24. Ritto AK, Kyung HM [2004] [Bracket Head Micro Implant for Orthodontic Anchorage](#). *Orthodontic Cyberjournal*,
25. Herman RJ, Currier GF, Miyake A [2006] [Mini-implant anchorage for maxillary canine retraction: a pilot study](#). *Am J Orthod Dentofacial Orthop* 130: 228-235.
26. Garfinkle JS, Cunningham LL, Jr., Beeman CS, Kluemper GT, Hicks EP, Kim MO [2008] [Evaluation of orthodontic mini-implant anchorage in premolar extraction therapy in adolescents](#). *Am J Orthod Dentofacial Orthop* 133: 642-653.
27. Thiruvengkatahari B, Ammayappan P, Kandaswamy R [2008] [Comparison of rate of canine retraction with conventional molar anchorage and titanium implant anchorage](#). *Am J Orthod Dentofacial Orthop* 134: 30-35.
28. Ziegler P, Ingervall B [1989] [A clinical study of maxillary canine retraction with a retraction spring and with sliding mechanics](#). *Am J Orthod Dentofacial Orthop* 95: 99-106.
29. Hayashi K, Uechi J, Murata M, Mizoguchi I [2004] [Comparison of maxillary canine retraction with sliding mechanics and a retraction spring: a three-dimensional analysis based on a midpalatal orthodontic implant](#). *Eur J Orthod* 26: 585-589.
30. Cheng S, Tseng I, Lee J, Kok S [2004] [A prospective study of the risk factors associated with failure of mini-implants used for orthodontic anchorage](#). *Int J Oral Maxillofac Implants* 19: 100-106.
31. Miyawaki S, Koyama I, Inoue M, Mishima K, Sugahara T, Takano-Yamamoto T [2003] [Factors associated with the stability of titanium screws placed in the posterior region for orthodontic anchorage](#). *Am J Orthod Dentofacial Orthop* 124: 373-378.
32. Park H, Jeong S, Ow K [2006] [Factors affecting the clinical](#)

success of screw implants used as orthodontic anchorage. Am J Orthod Dentofacial Orthop 130: 18-25.

33. Kuroda S, Sugawara Y, Deguchi T, Kyung H, Yamamoto T [2007] Clinical use of miniscrew implants as orthodontic anchorage: success rate and postoperative discomfort. Am J Orthod Dentofacial Orthop 131.

34. Mah J, Bergstrand F [2005] Temporary anchorage devices: a status report. J Clin Orthod 39: 132-136; discussion 136; quiz 153.

35. Thiruvengkatachari B, Pavithranand A, Rajasigamani K, Kyung HM [2006] Comparison and measurement of the amount of anchorage loss of the molars with and without the use of implant

anchorage during canine retraction. Am J Orthod Dentofacial Orthop 129: 551-554.

36. Kojima Y, Fukui H [2005] Numerical simulation of canine retraction by sliding mechanics. Am J Orthod Dentofacial Orthop 127: 542-551.

37. Staggers JA, Germane N [1991] Clinical considerations in the use of retraction mechanics. J Clin Orthod 25: 364-369.

38. Cornelis MA, De Clerck HJ [2006] Biomechanics of skeletal anchorage. Part 1. Class II extraction treatment. J Clin Orthod 40: 261-269; quiz 232.