



Interventional Nephrology Primer: Part 1

Fistulas, Grafts, Catheters and PICC lines

2020

Ammar Almeahmi, MD, MPH

University of Alabama at Birmingham

Editor: Anil Agarwal, MD

Editorial Assistance: Sloan Almeahmi, BS, MA

Vascular Access Primer

Vascular access: is the lifeline for dialysis patients. As the name implies, it is the method by which the blood vessel is accessed to get the blood from the patient to the hemodialysis machine for both fluid removal and clearance purposes.

There are 3 types of vascular accesses for hemodialysis:

1. Catheters:

- **Non-tunneled- (referred to as temporary)** Used for 7-10 days (e.g. VasCath).
- **Tunneled (referred to as permanent):** Used for long time; months-years (e.g. PermCath).

2. Arteriovenous fistulas (AVFs):

AVF is created by connecting an artery to a native vein. After the creation, the **native** vein becomes thicker, stronger (arterialized) and larger in diameter to be used for cannulation to perform dialysis. There can be a number of locations of AVF, though the common sites used are:

I. Upper Arm AVF:

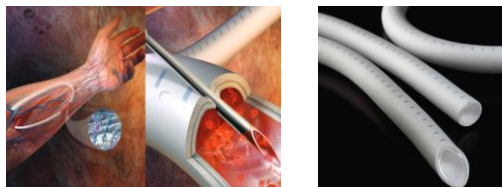
- Brachial artery to cephalic vein (brachio-cephalic AVF)
- Brachial artery to basilic vein (brachio-basilic AVF)

II. Forearm AVF:

- Radial artery to cephalic vein (radio-cephalic AVF)

3. Arteriovenous grafts (AVGs):

AVG is created by connecting an artery to a large vein via **synthetic** (usually PTFE) material (called graft). The graft segment is used for cannulation.

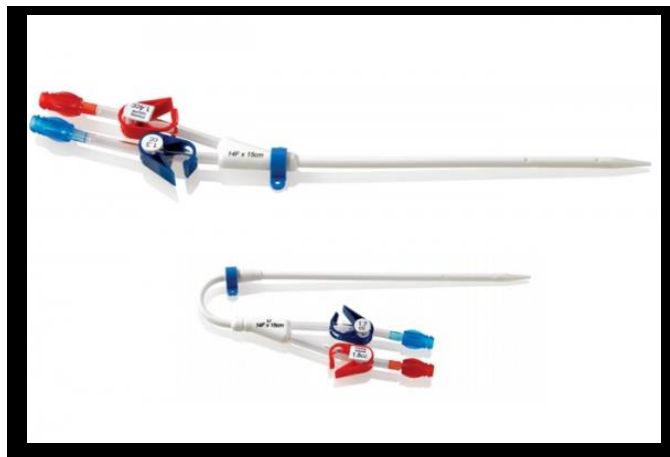
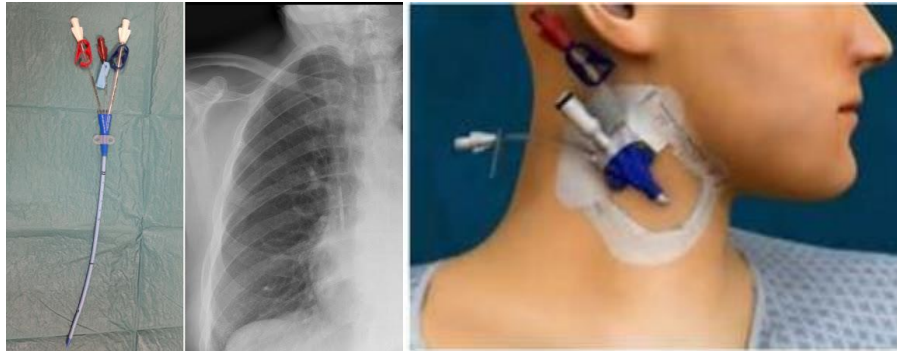


- I. **Upper Arm AVG:** can be straight or in loop configuration.
 - The AVG connects brachial artery to brachial/axillary vein.
- II. **Forearm AVG:** is usually a loop graft.
 - The AVG connects brachial (or radial) artery to the vein.
- III. **Femoral (thigh) AVG:** is usually a loop graft.
 - The AVG connects iliac/femoral artery to the iliac/femoral vein.

Catheters

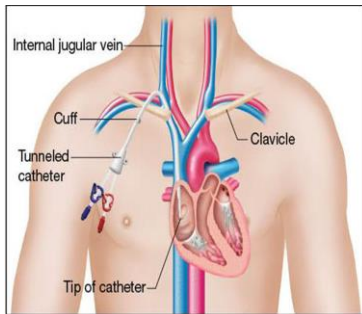
Non-tunneled (short-term) catheters (usually called VasCath)

- Can be used for 7-10 days only due to the risk of bacterial invasion.
- Can be inserted in emergent situations and in unstable patients such as in ICU setting to initiate dialysis when tunneled catheter insertion is not feasible.
- Generally inserted at bedside under ultrasound guidance.
- These catheters have 2 large lumens, and sometimes a smaller third lumen (trialsysis catheter).
- Different lengths: the common sizes are 15, 20 and 24 cm, which can be used in right internal jugular, left internal jugular and femoral locations, respectively.

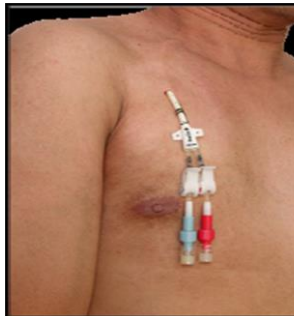


Tunneled (long-term) catheters (usually called PermCath)

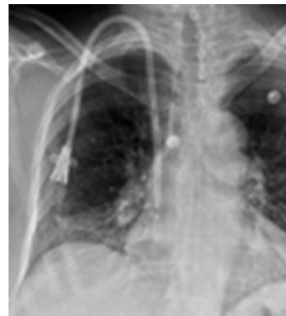
- Tunneled under the skin where the cuff is buried to prevent bacterial invasion.
- Can be used for longer time- months but occasionally for years.
- Commonly seen in patients starting hemodialysis- either acute or chronic.
- Common size 14.5 F; the length ranges between 15 cm-55 cm
- Typical locations in order of preference: Right internal jugular (IJ), left IJ, right femoral, and left femoral veins.
- Rare locations are used when other options are exhausted: trans-lumbar and trans-hepatic.



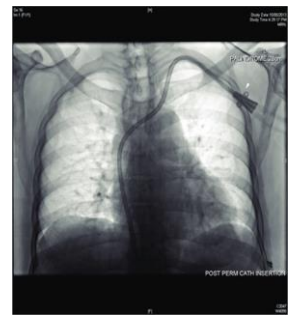RIJ PermCath



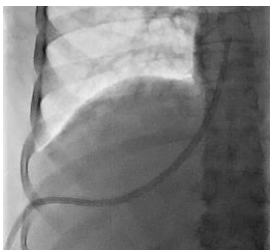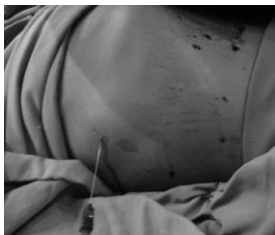RIJ PermCath



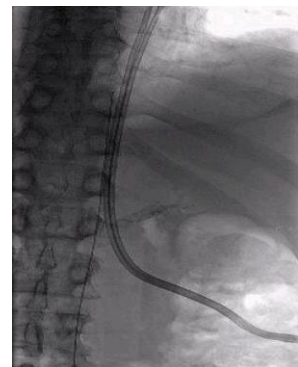
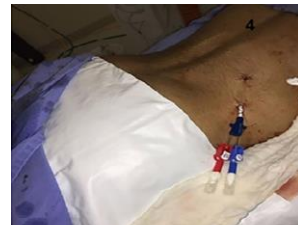CXR-RIJ PermCath



CXR-LIJ PermCath



Trans-hepatic PermCath
Rare to see.



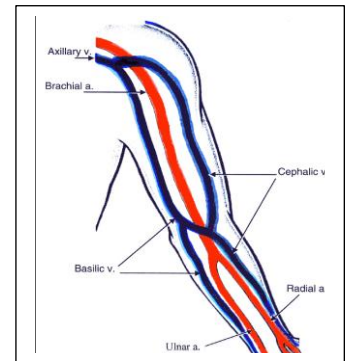
Trans-lumbar PermCath
Rare to see.

Arteriovenous fistulas (AVFs)

- AVF is created by connecting an artery to a native vein.
- After creation, the enlarged and 'mature' **native** vein is used for cannulation.
- The venous system of the upper extremity includes superficial and deep veins.
- The superficial vein system (cephalic) is usually used for AVF creation.
- The deep vein system (basilic, brachial) is used if the cephalic veins are not suitable for AVF creation.

- The basic vascular anatomy of the upper extremity is shown:

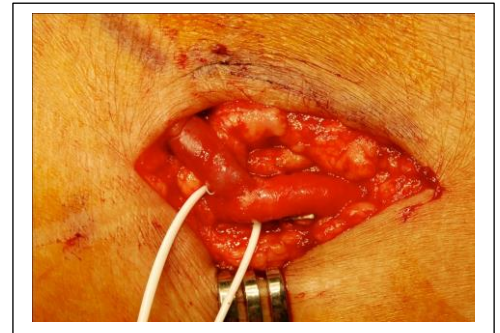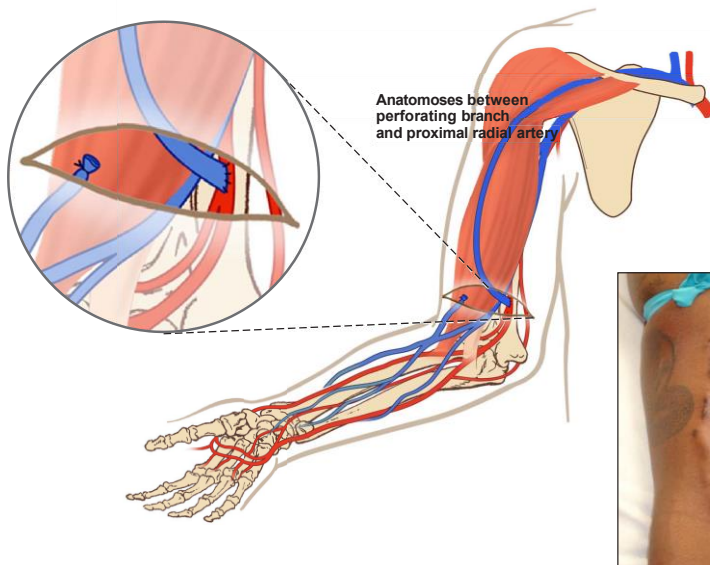
- Upper arm basilic vein
- Upper arm cephalic vein
- Forearm basilic vein
- Forearm cephalic vein



Upper Arm AVFs:

1-Brachio-cephalic AVFs:

The brachial artery is connected to the cephalic vein.

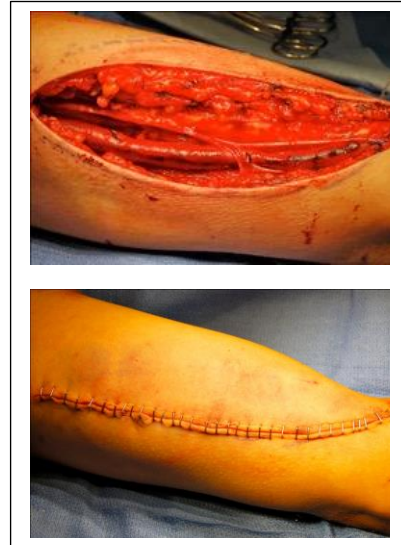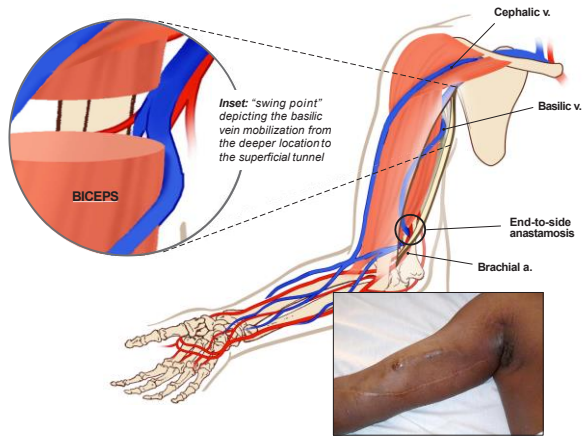


2-Brachio-basilic AVFs:

The brachial artery is connected to the basilic vein.

These AVFs require superficialization to become suitable for cannulation.

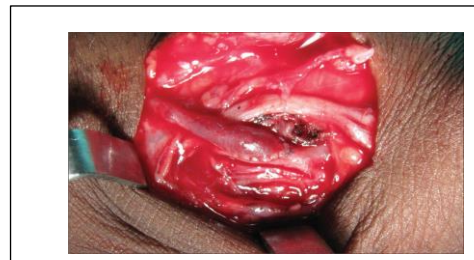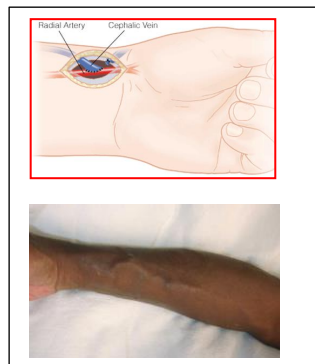
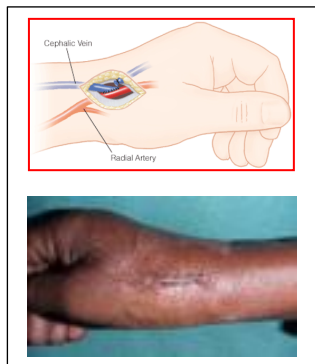
On exam, these AVFs have a long scar on the medial aspect of the upper arm.



Forearm AVFs:

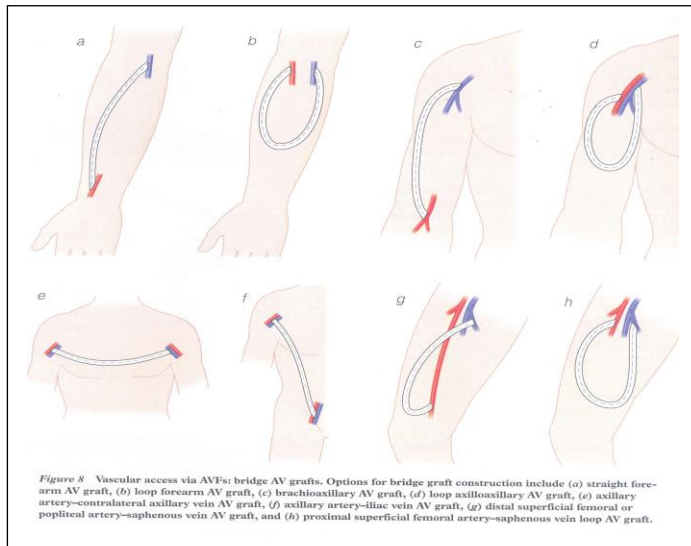
Radio-cephalic AVFs: the radial artery is connected to the cephalic vein.

On very rare occasions, radio-basilic AVF is created and usually requires superficialization.

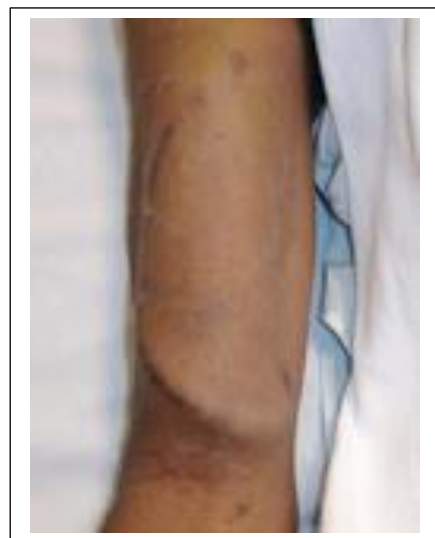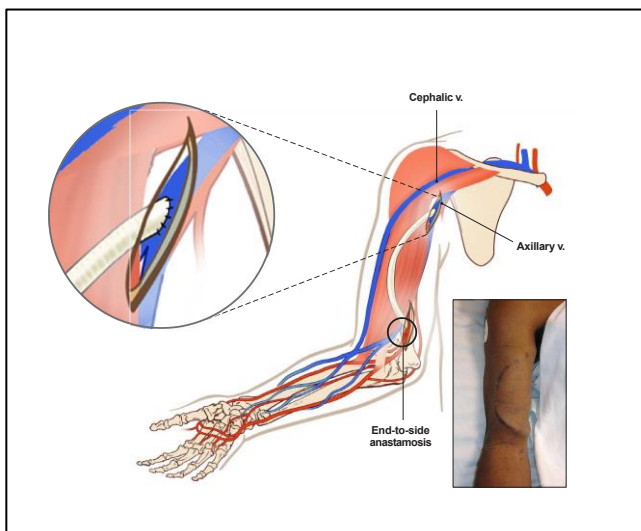


Arteriovenous Grafts (AVGs)

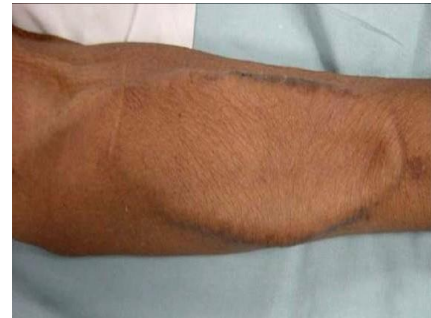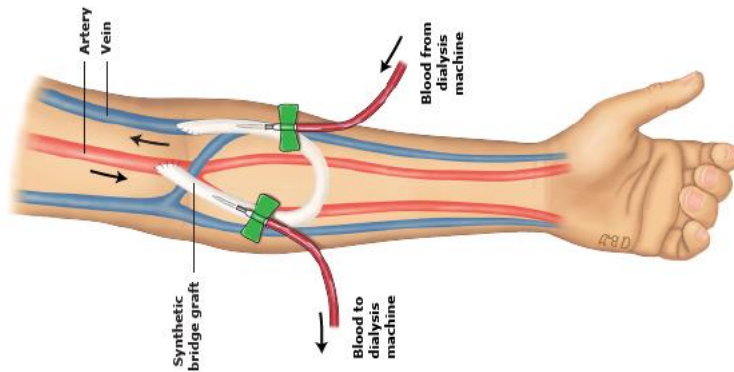
- AVGs are created by connecting an artery to a large vein via **synthetic** (PTFE) material called graft.
- There are multiple locations where AVGs can be created with different configurations.
- The most common locations are upper arm (loop or straight) AVGs, forearm loop AVGs and thigh loop AVGs.



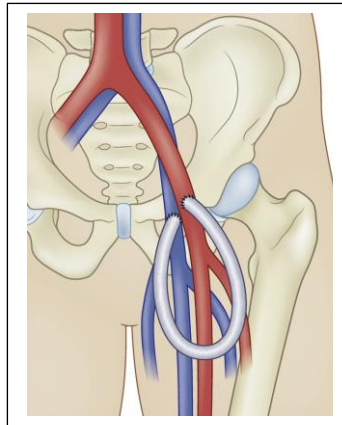
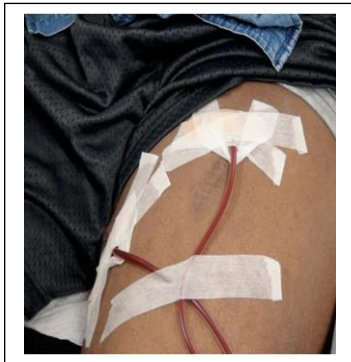Upper Arm AVGs: the configuration of AVG can be straight or loop. The graft connects the brachial artery to the brachial/axillary vein.



Forearm AVGs: the configuration of AVG is usually loop.
The AVG connects brachial artery to a vein at the elbow level.



Femoral (thigh) AVGs: the configuration of AVG is usually loop.
The AVG connects the femoral or iliac artery to the femoral or iliac vein.



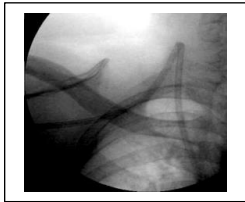
ATTENTION

**AVFs and AVGs can NOT be used for Continuous Renal Replacement Therapy (CRRT).
VasCath or PermCath is needed to run the CRRT machine.**

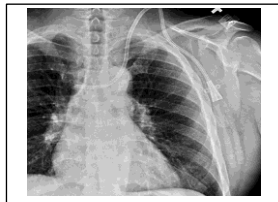
Complications of Catheters

Several complications are encountered with tunneled dialysis catheters.

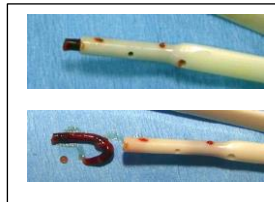- Catheter dysfunction: due to kink, retraction (especially with left IJ), thrombus, and fibrin sheath.
- Infectious complications are common such as cuff exposure, tunnel infection, exit site infection and catheter related bacteremia.
- Most of these complications require catheter exchange or removal based on the clinical scenario.
- Central vein stenosis can occur with repeated insertion or prolonged catheter stay.



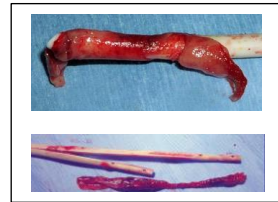Kink



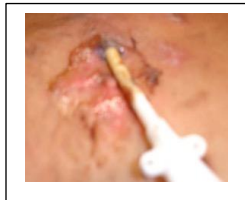Catheter is short



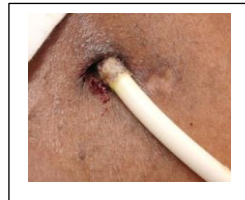Intraluminal thrombus



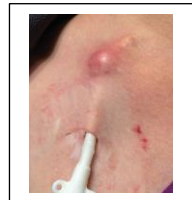Fibrin sheath



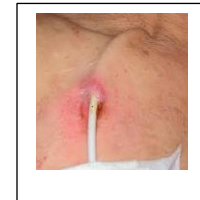Catheter infection



Cuff exposure



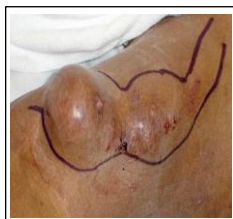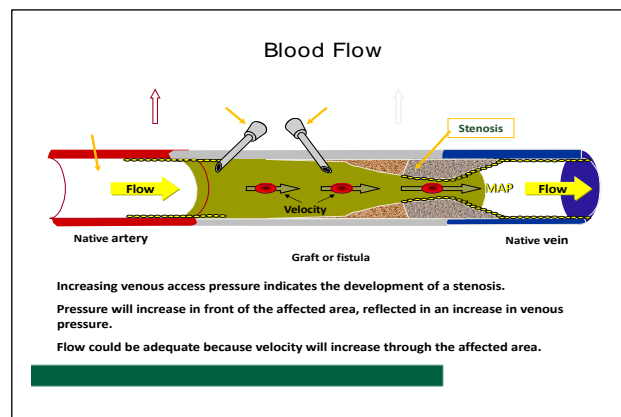
Tunnel infection



Exit site infection

Complications of AVFs and AVGs

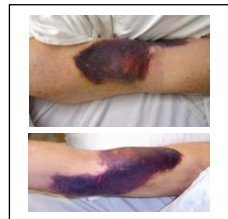- Most of AVF/AVG complications are related to the repetitive cannulation during dialysis using large gauge needles that causes wall injury and may introduce infection. Examples include stenoses, pseudoaneurysms, aneurysms, infiltration/hematomas and access wall infection.
- Dialysis machine (pump speed) usually requires 400-600 ml/min blood flow for adequate hemodialysis.
- As the dialysis access matures, the blood flow increases to reach 800-2500 ml/min.
- Some of the complications of the dialysis access are related to the high blood flow rate through the dialysis access conduit leading to neointimal hyperplasia and stenosis formation. These complications manifest as elevated venous pressure, machine alarming, and access clotting.



Pseudoaneurysm



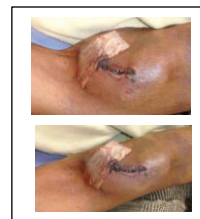Watch and see.
 If the wall becomes pink and thin, then patient needs surgical referral.



infiltration



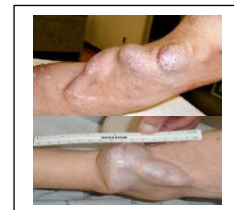Continue to use dialysis access if the patient tolerates it; otherwise, give the access rest and insert a catheter.



Hematoma



Continue to use dialysis access if the patient tolerates it; otherwise, give the access rest and insert a catheter.



Aneurysms

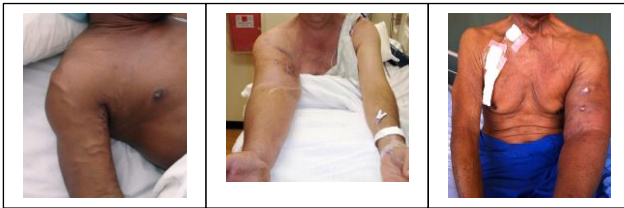

Watch and see.
 If the wall becomes pink and thin, then patient needs surgical referral.

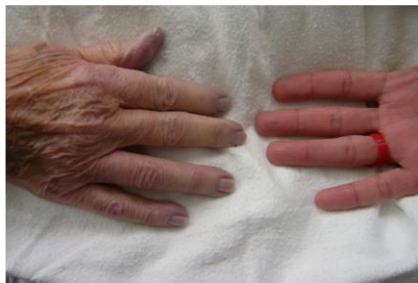
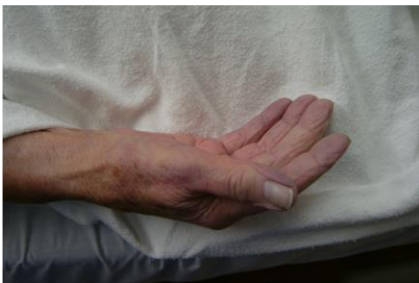
Repeated cannulation of AVG (3times/wk) → The formation of pseudoaneurysms

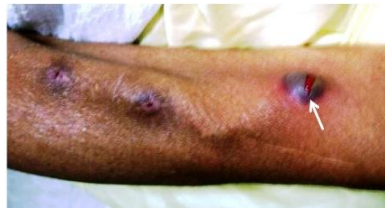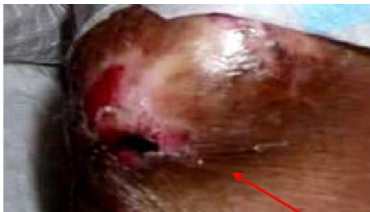- Sometimes, dialysis patients present with swelling and prominent dilated veins of the upper/lower extremity. This phenomenon is related to central venous stenoses induced by previous use of central venous catheters (central line, PICC line, VasCath or PermCath). These patients require angiogram of the dialysis access combined with angioplasty and occasionally stenting. Central lesions are recurrent by nature and require frequent interventions (usually every 3-4 months).



- In rare cases, the patient can develop steal syndrome that results from shunting the blood away from the affected extremity. Symptoms include cramps and pain during dialysis session, cold sensation and color changes. Exam usually reveals weak pulse and low O₂ sat of the affected hand. In severe cases, the patient can develop necrotic lesions of the fingertips. These patients require **immediate** referral for steal syndrome evaluation by interventional radiology (IR) or vascular surgery.



ATTENTION



If you see these lesions (above) in a AVF/AVG, **immediate** attention is required (**hospitalization**) due to the high risk of rupture and possible death.

Needle Gauge and Blood Flow Rate Used in Dialysis

(Usual blood flows recommended according to needle lumen diameter)

NeedleGauge	MaximumBFR
17gauge	200–250
16gauge	250-350
15gauge	350-450
14gauge	>450

AVF and AVG: Indications for Referral and Intervention

1. High venous pressure.
2. High arterial pressure.
3. Machine alarming.
4. Pulling clots.
5. Difficulty cannulation.
6. Clotted access.
7. Arm swelling.
8. Excessive bleeding after dialysis
9. Color changes (pink discoloration).
10. Access infection.

Dialysis Access Exam

Inspection: Check for the following:

- Scars:
 - It denotes the location of the arterial anastomosis (artery -vein hook up).
 - Number of scars indicates old access surgeries.
 - Long scars are seen in deep brachio-cephalic AVF that underwent superficialization and basilic vein transposition.
- Arm swelling and collateral veins: seen in central venous lesions.
- Aneurysm formations.
- Ulcerative changes of the dialysis access.
- Erythema and hematomas.
- Hand and finger discoloration.
- Old scars of old tunneled catheters on the chest wall.

Palpation:

- Normal access: thrill (buzz).
- Hyperpulsatility: Outflow stenotic lesions.
- Cold hands: may indicate steal syndrome of the access extremity.

Maneuvers:

- Arm elevation:
 - If AVF vein collapses: it indicates no outflow lesions.
 - If AVF vein does not collapse: it indicates outflow stenosis.
- Augmentation test:

This test is performed by occluding the access 2-3 inches above the arterial anastomosis with one hand while evaluating the intensity of the pulse with the other. With outflow AVF vein occlusion, the soft pulse becomes stronger (augmented) indicating good blood from the feeding artery. Weak augmentation indicates arterial anastomosis stenosis.

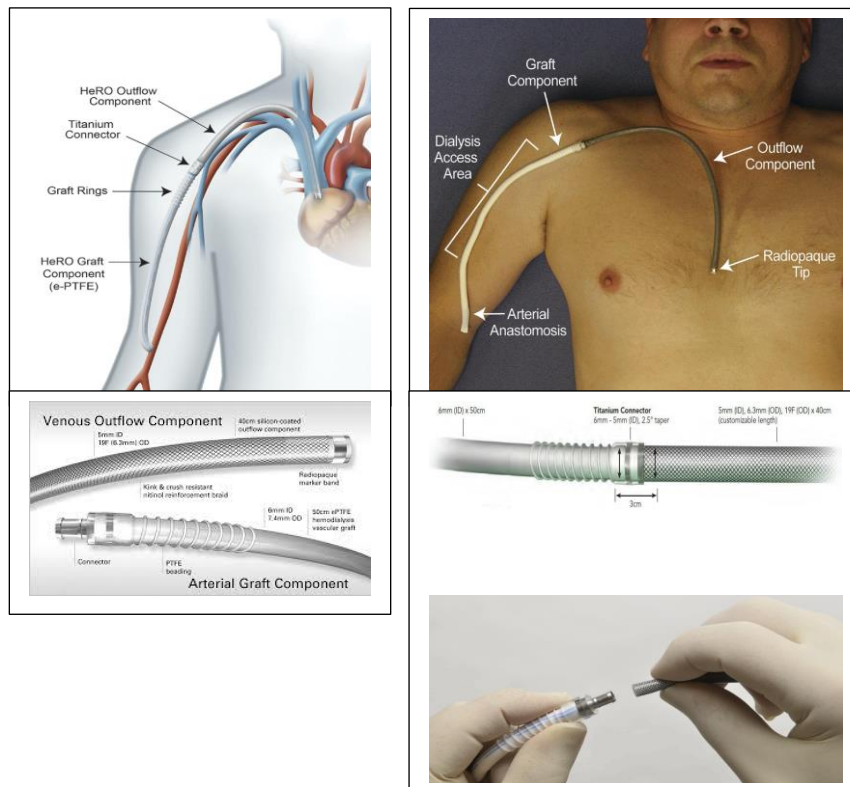
References:

1. Cavallaro G, Taranto F, Cavallaro E, Quatra F. Vascular complications of native arteriovenous fistulas for hemodialysis: role of microsurgery. *Microsurgery*. 2000;20:252-4.
2. Clark TW, Cohen RA, Kwak A, Markmann JF, Stavropoulos SW, Patel AA, Soulen MC, Mondschein JI, Kobrin S, Shlansky-Goldberg RD, Trerotola SO. Salvage of non-maturing native fistulas by using angioplasty. *Radiology*. 2007; 242:286-92.
3. Faintuch S, Salazar GM. Malfunction of dialysis catheters: management of fibrin sheath and related problems. *Tech Vasc Interv Radiol*. 2008; 11:195-200.
4. Gracz KC, Ing TS, Soung LS, Armbruster KF, Seim SK, Merkel FK. Proximal forearm fistula for maintenance hemodialysis. *Kidney Int*. 1977;11(1):71-5.
5. Hausegger KA, Tiessenhausen K, Klimpfinger M, Raith J, Hauser H, Tauss J. Aneurysms of hemodialysis access grafts: treatment with covered stents: a report of three cases. *Cardiovasc Intervent Radiol*. 1998; 21:334-7.
6. Janne d'Othee B, Tham JC, Sheiman RG. Restoration of patency in failing tunneled hemodialysis catheters: a comparison of catheter exchange, exchange and balloon disruption of the fibrin sheath, and femoral stripping. *J Vasc Interv Radiol*. 2006;17:1011-5.
7. Keeling AN, Naughton PA, McGrath FP, Conlon PJ, Lee MJ. Successful endovascular treatment of a hemodialysis graft pseudoaneurysm by covered stent and direct percutaneous thrombin injection. *Semin Dial*. 2008; 21:553-6.
8. Konner K, Hulbert-Shearon TE, Roys EC, Port FK. Tailoring the initial vascular access for dialysis patients. *Kidney Int*. 2002;62:329-338.
9. Badero OJ, Salifu MO, Wasse H, Work J. Frequency of swing-segment stenosis in referred dialysis patients with angiographically documented lesions. *Am J Kidney Dis*. 2008;51:93-8.
10. Balaz P, Rokosny S, Klein D, Adamec M. Aneurysmorrhaphy is an easy technique for arteriovenous fistula salvage. *J Vasc Access*. 2008;9:81-4.
11. Barshes NR, Annambhotla S, Bechara C, et al. Endovascular repair of hemodialysis graft-related pseudoaneurysm: an alternative treatment strategy in salvaging failing dialysis access. *Vasc Endovascular Surg*. 2008;42:228-34.
12. Beathard GA. Catheter thrombosis. *Semin Dial*. 2001;14:441-5.
13. Bender MH, Bruyninck CM, Gerlag P. The Gracz arteriovenous fistula evaluated: Results of the brachiocephalic elbow fistula in haemodialysis angio-access. *Eur J Vasc Endovasc Surg* 10. 1995;294-297
14. Berman SS, Gentile AT, Glickman MH, et al. Distal revascularization-interval ligation for limb salvage and maintenance of dialysis access in ischemic steal syndrome. *J Vasc Surg*. 1997;26:393-402; discussion 402-4.
15. Bourquelot P, Gaudric J, Turmel-Rodrigues L, Franco G, Van Laere O, Raynaud A. Transposition of radial artery for reduction of excessive high-flow in autogenous arm accesses for hemodialysis. *J Vasc Surg*. 2009;49:424-8, 428 e1.
16. Rajan DK, Bunston S, Misra S, Pinto R, Lok CE. Dysfunctional autogenous hemodialysis fistulas: outcomes after angioplasty—are there clinical predictors of patency? *Radiology*. 2004;232:508-15.
17. Rajan DK, Clark TW, Patel NK, Stavropoulos SW, Simons ME. Prevalence and treatment of cephalic arch stenosis in dysfunctional autogenous hemodialysis fistulas. *J Vasc Interv Radio*. 2003;14:567-73.
18. Rodriguez, HE, Leon, L, Schalch, P, Labropoulos, N, Borge, M, Kalman, PG. Arteriovenous access: managing common problems. *Perspect Vasc Surg Endovasc Ther*. 2005;17:155-66.

19. Salman L, Beathard G. Interventional nephrology: Physical examination as a tool for surveillance for the hemodialysis arteriovenous access. *Clin J Am Soc Nephrol*. 2013;8(7):1220-1227.
20. Wang S, Almehti A, Asif A. Surgical management of cephalic arch occlusive lesions: are there predictors for outcomes?. *Semin Dial*. 2013;26(4):E33-E41.
21. Almehti A, Broce M, Wang S. Thrombectomy of prosthetic dialysis grafts using mechanical plus "no-wait lysis" approach requires less procedure time and radiation exposure. *Semin Dial*. 2011;24(6):694-697.
22. Almehti A, Wang S. Partial aneurysmectomy is effective in managing aneurysm-associated complications of arteriovenous fistulae for hemodialysis: case series and literature review. *Semin Dial*. 2012;25(3):357-364.
23. <https://cdn.ymaws.com/www.asdin.org/resource/resmgr/imported/atlas%20of%20dialysis%20access.pdf>
24. Arhuidese IJ, Orandi BJ, Nejm B, Malas M. Utilization, patency, and complications associated with vascular access for hemodialysis in the United States. *J Vasc Surg*. 2018;68(4):1166-1174.
25. Coentrão L, Van Biesen W, Nistor I, et al. Preferred haemodialysis vascular access for diabetic chronic kidney disease patients: a systematic literature review. *J Vasc Access*. 2015;16(4):259-264.
26. DeSilva RN, Patibandla BK, Vin Y, et al. Fistula first is not always the best strategy for the elderly. *J Am Soc Nephrol* 2013; 24:1297.
27. Beathard GA, Spergel LM. Hand ischemia associated with dialysis vascular access: an individualized access flow-based approach to therapy. *Semin Dial* 2013; 26:287.
28. Han S, Song D, Yun S. Long Term Outcomes of Arteriovenous Grafts for Hemodialysis in Lower Extremities. *Vasc Specialist Int* 2016; 32:180.
29. Antoniou GA, Lazarides MK, Georgiadis GS, et al. Lower-extremity arteriovenous access for haemodialysis: a systematic review. *Eur J Vasc Endovasc Surg* 2009; 38:365.
30. Allon M. We Underutilize the Leg Graft. *Semin Dial* 2016; 29:281.

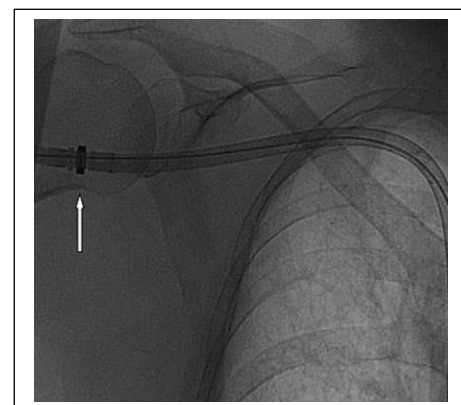
Hemodialysis Reliable Outflow (HeRO) Grafts

The HeRO device consists of a 6-mm expanded polytetrafluoroethylene (ePTFE) graft attached to a 5-mm nitinol-reinforced silicone outflow component designed to bypass venous stenoses. It enters the internal jugular vein directly and provides a continuous arterial blood flow into the right atrium. The two components are brought together entirely subcutaneously with a titanium connector.



HeRO Graft are good alternatives for catheter dependent patients with central venous stenosis and in those with failing AVFs or AVGs. The key benefits of HeRO grafts compared to catheters are:

- Less infections.
- Improved dialysis adequacy.
- Patency rates approach the rates of AVGs.

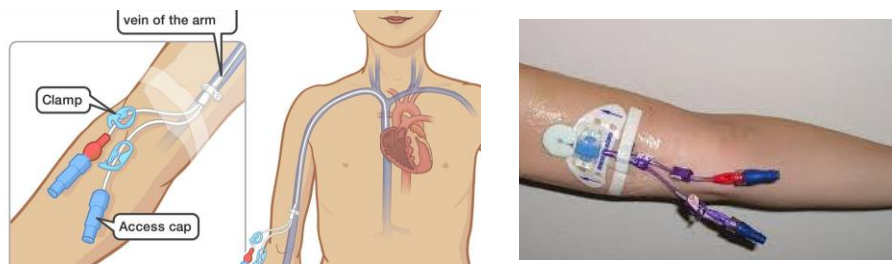


References:

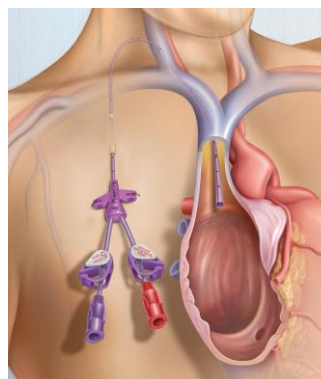
1. Katzman HE, McLafferty RB, Ross JR, Glickman MH, Peden EK, Lawson JH. Initial experience and outcome of a new hemodialysis access device for catheter-dependent patients. *J Vasc Surg.* 2009;50(3):600-607.e1.
2. Nassar GM, Glickman MH, McLafferty RB, et al. A comparison between the HeRO graft and conventional arteriovenous grafts in hemodialysis patients. *Semin Dial.* 2014;27(3):310-318
3. Gebhard TA, Bryant JA, Adam Grezaffi J, et al. Percutaneous interventions on the hemodialysis reliable outflow vascular access device. *J Vasc Interv Radiol.* 2013;24(4):543-549.
4. Wallace JR, Chaer RA, Dillavou ED. Report on the Hemodialysis Reliable Outflow (HeRO) experience in dialysis patients with central venous occlusions. *J Vasc Surg.* 2013;58(3):742-747.
5. Al Shakarchi J, Houston JG, Jones RG, Inston N. A Review on the Hemodialysis Reliable Outflow (HeRO) Graft for Haemodialysis Vascular Access. *Eur J Vasc Endovasc Surg.* 2015;50(1):108-113.
6. Glickman MH. HeRO Vascular Access Device. *Semin Vasc Surg.* 2011;24(2):108-112.
7. Glickman MH. HeRO graft versus lower extremity grafts in hemodialysis patients with long standing renal failure. *J Vasc Access.* 2016;17 Suppl 1: S30-S31.

PICC Lines

- Peripherally inserted central catheters (PICC) are increasingly utilized in modern clinical practice specially among critically ill patients.
- PICC lines are usually single or dual lumen catheters that are inserted under ultrasound guidance by a nurse-led team.
- Above the elbow basilic, brachial or cephalic veins are commonly used for PICC insertion with the catheter tip being in the central venous system (superior vena cava, subclavian or brachiocephalic veins).
- The presence of these lines within the vein lumen for porlonged time is associated with repetitive trauma and subsequent thrombosis and stenosis.
- In stage 3-5 CKD patients, the preservation of the forearm and upper arm veins that are suitable for fistula creation is the goal. These veins should not be used for venipuncture or the placement of PICC lines.
- In stage 3-5 CKD patients, it is recommended to insert tunneled central lines and not PICC lines.



PICC line (non-tunneled)



Tunneled Central Infusion Catheters

References:

1. Govindan, S., et al., *Peripherally Inserted Central Catheters in the ICU: A Retrospective Study of Adult Medical Patients in 52 Hospitals*. Crit Care Med, 2018. **46**(12): p. e1136-e1144.
2. El Ters, M., et al., *Association between prior peripherally inserted central catheters and lack of functioning arteriovenous fistulas: a case-control study in hemodialysis patients*. Am J Kidney Dis, 2012. **60**(4): p. 601-8.
3. Kalloo, S. and J.B. Wish, *Nephrologists Versus Peripherally Inserted Central Catheters: Are the PICCs Winning?* Clin J Am Soc Nephrol, 2016. **11**(8): p. 1333-4.
4. Drew, D.A. and D.E. Weiner, *Peripherally Inserted Central Catheters (PICCs) in CKD: PICC'ing the Best Access for Kidney Disease Patients*. Am J Kidney Dis, 2016. **67**(5): p. 724-7.
5. Chopra, V., et al., *Risk of venous thromboembolism associated with peripherally inserted central catheters: a systematic review and meta-analysis*. Lancet, 2013. **382**(9889): p. 311-25.
6. Chopra, V., et al., *Bloodstream infection, venous thrombosis, and peripherally inserted central catheters: reappraising the evidence*. Am J Med, 2012. **125**(8): p. 733-41.
7. McGill, R.L., et al., *Peripherally Inserted Central Catheters and Hemodialysis Outcomes*. Clin J Am Soc Nephrol, 2016. **11**(8): p. 1434-40.
8. Shingarev, R. and M. Allon, *Peripherally inserted central catheters and other intravascular devices: how safe are they for hemodialysis patients?* Am J Kidney Dis, 2012. **60**(4): p. 510-3.
9. Williams, A.W., et al., *Critical and honest conversations: the evidence behind the "Choosing Wisely" campaign recommendations by the American Society of Nephrology*. Clin J Am Soc Nephrol, 2012. **7**(10): p. 1664-72.
10. Paje, D., et al., *Patterns and Predictors of Short-Term Peripherally Inserted Central Catheter Use: A Multicenter Prospective Cohort Study*. J Hosp Med, 2018. **13**(2): p. 76-82.