



# Intraoral Digital Impression Technique Compared to Conventional Impression Technique. A Randomized Clinical Trial

Björn Gjelvold, DDS,<sup>1</sup> Bruno Ramos Chrcanovic, DDS, MSc,<sup>2</sup> Eva-Karin Korduner, DDS,<sup>1</sup> Ingrid Collin-Bagewitz, DDS, PhD,<sup>1</sup> & Jenö Kisch, DDS<sup>1</sup>

<sup>1</sup>Folktandvården Skåne AB—Centre of Dental Specialist Care Malmö, Malmö, Sweden

<sup>2</sup>Department of Prosthodontics, Malmö University, Malmö, Sweden

The article is associated with the American College of Prosthodontists' journal-based continuing education program. It is accompanied by an online continuing education activity worth 1 credit. Please visit [www.wileyhealthlearning.com/jopr](http://www.wileyhealthlearning.com/jopr) to complete the activity and earn credit.

## Keywords

Digital impression; computer-aided impression; clinical efficiency; intraoral scanner; patient perception; CAD/CAM.

## Correspondence

Björn Gjelvold, Folktandvården Skåne AB—Centre of Dental Specialist Care Malmö, Spårväggsgatan 12 Malmö 214 27, Sweden.  
E-mail: [bjorn.gjelvold@gmail.com](mailto:bjorn.gjelvold@gmail.com).

Bruno Ramos Chrcanovic ORCID:  
<http://orcid.org/0000-0002-3460-3374>

Björn Gjelvold ORCID:  
<http://orcid.org/0000-0001-6186-4804>

Funded by Region Skåne and Folktandvården Skåne AB (Public Dental Care Service, Scania, Sweden).

The authors deny any conflicts of interest.

Accepted July 24, 2014

doi: 10.1111/jopr.12410

Dental impressions have been used to obtain impressions of the intraoral conditions; casts need to be made to fabricate restorations on the casts. Impressions have a wide range of applications, ranging from providing casts for treatment planning or patient communication to providing final casts for the production of definitive/interim restorations.<sup>1</sup>

In the so-called “conventional” technique, a cast is produced after an impression has been made with a tray filled with an impression material. Impressions made with irreversible hydrocolloids should be poured immediately, as delayed pouring negatively influences their dimensional stability and precision.<sup>2</sup> Elastomeric impression materials available for final impressions are vinyl siloxanether, vinylpolysiloxane, silicone, and polyether.<sup>3</sup> They are still the most common methods of transferring information from the patient to the dental laboratory when making indirect restorations.<sup>1</sup>

## Abstract

**Purpose:** To compare digital and conventional impression techniques in a randomized clinical trial; specifically, procedure times, patient-centered outcomes, and clinical evaluation of the restorations.

**Materials and Methods:** Forty-two patients in need of tooth-supported single crowns and/or fixed partial prostheses up to six units were randomly allocated to one of the impression techniques. The procedure times, dentists' and patients' assessments using a visual analog scale (VAS), and clinical evaluation of the restorations were compared between the two groups.

**Results:** The mean total procedure times for digital and conventional impression technique were 14:33 ± 5:27 and 20:42 ± 5:42, respectively ( $p < 0.0001$ ). Mean impression times were 7:33 ± 3:37 and 11:33 ± 1:56, respectively ( $p < 0.0001$ ). Mean VAS scores for the dentist's assessment of difficulty (0 to 100; very difficult = 100) were 24.00 ± 18.02 and 48.02 ± 21.21, respectively ( $p < 0.0001$ ). Mean VAS scores for the patients' assessment of discomfort (0 to 100; very discomforting = 100) was 6.50 ± 5.87 and 44.86 ± 27.13, respectively ( $p < 0.0001$ ). Occlusal contacts showed a better result for the digital technique.

**Conclusion:** The results of this study demonstrated that the digital technique was more efficient and convenient than the conventional impression technique.

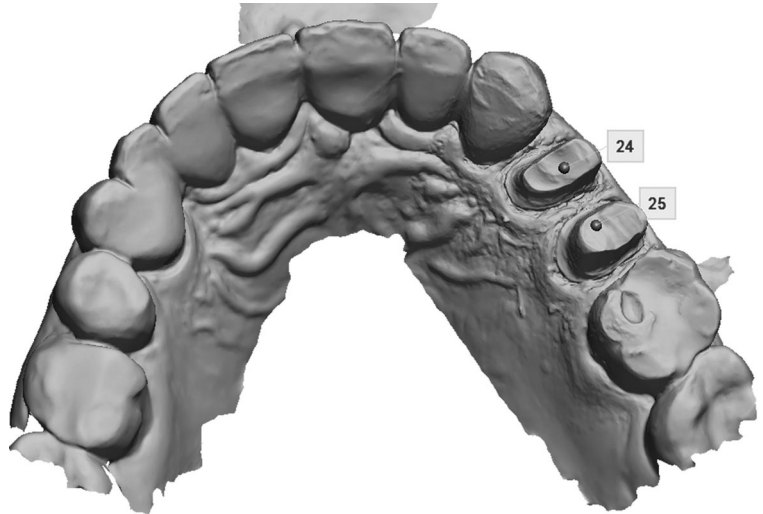
With the increasing use of digital intraoral impression systems, developed in the 1980s, the total elimination of physical casts using conventional impression systems has become possible.<sup>4</sup> In the digital system, the intraoral condition has been digitally recorded using an intraoral 3D acquisition device, and the acquired information enables the computer to generate a virtual model. Definitive restorations are fabricated on the basis of the virtual model.<sup>5</sup> An increasing number of fixed prostheses have been manufactured with intraoral digital impression techniques now becoming an important part of the digitization process of prosthodontics.<sup>6</sup>

The digital impression technique has many advantages, such as improvement of patient acceptance, reduction in the distortion of impression materials, the possibility of providing improved 3D previsualization of tooth preparations, and potential cost- and time-effectiveness.<sup>4,7-11</sup> Previous studies on the

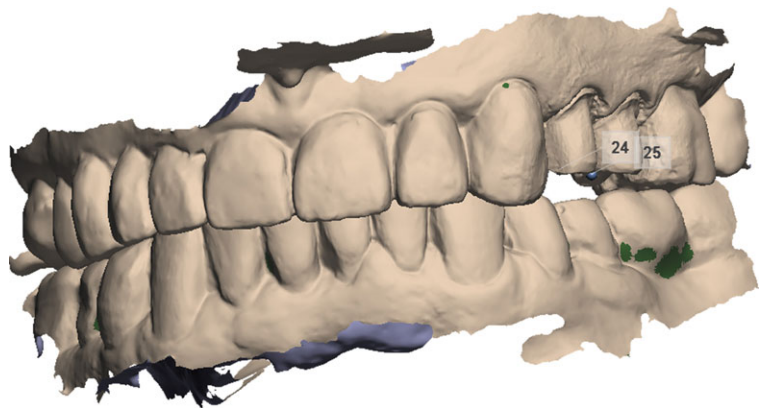**Table 1** Prosthetic restorations

Group	Restoration type (n)			Number of prepared teeth per impression (n)						Localization (n)	
	Single	FPP	Both	1	2	3	4	5	6	Anterior	Posterior
Conventional	13	10	1	5	10	2	3	3	1	11	13
Digital	12	11	1	5	12	2	2	1	2	8	16

FPP = fixed partial prosthesis.



**Figure 1** Occlusal full-arch scan demonstrating preparation of two premolars for single-unit crown restorations.



**Figure 2** Buccal scan with teeth in occlusion for an interocclusal registration.

accuracy of single or fixed partial prostheses have suggested that the digital impression technique may be considered an alternative to the conventional impression technique.<sup>8,10,12</sup> No studies could be identified reporting on the accuracy of printed/milled models and implications of the use of such models in the fabrication of dental restorations.

A limited number of studies have reported on differences in treatment times and patient-centered outcomes.<sup>9,11,13</sup> Therefore, the aim was to compare the digital impression technique for single- and multiple-unit tooth-supported restorations with the conventional impression technique regarding procedure times, dentists' assessment of difficulty, and patients' assessment of discomfort during the procedure, as well as clinical evaluation of the processed prosthetic restorations in a randomized clinical trial.

## Materials and Methods

Patients referred to the Department of Prosthodontics, at the Centre of Dental Specialist Care, Malmö, Sweden, in need of tooth-supported single crowns and/or fixed partial prostheses (FPP) of up to six units were considered for inclusion. The protocol was approved by the Regional Ethical Review Board in Lund (Ref: 2011/125).

One dentist (BG) was responsible for preparations, impressions, and enrolling participants. Of the total of 56 patients asked to participate in the study, two declined to participate, four were excluded due to the need for combined impressions (implant- and tooth-supported restoration), and two due to a need to extend the fixed dental prostheses to more than six units. Forty-eight patients agreed to participate in the study,

and their informed consent was obtained. A randomization scheme using sealed envelopes divided the 48 patients into two groups of equal size according to the impression method. There were 13 men and 11 women with a mean age of 56 years (SD 15.19, range 19 to 81) in the group for conventional impression technique, and 12 men and 12 women in the group for a digital impression technique, with a mean age of 56 years (SD 15.3, range 20 to 82). The detailed distribution of the prosthetic restorations is presented in Table 1.

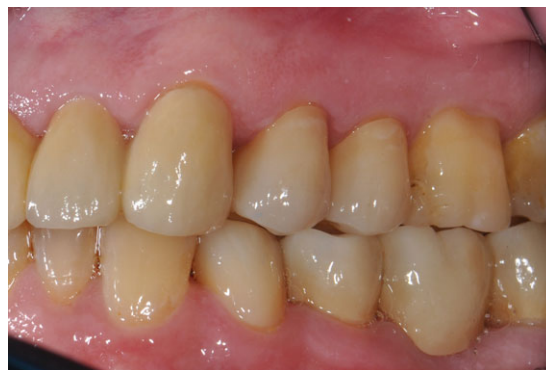All patients received local anesthesia prior to tooth preparation. Although preparations with subgingival margins were not excluded from the study, the preparation margins were preferably placed supragingival.

Four patients had preparations with a subgingival margin in the group for a conventional impression technique and three in the group for digital impression technique. Immediately after tooth (teeth) preparations were completed, patients were asked to pull an envelope to determine group allocation. The impressions were made at the same appointment immediately after tooth preparations were completed. Before taking the impression, retraction cords (Ultrapack; UP Dental GmbH, Am Westhover Berg, Germany) were placed in a single cord technique with astringent-hemostatic agents. The same retraction cord technique was used both for the conventional and digital impressions. Both impression techniques were only performed after an appropriate visibility of the preparation margins had been attained.

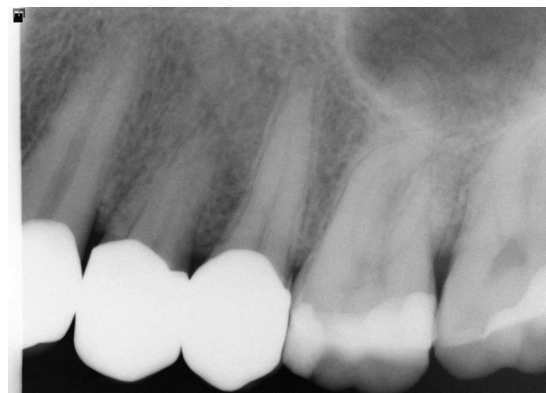In the first group, the patients had conventional one-step impressions through the use of perforated stainless steel inflexible trays (Asa Dental, Massarosa, Italy) and polyether impression material (Impregum Penta; 3M ESPE Dental Products, St. Paul, MN). The trays were filled with the impression material using a Pentamix Automatic Mixing Unit (3M ESPE, Seefeld, Germany), and the impression material was applied over the preparations using a disposable syringe. Alginate impression material (Blueprint Crème; Dentsply DeTrey GmbH, Konstanz, Germany) was used for the opposing impressions. The impressions were collected by the dental laboratory and poured on the same day with type IV dental stone (GC Fujirock, EP; GC Europe N.V., Leuven, Belgium). The casts were trimmed and mounted on a baseplate (Giroform; Amann Girrbach AG, Koblach, Austria). The occlusal relationship was recorded in an interocclusal registration wax (Alminax; Kemdent, Associated Dental Products Ltd, Wiltshire, UK). All setting times stated by the manufacturer were followed and were used according to manufacturer's guidelines.

In the second group, a digital intraoral scan was made with the Trios scanner Standard-P12 (3Shape A/S, Copenhagen, Denmark) with 3Shape TRIOS 2014-1 version 1.3.2.1 software. The prepared teeth were scanned first, followed by teeth in the other quadrant, and then a scan of the opposing teeth. The interocclusal registration was performed by buccal scan with teeth in occlusion. All digital restorations had models printed by Scan LED Technology (SLT) systems D30/35, with the high-tech resin FotoDent LED.A, according to the information provided by the manufacturer (Dreve Dentamid GmbH, Unna, Germany). Examples of scans of a clinical case are shown in Figures 1 and 2.

The restorations in both groups were all designed and fabricated at the same dental laboratory (Dental Syd, Malmö,



**Figure 3** Clinical case with ceramic single-unit crown restorations.



**Figure 4** Radiograph of ceramic single-unit crown restorations.

Sweden) by the same dental technician using the software Dental System 2014, version 2.9.9.5 (3Shape A/S). Concerning the material used for the prosthetic restorations, 13 (6 in the conventional group, 7 in the digital group) were made of lithium disilicate (e.max; Ivoclar Vivadent AG, Schaan, Liechtenstein), 16 (7 and 9, respectively) of full zirconia (BruxZir; Glidewell Laboratories, Newport Beach, CA), and 19 (11 and 8, respectively) were metalceramic (metal part milled from a cobalt-chrome alloy). All -ceramic restorations were milled from presintered material.

All impressions were performed by one dentist (BG), who had previously trained on the digital impression technique until he felt comfortable with the technology. The dentist had 10 years of experience with the conventional technique.

The parameters analyzed for each technique included procedure times, dentist's and patients' assessments of the technique through visual analog scale (VAS), and dentist's (BG) clinical evaluation of the prosthetic restorations. The prosthetic restorations were also evaluated by a second dentist (JK), with more than 40 years of clinical practice. This dentist was not present at the dental office when the impressions were taken and was not aware of which group the patients belonged to (i.e., this dentist was blinded to the intervention performed).

The procedure times were measured in minutes and seconds and divided into two periods. For the first period (the preparation time), the timer was started when the dentist started exposing the preparation and ended just before the mixing of impression material or starting the digital impression.

Procedures included in this period were retraction cord placement, choice of the impression tray, entry of patient data into the software (for the digital scanning technique), and preparation of dental laboratory requisition (for the conventional technique). For the second period (the impression time), the timer was started immediately after the previous timing and included the impression of the prepared teeth and the opposing impression, and interocclusal registration. The number of repetitions (if necessary) was recorded and the time taken for each repetition. The timing included all steps required to take a new valid impression.

The clinical evaluation of the prosthetic restorations was conducted according to the California Dental Association criteria and the World Dental Federation's recommendation for clinical studies, and was modified to suit the present study.<sup>14,15</sup> The criteria (and the rating scales) included three items:

- (i) "Marginal fit" was checked around the entire preparation perimeter, using probes with defined tip diameters of 150  $\mu\text{m}$  (Deppeler, Rolle, Switzerland) to clinically examine the range of the gap size before cementation, using the following rating: (1) clinically excellent (no clinically detectable gap); (2) clinically acceptable (detectable gap < 150  $\mu\text{m}$ ); (3) correction needed (gap larger than 150  $\mu\text{m}$ , making possible to insert the probe tip into the marginal misfit);
- (ii) "Occlusal contacts" were verified with occlusal foil (Troll-Foil blue; Trollhätteplast AB, Trollhättan, Sweden), using the following rating: (1) excellent (no need for occlusal contact adjustments); (2) acceptable (minor occlusal contact corrections were needed); (3) correction needed (major corrections needed);
- (iii) "Interproximal contact points" were verified with waxed dental floss (Dentotape, Johnson & Johnson, Brunswick, NJ), using the following rating: (1) clinically excellent (dental floss could only be inserted into the interdental space under pressure); (2) clinically acceptable, slightly strong (contact slightly tight, but dental floss could still be inserted); (3) clinically acceptable, slightly weak (floss passed very easily with only a slight snap effect); (4) correction needed (contact is weak and a 100  $\mu\text{m}$  metal blade could easily pass through).

The examiners were calibrated for the clinical parameters. The calibration process was performed in patients not included in the study. First, the two dentists (BG, JK) responsible for the clinical evaluation of the prosthetic restorations became acquainted with the theory of the clinical criteria and recommendations for clinical studies. The second step was dedicated to clinical exercise, with the aim of providing clinical familiarity to the presented criteria to the examiners. In this step, both examiners were simultaneously present in the dental office with each patient, and disagreements were resolved by discussion between the dentists. In the third step, the examiners separately assessed the clinical parameters of new patients, without any communication between examiners, to evaluate the calibration result. The last step of the calibration was aimed at discussing the results, emphasizing the need to reach a good agreement before starting with the study patients. Prosthetic restorations were sent back to the dental technician (or remade) in cases where one or more criteria were rated as "correction needed."

**Table 2** Comparison of the procedures times (in minutes; mean value  $\pm$  SD) and visual analog scale (VAS; mean value  $\pm$  SD) results between the techniques

	Conventional	Digital	<i>p</i> -value*
Procedure			
Preparation	07:48 $\pm$ 03:44	07:00 $\pm$ 03:12	0.432
Impression	11:33 $\pm$ 01:56	07:33 $\pm$ 03:37	<0.0001
Total	20:42 $\pm$ 05:42**	14:33 $\pm$ 05:27	<0.0001
VAS			
Dentist's assessment	48.02 $\pm$ 21.21	24.00 $\pm$ 18.02	<0.0001
Patient's assessment	44.86 $\pm$ 27.13	6.50 $\pm$ 5.87	<0.0001

\*Student's *t*-test.

\*\*In three cases the impression needed to be repeated, which increased the total mean time for the conventional group.

To evaluate the dentist's and patients' assessment of the impression procedure, a VAS was used.<sup>16,17</sup> The dentist conveyed his assessments on a nonnumerical 100 mm line ranging from "not difficult at all = 0" to "very difficult = 100." The patients conveyed their assessments on a nonnumerical 100 mm line ranging from "not discomforting at all = 0" to "very discomforting = 100." Each response was given a numerical value ranging from 0 to 100.

All data were statistically analyzed by a third dentist (BRC), who did not take part in any of the clinical procedures. The software used was the SPSS v.22 (SPSS Inc., Chicago, IL). The performed tests for the two independent groups were Student's *t*-test or Mann-Whitney test, depending on the normality. Correlation and linear regression were performed to verify the relationship between the impression times and the VAS scores. Correlation was performed to check the relationship between the impression technique and the following parameters: marginal fit, occlusal contacts, interproximal contacts. Moreover, correlation and linear regression were also performed to check the relationship between the impression technique and the number of prepared teeth in the same impression. The degree of statistical significance was considered  $p < 0.05$ .

## Results

The difference in the mean total procedure times was statistically significant, resulting in 14:33  $\pm$  5:27 and 20:42  $\pm$  5:42 for digital and conventional impression techniques, respectively. The mean impression times were 7:33  $\pm$  3.37 and 11:33  $\pm$  1.56, respectively. There was no statistically significant difference in preparation times between the techniques. The dentist reported the digital impression technique as less difficult than the conventional technique, and patients reported the digital impression technique more comfortable than the conventional technique. The mean VAS scores for the dentist's assessment of difficulty were 24.00  $\pm$  18.02 and 48.02  $\pm$  21.21 for digital and conventional impression technique, respectively. The mean VAS scores for the patients' assessment of discomfort were 6.50  $\pm$  5.87 and 44.86  $\pm$  27.13, respectively (Table 2).

"Occlusal contacts" was the only clinical parameter with statistically significant difference between the impression techniques, showing better results for the digital impression

**Table 3** Comparison of the clinical parameters of the prosthetic restorations between the techniques (mean value  $\pm$  SD)

Clinical parameters	Conventional	Digital	<i>p</i> -value*
Marginal fit	1.54 $\pm$ 0.66	1.25 $\pm$ 0.53	0.075
Occlusal contacts	1.58 $\pm$ 0.65	1.21 $\pm$ 0.41	0.028
Interproximal contact points	1.58 $\pm$ 1.21	1.79 $\pm$ 0.83	0.100

\*Mann-Whitney test.

**Table 4** Relationship between the impression times and the VAS scores (correlation and linear regression)

Group	R	R <sup>2</sup>	<i>p</i> -value	Correlation <sup>a</sup>	Equation
<i>VAS (dentist)</i>					
Conventional	0.611	0.373	0.002	Moderate	$y = 1.1 + 0.038x$
Digital	0.582	0.339	0.003	Moderate	$y = -3.9 + 0.032x$
<i>VAS (patient)</i>					
Conventional	0.182	0.033	0.396	Very weak	$y = 27.0 + 0.014x$
Digital	0.252	0.063	0.236	Weak	$y = 2.6 + 0.005x$

<sup>a</sup>Pearson.

technique. The clinical parameters “marginal fit” and “interproximal contact points” failed to show any statistically significant difference between the impression techniques (Table 3).

When the relationship between impression times and VAS scores was verified (Table 4), a stronger correlation was observed between the dentist’s assessment of the impression taking and the impression time, than it was between the patients’ assessment of the impression taking and the impression time. Moreover, 37.3% and 33.9% of the variance of dentist VAS scores is explained by the conventional and digital impression times, respectively. For each minute increase of impression time the dentist’s VAS value increased by 2.28 points ( $p = 0.002$ ) for the conventional impression, and 1.92 points ( $p = 0.003$ ) for the digital impression. As the value of both “b” coefficients are statistically significant, the model fits the data very well. The numbers for the variance of the patients’ VAS scores were 3.3% and 6.3%, respectively, for the conventional and digital impression times. For each minute increase of impression time the patient’s VAS value increased by 0.84 points ( $p = 0.396$ ) for the conventional impression, and 0.30 points ( $p = 0.236$ ) in the digital impression; however, the models were not statistically significant, and the relationship was very weak or weak.

When the relationship between the impression times and the number of teeth included in each impression were verified, there was a moderate relation between the digital impression and the number of teeth ( $R = 0.426$ ;  $R^2 = 0.182$ ;  $p = 0.038$ ). There was a mean increase of 62.8 seconds in the impression time for each additional tooth included. On the other hand, the same was not true for the conventional method ( $R = 0.155$ ;  $R^2 = 0.024$ ;  $p = 0.470$ ).

## Discussion

Digital impression technique was less time consuming than the conventional one in impression time and total amount of

time consumed. This is in accordance with four recent studies, three assessing single implant restorations,<sup>9,12,13</sup> and another assessing full-arch impressions without dental preparation and/or implants.<sup>11</sup> This difference may be influenced by the possibility to rescan only the missing and unacceptable areas of the digital impression. For the conventional impression technique the entire impression needs to be retaken, which was the case for three patients in the present study, increasing the total mean time for the conventional group. The digital impression time may also differ between different impression systems available; hence, the current results may not be applicable for other systems. A moderate relationship was found in the digital impression group for the number of prepared teeth and impression time. This fits the impression procedure well, meaning that digital impressions will take longer time if the number of prepared teeth are increased.

The present results showed that the level of difficulty for the dentist and the level of discomfort felt by the patients were significantly lower for the digital impression technique than for the conventional technique. It has been shown that the use of digital impressions increases the patients’ level of comfort and treatment acceptance.<sup>11</sup> Possible reasons for that include the reduced amount of time for the procedure, the avoidance of a possible gagging reflex, the decreased discomfort in patients with limited mouth opening, and no possibility of tooth/gingival sensitivity due to the impression material.

Considering the level of difficulty judged by the dentist, the intraoral scanner seems to be easier to manage than the conventional impression materials. Rescan of the missing areas seems to be more convenient and less cumbersome than retaking the entire impression with a conventional technique. Moreover, conventional impressions require more experience to achieve the same level of proficiency than digital impressions, suggesting that the learning process for digital impressions would be simpler than for conventional impressions.<sup>9</sup> The level of difficulty was considered by one dentist, and it is hard to draw any further conclusions to the whole dental population. Further studies exploring this aspect would be needed to draw conclusions regarding if the new technique is easier to manage. The present study found a moderate relationship between the impression time and the level of difficulty judged by the dentist, suggesting that an increase in impression time makes the dentist consider the procedure as more difficult.

The digital impression technique showed better results for “occlusal contacts” when the impression techniques were compared. This might be explained by the difference in interocclusal registration between the two techniques. For the digital impression the interocclusal registration was performed by a buccal scan with teeth in occlusion, and directly from that relationship, crowns and FPPs were then designed and manufactured. There was no need of an intermediate model. This eliminates possible changes of the interocclusal registration material due to distortion on removal from the mouth, or during transit, or changes due to temperature variations. Improper mounting of the casts in the articulator could also be considered as a possible explanation. Another aspect that can be of importance is the accuracy of printed models if used for veneering or final adjustments of the restorations. This needs to be further investigated. Previous

studies have reported better fit for digital impressions of single or fixed partial prosthesis preparations than for conventional impressions.<sup>8,10</sup> However, in the present study there was no statistically significant difference between the methods, which may be explained by the limitations of the method used for the clinical evaluation (i.e., the use of probes with defined tip diameters of 150  $\mu\text{m}$ ). The other two studies showing better fit for digital impression were in vitro studies and made use of computer software<sup>8</sup> or a 3D-coordinate measuring system,<sup>10</sup> both with the capacity to detect discrepancies much smaller than 150  $\mu\text{m}$ . The lack of a statistically significant difference between the methods for the interproximal contact points can also be explained by the limitations of the method used for the clinical evaluation. In this case, dental floss and a 100- $\mu\text{m}$ -thick metal blade.

As the assessments may vary considerably from patient to patient even with the same impression technique, the fact that different techniques were not performed on the same patient may be a limitation of the present study. The use of two groups eliminates the risk that impression number two in succession may be of inferior quality and the patient's experience is not influenced by the first impression or the extended chair time. Moreover, the study does not include full-arch restoration, being limited to single crowns and FPPs. Another limitation is that this study ignored the time factors for the dental technician involved in the conventional impression technique, such as pouring and mounting the cast, trimming the dies, and painting the die spacer. These steps are naturally reduced by the digital technique; therefore the time for the workflow may be reduced. Last but not least, it would be a more valuable comparison if the type of crowns were all the same, as each of the types of crowns tends to present with different fit values.

Concerning the impression material, polyether was the choice for the present study due to its high accuracy<sup>3</sup> and to the dentist's long familiarity with this material. As different impression materials have different setting times, the choice for material other than polyether may have resulted in a different contrast in time difference between the techniques (conventional vs. digital). Although conventional impression materials like polyether are well developed and present great accuracy, the intraoral digital impression technique has a distinct superiority in work efficiency and saving of materials.<sup>7</sup> However, the number of prepared teeth that need to be scanned with a digital impression seems to increase the impression time (a mean increase of 62.8 seconds for each additional tooth) and should be considered. According to the results of the present study, the intraoral digital impression technique seems to be convenient and time-saving, and the concept is somewhat incipient, but there is still need for further research.

## Conclusion

According to the results of this study, the digital impression technique was less time consuming and more convenient for the dentist as well as for the patients. "Occlusal contacts" was the

only clinical parameter with statistically significant difference between the impression techniques.

## References

1. Hamalian TA, Nasr E, Chidiac JJ: Impression materials in fixed prosthodontics: influence of choice on clinical procedure. *J Prosthodont* 2011;20:153-160
2. Rodrigues SB, Augusto CR, Leitune VC, et al: Influence of delayed pouring on irreversible hydrocolloid properties. *Braz Oral Res* 2012;26:404-409
3. Wadhvani CP, Johnson GH, Lepe X, et al: Accuracy of newly formulated fast-setting elastomeric impression materials. *J Prosthet Dent* 2005;93:530-539
4. Christensen GJ: Impressions are changing: deciding on conventional, digital or digital plus in-office milling. *J Am Dent Assoc* 2009;140:1301-1304
5. Ender A, Mehl A: In-vitro evaluation of the accuracy of conventional and digital methods of obtaining full-arch dental impressions. *Quintessence Int* 2014;46:9-17
6. Galhano GA, Pellizzer EP, Mazaro JV: Optical impression systems for CAD-CAM restorations. *J Craniofac Surg* 2012;23:575-579
7. Christensen GJ: Will digital impressions eliminate the current problems with conventional impressions? *J Am Dent Assoc* 2008;139:761-763
8. GÜth JF, Keul C, Stimmelmayer M, et al: Accuracy of digital models obtained by direct and indirect data capturing. *Clin Oral Investig* 2013;17:1201-1208
9. Lee SJ, Gallucci GO: Digital vs. conventional implant impressions: efficiency outcomes. *Clin Oral Implants Res* 2013;24:111-115
10. Seelbach P, Brueckel C, Wostmann B: Accuracy of digital and conventional impression techniques and workflow. *Clin Oral Investig* 2013;17:1759-1764
11. Yuzbasioglu E, Kurt H, Turunc R, et al: Comparison of digital and conventional impression techniques: evaluation of patients' perception, treatment comfort, effectiveness and clinical outcomes. *BMC Oral Health* 2014;14:10
12. Boeddinghaus M, Breloer ES, Rehmann P, et al: Accuracy of single-tooth restorations based on intraoral digital and conventional impressions in patients. *Clin Oral Investig* 2015;19:2027-2034
13. Joda T, Bragger U: Patient-centered outcomes comparing digital and conventional implant impression procedures: a randomized crossover trial. *Clin Oral Implants Res* 2015 Apr 12. doi: 10.1111/clr.12600. [Epub ahead of print]
14. Cvar JF, Ryge G: Reprint of criteria for the clinical evaluation of dental restorative materials. 1971. *Clin Oral Investig* 2005;9:215-232
15. Hickel R, Roulet JF, Bayne S, et al: Recommendations for conducting controlled clinical studies of dental restorative materials. Science Committee Project 2/98—FDI World Dental Federation study design (Part I) and criteria for evaluation (Part II) of direct and indirect restorations including onlays and partial crowns. *J Adhes Dent* 2007;9(Suppl 1):121-147.
16. Aitken RC: Measurement of feelings using visual analogue scales. *Proc R Soc Med* 1969;62:989-993
17. Briggs M, Closs JS: A descriptive study of the use of visual analogue scales and verbal rating scales for the assessment of postoperative pain in orthopedic patients. *J Pain Symptom Manage* 1999;18:438-446