

Efficacy of Harmonic US and LigaSure in Surgical Treatment of 3rd and 4th Degree Internal Hemorrhoids versus Conventional Hemorrhoidectomy

Mohamed Aly Elhorbity^{1*}, Mohamed Ibrahim Mansour² and Nady Ahmed Mahmoud¹

¹Department of General Surgery, Benha Teaching Hospital, General Organization for Teaching Hospitals and Institutes, Egypt

²Department of General Surgery, Faculty of Medicine, Zagazig University, Egypt

Abstract

The hemorrhoids are normal vascular components in the anal canal. About 5% of the general population is affected by symptoms related to the hemorrhoidal disease. They will become a disease when inflamed or enlarged, termed "hemorrhoid" that is frequently applied for indicating to a disease. Hemorrhoids are commonly diagnosed by the physical examination.

The internal hemorrhoids were originated above the dentate (pectinate) line meanwhile; external hemorrhoids were originated below it. During 1985, the internal hemorrhoids were categorized into 4 grades based on the degree of prolapse.

The aim of the present investigation is to determine and estimate the efficacy of hemorrhoidectomy performed by the harmonic US and LigaSure scalpels in terms of minimizing postoperative pain, and lowering the complexities versus conventional hemorrhoidectomy.

Between October 2015 and October 2019, this investigation included 60 patients complaining from III or IV-degree internal hemorrhoids, classified into 3 groups; 20 patients for each, group A, in which hemorrhoidectomy done with harmonic US scalpel, group B, hemorrhoidectomy done with LigaSure and group C, hemorrhoidectomy done with conventional scalpel and monopolar electrocautery.

Harmonic scalpel and LigaSure, are more safe and effective procedures for surgical treatment of Grade III and Grade IV hemorrhoidal disease. Less postoperative pain, time consuming, bloodless and lower postoperative complications compared with conventional hemorrhoidectomy and earlier wound healing. However, the unique disadvantage of Harmonic scalpel and LigaSure is a moderately expensive than the conventional protocol.

Keywords: Harmonic US scalpel • LigaSure • Hemorrhoids • Conventional • Hemorrhoidectomy

Introduction

The hemorrhoids are common vascular components in the anal canal. About 5% of the common population is influenced by symptoms correlating to the hemorrhoidal disease [1]. They will become a disease when inflamed or enlarged, termed "hemorrhoid" that is frequently applied for indicating to a disease [2].

Hemorrhoids are typically diagnosed by the physical examination [3]. The internal hemorrhoids were originated above the dentate (pectinate) line meanwhile; external hemorrhoids were originated below it [4]. During 1985, the internal hemorrhoids were categorized into 4 grades based on the degree of prolapse [5].

The surgical excision of hemorrhoids still a extremely functional approach for the handling of symptomatic hemorrhoids but is confined for chosen patients [3].

Patients with grade 3 or 4 internal hemorrhoids, and those with severe external hemorrhoids, appear to benefit greatly from surgery. Hemorrhoidectomy is believed to be a simple operation but the postoperative healing is a extremely painful to the patient and so the patients believe hemorrhoidectomy is the final choice for caring. The classical techniques involve Ferguson's closed hemorrhoidectomy and Milligan–Morgan's open hemorrhoidectomy that can be operated with scalpel or electrocautery. Harmonic scalpel is introduced for the first time in 1992, using the ultrasound energy to cut and coagulate soft tissue, with minimal thermal destruction to the surrounding tissue [6].

LigaSure vessel sealing system is a dipolar electro-thermal instrument that seals the blood vessels by a calculated arranging of pressure and radio frequency [7].

The recently advanced surgical device as harmonic US, ligaSure scalpels and circular staplers are newly applied in the surgical handling of hemorrhoids, and the effect are perfect concerning the minimum bleeding and preferable postoperative pain control, that decreasing the need for analgesics postoperatively when compared with hemorrhoidectomies

*Address for Correspondence: Mohamed Aly Elhorbity, Department of General Surgery, Benha Teaching Hospital, General Organization for Teaching Hospitals and Institutes, Egypt, Tel: +201222498246; E-mail: Mohamed_elhorbity@hotmail.com

Copyright: © 2020 Elhorbity MA, et al. This is an open-access article distributed under the terms of the creative commons attribution license which permits unrestricted use, distribution and reproduction in any medium, provided the original author and source are credited.

Received: 29 March, 2020; Accepted: 9 April, 2020; Published: 18 April, 2020

performed with the conventional surgical methods [8]. A systematic review and network meta-analysis of 98 randomized trials compared clinical outcomes and effectiveness of various hemorrhoidectomy techniques used in treating the grade III and IV internal hemorrhoids [9].

The traditional hemorrhoidectomies performed with one of the advanced electrosurgical equipment; LigaSure or Harmonic scalpel may cause less severe pain but cost more compared with the ones performed with a scalpel or monopolar electrocautery [7].

The ultimate choice of procedure is detected by surgeon preference, as individual surgeons may not have either the expertise or equipment required to perform all hemorrhoidectomy procedures [3].

Aim of Work

The aim of the present investigation is to determine and estimate the effectiveness of hemorrhoidectomy performed by the harmonic US and LigaSure scalpels for minimizing postoperative pain, and lowering the complexities versus traditional hemorrhoidectomy.

Patients and Methods

Between October 2015 and October 2019, this investigation included 60 patients complaining from III or IV-degree internal hemorrhoids, classified into 3 groups; 20 patients for each, group A, in which hemorrhoidectomy done with harmonic US scalpel, group B, hemorrhoidectomy done with LigaSure and group C, hemorrhoidectomy done with conventional scalpel and monopolar electrocautery.

Inclusions criteria

All patients included in the present study aged between 20 and 60 years old, 32 male and 28 female patients, presented with grade III or grade IV hemorrhoids and patients who were willing to participate in this study.

Exclusions criteria

Patients with liver cirrhosis, anticoagulant therapy, cancer, hemorrhagic diseases, previous anal surgery, patients with associated anorectal pathology such as perianal fistula or fissure, external hemorrhoids and acute thrombosed hemorrhoids were excluded.

Examination, diagnosis and operation protocol

Diagnosis of III and IV-degree hemorrhoids were occurred, according to patient history, symptoms, digital rectal examination, complete physical examination, and colonoscopy for age more than 50 or symptoms of inflammatory bowel disease or risk factors of colorectal cancer.

All patients underwent routine lab tests (complete blood picture, random blood sugar, coagulation profile, renal and liver functions tests), electrocardiogram. All patients with indication for surgery were informed about the procedures and written consent taken. Purgative enema was done at the night before surgery and prophylactic antibiotic, metronidazole 500 mg slowly IV, 10 minutes before anesthesia followed by oral metronidazole 500 mg/8 hrs for one week plus oral levofloxacin 500 mg once daily for 10 days.

The operation was done in lithotomy position, under spinal anesthesia. The perianal, perineum and upper thigh were prepared and draped in sterile fashion. Anal canal examination with anoscope before hemorrhoidectomy was done. Open hemorrhoidectomy done for all patients using harmonic US scalpel in group A patients, LigaSure in group B patients and scalpel with monopolar electrocautery in group C patients in dissection and excision of the hemorrhoidal tissue from the anal sphincter with the helping of vascular (artery) forceps, till reaching the pedicle; apex region. In all patients in group A and B, were categorized the hemorrhoid tissue post complete coagulation

of the pedicle using harmonic scalpel in group A and LigaSure in group B. Meanwhile, in group C, before dividing the hemorrhoidal tissue trans fixation ligation of the hemorrhoidal pedicle with vicryl 2-0 securing the pedicle. Complete hemostasis, then small gauze with local anesthetic ointment was inserted into the anal canal in all patients in group A, B and C, then removed 12 hours postoperative.

The operative time of each procedure was recorded by an operating nurse and blood loss was also recorded as the number of soaked gauzes. Soakage of one 4x4 gauze piece was considered as 30 ml blood loss. All patients were asked to clean the wound doing sitz bath twice daily in the first week, then once daily after defecation in the second week. Pain control postoperative with oral paracetamol 500 mg each 8 hrs for one week plus Ibuprofen 400 mg each 8 hrs for 72 hrs postoperative and ketolac 30 mg amp IM each 12 hrs for 24 hrs postoperative and when needed according to the severity of pain.

The patients were discharged home on the first postoperative day unless otherwise clinically indicated. Follow up for all patients in the outpatient clinic 1st, 2nd, 3rd, 4th and 8th week after discharge. The patients were asked to record at home before bed-time their maximum pain score for the day during rest and post defecation using numeral analogue score for pain from 1 to 10 in the first 3 days, one week and 2 weeks postoperative. Recording any postoperative urine retention, early or late bleeding, anal infection, anal stenosis or anal incontinence for one month postoperative was done.

Results

All the 60 patients included in this study aging from 20 to 60 years old, 32 male and 28 females. According to their symptoms and after complete physical examination and full investigations, they diagnosed as third- or fourth-degree internal hemorrhoids and classified into 3 groups each group includes 20 patients. Group A, open hemorrhoidectomy done with harmonic US scalpel, group B, open hemorrhoidectomy done with ligaSure, and group C, open hemorrhoidectomy done with conventional scalpel and monopolar electrocautery (Figures 1-3).

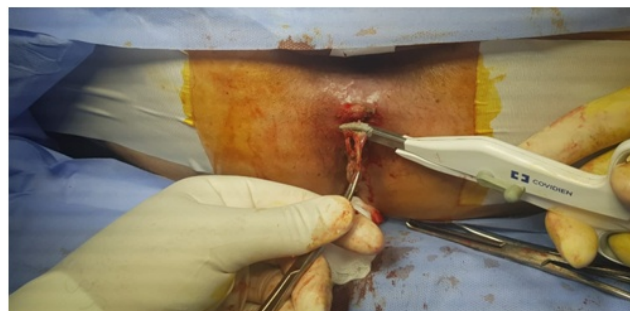

Figure 1. Showing 4th degree hemorrhoid and harmonic scalpel prepared for hemorrhoidectomy.

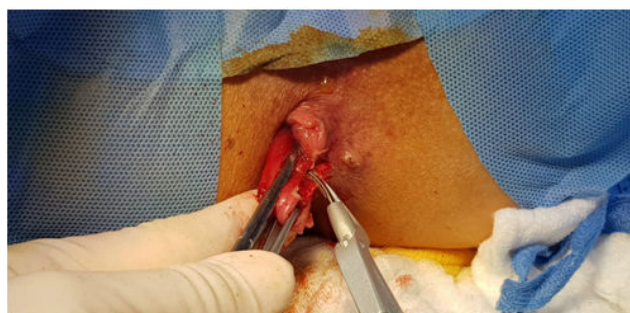

Figure 2. Showing harmonic scalpel during dissection of 4th degree hemorrhoid at 3 o'clock.

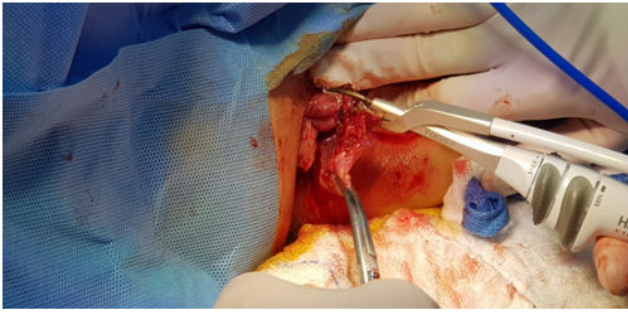


Figure 3. Showing complete dissection and hemorrhoidectomy of 4th degree hemorrhoid at 3 o'clock with harmonic scalpel.

Postoperative pain according to numeral analogue score for pain from 1 to 10 in the first 3 days, one week and two weeks postoperative was significantly lower in both group A and group B (Harmonic and LigaSure hemorrhoidectomy) ranging from number 2 to number 5 in the first 3 days and from number 1 to number 3 after one and two weeks compared with group C (Conventional hemorrhoidectomy) ranging from number 3 to number 8 in the first 3 days and from number 1 to number 5 after one and two weeks postoperative. Operative time in group A and group B, ranging from 20 to 40 min, mean operative time 30 minutes while was higher in group C, ranging from 30 to 60 min, mean operative time 45 minutes (**Figure 4 and 5**).

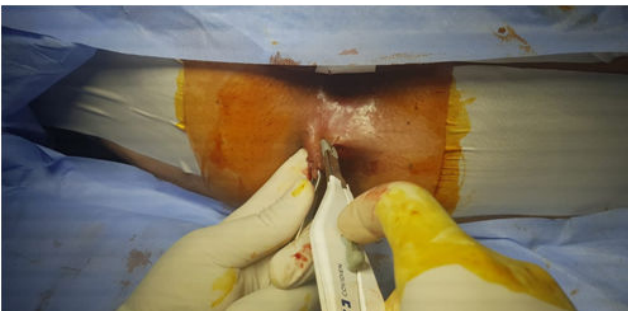


Figure 4. Showing ligaSure scalpel during dissection of 4th degree hemorrhoid at 11 o'clock.

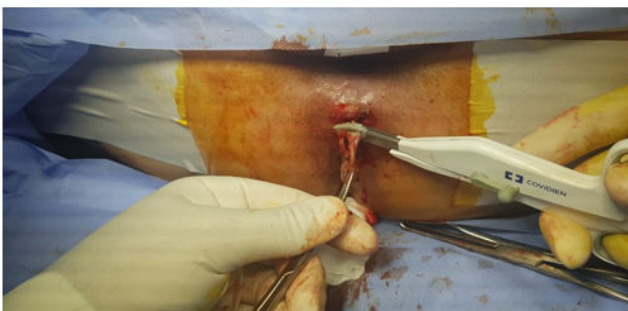


Figure 5. Showing complete dissection and hemorrhoidectomy of 4th degree hemorrhoid at 11 o'clock.

Postoperative urine retention, one male patients in group A and two male patients in group B, and four male patients in group C. All patients of urine retention managed by urinary catheter removed 2 hrs before discharge from the hospital. Blood loss during the operation was less in both group A and group B (from 30 to 60 ml equal to 1-2 soaked 4 × 4 gauze piece) mean blood loss 45 ml, compared to group C (from 60 to 100 ml, equal to 2-3 soaked 4 × 4 gauze piece) mean blood loss 80 ml. According to postoperative bleeding, one female patient in group A, minor bleeding one week after the procedure and one male patients in group B, minor bleeding 10 days after the operation and the 2 patients managed conservatively. In group C, two patients complained from postoperative bleeding, one after 24

hrs and the second 10 days postoperative and the two patients were managed conservatively.

In this study there is one case of anal stenosis in group C (conventional hemorrhoidectomy) appeared 4 weeks after the operation and managed with anal dilation under general anesthesia and no cases of incontinence in all groups. Wound healing was evaluated according to the numeral analogue score for pain with the regular physical local examination and patient satisfaction. It was better in group A and B, ranging from 2-4 weeks compared to group C, ranging from 4 - 6 weeks, after follow up for 8 weeks for all patients' groups. Hospital stay in all groups not more than 24 hrs except one patient in group C, discharged after 2 days due to minor postoperative bleeding managed conservatively.

Discussion

The surgical handling is the standard treatment for grade III or grade IV internal hemorrhoids. In spite of this, pain after traditional hemorrhoidectomy is still a great challenge. Various devices like harmonic and ligaSure scalpels have been improved for minimizing intraoperative bleeding, postoperative pain, and postoperative complications such as bleeding, anal incontinence, and anal stenosis [10]. The harmonic scalpels and LigaSure are recently improved ultrasonic scalpel equipments with automatic vessel-sealing systems. They include whole cutting and coagulation of vessels up to 7 mm in diameter, with minimal surrounding thermal spread (<2 mm) and limited tissue-charring [11].

Harmonic US scalpel transform electricity into high frequency ultrasound mechanical vibrations (550000 Hz), thus for tissue coagulating and cutting. High frequency ultrasound energy causes destruction of hydrogen bonds within the proteins and also their denaturation. Temperature released during the procedure is lower (80°C) and the heat damage of surrounding tissue is minimal [12]. Harmonic scalpel exhibited less intraoperative blood loss, better exposure of the operative field, and lesser operative time [13]. The LigaSure vessel sealing system is a dipolar electro-thermal instrument that seals the blood vessels by a calculated arranging of pressure and radio frequency [14].

The energy is only delivered to the tissue grasped within the jaws of the hand piece with minimal spread of electrical or thermal energy to adjacent tissue. A computer-controlled feedback loop automatically stops the flow of energy when coagulation of the vessels and mucosa is achieved.

Ravi Kumar and colleagues clarified investigation on 60 patients to compare harmonic scalpel hemorrhoidectomy with traditional open protocol (Milligan–Morgan); they observed that VAS pain scores at days 1, 7 and 14 postoperatively were minimal in harmonic scalpel group compared with Milligan–Morgan group. Furthermore, the blood loss through the operation was minimal in harmonic scalpel group (6.1 ml for harmonic scalpel group vs. 19.4 for Milligan–Morgan group). Other postoperative complexities like hemorrhage and urinary retention were more in Milligan–Morgan group [14]. Abo-Hashem and colleagues clarified a considerable quick wound healing in harmonic scalpel hemorrhoidectomy. They assigned this higher rate of wound healing at 6 weeks postoperatively to the lesser tissue trauma, lesser charring, minimal local edema in the surrounding tissues, and absence of tissue necrosis [15].

Some authors has been carried out about the outcome of LigaSure, and it has been confirmed as the simple and safe surgical handling of hemorrhoids in the operative time, postoperative pain and wound infection as compared to traditional hemorrhoidectomy [16,17].

Chung and colleagues compared the results of hemorrhoidectomy carried out by three various protocols: scalpel of harmonic, bipolar scissors, or by excision-ligation technique (Milligan–Morgan) using the ordinary surgical scissor. Both harmonic scalpel hemorrhoidectomy and bipolar scissors hemorrhoidectomy claimed preferable outcomes than Milligan–Morgan hemorrhoidectomy regarding lowering of blood loss. Harmonic scalpel

hemorrhoidectomy had the minimal pain score and preferable satisfaction score during comparing with the other two protocols [18].

In this investigation, Harmonic US scalpel and LigaSure electrosurgical unit were used for the treatment of patients who presented with symptomatic hemorrhoids and compared the results and surgical outcomes with that been recorded after the conventional excisional hemorrhoidectomy. The results were clarified that both, Harmonic and LigaSure hemorrhoidectomy when compared with conventional hemorrhoidectomy, are simple, safe, and very effective treatment modality. Both of them characterized by bloodless submucosal dissection, less operative time, less postoperative pain and less overall postoperative complications, besides, excellent surgical outcomes compared with conventional hemorrhoidectomy. There is no significant difference between the result of, Harmonic and LigaSure hemorrhoidectomy, but both are better than conventional hemorrhoidectomy.

Furthermore, our findings clarified that the post-operative pain score, the amount of intraoperative blood loss and operative time were obviously less in the Harmonic and LigaSure groups compared with traditional group. Postoperative pain according to the numeral analogue scores for pain from 1 to 10 in the first 3 days, one and two weeks postoperative were significantly lower in both group A and group B (Harmonic and LigaSure hemorrhoidectomy) compared with group C (Conventional hemorrhoidectomy).

These findings were consistent with that obtained by Bakhtiar et al. and Gentile et al. who compared between LigaSure and traditional hemorrhoidectomy for IV degree hemorrhoids, and they clarified that the LigaSure is simple and more effective with short operating time, less postoperative pain score due to limited tissue damage, and free from pain earlier than those with traditional hemorrhoidectomy [19,20].

In a prospective study Armstrong et al. observed significantly minimal postoperative pain in Harmonic scalpel hemorrhoidectomy compared with electrocautery hemorrhoidectomy [21]. Talha and colleagues observed that both harmonic scalpel and ligaSure were superior to traditional diathermy in hemorrhoidectomy, in having minimal operative time, minimal postoperative pain, and minimal analgesic uptake through the first day postoperatively and rapid wound healing [22].

Nienhuijs and de Hingh compared the patients' tolerance and postoperative pain after LigaSure and traditional hemorrhoidectomy, and they clarified that LigaSure protocol is superior in terms of postoperative pain, patients' tolerance, and without any adverse effect on the surgical result and postoperative complexities [23].

Incontinence and anal stenosis are a short-term complication and two of the most important parameters affecting the patient comfort and satisfaction. In the present investigation, there is only one case of anal stenosis in group C (traditional hemorrhoidectomy) observed 4 weeks post the operation and handling with anal dilation under general anesthesia and no cases of incontinence in all groups.

Conclusion

Harmonic scalpel and LigaSure, are more safe and effective procedures for surgical handling of Grade III and Grade IV hemorrhoidal disease. Less postoperative pain, time consuming, bloodless and lower postoperative complications compared with conventional hemorrhoidectomy and earlier wound healing. But, the only disadvantage of Harmonic scalpel and LigaSure is a moderately expensive than the traditional protocol.

References

1. Sneider, Erica B, and Justin A Maykel. "Diagnosis and Management of Symptomatic Hemorrhoids." *Surgical Clinics* 90 (2010): 17-32.

2. Schubert, Moonkyung Cho, Subbaramiah Sridhar, Robert R Schade, and Steven D Wexner. "What every Gastroenterologist Needs to know about Common Anorectal Disorders." *World J Gastroenterol* 15 (2009): 3201.
3. Rivadeneira, David E, Scott R Steele, Charles Terment and Sridhar Chalasani, et al. "Practice Parameters for the Management of Hemorrhoids (Revised 2010)." *Diseases Colon Rectum* 54 (2011): 1059-1064.
4. Dayton, Merrill T, Peter F Lawrence, Richard Bell. "Essentials of General Surgery (4th ed)." Philadelphia; Baltimore:Williams and Wilkins (2006):329.
5. Beck, David E, Patricia L Roberts, Theodore J Saclarides and Anthony J Senagore, et al. "The ASCRS Textbook of Colon and Rectal Surgery." Springer Sci Business Media (2011): 1-907.
6. Chung, CC, Hester YS Cheung, Eva SW Chan and SY Kwok, et al. "Stapled Hemorrhoidopexy vs. Harmonic Scalpel™ Hemorrhoidectomy: A Randomized Trial." *Diseases Colon Rectum* 48 (2005): 1213-1219.
7. Milito, G, M Gargiani and F Cortese. "Randomised Trial Comparing LigaSure Haemorrhoidectomy with the Diathermy Dissection Operation." *Techniq Coloproctol* 6 (2002): 171-175.
8. Bulus, Hakan, Adnan Tas, Ali Coskun, and Metin Kucukazman. "Evaluation of Two Hemorrhoidectomy Techniques: Harmonic Scalpel and Ferguson's with Electrocautery." *Asian J Surg* 37 (2014): 20-23.
9. Simillis, Constantinos, SN Thoukididou, AAP Slesser and Shahnawaz Rasheed, et al. "Systematic Review and Network Meta-Analysis Comparing Clinical Outcomes and Effectiveness of Surgical Treatments for Haemorrhoids." *British J Surg* 102 (2015): 1603-1618.
10. Tan, Emile K, Julie Cornish, Ara W Darzi and Savas Papagrigroriadis, et al. "Meta-Analysis of Short-Term Outcomes of Randomized Controlled Trials of Ligasure vs Conventional Hemorrhoidectomy." *Arch Surg* 142 (2007): 1209-1218.
11. Sayfan, Joel, Alexander Becker, and Lev Koltun. "Sutureless Closed Hemorrhoidectomy: A New Technique." *Annals Surg* 234 (2001): 21.
12. McCarus, Steven D. "Physiologic Mechanism of the Ultrasonically Activated Scalpel." *J Amer Associat Gynecol Laparoscop* 3 (1996): 601-608.
13. Khanna, Rahul, Seema Khanna, Shilpi Bhadani and Sanjay Singh, et al. "Comparison of Ligasure Hemorrhoidectomy with Conventional Ferguson's Hemorrhoidectomy." *Ind J Surg* 72 (2010): 294-297.
14. GV, Ravi Kumar, BS Madhu, Vishal Tanga and Praveen M Pawar. "Harmonic Scalpel Compared with Conventional Open (Milligan-Morgan) Method in Surgical Management of Symptomatic Haemorrhoids." *Internat J Surg* 4 (2017): 2010-2013.
15. Abo-Hashem, AA, A Sarhan, and AM Aly. "Harmonic Scalpel® compared with bipolar electro-cautery hemorrhoidectomy: A randomized controlled trial." *Internat J Surg* 8 (2010): 243-247.
16. Sakr, MF and Mohamed M Moussa. "LigaSure Hemorrhoidectomy Versus Stapled Hemorrhoidopexy: A Prospective, Randomized Clinical Trial." *Dis Colon Rectum* 8 (2010):1161-1167.
17. Gentile, Maurizio, Michele De Rosa, V Pilone and F Mosella, et al. "Surgical Treatment for IV-Degree Hemorrhoids: Ligasure™ Hemorrhoidectomy vs. Conventional Diathermy. A Prospective, Randomized Trial." *Minerva Chirurgica* 66 (2011): 207-213.
18. Chung, CC, JPY Ha, YP Tai and WWC Tsang, et al. "Double-Blind, Randomized Trial Comparing Harmonic Scalpel™ Hemorrhoidectomy, Bipolar Scissors Hemorrhoidectomy, and Scissors Excision." *Dis Colon Rectum* 45 (2002): 789-794.
19. Bakhtiar, Nighat, Foad Ali Moosa, Farhat Jaleel and Naeem Akhtar Qureshi, et al. "Comparison of Hemorrhoidectomy by Ligasure with Conventional Milligan Morgan's Hemorrhoidectomy." *Pak J Med Sci* 32 (2016): 657.
20. Gentile, Maurizio, Michele De Rosa, Gabriele Carbone and Vincenzo Pilone, et al. "LigaSure Haemorrhoidectomy versus Conventional Diathermy for IV-Degree Haemorrhoids: Is it the Treatment of Choice? A Randomized, Clinical Trial." *ISRN Gastroenterol* (2011).

21. Armstrong, David N, Wayne L Ambroze, Marion E Schertzer and Guy R Orangi. "Harmonic Scalpel® vs. Electrocautery Hemorrhoidectomy: A Prospective Evaluation." *Dis Colon Rectum* 44 (2001): 558-564.
22. Talha, Ahmed, Samer Bessa, and Moataza Abdel Wahab. "Ligasure, Harmonic Scalpel versus Conventional Diathermy in Excisional Haemorrhoidectomy: A Randomized Controlled Trial." *ANZ J Surg* 87 (2017): 252-256.
23. Nienhuijs, Simon W, and Ignace HJT de Hingh. "Conventional versus LigaSure Hemorrhoidectomy for Patients with Symptomatic Hemorrhoids." *Cochrane Database Systemat Rev* 21 (2009): CD006761.

How to cite this article: Elhorbity, Mohamed Aly and Mohamed Ibrahim Mansour. "Efficacy of Harmonic US and LigaSure in Surgical Treatment of 3rd and 4th Degree Internal Hemorrhoids versus Conventional Hemorrhoidectomy". *J Surg* 16 (2020): 1. doi: 10.37421/jos.2020.16.1