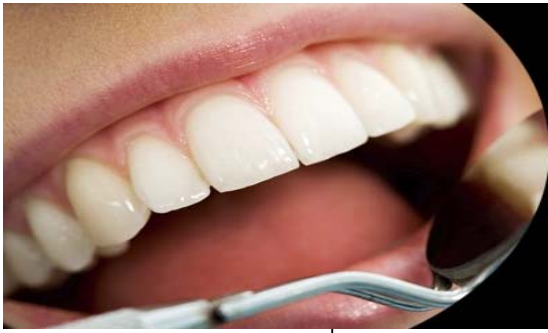



ISSN Print: 2394-7489
ISSN Online: 2394-7497
IJADS 2018; 4(4): 212-217
© 2018 IJADS
www.oraljournal.com
Received: 20-08-2018
Accepted: 21-09-2018

Dr. A Siddaraju
MDS, FOD (USA),
Associate Professor, GDCRI
Bangalore, Karnataka, India

Dr. Piyush Vatsa
MDS, Oral and Maxillofacial
Surgery, GDCRI, Bangalore,
Karnataka, India

A comparative clinical study on self-drilling screws and Erich arch bars in mandibular fractures

Dr. Piyush Vatsa and Dr. A Siddaraju

Abstract

Purpose: Intermaxillary fixation (IMF) is routinely done in the treatment of the patients with maxillofacial injuries. Traditional methods like Erich arch bars and eyelet wires are most commonly used for achieving IMF. Since 1989, IMF using intraoral self-drilling IMF screws has been introduced for treatment of mandibular fractures. The aim of this study was to compare the efficacy and potential complications associated with Self-drill IMF screws v/s Erich arch bars in the management of mandibular fractures.

Methods: After obtaining consent, the procedure were explained to the patient and each of the patients who met the inclusion criteria of the present study were randomly selected. Preoperatively all required investigations were done, fitness opinion for surgery was obtained and surgical procedure was carried out under local anaesthesia. The parameters considered were duration of the procedure, potential complications, stability of the fixation devices, oral hygiene status and patient acceptance during IMF with Self-drill IMF screws and Erich arch bars.

Keywords: self-drilling screws, Erich arch bars, mandibular fractures

Introduction

Maxillomandibular fixation (MMF) is a basic and fundamental principle in the management and treatment of the maxillofacial trauma patient. MMF serves as a cornerstone of maxillofacial reconstruction, providing a stable base from which facial form and function can be restored [1] The arch bar has been the mainstay for the management of maxillo-mandibular bony injuries since World War I [2]. The originators of this method, Sauer in Germany and Gilmer in the United States used an ordinary round bar that was ligated to the teeth with brass ligature wires. Blair and Ivy's modification was a bar flattened on one side that was about 2 mm in width to conform better to the teeth and provide greater stability [2] The successful treatment of mandibular fractures depends on fracture site reduction, restoration of normal masticatory jaw stability, and obtaining normal dental occlusion. In the open reduction and internal fixation of mandibular fractures, arch bars (such as Erich arch bars) can be used for placing the patient in temporary maxillomandibular fixation (MMF); hence, ensuring proper dental occlusion before fracture reduction. The application of arch bars with the requisite passage of circumdental wires, increases the chance of skin punctures and of blood-borne disease transmission [3] This can increase the risk of immunodeficiency virus (HIV) and hepatitis B virus (HBV) transmission to the surgeon. The use of intraoral cortical bone screw fixation (ICBSF), as an alternative to arch bars in achieving MMF, has been described as a definitive treatment modality for mandibular fracture repair. The described advantages of ICBSF over traditional arch bar placement include:

1. Decreased risk of percutaneous wire and mucosal punctures and disease transmission risk to surgeon and patient alike.
2. Significant intraoperative savings in time and cost. ICBSF can be placed and removed in less than 15 minutes, whereas arch placement can take 45 to 100 minutes for placement and removal.
3. Ease of application with acceptable proper occlusion attainment [3]

Rowe and Killey originally had the opinion that the period of immobilization should be four weeks in children, six in adults, and eight weeks in the elderly [12]

Killey's texts advocated a shorter immobilization period: 3-4 weeks for children, five weeks

Correspondence
Dr. Piyush Vatsa
MDS, Oral and Maxillofacial
Surgery, GDCRI, Bangalore,
Karnataka, India

for adults, and 6-7 weeks for older patients^[13]

Different methods have been used for intermaxillary fixation including custom-made arch bars, eyelet wires, and Schuchardt arch-shaped splints made of metal and acrylic (Schuchardt and Metz 1966). Wires tightened during the application of arch bars around the teeth may cause Ischemic necrosis of the mucosa and the periodontal membrane and if damage is extensive, tooth loss may result (Wilson and Hohmann 1976). Recently, self-tapping IMF screws have been advocated for intermaxillary fixation (Jones 1999). Self-tapping /self-drilling IMF screws are quick and easy to use and greatly shorten the operating time to achieve maxillomandibular fixation.

They are relatively inexpensive and reduce the risk of needle stick type injuries associated with wires. There is also no trauma to gingival margins and gingival health is easier to maintain as compared to arch bars or eyelets.

Therefore the present study aims to compare the two methods of IMF namely, Self-Drilling screws and Erich arch bar, with each other.

Materials and Methods

Study Design: The study design will be a prospective clinical study. Forty patients will be divided into Two Groups of twenty patients in each group: -

Group A- Self Drilling Screws used.

Group B- Erich Arch Bars used.

Sampling Method: Convenient sampling method will be used to select the sample group as per the inclusion and exclusion criteria after obtaining the required consent.

Sample Size: in our study we will take a sample size of 40 cases.

Method of Study

Preoperative evaluation

The clinical evaluation considering the age, sex, facial symmetry, integrity of mandibular arch form, degree of mobility of fractured ends, movements of mandible, and occlusion was conducted before the surgery. The pre-operative panoramic radiographs were used to confirm the isolated fracture, to locate the site of fracture and for post-operative comparison.

Surgical procedure

After obtaining consent, the procedures were explained to the patient and each of the patients who met the above said criteria were randomly selected. Preoperatively all required investigations were done, fitness opinion for surgery was obtained.

Surgical technique in fixation of Self Drilling screws

Procedure was done under all aseptic precautions. All the patients were injected with 2% lignocaine hydrochloride with adrenaline in 1:100,000 concentrations (Biocaine-ADR 2%) for full mouth block. Self -drilling IMF screws of 2mm diameter and 12-14 mm were placed after drilling a hole using a 1.5 mm drill bit at the junction of attached mucosa and reflected mucosa with one screw in each quadrant. Stability was checked and 26 gauge stainless steel wire was inserted through the cross holes provided in the screws and occlusion was established. Maxillo mandibular fixation was attained by tightening the wire by twisting the wire.

Surgical technique in fixation of Erich's arch bar

Procedure was done under all aseptic precautions. All the patients were injected with 2% lignocaine hydrochloride with adrenaline in 1:100,000 concentrations (Biocaine-ADR 2%) for full mouth block. Patients received inter-maxillary fixation with arch bars, using "Dentaurum" Erich arch bars and 26 gauge stainless steel wire. Arch bar should be cut to the required length and bent to the correct shape before starting the operation. 26 gauge pre stretched 18-8 stainless steel was taken. Arch bar was placed in position, upper bars hook should be facing up and lower bars hook should be facing down and secured in position by wiring it to the necks of the tooth from 1st molar to 1st molar in both arches. Wiring is done in such a way that, the wire is passed from the mesial surface of the tooth to lingual side and back on the buccal side from distal surface of the tooth, one end of wire is above the bar and one end is below. Each wire passed over the bar mesially, around the tooth, and under the bar distally, before the ends were twisted together in clockwise direction so bar is attached securely and firmly to the neck of teeth on buccal surface of arch. Inter maxillary fixation was attained by elastics or wiring.

Clinical Evaluation

Post-operative follow ups were done at 1 week, after 2 weeks and after 4 weeks. During the follow up visits again the clinical evaluation was conducted considering iatrogenic injury to adjacent teeth, the wound healing, presence/ absence of mobility at the fractured ends, integrity of mandibular arch form, occlusion, stability of the devices and patient oral hygiene graded as good, fair and poor.

Self-drill IMF screws and Erich arch bar were retrieved after 4th post-operative week in the out patient department under local anaesthesia.

Results

Frequency distribution among study group; 20 with self-drill screws (50%) and 20 with Erich arch bar (50%). Mean age distribution among study group ranging between 18 to 55 years with a mean age of 32.4 ± 10.770 for Erich arch bar and 18 to 54 years with a mean age of 31.0 ± 13.129 for Self-drill screws. Gender distribution among group A and group B patients; 17 were male (85%) and 3 were female (15%) in Erich arch bar group and 12 were male (60%) and 8 were female (40%) in Self-drill screws group. Distribution of isolated mandibular fractures sites among study group; 5 were at angle (12.5%), 5 were at body (12.5%), 5 were at para symphysis (12.5%), 4 were at angle and para symphysis (10.0%), 4 were at body and condyle (10.0%), 4 were at condyle (10.0%), 4 were at condyle and para symphysis (10.0%), 4 were at subcondylar and para symphysis (10.0%), 2 were body and angle (5.0%), 2 were at symphysis (5%) and 1 at body and para symphysis (2.5%). Time taken to perform the procedure between two study groups; the time taken ranged from 90 to 110 min with mean time of 102.8 min for Erich arch bar group and 20 to 30 min with mean time of 22.5 min for Self-drill screws group. Iatrogenic injury to the patients between two study groups- 3 root perforation injury seen in self-drill screws group (15%) and no iatrogenic injury seen in Erich arch bar group (0.0%). Stability of the fixation devices between two study groups- Self-drill screws and Erich arch bars were checked for stability after first post-operative week and forth post-operative week. The stability was adequate in both the groups after first post-operative (100%). After forth post-operative week; in self-drill screws group,

stability was adequate in 70% of the patients and inadequate in 30% of the patients while in Erich arch bars group, stability was adequate in 80% of the patients and inadequate in 20% of the patients. Oral hygiene status of patients pre and post operatively- in Erich arch bar group, 11 patients were with poor oral hygiene (55.0%) and 9 patients were with fair oral hygiene (45%) while in Self-drill screws group, 7 patients were with poor oral hygiene (35%) and 13 patients were with fair oral hygiene (65%), pre operatively. Post-operatively, in Erich arch bar group, 12 patients had fair oral hygiene (60%) and 8 patients had good oral hygiene (40%) while in Self-drill screws group, 5 patients had fair oral hygiene (25%) and 15 patients had good oral hygiene (75%).

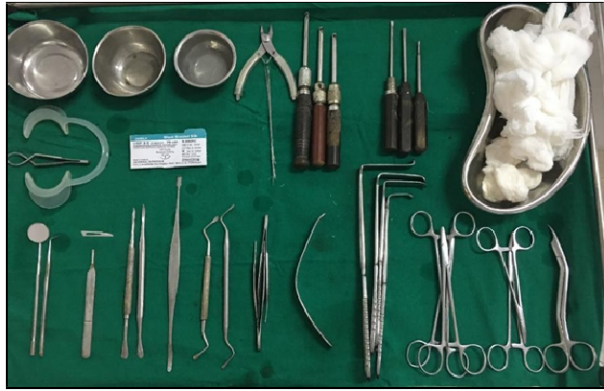

Fig 1: Armamentarium For Inter Maxillary Fixation




Fig 2: Self Drilling Screws



Fig 3: Erich Arch Bar

Case 1

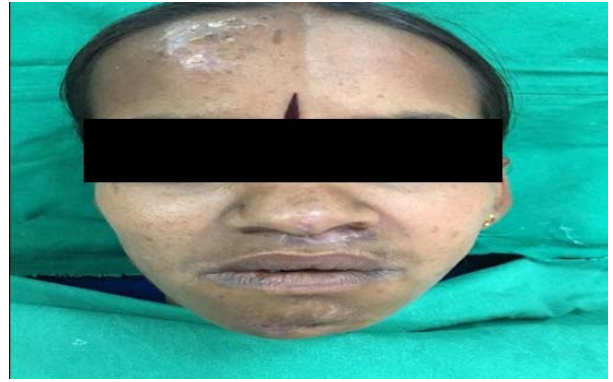


Fig 4: Shows Pre -Operative Facial Profile.

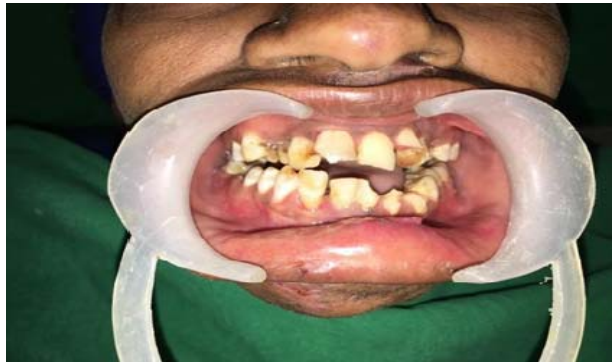

Fig 5: Pre-Op Right Parasymphysis and Left Condyle Fracture

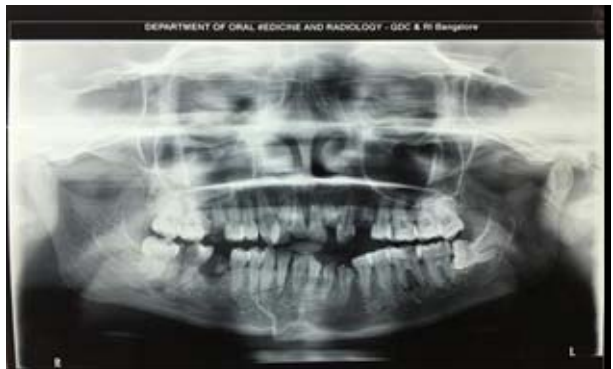

Fig 6: Pre-Op Opg

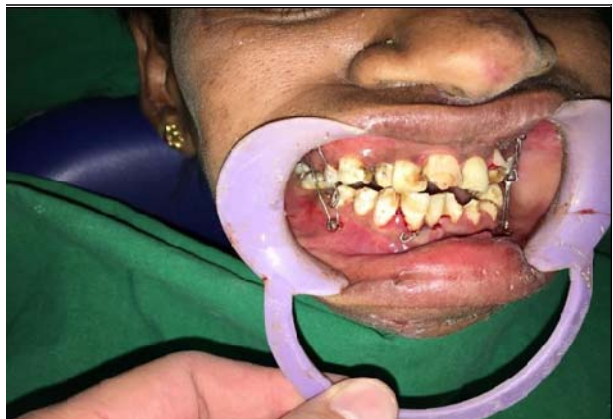

Fig 7: Post-Operative Placement Of Self Drilling Screws

Case-2

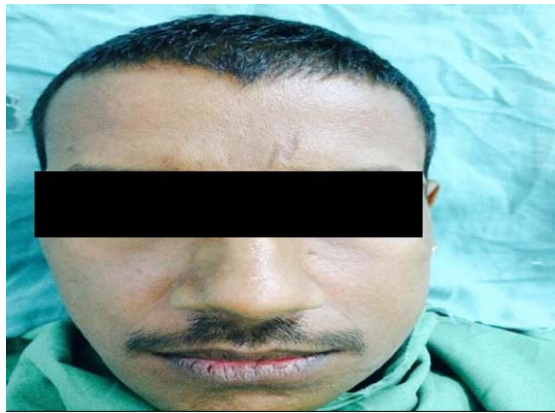

Fig 8: Shows Pre -Operative Facial Profile

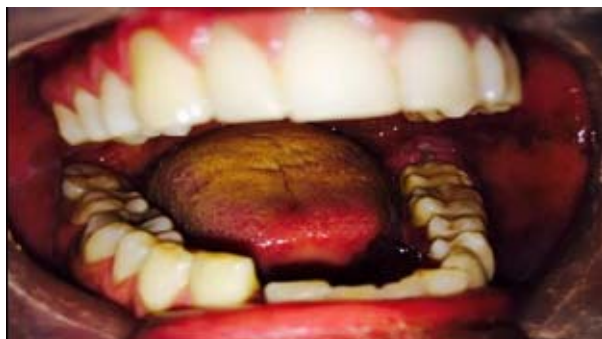

Fig 9: Pre-Op Right Parasymphysis Fracture And Left Angle Fracture

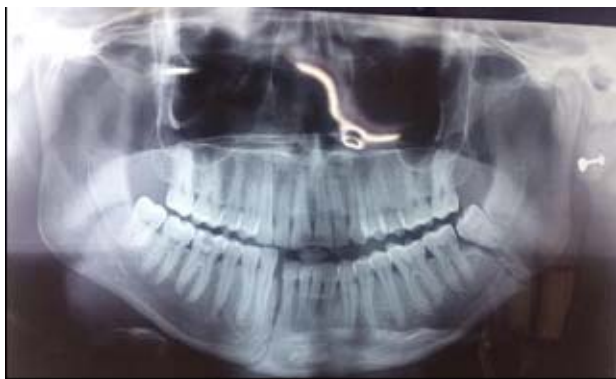

Fig 10: Pre-op OPG

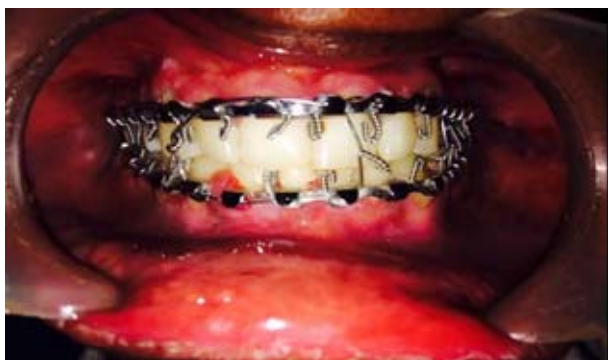

Fig 11: Post-Operative Placement of Erich Arch Bar

Case-3

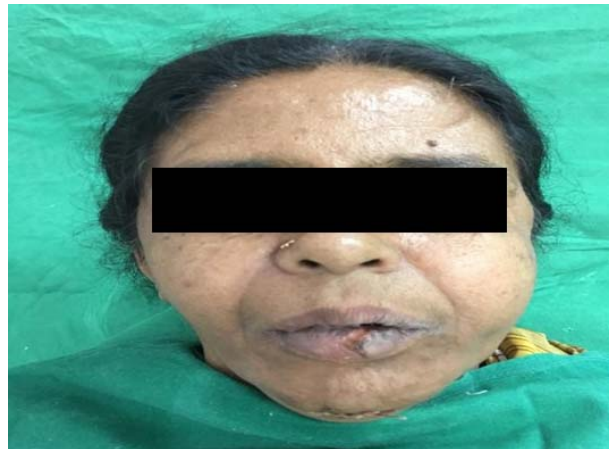

Fig 12: Shows Pre -Operative Facial Profile.

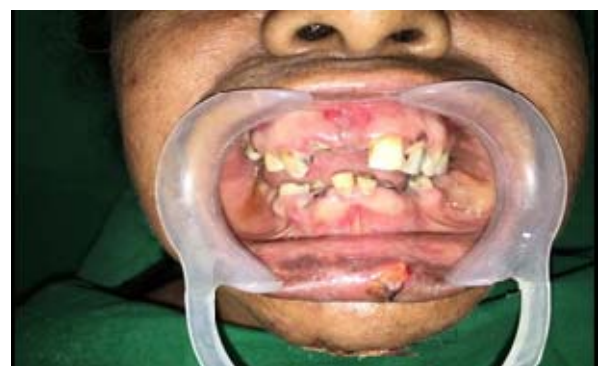

Fig 13: Pre-Op Left Angle and Bilateral Condylar Fracture

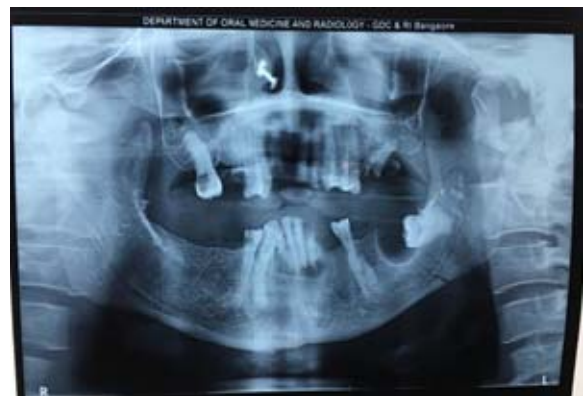

Fig 14: Pre-Op Opg

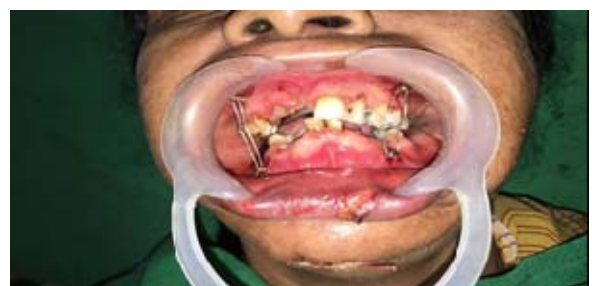

Fig 15: post-operative placement of self-drilling screws

Case 4

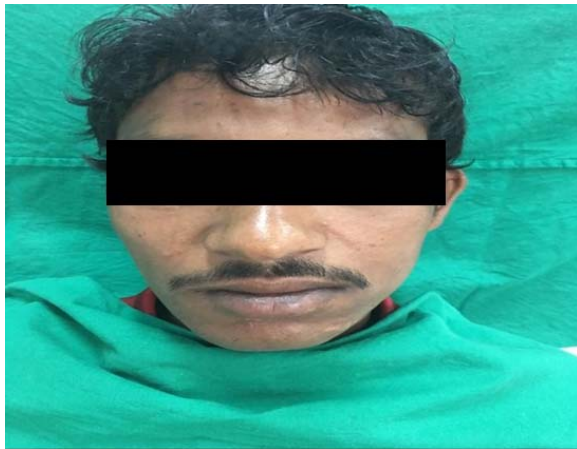

Fig 16: Shows Pre -Operative Facial Profile.

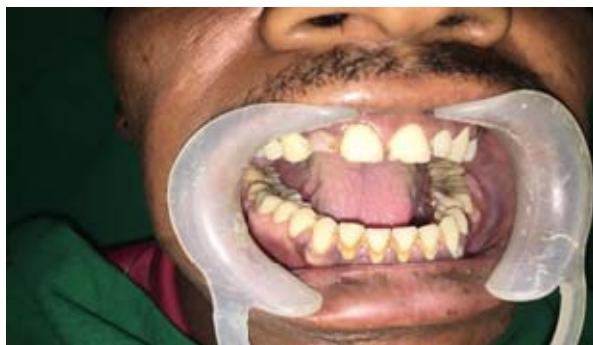

Fig 17: Pre-Op Left Angle and Right Para Symphysis Fracture

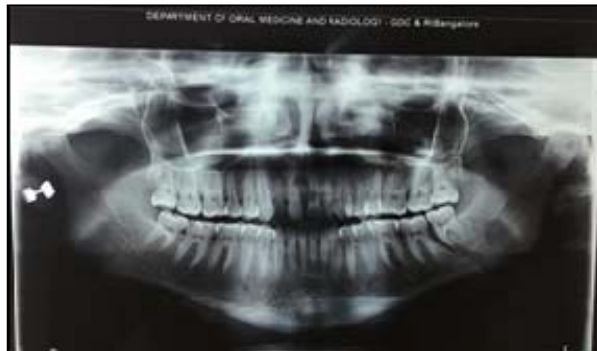

Fig 18: PRE-OP OPG

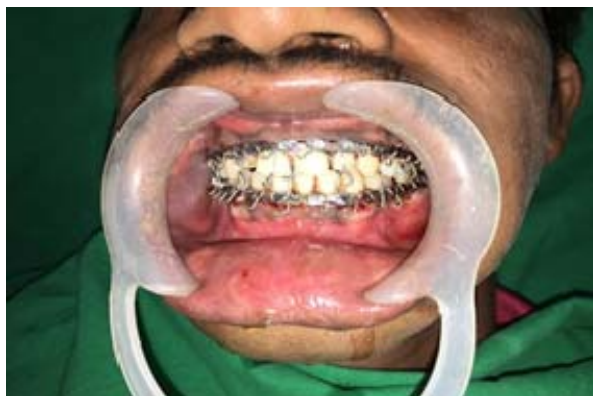

Fig 19: Post-Operative Placement of Erich Arch Bar



Fig 20: Showing Major Contact Of The Root With Screw Hole



Fig 21: Showing Minor Contact Of The Root With Screw Hole



Fig 22: Showing Minor Contact of The Root With Screw Hole

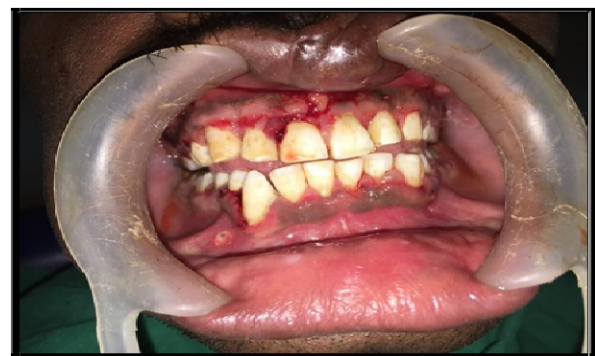

Fig 23: Showing Malocclusion In Self Drill Screws Patient After Removal

Conclusion

The application of arch bars and insertion of wires in the interdental spaces increase the chance of accidental skin puncture, hence increasing the chance of transmission of HIV and viral hepatitis. Intermaxillary fixation with Self-drill IMF screws is safe and effective method as compared to the conventional Erich arch bars in the treatment of mandibular fractures. Although both the techniques offer- good temporary intermaxillary fixation to check occlusion and postoperatively for intermaxillary fixation, Self- drill IMF screws reduces the operating time (Mean time taken - 22.5 min). Maintenance of

oral hygiene and patient acceptance was good with IMF screws as compared to arch bar. The results of this study shows it is advantageous to use Self-drilling IMF screws for treatment of mandibular fractures and extend it to the treatment of other facial fractures.

References

- Coletti DP, Salama A, Caccamese JF. Application of maxillomandibular fixation screws in maxillofacial trauma. *J Oral Maxillofac surg.* 2007; 65:1746.
- Baurmash H, Farr D, Baurmash M. Direct bonding of Arch bars in the management of maxilla mandibular injuries. *J Oral Maxillofac surg.* 1988; 46:813-815.
- Vartanian AJ, Alvi A. Bone screw mandible fixation: an intraoperative alternative to arch bars. *Otolaryngol Head Neck surg.* 2000; 123:718-721.
- Arthur G, Berardo N. A simplified technique of maxillomandibular fixation. *J Oral Maxillofac Surg.* 1989; 47(11):1234.
- Stevan K, Gibbons A. Care in the placement of bicortical intermaxillary fixation screws. *Br J Oral Maxillofac Surg.* 2001; 39(6):484
- Coburn DG, Kennedy DWG, Hodder SC. Complications with maxillomandibular fixation screws in the management of fractured mandibles. *Br J Oral Maxillofac Surg.* 2002; 40:241.
- Poggio PM, Incorvati C, Velo S, Carano A. "Safe Zones" : a guide for miniscrew positioning in the maxillary and mandibular arch. *Angle Orthod.* 2006; 76(2):191-197
- Roccia F, Rossi P, Gallesio C, *et al*: Self tapping and Self drilling screws for maxillomandibular fixation in management of mandibular fractures. *J Craniofac Surg.* 2009; 20:68,
- Gustav O. Kruger. *Oral & Maxillofacial Surgery.* Mosby, 1984.
- Ivy RH, Curtis L. Fractures of mandible: an analysis of one hundred cases. *Dental Cosmos.* 1926; 68:439
- Haug RH, Prather J, Indresano AT. An epidemiologic survey of facial fractures and concomitant injuries. *J Oral Maxillofac Surg.* 1990; 48:926-932
- Rowe NL, Killey H. *Fractures of the Facial Skeleton*, 2nd ed. Baltimore, Williams & Wilkins, 1968, 74
- Killey HC. *Fractures of the Mandible.* Bristol, John Wright, 1967, 53
- Kruger GO. *Textbook of Oral and Maxillofacial Surgery*, 5th ed. St. Louis, CV Mosby, 1979, 397
- Ellis E. 3rd: Treatment methods for fractures of the mandibular angle. *Int J Oral Maxillofac Surg* 1999; 28:243.
- Michelet FX, Deymes J, Dessus B. Osteosynthesis with miniaturized screwed plates in maxillo-facial surgery. *J Maxillofac Surg.* 1973; 1:79.
- Champy M, Lodde JP, Schmitt R, *et al*: Mandibular osteosynthesis by miniature screwed plates via a buccal approach. *J Oral Maxillofac Surg.* 1978; 6:14.
- Chacon GE, Larson PE. Principles of management of mandibular fractures, in Miloro M, Ghali GE, Larsen PE, *et al.* Peterson's Principles of Oral and Maxillofacial Surgery (2nd ed) Hamilton, BC Decker Inc, 2004, 401-431
- Fordyce AM, Hildreth AJ, Carton AT, *et al*: Intermaxillary fixation is not usually necessary to reduce mandibular fractures. *Br J Oral Maxillofac Surg.* 1999; 37:52.
- Dimitroulis G. Management of fractured mandibles without the use of intermaxillary wire fixation. *J Oral Maxillofac Surg.* 2002; 60:1435,
- Gear AJ, Apasova E, Schmitz JP, *et al*: Treatment modalities for mandibular angle fractures. *J Oral Maxillofac Surg.* 2005; 63:655.
- Raymond J Fonseca, Walker RV. editors. *Oral & Maxillofacial Trauma.* WB Saunders, 2013, 293-330
- Walter A Petrysyn. Flemington. The fractured mandible. A Method of treatment for otolaryngologist. *Laryngoscope* 1960; 1060:1109.
- Bradley JC. A radiologic investigation into the age changes of the inferior dental artery. *Br J Oral Maxillofac Surg.* 1975; 13:82
- Bruce RA, Strachen DS. Fractures of the edentulous mandible. Chalmers J Lyons Academy Study. *Oral surgery* 1976; 43:973
- Tateyuki Iizuka, Christian Lindqvist. Sensory disturbances associated with rigid internal fixation of mandibular fractures. *J Oral Maxillofac Surg:* 1991; 49:1264-1268
- Laskin DM. The role of meniscus in etiology of post traumatic temporomandibular joint Ankyloses. *Int J. Oral surg.* 1978; 7:340
- Win S, Handa Y, Ichihara H, Tatematsu N. Intermaxillary fixation using screws. *Int J Oral Maxillofac surg.* 1991; 20:283-284
- Roccia F, Rossi P, Gallesio C, Boffano P. Self-tapping and self-drilling screws for intermaxillary fixation in management of mandibular fractures. *J Craniofac surg* 2009; 20:68-70
- Kyle F, Gordon, Mark Reed. Results of intraoral cortical bone screw fixation technique for mandibular fractures. *Otolaryngol Head Neck Surg.* 1995; 113:248-52
- Richard F. Busch. Maxillomandibular fixation with intraoral cortical bone screws: A 2-year experience. *Laryngoscope* 104: august 1994, 1048-1050
- Jones DC. The intermaxillary screw: a dedicated bicortical bone screw for temporary intermaxillary fixation. *British J Oral Maxillofac surg.* 1999; 37:115-116
- Holmes S, Hutchison I. Caution in use of bicortical intermaxillary fixation screws. *Br J Oral Maxillofac surg.* 2000; 38(5):574
- Majumdar A. Iatrogenic injury caused by intermaxillary fixation screws. *Br J Oral Maxillofac surg.* 2002; 40(1):84-88
- Busch RF, Prunes F. Intermaxillary fixation with intraoral cortical bone screws. *Laryngoscope.* 1991; 101:1336-1338
- Lello JL, Lello GE. The effect of interdental continuous loop wire splinting and intermaxillary fixation on the marginal gingiva. *Int. J. Oral Maxillofac surg.* 1988; 17:249-252
- Roccia F, Tivolaccini A, Dell'Acqua A. *et al*: An audit of mandibular fractures treated by intermaxillary fixation using intraoral cortical bone screws. *J Craniofac Surg.* 2005; 33:251,
- Schneider AM, David LR, DeFranzo AJ, *et al*: Use of specialized bone screws for intermaxillary fixation. *Ann Plast Surg.* 2000; 44:154