

It's time for...



## Intraoral Radiographic Anatomy

Steven R. Singer, DDS  
212.305.5674  
srs2@columbia.edu



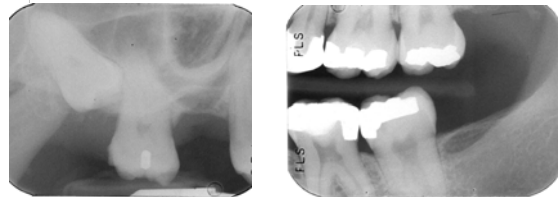
"Alas, poor Yorick!"

## Radiographic Contrast



- ◆ The difference in densities between adjacent areas of the image
- ◆ Influenced by:
  - Subject contrast
  - Film contrast
  - Beam energy and intensity
  - Fog and scatter radiation

## Radiographic Contrast



## Radiographic Contrast

- ◆ By adjusting kVp, contrast can be varied
  - **High contrast films** can enhance detection of lesions where subject contrast between the lesion and healthy tissue is low
  - Examples include:
    - ◆ Caries
    - ◆ Apical lucencies

## Radiographic Contrast

- ◆ By adjusting kVp, contrast can be varied
  - **Low contrast films** can enhance detection of subtle findings.
  - Examples include:
    - ◆ Calculus
    - ◆ Soft tissue outlines
    - ◆ Small changes in crestal bone

## Radiographic Density


- ◆ The overall degree of darkening of the radiographic image. Three factors which determine radiographic density are:
  - Exposure
  - Subject thickness
  - Object density

## Radiographic Density

- ◆ Exposure
  - Determines the # of photons that are absorbed by the emulsion
  - Four exposure factors
    - kVp
    - ma
    - Impulses (time)
    - Source to film distance

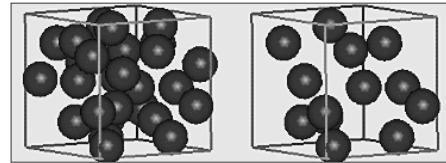
## Radiographic Density

- ◆ Subject thickness



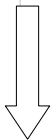
## Radiographic Density

- ◆ **Object Density.** The denser the object and higher the atomic #, the better the absorption of photons.



## Radiographic Density

- ◆ In decreasing order of density:
  - Metallic restorations
  - Enamel
  - Dentin
  - Bone
  - Fat/fluid
  - Air



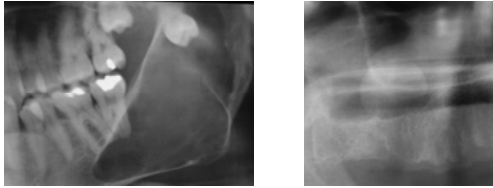
## Subject Contrast

- ◆ Influenced by:
  - Thickness
  - Density
  - Atomic #



- ◆ Relatively **large** differences in Subject Contrast of oral structures allow the image to be seen

## Subject Contrast




## Definitions





- ◆ **Radiodensity:** The degree to which the subject attenuates the x-ray beam
- ◆ **Radiopacity:** An area of the image where the beam has been relatively highly attenuated
- ◆ **Radiolucency:** An area of the image where the beam has been relatively minimally attenuated

## Radiolucencies

- ◆ Marrow spaces
- ◆ Foramina
- ◆ Canals (N.B. the walls of the canal are opaque)
- ◆ Fissures
- ◆ Fossae
- ◆ Meati
- ◆ Sinuses
- ◆ Sutures
- ◆ Dental pulp

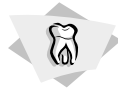

## Radiopacities

- |   |   |  |   |
|---|---|--|---|
| <p><b>Bone</b></p> <ul style="list-style-type: none"> <li>◆ Condyles</li> <li>◆ Eminences</li> <li>◆ Processes</li> <li>◆ Tuberosities</li> <li>◆ Walls of canals</li> <li>◆ Tubercles</li> <li>◆ Ridges</li> <li>◆ Trabeculae</li> </ul> |  | <p><b>Teeth</b></p> <ul style="list-style-type: none"> <li>◆ Enamel</li> <li>◆ Dentin</li> <li>◆ Cementum</li> </ul> |  |
|---|---|--|---|

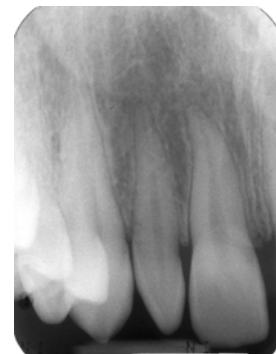## The Teeth

- |  |  |
|--|--|
| <ul style="list-style-type: none"> <li>◆ Enamel</li> <li>◆ Dentin</li> <li>◆ Cementum</li> <li>◆ Pulp</li> </ul> | <ul style="list-style-type: none"> <li>90% mineralized</li> <li>75% mineralized</li> <li>50% mineralized</li> <li>Soft tissue</li> </ul> |
|--|--|



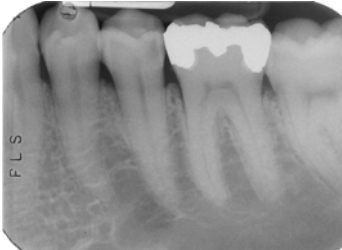## The Teeth

- ◆ Enamel
- ◆ Dentin
- ◆ Pulp



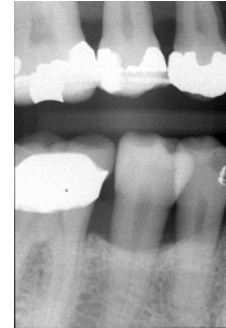## The Teeth

- ◆ Cervical burnout



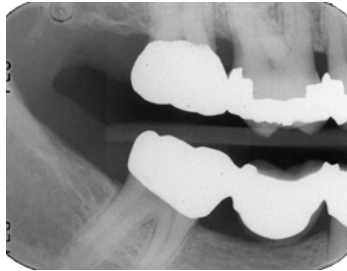
## The Teeth

- ◆ Concavities



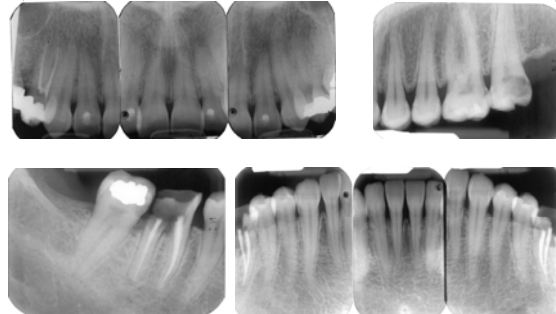
## The Teeth

- ◆ Fluting of root surfaces

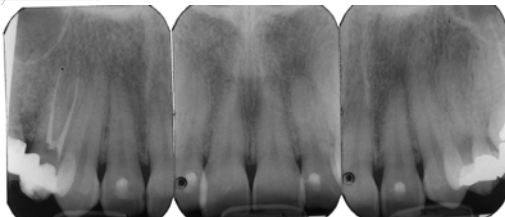


## Supporting Structures of the Teeth

- ◆ Trabecular bone

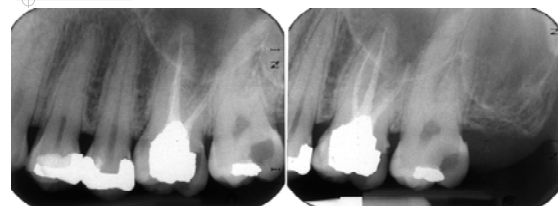

## Bone in the Anterior Maxilla



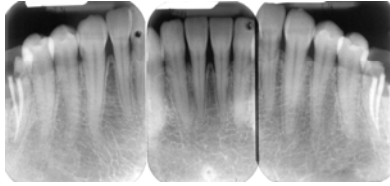
- ◆ Trabeculae are thin and numerous
- ◆ Small marrow spaces

## Bone in the Posterior Maxilla



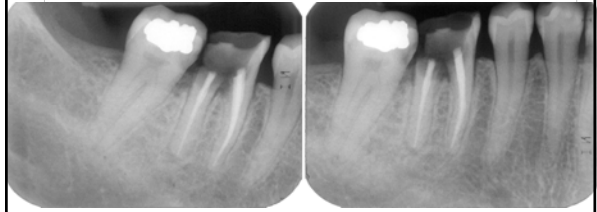
- ◆ Similar pattern to anterior maxilla
- ◆ Slightly larger marrow spaces

### Bone in the Anterior Mandible



- ◆ Trabeculae are somewhat thicker than in the maxilla
- ◆ Plates are in a horizontal pattern

### Bone in the Posterior Mandible



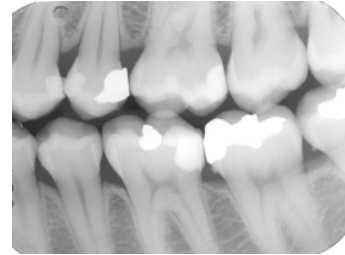
- ◆ Horizontal Plates
- ◆ Larger marrow spaces than anterior mandible

### Supporting Structures of the Teeth



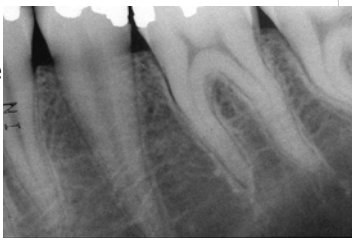### Supporting Structures of the Teeth

- ◆ Crestal bone



### Supporting Structures of the Teeth

- ◆ Lamina dura
- ◆ Periodontal ligament space




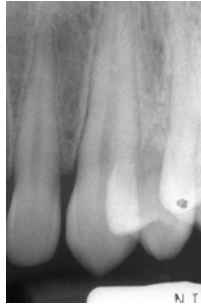
### Supporting Structures of the Teeth



The joint between the tooth and the bone is a **gomphosis**. The periodontal ligament allows for movement around a center of rotation.

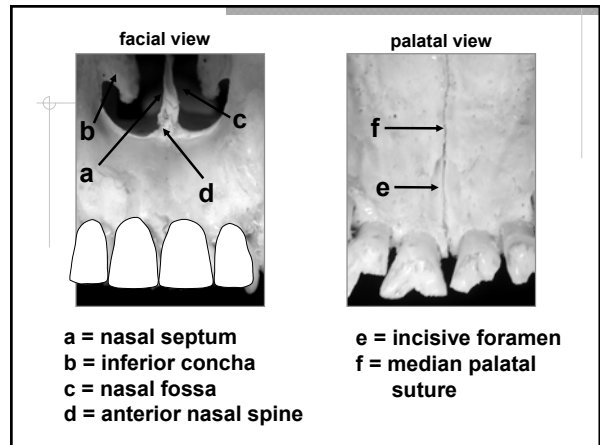
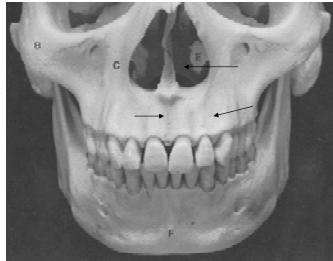
## Supporting Structures of the Teeth

- ◆ Lamina dura and PDL



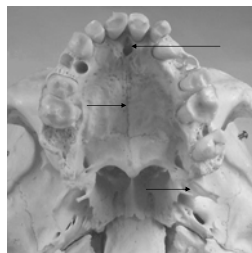
## Landmarks in the Maxilla

- ◆ Intermaxillary suture
- ◆ Nasal Fossa
- ◆ Nose
- ◆ Lateral fossa



## Landmarks in the Maxilla

- ◆ Incisive foramen
- ◆ Median palatine suture
- ◆ Pterygoid plates

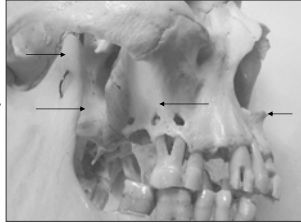


## Pterodactyl gr. *pteron*, wing



## Landmarks in the Maxilla

- ◆ Anterior nasal spine
- ◆ Zygomatic process
- ◆ Pterygoid plates
- ◆ Coronoid process of the **mandible**
- ◆ Nasolabial fold



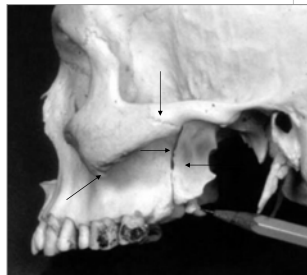
## Coronoid Process

- ◆ From the Greek word for "Crow's Beak"

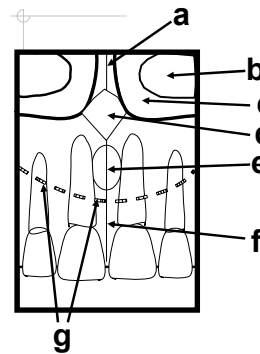


## Landmarks in the Maxilla

- ◆ Lateral pterygoid plate
- ◆ Pterygo-maxillary fissure
- ◆ Zygomatico-temporal suture
- ◆ Zygomatic process of the maxilla

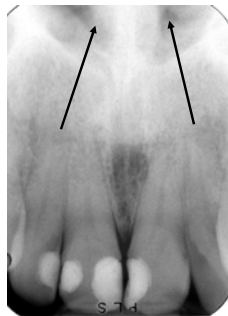
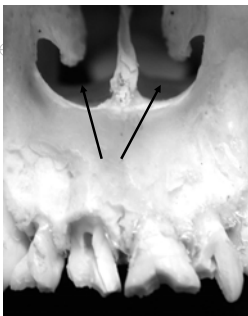
## Maxillary Incisor



- a = nasal septum
- b = inferior concha
- c = nasal fossa
- d = anterior nasal spine
- e = incisive foramen
- f = intermaxillary suture
- g = soft tissue of nose

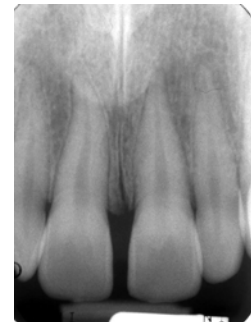
facial view



Nasal fossa

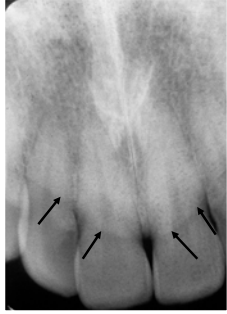
## Landmarks in the Maxilla

- ◆ Intermaxillary suture
- ◆ Soft tissue of the nose
- ◆ Incisive foramen



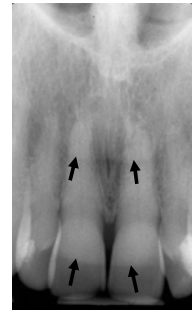### Landmarks in the Maxilla

- ◆ Soft tissue of the nose



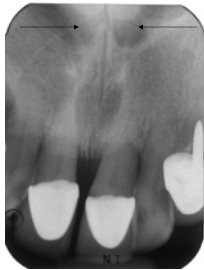### Landmarks in the Maxilla

- ◆ The red arrows point to the soft tissue of the nose. The green arrows identify the lip line.



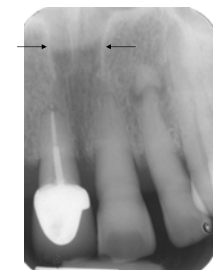
### Landmarks in the Maxilla

- ◆ Foramina of von Ebner



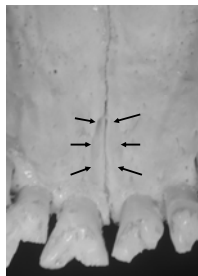
### Landmarks in the Maxilla

- ◆ Nasopalatine canal



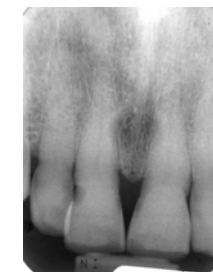### Landmarks in the Maxilla

- ◆ Incisive foramen

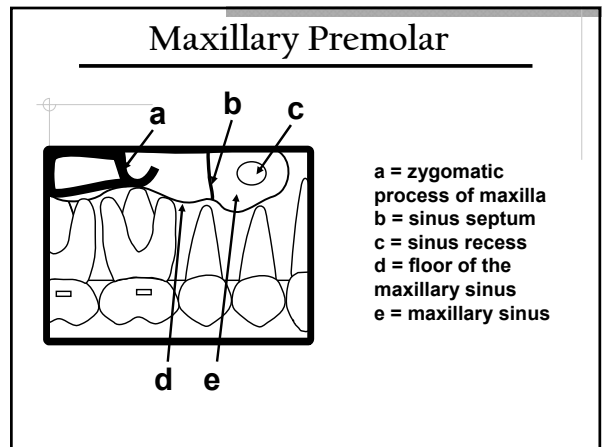
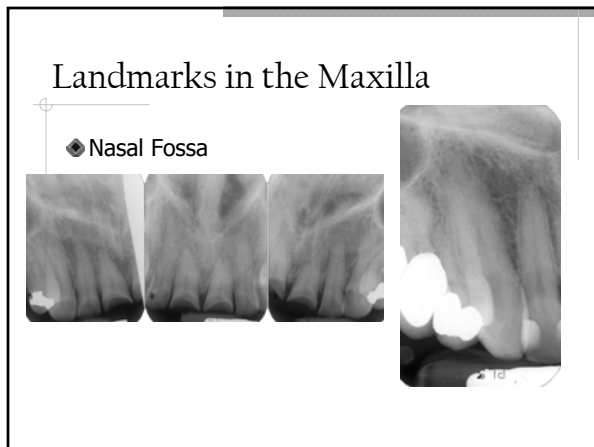
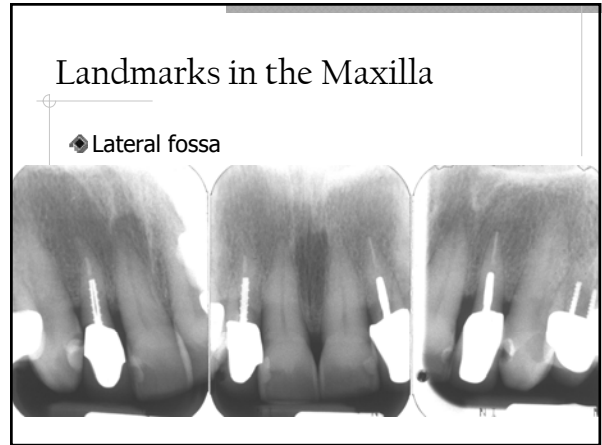
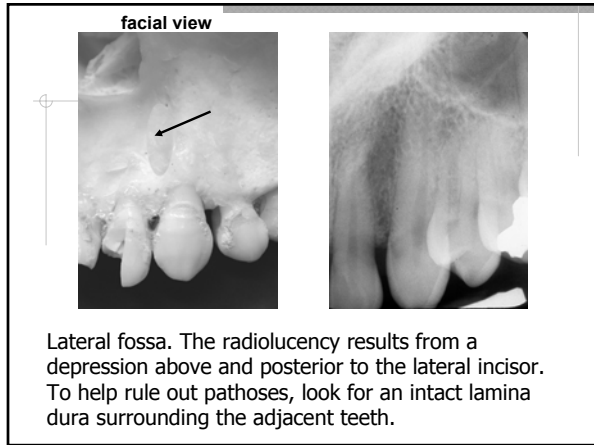
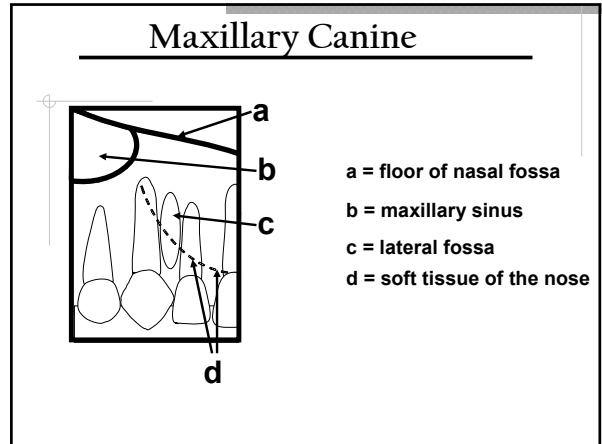
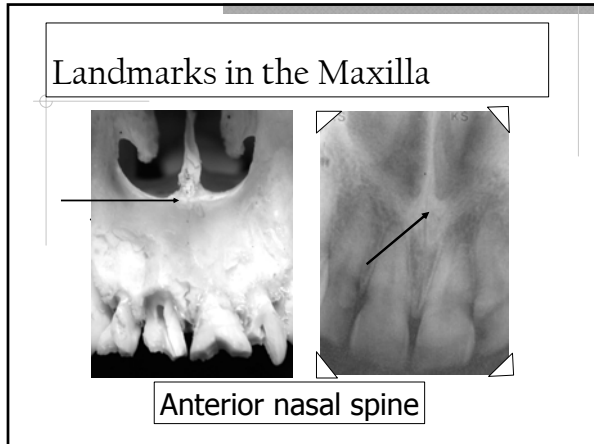


### Landmarks in the Maxilla

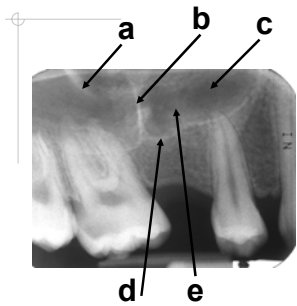
- ◆ Incisive foramen





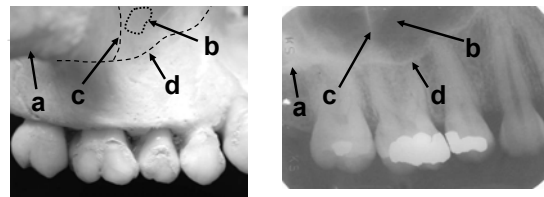


## Maxillary Premolar



a = zygomatic process of maxilla  
 b = sinus septum  
 c = sinus recess  
 d = floor of the maxillary sinus  
 e = maxillary sinus

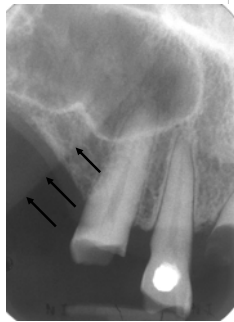
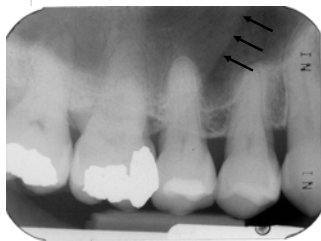
facial view



a = zygomatic process  
 b = sinus recess  
 c = sinus septum  
 d = floor of the maxillary sinus

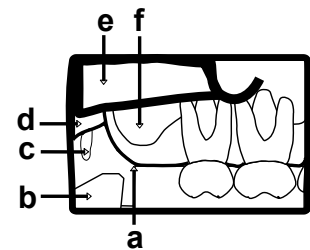
## Landmarks in the Maxilla

◆ Nasolabial fold



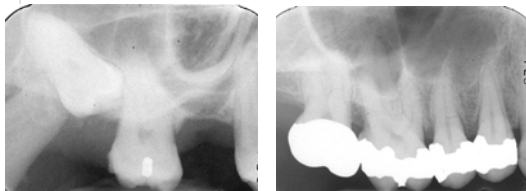
## Maxillary Molar

a = maxillary tuberosity  
 b = coronoid process  
 c = hamular process  
 d = pterygoid plates  
 e = zygoma  
 f = maxillary sinus



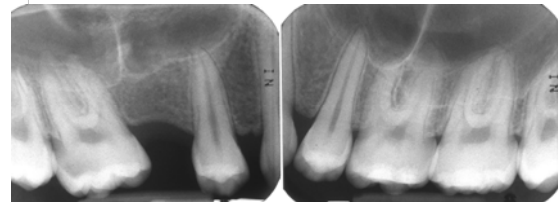
## Landmarks in the Maxilla

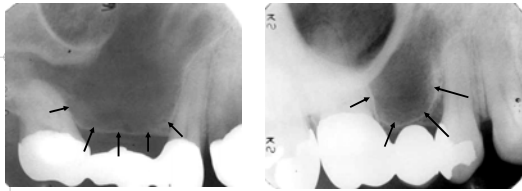
◆ Zygomatic Process and Maxillary Sinus



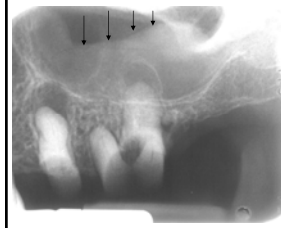## Landmarks in the Maxilla

◆ Zygomatic Process and Maxillary Sinus

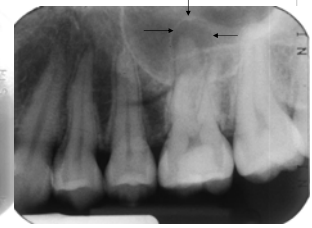



**Pneumatization.** From the Latin "filled with air" Expansion of sinus wall into surrounding bone, usually in areas where teeth have been lost prematurely. Increases with age.



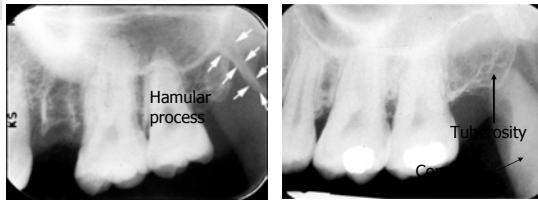
Mucositis



Halo effect

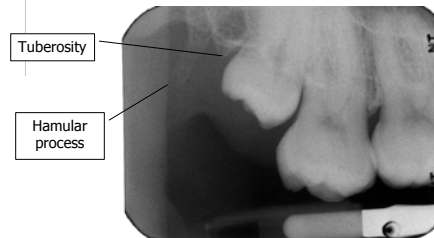
### Landmarks in the Maxilla

- ◆ Maxillary tuberosity
- ◆ Coronoid process of the mandible
- ◆ Hamular process

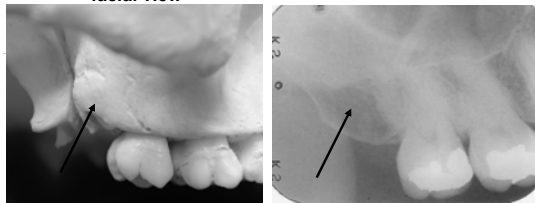


### Landmarks in the Maxilla

- ◆ Hamular process



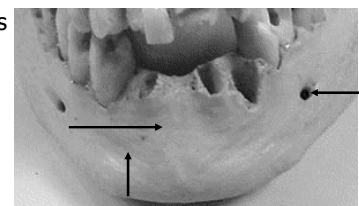
### facial view



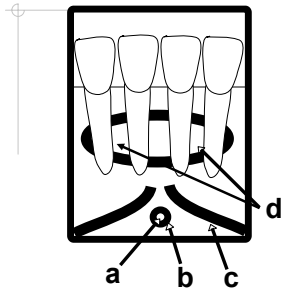
**Maxillary Tuberosity.** The rounded elevation located at the posterior aspect of both sides of the maxilla.

### Landmarks in the Mandible

- ◆ Mental ridges
- ◆ Mental foramen
- ◆ Mental fossa




## Mandibular Incisor



- a. lingual foramen
- b. genial tubercles
- c. mental ridge
- d. mental fossa

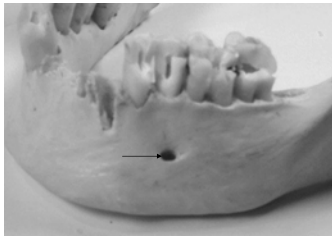
## The Thinker

Auguste Rodin, 1881



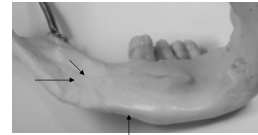
## Landmarks in the Mandible

- ◆ Mental foramen
- ◆ Inferior alveolar (Mandibular) canal



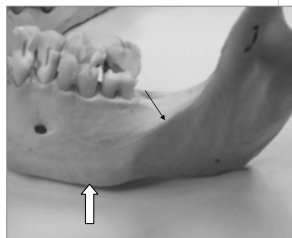
## Landmarks in the Mandible

- ◆ Mylohyoid (Internal oblique) ridge
- ◆ Submandibular gland fossa
- ◆ Inferior border of the mandible



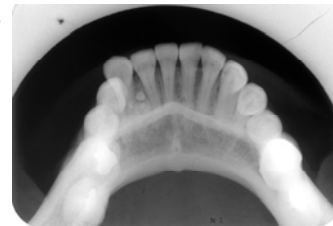
## Landmarks in the Mandible

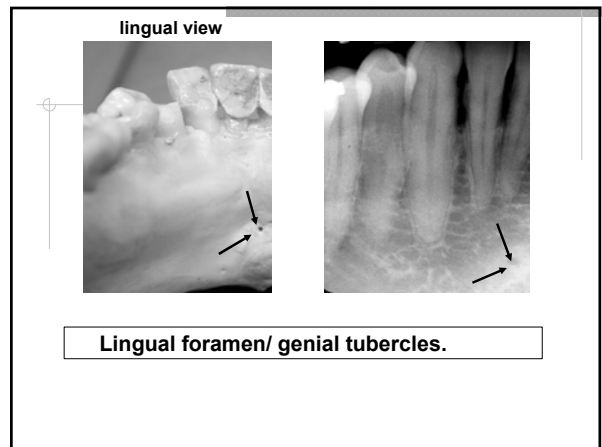
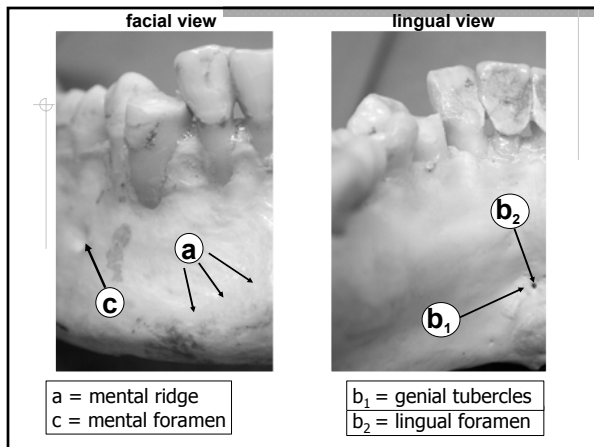
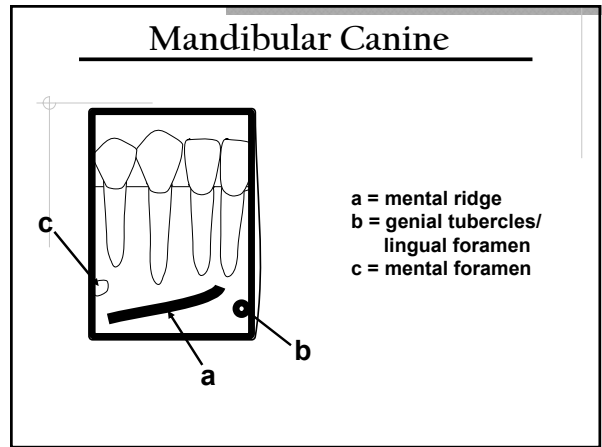
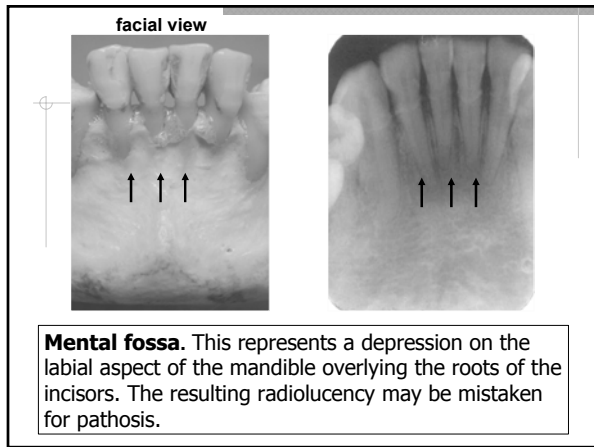
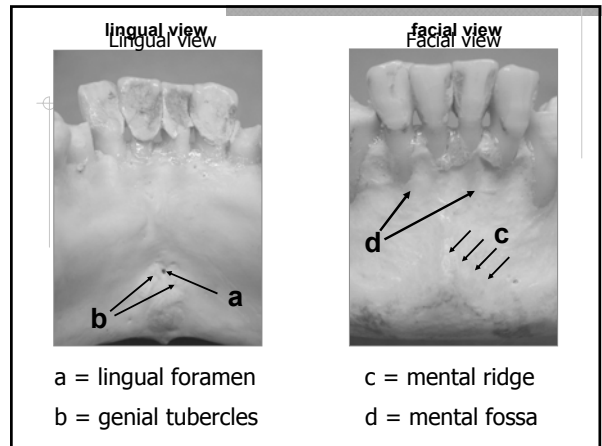
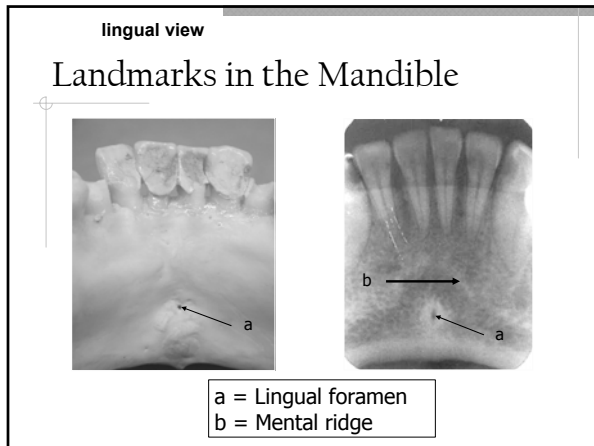
- ◆ External oblique ridge
- ◆ Inferior border of the mandible

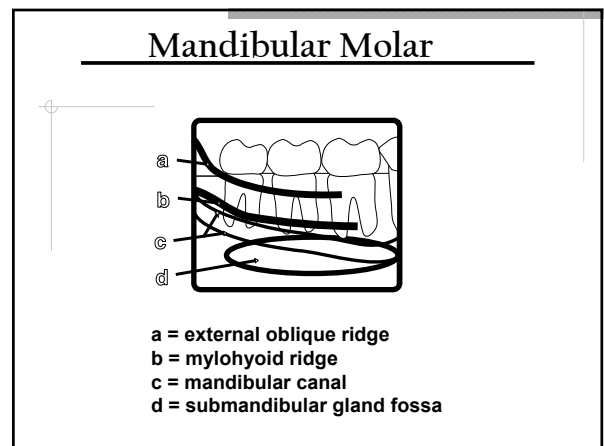
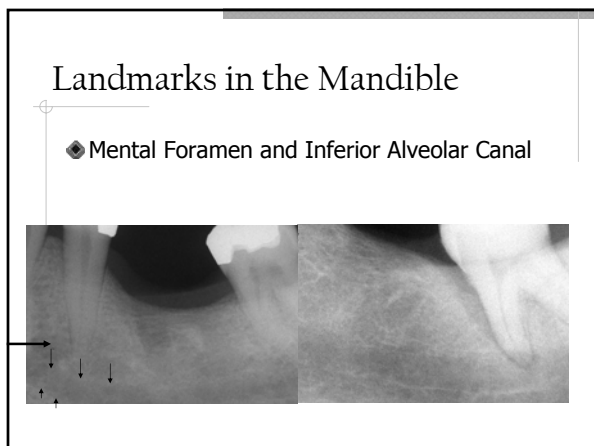
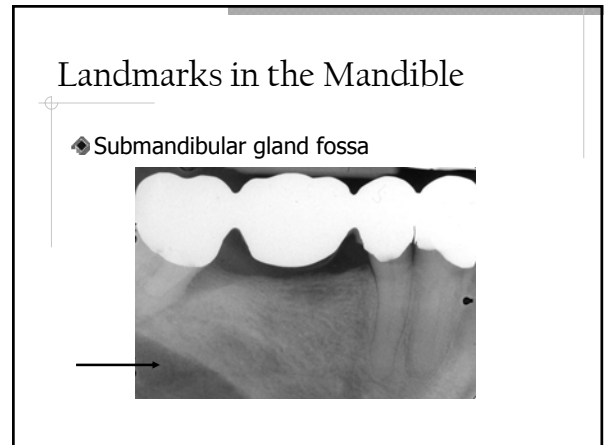
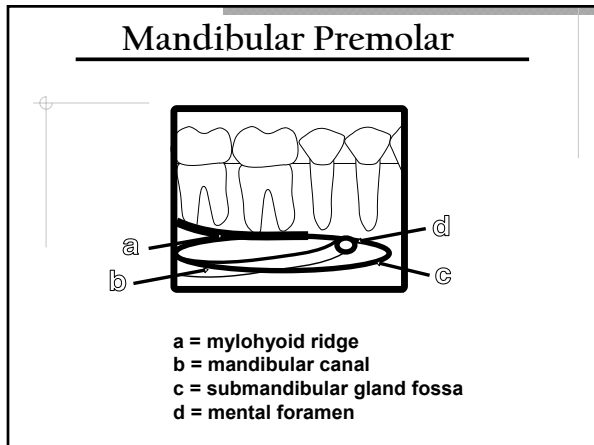
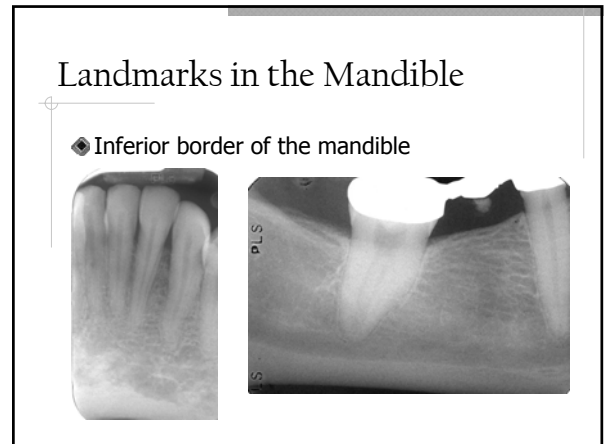
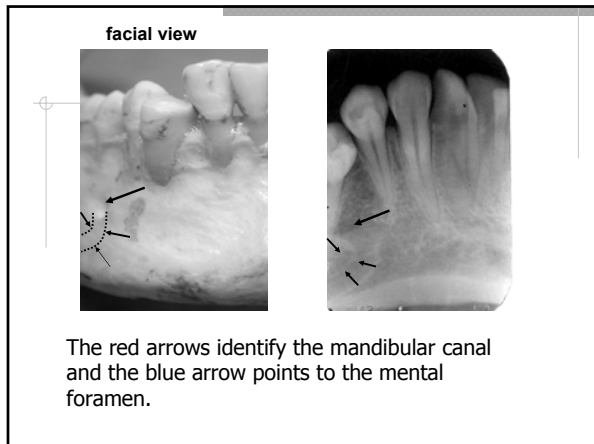


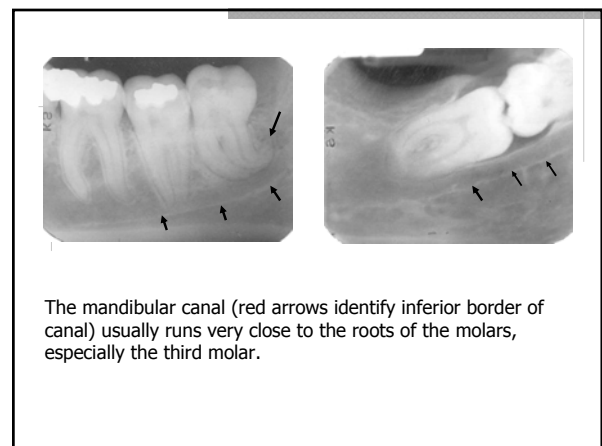
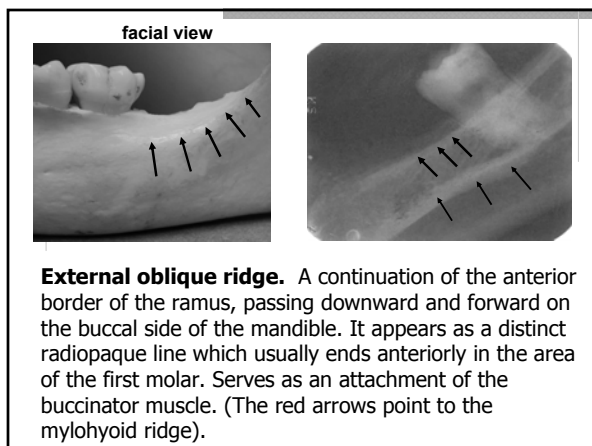
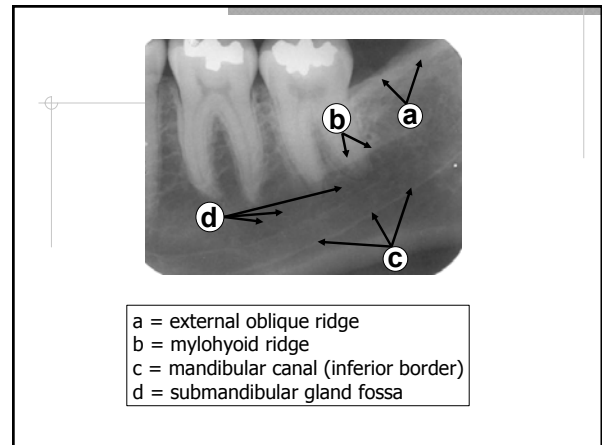
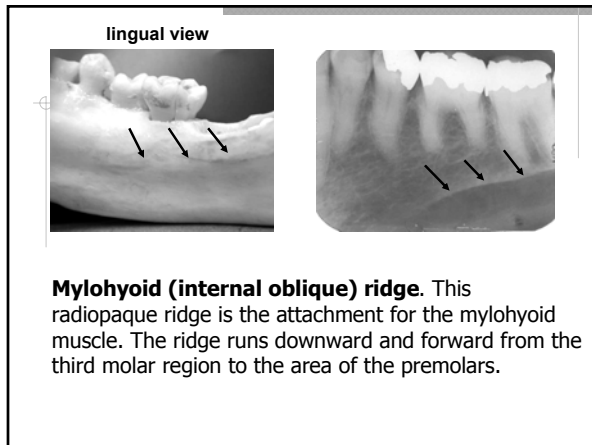
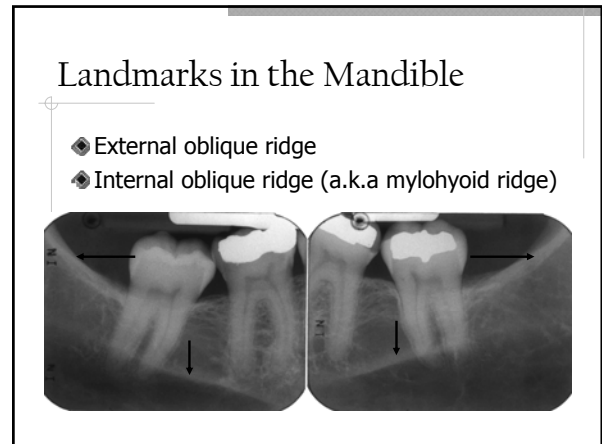
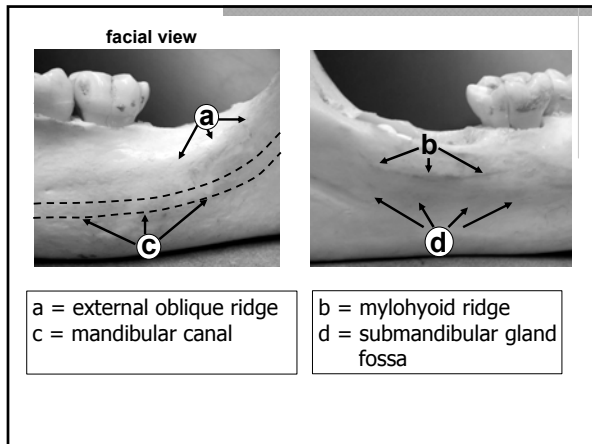
## Landmarks in the Mandible

- ◆ Genial tubercles
- ◆ Mental Ridge









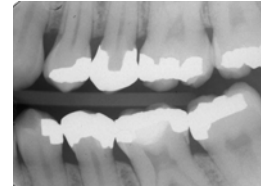
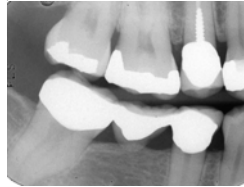
## Restorations

- ◆ Gold
- ◆ Amalgam
- ◆ Titanium
- ◆ Stainless Steel
- ◆ Gutta Percha
- ◆ Porcelain
- ◆ Composites
- ◆ Cements and Liners



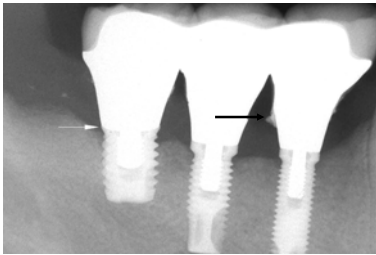
## Restorations

- ◆ Metallic Restorations
- ◆ Bases and liners



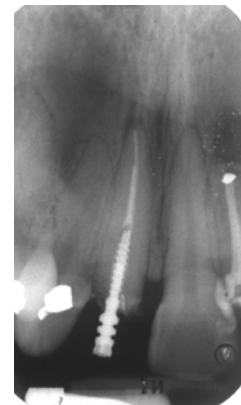
## Restorations

- ◆ Implant restorations



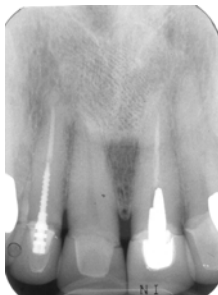## Restorations

- ◆ Stainless steel post
- ◆ Root-end amalgam



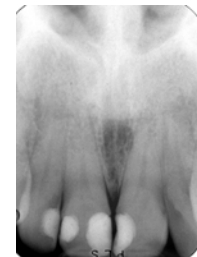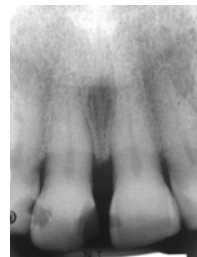
## Restorations

- ◆ Porcelain
- ◆ Gold
- ◆ Gutta percha
- ◆ Stainless steel



## Restorations

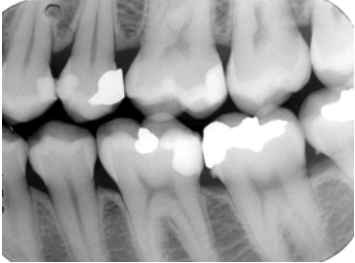
- ◆ Composites: Radiolucent and Radiopaque





## Restorations

- ◆ Posterior composites



## Acknowledgement

- ◆ Thanks to OSU College of Dentistry for the use of some of the slides, diagrams, and radiographs.



## Questions



Thank you!

