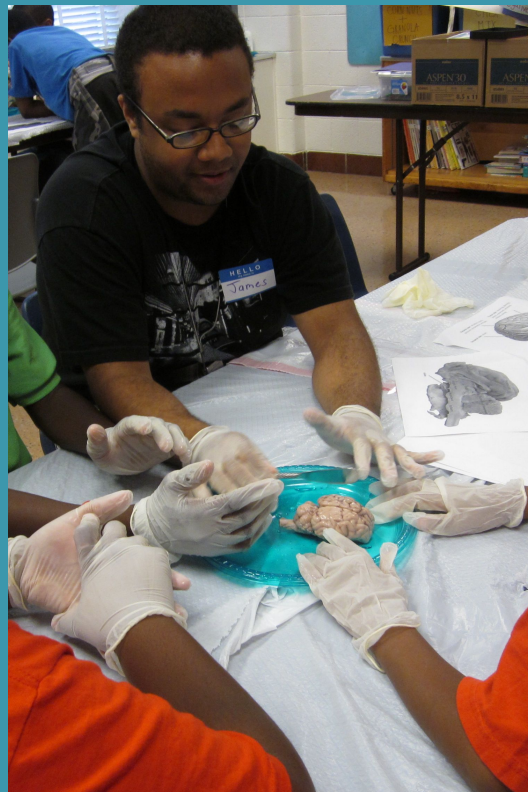

project **NEURON**



www.neuron.illinois.edu



Sheep Brain Exploration Guide

Sheep Brain Exploration

Introduction:

This guide is intended to lead you through the anatomy of the sheep brain dissection and also to make connections to the functional significance of the structures that you will locate—and why brain injury might cause functional and behavioral changes.

While we are using the sheep brain for dissection, this guide will highlight the similarities between the sheep and human brain, so that this dissection will give you valuable insight into the structure of the human brain. Being able to locate structures in the sheep brain will help you to understand the anatomy of the human brain as well.

Materials and Preparation:

You will need:

- Sheep brain
- Dissection tray
- Dissection kit: scalpel, probe, scissors, tweezers
- Gloves

The brains are stored in a preservative solution. Before beginning, rinse the brains under a slow stream of running water. When not in use, the brains should be stored in the preservative solution in a tightly sealed container. As with all procedures involving animal specimens, exercise proper safety precautions and handle brains with care.

Using the icons in this guide:



You Try It!: This indicates a question or way you can apply your knowledge.



Question: This icon means that there are questions to answer in your guide.



Talk About It: This icon indicates an area meant to generate thought and discussion.



Clinical Connection: This indicates a connection to real-life medical practices or conditions.

What's up with all the new words?!

With all of the new terminology in this guide, you may wonder why you should even bother learning the new vocabulary. Why can't you just say "up" instead of "dorsal"? Learning the language to speak about neuroanatomy is tricky, but careful language helps us to accurately describe the science and anatomy of the brain and ensures that scientists are consistent. In this dissection, don't get too caught up in remembering every new term, but do practice using them throughout the guide.



Clinical Connections: How do we determine function?

Throughout this brain dissection guide, and indeed throughout neuroscience, you will hear about the functions associated with different brain regions. However, it is important to understand that brain regions are so interconnected that when one brain region is active many other regions are affected—either by increased or decreased activity. It is thought that it only takes three stages of connections (called synapses) to get from one brain region to any other.

How do we determine what the different regions of the brain do? One method is through the use of **lesion experiments**. In these studies, brain areas are removed (or in humans, may be damaged by head injury) and then behavior and physiology is measured and then the function lost by the damage is assigned to that structure.

While lesion studies are important tools, they are not uncomplicated. There are some basic problems with the logic of lesion studies:

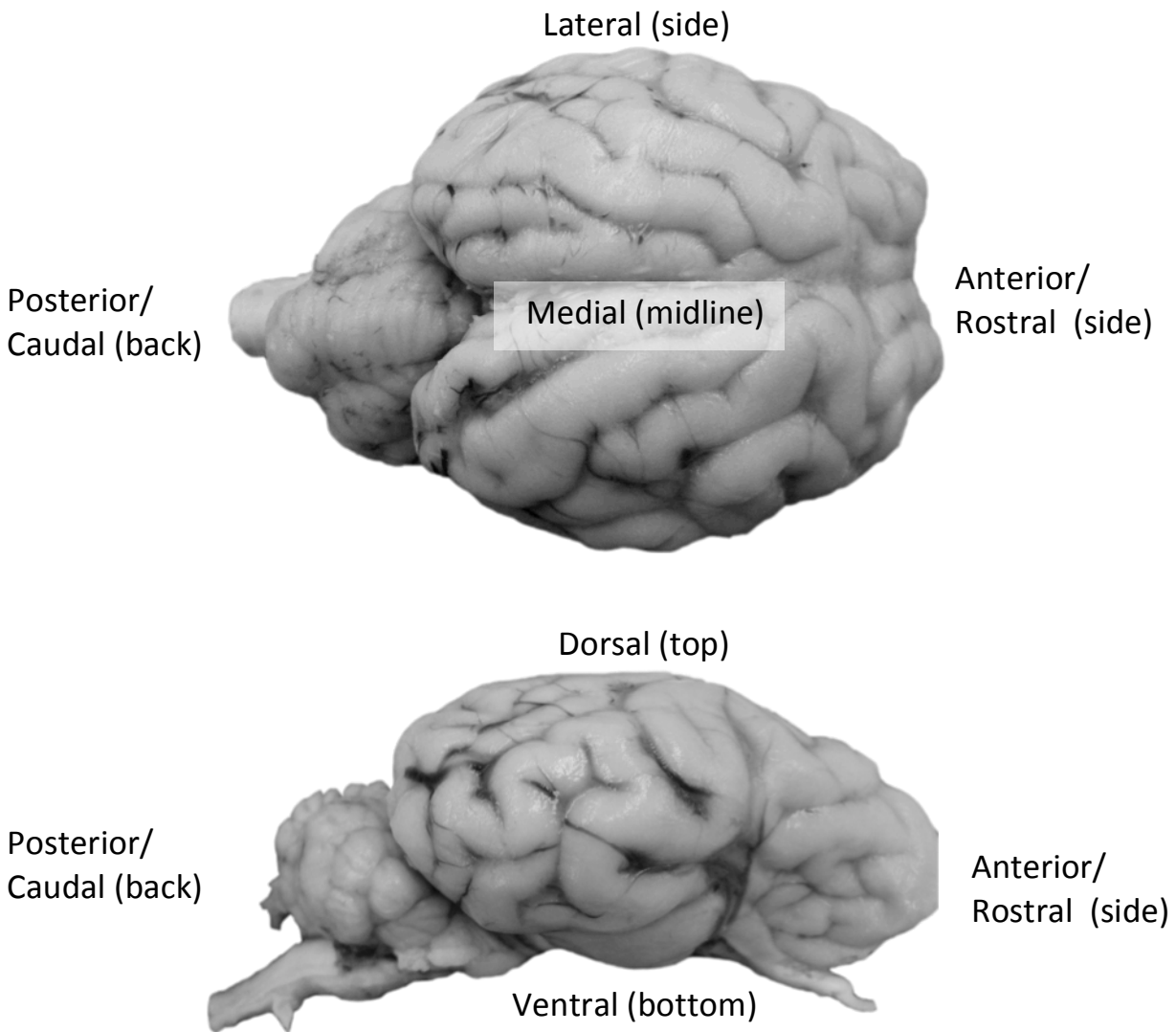
1. The cells of the brain are interconnected, so defining one area as an independent region is a challenge.
2. Lesion studies can only tell us what the brain CAN do without that structure functioning normally, or at all.
3. Our brains are plastic, able to change in response to experience or damage. When one region is damaged, neighboring areas may take over for lost function.
4. The functions that we assign to regions may be too general to relate to one brain region.

Even with the cautions listed above, damage can produce reproducible deficits and neurologists can use the information to identify specific sites of damage.

Anatomical Directions

Similar to using north, south, east, and west to describe relative locations of places on a map, when you are looking at anatomical structures there are terms that are used to help describe the relative location of the brain structures. **These terms refer to the orientation of the brain in the body, so they are the same no matter how you hold or rotate the brain.** These terms will be used throughout the guide and should also be used within your groups to discuss the brain.

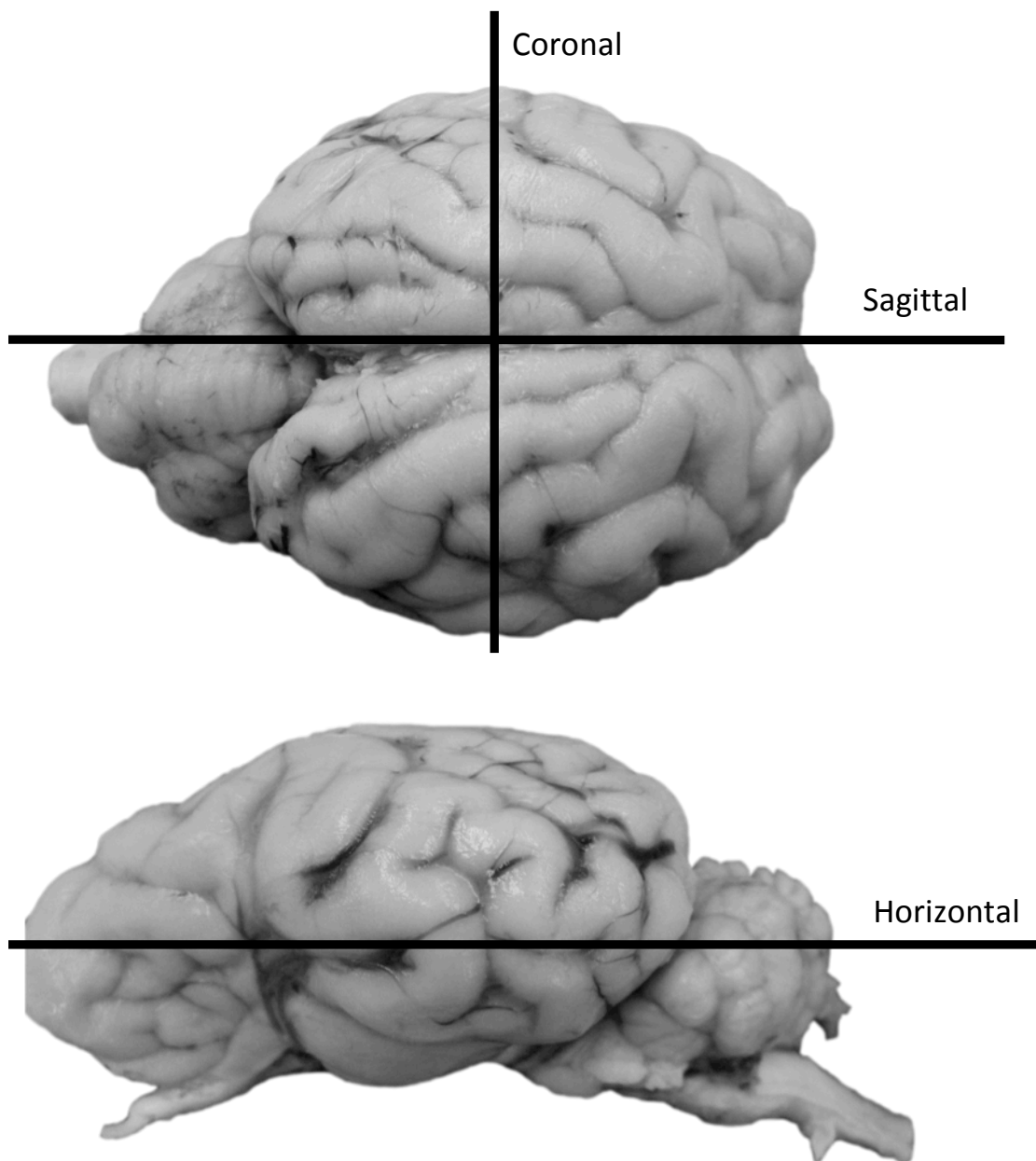
- **Anterior (rostral or “towards the nose”)** means towards the front.
- **Posterior (caudal or “towards the tail”)** means towards the back.
- **Lateral** means towards the side.
- **Medial** means towards the middle.
- **Dorsal (“towards the back”)** means on top
- **Ventral (“towards the stomach”)** means on the bottom.





Planes of Orientation

In addition to the vocabulary that describes direction in the brain, there are terms that describe how we cut the brain. There are many methods used to image the brain and these images can be displayed in different orientations. The three most common ways to slice the brain are **coronal, sagittal, and horizontal**.

- The **coronal** plane divides the brain from front to back. This is like slicing a loaf of bread.
- The **sagittal** plane divides the brain from left to right. In your dissection, you will be making a mid-sagittal cut to divide the right and left hemispheres.
- The **horizontal** plane divides the top and the bottom of the brain.



 **You Try It!**

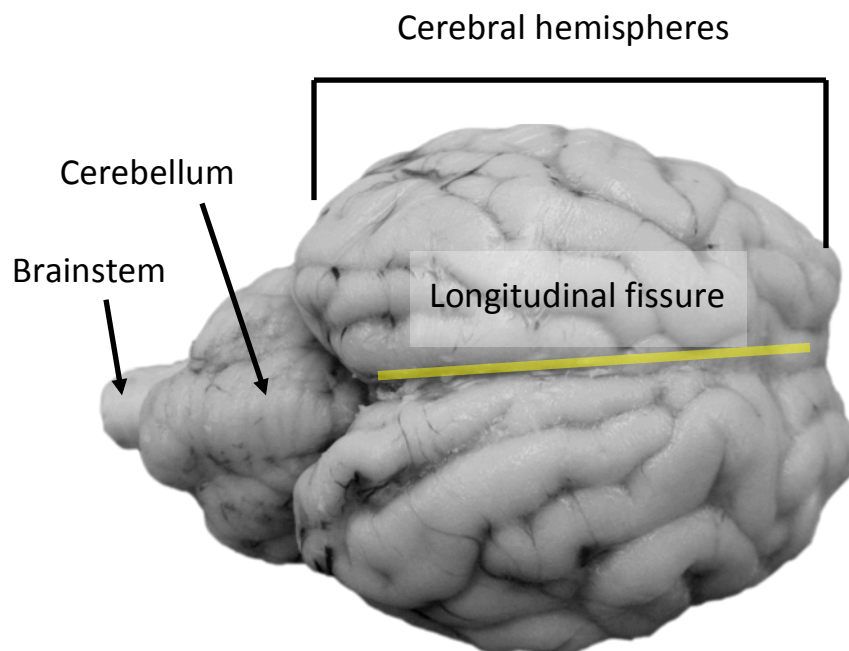


One clinical imaging technique used to visualize the brain is Magnetic Resonance Imaging (MRI). The images produced by this technique are equivalent to looking at thin slices of the brain. The images above are in three different planes of orientation. Label which image is in **sagittal**, **coronal**, and **horizontal** orientations.

Examination of the exterior of the brain

The first part of the dissection is examination of the exterior surface of the brain. This part requires no actual cutting. As you identify the listed structures, think about how these structures may be functionally related (or not).

Examine the exterior of the entire brain. You will notice the two symmetrical **cerebral hemispheres (cerebrum)**, the **cerebellum**, and the **brainstem**. The **longitudinal fissure** separates the two cerebral hemispheres.





You Try It!

Label the following anatomical directions in the previous figure: **rostral**, **caudal**, **dorsal**, **lateral**, and **medial**.

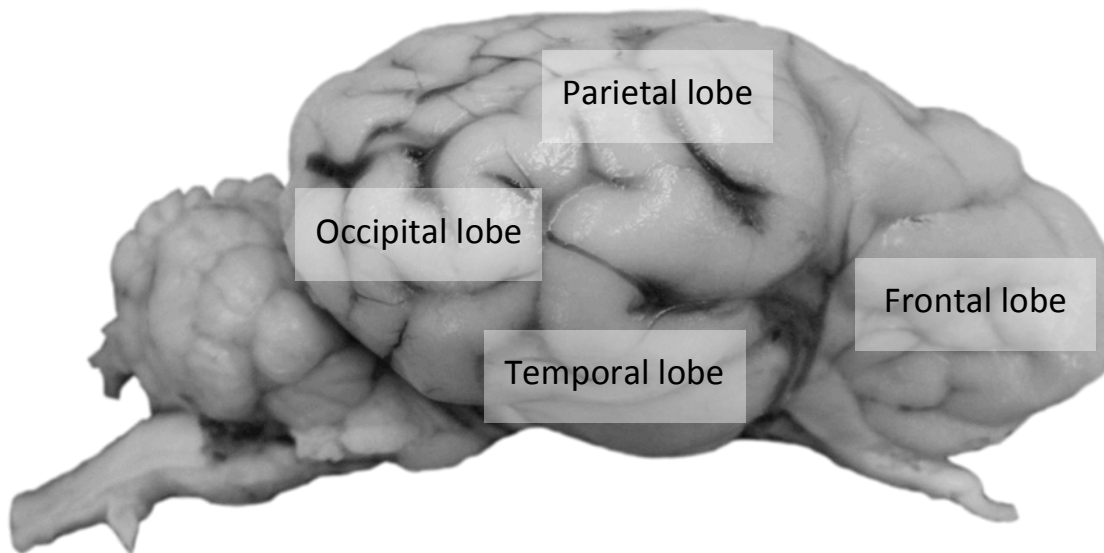


Select the correct answer for the following questions:

1. In the sheep brain, the cerebellum is **rostral** or **caudal** (circle the best answer) to the cerebral hemispheres. This is different than in the human brain, where the cerebellum is **ventral** or **dorsal** (circle the best answer) to the cerebral hemispheres.
2. The **right** or **left** (circle the best answer) hemisphere controls movement of the right arm.
3. A patient comes to the emergency room with impaired motor ability on the right side of her body and impaired speech. The physician suspects that the patient suffered from a stroke, which causes the loss of blood flow to certain brain region.
 - a. The stroke most likely occurred in the **right** or **left** (circle the best answer) cerebral hemisphere.
 - b. What characteristics of the patient's symptoms indicate that this is the region of the stroke?

The Four Lobes of the Brain

With your sheep brain, identify the major lobes of the brain: **frontal**, **temporal**, **parietal** and **occipital**.





Talk About It: Lobe Damage Research


Many functions of the cerebral cortex are distributed among multiple brain regions. However, some functions are associated primarily with portions of one lobe. Much of the information about the functions of the four lobes is obtained using research from patients with damage to one of the lobes.

The **occipital lobe** is responsible for **vision**. Damage to this lobe can result in visual impairment and hallucinations.

Patients with damage to the **frontal lobe** have significant changes to their **personality and social behavior**. A famous example is **Phineas Gage**, a railroad worker who suffered from an injury to his left frontal lobe when a large iron rod went through his skull in 1845. The case sparked doctors' interests in cerebral localization of personality and behavior.

The **parietal lobe** takes the sensory information from a single perception and then **integrates** these perceptions into a complex network that creates the world around us. Patients with damage to the parietal lobe can have difficulties in determining spatial relationships.

Finally, the **temporal lobe** is responsible for a multitude of functions including taste, and hearing. Notably, damage to the temporal lobe can result in a loss of **recognition of words and faces** as well as the inability to categorize words or pictures, depending on which side is damaged. Memory processing is also affected by temporal lobe damage.



Phineas Gage shows his skull and where the iron rod passed through it. (Illustration by Phineas Jones; octophant.us)



4. Damage to which lobe(s) would interfere with parking the car?
5. Damage to which lobe(s) would interfere with learning and remembering new words?
6. Damage to which lobe(s) would interfere with the ability to solve problems?

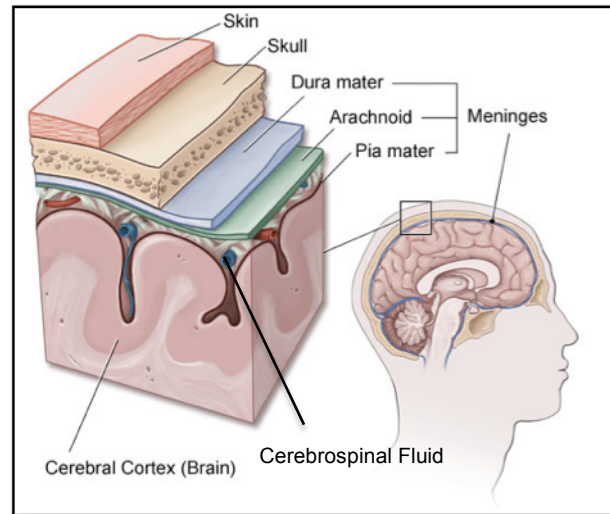
The Cerebral Cortex

The cortex has “wrinkles” called **sulci** (grooves; singular: sulcus) and **gyri** (ridges; singular: gyrus). The human brain is characterized by many sulci and gyri, but other species have fewer. The sheep brain, for example, has fewer than the human brain, and the rat and mouse brains are almost entirely smooth. Sulci and gyri increase the total surface area of the brain.

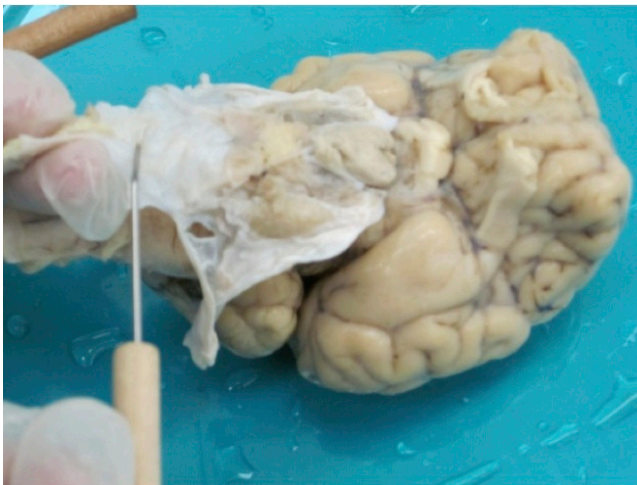The cortex of the brain is comprised of neuron cell bodies. There are about 100 billion neurons in the brain; in the cortex they make about 0.15 quadrillion connections with one another.

Depending on the brain, you may be able to see one or two of the three layers of the **meninges**. The meninges are the protective covering of the brain and spinal cord. There are three layers: the **dura mater**, the tough protective outer layer that lines the skull (this will likely have been removed from your sheep brains), the middle **arachnoid layer** with blood vessels, and the **pia mater** that lines the brain. The thin pia mater follows the sulci and gyri of the brain surface and is likely still attached to the brain. However, this layer is thin and may be hard to distinguish from the surface of the brain itself.

Surrounding the brain and circulating through the ventricles (inside the brain) is the **cerebrospinal fluid (CSF)**. This clear, colorless body fluid is located between the arachnoid layer and the pia mater. It acts as a cushion for the cortex, to protect the cortex from mechanical harm if the head were to experience an impact. Also, it protects the cortex from infections by sequestering viruses and bacteria in the CSF.

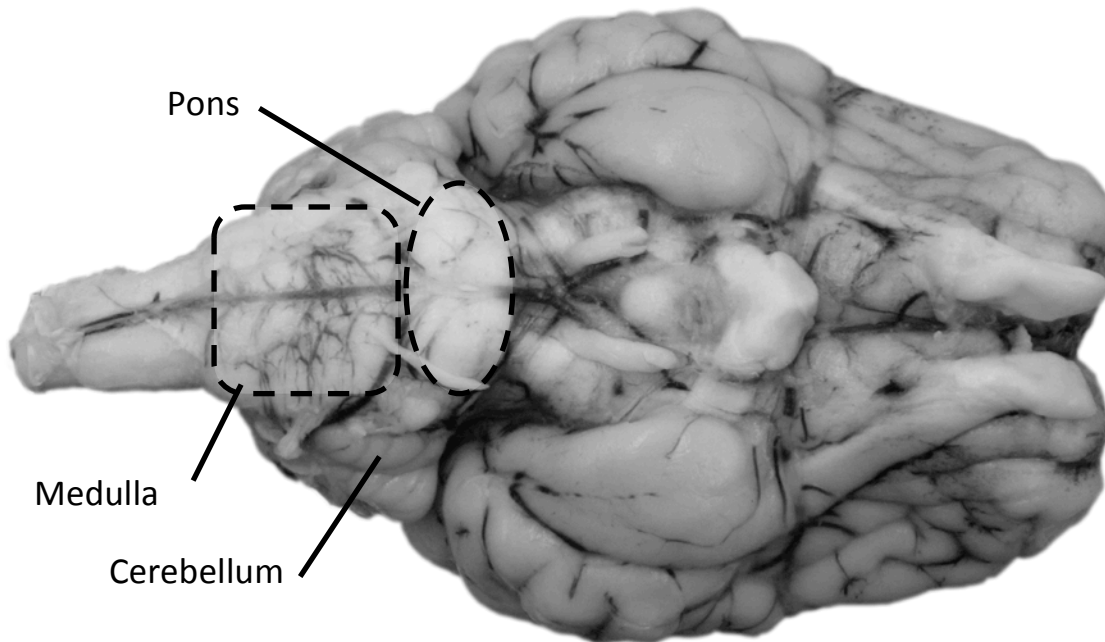


The meninges of the brain image from <http://www.ecommunity.com/health/index.aspx?pageid=P00789>



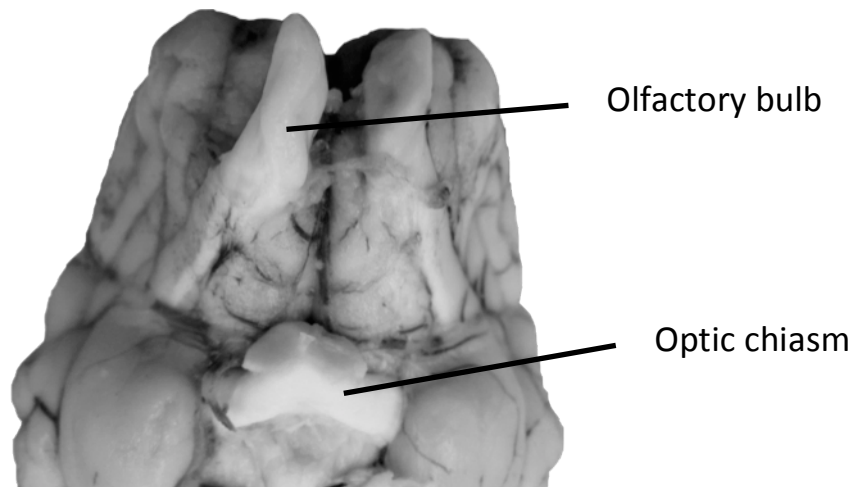
Before identifying structures on the ventral surface of the brain, you will need to carefully remove the meninges. Using your tweezers, carefully pull these layers away from the brain. Use care because the brain tissue is soft and easily damaged.

Once the protective layers of the meninges are removed, look at the ventral side of the brain. You will see the **pons**, the **medulla**, and the **cerebellum**.



7. "Pons" is the Latin word for "bridge." Why might this structure be called bridge or pons?
8. "Medulla" refers to the "middle." What is the medulla in the middle of?
9. Cerebellum is Latin for "little brain." How does the cerebellum resemble a little brain?

When looking at the ventral surface of the sheep brain, you will also see structures used for processing visual and olfactory (smell) signals. First, you will notice the prominent **olfactory bulbs** on the ventral surface of the frontal cortex.



Next, identify the **optic chiasm**, where the **optic nerves** from the left and right eye meet. (Note: muscle and fatty tissue may surround the optic nerve; use your knife to carefully remove any excess tissue.)

As illustrated in the human brain diagram below, there are two optic nerves that bring visual information from the eye to the brain. These nerves cross at the **optic chiasm**. The optic chiasm is an "X"-shaped structure where the two optic nerves, each of which originates in one of the eyes, partially cross. The crossing of the optic nerves that occurs at the chiasm, a phenomenon known as **decussation**, results in information from the right visual fields of both eyes being processed by the left hemisphere of the brain, and vice versa.

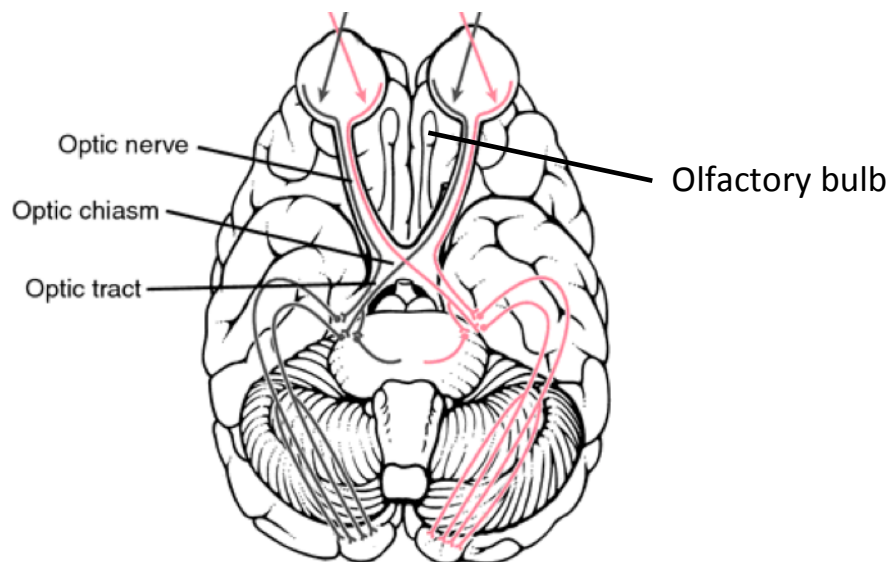


Image from Miller-Keane Encyclopedia and Dictionary of Medicine, Nursing, and Allied Health.



10. Why are the olfactory bulbs in a sheep brain larger than in a human brain?



Talk About It: Cross-eyed cats

There are two optic nerves that bring visual information from the eye to the brain. These tracts cross at the **optic chiasm**. The optic chiasm is an "X"-shaped structure where the two optic nerves, each of which originates in one of the eyes, partially cross. The crossing of the optic nerves that occurs at the chiasm, a phenomenon known as **decussation**, results in information from the right visual fields of both eyes being processed by the left hemisphere of the brain, and vice versa.



Image from Bobbi Bowers, flickr.com

Some Siamese cats have a genetic mutation where the wiring of the optic chiasm is disrupted. This causes a decrease in the crossing of the nerves. Interestingly, these cats are able to function normally but have to alter their behavior to do this.



11. Why do you think the cats have to cross their eyes to correct this problem?

Examination of the Mid-Sagittal Cut

Different cuts allow different views of brain structures. Structures that are not on the external surface of the brain are easier to visualize with coronal or sagittal sections. Together with your exploration of the brain surface anatomy, making a series of cuts will allow you to become more familiar with the three-dimensional structure of the brain.

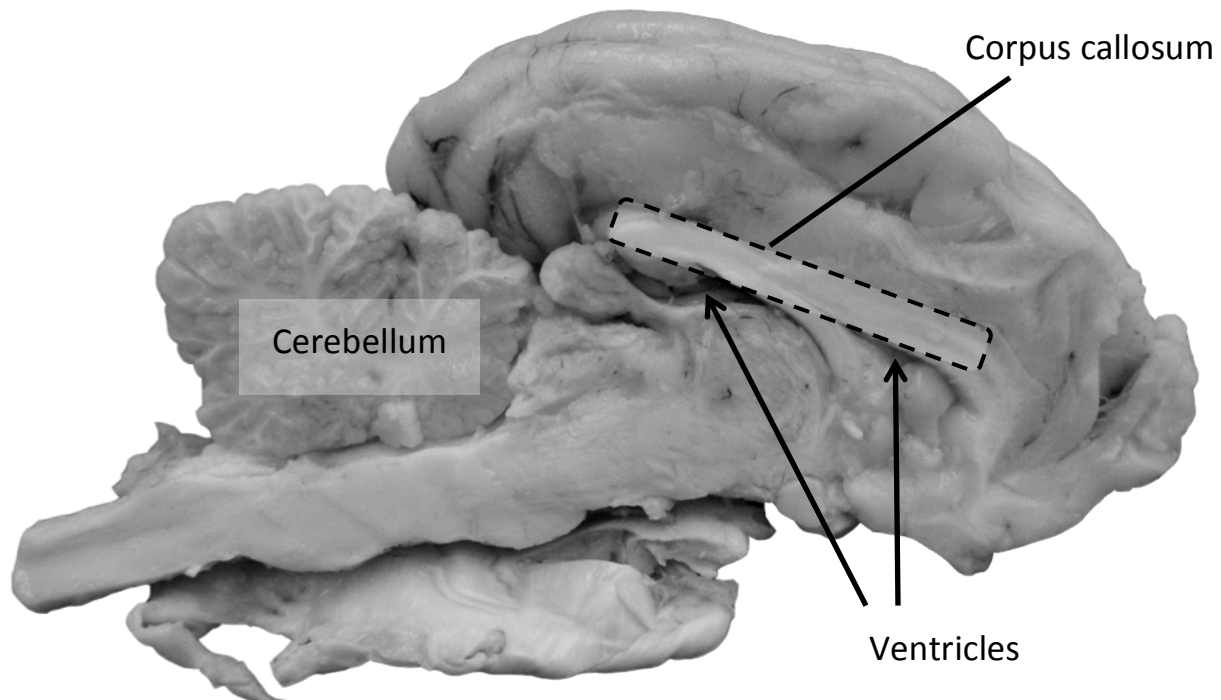
Before making your first cut, place the brain so that you are looking at the dorsal (top) side. Using your hands, not the scalpel, gently pull the two hemispheres of the brain away from the midline. You don't want to rip anything, but you should notice that the two hemispheres can be pulled apart slightly, and looking into the longitudinal fissure. You will see a structure that connects the two hemispheres: the **corpus callosum**. The corpus callosum contains bundles of fibers (axons) that connect neurons in the two hemispheres.



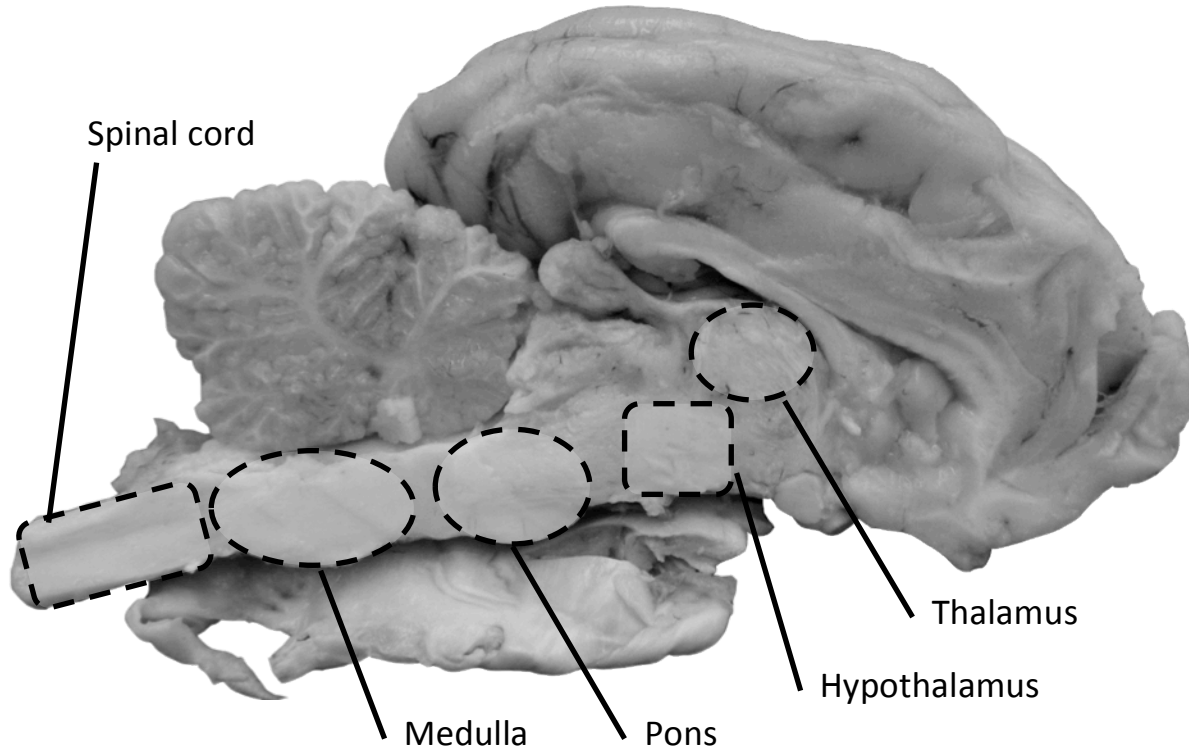
Clinical Connection: Callosotomy for the Treatment of Epilepsy

Historically, treatment of severe epilepsy sometimes included surgically severing the corpus callosum. The idea was that the current of random electrical activation causing epilepsy could then not spread between the hemispheres. Currently, this surgery is not widely used unless the epilepsy is very severe and fails to respond to other treatments.

Make a mid-sagittal cut. Holding the brain flat and level cut along the longitudinal fissure all the way through the brain. In this cut, you can see the **ventricles**, which are the open spaces in the brain that normally contain the cerebrospinal fluid, which carries nutrients and regulates pressure. The ventricles ensure that the fluid has access to all areas of the brain, not only the external surface. As you cut, you may notice a thin layer of cells lining the ventricles (it looks like pinkish "gunk") that are responsible for the production of **cerebrospinal fluid**.



Recall that you could identify the **spinal cord**, the **medulla**, and the **pons** on the exterior ventral (bottom) surface of the brain. Identify these structures in the mid-sagittal section. You can also see the **thalamus**, and the **hypothalamus**. The thalamus integrates information and relays it to appropriate regions for processing. The hypothalamus (“hypo” means below, so below the thalamus) is involved in many functions from biological timekeeping to regulation of body temperature.



Clinical Connection: Hypothalamus and Obesity

The **hypothalamus** comprises several nuclei, or a collection of cells that are involved in a variety of functions. It links the nervous system to the endocrine system and keeps many of the body's processes at a set point within narrow parameters. These functions include

- circadian rhythms (keeping “biological time”) and sleep
- feeding and drinking
- body temperature

Some strokes can affect the hypothalamus and cause it to malfunction, which leads to an imbalance of hormones released from the thyroid. This release of the wrong hormones can cause extra sensations of reward when eating, encouraging overeating.



A patient has recently suffered from a stroke and is concerned about her recent weight gain. She exercises everyday and eats a healthy diet but still seems to gain weight.

12. Which area of the brain might be malfunctioning?

Finally, look at the gray and white matter of the sagittal section of the cerebellum. It resembles a tree and is called the *arbor vitae*, the “tree of life.” The **white matter** appears white because of the myelin sheaths that cover the axons (see image below). The **gray matter** appears gray because of the neuronal cell bodies.

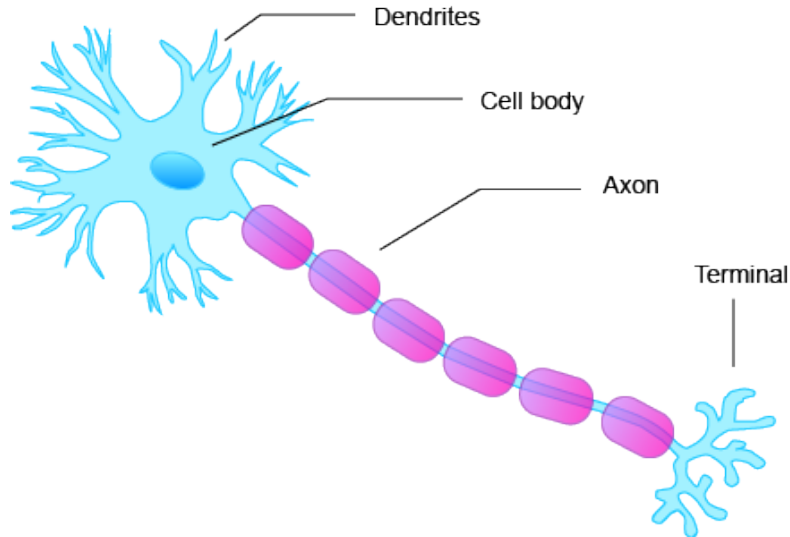


Image from interaxon.ca/blog/2010/11/what-is-a-brain-wave/



You Try It!

Label the structures of the neuron above with what appears as “gray matter” and “white matter” in the cerebellum.



13. Is the cerebral cortex composed of gray matter or white matter? Does it contain mostly axons or mostly cell bodies?

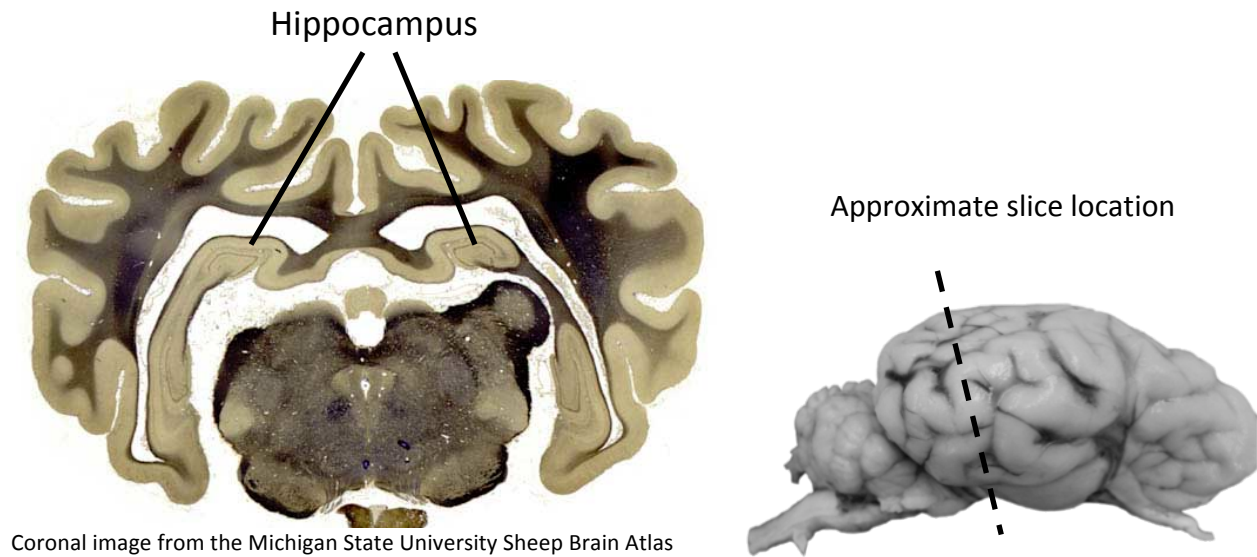
14. In some diseases, neuronal cell bodies in the cortical gray matter can be lost. How do you think this will affect the appearance of the sulci and gyri?

Examination of the coronal cuts

Coronal cuts separate the front and the back of the brain (like slicing a loaf of bread).

You will make a series coronal cuts starting from the anterior (front) of the brain and working back. Each section should be about 1 cm thick. The more slices, the more that you can see, however, slices that are very thin are difficult to work with and are very fragile. Set the slices out and try to identify the ventricles.

Identify a coronal section that allows you to see the **hippocampus**. The hippocampus is located deep in the temporal lobe, and may be hard to identify. The word “hippocampus” is based on the word for seahorse. The structure folds in on itself, like a jelly roll, resembling a seahorse when cut into slices.



Talk About It!

How do we remember to ride a bike? Or where we live? Are these memories processed in the same brain areas? It turns out that **different types of memory are managed by different regions of the brain**. For example, procedural memories, which allow us to remember how to hold a pencil, are processed in the striatum, brainstem, and cerebellum. Emotional memories (the events during a difficult test) are regulated by an area of the brain near the hippocampus, called the amygdala. Finally, the hippocampus is important for declarative memories, such as facts that you might need to know for the test. Each of these regions is responsible for helping us perform our daily tasks.



15. Research has shown that jugglers, who need particularly attuned motor memory, and London cabbies, who must memorize extensive street maps, each have a particular region of their brain that is enlarged. Can you speculate as to which region is enlarged in the jugglers and the London cabbies?

Brain Exploration Guide: Structure Glossary

Arachnoid mater: the middle of the three protective layers of meninges surrounding the brain and spinal cord.

Cerebellum: controls balance and muscle coordination; located caudal to the cerebrum in the sheep brain.

Cerebrum: largest portion of the mammalian brain; two hemispheres separated by the longitudinal fissure.

Corpus callosum: large band of fibers that connects the two cerebral hemispheres.

Cortex: outer portion of the cerebrum

Dura mater: the tough outermost layer of the three protective layers of meninges surrounding the brain.

Gray matter: areas of the brain and spinal cord containing neuronal cell bodies, dendrites, and unmyelinated axons. Found in the cerebral cortex of the brain and inner area of the spinal cord.

Gyri: the folds of the cerebral cortex.

Hippocampus: involved in emotional states and memory processing.

Hypothalamus: responsible for regulation of homeostasis (body temperature, appetite, sleep).

Medulla: part of the brainstem, contains centers for heart rate, blood pressure, and respiration. The reflex centers for coughing, sneezing, and hiccupping are also located in the medulla.

Olfactory bulb: contains cell bodies of neurons that synapse with olfactory nerves. Involved in olfaction (smell) processing.

Optic chiasm: crossing point (decussation) of the optic nerves

Pia mater: innermost layer of the three protective layers of the meninges that surround the brain.

Pons: contains nerve tracts that connect the cerebellum with other areas of the brain and spinal cord.

Sulci: grooves between gyri of the cerebral cortex.

Thalamus: a sensory relay center; sensory nerves connect to appropriate processing regions.

Ventricle: cavity in the brain filled with cerebral spinal fluid.

White matter: bundles of myelinated axons within the brain and spinal cord; found in the inner portion of the cerebrum and the outer regions of the spinal cord.

Post-Dissection Discussion and Homework

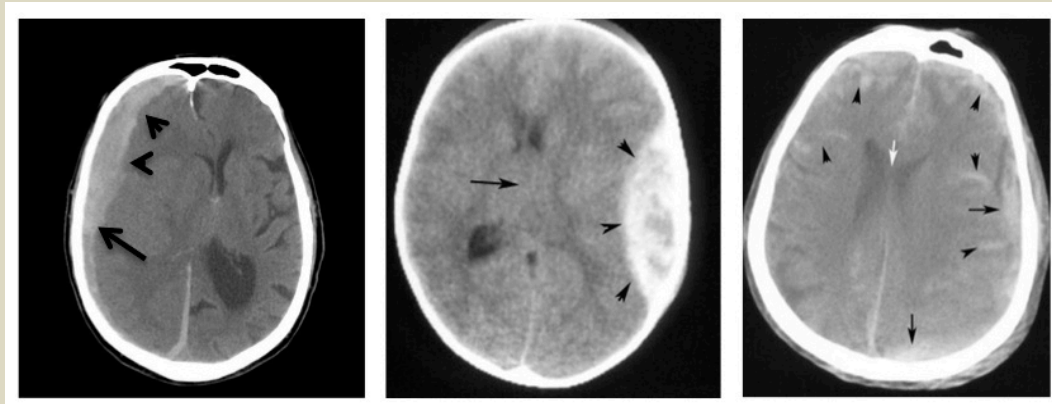


Clinical Connection: Hematomas

Head injury from impact can sometimes result in the accumulation of blood around the brain, called a **hematoma**. Brain imaging techniques allow visualization of fluid accumulation and the patterns of this accumulation can inform physicians about the location of the bleeding within the layers of the meninges. Blood can accumulate between any of the layers, or between the dura and the skull.

For example, a **lens-shaped** pattern of blood accumulation indicates that blood is pooling between the dura and the skull. This is called an epidural hematoma, literally “above the dura.” People with epidural hematomas are referred to as patients who “talk and die” because they have a brief lucid phase followed by rapid deterioration. Being able to quickly image the brain after head injury, identify the pattern of blood accumulation, and then treat the head injury is essential for survival and prognosis.

In contrast, a subdural hematoma, where blood accumulates under the dura, between the dura mater and the arachnoid layer, appears as a **crescent shape** in brain images. Subdural hematomas can occur immediately following head injury, or can accumulate slowly many weeks or even months after injury.



Subdural (left), epidural (center), and subarachnoid (right) hematomas. The pattern of blood accumulation is limited by the position of the bleeding between the layers of the meninges. Blood or fluid appears white in these images. (Images from Loyola Stritch School of Medicine)

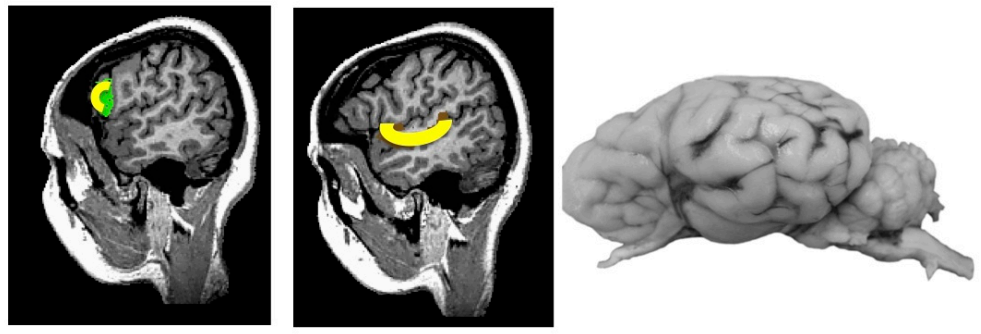
Finally, in subarachnoid hematomas (between the pia and the arachnoid layers), the blood can pool along the ridges of the sulci and gyri because the underlying pia layer closely follows the contours of the brain.



Talk About It: Language Processing

Neurosurgeon Paul Broca first identified **Broca's area** following observations of his patient Mr. Tan. Mr. Tan's true identity is unknown; he was called "Tan" by the workers at the hospital where he died, because "tan" was the only thing he ever said (as he was suffering from severe **Broca's aphasia**, which is characterized by very limited verbal production). When he died in 1861, Broca dissected his brain and found a tumor in the **left hemisphere**. After observing this fact in subsequent autopsies of people suffering from similar type of aphasia, Paul Broca concluded that "the faculty for articulate language" was located in the left hemisphere of the brain. **Broca's area is responsible for language output and production of words.**

Wernicke's area is an important language center located in the left hemisphere of the brain. While the precise location of the Wernicke's area is not very clear, it is known to be located around the lateral sulcus, posterior section of the superior temporal gyrus. This area was discovered by Carl Wernicke, a German neurologist, who observed that people with lesions at this location could speak, but their **speech was often incoherent and made no sense**. Wernicke's area is responsible for processing of language input (words that we hear). Broca's area and Wernicke's area are connected by a large bundle of nerve fibers.



Broca's and Wernicke's areas control language processing. Label the corresponding regions in the sheep brain, above (note that these regions may have different functions in sheep and humans). MR images from *Brain Voyager Brain Tutor* software:
<http://www.brainvoyager.com/downloads/downloads.html>



Talk About It: Science mythbuster

The brain has two hemispheres with "contralateral" (opposite side) control of motion and sensation. That is, the right hemisphere generally controls motion and processes sensation from the left half of the body. You might have heard of "right brain" and "left brain" functions or even personalities. This is a myth. The two hemispheres share 96% functional similarity and most differences between right and left brain functions are biases, rather than capabilities. One important difference, however, is that **in most individuals the left hemisphere controls speech.**



16. In what plane of section are the images in the “Clinical Connections: Hematoma” section above?
17. An 8-year-old boy comes into the emergency room with his parents. He hit his head while playing baseball and, though he says that he feels ok, his parents are still worried. The physician requests a brain scan that shows a crescent-shaped pattern of blood accumulation.
 - a. Is this blood accumulation above the dura mater (**epidural**) or below the dura mater (**subdural**)?
 - b. Should the physician be concerned, or send the child home since he seems fine? Explain your response.
18. Do you think the sheep brain has the Broca and/or Wernicke’s area(s)? Why or why not?
19. Are there limitations to using the sheep brain as a model for human brains? If so, what are they?