

Title	Laparoscopic repair for recurrent parastomal hernia of an end stoma using the sandwich technique while preserving an ileal conduit: A case report
Author(s)	Wada, Toshiaki; Kawada, Kenji; Hasegawa, Suguru; Sakai, Yoshiharu
Citation	International Journal of Surgery Case Reports (2016), 25: 75-78
Issue Date	2016
URL	<a href="http://hdl.handle.net/2433/216142">http://hdl.handle.net/2433/216142</a>
Right	© 2016 The Author(s) Published by Elsevier Ltd on behalf of IJS Publishing Group Ltd. This is an open access article under the CC BY-NC-ND license ( <a href="http://creativecommons.org/licenses/by-nc-nd/4.0/">http://creativecommons.org/licenses/by-nc-nd/4.0/</a> ).
Type	Journal Article
Textversion	publisher



Contents lists available at ScienceDirect

## International Journal of Surgery Case Reports

journal homepage: [www.casereports.com](http://www.casereports.com)

# Laparoscopic repair for recurrent parastomal hernia of an end stoma using the sandwich technique while preserving an ileal conduit: A case report



Toshiaki Wada, Kenji Kawada\*, Suguru Hasegawa, Yoshiharu Sakai

Department of Surgery, Kyoto University Graduate School of Medicine, Kyoto, Japan

## ARTICLE INFO

## Article history:

Received 18 April 2016

Received in revised form 19 May 2016

Accepted 11 June 2016

Available online 16 June 2016

## Keywords:

Parastomal hernia

Laparoscopic hernia repair

Sandwich technique

## ABSTRACT

**INTRODUCTION:** Parastomal hernia is a common complication following stoma creation. The surgical approaches included local repair by suture, stoma relocation and mesh-based techniques; but none has been able to provide satisfactory results.

**PRESENTATION OF CASE:** A 60-year-old asian female was referred complaining of abdominal pain and constipation caused by recurrent parastomal hernia of an end stoma. She had undergone total cystectomy with creation of an ileal conduit at the age of 53 years, and laparoscopic sigmoid colostomy at the age of 55 years. Parastomal hernia of an end stoma had developed postoperatively, and she had undergone recreation of colostomy at the same place with fasciorrhaphy at the age of 59 years, but parastomal hernia recurred 6 months later because of split fascia sutures. Laparoscopic repair for recurrent parastomal hernia was conducted using the sandwich technique while preserving an ileal conduit. The patient has been followed postoperatively for more than 3 years without any sign of recurrence.

**DISCUSSION:** Although further cases are required to get definitive conclusions, we suppose that the laparoscopic sandwich technique can be useful for parastomal hernia.

**CONCLUSION:** We herein report a case of recurrent parastomal hernia treated laparoscopically while preserving an ileal conduit using the sandwich technique which combines the keyhole and Sugarbaker techniques. This is a quite rare case report of laparoscopic repair for recurrent parastomal hernia in a patient with an ileal conduit.

© 2016 The Author(s). Published by Elsevier Ltd on behalf of IJS Publishing Group Ltd. This is an open access article under the CC BY-NC-ND license (<http://creativecommons.org/licenses/by-nc-nd/4.0/>).

## 1. Introduction

Parastomal hernia is one of the most common complications following stoma creation, with a reported incidence of up to 50% in clinical examination and even 78% using computed tomography (CT) [1]. The surgical approaches for parastomal hernia include local repair by suture, stoma relocation and mesh-based techniques, although none of the techniques has been able to provide satisfactory results. We herein report a case of recurrent parastomal hernia treated laparoscopically while preserving an ileal conduit using the sandwich technique which combines the keyhole and Sugarbaker techniques.

## 2. Presentation of case

A 60-year-old asian female was admitted to our hospital complaining of abdominal pain and constipation caused by recurrent

parastomal hernia. She had bronchial asthma and type 2 diabetes mellitus that were well controlled by medication. She had suffered a spine injury due to a traffic accident at the age of 42 years, and her lower part of the body became paresis. She had undergone total hysterectomy for uterine myoma at the age of 45 years. Due to a contracted bladder caused by neurogenic dysfunction, she had undergone cystostomy at the age of 47 years, reoperation of cystostomy at 49 years, and then total cystectomy with creation of an ileal conduit at 53 years. At the age of 55 years, she had undergone laparoscopic sigmoid colostomy for severe constipation caused by neurogenic dysfunction. Parastomal hernia of a stoma had occurred after the operation, and so she had undergone recreation of colostomy at the same place with parastomal hernioplasty (fasciorrhaphy) at the age of 59 years. However, parastomal hernia had recurred 6 months later because of split fascia sutures, and then she was admitted to our hospital for treatment. She was obese and her body mass index (BMI) was 32.2. She presented with a parastomal hernia of a stoma in the left lower abdomen and an ileal conduit in the right lower abdomen (Fig. 1a). Abdominal CT scans showed a large parastomal hernia of a stoma with prolapse of the transverse colon (Fig. 1b).

We performed laparoscopic repair for recurrent parastomal hernia by the sandwich technique while preserving an ileal conduit.

\* Corresponding author at: Department of Surgery, Graduate School of Medicine, Kyoto University, 54 Shogoin- Kawara-cho, Sakyo-ku, Kyoto, 606–8507, Japan

E-mail addresses: [wt0520@kuhp.kyoto-u.ac.jp](mailto:wt0520@kuhp.kyoto-u.ac.jp) (T. Wada),

[kkawada@kuhp.kyoto-u.ac.jp](mailto:kkawada@kuhp.kyoto-u.ac.jp) (K. Kawada), [shase@kuhp.kyoto-u.ac.jp](mailto:shase@kuhp.kyoto-u.ac.jp)

(S. Hasegawa), [ysakai@kuhp.kyoto-u.ac.jp](mailto:ysakai@kuhp.kyoto-u.ac.jp) (Y. Sakai).

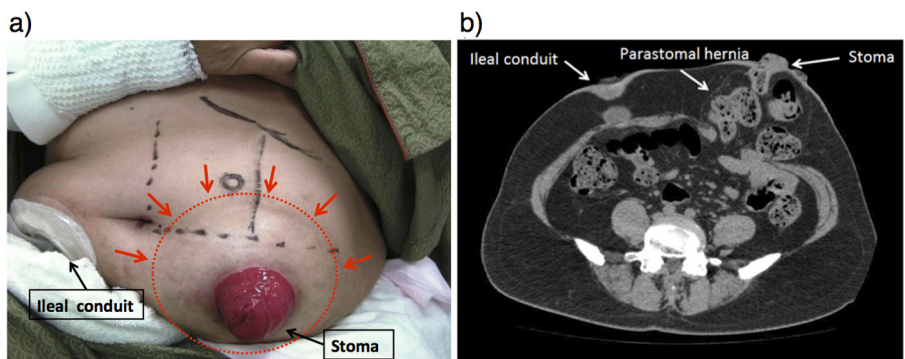


Fig. 1. a) The patient had a large parastomal hernia in the left lower abdomen and an ileal conduit in the right lower abdomen. b) Abdominal CT scans showed a large parastomal hernia of a stoma with herniation of transverse colon.

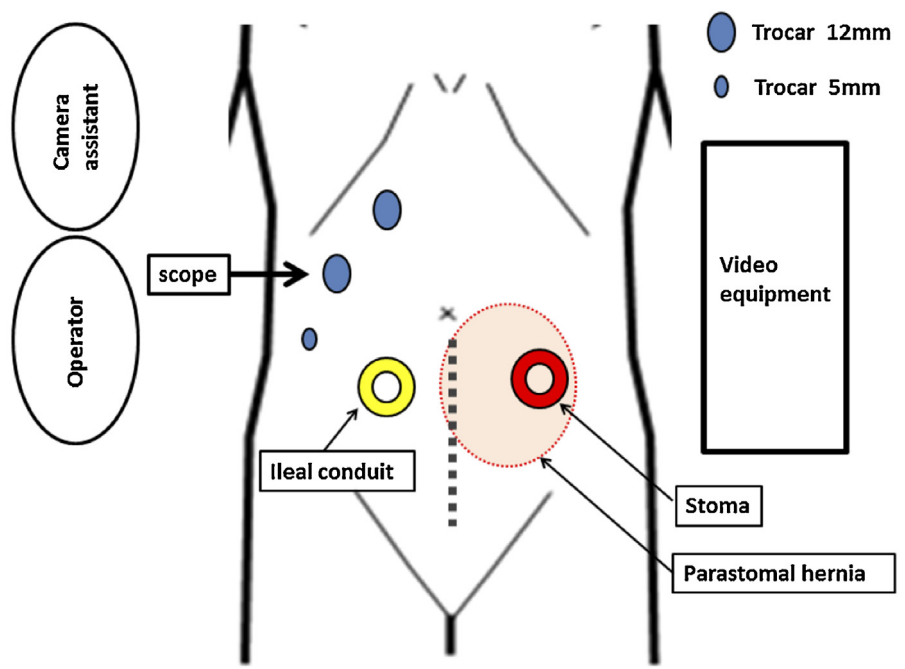


Fig. 2. Positioning of trocars, operator, and equipment for the laparoscopic surgery.

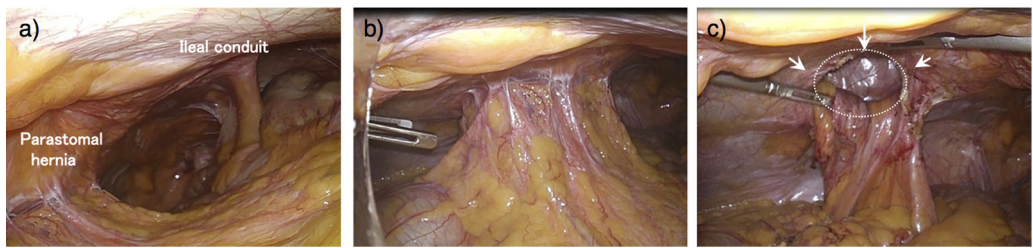
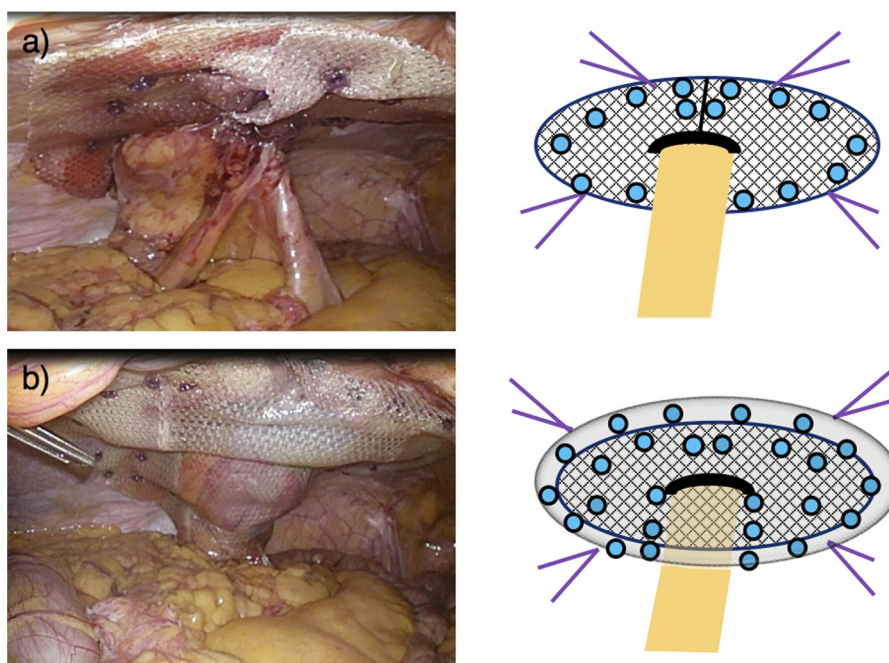


Fig. 3. Laparoscopic views of operation procedures. a) Laparoscopic views of a parastomal hernia and an ileal conduit. b) Greater omentum and transverse colon protruded into the hernia sac. c) A parastomal fascial gap was completely freed. Dotted line indicates a parastomal fascial gap.

Three ports were placed as follows: a 12-mm trocar on the right side of the umbilicus for a flexible laparoscope; a 12-mm trocar in the right subcostal region; and a 5-mm trocar in the right lower quadrant, while taking care to avoid injuring the ileal conduit (Fig. 2). In this case, these trocars needed to be placed at more cranial position than usual because of an ileal conduit (Fig. 3a). Careful adhesiolysis of the abdominal wall around the stoma was performed by sharp dissection. A parastomal fascial gap was completely freed from the greater omentum and transverse colon, which protruded into the hernia sac (Fig. 3b and c). The hernia

orifice was 5.2 × 4.8 cm in diameter. A concomitant incisional hernia was not present. After identification of the orifice of parastomal hernia, the stoma loop was completely dissected free from the peritoneal adhesion to become a straight line. The appropriate size of the mesh was selected enough to cover the hernia orifice by at least 5 cm in all directions. We used Paritex™ Composite (PCO) mesh (Covidien, Mansfield, MA, USA): a hole type (15 × 15 cm with 35 mm hole) and a central band type (15 × 15 cm). A mesh (hole type) incised to the center was placed around the stoma to cover the orifice of parastomal hernia using the keyhole technique (Fig. 4a).



**Fig. 4.** Operation procedures of the sandwich technique.

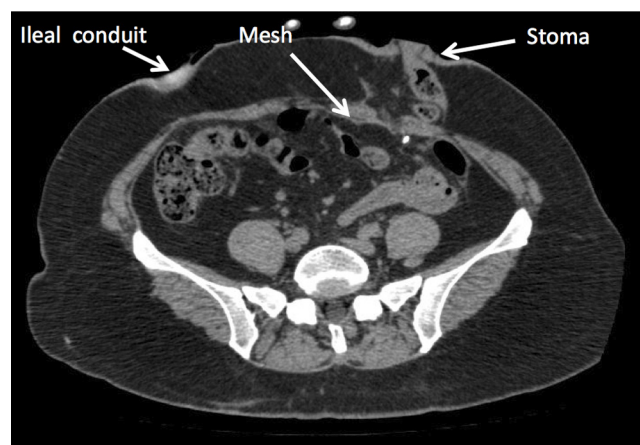
a) Composite mesh was applied by the keyhole technique. Laparoscopic views (left) and its illustration figures (right). b) A further mesh (central band type) was overlaid to cover the first mesh and the whole abdominal wall by the Sugarbaker technique. Laparoscopic views (left) and its illustration figures (right). In illustration figures (right), purple lines represent stay sutures, while blue circles do absorbable tacks.

The mesh was fixed by nonresorbable stay sutures and absorbable tacks (AbsorbaTack™ 5-mm fixation device; Covidien), with the incised parts of the mesh medially closed. Absorbable tacks were placed around the periphery of the mesh, approximately 1 cm apart. Afterwards, a further mesh (central band type) was overlaid to cover the first mesh and the whole abdominal wall by the Sugarbaker technique (Fig. 4b). After fixation of the second mesh by nonresorbable stay sutures and absorbable tacks, the stoma loop was placed between both meshes to facilitate the desired lateralization. Around the stoma loop, a one finger-wide space was left to avoid stricture by the mesh. In brief, the recurrent parastomal hernia was repaired by the recently described sandwich technique with two meshes implanted in an intraperitoneal onlay position. The abdomen was closed without intraperitoneal drainage.

The operative time was 113 min, and the estimated blood loss was a negligible amount. Two weeks after the operation, the patient was discharged without any event. She has been followed up for more than 3 years without any signs of recurrence (Fig. 5).

### 3. Discussion

A parastomal hernia is an incisional hernia related to the pressure of an enterostomy. Risk factors for parastomal hernia include clinical conditions to increase abdominal muscle pressure, i.e., obesity/BMI, waist circumference, chronic obstructive pulmonary disease, and ascites, and those to cause weakness of the abdominal wall, i.e., increasing age, malnutrition, multiple operations, and steroid use [2]. Although most parastomal hernias can be managed conservatively, a small but substantial number of patients develop severe complications such as bowel obstruction, incarceration or strangulation, which can become life-threatening. In this case, the patient underwent multiple abdominal surgeries in addition to having other comorbidities including bronchial asthma, type 2 diabetes mellitus and severe obesity. Furthermore, she had an ileal conduit in the right lower abdomen and an end stoma in the left lower abdomen. She was repeatedly hospitalized for short



**Fig. 5.** Abdominal CT scans showed no recurrence for more than 3 years after surgery.

terms because of severe abdominal pain and constipation caused by recurrent parastomal hernia, and thus she strongly desired to undergo the operation for recurrent parastomal hernia. The orifice of recurrent parastomal hernia was larger than 5 cm and there was not a concomitant incisional hernia. Therefore, this case is classified as Type III according to the European Hernia Society classification of parastomal hernia [3]. Here we report a case of recurrent parastomal hernia which was successfully treated by laparoscopic surgery using the sandwich technique while preserving an ileal conduit.

The surgical techniques available for parastomal hernia repair are relocation of the stoma or repair with or without the use of prosthetic mesh, either by an open or by a laparoscopic approach. The results of National Surgical Quality Improvement Program (NSQIP) in American College of Surgeons (ACS) indicated that laparoscopic parastomal hernia repair was associated with a shorter operative time and hospital stay as well as a lower risk of overall morbidity.



ity and surgical site infection [4]. The two laparoscopic approaches most cited in the literature are the keyhole technique and the Sugarbaker technique. The keyhole technique was described in 1977 by Rosin and Bonardi [5], and consists of using an intraperitoneal mesh with a key hole-like slit covering the hernia orifice, which allows bowel to pass through the mesh to the stoma site. The Sugarbaker technique was reported by Sugarbaker in 1980 [6], and consists of placing a mesh sheet as an intraperitoneal patch and lateralizing the bowel to allow the stoma site to be covered by the mesh. Regarding the recurrence rate following parastomal hernia repair, meta-analysis comparing surgical techniques recently reported that suture repair resulted in a significantly increased recurrence rate when compared with mesh repair, and that the Sugarbaker technique was associated with a decreased risk for recurrence as compared to the keyhole technique in the laparoscopic repair group [7]. In the keyhole technique, flat meshes with a key hole-like slit cannot sufficiently cover the edge areas of the stoma where the hernias occur [7]. In the Sugarbaker technique, one theoretical concern is that lateralizing the bowel could lead to severe bowel-obstructing angulation. In addition, a lateral portion of the parastomal hernia orifice cannot be covered well, which could lead to the lateral recurrence. The sandwich technique was recently reported to be superior to the Sugarbaker technique [8], despite other previous reports showed promising results with the Sugarbaker technique. The recurrence rate following the sandwich technique was reported to be only 2.1%, although it was calculated from only 47 cases in one institution [9]. The reason for this low recurrence rate may be due to the availability of an overlap of two or more meshes. Guidelines for laparoscopic treatment of ventral and incisional abdominal wall hernias (International Endohernia Society [IEHS]) describes that the sandwich technique can be considered a safe alternative to the keyhole or Sugarbaker techniques [10]. In this case, an ileal conduit was relatively close to the recurrent parastomal hernia of an end stoma (Fig. 3a), which suggested that it seemed to be difficult to cover the hernia orifice with a sufficiently wide range by the keyhole or Sugarbaker techniques. It was reported a minimum of 5 cm overlap between the mesh and the adjacent fascia is mandatory to prevent recurrent hernias for the Sugarbaker technique [11]. Therefore, we selected the sandwich technique to more effectively reduce the risk of recurrence. However, the main problem of the sandwich technique is the possibility of producing a stenosis of the stoma loop. It was reported that a stenosis was occurred following the sandwich technique in two cases (2.1%) out of 47 cases [9]. The sandwich technique often raises concern because of the sharp edges of the keyhole mesh which might lead to bowel erosion, and because of the anatomical change due to the lateralization that may lead to bowel obstruction. We suppose that, for the sandwich technique, it is important to prepare the appropriate mesh in size for the hernia orifice, not to narrow a key hole-like slit too much, and not to tighten the mesh fixation of the Sugarbaker technique too much. The sandwich technique for parastomal hernia is rare, and only one series have been reported previously in the English literature [8,9]. Although further cases are required to get definitive conclusions, we suppose that the laparoscopic sandwich technique can be useful for parastomal hernia.

#### 4. Conclusion

We present a rare case of recurrent parastomal hernia treated laparoscopically while preserving an ileal conduit using the

sandwich technique which combines the keyhole and Sugarbaker techniques. The patient has been followed postoperatively for more than 3 years without any sign of recurrence. Laparoscopic sandwich technique can be useful for parastomal hernia.

#### Conflict of interest

None.

#### Funding

None.

#### Ethical approval

Not applicable.

#### Consent

Written informed consent was obtained from the patient for publication of this case report and accompanying images. A copy of the written consent is available for review by the Editor-in-Chief of this journal.

#### Author contribution

TW drafted the manuscript, and KK had revised the manuscript critically. SH and YS added important intellectual comments. All authors read and approved the final manuscript.

#### Guarantor

None.

#### References

- [1] A. Cingi, T. Takir, A. Sever, A.O. Aktan, Enterostomy site hernias: a clinical and computerized tomographic evaluation, *Dis. Colon Rectum* 49 (2006) 1559–1563.
- [2] C.H. O'Neill, E.C. Borrazzo, N.H. Hyman, Parastomal hernia repair, *J. Gastrointest. Surg.* 19 (2015) 766–769.
- [3] M. Smietanski, M. Szczepkowski, J.A. Alexandre, D. Berger, K. Bury, J. Conze, B. Hansson, et al., European Hernia Society classification of parastomal hernias, *Hernia* 18 (2014) 1–6.
- [4] W.J. Halabi, M.D. Jafari, J.C. Carmichael, V.Q. Nguyen, S. Mills, M. Phelan, et al., Laparoscopic versus open repair of parastomal hernias: an ACS-NSQIP analysis of short-term outcomes, *Surg. Endosc.* 27 (2013) 4067–4072.
- [5] J.D. Rosin, R.A. Bonardi, Paracolostomy hernia repair with Marlex mesh: a new technique, *Dis. Colon Rectum* 20 (1977) 299–302.
- [6] P.H. Sugarbaker, Prosthetic mesh repair of large hernias at the site of colonic stomas, *Surg. Gynecol. Obstet.* 150 (1980) 576–578.
- [7] B.M. Hansson, N.J. Slater, A.S. van der Velden, H.M. Groenewoud, O.R. Buyne, I.H. de Hingh, et al., Surgical techniques for parastomal hernia repair: a systematic review of the literature, *Ann. Surg.* 255 (2012) 685–695.
- [8] D. Berger, M. Bientzle, Laparoscopic repair of parastomal hernias: a single surgeon's experience in 66 patients, *Dis. Colon Rectum* 50 (2007) 1668–1673.
- [9] D. Berger, M. Bientzle, Polyvinylidene fluoride: a suitable mesh material for laparoscopic incisional and parastomal hernia repair! A prospective, observational study with 344 patients, *Hernia* 13 (2009) 167–172.
- [10] R. Bittner, J. Bingener-Casey, U. Dietz, M. Fabian, G. Ferzli, R. Fortelny, et al., Guidelines for laparoscopic treatment of ventral and incisional abdominal wall hernias (International Endohernia Society [IEHS])—Part III, *Surg. Endosc.* 28 (2014) 380–404.
- [11] S. Stelzner, G. Hellmich, K. Ludwig, Repair of paracolostomy hernias with a prosthetic mesh in the intraperitoneal onlay position: modified Sugarbaker technique, *Dis. Colon Rectum* 47 (2004) 185–191.

#### Open Access

This article is published Open Access at [sciencedirect.com](https://www.sciencedirect.com). It is distributed under the [IJSCR Supplemental terms and conditions](#), which permits unrestricted non commercial use, distribution, and reproduction in any medium, provided the original authors and source are credited.