

# Laparoscopic Repair of Ileal Conduit Parastomal Hernia Using the Sling Technique

Brian Mirza, MD, Bipan Chand, MD

## ABSTRACT

Laparoscopic parastomal hernia repair has become a viable option to overcome the challenges that face the hernia surgeon. Multiple techniques have been described over the last 5 years, one of which is the lateralizing “sling” technique, first described by Sugarbaker in 1980. In this study, we report the technique and our early results with the laparoscopic modified Sugarbaker repair of parastomal hernias after ileal conduit.

**Key Words:** Parastomal hernia, Laparoscopic surgery, Mesh, Ileal conduit.

## INTRODUCTION

Parastomal hernia is a common complication of stoma formation; the reported incidence is variable depending on the degree, the duration of follow-up, and the type of stoma. The incidence for colostomies ranges from 4% to 48.1%,<sup>1</sup> for ileostomies 1.8% to 28.3%,<sup>1</sup> and for ileal conduits 2% to 6.5%.<sup>2</sup>

Most parastomal hernias remain asymptomatic; however, 10% to 20% become symptomatic and require surgical repair. Symptoms include pain, poor fitting of an appliance, prolapse, or obstruction.

Early described repair methods include primary local repair and relocation of the stoma. However, both techniques were associated with unacceptably high recurrence rates of 46% to 100% and 36.3%, respectively.<sup>1,3-6</sup>

The introduction of prosthetic meshes significantly decreased the recurrence rates<sup>7-10</sup> associated with parastomal hernia repair. Two techniques using mesh repair have been described, the keyhole technique first described by Rosin and Bonardi in 1977<sup>8</sup> and the sling lateralizing technique described by Sugarbaker in 1985.<sup>9</sup>

Minimally invasive surgery revolutionized hernia surgery, decreasing postoperative pain, recovery time, and minimizing many of the morbidities associated with open procedures. Generally, 3 techniques have been described for laparoscopic parastomal hernia repair. The first is the keyhole technique, the second is the double keyhole technique, and the third is the bowel lateralizing or the modified Sugarbaker technique, which was reported in 1980 and reproduced laparoscopically for paracolostomy hernia by Voitk in 2000.<sup>11</sup> This technique has to date the lowest recurrence rate in reported series, both open and laparoscopic.<sup>9,11-14</sup>

In this study, we report 2 cases of the laparoscopic modified Sugarbaker technique applied to repair 2 ileal conduit parastomal hernias. The technique is described, and our early results are reported.

## METHODS

In 2005, two patients with ileal conduit underwent elective laparoscopic repair of symptomatic parastomal hernia

Minimally Invasive Surgery, Department of General Surgery, The Cleveland Clinic Foundation, Cleveland, Ohio, USA (all authors).

Address reprint requests to: Brian Mirza, MD, Mary Washington Hospital, 1101 Sam Perry Blvd, Ste 203, Fredericksburg, VA 22401, USA. Telephone: 540 899 1340, Fax: 540 899 1346, E-mail: bibarmirza@hotmail.com

© 2008 by JLS, *Journal of the Society of Laparoendoscopic Surgeons*. Published by the Society of Laparoendoscopic Surgeons, Inc.

in the Department of General Surgery of the Cleveland Clinic Foundation.

### Patient 1

A 56-year-old male patient with bladder cancer underwent radical cystoprostatectomy and bilateral pelvic lymphadenectomy with Indiana pouch continent cutaneous diversion in 2004. The stoma was brought out through the umbilical scar. The patient developed a parastomal hernia and complained of parastomal pain and intermittent difficulties in accessing the pouch.

The patient underwent a laparoscopic hernia repair while under general anesthesia. Preoperative measures included standard bowel preparation and perioperative antibiotics.

The patient was positioned supine with both arms tucked. The monitors were placed more toward the foot of the bed and rotated 45 degrees to face the operating surgeon and the first assistant. The surgeon stood on the left side of the patient and the first assistant on the right. The pouch was then aseptically cannulated with a Foley catheter, and the abdominal wall skin was prepped and covered with an iodine impregnated plastic adhesive drape (Ioban).

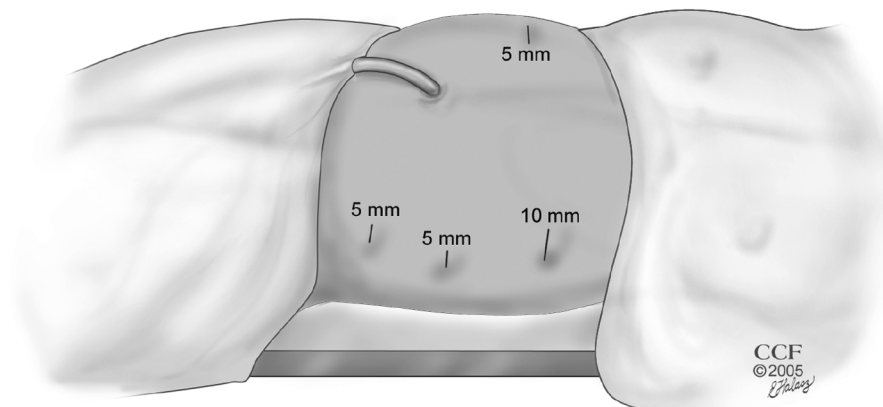
The abdomen was accessed using the 10-mm Endopath trocar (Ethicon Endosurgery, Inc., Cincinnati, OH) in the left upper quadrant of the abdomen. And under laparoscopic vision, 2 additional 5-mm trocars were placed in the left abdomen laterally at the anterior axillary line. A fourth 5-mm trocar was placed in the right upper quadrant (**Figure 1**).

A tedious lysis of adhesions was then performed with minimal use of thermal energy. The lateral adhesions of

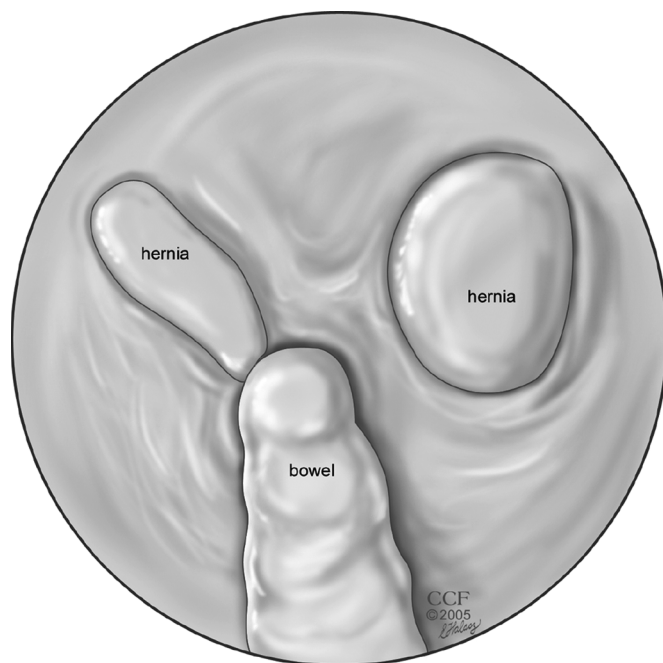
the stoma and its mesentery to the right abdominal wall were left intact (**Figure 2**).

The parastomal and an unexpected incisional hernia defect were identified and measured 5 cm x 3 cm and 5 cm x 4 cm, respectively (**Figure 2**). The measurements were made by using a spinal needle passed through the abdominal wall to determine and draw the borders of the defects on the abdominal skin. Those measurements were also confirmed by using an intraabdominal measuring tape introduced through the 10-mm trocar then removed. We then added 4cm to the drawing on the abdominal wall skin in all directions to assure appropriate overlap of the mesh over all the defects and the stoma site. It is important to mention here that the abdominal cavity should be deflated when drawing the hernia and the mesh size on the Ioban covering the abdominal wall. The reason is that the measurements at the skin level when the abdomen is distended are much greater than at the peritoneal level.

The mesh was then cut to the size of the final drawing; a 16 cm x 16 cm Dual mesh patch (WL Gore & Assoc, Flagstaff, AZ) was used. The corners of the mesh were trimmed, and 4 corner stay sutures were sewn to the 4 corners of the mesh by using 0 polypropylene sutures; those sutures' tails were left long (15 cm to 20 cm). The soft side and the direction of the mesh were marked with a surgical marker pen. The mesh was then rolled from each end to the middle of the mesh to make it easier to unroll once in the abdominal cavity. The rolled mesh was introduced into the abdominal cavity by grasping it with a grasper placed through the right upper quadrant trocar and exiting through the large left upper quadrant trocar and pulling it into the abdomen. Gore-Tex mesh is very compressible and has the advantage that even a very large




**Figure 1.** Trocar placement.



**Figure 2.** Laparoscopic view of the hernia defects and the pouch after removal of the adhesions in patient 1.

mesh can easily be pulled through a 5-mm or 10-mm port site. This is not the case for a polypropylene type of mesh. The mesh was then unrolled, and the 4 stay sutures were passed through the abdominal wall using the suture passer at the corners of the drawing on the abdominal wall. It is important here to mention that the far lateral 2 stay sutures secured to the mesh side that lateralize the pouch should be passed through first to assure good coverage laterally, then the closer stay sutures can be passed. Those stay sutures can be tightened or loosened to obtain an ideal coverage of the defects and the pouch. At this point and as the stay sutures were being tightened, the pouch was lateralized (slung) to the right and the mesh was lifted against the abdominal wall with appropriate overlap of at least 4 cm in all directions. The mesh was then tacked in position to the abdominal wall in its periphery using the 5-mm tacking device; this was started on the medial side (medial to the stoma) first then circumferentially to assure appropriate overlap on all edges of the hernia defects and the pouch (**Figure 3**). A second inner row of tacking was then used; care was taken not to tack through the pouch or its mesentery. Additional transfixing U-stitches were then placed in the periphery at an interval of 5 cm using the suture passer needle. Laterally on the right side over the lateralized pouch and its mesentery, the mesh edge was tacked and suture fixated, leaving only a small area



**Figure 3.** Laparoscopic view of the mesh repair. Notice the tacks, transfixing sutures, and the mesh overlap.

for the passage of the conduit and its mesentery (**Figure 3**). The pouch was not sutured to the mesh but simply was covered by it. The trocars were removed and the pneumoperitoneum was evacuated. A flexible pouchoscopy was performed and showed the pouch to be intact, patent, and viable.

### Patient 2

A 63-year-old male patient with a history of prostate cancer and dysfunctional bladder underwent a cystoprostatectomy and Indiana pouch continent cutaneous diversion through the umbilical scar in 2004. The patient developed some pain surrounding his umbilical stoma and was found to have a parastomal hernia on physical examination. CT scan of the abdomen showed the hernia.

The patient underwent an elective repair of his hernia laparoscopically in a similar manner as the previous patient. The hernia defect was parastomal in position and measured 6 cm x 7 cm. The mesh used was 15 cm x 15 cm.

### RESULTS

Both patients experienced no perioperative complications. The operative time was 190 minutes for the first patient and 150 minutes for the second. Blood loss was less than 100 mL in both cases. Oral diet was resumed on

the evening of the operation. The patients were both discharged home on the second postoperative day. They had minimal pain on discharge and were ambulating with minimal restriction for heavy lifting.

At the time of this writing, both patients were asymptomatic with no signs of infection, seroma formation, pouch malfunction, recurrence, or any other complications. The follow-up period is 18 months for the first patient and 17 months for the second patient.

## DISCUSSION

Parastomal hernias are common complications of stoma surgery. The disappointing results associated with primary repair and stoma relocation led to the interest in enforcing the peristomal abdominal wall with synthetic meshes. This was first described in 1977 by Rosin and Bonardi<sup>8</sup> who used a polyethylene mesh to repair parastomal hernias in 7 patients. The mesh was placed around the colon, and there were no recurrences in this series. Sugarbaker<sup>9</sup> in 1985 described a different open technique to repair parastomal hernias. The mesh was placed over the hernia defect and the lateralized bowel; no orifice was made in the mesh. The mesh was secured to the hernia defect with sutures with 1cm intervals except where the colon passed laterally. Sugarbaker did not mention the mesh type used. The technique was used in 6 patients with recurrent and one patient with primary paracolostomy hernias. There were no recurrences or infections after a minimum of 4 years of follow-up.

Since then, there have been multiple reports of the open keyhole technique for parastomal hernia repair with reported recurrence rates of 14% to 43%.<sup>3,7,15–17</sup> Steele et al<sup>17</sup> reported in 2003 a series of 58 patients with parastomal hernia repaired using polypropylene mesh and the keyhole technique. The complication rate was alarmingly 36% including bowel obstruction in 9%, prolapse in 3%, wound infection in 3%, fistula in 3%, mesh erosion in 2%, and recurrence in 26%.<sup>17</sup>

The success of laparoscopic repair of incisional hernia in decreasing the recurrence rate and the complications associated with open procedures<sup>18,19</sup> led to the interest in applying the laparoscopic technique to parastomal hernia repair.

We conducted an extensive literature review of laparoscopic parastomal hernia repair using Medline (National Library of Medicine, Washington, DC) and the reference lists of all relevant articles. The review is summarized in **Table 1**.<sup>11,12,14,20–28</sup> Porcheron et al<sup>24</sup> described in 1998 the

laparoscopic preperitoneal mesh repair of a paracolostomy hernia in one patient. The mesh was simply placed over the hernia defect and was stapled in place. No slit was made in the mesh; the bowel was not covered with the mesh nor lateralized. The patient was discharged on the fourth postoperative day and had no recurrence after one year.

Voitek<sup>11</sup> in 2000 described a laparoscopic repair of paracolostomy hernias in 4 patients using a technique similar to the method described by Sugarbaker. Polypropylene mesh was used with “generous” overlap over the defect and the lateralized colon. No slit was made in the mesh that was sutured to the colon with nonabsorbable sutures and fixed to the abdominal wall with tacks. Three patients were discharged after a 2-day stay and one patient after 9 days. He reported no complications with follow-up of 2 months to 12 months.

LeBlanc and Bellanger<sup>20</sup> in 2002 described their method for laparoscopic paracolostomy hernia repair using Dual Mesh (WL Gore & Assoc, Flagstaff, AZ) patches in 3 patients. A circular area was cut in the center of the mesh, and a slit was made to allow the mesh to surround the bowels exiting the abdomen. The mesh was fixed in position with helical tacks and transfascial sutures, and to “prevent any migration of intestine and to bolster the abdominal wall” another similar mesh was placed on top of the first mesh with the slit location directed on the opposite side of the slit of the first mesh. The 3 reported patients were discharged the next day. A wound seroma in one patient resolved after 2 weeks, and no recurrence was reported with a follow-up of 3 months to 11 months.

LeBlanc et al<sup>12</sup> recently reported a series of 12 laparoscopic parastomal hernia repairs including 8 colostomy, 2 ileostomy, and 2 urostomy. Two different repair techniques were used. The first is the 2-patch keyhole technique described in a previous report,<sup>20</sup> and the second is an onlay technique similar to the modified Sugarbaker technique. There were 2 deaths, 1 due to aspiration, and 1 due to unrelated causes. Morbidities included 1 enterotomy, 1 ileus, 1 seroma, 1 colonic obstruction, and 1 recurrence in the 2-patch keyhole technique group (20%). They concluded that the single-patch onlay technique “might be the better alternative” technique to the 2-patch keyhole technique, requiring less operative time, and avoiding the concern of herniation through the slit in the mesh.

Hansson et al<sup>21</sup> in 2002 reported 4 patients with parastomal hernias repaired laparoscopically by first closing the defect with 2 Vicryl (Ethicon, Inc., Somerville, NJ) 1 su-

**Table 1.**  
Review of the Literature on Laparoscopic Parastomal Hernia Repair

Author	Year	Number	Stoma*	Mesh†	Technique‡	Morbidity§	Recurrence¶	Follow-up (months)
Porcheron et al <sup>24</sup>	1998	1	C.	ePTFE	K	0	0	12
Bickel et al <sup>25</sup>	1999	1	C.	Polypro.	K	0	0	12
Voitek <sup>11</sup>	2000	4	C.	Polypro.	S	0	0	2–12
Kozlowski et al <sup>26</sup>	2001	4	NS.	ePTFE	NS.	0	0	NS
Dunet et al <sup>27</sup>	2002	1	1C.	ePTFE	K	0	0	24
LeBlanc and Bellanger <sup>20</sup>	2002	3	2C., III.	Dual-M.	DK	0	0	3–11
Gould and Ellison <sup>28</sup>	2003	1	C.	Dual-M.	K	0	0	6
Deol and Shyani <sup>23</sup>	2003	1	II.	ePTFE.	K	0	0	10
Berger et al <sup>14</sup>	2003	21	NS.	Dual-M	S	a	4 (19%)	12
Hansson <sup>21</sup>	2003	3	NS.	Dual-M.	K	0	0	NA
Safadi <sup>22</sup>	2004	9	2 C. 2II, 5IC.	Dual-M.	7 K, 2 DK	b	4 (44%)	18–33
LeBlanc et al <sup>12</sup>	2005	12	8C, 2II. 2 U.	Dual-M, Mm	5 KD, 7 S	c	1 (8%) DK	3–39
Current cases	2005	2	2 IC.s	Dual-M	S	0	0	17–18

\*C = Colostomy; IL = ileostomy; IC = ileal conduit; U = urostomy; NS = not specified.

†ePTFE = expanded polytetrafluoroethylene; Polypro = Polypropylene; Mm = Mycromesh; Dual-M = Dual-Mesh (WL Gore and Associates, Inc., Flagstaff, AZ, USA).

‡28K = keyhole technique; DK = double keyhole technique; S = sling underlay (Modified Sugarbaker) technique.

¶a = 1 small bowels strangulation, 1 infection; b = 1 stoma prolapse, 1 ileus, 1 urinary retention, 1 ulnar neuropathy; c = 1 death, 1 obstruction, 1 ileus, 1 seroma, 1 enterotomy.

tures then covering it with a Gore-Tex dual Mesh with a central 2-cm keyhole surrounding the bowels of the stoma. The mesh was then sutured to the bowels with 2 seromuscular U-stitches. The mean hospital stay was 5 days, and no recurrence was reported with a follow-up of up to 14 months.

Safadi<sup>22</sup> in 2004 reported his institution’s experience with laparoscopic parastomal hernia repair in 9 patients. Gore-Tex Dual Mesh was used in the repairs. A slit was made in all meshes, and the mesh was fixed to completely cover the defect with the slit oriented toward the “healthy” side after surrounding the bowels. Hospital stay was 2 days to 7 days. Complications included postoperative ileus in 2 patients, ulnar neuropathy in 1 patient, recurrence in 4 patients (44.4%), and stoma prolapse in 1 patient. Three of the 4 patients with recurrent hernia underwent redo laparoscopic repair, and the recurrent hernia sac was adjacent to the bowels exiting the abdomen. Safadi<sup>22</sup> suggested that multiple factors might have caused the recurrence including improper placement of the mesh, mesh retraction, or extension of the mesh slit.

In general, we can summarize the described laparoscopic techniques into 3 broad categories: the keyhole, double keyhole, and the sling underlay technique (**Table 1**).<sup>11,12,14,20–28</sup> The associated reported recurrence rate for the keyhole and double keyhole techniques is 0% to 44%, while it is 0% to 19% for the sling lateralizing technique. The recurrences with the sling technique were all reported by Berger and Muller.<sup>14</sup> They were “seen in the early phase of his series,” and 3 of the 4 recurrences were “clearly due to inadequate lateralization of the stoma loop.” Berger did not report whether he used transfixing sutures, and this can also be another explanation for the recurrences.

In our current cases, we performed a laparoscopic modified Sugarbaker technique (sling) to repair 2 ileal conduit parastomal hernias. We believe that the high recurrence rate seen in some of the reported series is due to the herniation of the intraabdominal content through the mesh defect around the stoma.

It seems that no matter how small the distance is between the exiting bowels and the mesh keyhole defect edge, the

intraabdominal pressure will in many cases push through the defect a bowel loop or a piece of omentum creating an enlarging parastomal hernia defect. Another possible explanation for the recurrence with the keyhole technique is the possible enlargement of the keyhole defect in the mesh overtime.

Using an intact piece of mesh with large overlap eliminates both of the above-mentioned possible mechanisms by allowing the intraabdominal pressure to play a beneficial role in lifting up the mesh against the abdominal wall. Although the helical tacks and the transfixing sutures prevent any mesh slippage, we believe that suture fixation of the mesh to the abdominal wall is mandatory to prevent recurrence. Van't Riet et al<sup>29</sup> demonstrated in a porcine model that the fixating suture's tensile strength is 2.5 times greater than that of tacks.

Suturing the mesh to the stoma as described in some reports<sup>11,23</sup> is probably unnecessary and may cause bowel erosion or mesh contamination leading to mesh infection.

Missed hernia defects are another common cause of presumed recurrence in the open series. This is eliminated when the procedure is done laparoscopically by the ability to visualize the entire undersurface of the anterior abdominal wall after lysing all the adhesions. A clear example is the first case reported in this current series with the unexpected discovery of an incisional hernia in combination with the parastomal hernia.

Many types of mesh have been used for open and laparoscopic parastomal and incisional hernia repair including but not limited to steel, silastic, polyester, polypropylene, polytetrafluoroethylene (PTFE), polyglactin, and porcine small intestinal submucosa (SIS). Each of these mesh types has advantages and disadvantages. The steel, silastic, and polyester meshes are not in general use today and of historic significance only. The polypropylene mesh is still in general use, but over the last 2 decades there have been multiple reports of fistulization<sup>17,30-32</sup> and/or bowel erosion when this type of mesh was used in close proximity to the bowel wall beside the dense adhesions that can form due to intense body reaction to the mesh materials. SIS is a new and promising mesh material that can be used safely in contaminated fields with a low risk of infection.<sup>33</sup> The accumulated experience with this type of mesh is still small with a very small number of reports in the literature besides the significant increase in cost associated with its use.

We have had a long and positive experience with the use of Dual Mesh for the repair of incisional hernias. Dual

Mesh has been used in the ventral hernia setting for years with very good results.<sup>18</sup> We believe that this mesh is very appropriate for the repair of parastomal hernias due to its very low risk of causing bowel erosion or fistulization.<sup>32</sup> The smooth visceral side of the mesh faces the bowels preventing the formation of dense adhesions. The rough surface of the mesh faces the abdominal wall and the tunneled, lateralized bowels of the stoma promoting tissue ingrowth and preventing hernia recurrence.

Gore-Tex Dual Mesh is the most commonly used mesh in laparoscopic parastomal hernia repair in recent reports (**Table 1**).<sup>11,12,14,20-28</sup> One of the disadvantages of this mesh type is the inability to see through when repairing the abdominal wall defect. We found that frequent checks of the mesh and its relation to the defect and the conduit associated with the appropriate use of the initial transfixing corner sutures for adjustments were of great help in securing the mesh in the right position.

## CONCLUSION

These early results suggest that parastomal hernia repair in patients with ileal conduit can be safely performed laparoscopically using the modified Sugarbaker technique. The procedure is described in detail in this study. Long-term follow-up and larger series are necessary to validate the findings and track the possible late complications.

## References:

1. Carne PW, Robertson GM, Frizelle FA. Parastomal hernia. *Br J Surg*. 2003;90(7):784-793.
2. Franks ME, Hrebinko Jr. RL. Technique of parastomal hernia repair using synthetic mesh. *Urology*. 2001;57(3):551-553.
3. Rubin MS, Schoetz, Jr. DJ, Matthews JB. Parastomal hernia. Is stoma relocation superior to fascial repair? *Arch Surg*. 1994; 129(4):413-419.
4. Allen-Mersh TG, Thomson JP. Surgical treatment of colostomy complications. *Br J Surg*. 1988;75(5):416-418.
5. Williams JG, Etherington R, Hayward MW, Hughes LE. Para-ileostomy hernia: a clinical and radiological study. *Br J Surg*. 1990;77(12):1355-1357.
6. Cheung MT, Chia NH, Chiu WY. Surgical treatment of parastomal hernia complicating sigmoid colostomies. *Dis Colon Rectum*. 2001;44(2):266-270.
7. Abdu RA. Repair of paracolostomy hernias with Marlex mesh. *Dis Colon Rectum*. 1982;25(6):529-531.
8. Rosin JD, Bonardi RA. Paracolostomy hernia repair with

- Marlex mesh: a new technique. *Dis Colon Rectum*. 1977;20(4):299–302.
9. Sugarbaker PH. Peritoneal approach to prosthetic mesh repair of paraostomy hernias. *Ann Surg*. 1985;201(3):344–346.
  10. Hofstetter WL, Vukasin P, Ortega AE, Anthonie G, Bert RW Jr. New technique for mesh repair of paracolostomy hernias. *Dis Colon Rectum*. 1998;41(8):1054–1055.
  11. Voitk A. Simple technique for laparoscopic paracolostomy hernia repair. *Dis Colon Rectum*. 2000;43(10):1451–1453.
  12. LeBlanc KA, Bellanger DE, Whitaker JM, Hausmann MG. Laparoscopic parastomal hernia repair. *Hernia* 2005;9(2):140–144. Epub 2004 Dec 16.
  13. Stelzner S, Hellmich G, Ludwig K. Repair of paracolostomy hernias with a prosthetic mesh in the intraperitoneal onlay position: modified Sugarbaker technique. *Dis Colon Rectum*. 2004;47(2):185–191.
  14. Berger DB, Muller AM. Technique and results of the laparoscopic repair of parastomal hernias. *Surg Endosc*. 17(suppl):S3, 2003.
  15. Morris-Stiff G, Hughes LE. The continuing challenge of parastomal hernia: failure of a novel polypropylene mesh repair. *Ann R Coll Surg Engl*. 1998;80(3):184–187.
  16. Kasperk R, Klinge U, Schumpelick V. The repair of large parastomal hernias using a midline approach and a prosthetic mesh in the sublay position. *Am J Surg*. 2000;179(3):186–188.
  17. Steele SR, Lee P, Martin MJ, Mullenix PS, Sullivan ES. Is parastomal hernia repair with polypropylene mesh safe? *Am J Surg*. 2003;185(5):436–440.
  18. Heniford BT, Park A, Ramshaw BJ, Voeller G. Laparoscopic repair of ventral hernias: nine years' experience with 850 consecutive hernias. *Ann Surg*. 238(3):391–399, 2003; discussion 399–400.
  19. Carbajo MA, Martín del Olmo JC, Blanco JI, et al. Laparoscopic treatment vs open surgery in the solution of major incisional and abdominal wall hernias with mesh. *Surg Endosc*. 1999;13(3):250–252.
  20. LeBlanc KA, Bellanger DE. Laparoscopic repair of paraostomy hernias: early results. *J Am Coll Surg*. 2002;194(2):232–239.
  21. Hansson BM, van Nieuwenhoven EJ, Bleichrodt RP. Promising new technique in the repair of parastomal hernia. *Surg Endosc*. 2003;17(11):1789–1791.
  22. Safadi B. Laparoscopic repair of parastomal hernias: early results. *Surg Endosc*. 2004;18(4):676–680.
  23. Deol ZK, Shayani V. Laparoscopic parastomal hernia repair. *Arch Surg*. 2003;138(2):203–205.
  24. Porcheron J, Payan B, Balique JG. Mesh repair of paracolostomal hernia by laparoscopy. *Surg Endosc*. 1998;12(10):1281.
  25. Bickel A, Shinkarevsky E, Eitan A. Laparoscopic repair of paracolostomy hernia. *J Laparoendosc Adv Surg Tech A*. 1999;9(4):353–355.
  26. Kozłowski PM, Wang PC, Winfield HN. Laparoscopic repair of incisional and parastomal hernias after major genitourinary or abdominal surgery. *J Endourol*. 2001;15(2):175–179.
  27. Dunet F, Pfister C, Denis R, Pascal T, Khalil H, Peillon C. Laparoscopic management of parastomal hernia in transileal urinary diversion. *J Urol*. 2002;167(1):236–237.
  28. Gould JC, Ellison EC. Laparoscopic parastomal hernia repair. *Surg Laparosc Endosc Percutan Tech*. 2003;13(1):51–54.
  29. van't Riet M, de Vos van Steenwijk PJ, Kleinrensink GJ, Steyerberg EW, Bonjer HJ. Tensile strength of mesh fixation methods in laparoscopic incisional hernia repair. *Surg Endosc*. 2002;16(12):1713–1716.
  30. Aldridge AJ, Simson JN. Erosion and perforation of colon by synthetic mesh in a recurrent paracolostomy hernia. *Hernia*. 2001;5(2):110–112.
  31. DeGuzman LJ, Nyhus LM, Yared G, Schlesinger PK. Colocutaneous fistula formation following polypropylene mesh placement for repair of a ventral hernia: diagnosis by colonoscopy. *Endoscopy*. 1995;27(6):459–461.
  32. Losanoff JE, Richman BW, Jones JW. Entero-colocutaneous fistula: a late consequence of polypropylene mesh abdominal wall repair: case report and review of the literature. *Hernia*. 2002;6(3):144–147.
  33. Franklin ME, Jr., Gonzalez, Jr. JJ, Glass JL. Use of porcine small intestinal submucosa as a prosthetic device for laparoscopic repair of hernias in contaminated fields: 2-year follow-up. *Hernia*. 2004;8(3):186–189.