

DISSERTATION ON

Locking compression plating for

distal femoral fractures –

A Short Term Outcome analysis

Submitted for

M.S.Degree examination

Branch II – Orthopaedic Surgery



INSTITUTE OF ORTHOPAEDICS AND TRAUMATOLOGY

MADRAS MEDICAL COLLEGE &

GOVERNMENT GENERAL HOSPITAL,

THE TAMILNADU DR.M.G.R. MEDICAL UNIVERSITY

CHENNAI

MARCH 2010

CERTIFICATE

This is to certify that this dissertation entitled “**Prospective study on the Locking compression plating for distal femoral fractures.**” submitted by **Dr.M.JAYAKUMAR** appearing for Part II, M.S. Branch II - Orthopaedics degree examination in March 2010 is a bonafide record of work done by him under my direct guidance and supervision in partial fulfilment of regulations of The Tamil Nadu Dr. M.G.R. Medical University, Chennai.

I forward this to The Tamil Nadu Dr. M.G.R. Medical University, Chennai, Tamil Nadu, India.

Prof. MAYIL VAHANAN NATARAJAN

M.S.Ortho.,M.Ch.Ortho(Liverpool).Ph.D.(Ortho Onco).,
D.Sc.,FAMS.,FRCS(Eng)

Director , Institute of Orthopaedics and Traumatology,

Madras Medical College &

Government General Hospital

Chennai- 600 003

DEAN,

Madras Medical College,
Govt. General Hospital,
Chennai - 600 003.

ACKNOWLEDGEMENT

Any prospective study in a place as big as this Institution requires the support and guidance of a lot of people. It would only be appropriate if all the hours they have put in are properly remembered and acknowledged. My sincere thanks to **Dr.MOHANASUNDARAM M.D.**, Dean, Madras Medical College, for permitting the utilization of the resources and clinical materials in this hospital.

I will forever be indebted to our Director **Padma Laureate PROF. MAYIL VAHANAN NATARAJAN**, M.S.Ortho., M.Ch., Ortho (Liverpool) .. D.Sc.,Ph.D., (Orthopaedic Oncology)FAMS.,FRCS(Eng). He has always been a constant source of inspiration with his advice and guiding me through the finer aspects of this study. Without him this study would not have been possible.

My sincere thanks and gratitude to **PROF. R.H.GOVARDHAN M.S.Ortho., D.Ortho.**, for his support, guidance and encouragement during the study.

My sincere thanks and gratitude to my guide **PROF.V.THULASIRAMAN M.S.Ortho., D.Ortho.**, for his constant inspiration and guidance during this study.

My sincere thanks and gratitude to **PROF. S. SUBBIAH.**, M.S.Ortho., D.Ortho., for his valuable guidance.

I am grateful to **Dr.R.SUBBIAH.** M.S.Ortho. D.Ortho, Reader in Spine Surgery, for his support in this study.

I am profoundly thankful to **Dr.NALLI R UVARAJ**,M.S. Ortho., D.Ortho., DNB Ortho., Reader in Spine Surgery, for all his valuable inputs to this study.

My special thanks to **Dr.N.B.THANMARAN** for his constant encouragement and valuable guidance throughout the study.

I sincerely thank **Dr.R.SELVARAJ, Dr.V.MAZHAVAN, Dr.B.PASUPATHI, Dr.T.R.RAMESH PANDIAN, Dr.ANTHONY VIMALRAJ, Dr.A.SHANMUGASUNDARAM, Dr.VELMURUGAN, Dr.S.KARUNAKARAN, Dr.NALLI.R.GOPINATH, Dr.K.P.MANIMARAN, Dr.PRABHAKARAN Dr.N.MUTHALAGAN, Dr. SENTHIL SAILESH, Dr. MOHAMMED SAMEER** who have each been great mentors in their own way.

I must thank all my fellow post graduates, staff members of the Department of Orthopaedic Surgery, theatre staff and Anesthetists who have all chipped in with their support during the study.

Last but not the least I am immeasurably indebted to all our patients who consented and cooperated with this study and without whom this study would not have been possible

INDEX

S.No.	TOPIC	Page No.
1.	INTRODUCTION	1
2.	AIM OF THE STUDY	3
3.	ANATOMICAL CONSIDERATIONS	4
4.	REVIEW OF LITERATURE	8
5.	MATERIALS AND METHODS	22
6.	OBSERVATION AND RESULTS	35
7.	CASE ILLUSTRATIONS	42
8.	DISCUSSION	54
9.	CONCLUSION	61
10.	BIBLIOGRAPHY	
11.	PROFORMA	
12.	MASTERCHART	

INTRODUCTION

Supracondylar fractures of the femur are becoming more common and are very challenging injuries to treat. These fractures occur in two different age groups -due to different types of injuries. In young patients these fractures occur due to high velocity injury such as road traffic accidents, fire arm injuries and sport's injuries. While in elderly patients usually low velocity injury like fall during walking, results in supracondylar fractures of the femur.

Because of the proximity of these fractures to the knee joint, regaining full knee motion and function may be difficult. The incidences of malunion, nonunion, and infection are relatively high in many reported series¹¹. In older patients, treatment may be complicated by previous joint arthroplasty.

There are multiple options for the treatment of these fractures with their associated merits and demerits. Anatomical restoration of the knee joint congruity proper alignment and secure fixation of both proximal and distal fragments are the key to achieve good functional outcome in these fractures to prevent early secondary osteoarthritis.

Early surgical stabilization can facilitate care of the soft tissue, permit early mobility and reduces the complexity of nursing care. Open reduction and internal fixation has been advocated, using implants, including angled blade plate, fickle devices, Rush rods, Ender nails, dynamic condylar screw, condylar buttress plate and interlocking nails. dynamic condylar screw.

AIM OF THE STUDY

The aim of the study is to analyze the short term results in terms of union and functional outcome for distal 3rd femoral fractures treated with distal femoral locking compression plating.

ANATOMICAL CONSIDERATIONS⁹

The lower extremity of the femur is larger than the upper, is somewhat cuboid in form, but its transverse diameter is greater than its antero-posterior; it consists of two oblong eminences known as the condyles. In front, the condyles are slightly prominent, and are separated from one another by a smooth shallow articular depression called the patellar surface; behind, they project considerably, and the interval between them forms a deep notch, the intercondyloid fossa.

The lateral condyle is the more prominent and is the broader both in its antero-posterior and transverse diameters. When, however, the femur is in its natural oblique position the lower surfaces of the two condyles lie practically in the same horizontal plane. The condyles are not quite parallel with one another; the long axis of the lateral is almost directly antero-posterior. Each condyle is surmounted by an elevation, the epicondyle. The lateral epicondyle, smaller and less prominent than the medial, gives attachment to the fibular collateral ligament of the knee-joint. Directly below it is a small depression from which a smooth well-marked groove curves obliquely upward and backward to the posterior extremity of the condyle. This groove is separated from the articular surface of the condyle by a prominent lip across which a

second, shallower groove runs vertically downward from the depression. In the fresh state these grooves are covered with cartilage.

The medial condyle is the longer and, when the femur is held with its body perpendicular, projects to a lower level than the lateral condyle. The long axis of the medial runs backward and medialward. The medial epicondyle is a large convex eminence to which the tibial collateral ligament of the knee-joint is attached. At its upper part is the adductor tubercle, already referred to, and behind it is a rough impression which gives origin to the medial head of the Gastrocnemius.

The articular surface of the lower end of the femur occupies the anterior, inferior, and posterior surfaces of the condyles. Its front part is named the patellar surface and articulates with the patella; it presents a median groove which extends downward to the intercondyloid fossa and two convexities, the lateral of which is broader, more prominent, and extends farther upward than the medial. Their opposed surfaces of the condyles are small, rough, and concave, and form the walls of the intercondyloid fossa. This fossa is limited above by a ridge, the intercondyloid line, and anteriorly by the central part of the posterior margin of the patellar surface. The posterior cruciate ligament of the knee-joint is attached to the lower and front part of the medial wall of

the fossa and the anterior cruciate ligament to an impression on the upper and back part of its lateral wall.

The lower and posterior parts of the articular surface constitute the tibial surfaces for articulation with the corresponding condyles of the tibia and menisci. These surfaces are separated from one another by the intercondyloid fossa and from the patellar surface by faint grooves which extend obliquely across the condyles. The lateral groove is the better marked; it runs lateralward and forward from the front part of the intercondyloid fossa, and expands to form a triangular depression. When the knee-joint is fully extended, the triangular depression rests upon the anterior portion of the lateral meniscus, and the medial part of the groove comes into contact with the medial margin of the lateral articular surface of the tibia in front of the lateral tubercle of the tibial intercondyloid eminence. The medial groove is less distinct than the lateral. It does not reach as far as the intercondyloid fossa and therefore exists only on the medial part of the condyle; it receives the anterior edge of the medial meniscus when the knee-joint is extended. Where the groove ceases laterally the patellar surface is seen to be continued backward as a semilunar area close to the anterior part of the intercondyloid fossa; this semilunar area articulates with the medial

vertical facet of the patella in forced flexion of the knee-joint. The tibial surfaces of the condyles are convex from side to side and from before backward. Each presents a double curve, its posterior segment being an arc of a circle, its anterior, part of a cycloid.

APPLIED ANATOMY

Supracondylar fracture of the femur is a particularly dangerous fracture because the distal fragment is drawn backwards by the gastrocnemius and the plantaris. Due to this the popliteal vessels and the internal popliteal nerve may either be wounded primarily or may be stretched by the sharp upper edge of the distal fragment. The artery lying deepest is the most liable to injury followed by the vein and finally the nerve. Gangrene necessitating amputation can occur due to this injury if unnoticed or presented late. So during reduction and internal fixation the knee should be flexed so as to relax the gastrocnemius and the plantaris pulling the distal fragment (fig.1).

REVIEW OF LITERATURE²¹

Supracondylar fractures of the femur usually occur as a result of low-energy trauma in osteoporotic bone in elderly persons or high-energy trauma in young patients¹⁷. Fractures proximal to knee replacements may be caused by notching of the anterior cortex when the surgeon placed the prosthesis or may be secondary to the stress riser effect of the interface between the rigid metal and soft bone. Pathologic fractures may also occur through metastatic lesions or primary bone tumors in this area.

Supracondylar femur fractures require anatomically stable internal fixation for best results, which usually necessitates surgical treatment. These fractures usually occur in elderly patients with multiple comorbidities and osteoporotic bone; thus, a high rate of complications exists

Non operative Therapy

No specific medical therapy for supracondylar femur fractures exists. If the patient is unable to tolerate surgery, temporary traction can be used to maintain length and alignment. Traction allows non-operative restoration of length and alignment while the patient is stabilized for surgery, but it is associated with the major complications of prolonged bed rest when used as definitive treatment. For non displaced and stable

fractures, bracing can provide enough stability to control pain and allow healing; however, bracing cannot control alignment or length because immobilizing the joint above and below is impossible.

Technical details in traction¹⁶

1. The threaded wire in the proximal tibia is placed more posteriorly on the medial side so that it lies parallel to the floor when the tibia is externally rotated 15 or 20 degrees.
2. The Pearson's leg piece is attached to the Thomas splint at the level of the fracture and padded so that the distal fragment, patella and tibia are lifted forward.
3. The Pearson's leg piece is flexed about 20 degrees in relation to the Thomas splint (fig.2).

fig.1: Pull of the distal fragment by the two heads of Gastrocnemius and Plantaris

Fig.2: With one tibial pin traction, moving the Pearson knee attachment proximally, so the apex of the leg support is at the level of the fracture, allows for correction of the typical extension i.e, posterior displacement deformity

Surgical Therapy^{11,22}

Surgical therapy requires reduction followed by fixation to maintain alignment. Options include external fixation or internal fixation. Internal fixation is with intramedullary devices (eg, flexible rods, more rigid retrograde or antegrade rods) or extramedullary plates and screws¹⁸.

Supracondylar femur fracture treated with a dynamic condylar screw plate:

This device allows fixed-angle stabilization of the fracture, which usually prevents late loss of reduction, but it is technically limited because it cannot be used to fix multiple fragments (fig.3).

Supracondylar femur fracture treated with a blade plate

This device allows fixed-angle stabilization of the fracture, which usually prevents late loss of reduction, but it is technically limited because it cannot be used to fix multiple fragments (fig.4).

Supracondylar femur fracture treated with a supracondylar buttress plate

This device provides multiple holes for screw fixation of multiple fragments, but it is not a fixed-angle implant so it may allow late deformity (fig.5).

Supracondylar femur fracture treated by retrograde intramedullary nail

Intramedullary devices are mechanically stronger than plates but have limited ability to control multiple fragments and require exposure through the knee joint (fig.6).

Supracondylar femur fracture treated with Zickel flexible intramedullary rods

These devices act as an internal splint and can be placed rapidly with minimal blood loss and surgical exposure but do not control length and alignment (fig.7).

Supracondylar femur fracture treated with external fixation and minimal internal fixation¹⁹

This technique allows immediate restoration of length and alignment with minimal surgical exposure, but it often cannot hold the alignment in the long term and has associated problems with pin care (fig.8).

Supracondylar femur fracture treated with a tibial buttress plate

This type of plate is rarely used for these fractures but can allow low-profile fixation of stable fracture patterns.

Fig.3:Supracondylar femur fracture treated with a dynamic condylar screw plate

Fig.4: Supracondylar femur fracture treated with a blade plate

Fig.5: Supracondylar femur fracture treated with a supracondylar buttress plate

Fig.6: Supracondylar femur fracture treated by retrograde intramedullary

Fig.7: Supracondylar femur fracture treated with Zickel flexible intramedullary rods:

Fig.8:Supracondylar femur fracture treated with external fixation and minimal internal fixation

HISTORY OF PLATING^{2,3,4,5}

The date that a bone plate was first used on bone is reported to be 1565 (300 years before general anesthesia). That plate was used to repair

a cleft palate and was made out of molded gold. The late 1880's brought the next major change in bone plating; surgeons began burying the bone screws below the skin. There were many designs and ideas that developed over the next 70 years. Unfortunately, malunions, nonunions and bone infections were issues due to lack of sterile techniques, and bone plates that were biomechanically unable to provide rigid fixation. Robert Danis (1880-1962) developed the ideas of compression plating and experimented with many different designs during his lifetime. Modern bone plating started in the 1950's when a group of 15 surgeons lead by Maurice Muller formed AO/ASIF (Arbeitsgemeinschaft für Osteosynthesfragen/ Association for the study of internal fixation) to improve the principles of bone plating. AO remains purely a medical organization to advance the study of fracture treatment while Synthes is the commercial arm of the AO.

The original plates had round holes. If compression was needed for the fracture, a separate device was needed to accomplish this. The Dynamic Compression Plate (Fig.9) (DCP was introduced in 1969 and was the standard AO plate until a few years ago. The holes are shaped like an inclined and transverse cylinder. The screw head can slide down the incline when tightened in a vertical direction. The horizontal force of the screw head as it impacts the side of the angled hole results in movement of the bone fragment.

In an effort to balance rigid fixation and preservation of blood supply to the bone, the Limited Contact Dynamic Compression Plate (LC-DCP) (Fig.10) was developed and released in 1990. The plate had many design features that improved the biomechanics and use of the plate such as, thinner design while maintaining equal stiffness at the screw hole interface and between them, better hole design and of course the ability not to contact the periosteum in between the holes. At the same time when this plate was released, surgeons were looking for methods to place plates that did not require large muscle dissection and therefore destruction of the blood supply to bone (MIPO -minimally invasive plate osteosynthesis). Systems such as the Less Invasive Stabilization System (LISS), Point Contact Fixator (PC-Fix) and Schuhl's systems used principles of external fixation, internally and locking technology theory. What resulted in 2000 was the Locking Compression Plate (LCP) (Fig.11) with a Combi hole so that the techniques of conventional and locked screw technology could be used in one plate.

The original AO principles were

- Anatomic fracture reduction & fixation (as we know not always possible).
- Rigid fracture stability (not always possible).
- Preservation of blood supply through careful soft tissue approaches and fracture reduction techniques (sometimes the blood supply is damaged from the injury).
- Early return to function of the plated limb (difficult in veterinary patients to control the amount of use).

With the understanding that not all fractures can be reconstructed, the "rules" have been somewhat modified to:

- Long bones must have axial re-alignment but not necessarily anatomic perfection. Anatomic reduction is still necessary for joints.
- Appropriate construct stability to ensure fracture healing via direct or indirect healing.
- Atraumatic approaches and fracture reduction or minimally invasive approaches.
- Early return to mobility.

Fractures can and will heal under both conditions but that is if the appropriate condition is chosen for the appropriate fracture situation!

Fig.9: The dynamic compression plate (DCP):

Fig.10: Limited contact dynamic compression plate (LC-DCP):

Fig.11: The locked compression plate (LCP):

Fig.12: A cortical screw, a locked screw with a StarDrive head depicted:

CONVENTIONAL BONE PLATING VERSUS LOCKED COMPRESSION PLATING⁶

Conventional bone plates depend on direct plate to bone and screw to bone friction to maintain fracture fixation. Therefore the plates must be perfectly contoured prior to application to the bone. Fracture reduction can be lost from axial loads causing excessive shear forces on the construct that are greater than the frictional loads between the bone-plate-screw construct. The cortical screws can toggle which leads to screw loosening and loss of plate-bone fixation. Each screw works independently; the construct depends on a single screw's stiffness or pullout strength.

The biomechanical goals of the LCPs^{26,28} are to increase the stiffness of the construct in a biological environment. The LCP is a fixed angle construct that does not rely on screw purchase in bone. Once the screw is locked into the plate, the fixed-angle converts shear stress into

compressive stress at the screw-bone interface. The load is now perpendicular to the screw axis. In order for the construct to fail under an axial load, the bone must collapse in compression. Therefore, the strength in the LCP is the sum of all the screw and plate interfaces.

Locking screws (Fig.12) are designed with smaller threads because they are not used to generate compression between the plate and the bone. They have a larger core diameter that ensures greater bending and shear strength and dissipate the load over a larger area of bone. They have the new Star Drive head that allows 65% greater insertion torque than conventional hexagonal drivers. The Star Drive is self-retaining (stays on the screw driver without a holding device). The locked screw has a conical, double-lead thread design that facilitates alignment with the threaded plate hole.

To date, there are no randomized clinical trials in human or animals comparing the LCP plate to conventional plates (DCP and LC-DCP) in patients with similar fractures. The plates are studied and compared *in vitro* (human and animal) and in case series' and these were the sources where the information on LCP principles and indications come from. The purported indications for LCPs include:

1. Patients with poor quality bone (osteoporosis, osteomyelitis)
2. Complex periarticular fracture (especially when contouring may be difficult in the metaphyseal area)

3. Inability to get minimal number of conventional screw cortices,
4. Periprosthetic fractures
5. Nonunions from failed fixations (cortex or cancellous screw stripping or screw back-out)
6. Polytrauma cases (especially when the fractures cannot be anatomically reconstructed).

In vitro studies in bone models do show that locked screw constructs fail at higher loads than cortical screws and their advantage is magnified in osteoporotic bone.

Technical and biological LCP aspects²³ that are not known when used in animals are: the ideal number of locked screws on either side of the fracture, the number of unicortical versus bicortical screws necessary for success, indications for some plate contouring (although not exact contouring), the effects of combining conventional screws and locked screws in the same construct, indications for double plating or adding additional implants (such as plate rod constructs), if there are additive biological effects on fracture healing when LCPs are placed minimally invasively. It is technically possible to place locking plates and screws minimally invasively with proper fluoroscopic equipment.

In human studies there is little mechanical advantage in placing more than 2 locked screws on either side of the fracture. This may be

quite different in animals in such a way that the animals cannot be strictly confined to bed or have multiple limbs fractured. Fracture fixation failures with LCPs do occur; the clinical case application will address some of the reasons for this.

For distal femoral fractures two designs of LCP were available. In our study we used condylar buttress type of distal femoral LCP because of easy availability in our setup and lower cost compared to the Distal femur LISS plate.

Condylar buttress distal
femoral LCP

Distal femur LISS plate
design

MATERIALS AND METHODS

Setting

This is a study conducted in the Department of Orthopaedics, Madras Medical College, Government General Hospital, Chennai.

This study is a prospective study Conducted in the Department of Orthopaedics from September 2007 to September 2009 with a sample size of 25 cases.

Patients

Patients were randomly selected from among the admissions to the Orthopaedic ward in the Department of Orthopaedics, Government General Hospital, Chennai and recruited into the study prospectively based on the following criteria

Inclusion criteria

1. Age more than 16 years.
2. Presence of distal 3rd femoral fractures which needs to be internally fixed in displaced Muller's type A and Type C fractures.
3. Patients who give consent to be included in the study.
4. Patient who is preoperatively mobile.

Exclusion criteria

Skeletal immaturity with open physis.

Muller's type B fracture.

Undisplaced fracture patterns needing only conservative management.

Patients not willing for surgery.

Supracondylar # femur associated with # neck of femur.

Study protocol⁹

A total of 25 patients with distal 3rd femoral fractures were included in the study as per the criteria outlined previously.

On admission detailed examination of the patients was carried out after hemodynamic stabilization. Patients were then applied on a Mid tibial pin traction to immobilize and maintain the length to prevent from shortening.

Then standard Antero – Posterior and Lateral view X – Rays are taken and the fracture configuration noted. Computerized Tomography is also taken when needed to assess the exact alignment of the fragments. The fracture is classified using the following classification

Classification¹³

The classification of distal femoral fractures described by Müller et al. and expanded in the AO/OTA classification is useful in determining treatment and prognosis. It is based on the location and pattern of the fracture and considers all fractures within the transepicondylar width of the knee.

AO-ASIF classification of supracondylar femur fractures (Muller's) (Fig.13)

Type A: Extra-articular fracture

A1 - Simple

A2 - Metaphyseal, wedge

A3 - Metaphyseal, complex

Type B: Partial articular fracture

B1 - Lateral condyle (sagittal fracture line)

B2 - Medial condyle (sagittal fracture line)

B3 - Frontal (coronal fracture line)

Type C: Complete articular fracture

C1 - Articular and metaphyseal segments, simple fractures

C2 - Articular simple, but metaphyseal multifragmentary fractures

C3 - Articular and metaphyseal segments, multifragmentary fractures

Then after the assessment for anesthetic fitness open reduction and internal fixation of the fracture is done using the distal femoral locking compression plate through the lateral approach under Spinal Anaesthesia.

4.5mm Distal Femur Locking compression Plate^{7,8}(Fig.14):

The plate system has many similarities to traditional plate fixation methods with few improvements such as

Locking screws provides fixed angle construct and improved fixation in osteoporotic bones

1. The screws do not rely on plate bone compression
2. Multiple screw fixation in distal femoral condyle allows improved fixation in Type C3 fractures
3. Anatomically shaped distal end is contoured to match the distal femur and hence intra-operative contouring is not required.
4. Combi - holes have additional dynamic compression holes providing options for axial compression in addition to locking mechanism.
5. Lateralisation of proximal femur is prevented by maintaining a gap between the proximal fragment and the plate until locking screw is applied after which the alignment is maintained (Fig.14).

Fig.14: Gap between proximal fragment and plate is maintained to prevent lateralisation

Swashbuckler Approach to the Distal Femur^{13,14,15,24}


<p>nt supine, preferably on a radiolucent table.</p>		<p>Female</p>
<p>ourniquet only if necessary to avoid medial retraction</p>		
<p>triangle under the knee (Fig.15). Make a lateral incision above the fracture laterally to cross the patella</p>		
<p>ision directly down to the fascia of the quadriceps. Quadriceps fascia in line with the skin incision. Sharply divide quadriceps fascia off the vastus lateralis muscle laterally</p>		
<p>tibial band and fascia laterally, continuing the</p>		
<p>al parapatellar retinaculum, separating it from the</p>		
<p>parapatellar arthrotomy to expose the femoral</p>		
<p>or under the vastus lateralis and medialis, exposing the</p>		
<p>and displacing the patella medially.</p>		
<p>Forating vessels, and elevate the vastus lateralis, entire distal femur (Fig.17,18,19).</p>		
<p>the internal fixation as needed (Fig.20).</p>		
<p>Close the wound by suturing the fascia back in place with suction</p>		
<p>Fig.15: Sandbag kept under the affected</p>		

Fig.16: Marking of the incision

Fig.17: Distal femur exposed with perforator

Fig.18: Anterior view of

Fig.19: Joint surface

Fig.20: Fracture reduced and plate

Demographic data (age, gender and profession), mechanism of injury, severity of the injury (AO classification, open or closed fracture), associated injuries (injury severity score), initial management and time to definitive treatment were recorded. Intra-operative events and difficulties, use of bone graft, post

operative local or systemic complications, time to union and time required to return to pre-injury activities were documented. All patients at their final assessment, underwent radiological and functional evaluation using the hospital for special surgery knee score (HSS)

Postoperatively X- rays were taken to assess the alignment and early mobilization started according to the stability of the fixation. Patients were followed every monthly for examination, HSS (hospital for special surgery) score and X – rays were taken to assess the

HSS (hospital for special surgery)

Walking (none to severe): points 15–0

At rest (none to severe): points 15–0

Walking (unlimited to unable): points 12–0	
Stairs (normal to with support): points 5–2	
Transfer (normal to with support): points 5–2	
RoM (80°–120°): points 10–15	
Muscle strength (grade 5–0): points 15–0	
Flexion deformity (none to >20°): points 10–0	
Instability (none to >15°): points 5–0	
One cane: 1 point	
One crutch: 2 points	
Two crutches: 3 points	
Extension lag (5°–15°): 2–5 points	
Deformity (every 5°): 1 point	
Excellent = 85 points or more, 70–84 points, Fair = 60–69 Poor = less than 60 points.	
The total numbers of the patients were 25 with a mean age of the 35.1 years. There were 15 males and 10 females. 20 fractures were due to RTA and 1 due to fall of heavy object both were high energy trauma. 3 were due to accidentally and all 3 were females >50 yrs old. 1 fracture was in an osteoporotic	

elderly female which occurred intra-operatively while manipulation during hemiarthroplasty for fracture neck of femur.

Applying the Muller's classification one case of type A1, two cases of type A2, five cases of type A3, four cases of type C1, ten cases of type C2 and three cases of type C3. Two fractures were classified as Compound fractures with 1 grade one type and 1 grade 3B type.

Most of the fractures were provisionally stabilized pre-operatively with mid tibial pin traction and a few were stabilized by means of a above knee slab. One case of grade 3B fracture was treated with wound debridement and K – wire fixation. One case of grade 1 fracture was treated initially with wound debridement and primary

Joint mobilization was commenced after suture removal

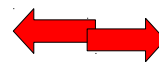
depending on the fracture pattern and the stability of fixation. Joint mobilization was delayed in 5 cases, one due to severe osteoporosis, two due to associated tibial plateau fracture and due to unstable fixation. All the delayed cases were immobilized with above knee slab.

The weight bearing status: Non weight bearing for 6 weeks followed by partial weight bearing and full weight bearing was allowed after radiological evidence of union.

All the patients were followed up with regular radiological and functional assessment with a mean follow up of 13.6 months.

Successful fracture union was defined as complete bridging callus in three cortices, together with painless full weight bearing (Fig.20).

Fig.20: Fracture union shown by



OBSERVATION AND RESULTS

The following were the observations made in the present study. The total number of the patients was 25 with 15 males and 10 females.

Sex incidence (Chart.1)

Male	
68%	32%
(17)	(8)

Age incidence (Chart.2)

Age	No. of Cases	Percentage	Males	Females
11 – 20	1	4%	1	-
21 – 30	7	28%	7	-
31 – 40	7	28%	5	2

41 – 50	2	8%	2	-
51 – 60	6	24%	2	4
62 – 70	2	8%	-	2

: Age Distribution

The youngest age in our study was 19 and the oldest age is 65 with a mean age of 35.1 years. High incidence is found in 21 to 40 yrs age group more common in males due to high velocity injuries. In more than 50 yrs age group females are predominantly affected mainly due to low velocity injuries. Right side to left side ratio was 3:2 (ie., 15 : 10).

Mode of injury (Chart.3)

Mode	RTA	Accidental fall	Fall of weight	Intra – Op
No	20	3	1	1

Mode of injury were 20 cases due to RTA, 3 cases due to accidental fall, 1 case due to fall of heavy object and 1 case was iatrogenic during reoperative reduction maneuver in hemiarthroplasty of hip. The average

months of follow up were 13.6 months with longest of 23 months and shortest of 6 months.

Muller's classification type (Chart.4)

Type	A1	A2	A3	B1	B2	B3	C1	C2	C3
No	1	2	5	-	-	-	4	10	3

Chart.4: Muller's Classification type

Of the 25 cases nine (36%) were compound fractures with five Gustilo's Grade I compound, two Grade II and one Grade IIIB.

Successful fracture union was defined as complete bridging callus in three cortices, together with painless full weight bearing. All patients were able to bear full weight postoperatively except for three patients. Excluding these patients, average time to union was 18 weeks with a range from 10 weeks to 36 weeks. Mean Range of motion was 0° - 106.8°. Using the HSS scoring system, there were fourteen excellent results, four good, four fair and three failures. Excellent and Good 72%.

Charts 5&6

HSS outcome	No of cases	Percentage
Excellent	14	56%
Good	4	16%
Fair	4	16%
Failure	3	12%

COMPLICATIONS

Complications included two implant failures of which one needed revision and in the other alignment was maintained and hence union achieved with Above Knee Cast application. There was one case of non union and one case of deep infection which needed implant exit and external fixation done. One patient had knee pain for which implant exit was done and after which he got relieved of pain.

Comparison of results of distal femoral fractures treated with LCP obtained by other studies¹²

Author	No	Open #'s %	Type A %	Type C %	Age	F/up mths	ROM°	Deep infect%	Implant Failure %	Removal due to pain %	Excellent and Good results
Kregor et al	66	N/A	50	50	49	9	2-103	3	1.5	-	-
Schutz et al	99	29	67	33	54	13.7	0-107	7	6	-	-
Markmiller et al	20	N/A	50	50	57	12	0-110	-	10	-	87.5
Apostolou et al	19	20	30	55	54.5	16	0-108	5	5	-	81.25
Yeap and Deepak et al	11	36	55	45	44	9.7	1-107.7	-	9	-	72.7
Our study	25	36	28	72	35.1	13.6	0-106.8	4	8	4	72

The comparison with other studies for distal femoral LCP as mentioned in the above table has shown similar results. The mean range of motion was 0-106.8 degrees which is similar to the other studies compared. The incidence of deep infection was 4%, with implant failure of 8% which all are comparable with the various studies. The percentage of patients with excellent and good results was 72% which is comparable and similar to the 72.7% obtained by Yeap and Deepak et al.

CASE ILLUSTRATIONS

Case – 1

40 years old male

Road Traffic Accident

Grade I compound Muller's Type C2 # Right side

Open Reduction and internal fixation with 5 holed condylar buttress locking compression plate.

Radiological fracture union: 14 weeks

Range of Motion: 0 - 135°

Implant exit done 11 months postoperatively due to pain probably due to iliotibial band irritation.

HSS: Excellent (90)

Case 1

Pre Operative

Immediate Post Operative

1 year Post OP

After Implant Exit showing Union

Clinical Outcome Knee Flexion and Extension

Case 2

35 years old female

Road Traffic Accident

Closed Muller's Type C2# Right side

Open Reduction and internal fixation with 7 holed distal femur locking compression plate.

Radiological fracture union: 12 weeks

Range of Motion: 0 – 135°

HSS: Excellent (91)

Case 2

Pre Operative

Immediate Post Operative

6 months post operative

Clinical Outcome Knee Flexion and Extension

Case 3

52 years old male

Road Traffic Accident

Grade II compound Muller's Type C2 # Right side

1st procedure – Wound debridement and cancellous screw fixation

2nd procedure - Open Reduction and internal fixation with 5 holed condylar buttress locking compression plate.

Post operative varus deformity i.e. lateralization of distal fragment was noted

Radiological fracture union: 12 weeks

Range of Motion: 0 - 120°

HSS: Excellent (86)

Case 3

Pre Operative

After 1st procedure

Immediate Post Operative

11 months post operative

Clinical Outcome Knee Flexion

Case 4

35 years old male

Road Traffic Accident

Grade I compound Muller's Type A3 # Right side

Open Reduction and internal fixation with 11 holed condylar
buttress locking compression plate.

Radiological fracture union: 12 weeks

Range of Motion: 0 - 110°

HSS: Excellent (86)

Case 4

Pre Operative

Immediate Post Operative

10 months postoperative

Clinical Outcome Knee Flexion and Extension

Case – 5

28 years old male

Road Traffic Accident

Grade I compound Muller's Type C3 # Right side

Open Reduction and internal fixation with 5 holed condylar
buttress locking compression plate.

Radiological fracture union: 12 weeks

Range of Motion: 0 - 90°

HSS: Fair (60)

Case 5

Pre Operative

Intra operative

Immediate Post Operative

20 months postoperative Clinical Outcome Knee Flexion and Extension

Complication Case 1

40/M

Road traffic accident

Muller's Type C2 Supracondylar # Left femur

Orif with 5 holed condylar buttress LCP

Postoperative alignment was good

Implant failure noted four and half months postoperatively

Outcome: Failure

Plan: Implant exit and revision osteosynthesis

Illustration Complication Case 1

Preoperative

Intra operative

Immediate postoperative X-ray

X ray showing implant failure

DISCUSSION

Treatments of the Supracondylar fractures of the femur have been a controversial subject over the past two decades. There have been changing philosophies towards surgical treatment of supracondylar fractures of femur. Close management of these fractures was the treatment of choice until 1970²¹. This was due to non availability of appropriate implants and lack of proper techniques. Apart from the usual problems of confining elderly patient to bed, conservative methods at any age may be complicated by knee stiffness, mal union and non union.

Early surgical stabilization can facilitate care of the soft tissue, permit early mobility and reduces the complexity of nursing care²⁹. Open reduction and internal fixation has been advocated, using implants, including angled blade plate, fickle devices, Rush rods, Ender nails, dynamic condylar screw, condylar buttress plate and interlocking nails. dynamic condylar screw¹².

The use of fixed angle devices such as condylar blade plate and the dynamic condylar screw (DCS) require certain amount of bone stock present, which limits their use in some fracture types. This lead to the development of condylar buttress plates for comminuted fractures. However with standard buttress plating, these fractures often fall into varus deformity. Biomechanical studies revealed that gross loosening of standard condylar buttress plate and DCS occurred because of the toggle

at the screw- plate interface. To address these issues, a first generation locking condylar plate was designed⁷. A locking plate decreases the screw-plate toggle and motion at the bone-screw interface and provides more rigid fixation. Rigid fixation is felt to be one key to the successful treatment of these fractures.

The conventional plates are associated with their own demerits such as screw pullout, implant failure and unstable fixation needing postoperative immobilization⁸. Delay in postoperative mobilization results in stiffness of the knee which is an indicator of poor outcome. Fixation in osteoporotic and comminuted fractures which was difficult previously was addressed with the invention of locking condylar buttress plate⁶.

So now with the evolution of locking compression plating for distal femoral fractures especially for the comminuted intra – articular fractures many of the older demerits could be addressed which includes the increased stability due to locking compression plating principle, multiple screw options in the distal fragment providing option for fixing the multiple fragments restoring the anatomical congruity and providing stable fixation of the distal fragment with the proximal fragment with resulting increased stability allowing for early mobilization.

Current fracture patterns which we encounter are complex comminuted types due to the prevalence of high speed vehicles mainly due to the high two wheeler population in countries like India. Improved

healthcare results in a longer lifespan and subsequently presents us with more osteoporotic fractures which were previously treated using conservative methods. The LCP is a single beam construct where the strength of its fixation is equal to the sum of all screw-bone interfaces rather than a single screw's axial stiffness and pullout resistance in unlocked plates³⁰. Its unique biomechanical function is based on splinting rather than compression resulting in flexible stabilization, avoidance of stress shielding and induction of callus formation. It can also be used as biological fixation without disturbing the fracture site³¹.

The Distal Femur-LCP is a further development from the LISS, which was introduced in the mid to late 1990's³². The main difference between the Distal Femur-LCP and the LISS is that the LISS utilizes an outrigger device for shaft holes, functioning essentially as a locking guide jig, which is attached to the distal part of the plate and guides the placement of the proximal locking screws. The shaft holes on the Distal Femur-LCP are oval allowing for the options of a compression screw or a locking screw. This leads to a more precise placement of the plate, as it is able to be compressed more closely to the bone. Although Distal Femur-LCP is designed to fit the anatomy of the distal femur, we were worried about the fit in our local Asian population where shorter and smaller femurs are the norm. During fixation in delayed cases especially if there was severe comminution maintaining the reduction in good alignment and applying the initial screw were difficult.

The average time of union was 18 weeks which is similar to the other modes of fixation and there is no additional benefit of early healing. However, thus far, our limited numbers demonstrate that this is not an issue.

Comparable studies utilizing the Distal femur LCP demonstrate similar short term results. Although the follow-up period of our series was short, studies have shown that early function is comparable to final long term outcome. The outcome seems to correlate with fracture severity, anatomic reduction, etiology, bone quality, length of time elapsed from injury to surgery, concomitant injuries and the exact positioning and fixation of the implant. The definitive long term prognosis remains unknown as of today, as the earliest LISS was implanted in the mid to late 1990's. Furthermore, the initial severe concomitant cartilage damage may predispose to early osteoarthritis although there is no evidence of that yet³³.

Of the 17 male cases 16 cases were due to RTA while travelling in a two wheeler. Of the 16 cases eleven cases (i.e., 68.7%) involved the dominant Right side which shows that the increased two wheeler population and the left sided driving regulation are to be blamed for.

One patient was encountered with deep infection which was noticed in the 5th postoperative day for which wound wash was given was done an implant exit and external fixation because of uncontrolled infection. The patient was later lost in follow up and could not be traced back.

Two patients had implant breakage^{25,27} out of whom one had the fracture alignment maintained and hence he was immobilized in a Above Knee Cast after which fracture got united and Fair result was obtained. The other had displaced fragments for which implant exit and redo was planned.

One patient had non union. Initially he had Gustilo's Grade III B compound fracture for which wound debridement and K-wire fixation was done. After that ORIF with LCP was done. There was no evidence of union at 6months post op. Later for non union bone grafting was done but still there was no progression.

There were four fair results. The first one was an implant failure. The fracture was in good alignment even after implant failure and hence conservative management with AK cast was done and resulted in a Fair result. The second one was the one with Muller's Type C3 fracture with severe comminution fixed with LCP had decreased postoperative knee mobility.

The third was an elderly female who sustained a peroperative SC# while manipulation during hemiarthroplasty for which LCP fixation was done and post operatively the operated limb was immobilized in a AK cast and mobilization was done very late due to severe comminution in the condyles which resulted in less score.

The last case was the one who had concomitant ipsilateral proximal tibia # which was planned for conservative management with AK cast for 3 months didn't allow for early mobilization and hence the outcome was fair. Our cases demonstrated only one case of crepitus during knee movement so that the implant was removed after fracture union. This complication was due to an intra-articular screw which caused irritation and pain during movement.

In Muller's C2 and C3 fractures due to the multiple screw options multiple fragments can be reduced with improved stability which cannot be achieved by using the conventional DCS which uses only one large lag screw. Also revision surgery can be done easily in LCP whereas in DCS if a revision surgery is planned the removal of the lag screw leaves a cavity in the condylar area which renders it difficult for fixation and even if fixation is done chances of failure is more due to poor bone stock.

One case had a shortening of 2.5 cm which was due to multiple procedures for the same fracture with different implants before the application of LCP which resulted in a bone loss. The fracture united well but with shortening.

Varus mal alignment was one of the complications which was encountered during the initial phase of the study. In the later phase of the study Varus mal alignment was low due to the technique of maintaining gap between the plate and the proximal fragment and hence the good alignment was maintained. Also using lengthier plates rather than using

small plates resulted in reduced rate of this complication in the later part of the study³⁴.

CONCLUSION

The Distal Femur-Locking Compression Plate is a good implant to use for fractures of the distal femur. However, accurate positioning and fixation are required to produce satisfactory results. We recommend use of this implant in Muller's Type A and C fractures. Our early results are encouraging but long term studies are needed to prove definitively acceptable outcomes so that the technique can become part of the in the armamentarium of the orthopaedic trauma surgeon.

BIBLIOGRAPHY

1. Charles S. Neer. "Supracondylar fracture of adult femur". JBJS American volume, Volume 49-A, No 4, June 1967.
2. The Evolution of AO/ASIF Bone Plating Equipment: Are They Better or Just Different? Amy S. Kapatkin, DVM, MS, DACVS
Department of Surgical & Radiological Sciences, University of California, Davis
3. AO Manual of Fracture Management. Internal Fixators: Concepts and Cases Using LCP and LISS. Wagner M, Frigg R (eds.), Thieme, Stuttgart, 2006
4. Egol KA, Kubiask EN, Fulkerson E, et al: Biomechanics of locked plates and screws. J Orthop Trauma 18(8): 488-493, 2004
5. Perren SM: Evolution of the internal fixation of long bone fractures. The scientific basis of biologic internal fixation: choosing a new balance between stability and biology. J Bone Jt Surg 84B:1092-1110, 2002
6. Stoffel K, Dieter U, Stachowiak G et al: Biomechanical testing of the LCP-how can stability in locked internal fixators be controlled? Injury 34: S-B-11- S-B19
7. Wagner M: General principles for the clinical use of the LCP. Injury 34: S-B31- S-B42, 2003

8. Zura RD, Browne JA: Current concepts in locked plating. J Surgical Orthop Advances 15(3): 173-176, 2006
9. Steven I Rabin MD, Supracondylar femur workup, medscape >medicine specialities> orthopaedic surgery> trauma
10. C.D. Apostolou Preliminary results and technical aspects following stabilisation of fractures around the knee with liss Journal of Injury, function and rehabilitation Injury Extra Volume 36, Issue 12, December 2005, Pages 529-536
11. Muhammad Ayaz Khan, Management of supracondylar fractures with Dynamic Condylar Screw (DCS), Journal of Medical Sciences January 2006, Vol. 14, No. 1
12. EJ Yeap, MS (Ortho)*, AS Deepak, MS (Ortho), Distal Femoral Locking Compression Plate Fixation in Distal Femoral Fractures: Early Results, Malaysian Orthopaedic Journal 2007 Vol 1 No 1
13. Canale & Beaty: Campbell's Operative Orthopaedics, 11th ed.
14. Hoppenfeld, Stanley, Surgical Exposures in Orthopaedics: The Anatomic Approach, 3rd Edition
15. Chapman, Chapman's Orthopaedic Surgery, 3rd Edition
16. Bucholz, Rockwood & Green's Fractures in Adults, 6th Edition

17. Martinet O, Cordey J, Harder Y, Maier A, Buhler M, Barraud GE. The epidemiology of fractures of the distal femur. *Injury*. 2000; 31(suppl 3):C62-C63.
18. Stover M. Distal femoral fractures: current treatment, results and problems. *Injury*. 2001; 32(suppl 3):SC3-SC13.
19. Ali F, Saleh M. Treatment of isolated complex distal femoral fractures by external fixation. *Injury*. 2000; 31:139-146.
20. Henry SL. Supracondylar femur fractures treated percutaneously. *Clin Orthop Relat Res*. 2000; (375):51-59.
21. Schatzker J, Home G, Waddell J. The Toronto experience with the supracondylar fracture of the femur, 1966-72. *Injury*. 1974; 6(2):113-128.
22. Mize RD, Bucholz RW, Grogan DP. Surgical treatment of displaced, comminuted fractures of the distal end of the femur. *J Bone Joint Surg Am*. 1982; 64(6):871-879.
23. Bolhofner BR, Carmen B, Clifford P. The results of open reduction and Internal fixation of distal femur fractures using a biologic (indirect) reduction technique. *J Orthop Trauma*. 1996;10(6):372-377.
24. Krettek C, Schandelmaier P, Miclau T, Bertram R, Holmes W, Tscherne H. Transarticular joint reconstruction and indirect plate osteosynthesis for complex distal supracondylar femoral fractures. *Injury*. 1997; 28(suppl 1):A31-41.

25. Button G, Wolinsky P, Hak D. Failure of less invasive stabilization system plates in the distal femur: a report of four cases. *J Orthop Trauma*. 2004; 18(8):565-570.
26. Wagner M. General principles for the clinical use of the LCP. *Injury*. 2003; 34(suppl 2):B31-42.
27. Vallier HA, Hennessey TA, Sontich JK, Patterson BM. Failure of LCP condylar plate fixation in the distal part of the femur. A report of six cases. *J Bone Joint Surg Am*. 2006; 88(4):846-853.
28. Ricci W, Zheng, Z, Jones, B, Cartner, J. Does Locked Plating Provide Improved Fatigue Properties over Nonlocked Plating and Does Bone Quality Matter? OTA Annual Meeting Poster Presentation Boston, MA; 2007.
29. Healy WI., Brooker AF. Distal femur fractures: comparison of open and closed methods of treatment. *Clin Orthop*. 1983, 174, 166.
30. Egol KA, Kubiak EN, Fulkerson E, Kummer FJ, Koval JK. Biomechanics of Locked Plates and Screws. *J Orthop Trauma* 2004; 18: 488-93.
31. Bolhofner BR, Carmen B, Clifford P. The Results of Open Reduction and Internal Fixation of Distal Femur Fractures Using a Biologic (Indirect) Reduction Technique. *J Orthop Trauma* 1996; 10(6): 372-7.

32. Frigg R, Appenzeller A, Christensen R, Frenk A, Gilbert S, Schavan R. The development of the distal femur Less Invasive Stabilization System (LISS). *Injury* 2001; 32: SC 24-31.
33. Markmiller M, Konrad G, Sudkamp N. Femur-LISS and Distal Femoral Nail for Fixation of Distal Femoral Fractures. *Clin Orthop* 2004; 426: 252-7.
34. Wong MK, Leung F, Chow SP. Treatment of Distal Femoral Fractures in the Elderly Using a Less-Invasive Plating Technique. *Int Orthop* 2005; 29: 117-20.

PROFORMA

LCP Distal Femur

Case No:..... Unit:.....

Name:..... Age/Sex:..... /.....

I.P No:.....Occupation:.....

Address:.....
.....
.....
.....Phone:
.....

Date of injury :/...../.....

Date of admission:/...../
.....

Date of definitive surgery:...../...../.....

Date of discharge:/...../.....

Mechanism of injury:

- a. Road traffic accident
 - b. Accidental fall
 - c. Industrial accident
 - d. Assault with weapon
- Others.....

Severity of injury:

- High velocity
- Moderate velocity
- Trivial

General condition:

- 1) Conscious
- 2) Drowsy
- 3) Unconscious

Haemodynamic status:

- a. Stable (Systolic BP>110 mmHg, PR<90/min)
- b. Moderately stable (Systolic BP 70 to 90 mmHg, PR 90 to 110/min)
- c. Unstable (Systolic BP<70 mmHg, PR>110/min)

Side involved: (Right/Left)

Type of injury:

4. Closed
5. Open

Grade I

Grade II

Grade III A

Grade III B

X ray findings:

Type of the fracture:

Type A: Extra-articular

- A1: simple # of metaphysic
- A2: metaphyseal wedge #
- A3: complex metaphyseal#

Type B: Partial-articular

- B1: lateral condylar # in sagittal plane

- B2: medial condylar # in sagittal plane
- B3: # of condyle in frontal plane

Type C: Complete articular

- C1: simple # of both the articular surface and the metaphysic
- C2: simple # of articular surface, multifragmentery at metaphysic
- C3: multifragmentary # of articular surface

Associated other long bone injuries: (Yes/No)

Associated head injury: (Yes/No)

Treatment history:

Treatment elsewhere if any:

Treatment in our institution:

Initial management:

Date :
____ / ____ / _____

Time interval between injury and initial management :

Procedure done :

Definitive management

Time interval :

Procedure done:

Plate :

Proximal Screws :

Distal Screws:

Cortical :

Cancellous :

Additional stabilization:

Bone grafting : (Yes / No)

Blood transfusion : (Yes / No)

Intraoperative events and difficulties :

Stability of fixation :

Immediate post operative events

Complications :

Post operative immobilization :

Post operative alignment

: _____

Limb length discrepancy: _____

Other injuries if any and their management :

FOLLOWUP

Suture removal : _____

Non weight bearing : _____

Partial weight bearing: _____

Full weight bearing : _____

Knee mobilization : _____

Radiological picture

Sign of callus
: _____

Bony union

: _____

Consolidation

: _____

Remodelling

: _____

1 st Fo llo w up	D a t e :	Complaints	
		Wound	
		Range of mobility	
		Advice	
		Asst. Sign	

F o l l o w u p	D a t e :	Complaints	
		Wound	
		Range of mobility	
		Advice	
		Asst. Sign	

F	D	Complaints	
---	---	------------	--

o l l o w u p	a t e :	Wound	
		Range of mobility	
		Advice	
		Asst. Sign	

F o l l o w u p	D a t e :	Complaints	
		Wound	
		Range of mobility	
		Advice	
		Asst. Sign	

INSTITUTIONAL ETHICAL COMMITTEE
MADRAS MEDICAL COLLEGE, CHENNAI-600 003.

Telephone : 25363970

Fax :044 - 253-5115
:044 25363970

L.Dis.No. 14597 /MES/EthicsDean/MMC/2009

Dated .09.2009

Title of the work
Principal Investigator

: "Lacking Compression Plating for distal femoral
fractures - A short term outcome Analysis".

Department

: DR. M. Jayakumar
: Pa ms ortho
: Madras Medical College Ch-3.

The request for an approval from the Institutional Ethical Committee(IEC) was considered on the IEC meeting held on 23rd September 2009 at 2.00P.M in Madras Medical College, Deans, Chamber, Chennai-3. /Pharmacology Seminar hall, Madras Medical College, Ch. 3

The members of the Committee, the Secretary and the Chairman are pleased to approve the proposed work mentioned above, submitted by the principal investigator.

The principal investigator and their term are directed to adhere the guidelines given below:

1. You should get detailed informed consent from the patients/participants and maintain confidentiality.
2. You should carry out the work without detrimental to regular activities as well as without extra expenditure to the Institution or Government.
3. You should inform the IEC in case of any change of study procedure, site and investigation or guide.
4. You should not deviate form the area of the work for which I applied for ethical clearance.
5. You should inform the IEC immediately, in case of any adverse events or serious adverse reactions.
6. You should abide to the rules and regulations of the institution(s).
7. You should complete the work within the specific period and if any extension of time is required, you should apply for permission again and do the work.
8. You should submit the summary of the work to the ethical committee on completion of the work.
9. You should not claim funds from the Institution while doing the work or on completion.
10. You should understand that the members of IEC have the right to monitor the work with prior intimation.


SECRETARY
IEC, MMC, CHENNAI


CHAIRMAN
IEC MMC CHENNAI


DEAN
MADRAS MEDICAL COLLEGE
CHENNAI

