

Management of secondary angle closure glaucoma

Parivadhini Annadurai and Trupti Sudhir Patil

Correspondence:

Parivadhini Annadurai,
Consultant,
Smt Jadhavbai Nathmal
Singhvee Glaucoma Service,
Sankara Nethralaya,
College Road,
Chennai.
Email: drap@snmail.org

Introduction

Secondary angle closure glaucomas are a separate entity from primary angle closure glaucoma. Secondary angle closure glaucoma is usually caused by multiple factors, so identification of the primary cause is important for appropriate management.

(Table 1)¹

Aqueous misdirection syndrome (AMS)

Aqueous misdirection syndrome is a post-ocular surgery secondary angle closure glaucoma characterized by raised intraocular pressure (IOP) with shallowing of central and peripheral anterior chamber (AC) in the presence of patent peripheral iridotomy (PI).

Clinical features

Aqueous misdirection has been reported post trabeculectomy, post cataract/combined surgery, and post glaucoma valve surgery, following laser peripheral iridotomy (LPI), Argon laser suture lysis, and diode cyclophotocoagulation (CPC). Risk factors include a diagnosis of primary angle closure disease, postoperative shallowing of the AC, and the use of miotic therapy. AMS occurs in 2–4% of eyes undergoing surgery for angle closure glaucoma². Proposed theories include misdirection of aqueous into the vitreous cavity, poor fluid conduction through the vitreous, decreased permeability of the anterior vitreous face, and choroidal expansion.

AMS can occur anytime from first postop day to months after surgery, characterized by elevated IOP, shallow AC, patent PI, normal fundus, and B-scan ultrasonography. Ultrasound biomicroscopy (UBM) shows anteriorly rotated ciliary processes (Fig. 1). IOP may also be normal in patients with functional bleb. It is important to confirm PI patency to rule out pupillary block.

Management

Medical management consists of hyperosmotic agents, aqueous suppressants, and cycloplegics to reduce vitreous volume and to increase permeability of the vitreous. In pseudophakic and aphakic eyes, YAG laser disruption of the posterior capsule/anterior hyaloid is performed to break the anterior hyaloid face which allows percolation of aqueous through the vitreous. Surgery is necessary if medical treatment fails to reverse the aqueous misdirection within 4–5 days³.

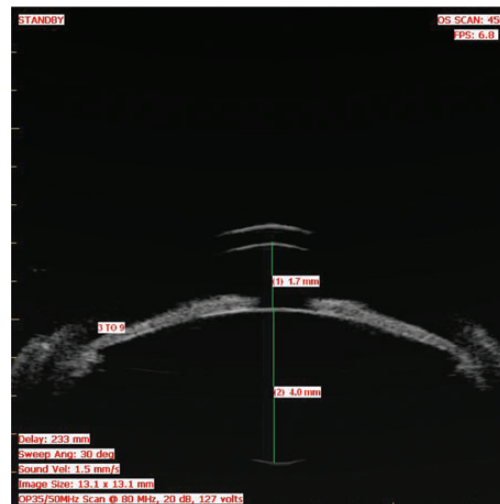


Figure 1: UBM showing shallow anterior chamber with anterior rotation of ciliary processes.

The goal of surgery is to establish direct communication between the anterior and vitreous cavity by disturbing the anterior hyaloid face. Various studies have reported resolution of AMS with vitrectomy, hyaloidozonullectomy, iridectomy, and addition of phacoemulsification in phakics^{4, 5}. Recurrences occur due to incomplete removal of anterior hyaloid and zonular fibres.

Diode CPC has also been described at an early stage in the treatment of AMS, prior to any surgical intervention in cases where medical treatment has been insufficient to control the IOP⁶.

Prophylactic measures include prolonged use of atropine after trabeculectomy surgery (with careful monitoring after this is stopped), avoidance of AC shallowing in the postoperative period (using tight scleral flap suturing) and avoiding use of miotics⁷.

Neovascular glaucoma

This is a severe form of secondary glaucoma characterized by proliferation of fibrovascular tissue in the AC angle which develops secondary to retinal ischaemia⁸.

Clinical features

NVG is commonly associated with proliferative diabetic retinopathy (PDR), central retinal vein occlusion (CRVO), and ocular ischemic syndrome. In response to tissue hypoxia, endothelial cells secrete pro-angiogenic factors such as vascular

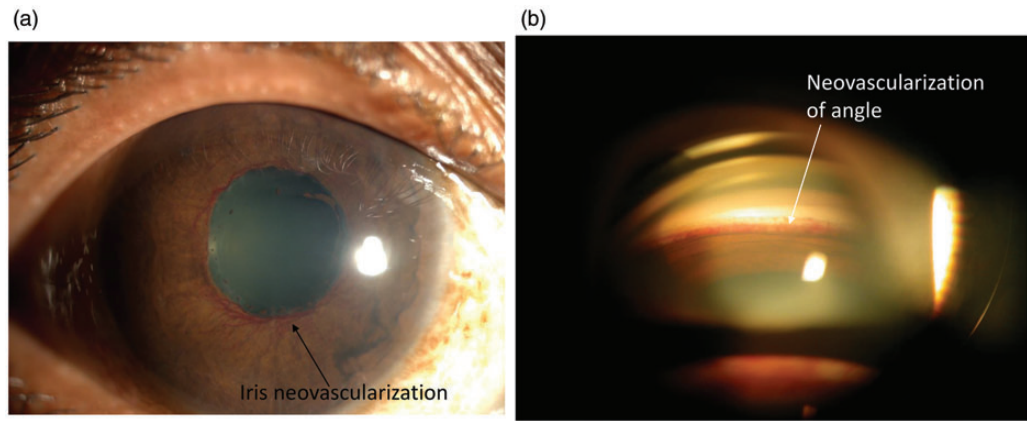


Figure 2: (a) Iris neovascularization. (b) Angle neovascularization.

endothelial growth factor (VEGF), basic fibroblast growth factor⁹. These angiogenic factors activate endothelial cells which proliferate and migrate with the formation of new, leaky, fragile blood vessels. Neovascularization may involve the iris (NVI) (Fig. 2A), the angle (NVA) (Fig. 2B) or both, causing formation of the fibrovascular membrane obstructing the aqueous outflow through the trabecular meshwork and resulting in open-angle glaucoma. As the disease progresses, the fibrovascular membrane contracts, leading to ectropion uveae and synechial angle closure.

The clinicopathologic course and treatment may be described in the following stages.

Rubeosis stage—rubeosis of iris usually begins at pupillary margin with IOP being normal at this stage. Gonioscopy should be done to look for NVA, since it can precede NVI. Pan retinal photocoagulation (PRP) decreases the metabolic oxygen demand of retina, thereby reducing the stimulus for release of angiogenesis factors¹⁰.

Open-angle glaucoma stage—neovascularization involves iris stroma and the angle, associated with normal or elevated IOP.

Angle closure glaucoma stage—overlying fibrovascular membrane contracts resulting in synechial closure of the angle and ectropion uveae leading to intractable elevation of IOP and damage to the optic nerve.

Management

Medical management includes reduction of IOP, treating the underlying cause, and control of inflammation. Prostaglandin (PG) analogues and miotics are avoided as they can worsen inflammation.

Filtration surgery has limited success with risk of intraoperative and postoperative intraocular haemorrhage. Progressive fibrovascular membrane can block the trabeculectomy stoma. PRP performed preoperatively minimizes the risk of these complications, by reducing active neovascularization. Takihara et al.¹¹ reported success rate of

trabeculectomy with mitomycin C (MMC) in NVG of 62.6% at 1 year declining to 51.7% by 5 years. Role of bevacizumab in glaucoma surgery has been studied by several authors^{13, 14}. Anti-VEGF agents are proposed to cause reduction of inflammation, vascular permeability, regression of NVI, and NVA. Kobayashi et al.¹⁵ studied the long-term outcome of pre-operative intravitreal bevacizumab for trabeculectomy with MMC in NVG eyes and reported a cumulative surgical success rate of 83.3% at 1 and 3 years in 12 eyes. PRP was found to be an important factor to delay the need for surgery¹⁶.

Glaucoma drainage devices (GDDs) reported a better outcome as the tube evades the fibrovascular membrane. Park et al.¹⁷ have reported success rates of 83.8% at 1 year and 68.5% at 3 years in 31 eyes of NVG following treatment of PDR who underwent GDD surgery. Comparable success rates were noted for non-valved implants.

Ablation of the ciliary body (CB) is reserved for symptomatic poor visual potential eyes.

Iridocorneal endothelial syndromes (ICE)

ICE is a spectrum of disorders associated with corneal endothelial abnormalities with beaten metal appearance of endothelium and iris abnormalities. Proliferation of abnormal endothelial membrane (ICE membrane) over the corneal endothelium, angle and iris leads to contraction of the membrane causing secondary synechial closure.

Clinical features

Prevalence of glaucoma associated with ICE ranges from 46 to 82%. It is subdivided into three clinical variants. Essential iris atrophy (Fig. 3A) is characterized by iris atrophy with pupillary stretching and polycoria, Chandler syndrome (Fig. 3B) with severe corneal oedema, mild iris atrophy, and Cogan–Reese syndrome with pigmented nodules over the iris (Fig. 3C). The fine, beaten metal appearance of the cornea and PAS occur in various degrees in all the subgroups.

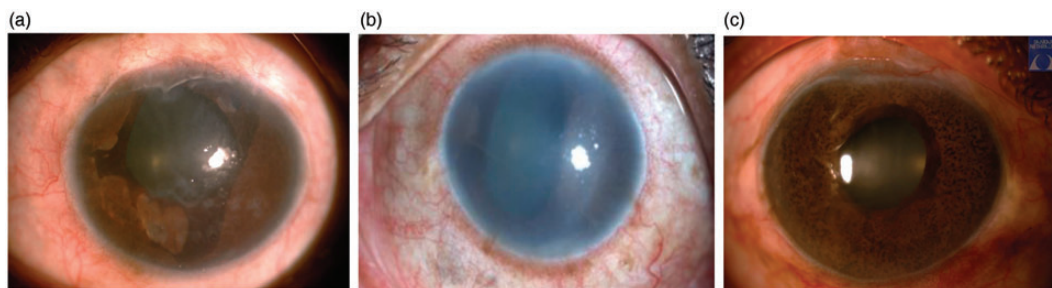

Figure 3: (a) Essential Iris atrophy. (b) Chandler's syndrome. (c) Cogan-Reese syndrome.

ICE is a unilateral condition seen most commonly in middle-aged women with IOP spike secondary to synechial angle closure and corneal oedema which later leads to corneal decompensation.

Management

ICE responds poorly to medication and surgery is eventually indicated in most cases¹⁸. Trabeculectomy yields 3- and 5-year survival rates of only 44% and 29%, respectively, compared with 71% and 53% with glaucoma drainage implants as noted by Doe et al.¹⁹. Blockage of the trabeculectomy stoma or tube lumen due to ICE membrane results in surgery failure. Revision surgery is required to relieve the tube block in almost 30% of GDD surgery²⁰. Repeated Nd: YAG laser of the tube ostium can help to maintain the tube patency over time. Corneal transplant after glaucoma drainage implant may be required in 30–50% of ICE patients²¹.

The extent of corneal involvement and the presence of secondary glaucoma decide the prognosis.

Inflammatory glaucoma

Glaucoma is one of the serious complications of uveitis which can affect the visual outcome.

Clinical features

It is seen in ~20% of these patients²². Various mechanisms can cause glaucoma such as inflammation leading into 360° posterior synechiae causing iris bombe (pupillary block) (Fig. 4), PAS, and less commonly, non-pupillary block angle closure glaucoma occurs due to CB oedema.

Due to multifactorial aetiology of ocular inflammatory disease, identifying the cause for angle closure is required for further management. Uveitis and IOP elevation needs to be treated together. Corticosteroids are necessary to control the inflammation and aqueous suppressants to control IOP. PG analogues are avoided as it can worsen inflammation and increase the risk of CME.

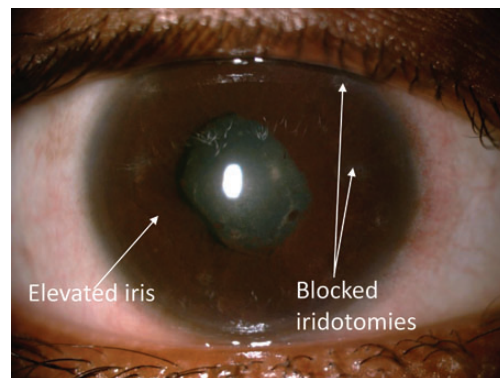


Figure 4: Iris bombe with blocked iridotomies.

Management

Iris bombe needs YAG PI, although fibrin can close small iridotomies in an inflamed eye. In case laser iridotomy is unsuccessful, surgical iridectomy may help if <75% of angle is closed.

If the above measures fail, then surgical intervention is required. Aggressive anti-inflammatory therapy should be given before and after trabeculectomy. Trabeculectomy with MMC has reported survival rates of 90% at 1 year and 79% at 2 years as noted by Nobel et al.²³ compared with AGV's success rate of 77% and 50% at 1 and 4 years, respectively reported by Papadaki et al.²⁴.

Diode CPC is considered in eyes with low visual potential; however risk of hypotony in uveitic eyes can be high.

CB cysts

Cysts of the CB neuroepithelium cause anterior displacement of the peripheral iris and may result in angle closure (Fig. 5A). It can cause either acute or chronic angle closure glaucoma, also called as pseudo-plateau iris. Diagnosis and the extent of cysts can be confirmed on UBM²⁵ (Fig. 5B).

Management

Laser iridotomy, laser iridoplasty²⁶, and laser cycloablation can be used. Therapeutic trial of pilocarpine therapy has also been described.

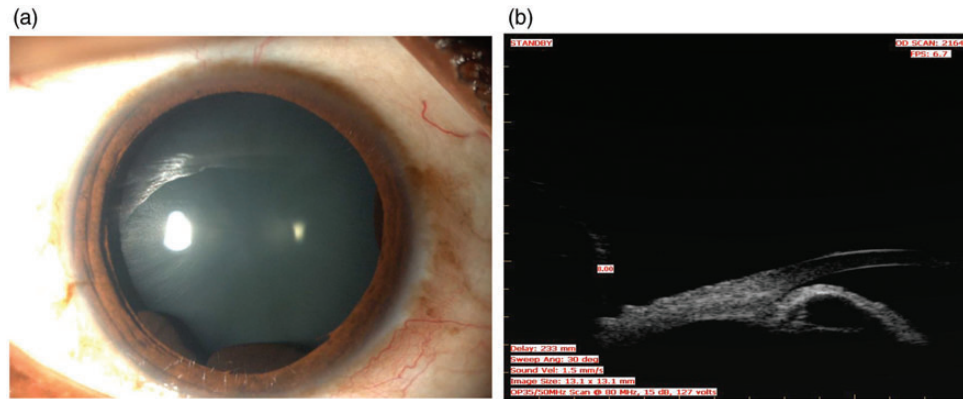


Figure 5: (a) Ciliary body cysts seen better with dilation. (b) Ciliary body cysts seen in UBM.

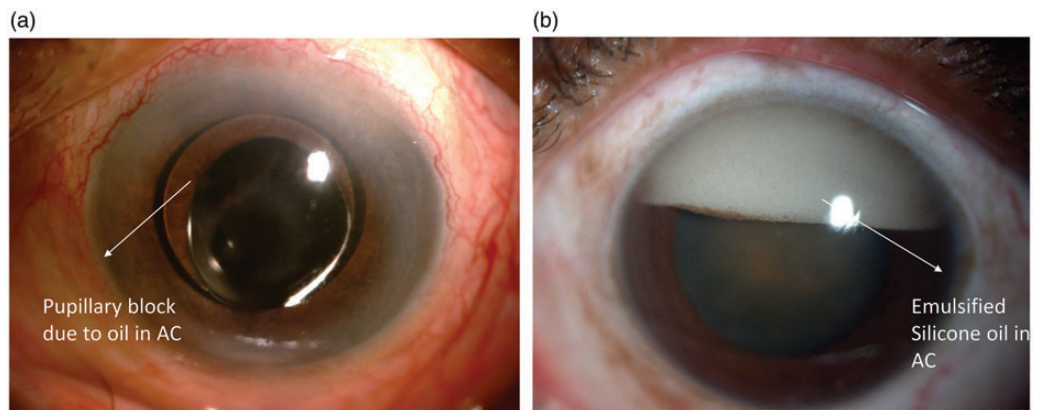


Figure 6: (a) Pupillary block due to Silicone oil in anterior chamber. (b) Emulsified Silicone oil in anterior chamber.

Glaucoma following scleral buckling procedures

Vortex vein compression due to scleral buckle can cause CB swelling which presents as angle closure glaucoma.

Clinical features-

Anteriorly placed buckle, pre-existing narrow angle, high myopia, old age, and the use of encircling band are predisposing risk factors. Incidence of angle closure post buckle ranges from 1.4 to 4.4%. It usually resolves spontaneously over a period of days or weeks.

Management

Aqueous suppressants, topical steroids, and cycloplegics form the mainstay of treatment. Cycloplegics help to pull iris lens diaphragm posteriorly and prevent synechiae formation. Miotics are not helpful and YAG PI is contraindicated in these eyes.

Trabeculectomy is difficult due to conjunctival scarring secondary to previous surgery. Nikhil et al.²⁷ noted a significant reduction in post-operative IOP and number of antiglaucoma medications in patients who underwent AGV

post scleral buckle. Diode CPC results are unpredictable.

Intraocular gas

Air or long-acting gases are injected into the vitreous cavity as their surface tension exerts tamponading effect on retinal breaks. The expansion of these gases during the early postoperative period can lead to IOP elevation

Clinical features

Incidence of IOP rise following intravitreal SF₆ range from 6.1% to 67% and C₃F₈ 18% to 59%²⁸. SF₆ expands to twice its volume within 24–48 h and stays for 10–14 days whereas C₃F₈ expands to four times its volume in 48–72 h and stays for 55–65 days²⁹. IOP spike is transient, common during gas expansion phase causing angle closure secondary to anterior pushing of iris lens diaphragm.

Management

Emphasis should be laid to maintain prone position and to abstain from air travel until complete reabsorption of intraocular gas.

If the IOP spike is severe, gas aspiration from the vitreous cavity (via the pars plana) may be indicated. Laser PI is helpful in cases with pupillary block.

Glaucoma drainage device is considered if trabeculectomy is not possible due to conjunctival scarring.

Glaucoma after silicone oil injection

Silicone oil is used as a vitreous substitute for retinal tamponade. It can produce glaucoma by pupillary block (Fig. 6A), migration of oil into AC (Fig. 6B), inflammation, synechial closure, or by open-angle mechanism. The incidence reported is 6–30%³⁰.

Management

Avoiding overfilling of oil and creating inferior prophylactic iridectomy helps in preventing pupillary block in pseudophakic and aphakic eyes. Zonule-lens barrier prevents anterior migration of the silicone oil in phakic eyes.

Medical therapy includes aqueous suppressants, cycloplegics, and corticosteroids. Laser PI is attempted for blocked surgical PI secondary to fibrinous reaction.

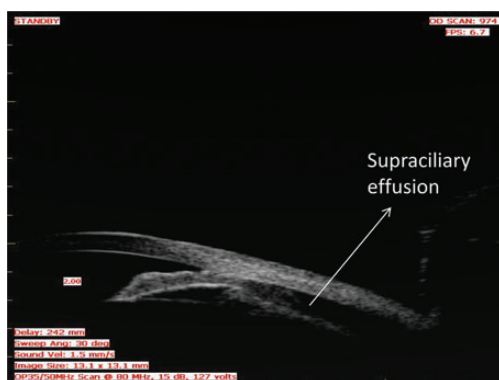


Figure 7: UBM showing supraciliary effusion following Topiramate intake causing secondary angle closure.

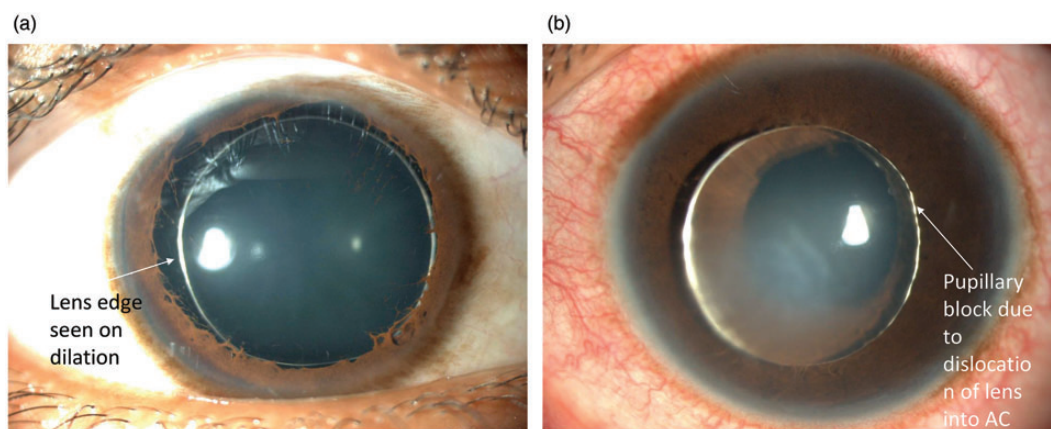


Figure 8: (a) Microspherophakia seen on dilation. (b) Microspherophakia causing pupillary block due to dislocation into anterior chamber.

If silicone oil removal is planned then it is combined with glaucoma surgery. Silicone oil removal carries some risk of retinal detachment³¹. The GDD should be positioned in the inferior quadrant in silicone oil-filled eyes³².

Diode CPC or endocyclophotocoagulation (ECP) can be used in refractory cases.

Glaucoma after laser photocoagulation

An elevated IOP may follow extensive laser photocoagulation of the retina.

Clinical features

Angle closure was observed within hours after PRP in 44% of patients who underwent PRP³². It is postulated to be due to anterior displacement of the iris secondary to CB swelling. The incidence of ciliochoroidal effusion following PRP was noted to be 90% on UBM study³³.

Management

In the majority of cases, the angle closure and resultant IOP rise is transient and asymptomatic. IOP spike usually resolves within 1 month and can be managed with topical medications.

Drug-induced acute angle closure

Sulfa-based drugs acetazolamide³⁴, topiramate³⁵, hydrochlorothiazide, and cotrimoxazole are known to cause secondary angle closure (Fig. 7). Patients present with acquired myopia, uniform shallowing of AC, and raised IOP.

Clinical features

CB effusion secondary to idiosyncratic response to drug causes anterior displacement of the lens-iris complex leading to secondary angle closure. UBM helps to diagnose CB effusion.

Management

Management requires discontinuation of drug, reduction of IOP with aqueous suppressants, and cycloplegics. PI and miotics have no role.

Systemic and topical carbonic anhydrase inhibitors should be avoided.

Nanophthalmos

It is a condition in which the eye ball is of normal shape but small in size. Angle closure glaucoma is usually seen in the middle age. (Dealt in detail in case reports).

Microspherophakia

Lens is usually smaller in size, spherical in shape with increased anteroposterior diameter³⁶. When angle closure is associated with high myopia, possibility of microspherophakia should be kept in mind. With dilation, the pupil entire edge of the lens can be visualized at the slit lamp (Fig. 8A). (Dealt in detail in case reports)

Phacomorphic glaucoma

In phacomorphic glaucoma, angle closure occurs due to swelling of the lens causing intumescent cataract. After IOP control and reduction of inflammation, cataract extraction is the definitive treatment as it removes the cause for angle closure glaucoma; however, it is combined with trabeculectomy if the duration of the attack lasts for more than 3 weeks. There is increased risk of expulsive haemorrhage, positive pressure, and zonular dialysis due to high IOP in these eyes. Manual small incision surgery has been studied to provide effective IOP control and good visual recovery in phacomorphic glaucoma eyes³⁷.

Conclusion

A careful history, astute clinical examination, and when necessary anterior segment imaging such as UBM aid in recognizing the aetiology for secondary angle closure. Identifying the cause early and timely institution of appropriate therapy helps in improving the visual outcome and reducing the ocular morbidity.

References

- Parivadhini A, Lingam V. Management of secondary angle closure glaucoma. *J Curr Glaucoma Pract.* 2014;8:25-32.
- Luntz MH, Rosenblatt M. Malignant glaucoma. *Surv Ophthalmol* 1987;32:73-93.
- Ruben S, Tsai J, Hitchings RA. Malignant glaucoma and its management. *Br J Ophthalmol* 1997;81:163-7.
- Sharma A, Sii F, Shah P, et al Vitrectomy-phacoemulsification-vitrectomy for the management of aqueous misdirection syndromes in phakic eyes. *Ophthalmology* 2006;113:1968-73.
- Debrouwere V, Stalmans P, Van Calster J, et al Outcomes of different management options for malignant glaucoma: a retrospective study. *Graefes Arch Clin Exp Ophthalmol* 2012;250:131-41.
- Stumpf TH, Austin M, Bloom PA, et al, Transscleral cyclodiode laser photocoagulation in the treatment of aqueous misdirection syndrome. *Ophthalmology* 2008;115:2058-61.
- Shahid H, Salmon JF. Malignant glaucoma: a review of the modern literature. *J Ophthalmol* 2012;2012.
- Sivak-Callcott JA, O'Day DM, Gass JDM, et al Evidence-based recommendations for the diagnosis and treatment of neovascular glaucoma. *Ophthalmology.* 2001;108:1767-78.
- Tsai JC, Shields MB. Neovascular glaucoma. In: Tombran-Tink J, Barnstable CJ, eds. *Ophthalmology: Ocular Angiogenesis: Diseases, Mechanisms, and Therapeutics.* Humana Press Inc: Totowa, NJ: 2006;127-47.
- Little HL, Rosenthal AR, Dellaporta A, et al The effect of pan-retinal photo-coagulation on rubeosis iridis. *Am J Ophthalmol* 1976;81:804-9.
- Takahara Y, Inatani M, Fukushima M, et al Trabeculectomy with mitomycin C for neovascular glaucoma: prognostic factors for surgical failure. *Am J Ophthalmol* 2009; 147:912-8.
- Saito Y, Higashide T, Takeda H, et al Beneficial effects of preoperative intravitreal bevacizumab on trabeculectomy outcomes in neovascular glaucoma. *Acta Ophthalmologica* 2010;88:96-102.
- Takahara Y, Inatani M, Kawaji T, et al Combined intravitreal bevacizumab and trabeculectomy with mitomycin C versus trabeculectomy with mitomycin C alone for neovascular glaucoma. *J Glaucoma* 2011;20:196-201.
- Kotecha A, Spratt A, Ogunbowale L, et al Intravitreal bevacizumab in refractory neovascular glaucoma: a prospective, observational case series. *Arch Ophthalmol* 2011; 129:145-50.
- Kobayashi S1, Inoue M, Yamane S, et al Long-term outcomes after preoperative intravitreal injection of bevacizumab before trabeculectomy for neovascular glaucoma. *J Glaucoma.* 2016;25:281-4.
- Olmos LC, Sayed MS, Moraczewski AL, et al Long-term outcomes of neovascular glaucoma treated with and without intravitreal bevacizumab. *Eye* 2016;30:463-72.
- Park UC, Park HK, Kim MD, et al Ahmed glaucoma valve implantation for neovascular glaucoma after vitrectomy for proliferative diabetic retinopathy. *J Glaucoma* 2011; 20:433-8.
- Frederick MR, Richard KP. Atypical angle closure. *Curr Opin Ophthalmol.* 2008;19:107-14.
- Doe EA, Budenz DL, Gedde SJ, et al Long-term surgical outcomes of patients with glaucoma secondary to the iridocorneal endothelial syndrome. *Ophthalmology* 2001;108:1789-95.
- Kim DK, Aslanides IM, Schmidt CM Jr, et al Long-term outcome of aqueous shunt surgery in ten patients with iridocorneal endothelial syndrome. *Ophthalmology* 1999;106:1030-4.
- Alvim PT, Cohen EJ, Rapuano CJ, et al Penetrating keratoplasty in iridocorneal endothelial syndrome. *Cornea* 2001;20:134-40.
- Takahashi T, Ohtani S, Miyata K, et al A clinical evaluation of uveitis-associated secondary glaucoma. *Jpn J Ophthalmol* 2002;46:556-62.
- Noble J1, Derzko-Dzulynsky L, Rabinovitch T, et al Outcome of trabeculectomy with intraoperative mitomycin C for uveitic glaucoma. *Can J Ophthalmol.* 2007;42:89-94.
- Papadaki TG1, Zacharopoulos IP, Pasquale LR, et al Long-term results of Ahmed glaucoma valve implantation for uveitic glaucoma. *Am J Ophthalmol* 2007;144:62-9.
- Ritch Robert. Role of ultrasound biomicroscopy in the differentiation of glaucomas. *Curr Opin Ophthalmol* 1998;9:39-45.
- Crowston JG, Medeiros FA, Mosaed S, Weinreb RN. Argon laser iridoplasty in the treatment of plateau-like iris configuration as result of numerous ciliary body cyst. *Am J Ophthalmol.* 2005;139:381-3
- Choudhari NS, George R, Shantha B, et al Ahmed glaucoma valve in eyes with preexisting episcleral encircling element. *Indian J Ophthalmol* 2014;62:570-4.
- Gedde SJ. Management of glaucoma after retinal detachment surgery. *Curr Opin Ophthalmol.* 2002;3:103-9.
- The Silicone Study Group. Vitrectomy with silicone oil or sulfur hexafluoride gas in eyes with severe proliferative

- vitreoretinopathy: results of a randomized clinical trial. *Silicone Study Report 1*. Arch Ophthalmol. 1992;110:770-9.
30. Flynn HWJ Jr. Surgical management of secondary glaucoma after pars plana vitrectomy and silicone oil injection for complex retinal detachment. *Ophthalmology* 2001;108:1628-32.
 31. Nguyen QH, Lloyd MA, Heuer DK, et al Incidence and management of glaucoma after intravitreal silicone oil injection for complicated retinal detachments. *Ophthalmology*. 1992;99:1520-6.
 32. Al-Jazzaf AM, Netland PA, Charles S. Incidence and management of elevated intraocular pressure after silicone oil injection. *J Glaucoma* 2005;14:40-6.
 33. Yuki T, Kimura Y, Nanbu S, et al Ciliary body and choroidal detachment after laser photocoagulation for diabetic retinopathy. A high-frequency ultrasound study. *Ophthalmology* 1997;104:1259-64.
 34. Narayanswamy AK, Antrolkar M, Vijaya L, Acetazolamide induced Glaucoma. *Asian J Ophthalmol* 2007; 9: 213-5.
 35. Sachi D, Vijaya L. Topiramate induced secondary angle closure glaucoma. *J Postgrad Med* 2006;52:72-3.
 36. Macken PL, Pavlin CJ, Tuli R, Trope GE. Ultrasound biomicroscopic features of spherophakia. *Aust N Z J Ophthalmol* 1995;23:217-20.
 37. Rajkumari V, Kaminibabu KS, Bhabanisana RD, et al Manual small incision cataract surgery in phacomorphic glaucoma: surgical technique and outcome in north-eastern India. *J Curr Glaucoma Pract*, 2013;7:43-8.

How to cite this article Parivadhini A. Management of secondary angle closure glaucoma, *Sci J Med & Vis Res Foun* 2017;XXXV:15-21.