



Military Advanced Regional Anesthesia and Analgesia

M A R R A

MILITARY ADVANCED REGIONAL ANESTHESIA AND ANALGESIA HANDBOOK

Published by the

Office of The Surgeon General
Department of the Army, United States of America

US Army Medical Center and School
Fort Sam Houston, Texas

John P. Murtha Neuroscience and Pain Institute
Johnstown, Pennsylvania

Telemedicine and Advanced Technology Research Center
US Army Medical Research and Materiel Command, Fort Detrick, Maryland

MILITARY ADVANCED REGIONAL ANESTHESIA AND ANALGESIA HANDBOOK

Chester Buckenmaier III, MD
*Colonel, Medical Corps, US Army
Walter Reed Army Medical Center
Associate Professor of Anesthesiology, Uniformed Services University of the Health Sciences
Military Advanced Regional Anesthesia and Analgesia Initiative*

Lisa Bleckner, MD
*Walter Reed Army Medical Center
Assistant Professor of Anesthesiology, Uniformed Services University of the Health Sciences
Military Advanced Regional Anesthesia and Analgesia Initiative*

With original illustrations by
Lieutenant Michael K. Sracic, MD, MC, US Navy

Borden Institute
Walter Reed Army Medical Center, Washington, DC

2008

Borden Institute

Martha K. Lenhart, MD, PhD, FAAOS
Colonel, Medical Corps, US Army
Director and Editor in Chief

Editorial Staff:

Bruce Maston
Illustrator

Douglas Wise
Illustrator

Joan Redding
Senior Production Editor

Vivian Mason
Technical Editor

Marcia Metzgar
Technical Editor

This volume was prepared for military medical educational use. The focus of the information is to foster discussion that may form the basis of doctrine and policy. The opinions or assertions contained herein are the private views of the authors and are not to be construed as official or as reflecting the views of the Department of the Army or the Department of Defense.

Dosage Selection:

The authors and publisher have made every effort to ensure the accuracy of dosages cited herein. However, it is the responsibility of every practitioner to consult appropriate information sources to ascertain correct dosages for each clinical situation, especially for new or unfamiliar drugs and procedures. The authors, editors, publisher, and the Department of Defense cannot be held responsible for any errors found in this book.

Use of Trade or Brand Names:

Use of trade or brand names in this publication is for illustrative purposes only and does not imply endorsement by the Department of Defense.

Neutral Language:

Unless this publication states otherwise, masculine nouns and pronouns do not refer exclusively to men.

Copyright © 2008 The Henry M. Jackson Foundation for the Advancement of Military Medicine, Inc.

NO COPYRIGHTED PARTS OF THIS PUBLICATION MAY BE REPRODUCED OR TRANSMITTED IN ANY FORM OR BY ANY MEANS, ELECTRONIC OR MECHANICAL (INCLUDING PHOTOCOPY, RECORDING, OR ANY INFORMATION STORAGE AND RETRIEVAL SYSTEM), WITHOUT PERMISSION IN WRITING FROM THE PUBLISHER OR COPYRIGHT OWNER.

Published by the Office of The Surgeon General at TMM Publications
Borden Institute, Walter Reed Army Medical Center, Washington, DC 20307-5001

Library of Congress Cataloging-in-Publication Data

Buckenmaier, Chester.

Military advanced regional anesthesia and analgesia handbook / Chester Buckenmaier III, Lisa Bleckner ; Michael K. Sracic, illustrator.

p. ; cm.

Developed as a supplement to Emergency war surgery. 3rd U.S. revision. 2004.

Includes bibliographical references.

ISBN 978-0-9818228-2-2

1. Conduction anesthesia--Handbooks, manuals, etc. 2. Analgesia--Handbooks, manuals, etc. 3. Medicine, Military--Handbooks, manuals, etc. I. Bleckner, Lisa. II. Borden Institute (U.S.) III. Emergency war surgery. IV. Title.

[DNLM: 1. Anesthesia, Conduction--methods--Handbooks. 2. Analgesia--methods--Handbooks. 3. Military Medicine--methods--Handbooks. 4. Pain--drug therapy--Handbooks. WO 231 B922b 2008]

RD84.B79 2008

617.9'64--dc22

2008031170

CONTENTS

Contributors	vii
Preface	ix
Prologue	xi
1. The Military Advanced Regional Anesthesia and Analgesia Initiative: A Brief History	1
2. Peripheral Nerve Block Equipment	5
3. Local Anesthetics	11
4. Nerve Stimulation and Ultrasound Theory	17
5. Upper Extremity Neuroanatomy	21
6. Cervical Plexus Block	23
7. Interscalene Block	25
8. Supraclavicular Block	29
9. Infraclavicular Block	33
10. Axillary Block	37
11. Peripheral Nerve Blocks of the Arm	41
12. Paravertebral Nerve Block	45
13. Lower Extremity Neuroanatomy	49
14. Lumbar Plexus Block	51
15. Femoral Nerve Block	53
16. Individual Nerve Blocks of the Lumbar Plexus	57
17. Sciatic Nerve Block: Posterior and Alternative Approaches	61
18. Sciatic Nerve Block: Anterior Approach	67
19. Sciatic Nerve Block: Lateral Approach	69
20. Popliteal Nerve Block	73
21. Saphenous Nerve Block	77
22. Ankle Block	79
23. Bier Block	81
24. Continuous Peripheral Nerve Block	83
25. Regional Anesthesia Complications	91

26. Acute Pain Management in the Field	95
27. Improving Surgical Pain Management With Multidisciplinary Care	103
28. Interventional Chronic Pain Treatment in Mature Theaters of Operation	107
29. Air Transport of the Critically Injured Patient: Controlling Pain During Transport and Flight	113
30. Basic Pediatric Regional Anesthesia	119
31. Acute Pain Nursing in the Field	125
32. Novel Medical Acupuncture Treatments for Active Combat Units on the Battlefield	129
Further Reading	xiii
Abbreviations and Acronyms	xvii

CONTRIBUTORS

TODD CARTER, MD
Lieutenant Colonel, Medical Corps, US Air Force

JOHN CHILES, MD
Colonel (Retired), Medical Corps, US Army

JAMES E. COX, MD
Colonel (Retired), Medical Corps, US Air Force

SCOTT CROLL, MD
Lieutenant Colonel, Medical Corps, US Army

STEVE COHEN, MD
Colonel, Medical Corps, US Army

JOHN DUNFORD, MD
Assistant Professor of Anesthesiology, Uniformed
Services University of the Health Sciences

ERIC ELSTER, MD
Commander, Medical Corps, US Navy

CARLO FRANCO, MD
Associate Professor of Anesthesiology and Anatomy,
Rush University Medical Center

BILL FRITZ, MD
Conemaugh Health System

KURT GRATHWOHL, MD
Lieutenant Colonel, Medical Corps, US Army

SCOTT GRIFFITH, MD
Major, Medical Corps, US Army

STEPHEN M. KLEIN, MD
Associate Professor of Anesthesiology, Duke
University Medical Center

ROBERT S. LENNON, DO
Brigadier General (Retired), Medical Corps, US
Army; Associate Professor, Mayo Clinic Medical
School

COURTNEY LENNON
Ensign, Medical Corps, US Navy

ROBERT LENNON, JD
Ensign, Medical Corps, US Navy

RANDALL MALCHOW, MD
Colonel, Medical Corps, US Army

GREG MALONE, MD
Captain, Medical Corps, US Air Force

GESELLE McKNIGHT, CRNA, MSN
Walter Reed Army Medical Center

BRIAN MCMILLAN, MD
Major, Medical Corps, US Army

JONATHON ROGERS, MD
Captain, Medical Corps, US Air Force

CHRISTINE RUPPRECHT, RN, MSN
Walter Reed Army Medical Center

CYNTHIA SHIELDS, MD
Colonel, Medical Corps, US Army

SEAN SHOCKEY, MD
Major, Medical Corps, US Army

KENNETH SON, MD
Lieutenant Commander, Medical Corps, US Navy

ALEX STOJADINOVIC, MD
Colonel, Medical Corps, US Army

ANN VIRTIS, MD
Colonel (Retired), Medical Corps, US Air Force

RONALD WHITE, MD
Major, Medical Corps, US Army

ALON P. WINNIE, MD
Professor of Anesthesiology, Northwestern
University Medical Center

MODELS

MICHAEL ADAMS, MD

BRIAN MCLEAN, MD

AIDAN SHIELDS

MICHAEL SHIGEMASA

NECIA WILLIAMS, MD

PREFACE

Almost 50 years ago a seminal observation in the renaissance and subsequent explosive development of regional anesthesia was made by a resident prosector preparing a cadaver for a nerve block course taught by the resident's chairman. Although the dissection was primarily focused on the nerves, the resident noted a consistent relationship between the nerves, muscles, and fascia: the brachial plexus, for example, was surrounded by a fascial sheath, provided in large part by the surrounding muscles, throughout its development and distribution to the upper extremity. As the dissection continued, he noted a similar fascial envelope surrounding the other major plexuses, cervical, lumbar, and sacral. As a result, the resident theorized that it might be possible to block an entire plexus by injecting local anesthetic through a needle inserted into its sheath, just as in producing epidural anesthesia. He tried it clinically and it worked. After his first few successful single injection blocks, he commented to his fellow residents how useful such single injection techniques would be on the battlefield, especially since the use of a catheter would allow analgesia to last as long as necessary.

Over the subsequent half century many (perhaps too many!) approaches to these "fascial envelopes" have been described, and many of them have become popular throughout the world. Furthermore, technological advances have kept pace with the increasing use of regional anesthesia, making all the techniques simpler to learn, safer to administer, and much more successful. Although

regional anesthesia was being utilized frequently in hospital clinical practice, it took the Military Advanced Regional Anesthesia and Analgesia (MARAA) group's vision to recognize the unique value of these techniques during wartime: for centuries morphine has been the traditional painkiller on the battlefield, despite producing a high incidence of nausea and vomiting, bringing the possibility of abuse and dependence, and never completely abolishing the pain. Continuous plexus or peripheral blocks can relieve pain completely and can maintain relief as long as necessary. Colonel Chester C Buckenmaier III, the founder of MARAA, personally provided the first successful application of a continuous peripheral nerve block on the battlefield: he placed a continuous catheter in the leg of a soldier who had sustained a severe shrapnel injury to his left calf from a rocket propelled grenade. This one catheter with a continuous infusion of local anesthetic provided complete pain relief during this soldier's entire evacuation, the initial surgery at the combat support hospital in Iraq, transport to Germany, a second surgical procedure there, transport home to Walter Reed Army Medical Center, and four additional surgical procedures there, the last being amputation. The catheter was finally removed after the last procedure, 16 days after its insertion!

As impressive as this approach is to the management of the acute pain of battlefield injuries and subsequent surgical procedures, its advantages may go even further: evidence is accumulating that

neural blockade of acute pain may prevent the subsequent development of chronic pain (complex regional pain syndrome I and II, phantom limb pain, etc); researchers are even predicting that the absence of excruciating pain following devastating injuries could prevent the development of posttraumatic stress syndrome. Only time and the data being obtained by MARAA will tell.

Military anesthesiologists should be proficient in regional anesthesia techniques, which will undoubtedly play an increasingly important role in providing pain relief and recovery during wartime. MARAA hopes to make this possible by providing this excellent, brief but complete synopsis of regional anesthesia as a resource for anesthesiologists serving in the armed forces. Not intended for the beginner or trainee, this book is carefully structured to provide a quick review of the anatomy and technique of each nerve block, formatted for easy reference on the battlefield or in the operating room. Because of the variable circumstances under which a block may be carried out on the battlefield, each technique is described using paresthesia, nerve stimulation, and ultrasound. I am certain that this book will not only go a long way toward integrating continuous plexus and peripheral nerve blocks into military medicine, but also, ultimately (because soldiers aren't soldiers forever), both the manual and MARAA will have a positive impact on civilian medicine, and in particular the way we manage painful trauma in large-scale civilian disasters.

Alon P. Winnie, M.D.

Alon P. Winnie, MD

PROLOGUE

The Military Advanced Regional Anesthesia and Analgesia (MARAA) Handbook was developed as a supplement to *Emergency War Surgery – Third United States Revision*. In *Emergency War Surgery*, regional anesthesia is described as “a ‘field friendly’ anesthetic requiring minimal logistical support while providing quality anesthesia and analgesia on the battlefield.” Until now, details on how to provide advanced regional anesthesia and acute pain medicine services on the modern battlefield were unavailable. The contributors to this MARAA handbook have collaborated to provide a useful resource for managing the pain of battlefield trauma.

Rapid advancement in medical science has been the hallmark of US military medicine throughout the nation’s history. The recent wars in Iraq and Afghanistan are no exception. Life-saving advances in body armor, rapid medical evacuation from point of injury, availability of blood products, improved far-forward surgical and critical care capability, and rapid air evacuation of casualties to level IV medical facilities have contributed to a less than 10% died-of-wounds rate in the current conflicts. The military medical triumph represented by this statistic is undeniable, although the achievement has resulted in other problems, particularly in the man-

agement of acute pain. Since the US Civil War morphine has been the accepted standard for battlefield pain control, because options for pain management in previous conflicts were limited, comprehension of pain mechanisms nascent, and casualties, when they survived, tended to remain near the battlefield while they recovered. Modern combat casualty care now emphasizes rapid evacuation to progressively higher levels of medical care with critical care support provided at all times (including transport). Casualties who earlier were kept in a war zone for days to weeks until they were stable for transport now are transported by plane from Iraq to Germany within 8 to 72 hours of injury. The environment of evacuation aircraft—crowded, deafening, jolting, poorly lit, with limited monitoring capabilities—only magnifies the difficulties of using opioid-only pain control therapy. Healthcare providers placed in this situation are less likely to use adequate doses of morphine because of valid patient safety concerns. The large numbers of healthcare providers in the evacuation chain and long evacuation distances further complicate opioid use in these patients.

Fortunately, among the medical advances arising from the current conflicts are improved under-

standing and management of pain in war casualties. Through the MARAA organization (see Chapter 1), like minded anesthesia providers from the Air Force, Army, and Navy have greatly improved the management of pain in combat wounded through the application of modern pain treatment medications and technologies, including advanced regional anesthesia. In the US military, uncontrolled acute pain is now recognized as a disease process of the nervous system, not just a symptom of trauma. This text celebrates this advancement, preserving what has been learned to serve as a new, higher standard for pain management in this and forthcoming conflicts.

The purpose of this handbook is to assist with the education of anesthesiology residents in the art and science of advanced regional anesthesia and acute pain medicine. As John J Bonica stated in *The Management of Pain*, “The proper management of pain remains, after all, the most important obligation, the main objective, and the crowning achievement of every physician.” This handbook is dedicated to the US military professionals who have been wounded in the service of this country. It is our hope that the knowledge within this text will be used to ease the burden of their wounds.

1. THE MILITARY ADVANCED REGIONAL ANESTHESIA AND ANALGESIA INITIATIVE: A BRIEF HISTORY

"He who would become a surgeon should join the army and follow it."

—Hippocrates

The history of warfare parallels the history of medical advances. In the field of anesthesia, wars have resulted in marked technical, chemical, and procedural advances, including the first battlefield use of inhalational anesthesia (Mexican-American War), first widespread use of anesthetics and inhalers for the application of inhaled anesthetics (US Civil War), use of the eye signs chart for safe monitoring by lay practitioners (World War I), development of specific short course training centers for predeployment anesthesia training (World War II), and the establishment of military anesthesia residency programs in response to shortages of specialty trained doctors (Korean War). The current wars in Iraq and Afghanistan are no exception to this historical trend (Figure 1-1), and perhaps the most significant advance resulting from these conflicts is the Military Advanced Regional Anesthesia and Analgesia Initiative (MARAA).

MARAA is the collaborative effort of like-minded anesthesiologists who perceived a need for improvement in battlefield pain management. Deployed military anesthesiologists recognized a disconnect between battlefield and civilian analgesic care that needed to be bridged. As one provider put it, "pain control in Baghdad, 2003, was the same as in the Civil War—a nurse with a syringe of morphine." Colonel (Retired) John Chiles was the first to voice the potential benefit of increasing the use of regional anesthesia in the Iraq war. With Lieutenant Colonel Chester Buckenmaier, Chiles started the Army Regional Anesthesia and Pain Management Initiative in 2000. Dr Buckenmaier administered



Figure 1-1. *As Long As There Is War, There Will Be Wounded*, by Lieutenant Michael K. Sracic, MD, MC, US Navy, 2008.

the first continuous peripheral nerve block in Operation Iraqi Freedom on October 7, 2003. Upon his return, Buckenmaier, Chiles, Lieutenant Colonel Todd Carter, and Colonel (Retired) Ann Virtis created MARAA, following in the tradition of the Anesthesia Travel Club created by John Lundy to rapidly disseminate research advances to practitioners.

MARAA's purpose is to develop consensus recommendations from the US Air Force, Army, and Navy anesthesia services to implement improve-

ments in medical practice and technology that will promote regional anesthesia and analgesia in the care of military beneficiaries. The organization also serves as an advisory board to the individual service anesthesia consultants to the surgeons general (see the MARAA charter, the attachment to this chapter). Initial support was provided indirectly by the public's demand for better pain control for wounded soldiers and directly via congressional funding through the John P Murtha Neuroscience and Pain Institute, the Telemedicine and Advanced

TABLE 1-1
ATTENDEES AT THE FIRST MEETING OF
THE MILITARY ADVANCED REGIONAL
ANESTHESIA AND ANALGESIA INITIATIVE

COL John Chiles, Army	Service Consultant
LTC Chester Buckenmaier, Army	Service Consultant designee; MARAA President
Lt Col Todd Carter, Air Force	Service Consultant
CAPT Ivan Lesnik, Navy	Service Consultant
CDR Dean Giacobbe, Navy	Service Consultant designee
MAJ Peter Baek, Air Force	Service Consultant designee

Technology Research Center, and the Henry M Jackson Foundation. The first MARAA meeting was held in February 2005 (Table 1-1).

As the service primarily responsible for transporting wounded soldiers from the battlefield to the United States, the Air Force supported the initiative and almost immediately issued a memorandum outlining specific directives to Air Force providers based on MARAA recommendations. By October 2006 MARAA meetings had grown to include over 30 senior military anesthesiologists. Nursing support of anesthesia was recognized early on, and a certified registered nurse anesthetist from each service was added to the board in April 2006. Initial meetings focused on approval of the Stryker PainPump 2 (Stryker; Kalamazoo, Mich) for use on Air Force military aircraft and the need for patient-controlled analgesia pumps on the battlefield and on evacuation aircraft. The organization developed a series of training modules and consensus recommendations on pain management for anesthesiologists preparing for deployment (available at: www.arapmi.org).

MARAA also spearheaded the regional anesthesia tracking system (RATS), designed to provide real-time continuous pain management information on patients from Iraq to the United States. RATS is currently being integrated into the Army's online Theater Medical Data Store as part of the military computerized patient record. These initiatives have led to greater pain control for wounded soldiers, and their success has been widely recognized in professional and lay journals from Newsweek to Wired magazine.

The need for comprehensive pain management has recently been recognized at the national legisla-

tive level with the introduction (and passage by the House May 26, 2008) of HR 5465, the Military Pain Care Act of 2008, which will require that all patients at military treatment facilities be assessed and managed for pain throughout their recovery period. In addition, all patients must be provided access to specialty pain management services, if needed. If the bill is passed, MARAA is in position to organize its implementation.

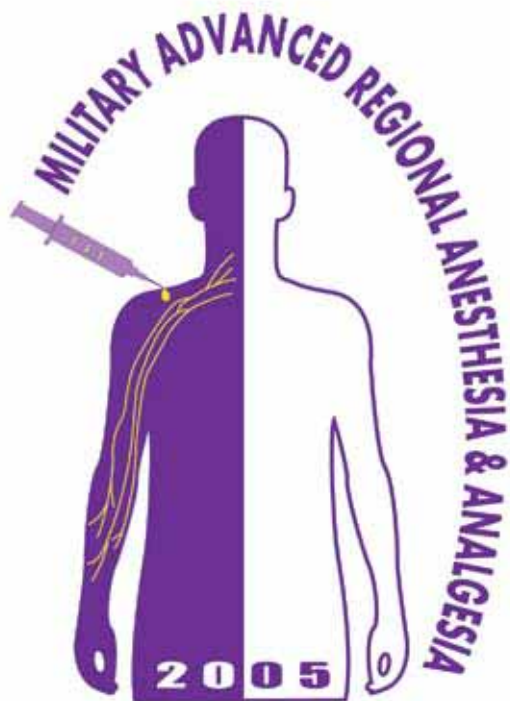Already, MARAA is expanding its role beyond improving the care of military beneficiaries by encouraging civilian attendees at its Annual Comprehensive Regional Anesthesia Workshop (Figure 1-2),

Figure 1-2. MAARA Annual Workshop faculty; l-r: Scott M Croll, Alon P Winnie, Chester Buckenmaier.



held at the Uniformed Services University of the Health Sciences in Bethesda, Maryland. This year marks the 7th year of the workshop, directed by Dr Buckenmaier and taught by senior anesthesiologists from around the nation. This year's faculty included doctors Alon P Winnie, Northwestern University; Andre P Boezaart, University of Florida; John H Chiles, former anesthesiology consultant to the Army surgeon general and currently at INOVA Mount Vernon Hospital; Laura Lowrey Clark, University of Louisville; Steven Clendenen, Mayo Clinic; Scott M Croll, Uniformed Services University and Walter Reed Army Medical Center; John M Dunford, Walter Reed Army Medical Center; Carlo D Franco, Rush University; Ralf E Gebhard, University of Miami; Roy A Greengrass, Mayo Clinic; Randall J Malchow, Brooke Army Medical Center; Karen C Neilsen, Duke University; Thomas C Stan, Far Hills Surgery Center; and Gale E Thompson, Virginia Mason Medical Center.

Although the recognition of MARAA's success has so far been directed to its immediate achievements—improved and systematic pain control for wounded soldiers—its ultimate contribution may be broader in scope. Patient care is a multispecialty team effort that MARAA recognizes. Therefore, MARAA solicits, evaluates, and appreciates input from other physician subspecialists and from nursing providers; much of the spring 2006 meeting was devoted to astute flight nurse observations collected by Lieutenant Colonel Dedecker, a US Air Force nurse in charge of the Patient Movement Safety Program. MARAA meetings remain open to any person interested in attending, and all meeting notes, data, and recommendations are freely available. As impressive as MARAA's contributions to patient care have been, history may view its greater contribution as a modern model of how a small group of persons with vision and energy can dramatically improve an entire field of care.



**CHARTER OF THE
MILITARY ADVANCED REGIONAL
ANESTHESIA & ANALGESIA
JUNE 2005**

ARTICLE I: NAME AND OBJECT

1. Name. The name of the organization is "Military Advanced Regional Anesthesia & Analgesia (MARAA)."
2. Object. The object of the organization is the promotion of regional anesthesia and improved analgesia for military personnel and dependents at home and on the nation's battlefields.
3. Purpose. The organization will work to develop consensus recommendations from the Air Force, Army, and Navy anesthesia services for improvements in medical practice and technology that will promote regional anesthesia and analgesia in the care of military beneficiaries. The organization serves as an advisory

board to the individual service anesthesia consultants to the surgeons general.

ARTICLE II: MANAGEMENT

The organization will consist of the anesthesiology consultant of each military service (or their designee) and a second appointee by each service anesthesiology consultant (six member board). Each member of the organization has one vote on issues that require agreement/collaboration between services. All decisions will be made by a simple two thirds majority. Issues that fail to obtain a two thirds majority consensus will be tabled and re-addressed at the next meeting called by the President of the organization.

ARTICLE III: DIRECTORS

The organization will select a President of the organization from organization members each fiscal year by simple majority vote. The President will be responsible for soliciting meeting issues from members and setting meeting agendas. The President will be responsible for generating organization position 'white papers' on decisions made by the organization. The position white papers will provide each service anesthesia consultant with collaborative recommendations for issues considered by the organization. The President can assign the writing of decision papers to committee members. The president will have final editorial authority over any white paper recommendations submitted to the service anesthesiology consultants.

ARTICLE IV: MEETINGS

1. Meetings. The organization will meet twice yearly. One formal meeting will be at the Uniformed Services Society of Anesthesiology meeting during the American Society of Anesthesiology conference. A second meeting will be scheduled during the Spring. Meetings will be coordinated by the organization president. Organization members can send proxies to attend meetings in their place (proxy voting is allowed) if approved by that member's service anesthesiology consultant. Teleconferencing is an acceptable means of attending a meeting. Meetings will only be held when a quorum of members (or their proxies) are available. A quorum will be defined as a majority of voting members with representation from each service.

2. Special Meetings. The president can call for a special meeting by organization members on issues requiring prompt attention.

3. Conduct of Meetings. Meetings will be presided over by the President or, in the absence of the President, a member of the organization designated by the President.

4. Meeting Agenda. The President will provide members with the meeting agenda one week prior to scheduled meetings. Members may add new items to the agenda during meetings with the President's request for 'new business'. Meetings will be concluded with review of old business.

ARTICLE V: ORGANIZATION SEAL

The organization seal is represented at the head of this document.

Amendment 1 (6 April 2006): The voting MARAA membership will include one CRNA vote per service. Representatives will be chosen by each service's anesthesiology consultants. There will now be 9 total votes (2 physician and 1 CRNA per service).

2. PERIPHERAL NERVE BLOCK EQUIPMENT

INTRODUCTION

The safe and successful application of regional anesthesia in patients requires specialized training and equipment. In 2005, guidelines for regional anesthesia fellowship training were published in the journal *Regional Anesthesia and Pain Medicine*. The guidelines were a collaborative effort of a group of North American regional anesthesia fellowship program directors who met to establish a standardized curriculum. An important part of this document is the categorization of regional anesthetic procedures into basic, intermediate, and advanced techniques. The Walter Reed Army Medical Center (WRAMC) regional anesthesia fellowship program has adopted this categorization as well as the published guidelines (Table 2-1).

This manual will focus on intermediate and advanced regional anesthesia techniques and acute pain therapies, which may not be included in routine anesthesia training. Some basic techniques are covered as well (with the exception of neuraxial anesthesia). The primary purpose of this manual is to serve as a guide for WRAMC resident and fellow anesthesiologists during their regional anesthesia and acute pain rotations. The facility, equipment, and staffing solutions used at WRAMC may not be entirely workable at other institutions; however, the editors are confident that other clinicians can benefit from this systematic approach to regional anesthesia and acute pain medicine.

Contemporary regional anesthesia increasingly relies on sophisticated equipment, as providers strive for accurate and safe methods of needle placement and anesthetic delivery. This chapter will review the equipment used at WRAMC as well as on the modern battlefield in the successful performance of regional anesthesia. *Note: The equipment displayed in this chapter is for illustration purposes only and should not be considered an endorsement of any product.*

TABLE 2-1

CLASSIFICATION OF REGIONAL ANESTHESIA TECHNIQUES AT WALTER REED ARMY MEDICAL CENTER

Basic Techniques	Intermediate Techniques	Advanced Techniques
<p><i>Anesthesia providers who have completed an accredited anesthesia program should be familiar with these techniques.</i></p> <ul style="list-style-type: none"> • Superficial cervical plexus block • Axillary brachial plexus block • Intravenous regional anesthesia (Bier block) • Wrist block • Digital nerve block • Intercostobrachial nerve block • Saphenous nerve block • Ankle block • Spinal anesthesia • Lumbar epidural anesthesia • Combined spinal-epidural anesthesia • Femoral nerve block 	<p><i>Should be familiar to anesthesia providers who have completed a supervised program in regional anesthesia and have demonstrated proficiency in these techniques (usually 20–25 blocks of each type).</i></p> <ul style="list-style-type: none"> • Deep cervical plexus block • Interscalene block • Supraclavicular block • Infraclavicular block • Sciatic nerve block: posterior approach • Genitofemoral nerve block • Popliteal block: all approaches • Suprascapular nerve block • Intercostal nerve block • Thoracic epidural anesthesia 	<p><i>Should be familiar to anesthesiologists with advanced or fellowship training in regional anesthesia appropriate for a subspecialist consultant in regional anesthesia.</i></p> <ul style="list-style-type: none"> • Continuous peripheral nerve blocks: placement and management • Ultrasound guided regional anesthesia • Thoracolumbar paravertebral blocks • Lumbar plexus block • Sciatic nerve block: anterior approach • Obturator nerve block • Cervical epidural anesthesia • Cervical paravertebral block • Maxillary nerve block • Mandibular nerve block • Retrobulbar and peribulbar nerve blocks

REGIONAL ANESTHESIA AREA

Regardless of the practice environment (military care level III through IV), a designated area for the application of regional anesthesia techniques outside of the operating room will enhance block success. This alternative location for nerve block placement will prevent unnecessary operating room delays, allow additional time for long-acting local anesthetics to “set up,” and allow the provider to assess the quality of the nerve block prior to surgery. Other advantages of a regional anesthesia area include

reduced anesthesia turnover times and improved patient-anesthesiologist relationships. Finally, the regional anesthesia area greatly enhances resident education by providing an instructional environment free from the pressures and distractions of a busy operating room.

The regional block area should have standard monitoring, oxygen, suction, airway, and emergency hemodynamic equipment. Certain military practice environments will necessitate adjustments or alternatives to this equipment list. Advanced cardiac life support capability and medications

should be readily available as well as Intralipid (KabiVitrum Inc, Alameda, Calif). Recent data have shown Intralipid to be an effective therapy for cardiac arrest related to local anesthetic toxicity (see Table 3-2 for Intralipid dosing).

PATIENT CONSENT FOR REGIONAL ANESTHESIA

As with any medical procedure, proper consent for the nerve block and documentation of the procedure (detailing any difficulties) is essential. Counseling should include information on risks of regional anesthesia, including intravascular injection, local anesthetic toxicity, and potential for nerve injury. Patients receiving regional anesthesia to extremities should be reminded to avoid using the blocked extremity for at least 24 hours. In addition, patients should be warned that protective reflexes and proprioception for the blocked extremity may be diminished or absent for 24 hours.

Particular attention must be paid to site verification prior to the nerve block procedure. Sidedness should be confirmed orally with the patient as well as with the operative consent. The provider should initial the extremity to be blocked. If another anesthesia provider manages the patient in the operating room, the provider who places the regional block must ensure that the accepting anesthesia provider is thoroughly briefed on the details of the block procedure.

EQUIPMENT

Needles. A variety of quality regional anesthesia stimulating needles are available on the market today. Qualities of a good regional anesthesia needle include the following:

- Stimulating needles should be insulated along the shaft, with only the tip exposed for stimulation.
- A comfortable finger grip should be attached to the proximal end of the needle.
- The wire attaching the needle to the stimulator should be soldered to the needle's shaft and have an appropriate connector for the nerve stimulator.
- Long, clear extension tubing must also be integral to the needle shaft to facilitate injection of local anesthetic and allow for early detection of blood through frequent, gentle aspirations.
- Stimulating needles are typically beveled at 45° rather than at 17°, as are more traditional needles, to enhance the tactile sensation of the needle passing through tissue planes and to reduce the possibility of neural trauma.
- Finally, markings on the needle shaft in centimeters are extremely helpful in determining needle depth from the skin.



Figure 2-1. Representative single injection, 90-mm, insulated peripheral nerve block needle (StimuQuik, Arrow International Inc, Reading, Pa; used with permission)

Centimeter markings on the needle shaft are particularly important now that ultrasound technology can provide accurate measurements of skin to nerve distances (Figure 2-1). A typical back table set-up for a peripheral nerve anesthetic is illustrated in Figure 2-2. Figure 2-3 provides the preferred method for all local anesthetic injections.

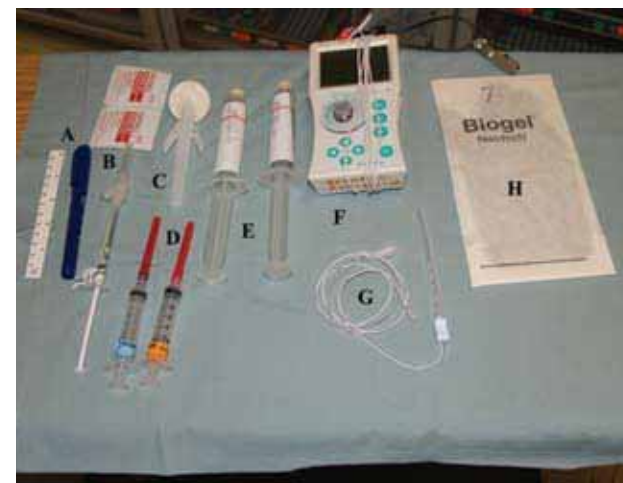

Figure 2-2. Set-up for peripheral nerve block
A: ruler and marking pen for measuring and marking landmarks and injection points
B: alcohol swabs and 25-gauge syringe of 1% lidocaine to anesthetize the skin for needle puncture
C: chlorhexidine gluconate (Hibiclens, Regent Medical Ltd, Norcross, Ga) antimicrobial skin cleaner
D: syringes for sedation (at WRAMC, having 5 mg midazolam and 250 mg fentanyl available for sedation is standard)
E: local anesthetic
F: peripheral nerve stimulator
G: stimulating needle
H: sterile gloves

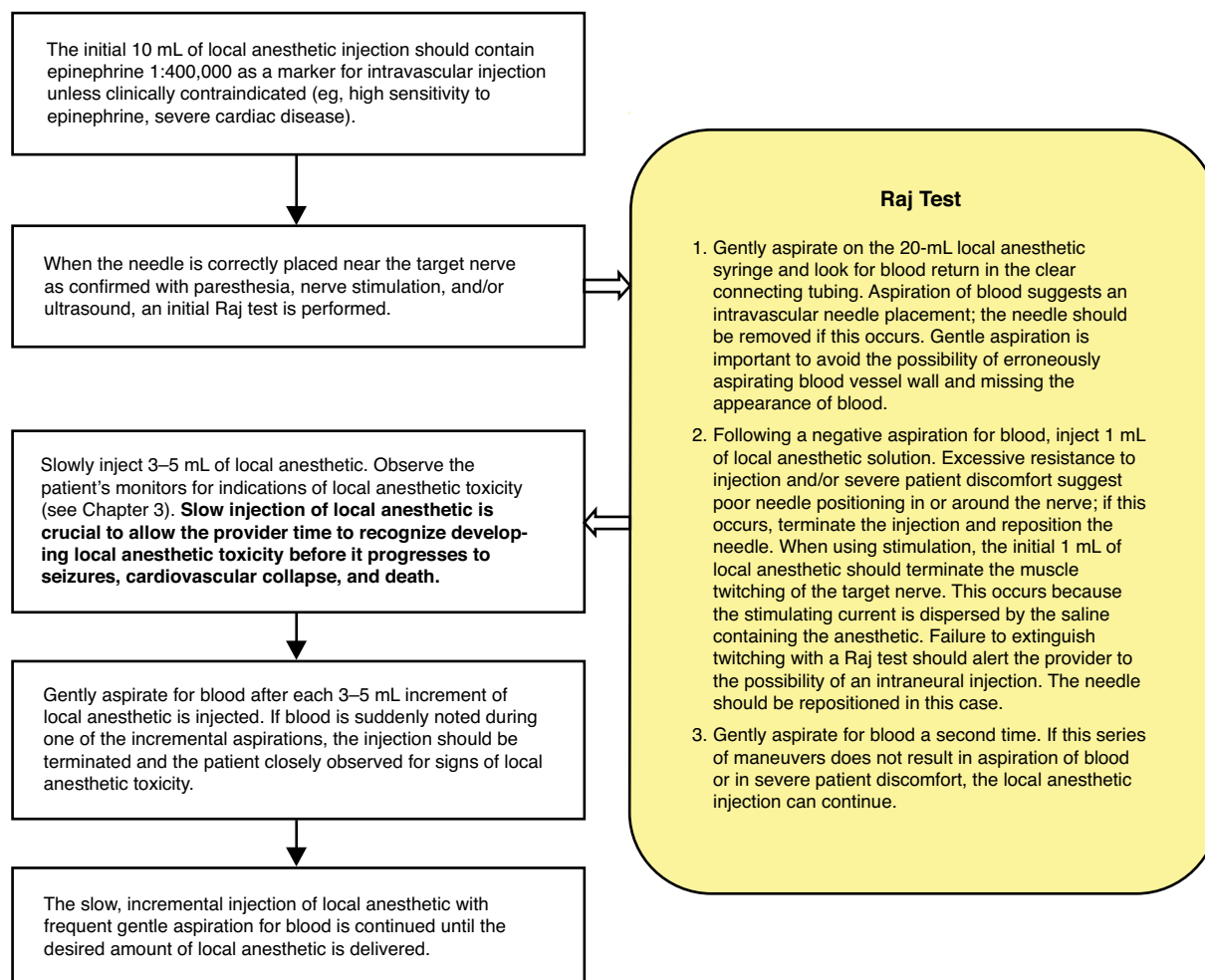


Figure 2-3. Procedure for injection of all local anesthetics

Peripheral Nerve Block Stimulators. Peripheral nerve stimulation has revolutionized the practice of regional anesthesia by providing objective evidence of needle proximity to targeted nerves. In the majority of peripheral nerve blocks, stimulation of nerves at a current of 0.5 mA or less suggests accurate needle placement for injection of local anesthetic. Chapter 4, Nerve Stimulation and Ultrasound Theory, discusses nerve stimulation in detail. A variety of peripheral nerve stimulators are available on the market. A good peripheral nerve stimulator has the following characteristics:

- a light, compact, battery-operated design with adjustable current from 0 to 5 mA in 0.01 mA increments at 2 Hz impulse frequency;
- a bright and easily read digital display;
- both a visual and audible signal of an open or closed circuit between the stimulator, needle, and patient; and
- an impulse duration adjustable between 0.1 millisecond (ms) and 1 ms.

Continuous Peripheral Nerve Block Catheters. Chapter 24, Continuous Peripheral Nerve Block, provides details on WRAMC procedures for placing and securing continuous peripheral nerve block (CPNB) catheters. The majority of catheters placed at WRAMC and in the field are nonstimulating catheters (Figure 24-1) because of how long the catheters remain in situ—1 to 2 weeks on average—and currently available stimulating catheter systems recommend removal after 72 hours (however, new catheter technology may soon change this limitation). In the management of combat wounded, hundreds of nonstimulating CPNB catheters have been placed to manage pain for weeks, some as long as a month, without complication related to the catheter. Desirable characteristics of a long-term CPNB catheter are listed in Table 2-2. The Contiplex Tuohy (B

Braun Melsungen AG, Melsungen, Germany) CPNB nonstimulating catheter system used at WRAMC has had years of successful long-term use in combat casualties and remains the recommended CPNB system for the field.

Ultrasound. Some regional anesthesia providers consider recent developments in ultrasound technology to be the next "revolution" (after peripheral nerve stimulation) in regional anesthesia. Improvements in ultrasound technology allow for high image resolution with smaller, portable, and less expensive ultrasound machines (Figure 2-4). Elements of a superior ultrasound machine for regional anesthesia are high image quality, compact

Figure 2-4. Contemporary laptop ultrasound machine (Logiq Book XP, GE Healthcare, Buckinghamshire, United Kingdom; used with permission)

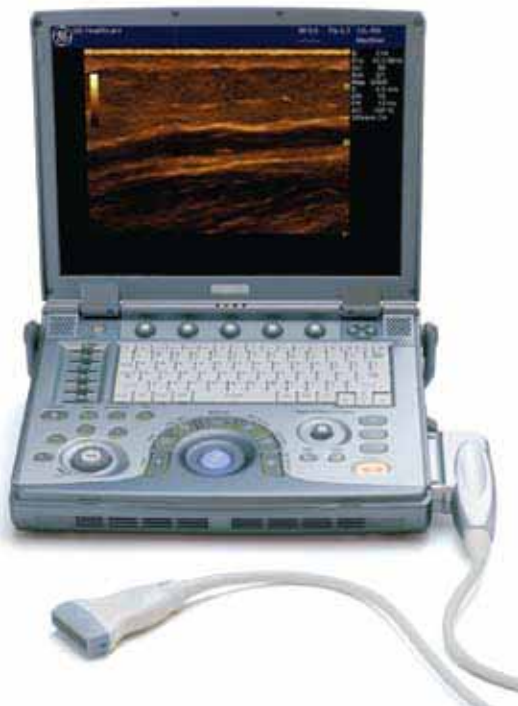

TABLE 2-2

DESIRABLE CHARACTERISTICS OF A LONG-TERM CONTINUOUS PERIPHERAL NERVE BLOCK CATHETER

- Easily placed through a standard 18-gauge Tuohy needle
- Composed of inert, noninflammatory material
- Centimeter markings to estimate depth/catheter migration
- Colored tip to confirm complete removal from patient
- Flexible, multiorifice tip
- Hyperechoic on ultrasound
- Radiopaque
- Secure injection port
- Capable of stimulation
- Nonadherent with weeks of internal use
- High resistance to breaking or kinking
- Low resistance to infusion
- Bacteriostatic
- System to secure the catheter to the patient's skin

and rugged design, simple and intuitive controls, easy image storage and retrieval, and ease of portability. Ultrasound for peripheral nerve blocks is discussed in Chapter 4.

Infusion Pumps. Recent improvements in acute pain management on the battlefield would have been impossible without improvements in microprocessor-driven infusion technology. The use

TABLE 2-3

DESIRABLE CHARACTERISTICS OF A MILITARY PAIN INFUSION PUMP

- Easily identifiable by shape and color
- Used only for pain service infusions
- Lightweight and compact
- Reprogrammable for basal rate, bolus amount, lockout interval, and infusion volume
- Battery operated with long battery life
- Program lock-out to prevent program tampering
- Simple and intuitive operation
- Medication free-flow protection
- Latex free
- Visual and audible alarms
- Stable infusion rate at extremes of temperature and pressure
- Inexpensive
- Durable for long service life without needing maintenance
- Certified for use in US military aircraft

of CPNB and other pain management techniques during casualty evacuation depends on this technology. Infusion pumps for the austere military environment should have the attributes listed in Table 2-3. The pain infusion pump currently used during casualty evacuation for patient-controlled analgesia (PCA), epidural catheters, and CPNB is the AmbIT PCA pump (Sorenson Medical Inc, West Jordan, Utah [Figure 2-5]).

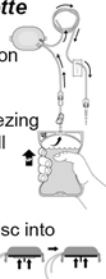

PCA Infusion Pump: Quick Setup & Programming Guide



Step A: Prepare Cassette

1. Attach Cassette to solution container.
2. Prime Cassette by squeezing solution container until all air is removed from bag and tubing.
3. Snap Cassette bottom disc into place to lock fluid path.
4. Bend away the wings of the protective cover. Insert the octagonal opening of the protective cover onto the shaft of the Cassette. Rotate shaft four (4) times counterclockwise. Remove protective cover.



Step B: Attach Cassette to Pump



Step C: Program Pump

1. Power on the Pump (see Clinician Manual).
2. To enter the programming mode, press and hold both the Run/Pause and Bolus buttons at the same time until one (1) beep is heard. "PRO" will appear in the display.
3. Set the program number (1-5) by pressing and releasing the

- Run/Pause button to increase the program number, or the Bolus button to decrease the program number.
4. To accept the program number, press and hold either the Run/Pause or Bolus button until one (1) beep is heard.
 5. If Program 1-4 is chosen, set the Volume to be Infused by pressing and releasing the Run/Pause button to increase the volume, or the Bolus button to decrease the volume.
 6. Once the desired Volume to be Infused is blinking on screen, press and hold either the Run/Pause or Bolus button until one (1) beep is heard.
 7. If Program 5 is chosen, move on to step C: number 8.
 8. The "ml/hr" indicator will begin to blink. Set the infusion rate by pressing and releasing the Run/Pause button to increase the rate, or the Bolus button to decrease the rate.
 9. To accept the setting, press and hold either button. The pump will beep and advance to the tenths number.
 10. Repeat steps 8 and 9 to set the Bolus Volume, Bolus Lockout Time, and the Volume to be Infused. When all steps are complete, the Pause indicator will blink in the display.

Program #5 Example Settings

Infusion Rate 3.0

Bolus Volume 2.2

Bolus Lockout Time 00:20

Volume to be Infused 250

Pause Indicator ☀

Step D: Start Infusion

1. Press and hold the Run/Pause button until one (1) beep is heard. **NOTE: If button is not held until beep is heard, pump will not go into run mode.**
2. The green Run light (inside the Bolus button) will begin to blink.



Step E: Pausing Infusion

1. Press and hold the Run/Pause button until two (2) beeps are heard. The Pause indicator will be displayed. **NOTE: If button is not held until beeps are heard, pump will not go into pause mode.**

Step F: Review Program Settings

1. Place the Pump in pause mode.
2. Press and release the Bolus button. Rx will appear in the display. Pump will then scroll through the program settings: (Program #, Basal Rate, Bolus Volume, Bolus Lockout Time, and Volume to be Infused).

Step G: Viewing & Clearing History

1. Viewing History:
 - a. Place the Pump in Pause. ▶/||
 - b. Press and hold the Bolus button until one (1) beep is heard and "HX" is in the display. HX

Release button and the Pump will scroll through the four history parameters:

 1. total ml infused
 2. # of bolus delivered
 3. # of bolus requests
 4. elapsed time
2. Clearing History: (Pump must be unlocked. See Clinician Manual.)
 - c. Perform steps a and b.
 - d. Release the button and again press and hold the Bolus button until one (1) beep is heard and "HX 0" is displayed. HX 0
 - e. Press and hold the Run/Pause button again until one (1) beep is heard to resume infusion. ▶/||

For 24 hour Clinical / Technical Assistance:
Call: (801) 352-1888
Toll Free (U.S.): (877) 352-1888

For complete pump operation instructions, see Clinician Manual.
1375 West 8040 South, West Jordan, UT 84088, USA
Fax: (801) 352-1818 www.sorensenmedical.com



Figure 2-5. Casualty evacuation acute pain management pump (AmbIT PCA pump [Sorensen Medical Inc, West Jordan, Utah; used with permission]) in current use, with operating instruction quick reference card

3. LOCAL ANESTHETICS

INTRODUCTION

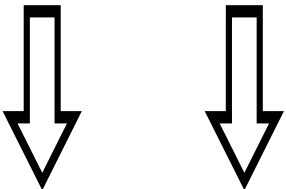
Compared to general anesthesia with opioid-based perioperative pain management, regional anesthesia can provide benefits of superior pain control, improved patient satisfaction, decreased stress response to surgery, reduced operative and postoperative blood loss, diminished postoperative nausea and vomiting, and decreased logistic requirements. This chapter will review the most common local anesthetics and adjuncts used in the US military for the application of regional anesthetic techniques, with particular emphasis on medications used for peripheral nerve block (PNB) and continuous peripheral nerve block (CPNB).

BASIC REVIEW OF LOCAL ANESTHETICS

Local anesthetics are valued for the ability to prevent membrane depolarization of nerve cells. Local anesthetics prevent depolarization of nerve cells by binding to cell membrane sodium channels and inhibiting the passage of sodium ions. The sodium channel is most susceptible to local anesthetic binding in the open state, so frequently stimulated nerves tend to be more easily blocked. The ability of a given local anesthetic to block a nerve is related to the length of the nerve exposed, the diameter of the nerve, the presence of myelination, and the anesthetic used. Small or myelinated nerves are more easily blocked than large or unmyelinated nerves (Table 3-1). Myelinated nerves need to be blocked only at nodes of Ranvier (approximately three consecutive nodes) for successful prevention of further nerve depolarization, requiring a significantly smaller portion of these nerves to be exposed to the anesthetic. Differential blockade to achieve pain and temperature block (A- δ , C fibers) while minimizing motor block (A- α fibers) can be

TABLE 3-1

NERVE CLASSIFICATION AND SEQUENCE OF BLOCK WHEN EXPOSED TO LOCAL ANESTHETIC

Fiber Type	Myelin	Diameter (μm)	Function	Conduction Velocity	Time to Block
A- α	Yes	12–20	Somatic motor and proprioception		Slow
A- β	Yes	5–12	Light touch and pressure		Fast
A- γ	Yes	3–6	Muscle spindle (stretch)		
A- δ	Yes	1–4	Pain (fast-localizing), temperature, firm touch		
B	Yes	1–3	Preganglionic autonomic		
C	No	0.3–1.3	Pain (nonlocalizing ache), temperature, touch, postganglionic autonomic		Slow

achieved by using certain local anesthetics and delivering specific concentrations to the nerve.

Local anesthetic structure is characterized by having both lipophilic and hydrophilic ends (ie, amphipathic molecules) connected by a hydrocarbon chain. The linkage between the hydrocarbon chain and the lipophilic aromatic ring classifies local anesthetics as being either an ester (–CO) local anesthetic, in which the link is metabolized in the serum by plasma cholinesterase, or an amide (–NHC) local anesthetic, in which the link is metabolized primarily in the liver.

The functional characteristics of local anesthetics are determined by the dissociation constant (pK_a), lipid solubility, and protein binding. The pK_a is the pH at which a solution of local anesthetic is in equilibrium, with half in the neutral base (salt) and half in the ionized state (cation). Most local anesthetics have a pK_a greater than 7.4. Because the neutral base form of the local anesthetic is more lipophilic, it can penetrate nerve membranes faster. As the pK_a of a local anesthetic rises, the percentage in the ionized

state increases and the onset of the block is slowed. Once the local anesthetic has passed through the cell membrane, it is exposed to the more acidic axoplasmic side of the nerve, favoring the ionized state. The ionized form of the molecule binds the sodium channel and blocks conduction.

The potency of local anesthetics is determined by lipid solubility. As lipid solubility increases, the ability of the local anesthetic molecule to penetrate connective tissue and cell membranes increases, causing the increase in potency.

The duration of action for local anesthetics is determined by protein binding. Local anesthetics with high affinity for protein binding remain bound to nerve membranes longer, resulting in an increased duration of action. Binding to serum α_1 -acid glycoproteins and other proteins decreases the availability of free drug in the blood, reducing the potential for toxicity in the primary organs. The free fraction of local anesthetic in the blood is increased in conditions of acidosis or decreased serum protein, thus heightening the potential for toxicity.

LOCAL ANESTHETIC TOXICITY

Shortly after Carl Koller introduced cocaine for regional anesthesia of the eye in 1884 and physicians worldwide began injecting cocaine near peripheral nerves, reports of “cocaine poisoning” began appearing in the literature. Local anesthetics are indispensable to the successful practice of regional anesthesia, and physicians who use these techniques must be familiar with the signs and symptoms of local anesthetic toxicity. Initial excitatory symptoms of local anesthetic toxicity are manifestations of escalating drug concentration in the central nervous system, specifically the amygdala. Increasing local anesthetic concentration begins to block inhibitory pathways in the amygdala, resulting in unopposed excitatory neuron function. This process is manifested clinically as symptoms of muscular twitching, visual disturbance, tinnitus, light-headedness, or tongue and lip numbness. Extreme patient anxiety, screaming, or concerns about imminent death are also suggestive of toxicity. As the blood concentration of local anesthetic increases, these initial symptoms, without intervention, will progress to generalized tonic-clonic convulsions, coma, respiratory arrest, and death.

The cardiovascular system, though significantly more resistant to local anesthetic toxicity than the central nervous system, will exhibit arrhythmias and eventual collapse as local anesthetic concentrations increase. The relationship between the blood concentration of a particular local anesthetic that results in circulatory collapse and the concentration needed to cause convulsions is called the circulatory collapse ratio. As this ratio becomes smaller, the interval between convulsions and circulatory collapse decreases. Generally, this ratio tends to be small in the more potent, long-acting local anesthetics (bupivacaine and ropivacaine) compared with intermediate- and shorter-acting drugs (mepivacaine and lidocaine). The more potent a local anes-

thetic, the greater potential it has for causing cardiac depression and arrhythmias.

Local anesthetics have been shown to be myotoxic in vivo, although little evidence is available to determine this phenomenon’s clinical relevance. Nevertheless, practitioners using local anesthetic for PNB or CPNB should consider the myotoxic potential of these medications in cases of unexplained skeletal muscle dysfunction. Local anesthetics have also been demonstrated to be neurotoxic in vitro, but the clinical significance of these findings remains theoretical.

A variety of anesthesia textbooks publish maximum recommended dosages for local anesthetics in an attempt to prevent high dose injections leading to toxicity. Because local anesthetic toxicity is related more to intravascular injection than to total dose, some physicians have suggested maximum dose recommendations are irrelevant. It is reasonable to assume that intravascular injections will occur, and practitioners of regional anesthesia should select techniques designed to minimize their occurrence, while maintaining preparation for appropriate treatments to use when such injections occur. The site of injection also affects the blood concentrations of local anesthetic. Blood absorption of local anesthetic varies at different injection sites according to the following continuum (from greatest to least absorption): intercostal > caudal > epidural > brachial plexus > femoral–sciatic > subcutaneous > intraarticular > spinal. Taking these factors into consideration, recommended techniques and conditions for local anesthetic injection are listed in Table 3-2.

Ropivacaine. Ropivacaine (Naropin, Abraxis BioScience Inc, Schaumburg, Ill) has a pK_a of 8.2. It is chemically similar to both mepivacaine and bupivacaine, but it is unique in being the first local anesthetic marketed as a pure levorotatory stereoisomer rather than a racemic mixture (ie, a combination of levorotatory and dextrorotatory molecules).

Levorotatory enantiomers of local anesthetics are typically less toxic than dextrorotatory enantiomers. Because ropivacaine is less cardiotoxic than bupivacaine, it is the preferred long-acting local anesthetic for PNB anesthesia for many providers. The motor-block-sparing properties associated with ropivacaine spinal and epidural analgesia may provide an advantage over bupivacaine. Ropivacaine is considered the safest long-acting local anesthetic currently available, but it is not completely safe (cardiovascular collapse has been reported with its use), and all standard precautions should be observed with its use. Ropivacaine is the long-acting local anesthetic of choice at Walter Reed Army Medical Center because of its favorable safety profile and efficacy when used in a variety of regional anesthetics (Table 3-3).

Bupivacaine. Bupivacaine (Marcaine, Sensorcaine; both made by AstraZeneca, London, United Kingdom) has a pK_a of 8.1. With an extensive history of successful use, bupivacaine is the long-acting local anesthetic to which others are compared. Although a bupivacaine block is long acting, it also has the longest latency to onset of block. Bupivacaine is noted for having a propensity for sensory block over motor block (differential sensitivity) at low concentrations. These factors, as well as the low cost of bupivacaine compared to newer long-acting local anesthetics, have established bupivacaine as the long-acting local anesthetic of choice in many institutions. When long-duration analgesia is required, the use of bupivacaine for low-volume infiltration or spinal anesthesia is well established.

In spite of the popularity of bupivacaine for regional anesthesia, its use for large-volume techniques such as epidural or peripheral nerve anesthesia may be problematic; prolonged resuscitation following accidental intravascular injection has been reported. The recommended dosages of bupivacaine are the lowest of any of the amide local an-

esthetics. If patient safety were the only issue (other than cost, convenience, or availability) involved in long-acting local anesthetic selection, less toxic options would likely be used for large volume-blocks. This issue remains controversial.

Mepivacaine. Mepivacaine (Polocaine [Abraxis BioScience Inc, Schaumburg, Ill]; Carbocaine [AstraZeneca, London, United Kingdom]) has a pK_a of 7.6. In terms of function and toxicity, mepivacaine is often compared to lidocaine. In dogs, mepivacaine has been shown to be less cardiotoxic than lidocaine. Mepivacaine can be used for infiltration anesthesia with a similar onset to lidocaine but a longer duration. It is considered one of the least neurotoxic local anesthetics. In addition to low toxicity, mepivacaine has other properties that make it an attractive local anesthetic for intermediate-acting PNB, particularly in high-risk cardiac patients. Mepivacaine has excellent diffusion properties through tissue, allowing block success despite less than optimal needle position. It also produces intense motor block, which is desirable for a variety of surgical procedures such as shoulder surgery. Mepivacaine is the preferred local anesthetic to reestablish surgical block via preexisting CPNB catheters for patients requiring multiple operations. Low toxicity, rapid onset, and dense motor block make mepivacaine attractive for this application.

Lidocaine. With a low pK_a (7.7) and moderate water and lipid solubility, lidocaine or lignocaine (Xylocaine [AstraZeneca, London, United Kingdom]) is the most versatile and widely used local anesthetic. Subcutaneous infiltration of lidocaine is the favored analgesic technique for many percutaneous procedures (such as venous cannulation). Despite a long history as the preferred agent for short-duration spinal anesthesia, intrathecal lidocaine use has become controversial because of its association with transient neurologic

syndrome. Lidocaine 0.5% is the most common local anesthetic used for intravenous regional anesthesia. Its low pK_a facilitates distribution of the local anesthetic into the exsanguinated extremity.

For use as an epidural anesthesia, lidocaine 2% is popular for cesarean sections and other major operations of the abdomen and lower extremities because of its low systemic toxicity, rapid onset, and intermediate length of duration. Lidocaine use for PNB has also been described; however, most physicians prefer longer acting local anesthetics for PNB, so that the duration of analgesia extends well into the postoperative recovery period.

REGIONAL ANESTHESIA ADJUNCTS AND ADDITIVES

The safe practice of regional anesthesia assumes an awake, though possibly sedated, patient who can manifest early signs and symptoms of evolving central nervous system or cardiovascular local anesthetic toxicity. Moderate sedation is used by many practitioners to reduce the pain and anxiety that many patients perceive during regional anesthesia procedures. Although a variety of intravenous medications are available for sedation, midazolam, fentanyl, and propofol are common. Deep sedation or general anesthesia is avoided because patient indicators of pending local anesthetic toxicity or nerve injury are masked. Even moderate sedation with midazolam and fentanyl degrades detection of these patient indicators of injury. The anesthesiologist must skillfully titrate sedation to strike a balance between patient comfort and safety during block placement.

The use of propofol and propofol with ketamine in the operating room following block placement for sedation is increasingly common. Ease of titration and rapid recovery with minimal side effects have popularized these medications for sedation complementing the regional block.

Remifentanyl has also been successfully infused for regional anesthesia sedation and compares favorably with propofol.

Epinephrine (1:200,000 or 1:400,000) is one of the most common local anesthetic additives. It is combined with local anesthetics to produce regional vasoconstriction, resulting in block prolongation and reduced levels of local anesthetic in plasma. Epinephrine added to local anesthetics also serves as a marker of intravascular injection during single injection blocks. Accidental intravascular injection is indicated by observation of increased heart rate (≥ 10 beats/min), increased systolic blood pressure (≥ 15 mmHg), or decreased electrocardiogram T-wave amplitude (depression $\geq 25\%$), associated with as little as 10 to 15 μg of intravascular epinephrine. Epinephrine containing local anesthetic “test dose” injections via epidural and peripheral nerve catheters with gentle aspiration is an accepted method to protect against intravascular placement. Based on animal models, concerns that epinephrine containing local anesthetics may enhance ischemia following nerve injury or circulatory compromise have caused some physicians to reduce the dose of epinephrine (1:400,000) or limit its use to the test dose.

A plethora of local anesthetic additives have been used to enhance block duration and quality of analgesia. Multiple studies have shown the addition of opioids to intrathecal local anesthetics prolongs sensory anesthesia without prolonging recovery from ambulatory procedures. The combination of local anesthetics with opioids for epidural anesthesia and analgesia is a common practice and has been shown to reduce local anesthetic requirements in obstetric patients. Despite the recognition of opioid receptors outside of the central nervous system, the addition of opioids to peripheral nerve injections of local anesthetics has not been successful in improving PNB characteristics.

Clonidine, an α_2 -adrenoceptor agonist that provides analgesia via a nonopioid receptor

mechanism, has been shown to be effective in prolonging analgesia in spinal, epidural, and peripheral nerve blocks. Clonidine 100 μ g is frequently added to local anesthetic for PNBs at Walter Reed Army Medical Center to prolong analgesia. Dexamethasone 8 mg added to local anesthetics has also been reported to enhance the duration of sensory and motor blockade.

The list of medications used to improve regional anesthesia continues to grow, including drugs such as midazolam, tramadol, magnesium, neostigmine, and ketamine, as well as others that have had varying success. Expanding the list of local anesthetic drugs has the potential to improve patient safety, enhance analgesia, and expand the role of regional anesthesia in perioperative management.

TABLE 3-2

RECOMMENDED TECHNIQUES AND CONDITIONS TO MINIMIZE THE RISK OF LOCAL ANESTHETIC INTRAVASCULAR INJECTION

-
- Standard monitoring with audible oxygen saturation tone.
 - Oxygen supplementation.
 - Slow, incremental injection (5 mL every 10–15 seconds).
 - Gentle aspiration for blood before injection and every 5 mL thereafter.
 - Initial injection of local anesthetic test dose containing at least 5–15 μ g epinephrine with observation for heart rate change > 10 beats/min, blood pressure changes > 15 mmHg, or lead II T-wave amplitude decrease of 25%.
 - Pretreatment with benzodiazepines to increase the seizure threshold to local anesthetic toxicity.
 - Patient either awake or sedated, but still able to maintain meaningful communication with the physician.
 - Resuscitation equipment and medications readily available at all times.
 - If seizures occur, patient care includes airway maintenance, supplemental oxygen, and termination of the seizure with propofol (25–50 mg) or thiopental (50 mg).
 - Local anesthetic toxicity that leads to cardiovascular collapse should immediately be managed with prompt institution of advanced cardiac life support (ACLS) protocols.
 - Intralipid (KabiVitrum Inc, Alameda, Calif) 20% 1 mL/kg every 3–5 minutes, up to 3 mL/kg, administered during ACLS for local anesthetic toxicity can be life saving. Follow this bolus with an Intralipid 20% infusion of 0.25 mL/kg/min for 2.5 hours.
-

TABLE 3-3

STANDARD ADULT ROPIVACAINE DOSAGES FOR SINGLE INJECTION AND CONTINUOUS REGIONAL ANESTHESIA AT WALTER REED ARMY MEDICAL CENTER

Regional Anesthesia Technique	Adult Single Injection*	Continuous Infusion of 0.2% Ropivacaine (mL/h)	Patient-Controlled Bolus Rate of 0.2% Ropivacaine [†] (mL bolus/20 min lockout)	Notes
Interscalene	30–40 mL of 0.5% ropivacaine	8–10	2–3	Often supplemented with an intercostal brachial nerve block
Supraclavicular	30–40 mL of 0.5% ropivacaine	8–10	2–3	Shortest latency block of the brachial plexus
Infraclavicular	35–40 mL of 0.5% ropivacaine	10–12	2–3	Catheter techniques less effective compared to supraclavicular catheters
Axillary	40 mL of 0.5% ropivacaine	10–12	2–3	Catheter techniques less common
Paravertebral	3–5 mL of 0.5% ropivacaine per level blocked	8–10	2–3	Catheters effective in thoracic region only
Lumbar plexus (posterior approach)	30–40 mL of 0.5% ropivacaine	8–10	2–3	Epidural spread is a concern
Femoral	20–30 mL of 0.5% ropivacaine	8–10	2–3	Catheter techniques may miss the obturator or lateral femoral cutaneous nerves
Sciatic (anterior or posterior approach)	20–30 mL of 0.5% ropivacaine	8–10	2–3	Proximal approaches to the sciatic nerve preferable for catheters
Sciatic (lateral or popliteal approach)	35–40 mL of 0.5% ropivacaine	10–12	2–3	Often the only approach available to the sciatic nerve following polytrauma
Lumbar plexus or femoral + sciatic	50–60 mL of 0.5% ropivacaine between both sites	5–10 for both catheters	2–3 on one catheter	Infusion rates divided between catheters based on distribution of patient's pain
Epidural	20–25 mL of 0.5% ropivacaine	6–10 thoracic 10–20 lumbar	2–3	Opioids often added to infusions
Spinal	5–15 mg of 1.0% ropivacaine	NA	NA	Opioids often added to injections

*Mepivacaine 1.5% can be used in place of ropivacaine at the volumes noted when a shorter duration block is desirable.

[†]Occasionally, a 5 mL bolus per 30-minute lockout is used in selected patients. Generally, total infusion (continuous plus bolus) > 20 mL/h are avoided.

NA: not applicable.

4. NERVE STIMULATION AND ULTRASOUND THEORY

NERVE STIMULATION

The concept of using an electric current to generate muscle contractions via nerve stimulation is nearly a century old, although the theory behind peripheral nerve stimulation is still poorly understood. Actual electrical stimulation of nerves to evoke a muscle response was first accomplished in 1850 by Herman von Helmholtz during experiments on isolated pieces of nerve and muscle tissues. In 1912 Dr VG Perthes described using a nerve stimulator to perform peripheral nerve blocks. Recent technological advances have made the use of nerve stimulation equipment easier and far more accurate than in past decades.

Ideally, a peripheral nerve stimulator (PNS), in combination with an insulated needle, provides objective information on needle location by eliciting muscular twitches in muscle groups served by targeted nerves. At the most basic level, a PNS works by generating an electric current and transmitting it via a needle insulated along most of its length, leaving only the needle tip exposed to deliver the current in very close proximity to targeted nerves. A few additional concepts, however, are essential to understanding how the PNS is used in peripheral nerve block procedures. For a nerve to be stimulated, its threshold potential must be achieved. To accomplish this, electrical energy is applied in the specific amount for electrons to depolarize the nerve cell membrane (threshold depolarization), causing shifts in intracellular and extracellular sodium and potassium ions. The impulse is then propagated along the nerve via saltatory conduction.

The threshold level of energy for depolarization of the nerve can be achieved by applying a high current over a short period of time or a lower current over a longer period of time; this is the most basic way to understand the concepts of “reobase” and “chronaxie.” Reobase is defined

as the minimum current necessary to achieve threshold potential over a long pulse. Chronaxie is the minimum duration of stimulus at twice the reobase for a specific nerve to achieve threshold potential. Certain nerves have a different chronaxie based on their physical properties (myelination, size, etc). Also, certain patient conditions, such as diabetes, have an effect on chronaxie. Large A-alpha motor fibers are more easily stimulated than are the smaller A-delta and C fibers, which are responsible for pain. The normal pulse duration needed for depolarization is between 50 and 100 microseconds for A-alpha fibers, 170 microseconds for A-delta fibers, and 400 microseconds for C fibers. By applying this knowledge, the duration of the PNS pulse can be adjusted to keep it above the normal A-alpha range and below the A-delta and C fiber level. The stimulation of motor A-alpha fibers provides muscle twitch information while avoiding A-delta and C fibers that cause pain, thus allowing for a more comfortable nerve stimulation experience for the patient. If the current is too high (eg, > 1.0 mA), the PNS may no longer be able to differentially stimulate nerve fibers.

By understanding the concepts of reobase and chronaxie, adjustments can be made to some nerve stimulators to achieve stimulation of targeted nerve fibers only, or of nerves that may not otherwise be stimulated with a PNS. For example, in diabetic patients with a prolonged history of elevated blood glucose levels, nerves may become glycosylated, making stimulation difficult. In these patients, increasing the duration of the electric pulse may be the only way to achieve a minimum current of 0.5 mA for stimulating a nerve.

Another important difference between a modern PNS (Figure 4-1) and older models is the ability to provide constant current output. According to Ohm’s law, $I=V/R$, where I is the current, V is the potential difference in volts, and R is the resistance or impedance. If resistance (impedance) were com-

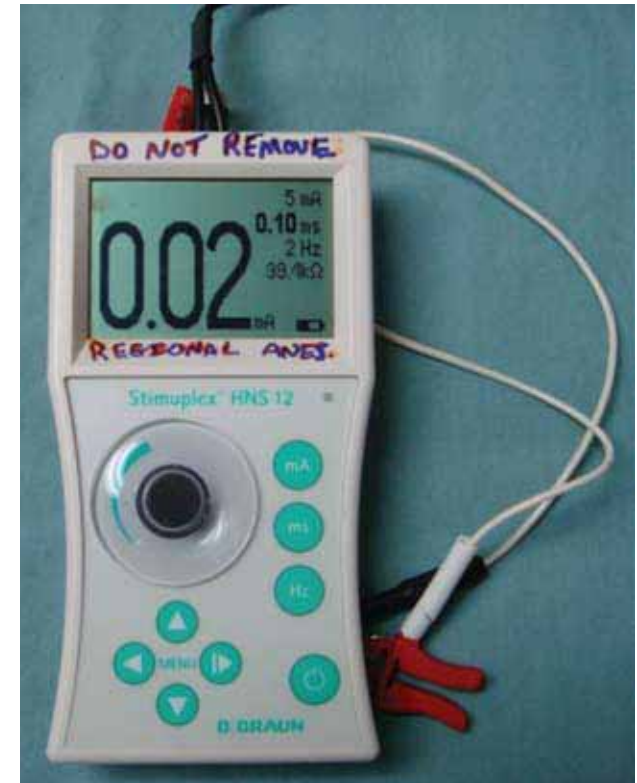


Figure 4-1. HNS 12 nerve stimulator manufactured by B Braun Medical Inc (Bethlehem, Pa; used with permission)

pletely removed from the equation, then current would equal the potential difference. In some modern PNS models, this equilibrium is achieved by a constant current generator that automatically adjusts the current set by the user. The constant output maintains the same level of needle tip current regardless of the impedance of body tissue and PNS circuit connections.

The ability to control the intensity and frequency (2 Hz) of the current being applied is an important aspect of a PNS. Using a higher current for initial nerve stimulation allows for earlier identification of the nerve’s location. Decreasing the current once

stimulation has been achieved allows the operator to place the needle in close proximity to the target nerve. Constant stimulation of the nerve below 0.5 mA but above 0.2 mA generally results in a safe, reliable block. The commonly used 2-Hz frequency allows for rapid manipulation of the needle to help locate the nerve.

ULTRASOUND GUIDANCE

Another recent technological advance of extraordinary benefit to the regional anesthesiologist is the portable ultrasound machine (Figure 4-2), which allows for real-time visualization of target nerves, as well as surrounding arteries, veins, muscle, and bone. Ultrasound technology also provides the ability to validate external landmarks against internal anatomy. Furthermore, the advantage of needle guidance under direct visualization allows the operator to avoid vascular structures and more accurately inject local anesthetic.

Most modern ultrasound machines have the ability to provide visualization of both superficial and deep structures based on the type of probe used. Basic understanding of ultrasound theory is vitally important for the safe use of this technology. Ultrasound waves are created by a number of vibrating piezoelectric crystals contained in the head of a transducer attached to the ultrasound machine. Ultrasound waves penetrate tissues to different depths based on the probe frequency. Higher frequency probes, which emit waves at a frequency between 5 and 13 MHz, provide images with greater resolution but do not penetrate deeply into tissue. Lower frequency probes, with frequencies between 2 and 5 MHz, can penetrate tissue deeply (up to a depth of 30 cm), but the resolution is far less than that of the high frequency probes.

The image produced by the ultrasound machine depends on both the tissue's density and its ability to reflect ultrasound waves back to the transducer (ie, the tissue's echogenicity). Hyperechoic struc-



Figure 4-2. Micromaxx Ultrasound Machine manufactured by SonoSite, Inc (Bothell, Wash)

tures are those with a greater propensity to reflect ultrasound energy, and hypoechoic structures tend to absorb this energy. Hyperechoic structures (bone, nerves below the clavicle, vascular walls, and other connective tissues) therefore appear brighter on the screen, and hypoechoic structures (nerves above the clavicle, blood vessel lumens, lung, and other fluid-filled structures) appear

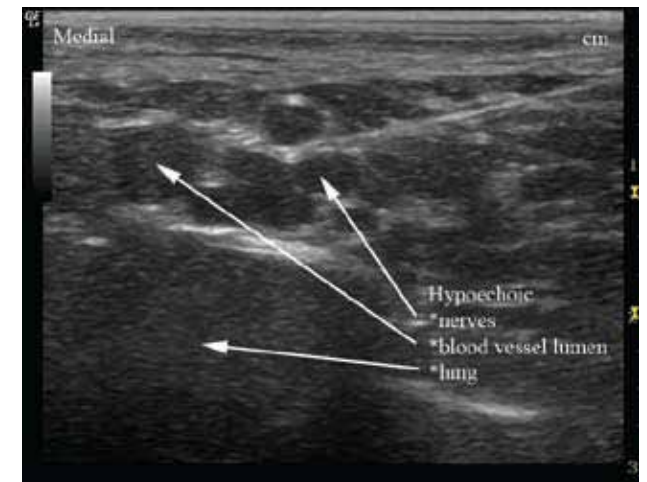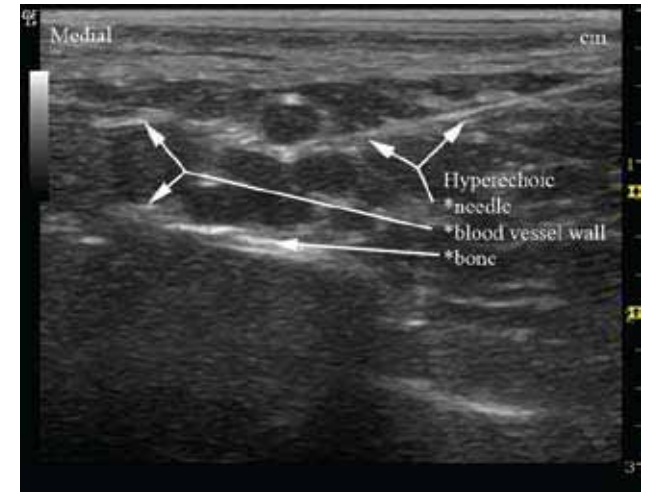


Figure 4-3. (a) Hyperechoic structures and (b) hypoechoic structures seen on ultrasound

darker (Figure 4-3). Acoustic impedance refers to the reduction in ultrasound wave energy that occurs as the wave passes through structures, which accounts for the depth limits on ultrasound penetration of tissues.

The operator's knowledge of anatomy is fundamental to the safe practice of ultrasound-guided regional anesthesia. Once the nerves are identified, the block is performed with the needle under direct visualization in the long-axis view (in plane) and the nerve in the short-axis view. Some experienced ultrasound operators prefer the out-of-plane technique (with the needle in short-axis view) for some blocks. Although this technique results in shorter needle distances to targeted nerves, it does not allow visualization of the entire needle during performance of the block. Both techniques allow the needle to be directed away from potentially dangerous areas and the local anesthetic to be deposited in multiple locations around the nerve for a safe, successful regional nerve block.

If the operator is uncertain about the needle tip's proximity to imaged structures, hydrodissection under ultrasound guidance may be used. This technique involves slowly injecting several milliliters of local anesthetic (or other fluid such as saline) to more precisely define the needle tip location. For example, if the injected fluid spreads away from the targeted nerve, the needle tip is probably external to the nerve sheath. Injected hypoechoic fluid also may enhance image clarity of the targeted structures.

Many compact ultrasound machines are currently available with updated software that improves image quality to a standard until recently obtainable only in large, cumbersome, and expensive

machines. Thorough familiarization with the ultrasound machine being used and its available options is necessary to obtain the best possible image for facilitating needle placement. Many ultrasound machine options are available, but most machines include a few basic image adjustment features:

- Depth control: allows the user to set a tissue depth (in cm) that the ultrasound waves will penetrate.
- Gain control: allows the user to adjust the screen grayscale contrast, thus alleviating unnecessary interference from poor tissue conduction properties, poor probe-to-tissue interface, or other problems.
- Doppler mode: allows for differentiation of structures containing moving fluid such as arteries and veins.
- Focus setting, including three basic image resolution settings:
 - o RES (resolution): provides the best detail of superficial structures.
 - o GEN (general): provides the best compromise for visualizing structures in detail at greater depth.
 - o PEN (penetration): provides the best image of deep structures, although image detail is significantly degraded.
- Zoom: magnifies image up to 200%.
- Image freeze and save: allows still pictures of

ultrasound blocks to be saved for documentation of the block procedure.

- Patient data screen: allows patient demographic data to be associated with saved ultrasound images.

Other advances in ultrasound software, such as clearer images through signal harmonics and three-dimensional ultrasound imaging, continually improve the value of ultrasound technology as a tool in regional anesthesia. The availability of this technology on a laptop, easily portable in the austere battlefield medical environment, is a particularly exciting advancement.

CONCLUSION

Whether nerve stimulators, ultrasound machines, or both are used to perform regional anesthesia, a basic understanding of how these technologies function when used on live tissues is an important addition to, but not a replacement for, detailed anatomical knowledge. This technology can only confirm and refine correct needle placement for regional blocks; it should never be considered a substitute for the physician's understanding of the anatomical basis for each block. Both tools likely enhance patient safety and improve nerve block success when used by a trained regional anesthesiologist. *Note: The technology shown to demonstrate concepts in this chapter should not be considered as an endorsement of these products or companies.*

5. UPPER EXTREMITY NEUROANATOMY

INTRODUCTION

Regional anesthesia of the upper extremity involves two major nerve plexuses, the cervical plexus and the brachial plexus. A detailed understanding of the anatomy of these nerve plexuses and surrounding structures is essential for the safe and successful practice of regional anesthesia in this area of the body.

CERVICAL PLEXUS

The cervical plexus is formed from a series of nerve loops between adjacent anterior rami of cervical nerve roots C1 through C4. The cervical plexus is deep to the sternocleidomastoid muscle and medial to the scalene muscles. The deep branches of the plexus are motor nerves. They include the phrenic nerve (diaphragm muscle) and the ansa cervicalis nerve (omohyoid, sternothyroid, and sternohyoid muscles). The named nerves of the superficial cervical plexus are branches from the loops and emerge from the middle of the sternocleidomastoid muscle (Figure 5-1):

- *Lesser occipital nerve* (C2): innervates the skin posterior to the ear.
- *Great auricular nerve* (C2–C3): innervates the ear and angle of the mandible to the mastoid process.
- *Transverse cervical nerve* (C2–C3): innervates the anterior neck.
- *Supraclavicular nerve* (C3–C4): innervates the area over the clavicle and shoulder.

The spinal accessory nerve (CN XI) emerges at the posterior border of the sternocleidomastoid muscle, passing superficial to the levator scapulae muscle to innervate the trapezius muscle. Stimulation of this nerve during interscalene block, which causes the shoulder to shrug, is occasionally mistaken as stimulation of the brachial plexus. Injection of local anesthetic based on this stimulation pattern will result in a failed interscalene block.

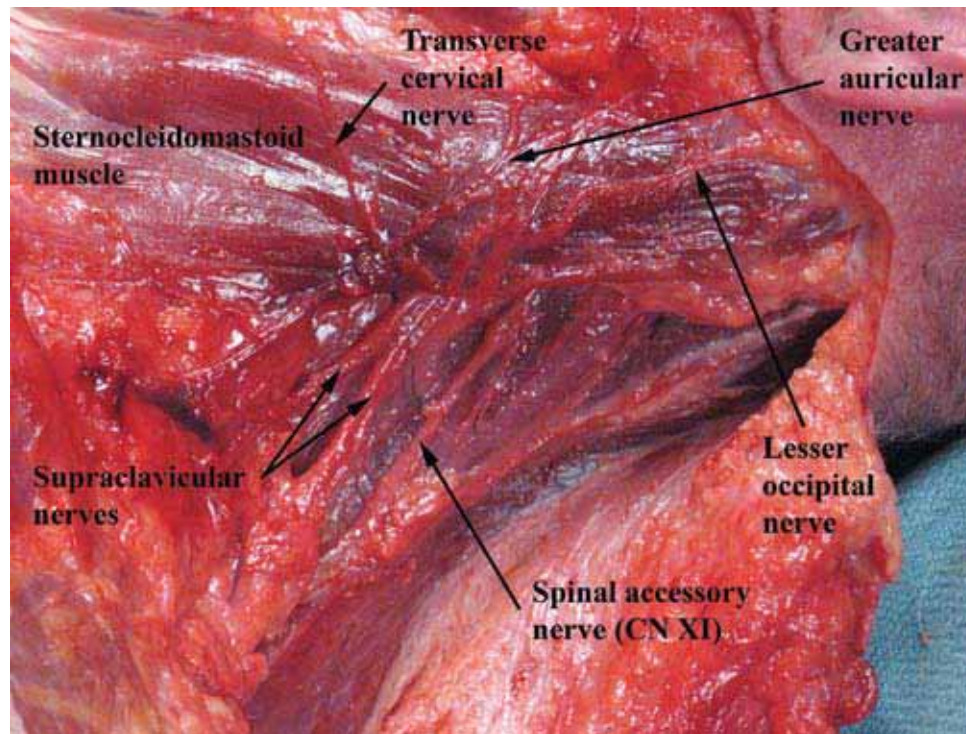


Figure 5-1. Dissection of the superficial cervical plexus in the posterior triangle

BRACHIAL PLEXUS

The brachial plexus is formed from the five roots (anterior rami) of C5–T1. Occasionally contributions to the brachial plexus come from C4 (prefixed plexus) or from T2 (postfixed plexus). There are seven described variations of brachial plexus anatomy, with the most common variant (Figure 5-2) occurring 57% of the time. Asymmetry between the left and right brachial plexus in the same individual occurs 61% of the time. Brachial plexus anatomy includes the following parts:

- **Three trunks.** The five roots unite to form the three trunks of the brachial plexus; superior (C5 and C6), middle (C7), and inferior (C8 and T1). The trunks pass between the anterior and middle scalene muscles.
- **Six divisions.** Each trunk divides into an anterior division (anterior flexor compartments of the arm) and a posterior division (posterior extensor

compartments of the arm). The brachial plexus divisions pass posterior to the mid-point of the clavicle through the cervico-axillary canal.

- **Three cords.** The divisions coalesce to form three cords. The anterior divisions of the superior and middle trunk form the *lateral cord*. The anterior division of the inferior trunk becomes the *medial cord*. The posterior divisions of all three trunks unite to form the *posterior cord*. The cords are named based on

their relationship to the axillary artery (as this neurovascular bundle passes in its sheath into the axilla).

- **Five terminal branches.** The cords give rise to five terminal branches. The *musculocutaneous nerve* (C5–C7) arises from the lateral cord and innervates the coracobrachialis, biceps brachii and brachialis muscles, and the skin to the lateral forearm. The *median nerve* is a compilation of the lateral cord (C6–C7) and the medial cord (C8, T1). It innervates muscles of the anterior forearm and the thenar half of the muscles and skin of the palm. The *ulnar nerve* is a branch of the medial cord (C7–T1) and innervates the forearm and hand medial to the midpoint of digit four. The *axillary nerve* (C5–C6) is a branch of the posterior cord and innervates the shoulder joint and lateral skin over the deltoid muscle. The *radial nerve* (C5–T1), which is also a branch of the posterior

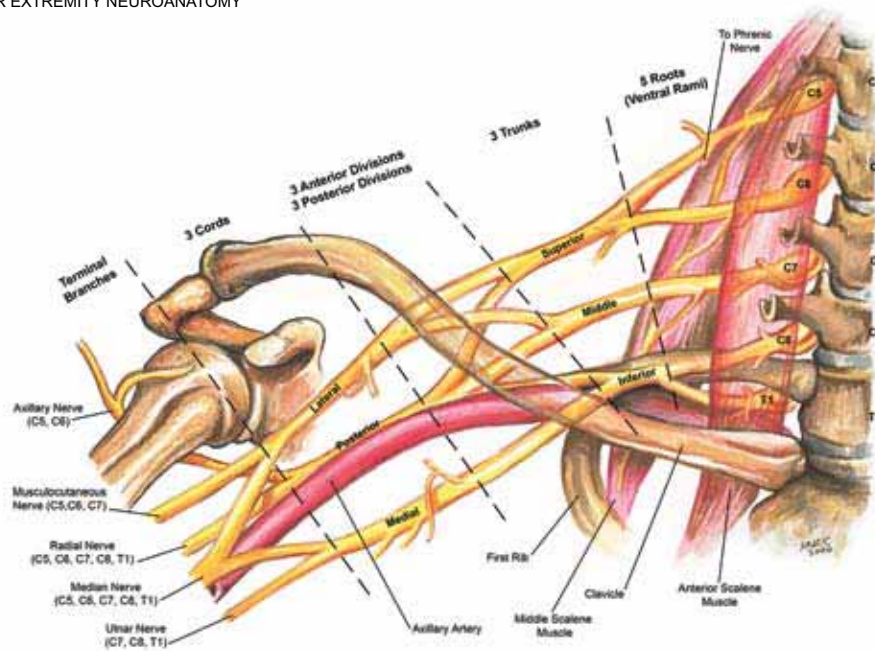


Figure 5-2

cord, innervates all of the muscles of the posterior compartments of the arm and forearm and most of the posterior skin of the upper extremity. Although there are numerous other named branches of the brachial plexus, familiarization with the plexus as outlined above is adequate for most upper extremity regional anesthesia procedures.

Considerable controversy has arisen about the existence of a nerve “sheath” surrounding the brachial plexus and including the artery, vein, and investing connective tissue. Anatomical dissection of the brachial plexus consistently reveals a distinguishable sheath of fibrous tissue surrounding the brachial plexus, vasculature, and loose investing connective tissue. In Figure 5-3, the platysma muscle has been reflected, exposing the brachial plexus sheath just posterior to the omohyoid muscle and lateral to the sternocleidomastoid muscle. In Figure

5-4, the omohyoid muscle has been retracted, and the sheath has been filled with normal saline. The nerves of the brachial plexus can now be seen through the “window” created by the fluid-filled sheath.

The existence of nerve sheaths is not unique to the brachial plexus and can be demonstrated on neurovascular structures throughout the human body. The practice of regional anesthesia depends on the anatomical fact of the sheath. The sheath improves the success of single injection blocks and continuous peripheral nerve catheters by containing the local anesthetic near nervous tissue targets and allowing the anesthetic to surround and bathe the nerves.

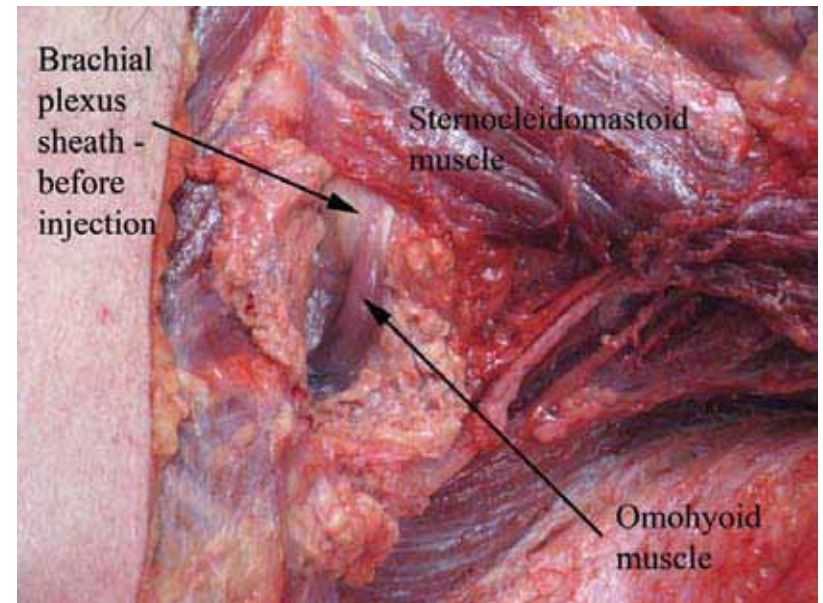


Figure 5-3. Sheath prior to injection with saline

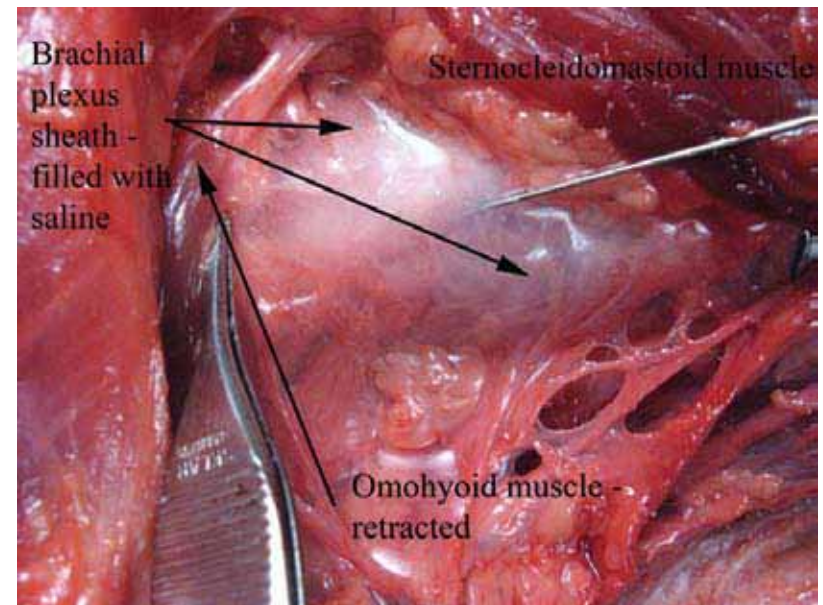


Figure 5-4. Sheath injected with normal saline. Note the nerve tissue visible within the sheath.

6. CERVICAL PLEXUS BLOCK

INTRODUCTION

The cervical plexus block provides anesthesia and analgesia to the head and neck region. Depending on the type of surgery, the plexus can be blocked either at a superficial or a deep level. The superficial branches (Figure 6-1) of the plexus innervate the skin and superficial structures of the head, neck, and shoulder. The deep branches (Figure 6-2) innervate the muscles of the deep anterior neck and the diaphragm. The deep cervical plexus block is used for deeper surgeries of the neck, such as carotid artery or thyroid surgery, and the superficial cervical plexus block is used for su-

perficial cutaneous surgeries of the head and neck. This block is also useful as a supplement to other regional techniques of the upper torso.

ANATOMY

The cervical plexus is formed from the anterior rami of the C1 through C4 nerve roots; it lies anterior to the cervical vertebrae and posterior to the sternocleidomastoid muscle. There are five main components of the cervical plexus: (1) the cutaneous branches, which supply the lesser occipital, greater auricular, transverse cervical, and supraclavicular nerves; (2) the ansa cervicalis, which innervates the infrahyoid and geniohyoid muscles; (3) the phrenic nerve, which is the only motor nerve to innervate

the diaphragm; (4) contributions to the accessory nerve (CN XI), which innervates the sternocleidomastoid and trapezius muscles; and (5) direct muscular branches, which supply prevertebral muscles of the neck.

Bilateral deep cervical plexus blocks, which would result in total diaphragmatic paresis, should not be performed. Also, patients with chronic respiratory conditions may not be suitable candidates for an ipsilateral deep cervical plexus block. Caution must be taken when placing a deep cervical plexus block because of the close proximity of the vertebral artery and the dural sleeve. Placing the block too close to the vertebral artery may result in an intravascular injection; placing it too close to the dural sleeve may result in a subarachnoid injection.

Figure 6-1. Superficial cervical plexus

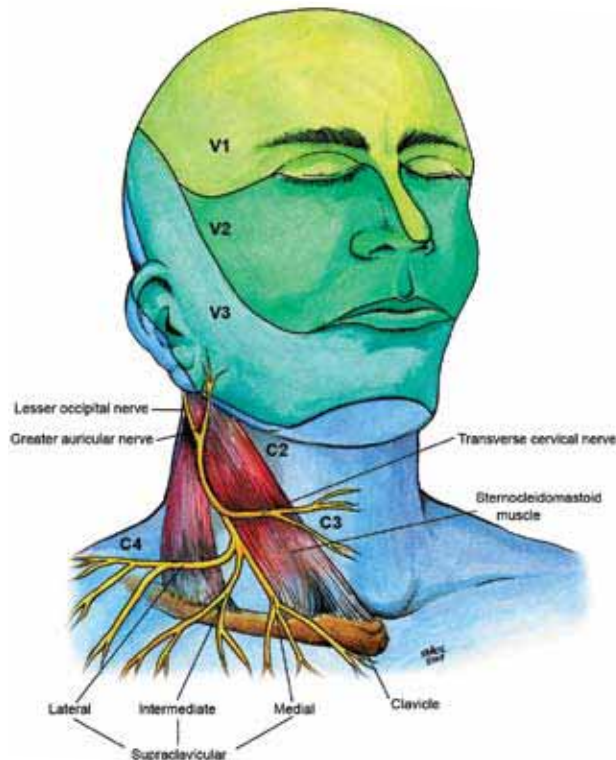
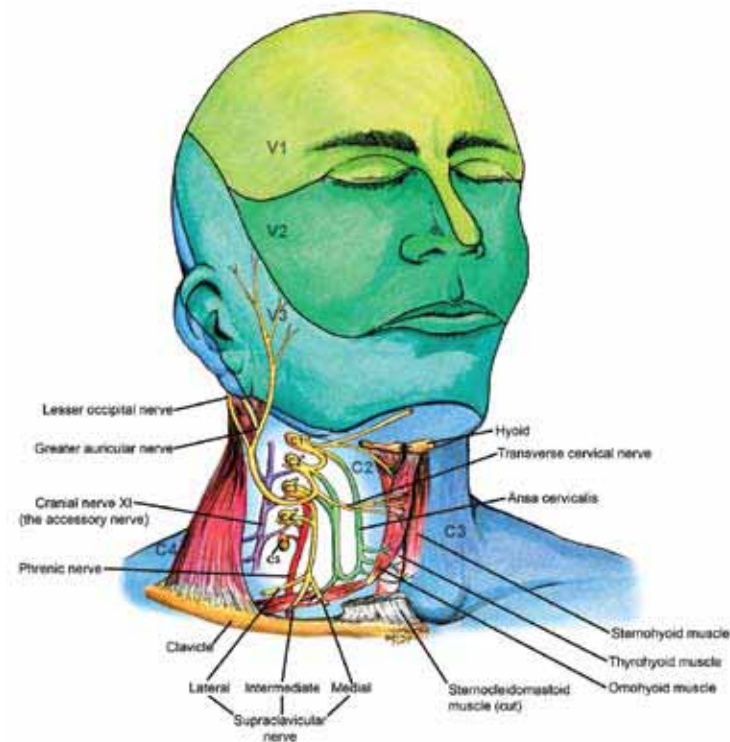


Figure 6-2. Deep cervical plexus



PROCEDURE

Landmarks

Superficial Cervical Plexus (Figure 6-3). Identify and mark the posterior border of the sternocleidomastoid, as well as the midpoint of the muscle.

Deep Cervical Plexus (Figure 6-4). Position the patient supine with the head turned toward the nonoperative side. Palpate the transverse process of C6 (Chassaignac's tubercle) at the level of the cricoid cartilage. Palpate the mastoid process behind the ear. Draw a line between the mastoid process and Chassaignac's tubercle. The transverse processes of the other cervical vertebrae will lie on or near this line. The first palpable transverse process below the mastoid process is C2. Palpate and mark the transverse processes of C2 to C4 (the C4 transverse process lies approximately at the level of the mandible). Insert the needle medially and caudally so that the needle tip is resting on the transverse process.

Needles

- 22-gauge, 5-cm, short bevel needle.

Injection

Superficial Cervical Plexus. Insert the needle at the midpoint of the posterior border of the sternocleidomastoid muscle to approximately half the depth of the muscle, and inject 3 to 4 mL of local anesthetic. Also perform a subcutaneous injection of additional local anesthetic cephalad and caudad along the length of the sternocleidomastoid muscle posterior border.

Deep Cervical Plexus. Attach a 10-mL control syringe to the needle. Once the transverse process

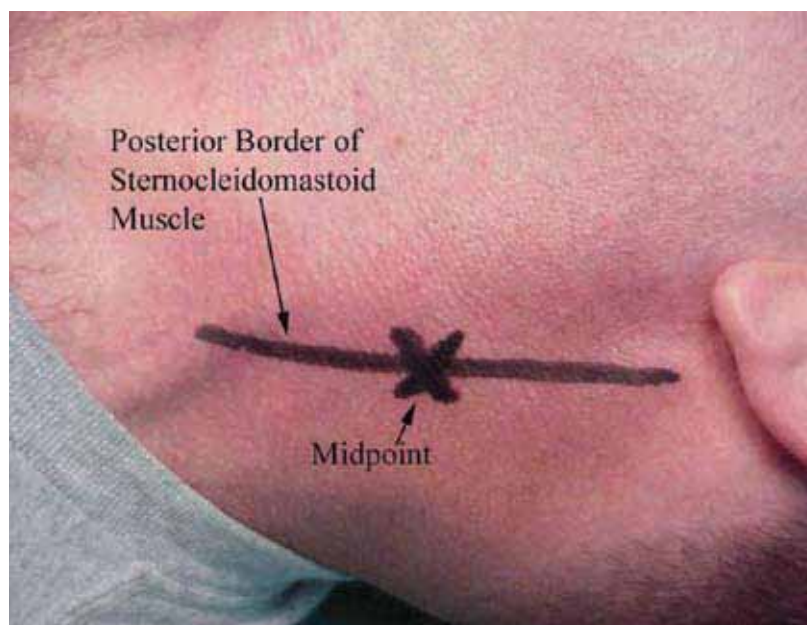


Figure 6-3

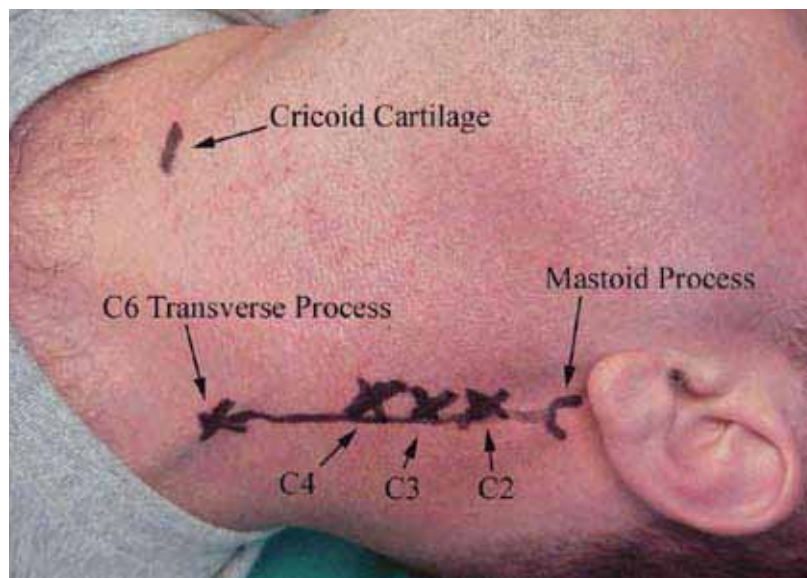


Figure 6-4

is contacted, withdraw the needle 1 to 2 mm. Inject the local anesthetic slowly with frequent aspirations. After completing the injection, remove the needle and repeat the block at the next level. (Many institutions perform only a superficial cervical plexus block, and the surgeon infiltrates deeper structures as required.)

Local Anesthetic

Superficial Cervical Plexus. 5–10 mL.

Deep Cervical Plexus. 3–5 mL at each level or 15 mL at C3 only.

Teaching Points. Caution should be exercised in patients receiving a deep cervical plexus block for carotid endarterectomy surgery. These patients will likely have atheromatous plaques that could be dislodged with excessive head hyperextension or cause cerebral ischemia with head rotation. For carotid endarterectomies, the surgeon must infiltrate the carotid body with local anesthetic because the cervical plexus does not innervate this structure.

7. INTERSCALENE BLOCK

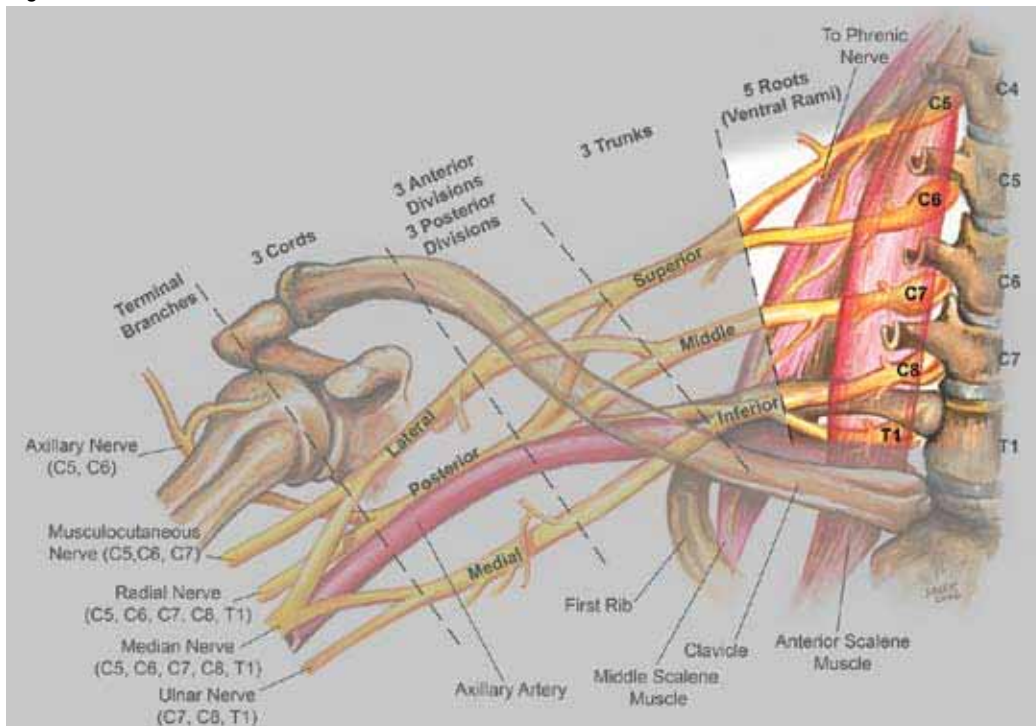
INTRODUCTION

The interscalene approach to the brachial plexus is particularly well suited for operations on the shoulder, clavicle, or upper arm. The approach preferentially blocks nerves of the brachial plexus (C5–C7), with variable proximal spread to the cervical plexus (C3–C4), while usually sparing the ulnar nerve (C8–T1). The nerves of the brachial plexus emerge from their respective intervertebral foramina and course posterior to the vertebral artery. They then pass between the anterior and middle scalene muscles as the trunks (superior C5–C6, middle C7, inferior C8–T1) of the brachial plexus.

ANATOMY

The interscalene block is performed at the level of the C6 vertebral body (Chassaignac's tubercle)

Figure 7-1



between the anterior and middle scalene muscles; C6 corresponds to the level of the cricoid cartilage. By blocking the plexus at this level, the local anesthetic is deposited around the upper roots (C5, C6) that innervate the muscles of the shoulder, specifically the deltoid, supraspinatus, infraspinatus, and teres major (Figure 7-1 through 7-3). Occasionally, there may be proximal spread to the cervical plexus (C3, C4) and cervical sympathetic chain, which can result in Horner's syndrome and hoarseness post block; this is not considered a complication, but the patient should be made aware of these possible side effects before the procedure is performed.

The interscalene block always results in hemidiaphragm paresis because of the close proximity of the phrenic nerve (C3–C5) to the interscalene groove. Any patient who cannot tolerate a reduction in pulmonary function greater than 30% should not receive this block. Even healthy patients may need reassurance that their feeling of dyspnea is transient.

The interscalene block is not appropriate for surgery of the hand and forearm, specifically in the ulnar distribution of C8, T1. Because it is performed at the upper roots of the plexus, the block typically spares the ulnar aspect of the hand. Additionally, C3, C4 nerve roots (cape area) are not consistently blocked.

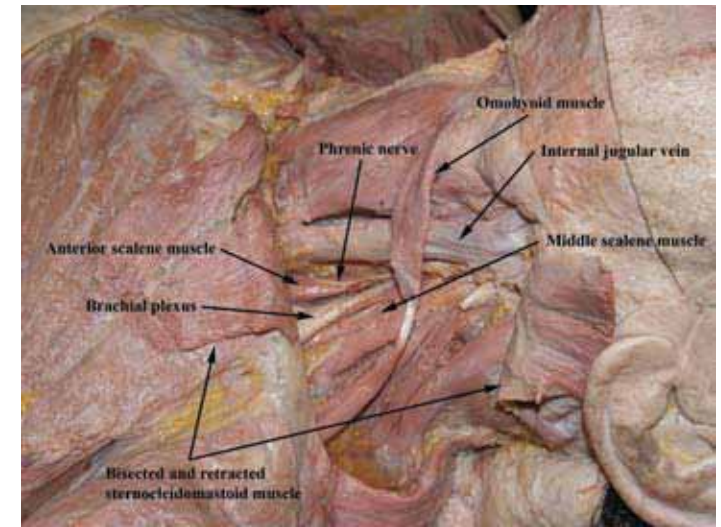
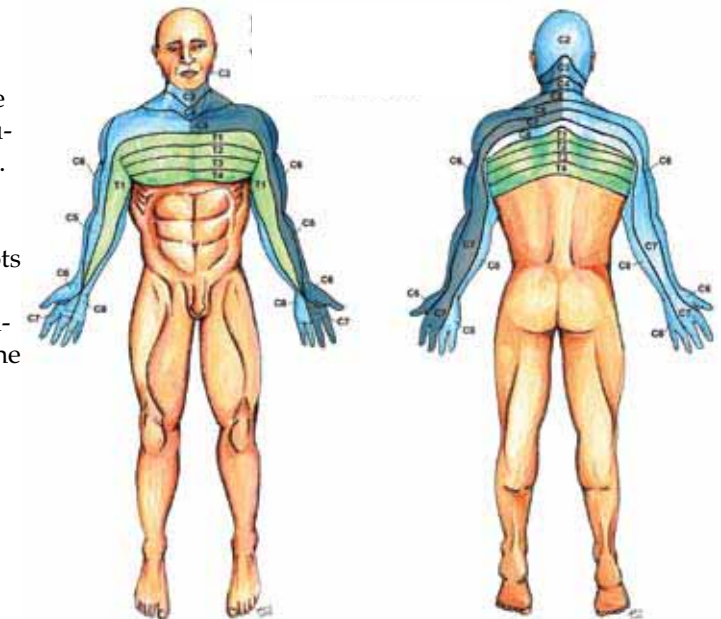


Figure 7-2

Figure 7-3. Dermatomes anesthetized with the interscalene block (dark blue)



PROCEDURE

Landmarks. Place the patient supine with the head turned toward the nonoperative side. Identify the cricoid cartilage, which indicates the C6 level. Palpate the lateral border of the sternocleidomastoid muscle (SCM), and move your fingers laterally into the interscalene groove (between the anterior and middle scalene muscles). Ensure that the clavicular head of the SCM, rather than the more medial sternal head, is being palpated. The external jugular vein often crosses the border of the SCM muscle at this point. If this is the case, the initial needle insertion should be posterior to the vessel (Figure 7-4). Initial needle insertion (at the level of C6) is indicated by an “X” (Figure 7-5).

Needles

- 22-gauge, 5-cm, insulated needle.
- 18-gauge, 5-cm insulated Tuohy needle for catheter placement. Catheters introduced 3 cm beyond needle tip.

Stimulation. The nerve stimulator is initially set at 1.0 to 1.2 mA. Muscle twitch in the shoulder, biceps, or triceps at 0.5 mA or less indicates adequate proximity to the brachial plexus for local anesthetic injection. Stimulation below the elbow suggests a needle position that is too caudal in the brachial plexus for shoulder surgery. In most adults, the brachial plexus is rarely deeper than 1 to 2 cm below the skin. Stimulation of the trapezoid muscle suggests that the needle tip is too posterior to the plexus. Conversely, stimulation of the diaphragm indicates phrenic nerve stimulation, and the needle tip is anterior to the plexus.

Local Anesthetic. In most adults, 30 to 40 mL of local anesthetic is sufficient to block the plexus.

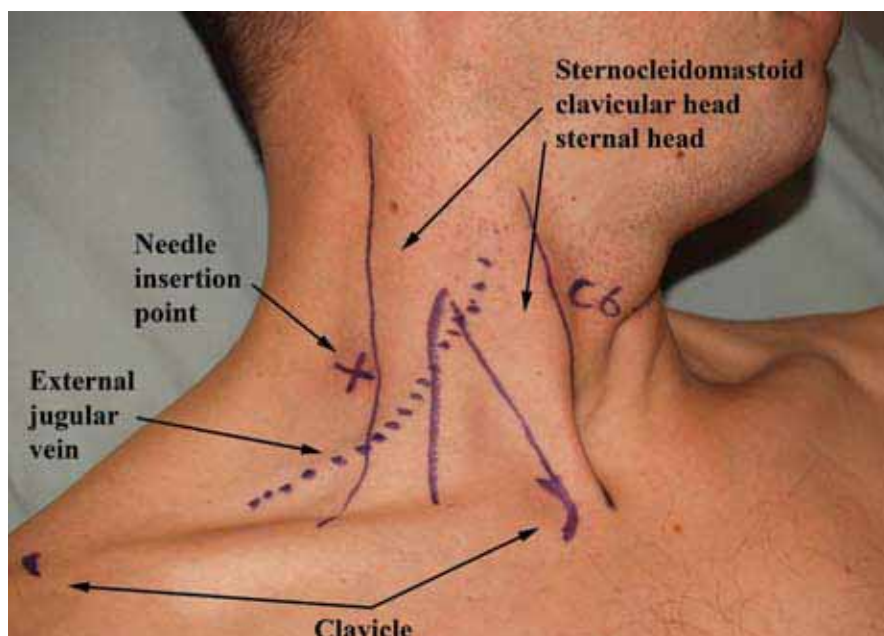


Figure 7-4

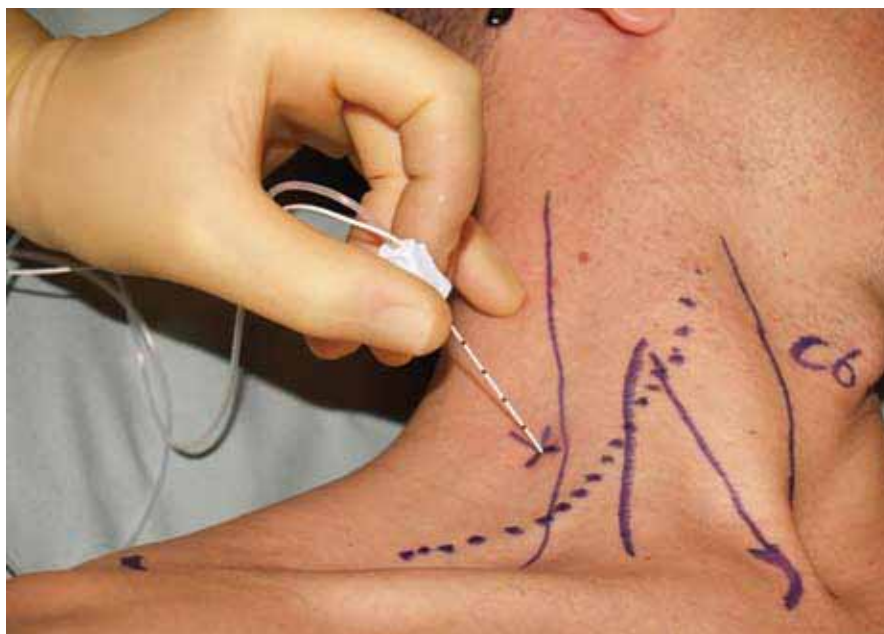

Figure 7-5

Additional Procedures.

An intercostobrachial nerve block (subcutaneous injection of local anesthetic from the axilla to the midpoint of the clavicle on the anterior chest) should be performed for major shoulder procedures. Paravertebral nerve blocks of T1–T2 may supplement the interscalene block for procedures involving significant posterior dissections.

Teaching Points. Injection of local anesthetic into the neighboring vertebral artery can result in a devastating complication of this block. Proper injection technique with frequent, gentle aspiration for blood is critical for safe block placement.

BLOCK WITH ULTRASOUND PROBE

Probe. High frequency (5-12 MHz), linear.

Probe Position. The oblique plane gives the best transverse view of the brachial plexus; a cross-sectional (axial) view displays the nerves as hypoechoic circles with hyperechoic rings. Position the probe on the neck at the level of C6 (Figure 7-6).

Approach. The plexus can be approached from either a posterior or anterior position. To use the posterior approach, begin the needle insertion at the lateral aspect of the probe; the needle will traverse the middle scalene muscle as the plexus is reached. For the anterior approach, insert the needle at the medial aspect of the probe, taking care to avoid the carotid artery and internal jugular vein; the needle will traverse the anterior scalene muscle on the way to the plexus (Figure 7-7).

Injection. Once the needle is adjacent to the nerve trunks, injection of local anesthetic may begin. The “donut sign” (created by the local anesthetic surrounding the nerves) is a positive indicator that the anesthetic is being properly distributed. Proper needle positioning should ensure local anesthetic spread around the superior and middle trunks.

Teaching Points. For ease of anatomic identification, locate the plexus at the level of a supraclavicular block (identify the subclavian artery, and the plexus will be just lateral to it). Once the plexus is located, slowly move the probe cephalad to observe the bundled nerve structures coalescing into the three major trunks, aligned superior to inferior. This is the transition from the more caudad divisions to the more cephalad trunks (Figure 7-8). Injection of local anesthetic should be directed toward the superior trunk of the plexus.

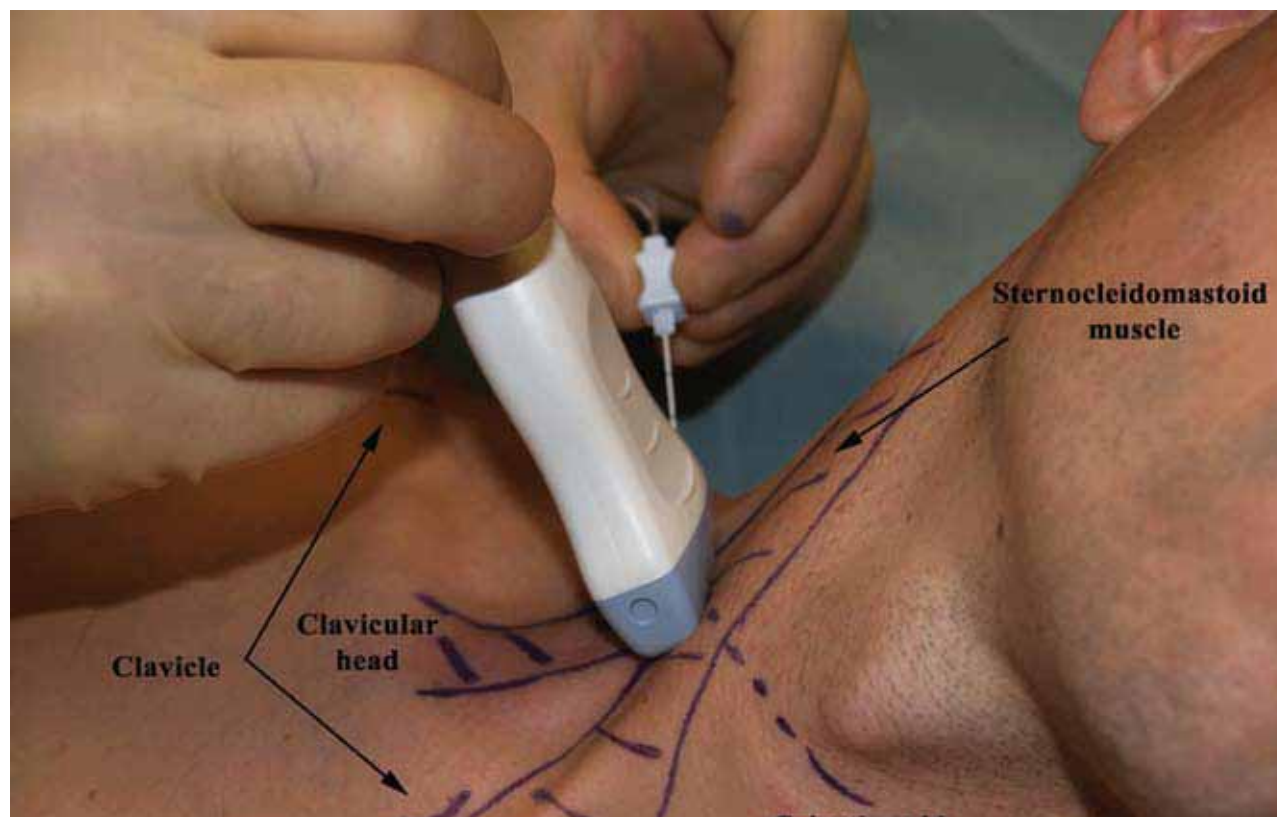


Figure 7-6

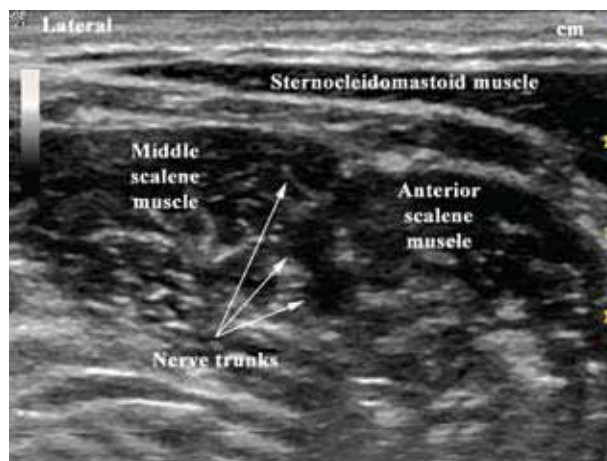

Figure 7-7

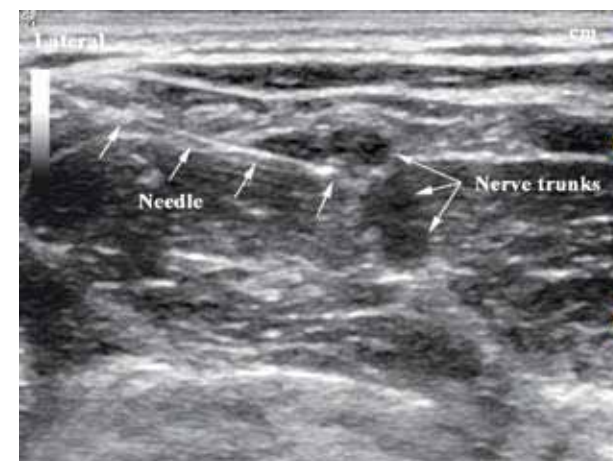


Figure 7-8

8. SUPRACLAVICULAR BLOCK

INTRODUCTION

The supraclavicular nerve block is ideal for procedures of the upper arm, from the midhumeral level down to the hand (Figure 8-1). The brachial plexus is most compact at the level of the trunks formed by the C5–T1 nerve roots, so blockade here has the greatest likelihood of blocking all of the branches of the brachial plexus. This results in rapid onset times and, ultimately, high success rates for surgery and analgesia of the upper extremity (excluding the shoulder).

ANATOMY

At the trunk level of the brachial plexus, the C5 and C6 nerve roots join to form the superior trunk, the C7 nerve root forms the middle trunk, and the C8, T1 nerve roots join to form the inferior trunk (the C4 and T2 nerve roots may also contribute significantly at these points) (Figure 8-2). Because the plexus is compactly arranged at this location, local

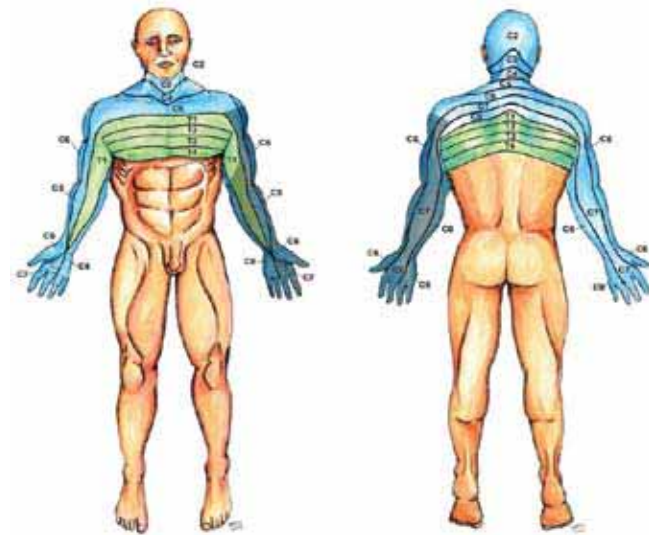


Figure 8-1. Dermatomes anesthetized with the supraclavicular block (dark blue)

anesthesia easily covers all the plexus nerves, which results in a rapid, dense block.

To locate the brachial plexus at the supraclavicular level, gently palpate the interscalene groove down to the midpoint of the clavicle (Figure 8-3). Note that the groove can occasionally be obscured near the clavicle by the omohyoid muscle. Palpation or ultrasound visualization of the subclavian artery just superior to the clavicle provides a useful anatomic landmark for locating the brachial plexus, which is lateral to the artery at this level.

The complication most often associated with this block is pneumothorax. When manipulating the needle in this region, remember that the apex of the lung is just medial and posterior to the brachial plexus as well as deep to the first rib. Using a shorter needle (5 cm) can decrease the incidence of pneumothorax. Unlike an interscalene block, the supraclavicular block causes diaphragmatic hemiparesis in approximately 50% of patients, with minimal accompanying reduction in forced vital capacity (FVC). Signs and symptoms of a large pneumothorax include sudden cough and shortness of breath.

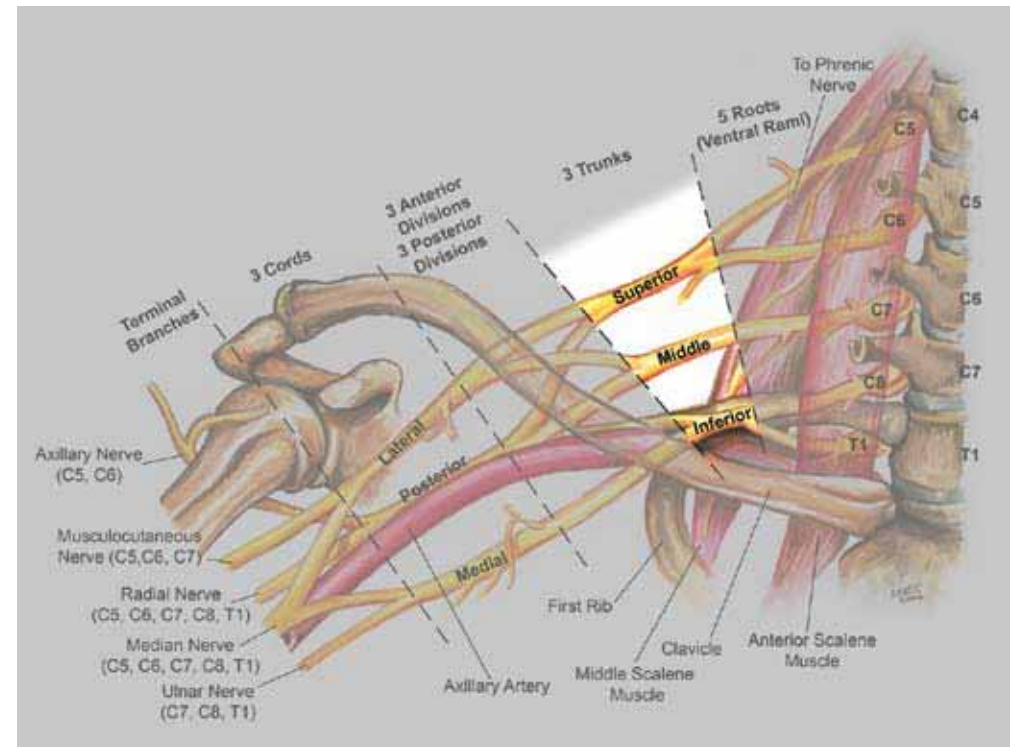


Figure 8-2

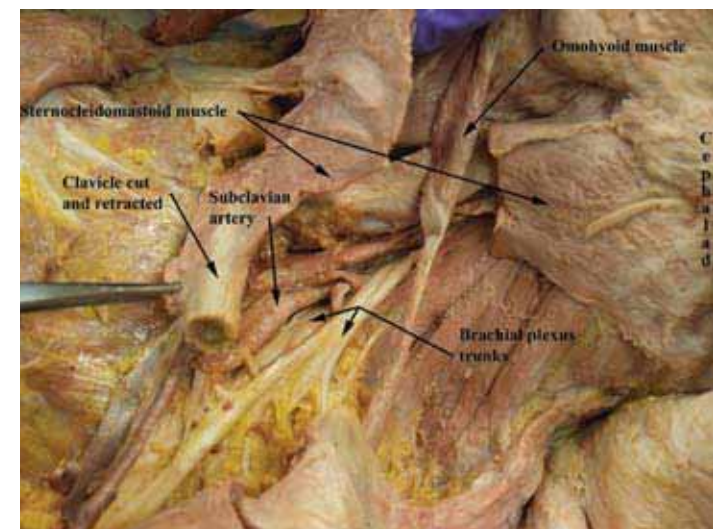


Figure 8-3

PROCEDURE

Landmarks. Place the patient in a supine position with the head turned toward the non-operative side. Palpate the posterior border of the sternocleidomastoid muscle at the C6 level and roll your fingers laterally over the anterior scalene muscle until they lie in the interscalene groove (the groove may be harder to identify below the C6 level because of the overlying omohyoid muscle). Then move your fingers laterally down the interscalene groove until they are approximately one centimeter from the mid-clavicle. This location is the initial insertion site for the needle (Figure 8-4). Standing at the patient's head, direct the needle toward the axilla, as demonstrated in Figure 8-5.

Needles

- 22-gauge, 5-cm, insulated needle.
- 18-gauge, 5-cm, insulated Tuohy needle for catheter placement. Catheters introduced 3 to 5 cm beyond needle tip.

Stimulation. The nerve stimulator is initially set at 1.0 to 1.2 mA. Proper needle placement is indicated by flexion or extension of the digits at 0.5 mA or less. The brachial plexus can be deep at this location, but is often reached at 2 to 4 cm. Aspiration of bright red blood suggests subclavian artery penetration, indicating the needle is too medial. Stimulation of the musculocutaneous nerve (biceps contractions) usually indicates the needle is too lateral. Pectoralis muscle contraction indicates the needle is anterior, and scapular movement indicates the needle is posterior to the plexus.

Local Anesthetic. In most adults, 30 to 40 mL of local anesthetic is sufficient to block the plexus.

Additional Procedures. The intercostobrachial nerve lies anterior and slightly superior to the axillary artery; it innervates the skin along the upper medial border of the arm. To block this

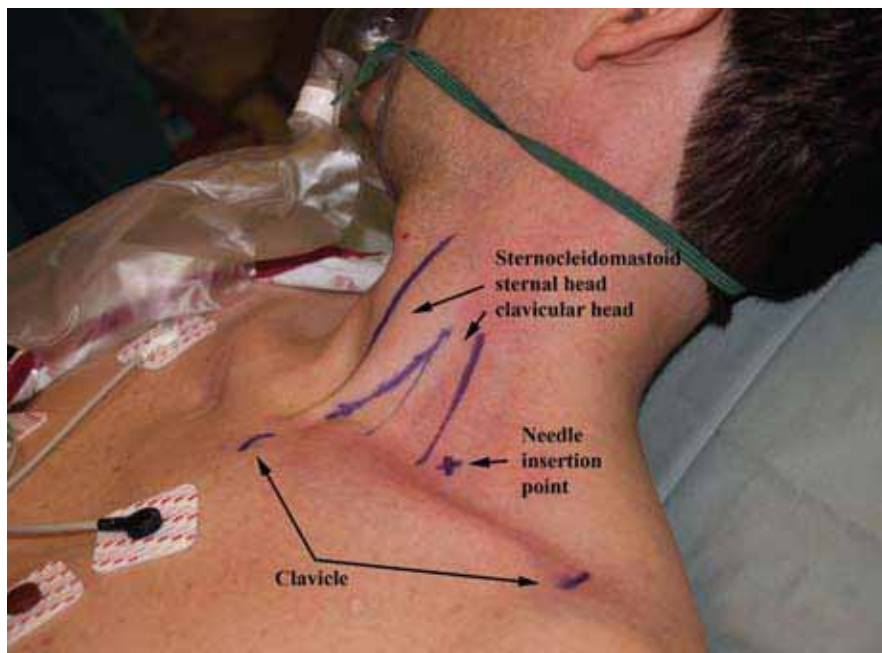


Figure 8-4

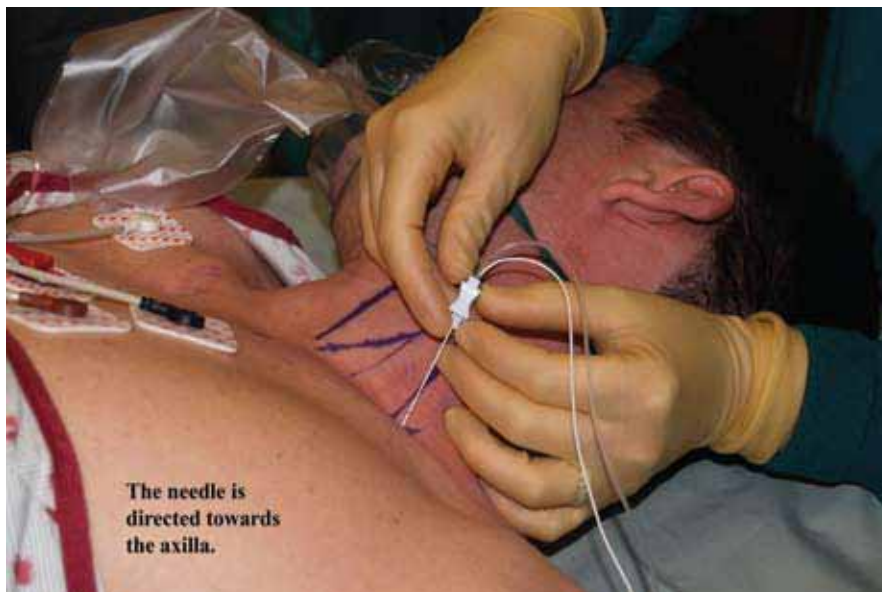

Figure 8-5

nerve, place a subcutaneous “wheal” of local anesthetic from the border of the pectoralis muscle insertion on the humerus to the inferior border of the axilla. The skin wheal should be placed as proximal on the arm as possible.

Teaching Points. Because of the close proximity of the lung, the needle should never be directed medially. If a tourniquet is being used for surgery, consider intercostobrachial blockade.

BLOCK WITH ULTRASOUND PROBE

Probe. High frequency (5-12 MHz), linear.

Probe Position. The coronal oblique plane gives the best transverse view of the brachial plexus; again, a cross-sectional (axial) view displays the nerves as hypoechoic circles with hyperechoic rings (“bundle of grapes”). Position the probe on the neck directly above the clavicle in the supraclavicular fossa. At this level, the plexus will be configured as trunks or divisions and is typically located lateral and slightly superior to the subclavian artery at a depth of 2 to 4 cm (Figure 8-6).

Approach. Insert the needle at the lateral end of the ultrasound probe and advance it parallel to the ultrasound beam until it approaches the plexus. Take care to maintain the needle within the ultrasound beam plane; this maneuver helps ensure that you can constantly visualize the entire needle shaft to the tip. If the image of the needle is lost during the block procedure, cease advancing the needle until it can be re-visualized through probe manipulation (Figure 8-7).

Injection. It is important to observe the spread of the local anesthetic during the injection, allowing real-time readjustment of the needle tip position if the spread is not appropriate. The “donut sign” (created by the local anesthetic surrounding the nerves) is a positive indicator that the anesthetic is being properly distributed (see section on interscalene ultrasound injection). Precise application of the local anesthetic can be achieved by injecting small aliquots (5 mL) and observing the local anesthetic spread (Figure 8-8).

Teaching Points. Be aware that this block is performed with the needle passing from a lateral to medial direction. It is very important to always keep the tip and shaft of the needle in clear view to ensure that the needle is not penetrating too deep into the supraclavicular fossa; deep penetration can result in an inadvertent pneumothorax or vascular puncture. If the needle image is maintained above the level of the first rib and pleura, the risk of pneumothorax is minimal.

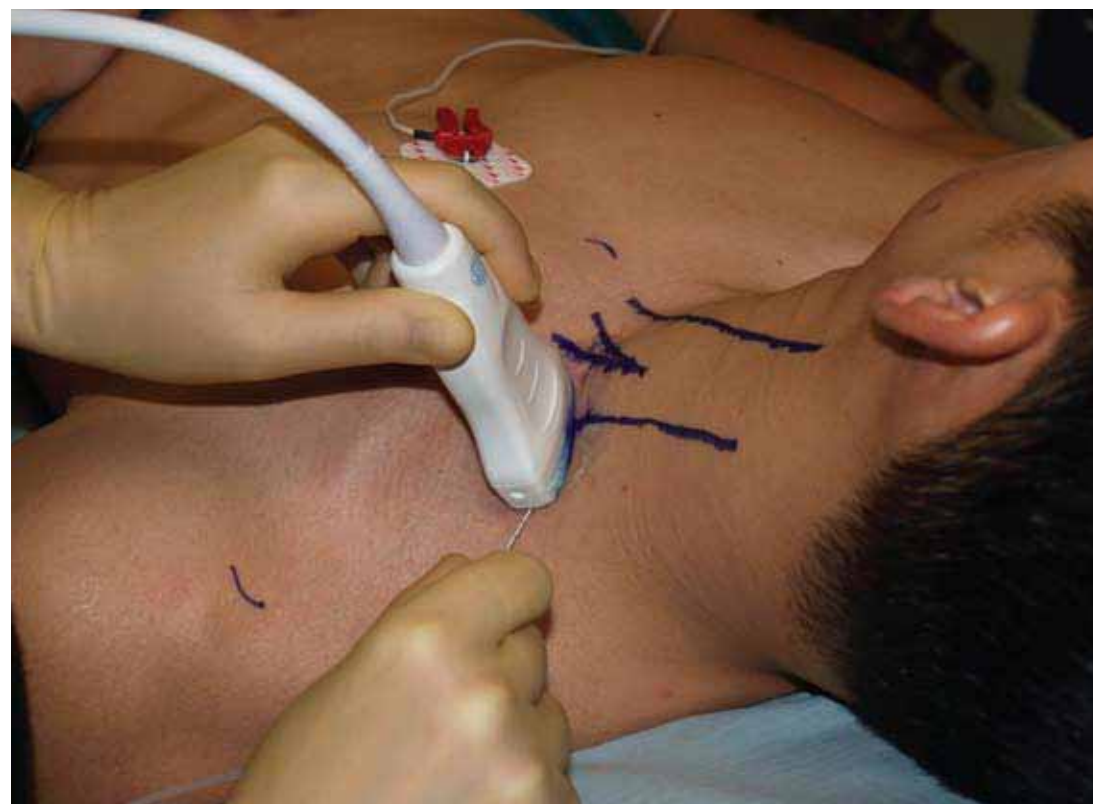


Figure 8-6

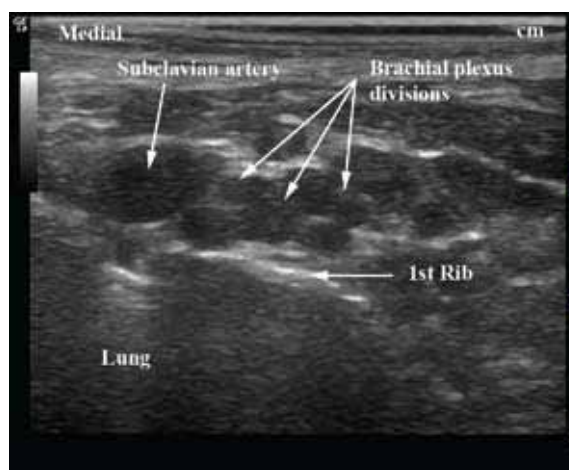


Figure 8-7

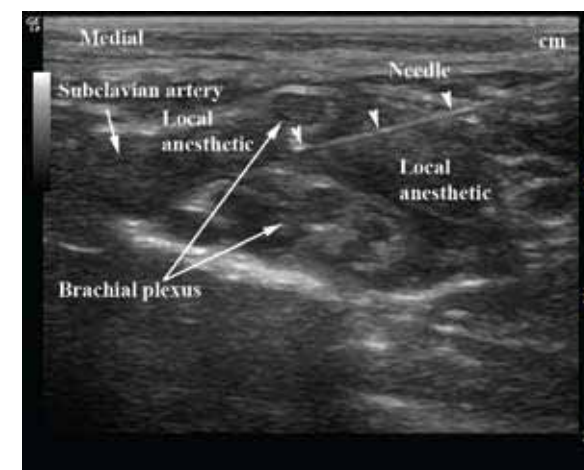

Figure 8-8

9. INFRACLAVICULAR BLOCK

INTRODUCTION

The infraclavicular brachial plexus block is ideal for operations distal to the elbow. Adequate time (approximately 20 minutes) should be allowed after the block placement to achieve a surgical level of anesthesia. Although there are multiple approaches to the infraclavicular block, success depends on where the needle tip stimulates the plexus. Caution must be taken to ensure that the needle tip is maintained within the infraclavicular fossa at the level of the cords and not directed distally toward the terminal branches located in the axilla. The latter erroneous position usually results from excessive angulation of the needle toward the axilla and may result in inadequate blockade of the musculocutaneous and axillary nerves.

ANATOMY

The infraclavicular block is performed at the level of the cords of the brachial plexus. The cords are named according to their relation to the axillary artery: lateral, medial, and posterior. The lateral cord is formed from the anterior divisions of the superior and middle trunks, the medial cord is formed from the anterior division of the inferior trunk, and the posterior cord is formed from the posterior divisions of all three trunks. The plexus, which begins to spread around the axillary artery at this level, is not as compact as the more proximal trunks (Figures 9-1 through 9-3). Therefore, this block typically has a longer latency, and may not be as dense, as a supraclavicular nerve block.

Compared to the supraclavicular block, an advantage of the infraclavicular block is the reduced possibility of pneumothorax and avoidance of cervical vascular structures. This block does not produce a reduction in respiratory function. Additionally, the infraclavicular block has been shown to be superior to the axillary nerve block for anesthetizing the axillary and musculocutaneous nerves, making a supplemental musculocutaneous nerve block unnecessary.

Acceptable muscle stimulation patterns are either extension (radial nerve) or flexion (median nerve) of the digits. A biceps twitch (musculocutaneous nerve), suggests that the needle placement is too lateral. The axillary vessels can be punctured using this approach, and vessel compression in this area is difficult.

Figure 9-1

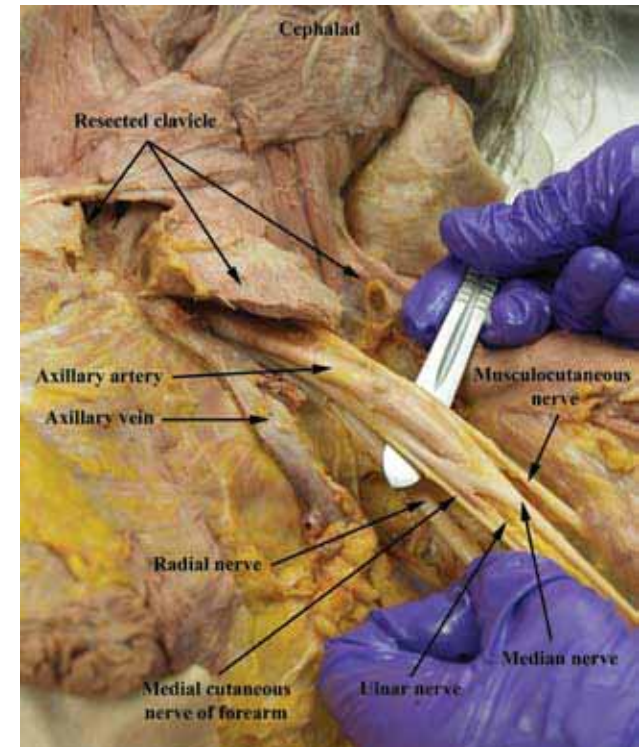
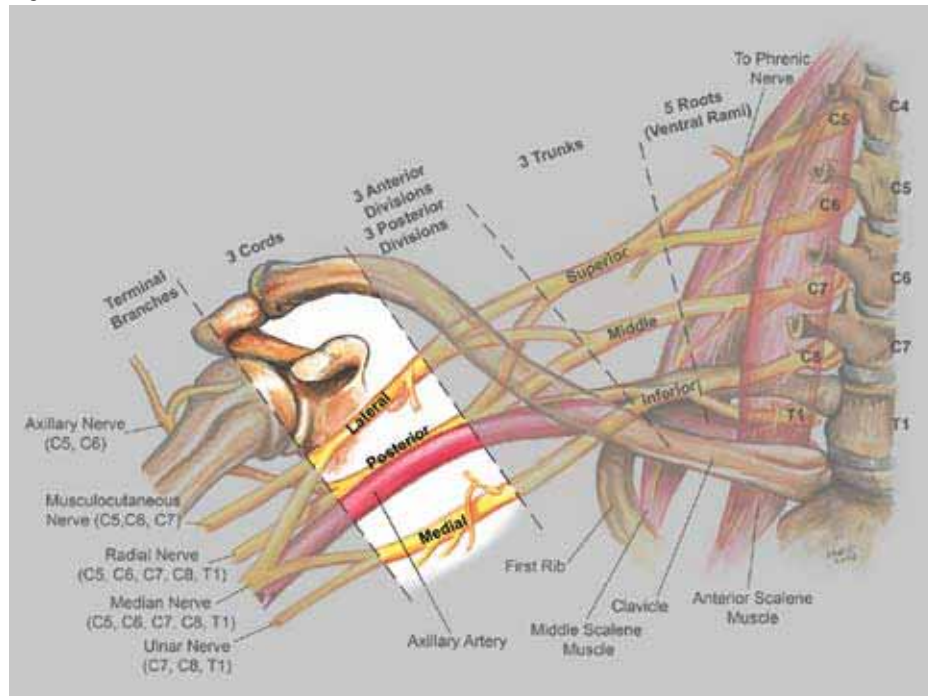
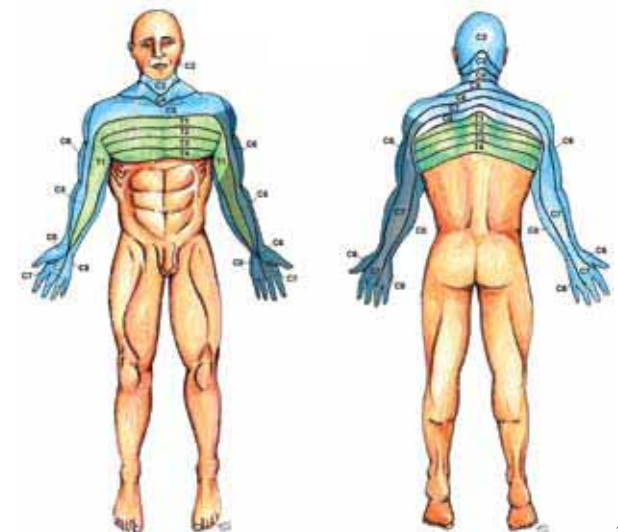


Figure 9-2

Figure 9-3. Dermatomes anesthetized with the infraclavicular block (dark blue)



PROCEDURE

Landmarks. Externally rotate and abduct the operative arm. Palpate the coracoid process. Make a mark 2 cm medial and 2 cm caudad from the coracoid process (Figure 9-4). This is the insertion point. Palpate the axillary artery as proximal as possible in the axilla. This is the direction of initial insertion. Insert the needle at an approximately 60° angle from the horizontal (Figure 9-5).

Needles

- 21-gauge, 10-cm, insulated needle.

- 18-gauge, 10-cm, insulated Tuohy needle for catheter placement. Catheters inserted 3 cm.

Stimulation. The nerve stimulator is initially set between 1.0 and 1.2 mA. Finger and/or thumb flexion at 0.5 mA or less indicates adequate needle placement for local anesthetic injection. Finger extension with stimulation is also acceptable. Stimulation of the musculocutaneous nerve indicates that the needle is too lateral.

Local Anesthetic. In most adults, 30 to 40 mL of local anesthetic will block the plexus at this level.

ALTERNATIVE APPROACH

A simple alternative to the coracoid approach is the deltopectoral groove approach (see Figure 9-5). With the patient's arm at his or her side, mark the base of the clavicle and palpate the deltopectoral groove from the axilla up to the clavicle. At approximately 1 cm below the clavicle, place the needle in the deltopectoral groove (perpendicular to the bed), and then redirect it 10° toward the axilla. Advance the needle until the plexus is encountered. Compared to the coracoid approach, this approach will block the plexus at a more proximal location, which is desirable because the plexus is more compact and easier to block proximal.

Figure 9-4

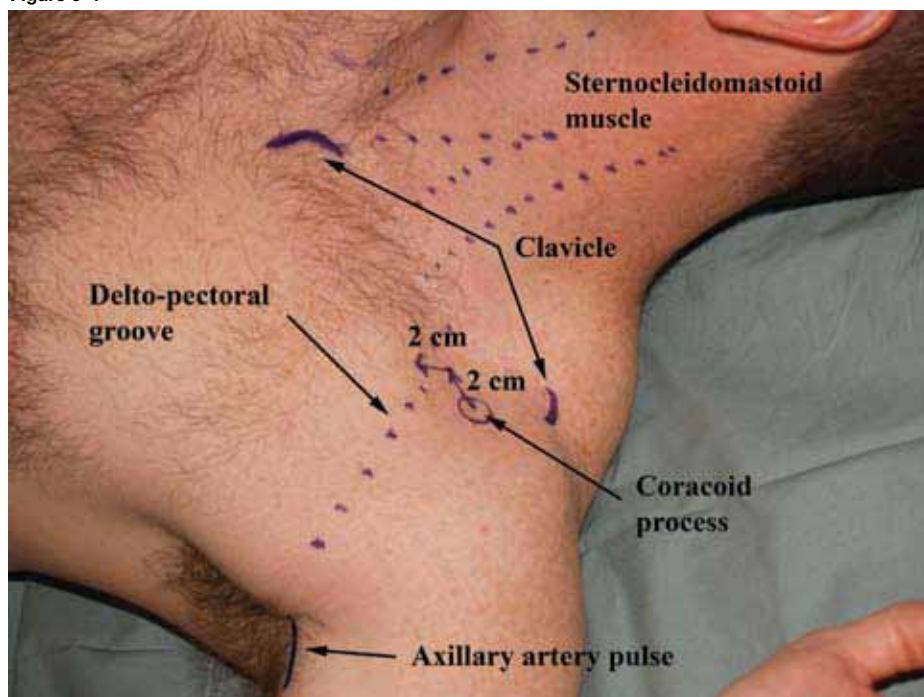
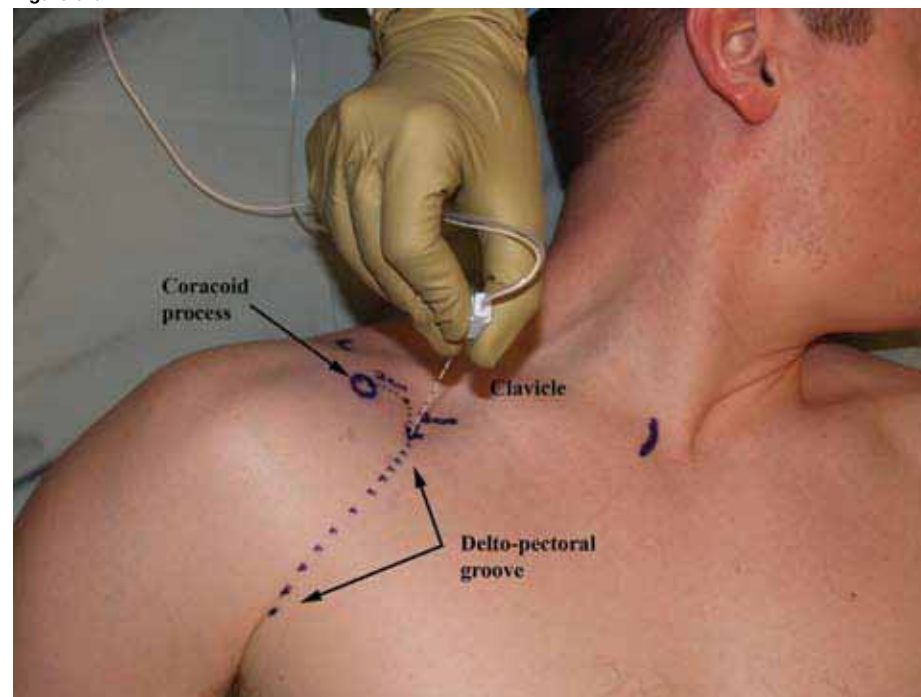


Figure 9-5



BLOCK WITH ULTRASOUND PROBE

Probe. High frequency (5–12 MHz), linear.

Probe Position. The parasagittal plane gives the best transverse view of the brachial plexus; below the level of the clavicle, the nerves appear hyperechoic. Position the probe beneath the clavicle and medial to the coracoid process (Figure 9-6).

Approach. The needle is typically inserted in-plane at the cephalad (lateral) aspect of the probe, and will be visualized at the lateral border of the axillary artery. The hyperechoic structure lateral to the artery is the lateral cord; the needle should pass lateral to this cord and progress farther to the posterior cord. The posterior cord is the hyperechoic structure located at the base of the axillary artery (Figure 9-7). Recent evidence suggests that deposition of local anesthetic around the posterior cord will result in improved block success.

Another approach to the posterior cord is via the inferior aspect of the probe (still in the parasagittal plane). With this technique, the needle is visualized at the medial border of the axillary artery, and between the axillary artery and vein. The needle must travel along the lateral aspect of the medial cord to reach the posterior cord. This approach is technically more difficult because of the close proximity of the axillary artery to the needle path; however, it allows catheters to be threaded with less difficulty.

Injection. It is important to observe the spread of the local anesthetic during the injection, which allows readjustment of the needle position if the spread is not appropriate. Spread should appear around the posterior cord; any spread above the artery in the area of the pectoralis muscles will likely result in block failure (Figure 9-8).

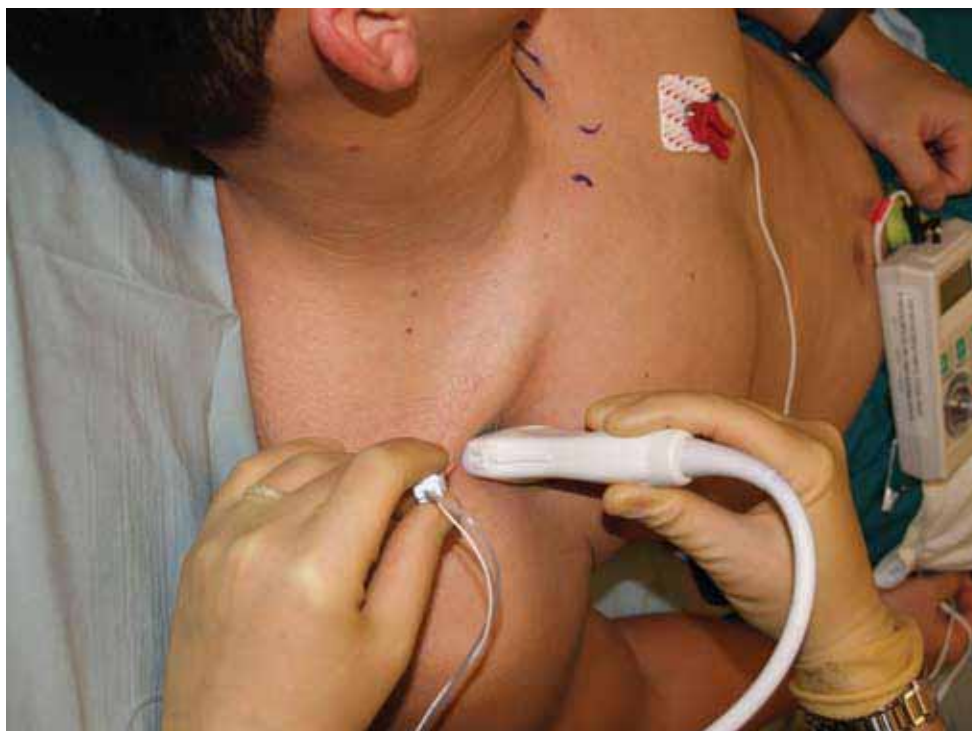


Figure 9-6

Teaching Points. As with the nerve stimulator technique, care must be taken to avoid vascular puncture because compression for bleeding in this area can be difficult. Always keep the axillary artery and vein in view during needle guidance, and always ensure that the full length of the needle to the tip in the longitudinal (in-plane) view is clear.

Figure 9-7

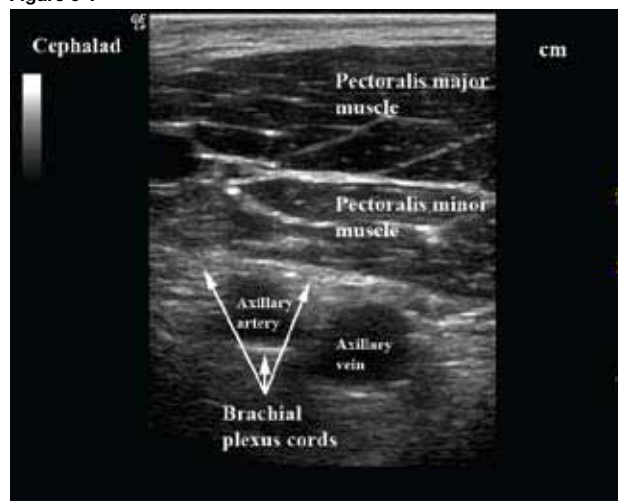
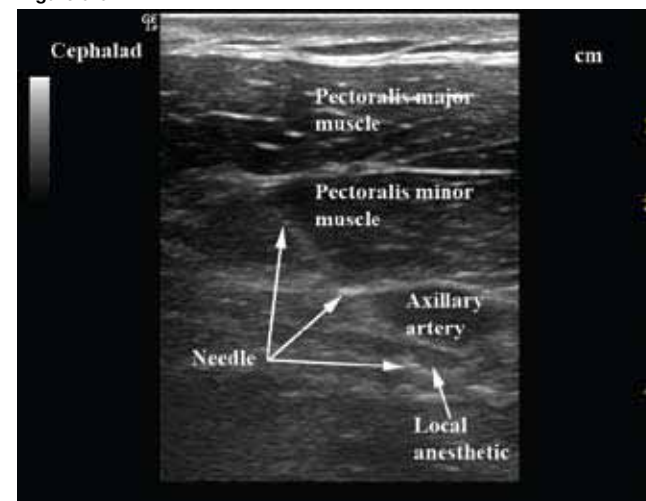


Figure 9-8



10. AXILLARY BLOCK

INTRODUCTION

Except for single nerve blocks in the arm and forearm, the axillary block is the most distal block performed on the brachial plexus. Because of the distal location (in contrast to other brachial plexus approaches), the axillary block has negligible risks of the respiratory compromise secondary to pneumothorax or phrenic nerve blockade. In addition, the peripheral location permits adequate arterial tamponade to be applied if an inadvertent puncture occurs.

ANATOMY

At this level, the plexus has divided into its terminal nerve branches, with two major nerves originating from each cord. The lateral cord divides into the musculocutaneous nerve and the

lateral portion of the median nerve, the medial cord divides into the ulnar nerve and the medial portion of the median nerve, and the posterior cord divides into the radial nerve and axillary nerve (Figures 10-1 and 10-2). The median, ulnar, and radial nerves all travel with the axillary artery within the axillary sheath; however, the musculocutaneous nerve travels separately within the belly of the coracobrachialis muscle. For this reason, the musculocutaneous nerve must be blocked separately during an axillary nerve block.

This block should only be performed for surgeries involving the hand or forearm (Figure 10-3). A supraclavicular or infraclavicular nerve block should be used for surgeries involving the upper arm or elbow to obtain more complete coverage of the upper extremity. Any patient who is unable to abduct their arm more than 45° at the shoulder is not an appropriate candidate for the axillary block.

Figure 10-1. Dermatomes anesthetized with the axillary block (dark blue)

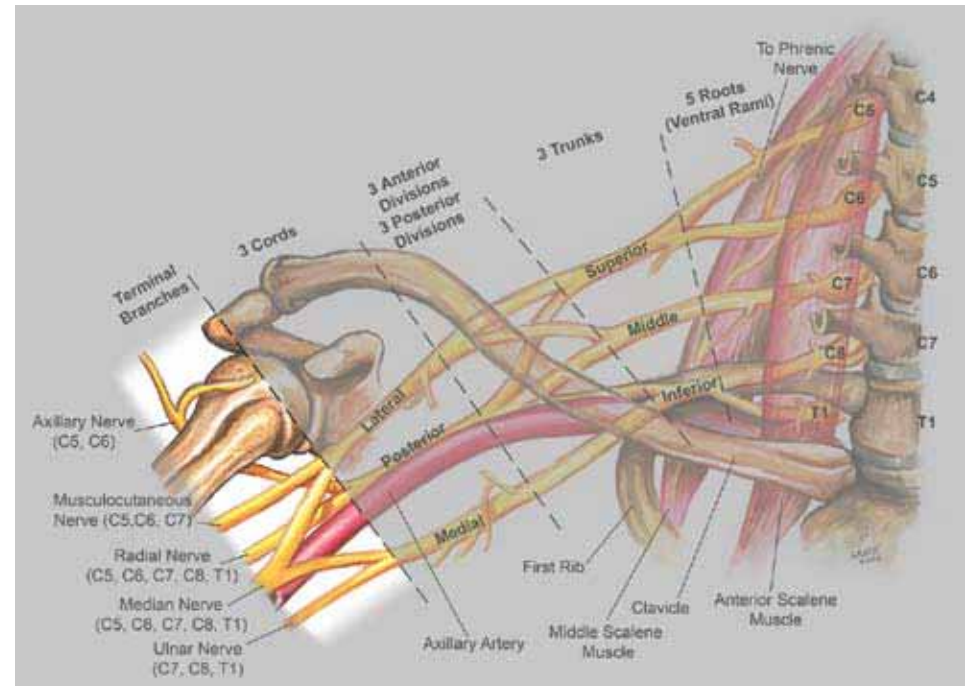
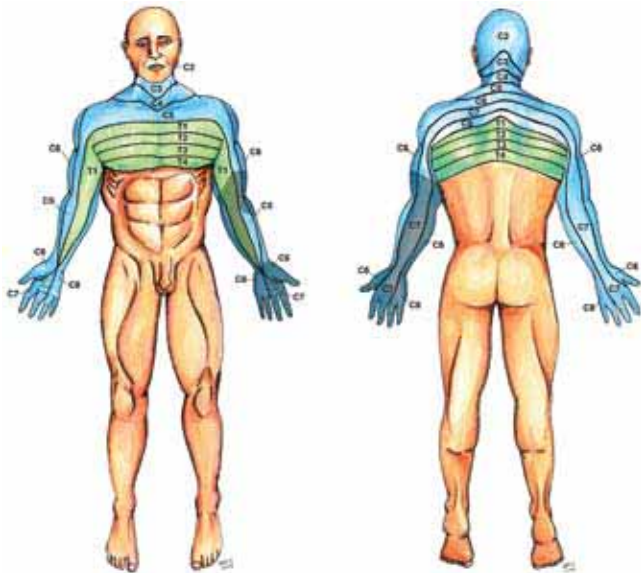
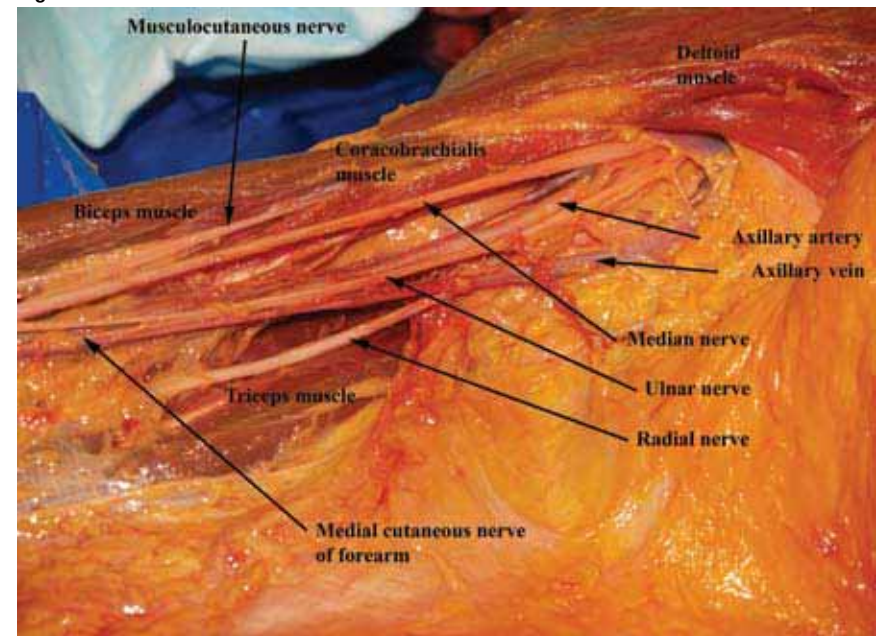


Figure 10-2

Figure 10-3



PROCEDURE

Landmarks. There are multiple approaches to the axillary block, including paresthesia seeking, nerve stimulating, ultrasound, perivascular, and transarterial techniques. With the paresthesia seeking and nerve stimulating approaches, all four nerves (median, ulnar, radial, and musculocutaneous) can be individually identified and anesthetized; both of these methods seem to be equally successful. However, in procedures using the nerve stimulation technique, studies have shown that actual stimulation of the musculocutaneous nerve leads to a more successful outcome than a simple injection into the coracobrachialis muscle.

It is important to note that although a true axillary sheath may exist, it may not be a tubular structure that neatly houses the terminal branches of the plexus. Instead, it may be a collection of connective tissues that surround the nerves and vessels, creating individual fascial compartments that can inhibit spread of the local anesthetic.

The patient is positioned supine with the operative arm abducted and externally rotated (Figure 10-4). The axillary artery is palpated as high in the axilla as possible. The needle is inserted superior to the axillary artery, entering at a 45° angle. To identify the coracobrachialis muscle for the musculocutaneous block, the biceps muscle is displaced laterally, and the coracobrachialis muscle is palpated just medial to it. At the level of the upper half of the humerus, the needle is inserted into the coracobrachialis muscle.

Needles

- 22-gauge, 3.8-cm, insulated b-bevel needle.
- 18-gauge, 3.8-cm insulated Tuohy needle for catheter placement. Catheters introduced 3–5 cm.

Stimulation

Median, Ulnar, and Radial Nerves. The nerve stimulator is initially set between 1.0 and 1.2 mA. Finger flexion and/or thumb opposition at 0.5 mA or less indicates proper needle placement (Figure 10-5).

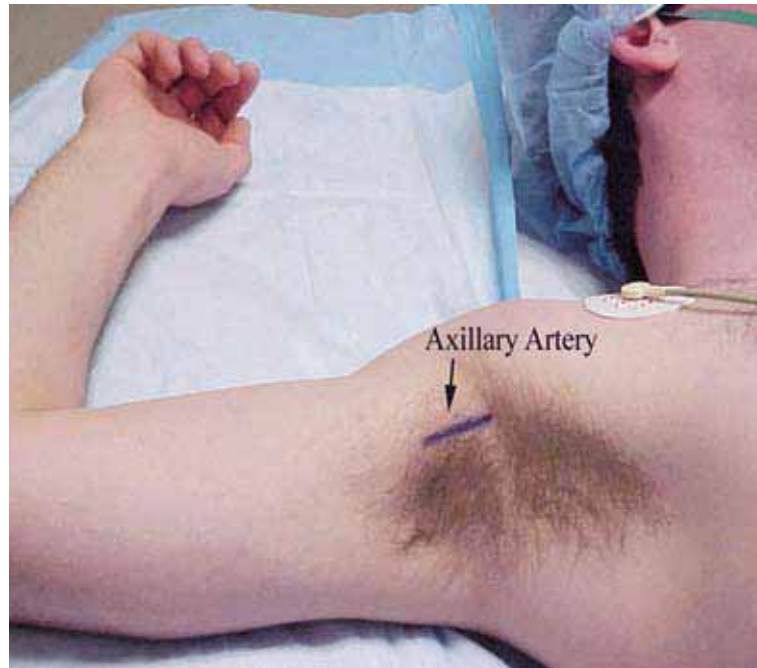

Figure 10-4

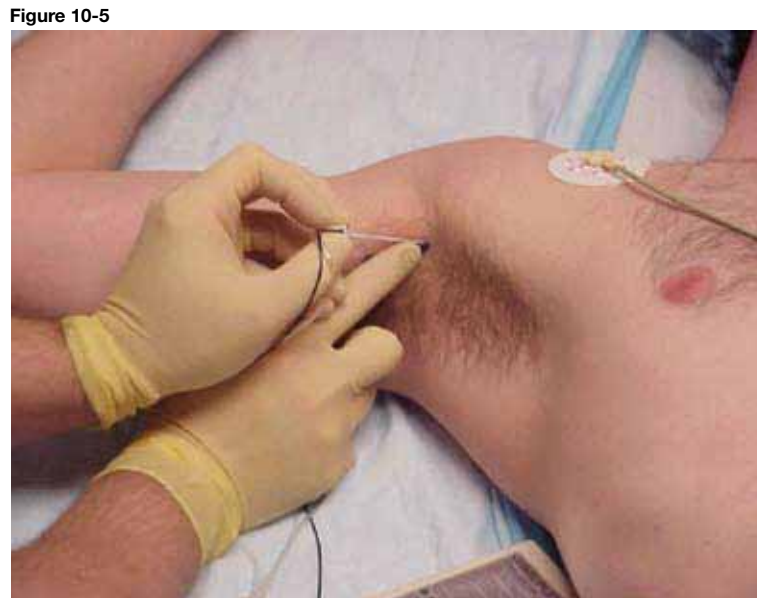

Figure 10-5

Aspiration of bright red blood means the needle has entered the axillary artery. If this occurs, the transarterial technique for axillary block can be used: advance the needle until blood aspiration stops, and deposit half of the local anesthetic volume deep to the artery. Then withdraw the needle until blood aspiration ceases again, and deposit the remaining local anesthetic at this more superficial location.

Musculocutaneous Nerve. The nerve stimulator is set to approximately 2.0 mA. Fan the needle through the coracobrachialis muscle until vigorous biceps contraction is elicited (ensure that biceps contraction is not secondary to direct stimulation of the biceps muscle). There is no need to dial down the current.

Local Anesthetic

Median, Ulnar, and Radial Nerves. In most adults, 30 to 40 mL of local anesthetic will block these nerves.

Musculocutaneous Nerve. In most adults, 10 mL of local anesthetic will block this nerve.

Teaching Points. Application of distal pressure (see Figure 10-5) during injection can help push the local anesthetic in a more proximal direction. Adducting the arm immediately after injection can also help with proximal spread of local anesthetic. If an arm tourniquet is used during the surgical procedure, blockade of the intercostobrachial nerve is required (see Chapter 8, Supraclavicular Block).

BLOCK WITH ULTRASOUND PROBE

Probe. High frequency (5–12 MHz), linear.

Probe Position. The transverse plane gives the best view of the brachial plexus at this level; nerves will appear as hypoechoic roundish structures with hyperechoic borders.

Approach. The patient is supine, with the arm abducted 90° and externally rotated so the dorsum of the hand rests on the bed. The probe should be placed high in the axilla, at the intersection of the pectoralis major muscle with the biceps muscle (Figure 10-6). At this level, the axillary artery and all three main nerves to be blocked (median, ulnar, radial) should be in view (Figure 10-7). Typical anatomic relations of the nerve to the artery are as follows: the median nerve is located superficial and slightly cephalad to the artery, the radial nerve is located deep to the artery, and the ulnar nerve is located caudad to the artery. If all three nerves are not visualized at the same time, sliding the probe from a medial to lateral direction should help identify the missing nerve. Individual nerves can be confirmed by stimulation. Once each nerve is identified, 10 mL of local anesthetic should be injected around each nerve (Figure 10-8). (Note: axillary veins are often not seen while performing this block under ultrasound guidance because they are easily compressed by the ultrasound probe.)

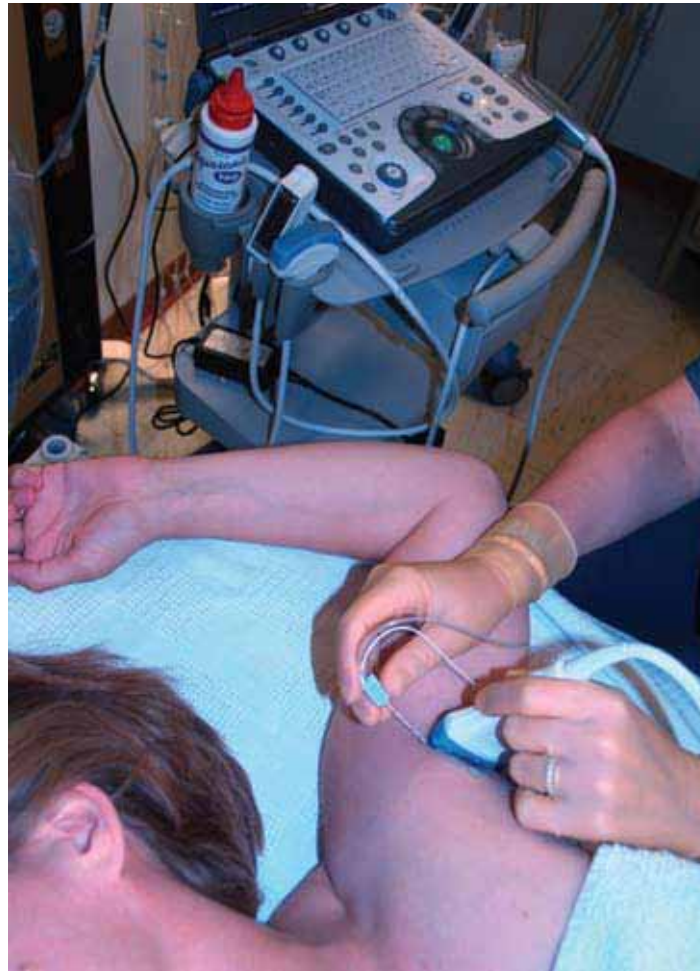

Figure 10-6

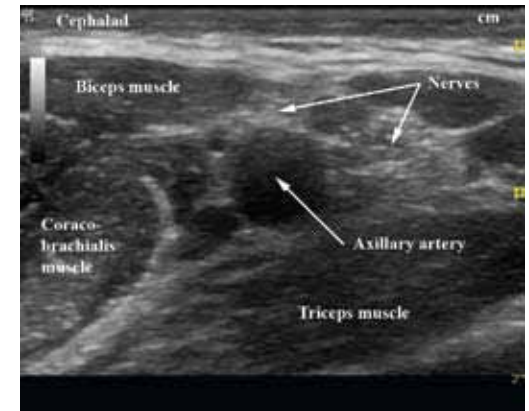

Figure 10-7

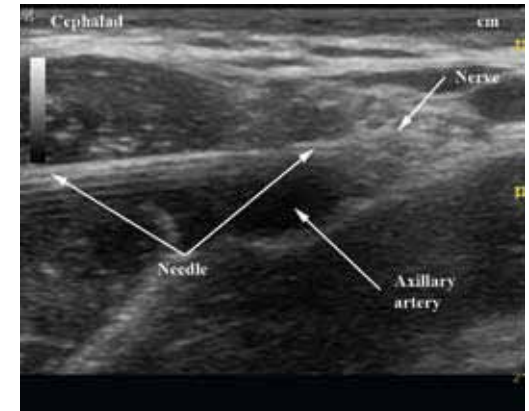


Figure 10-8

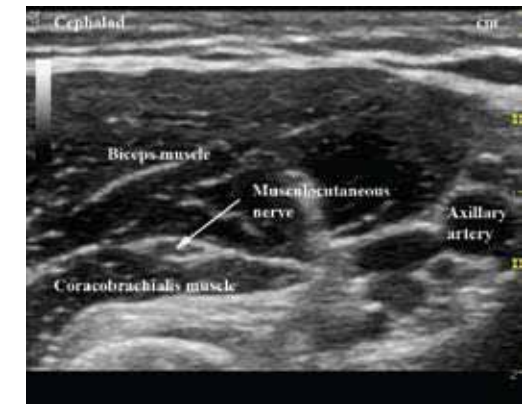

Figure 10-9

Teaching Points. As opposed to a field block or stimulation technique, blockade of the musculocutaneous nerve under ultrasound guidance is more precise. The patient's arm remains abducted and externally rotated while the probe is positioned at the junction between the pectoralis major and biceps muscles with the axillary artery in view. While the probe

is slowly brought toward the biceps muscle, the musculocutaneous nerve should come into view, either between the biceps and coracobrachialis muscles or within the body of the coracobrachialis muscle (Figure 10-9). Local anesthetic should be injected when the needle tip is visualized near the nerve or stimulation of the biceps muscle is noted.

11. PERIPHERAL NERVE BLOCKS OF THE ARM

INTRODUCTION

Peripheral nerve blockade of the upper extremity is often accomplished with proximal approaches to the brachial plexus (C5–T1) via supraclavicular, infraclavicular, or axillary nerve blocks. However, a single terminal nerve occasionally requires additional supplementation of local anesthetic to “rescue” a less than adequate block. These distal injection points may also be necessary for a patient with conditions that preclude more proximal injections (eg, preexisting wounds or infection). Coagulation abnormalities may also render the more proximal approaches less desirable because of the close proximity of major vascular structures to the needle entry site. These peripheral techniques are useful for minor surgical procedures within a single nerve distribution, such as wound exploration or small laceration repair.

ANATOMY

The three major peripheral nerves of the upper extremity (radial, median, and ulnar) may all be blocked at the level of the elbow (Figure 11-1). Because of its location within the ulnar groove, the ulnar nerve has the most reliable landmarks. The ulnar groove is palpated between the medial epicondyle of the humerus and the olecranon process. Ulnar nerve blockade at this level provides sensory blockade to the medial aspect of the hand, including the fifth digit and the medial half of the fourth digit.

The brachial artery is the landmark for median nerve blockade at the level of the elbow (see Figure 11-1). The median nerve lies just medial to the artery and may be blocked utilizing paresthesia, nerve stimulation, or ultrasound guidance based on this landmark. Median nerve blockade is useful for the anterolateral surface of the hand, including the thumb through middle finger.

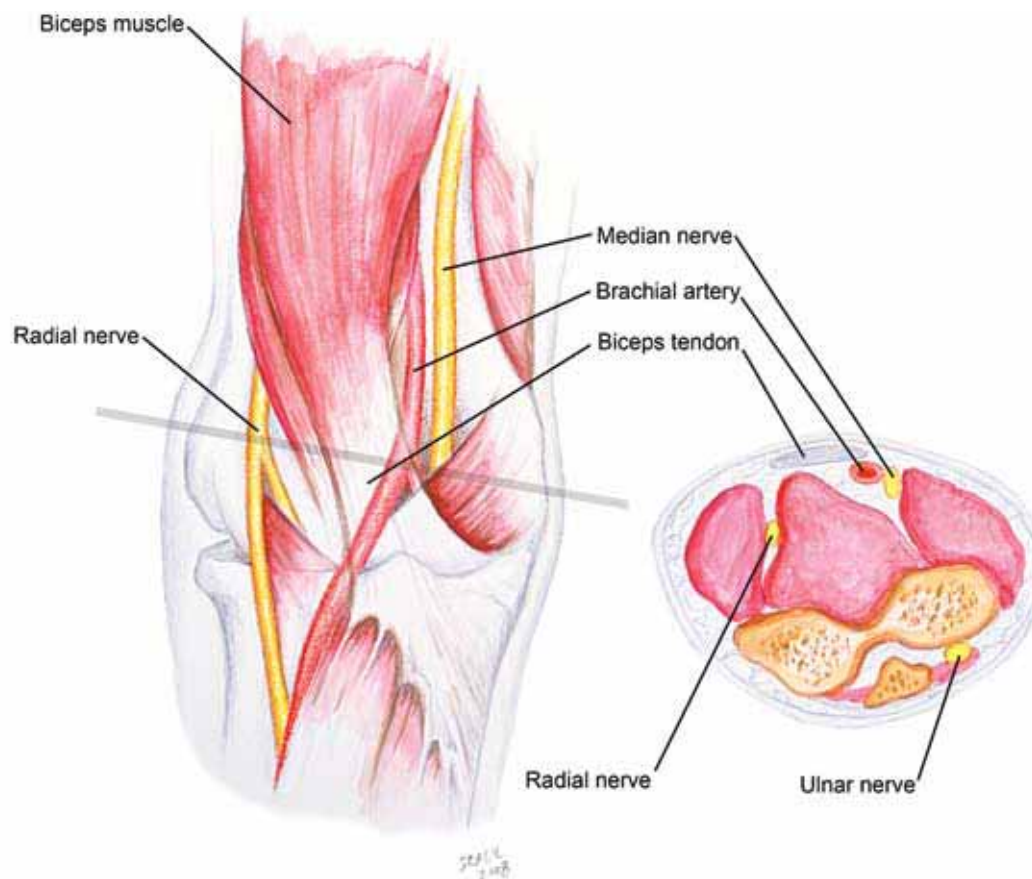


Figure 11-1

The radial nerve lies between the brachialis and brachioradialis muscles, 1 to 2 cm lateral to the biceps tendon. Using the biceps tendon as a landmark, the radial nerve can be blocked using paresthesia, stimulator, or ultrasound-based techniques. The radial nerve block at this level provides sensory anesthesia to the dorsolateral aspect of the hand (thumb, index, middle, and lateral half of the ring finger) up to the distal interphalangeal joint.

More distal blockade of the upper extremity may be accomplished at the level of the wrist. The median nerve lies between the palmaris longus and flexor carpi radialis tendons. The ulnar nerve is located immediately lateral to the flexor carpi ulnaris and just medial to the ulnar artery. It is important to note that the radial nerve has already branched at the level of the wrist, thus requiring field block over the radial aspect of the wrist.

PROCEDURE

Landmarks. Pertinent landmarks at the level of the elbow consist of the ulnar groove, median and lateral condyles of the humerus, brachial artery pulsation (median nerve), and tendon of the biceps muscle (radial nerve). At the level of the wrist, key landmarks include the tendons of the flexor palmaris longus and flexor carpi radialis (median nerve), anatomic snuffbox (radial nerve), and ulnar styloid (ulnar nerve).

At the Elbow

Radial nerve. Identify the biceps tendon. Insert the needle lateral to the tendon and above the antecubital crease (the line bisecting medial and lateral epicondyles). The nerve lies within the groove between the tendon and the brachioradialis muscle (Figure 11-2). Two excellent localization cues are paresthesia and motor response (finger/wrist extension) elicited by a nerve stimulator. Inject 5 to 7 mL of local anesthetic.

Figure 11-2

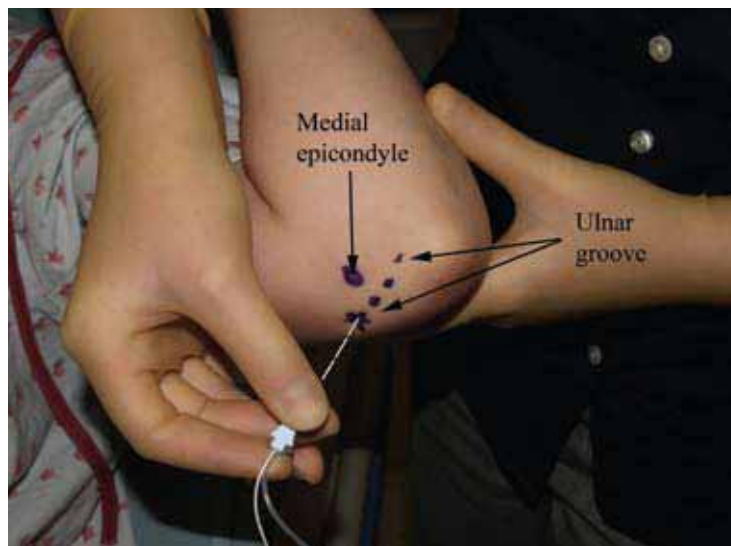
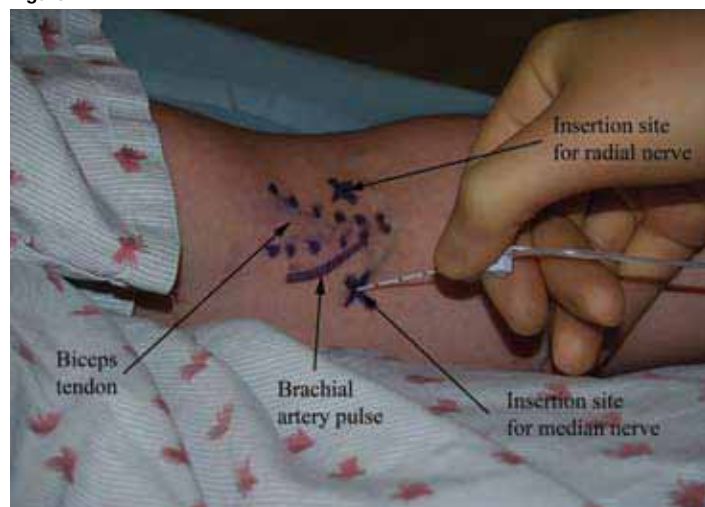


Figure 11-3

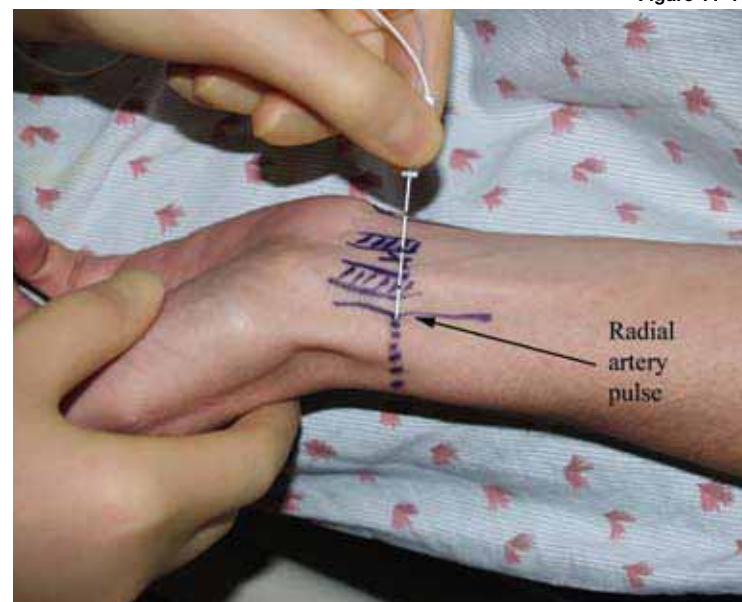
Median nerve. Insert the needle at the antecubital crease, just medial to the palpated brachial pulse (see Figure 11-2). When a paresthesia or motor response (finger/wrist flexion or hand pronation) is elicited, usually at 1- to 2-cm depth, inject 5 to 7 mL of local anesthetic.

Ulnar nerve. With the elbow flexed at mid-range, insert the needle into the ulnar groove 1 to 3 cm proximal to the medial epicondyle. Take care to avoid excessive injection pressure or intraneural injection in this relatively tight space. Limit local anesthetic injection to 4 or 5 mL (Figure 11-3).

At the Wrist

Radial nerve. To block the branches of the radial nerve, make an injection along the radial artery's lateral border 2 cm proximal to the wrist (Figure 11-4). Then extend the injection dorsally over the border of the wrist, covering the anatomic snuffbox. Injection of 5 to 7 mL of local anesthetic is usually sufficient.

Figure 11-4



Median nerve. Identify the tendons of the flexor palmaris longus and flexor carpi radialis by flexing the wrist during palpation. Insert the needle between the tendons 2 cm proximal to the wrist flexor crease, posteriorly towards the deep fascia (Figure 11-5). Inject 3 to 5 mL of local anesthetic while withdrawing the needle.

Ulnar nerve. Many texts describe the ulnar artery pulsation as a landmark for the ulnar nerve block at the wrist; however, the ulnar pulse is difficult to appreciate in many patients. A practical approach is to insert the block needle just proximal to the ulnar styloid process (Figure 11-6). After aspiration to confirm that the needle is not within the ulnar artery, inject 3 to 5 mL of local anesthetic.

Figure 11-5

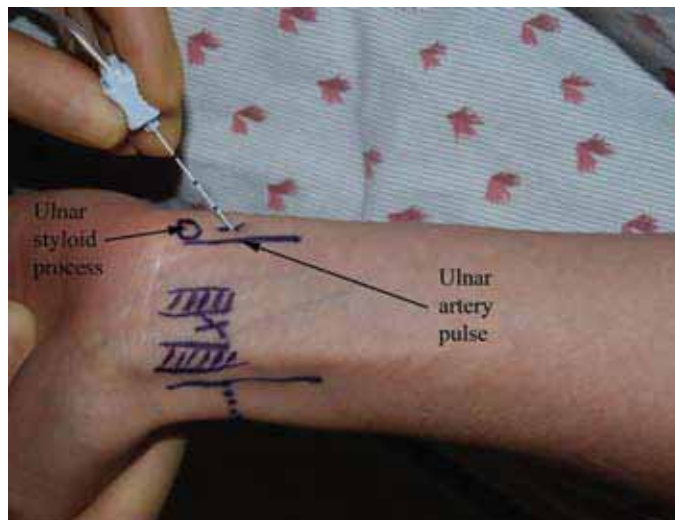
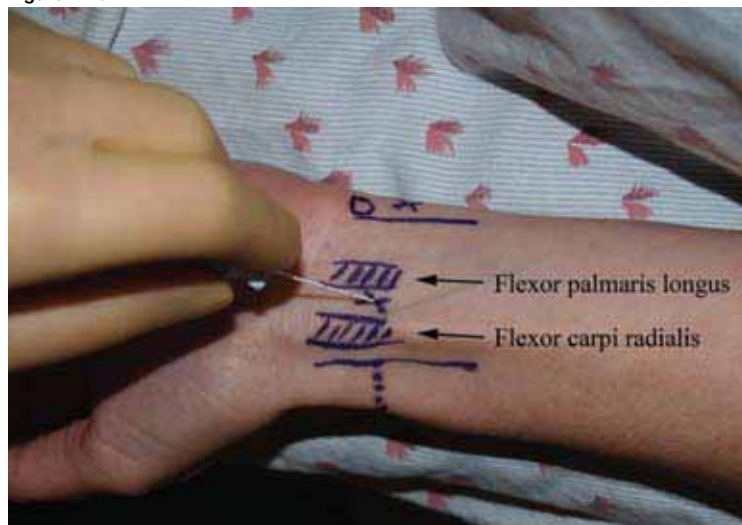


Figure 11-6

Needles

- 22-gauge, 5-cm, insulated needle for nerve stimulation techniques.
- 22-gauge, 5-cm regional needle or 25-gauge, 1- to 1.5-inch b-bevel needle.

Stimulation. Set the nerve stimulator initially at 1.0 to 1.2 mA. Muscle twitches for radial, median, and ulnar distributions should be sought at 0.5 mA or less, indicating adequate proximity to the peripheral nerve prior to injection. Stimulation at the level of the elbow is useful for defining peripheral nerve branches. Peripheral nerve blockade at the wrist is essentially a field block technique, with minimal utility gained from stimulation.

Local Anesthetic. In most adults, 3 to 5 mL of local anesthetic for each desired branch is sufficient. At the level of the elbow, 5 to 7 mL may be used for median and radial nerve blocks. The choice of local anesthetic is determined by user preference; usually mepivacaine, bupivacaine, or ropivacaine is selected. The use of epinephrine 1:400,000 as an adjuvant to local anesthetic is advisable for blocks at the level of the elbow but not recommended for distal blocks such as wrist blocks or digit blocks.

Additional Procedures. When performing an elbow block, an additional 5 mL of subcutaneous local anesthetic injected laterally from the biceps tendon to the brachioradialis muscle will provide anesthesia for the lateral cutaneous nerve of the forearm.

Teaching Points. As with all regional anesthesia techniques, proper injection technique should be followed. This includes frequent aspiration for blood, incremental injection, consideration of injection pressure, and avoidance of “pinning” nerves against underlying bone with the injection needle.

BLOCK WITH ULTRASOUND PROBE

Probe. High-frequency (5–12 MHz), linear.

Approach. Because of the proximity to vascular structures and the smaller size of nerves at this level, the in-plane approach is recommended. Ultrasound views of various nerves at the elbow are presented in Figures 11-7 through 11-9.

Injection. As above, 5 to 7 mL at each injection site.

Figure 11-7. Brachial artery and median nerve of the right arm at elbow level

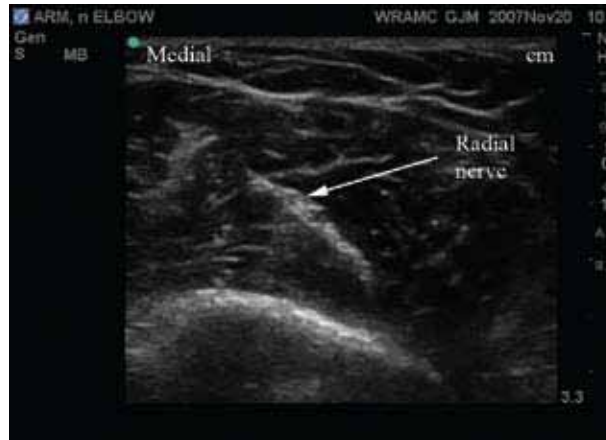
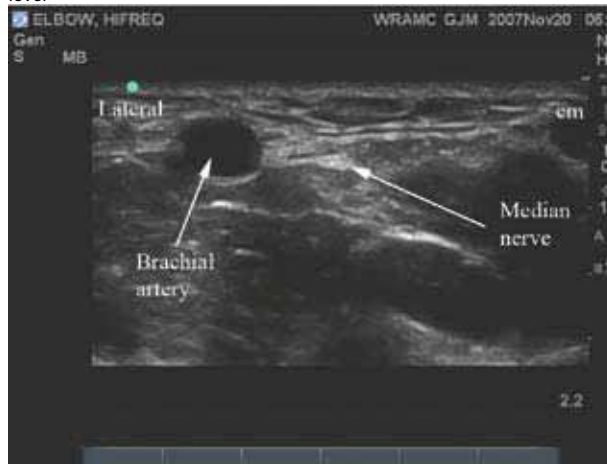
Figure 11-8. Radial nerve of the right arm at elbow level

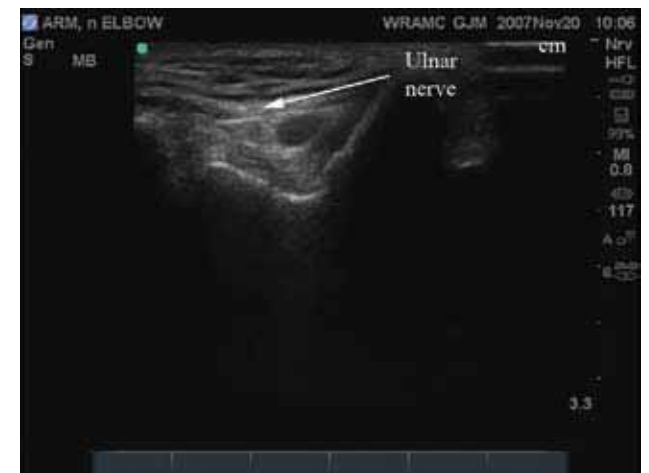

Figure 11-9. Ulnar nerve within the olecranon fossa, right arm

Teaching Points. Use caution when injecting local anesthetic into the olecranon fossa for selective blockade of the ulnar nerve. As shown in Figure 11-9, the ulnar nerve is “trapped” in a confined space at this location. Ensure that injection pressure is not too high, use less than 5 mL of anesthetic, and avoid over-flexing the elbow during the block so the ulnar nerve does not become “pinned” in the fossa and therefore more prone to intraneural injection or damage.

The radial nerve is easily traced from the cubital fossa more proximally to the mid-humeral level. Although the radial nerve may be more superficial proximally, the chance of vascular injury is decreased when the injection is done at the cubital fossa.

12. PARAVERTEBRAL NERVE BLOCK

INTRODUCTION

Paravertebral nerve blocks (PVBs) have been an established technique for providing analgesia to the chest and abdomen for many years. PVBs are highly versatile and may serve as the primary anesthetic for chest trauma, chest tubes, breast surgery, herniorrhaphy, soft tissue mass excisions, and bone harvesting from the iliac crest, as well as as a useful adjunct in laparoscopic surgery, cholecystectomy, nephrectomy, or other abdominal and thoracic surgeries. In addition, PVBs are a valuable tool in treating acute and chronic pain conditions of the chest and abdomen.

ANATOMY

The paravertebral space is a wedge shaped anatomical compartment adjacent to the vertebral bodies. Its boundaries are defined anterior-laterally by the parietal pleura; posteriorly by the superior costotransverse ligament (thoracic levels); medially by the vertebrae, vertebral disk, and intervertebral foramina; and superiorly and inferiorly by the heads of the ribs (Figure 12-1). The space is further divided into an anterior (ventral) and posterior (dorsal) compartment by the endothoracic fascia. Studies have suggested that to inject as close to the spinal nerves as possible, this fascial layer should be crossed and local anesthetic deposited into the ventral compartment.

Within the paravertebral space, the spinal nerves are essentially “rootlets” and are not as tightly bundled with investing fascia as they are more distally. This anatomy enhances local anesthetic contact; the nerve roots facilitate dense nerve blockade when a small volume of local anesthetic is introduced into the space. Injection of local anesthetic results in ipsilateral motor, sensory, and sympathetic blockade. Radiographic studies have demonstrated that if the anesthetic is deposited

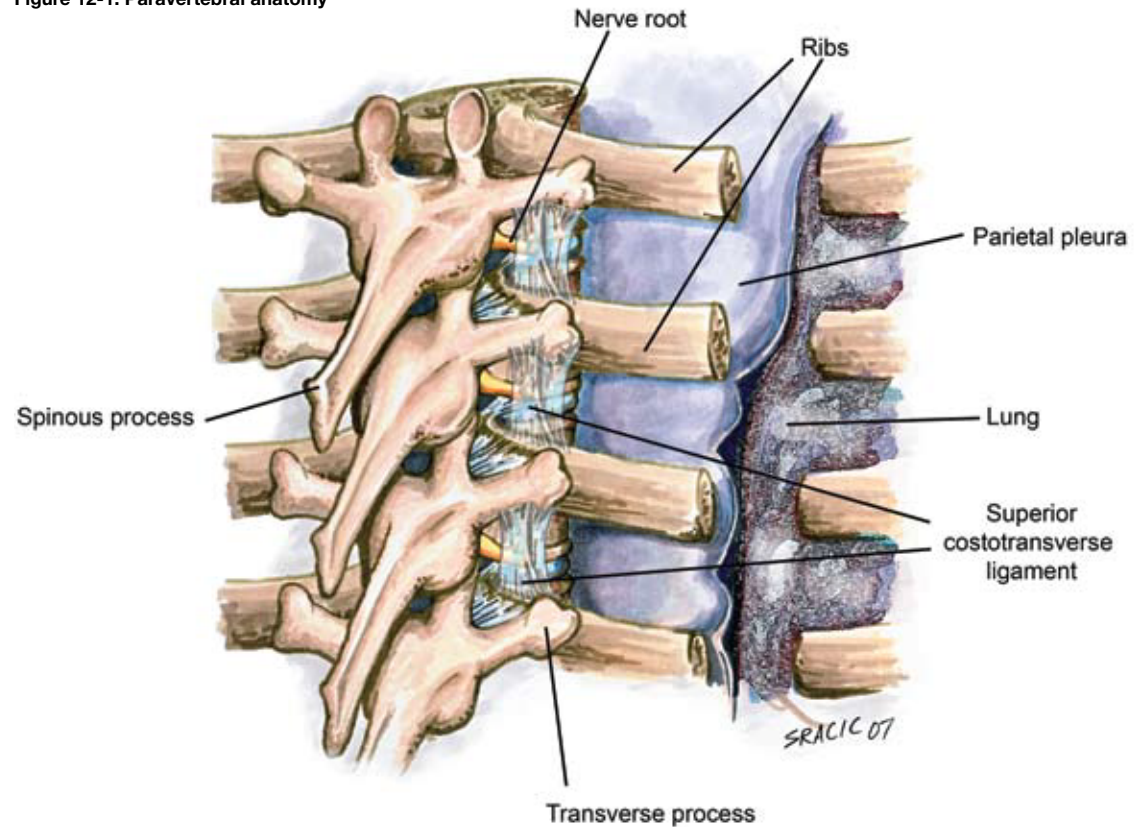
in the ventral compartment, a multisegmental longitudinal spread typically results, whereas injection into the dorsal compartment will more likely result in a cloud-like spread with limited distribution to paravertebral spaces above and below the injection site. The use of the peripheral nerve stimulator to more accurately place the needle in the ventral compartment can reduce the number of paravertebral injections needed. However, many providers are disinclined to rely on the multisegmental spread of local anesthetic associated with stimulator-guided injections and prefer the multiple injection technique, injecting each individual level required. This places less

emphasis on needle position within the paravertebral space. Both techniques are acceptable.

The median skin-to-paravertebral depth has been demonstrated to be 55.0 mm, with the depth being greater at the upper (T1–T3) and lower (T9–T12) thoracic levels. However, body mass index has been shown to significantly influence the skin-to-paravertebral depth at these levels. Depth is measurable by ultrasound.

Complications from paravertebral blocks include inadvertent vascular puncture, hypotension, hematoma, epidural spread (via the intervertebral foramina), intrathecal spread (via the dural cuff), pleural puncture, and pneumothorax.

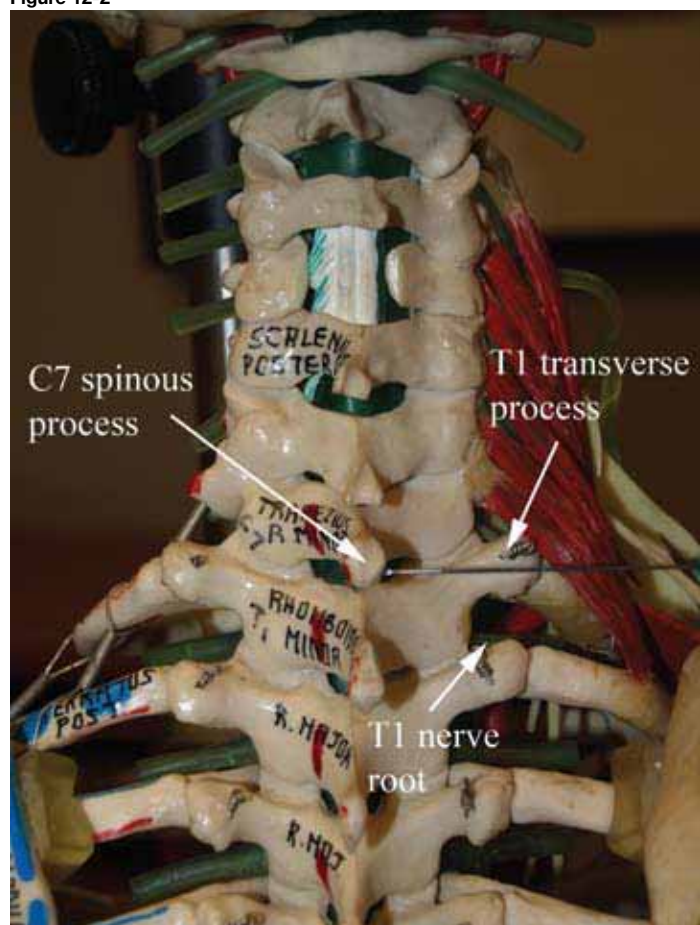
Figure 12-1. Paravertebral anatomy



PROCEDURE

Landmarks. The patient is placed sitting upright with the neck and back flexed and the shoulders relaxed forward. The spinous process of each level planned for the block is palpated and marked at its superior aspect. In thoracic paravertebral blocks, the numbered spinous process corresponds to the next numbered nerve root caudally because of

Figure 12-2



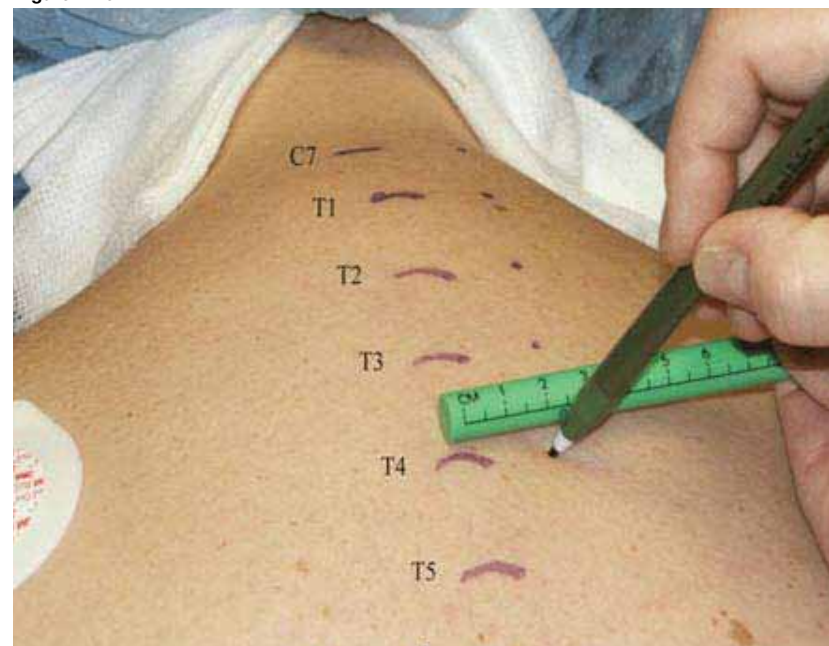
the cephalad angulation of the thoracic transverse processes. For example, a paravertebral block performed at the C7 spinous process actually blocks the T1 nerve root if the needle is passed caudally (Figure 12-2). From the midpoint of each spinous process, the needle entry site is marked 2.5 cm laterally (Figure 12-3). In the thoracic area these marks will overlie the transverse process of the next vertebral body, as noted above. In the lumbar area the transverse process is usually at the same level as the spinous process.

For mastectomy surgery with axillary dissection, T1–T6 is routinely blocked. For sentinel node biopsy with possible axillary dissection, blocking T1–T3 is sufficient. For breast biopsy, one injection is made at the dermatome corresponding to the lesion location plus additional injections one dermatome above and below this site. For inguinal herniorrhaphy, levels T11–L2 are blocked. For umbilical hernia, levels T9–T11 are blocked bilaterally. Ventral hernia repair and other applications of PVB require determining the dermatomes involved and then blocking these levels, as well as one dermatome above and below.

Needles

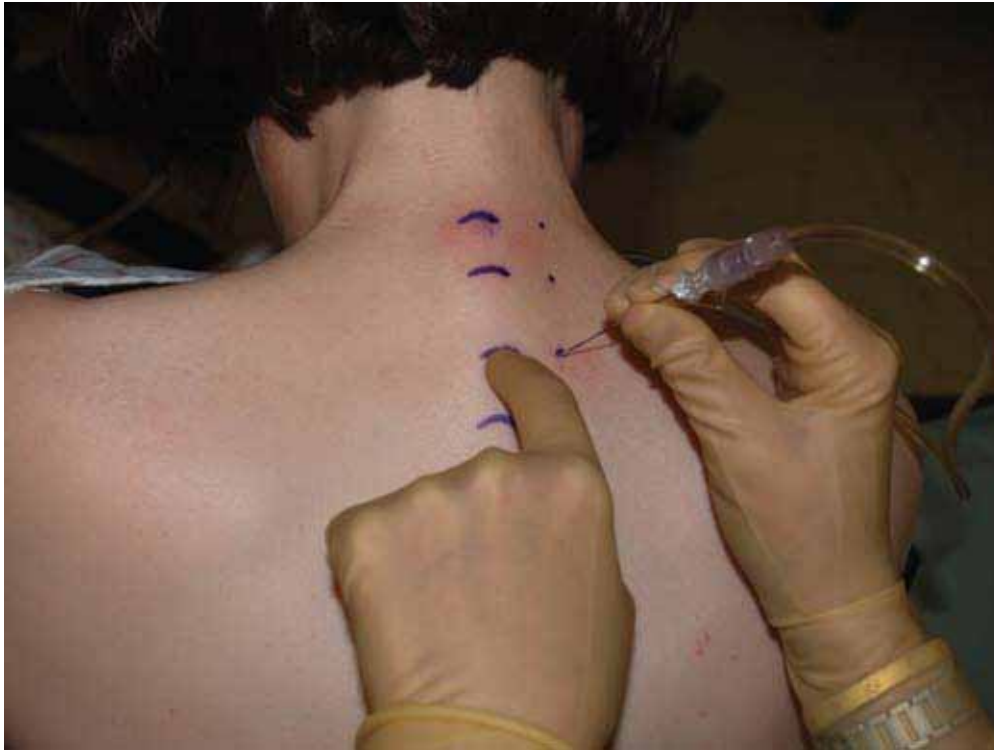- 21-gauge, 10-cm Tuohy needle with extension tubing.
- 21-gauge, 10-cm insulated needle for stimulation technique.
- 18-gauge, 10-cm Tuohy needle with hemostasis valve/sideport assembly and extension tubing. Catheters placed 2 cm into paravertebral space.

Figure 12-3



Block Without Stimulation. Employing aseptic technique, place a skin wheal of lidocaine local anesthetic at each level to be blocked. The Tuohy needle is attached via extension tubing to a syringe of local anesthetic. Grasp the shaft of the needle in your dominant hand, insert the needle through the skin wheal, and advance it anteriorly in the parasagittal plane (perpendicular to the back) until it contacts the transverse process (2–5 cm deep, depending on the body habitus of the patient). If you cannot identify the transverse process at an appropriate depth, assume that the needle tip lies between adjacent transverse processes, and redirect the needle cephalad and then caudad until the

Figure 12-4. Finding the transverse process



transverse process is successfully contacted (Figure 12-4). This depth should be noted as the estimated distance to subsequent transverse processes. With the needle contacting the transverse process, grasp the needle shaft with your fingers 1 cm from the skin surface (Figure 12-5). The fingers now serve as a “backstop” to prevent the needle passing beyond 1 cm into the paravertebral space and possibly into the pleura of the lung. Then withdraw the needle tip to the subcutaneous tissue and angle it to “walk off” the caudad edge of the transverse process, advancing no more than 1 cm into the space. Often, a loss of resistance or “pop”

is appreciated, indicating that the needle tip has penetrated the superior costotransverse ligament. After gentle aspiration of the syringe for blood and air, inject 3 to 5 mL of local anesthetic into the space.

Resistance to local anesthetic injection indicates that the needle tip is not in the paravertebral space or has not penetrated the ligament. If this occurs, advance the needle no more than 0.5 cm

until the resistance lessens (the tip has passed beyond the ligament) or bone is contacted (necessitating reposition of the needle). The reason for the caudal direction of needle placement is that if initial bone contact is inadvertently with the rib (too deep to the paravertebral space), “walking off” caudally will lead to needle contact with the transverse process at a more superficial point (“stepping up”), thus minimizing unintended deep needle insertion (Figure 12-6).

Figure 12-5. Finger backstop

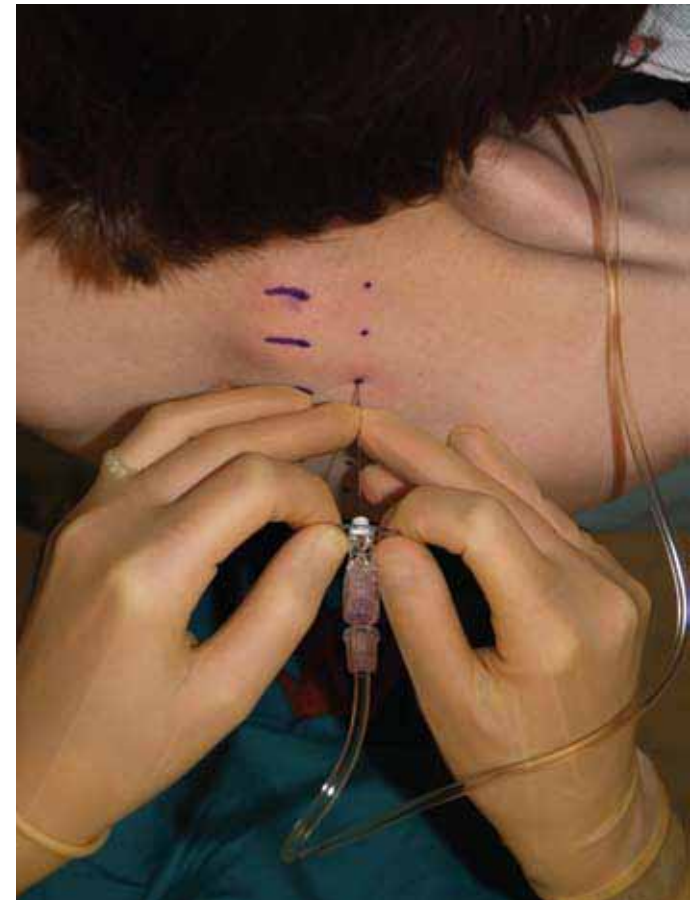
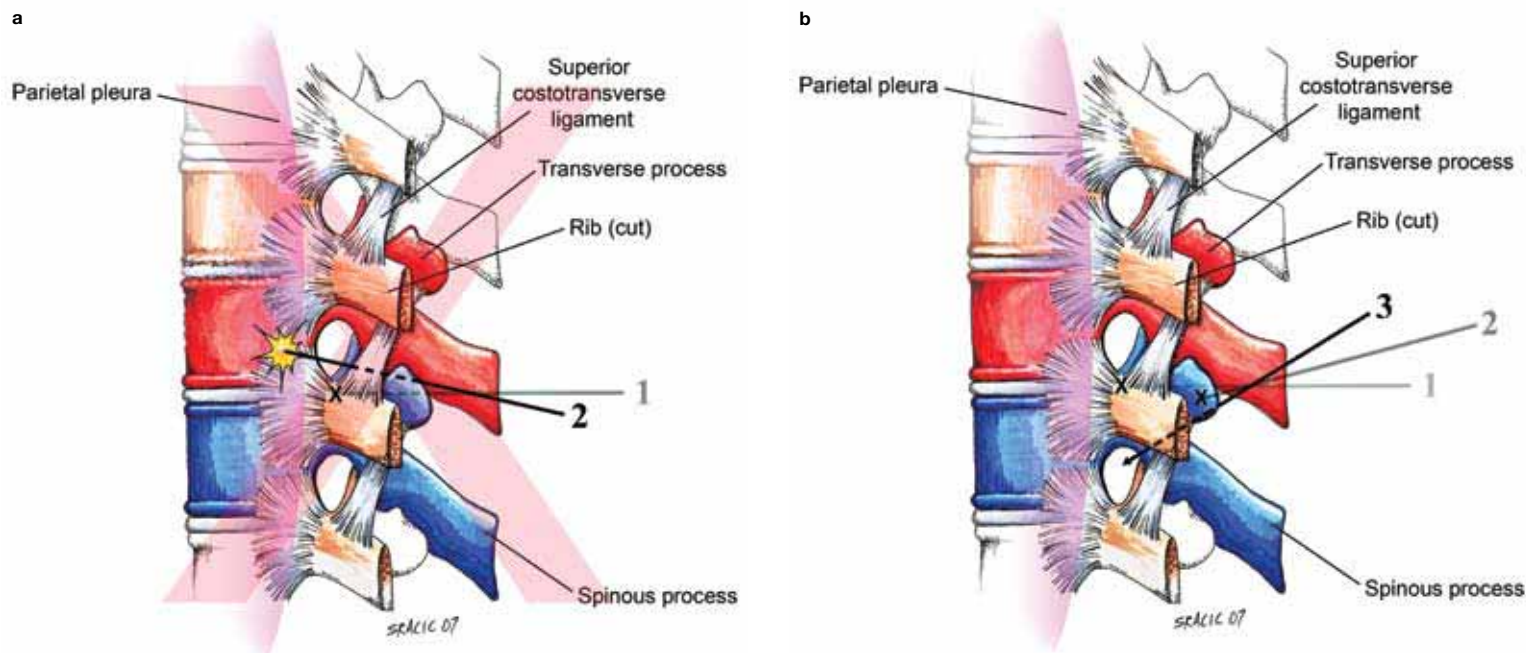


Figure 12-6. Cephalad versus caudal needle redirection for thoracic paravertebral blocks with erroneous initial needle contact with the rib. (a) In this figure the needle inadvertently contacts the rib (a-1), rather than the desired transverse process. If the provider directs the needle cephalad as depicted (a-2), inadvertent needle penetration of the pleura is possible. Therefore, cephalad needle redirection is NOT recommended. (b) In this figure the needle again incorrectly contacts the rib (b-1); however, with caudad redirection (recommended), this error is detected when the needle “steps up” onto the transverse process (b-2). With correct contact of the needle with the transverse process, the needle can be directed caudad into the paravertebral space with confidence using the 1-cm finger “backstop” (b-3).



Block With Stimulation. After identifying landmarks and prepping the area, attach a 21-gauge insulated needle to a nerve stimulator and turn the current to 2.5 mA. Advance the needle through the skin, perpendicular in all planes. Occasionally, contractions of the paraspinous muscles are seen at this point. Place the needle into the paravertebral space as described above for nonstimulating paravertebral blocks. Once the needle has advanced through the superior costotransverse ligament, any paraspinous contractions will stop and an intercostal muscle twitch will typically be observed. The patient can often confirm the contraction of his or her chest wall. Gently manipulate the needle tip to continue to view this twitch as you decrease the stimulator current to approximately 0.8 mA. The needle tip should now be within the ventral com-

partment of the paravertebral space and beyond the endothoracic fascia. Inject local anesthetic as above. The stimulation technique provides a more objective indication of correct needle placement within the space.

Local Anesthetic. For multiple injection techniques, 3 to 5 mL of local anesthetic (usually 0.5% ropivacaine) is injected at each space. Smaller volumes are injected when bilateral paravertebral blocks (more than 6 injections) are required. Larger volumes of 10 to 15 mL can be injected at a single thoracic level with typical spread of the local anesthetic 1 to 2 paravertebral levels above and below the injection level, particularly when stimulation is used. Each syringe of local anesthetic should contain epinephrine 1:400,000 as a marker of intravascular injection.

Teaching Points. At the thoracic levels it is common to appreciate a loss of resistance or a subtle “pop” as the needle passes through the superior costotransverse ligament. In the lumbar region, there is no superior costotransverse ligament. If a distinct “pop” is sensed here, the needle has likely punctured the psoas fascia and should be withdrawn to a more shallow depth, still remaining anterior to the transverse process.

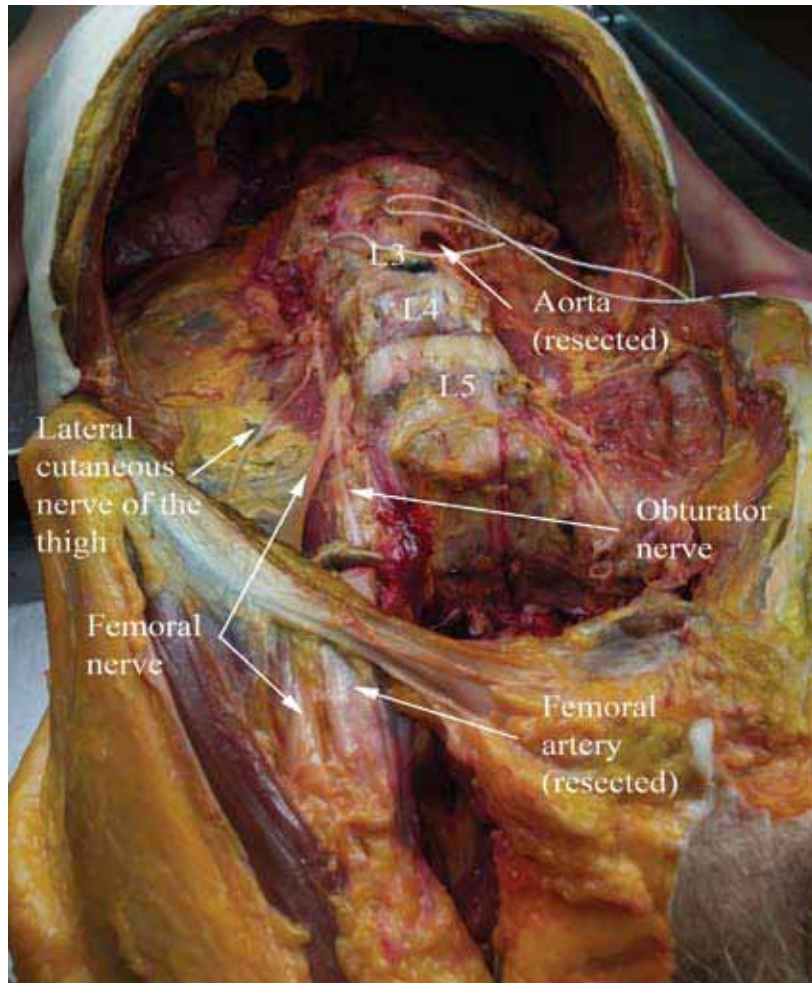
In addition, it is important to note that in the lumbar region, the transverse process is very thin, so the needle should be inserted only 0.5 cm past the transverse process. If using the nerve stimulator technique for thoracic paravertebral blocks, be aware that a blunt-tip Tuohy needle is not being used, which may increase the risk of pleural puncture.

13. LOWER EXTREMITY NEUROANATOMY

INTRODUCTION

Regional anesthesia of the lower extremity involves two major nerve plexuses, the lumbar plexus and the sacral plexus. The safe practice of lower extremity regional anesthesia depends on a comprehensive understanding of neuroanatomy in this region of the body.

Figure 13-1. Dissected right lumbar plexus. The exposed nerves have been dissected from the substance of the psoas muscle, which has been removed.

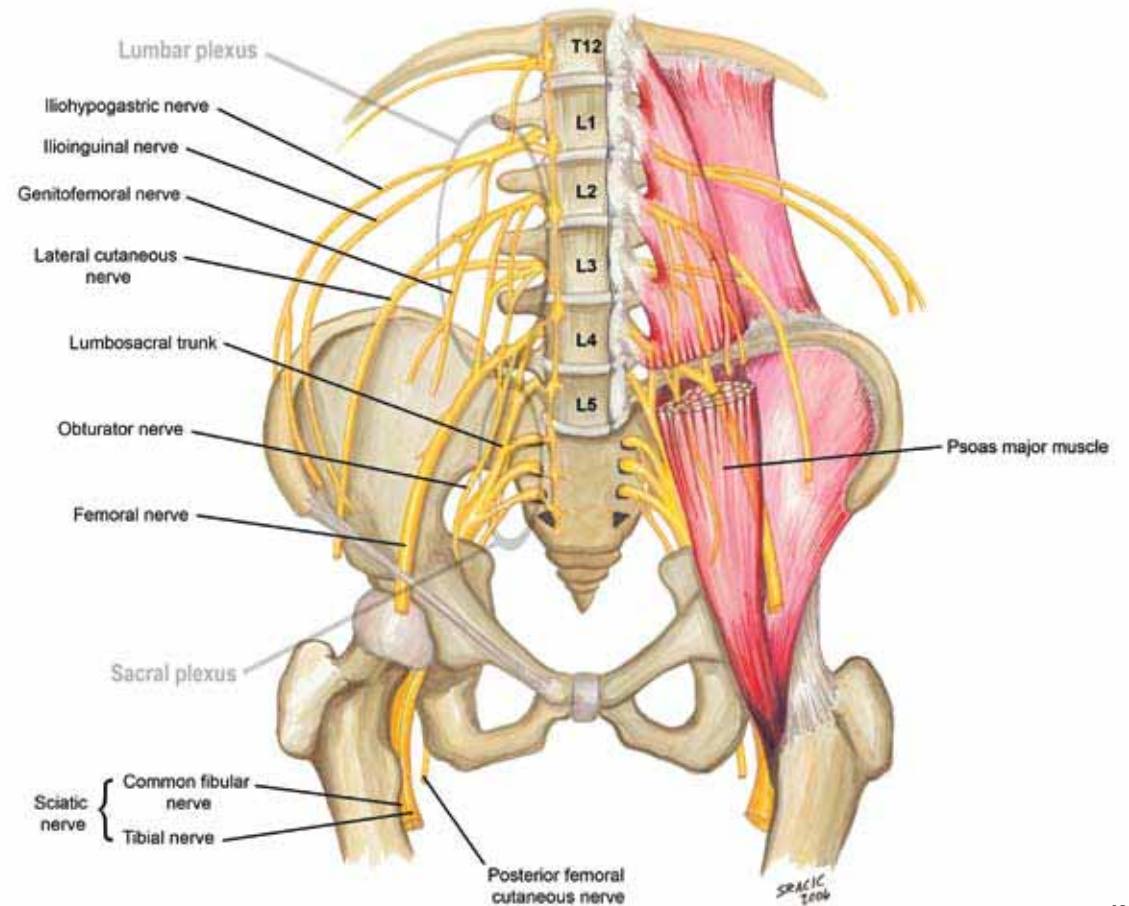


LUMBAR PLEXUS

The lumbar spinal nerves exit caudad to their numbered vertebrae and divide into posterior and anterior rami. The posterior rami of L1 through L5 supply the muscles and skin of the back. The lumbar plexus (Figure 13-1) consists of the anterior rami of L1 through L4. It forms anterior to the lumbar transverse processes within the proximal body of the psoas muscle. The major nerves of the lumbar plexus include the following (Figure 13-2):

- *Ilioinguinal and iliohypogastric nerves (L1)*: passes anterior to the quadratus lumborum and emerges near the anterior superior iliac spine to innervate the abdominal muscles and skin of the inguinal and pubic area.
- *Lateral femoral cutaneous nerve (L2, L3)*: emerges medial to the anterior superior iliac spine, passing deep to the inguinal ligament, to supply sensation to the anterolateral surface of the thigh.

Figure 13-2. Lumbar plexus and sacral plexus



- *Femoral nerve* (L2–L4): passes deep to the inguinal ligament to innervate the iliacus, hip flexors, and knee extensors of the thigh.
- *Obturator nerve* (L2–L4): passes medial to the psoas muscle, into the pelvis, and through the obturator foramen to innervate the medial thigh (adductors).
- *Lumbosacral trunk* (L4, L5): passes over the sacrum into the pelvis and joins the formation of the sacral plexus from the anterior rami of S1 through S4.

SACRAL PLEXUS

The sacral plexus is found within the lesser pelvis on the anterior surface of the piriformis muscle. It is formed from the anterior spinal nerve rami of L4 through S4. Most of the nerves originating from the sacral plexus leave the pelvis via the greater sciatic foramen. The major nerves of the sacral plexus are the following (see Figure 13-2):

- *Sciatic nerve* (L4–S3): travels in the posterior thigh to provide motor and sensory innervation to the posterior thigh and majority of the lower leg (with the exception of the medial lower leg). The largest nerve in the body, the sciatic nerve is composed of two individual nerves, the tibial nerve and common peroneal nerve, traveling together within the same nerve sheath (Figure 13-3).
- *Pudendal nerve* (S2–S4): enters the perineum via the lesser sciatic foramen. The pudendal nerve is the primary nerve of the perineum providing sensation to the genitalia and motor innervation to the muscles of the perineum.
- *Posterior femoral cutaneous nerve* (S2–S3): provides

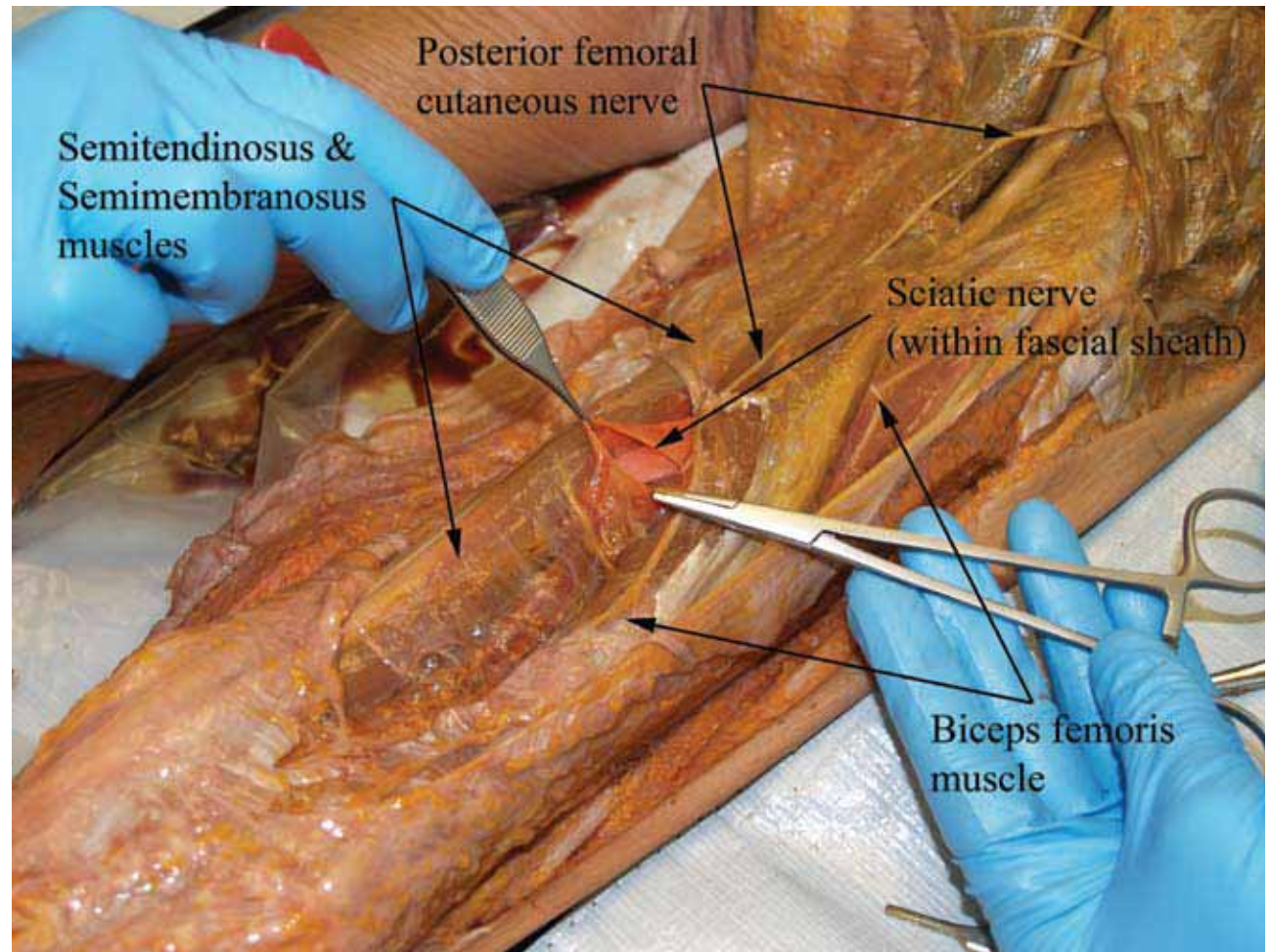
cutaneous innervation of the buttock and proximal medial/posterior surfaces of the thigh (see Figure 13-3).

- *Superior gluteal nerve* (L4–S1): leaves the pelvis superior to the piriformis and innervates the

gluteal muscles (gluteus medius and gluteus minimus) and the tensor to the fascia lata.

- *Inferior gluteal nerve* (L5–S2): leaves the pelvis inferior to the piriformis and superficial to the sciatic nerve, branching to innervate the gluteus maximus muscle.

Figure 13-3. Sciatic nerve within fascial sheath dissected at posterior mid-thigh



14. LUMBAR PLEXUS BLOCK

INTRODUCTION

The lumbar plexus consists of a group of six nerves that supply the lower abdomen and upper leg. Combined with a sciatic nerve block, the lumbar plexus block can provide complete analgesia to the lower extremity. This procedure is an alternative to neuraxial anesthesia, which also anesthetizes the nonoperative leg and occasionally results in urinary retention. The complete lumbar plexus can be blocked from a posterior approach (also known as the psoas compartment block), although the individual nerves of the plexus can be accessed anteriorly as well.

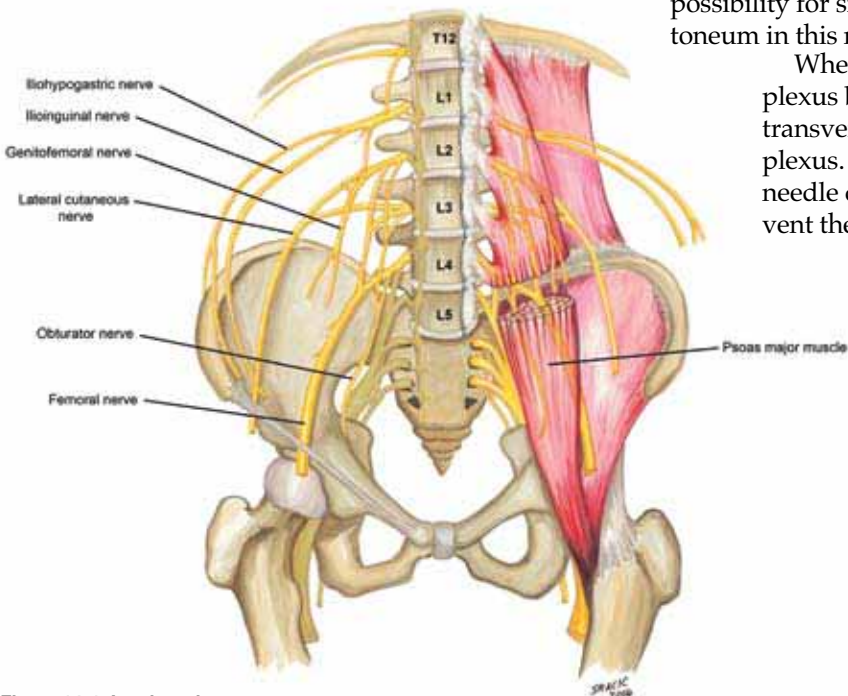


Figure 14-1. Lumbar plexus anatomy

ANATOMY

The lumbar plexus is formed from the ventral rami of L1–L4 with variable contributions from T12 and L5 (Figure 14-1). The peripheral branches of the lumbar plexus include the iliohypogastric, ilioinguinal, genitofemoral, lateral femoral cutaneous, femoral, and obturator nerves. The plexus forms within the body of the psoas muscle (Figure 14-2), and the lumbar plexus block consistently blocks the three nerves that supply the lower extremity (femoral, lateral femoral cutaneous, and obturator—Figure 14-3). As it passes to the pelvis, the obturator has more variability of location and is separated from the other two nerves of the plexus by the psoas muscle. This is why the femoral nerve block (also called the “3-in-1 block”) often fails to successfully block the obturator nerve and why the lumbar plexus approach is often selected when blockade of all three nerves is required. However, the lumbar plexus block remains controversial because of the deep location of the plexus within the psoas muscle and the possibility for significant bleeding into the retroperitoneum in this noncompressible area of the body.

When performing a posterior lumbar plexus block, it is important to contact the L4 transverse process before entering into the plexus. This bony landmark will serve as a needle depth safety point that should prevent the operator from advancing too deep into the retroperitoneum. Studies have shown that although variability exists in distances from the skin to the L4 transverse process among men and women with varying body mass indexes, once the transverse process is reached, the distance to the lumbar plexus is no more than 20 mm.

Complications from a posterior lumbar plexus block include intrathecal injection, epidural injection or diffusion (the most common complication), intravascular injection, and retroperitoneal bleeding.

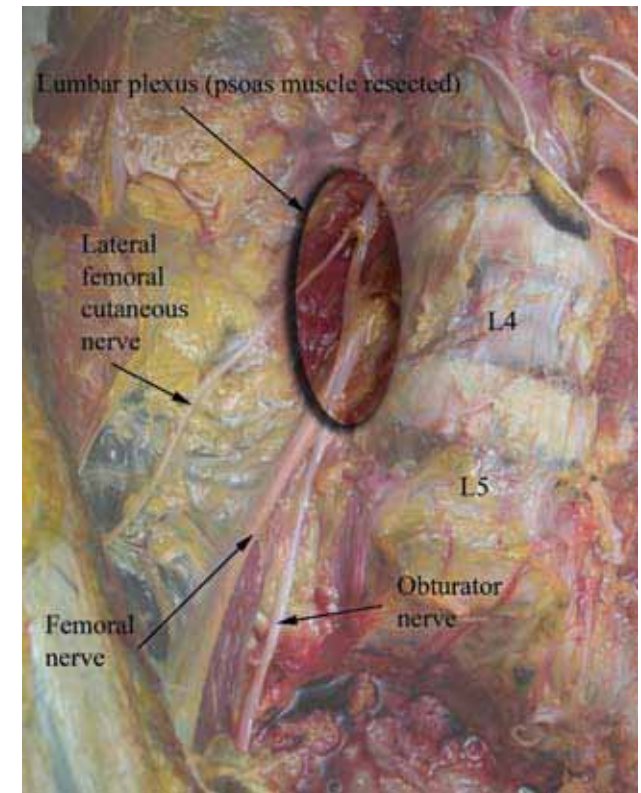


Figure 14-2. Lumbar plexus dissection

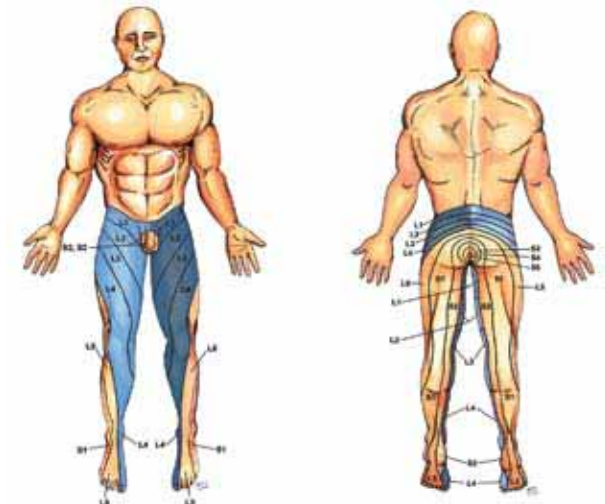


Figure 14-3. Dermatomes anesthetized with the lumbar plexus block (dark blue)

PROCEDURE

Landmarks. The patient is placed in the lateral decubitus position with the operative side up. A line is drawn from the top of the posterior iliac crest down to midline. Known as the “intercrystal line,” this line is positioned over the L4 transverse process in most adults. The intersection of the intercrystal line with a line drawn parallel to the spine from the posterior superior iliac spine determines the initial needle insertion point and is 5 cm lateral from midline in most patients (Figure 14-4).

Needles

- 21-gauge, 10-cm insulated needle for the majority of patients. 15-cm needles may be needed for obese patients.
- 18-gauge, 10-cm insulated Tuohy needle for catheter placement. Catheters introduced 5 cm beyond needle tip.

Stimulation. Set the nerve stimulator initially at 1.0 to 1.2 mA, and look for a quadriceps muscle twitch (femoral nerve) as evidence of needle proximity to the lumbar plexus (this twitch is usually encountered at a depth of 5 to 8 cm from the skin). Insert the needle with a slight medial angulation to the sagittal plane of the patient (Figure 14-5). Make small adjustments of the needle tip caudad and cephalad if initial passes fail to contact os. Once bone is contacted (usually the transverse process of L4), bring the needle back towards the skin, redirecting it caudally to “walk off” the process. The plexus should be stimulated at a depth of no more than 2 cm beyond the transverse process; beyond this the risk of injury to retroperitoneal structures is increased. Decrease the stimulator current to 0.5 mA. If the twitch remains evident with the decreased current, injection of local anesthetic can proceed.

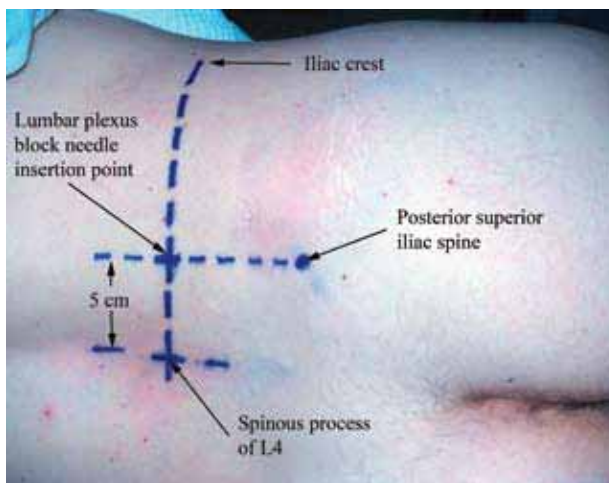


Figure 14-4. Lumbar plexus block landmarks

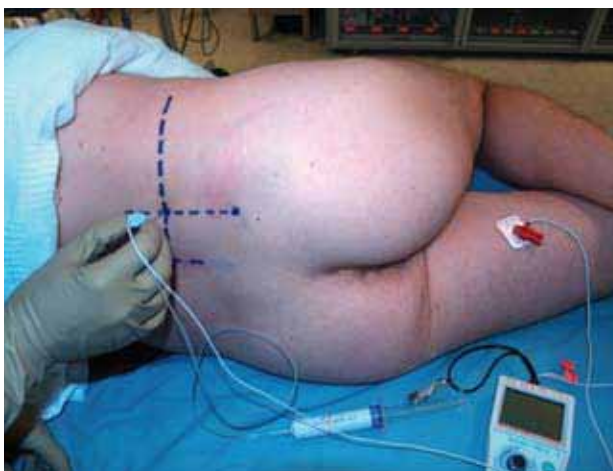


Figure 14-5.

Ultrasound can be used to confirm bony anatomical landmarks for this block (along the L4 transverse process); however, the depth of the plexus in adults will make visualization of the nerves difficult.

Local Anesthetic. In most adults, 30 to 40 mL of local anesthetic is sufficient to block the plexus.

Teaching Points. Occasionally stimulation of the hamstring muscles of the posterior thigh will be noted while attempting to perform the lumbar plexus block. This suggests sacral plexus stimulation (sciatic nerve) and indicates the needle tip is too caudal and medial. Injection here may lead to epidural spread or incomplete block of the plexus. Adjustment of the initial needle insertion point 1 cm cephalad and 1 cm lateral compensates for this error.

If os is repeatedly encountered despite “walking off” the transverse process, the needle tip may be too medial and may be hitting the vertebral lamina. Pull the needle back towards skin and redirect slightly more lateral.

The term “os” is specifically used rather than “bone” to remind the physician that lightly sedated patients may become concerned or agitated if they hear the needle described as contacting their bone. The term “os” is less familiar and therefore less alarming to patients, and this term should be used while discussing bony landmarks during regional anesthetic procedures.

15. FEMORAL NERVE BLOCK

INTRODUCTION

The femoral nerve block provides analgesia to the anterior thigh, including the flexor muscles of the hip and extensor muscles of the knee. Historically this block was also known as the “3-in-1 block,” suggesting that the femoral, lateral femoral cutaneous, and obturator nerves could be blocked from a single paravascular injection at the femoral crease. Studies have since demonstrated that the femoral and lateral femoral cutaneous nerves can be reliably blocked by a single injection, but the obturator nerve is often missed. Therefore, a posterior lumbar plexus block should be used when all three nerves need to be anesthetized (although this point remains controversial). The femoral nerve block is an ideal block for surgeries of the hip, knee, or anterior thigh and is often combined with a sciatic nerve block for near complete lower-extremity analgesia. Complete analgesia of the leg can be achieved without lumbar plexus block by combining a femoral nerve block with parasacral sciatic nerve block (which blocks the obturator over 90% of the time), or by adding an individual obturator nerve block to the femoral nerve block.

ANATOMY

The femoral nerve, formed by the dorsal divisions of the anterior rami of L2–L4, is the largest terminal branch of the lumbar plexus. It travels through the psoas muscle, leaving the psoas at its lateral border. The nerve then descends caudally into the thigh via the groove formed by the psoas and iliacus muscles, entering the thigh beneath the inguinal ligament (Figure 15-1). After emerging from the ligament, the femoral nerve divides into an anterior and posterior branch. At this level it is located lateral and posterior to the femoral artery (Figure 15-2). The anterior branch provides motor innervation to the sartorius and pectineus muscles and sensory innervation to the skin of the anterior and medial thigh. The posterior branch provides motor innervation to the quadriceps muscle (rectus femoris, vastus intermedius, vastus lateralis, and vastus medialis) and sensory innervation to the medial aspect of the lower leg via the saphenous nerve (Figures 15-3 and 15-4).

The anatomic location of the femoral nerve makes this block one of the easiest to master because the landmarks are usually simply identified (except in cases of morbid obesity), the patient remains supine, and the depth of the nerve is relatively superficial.

Figure 15-3

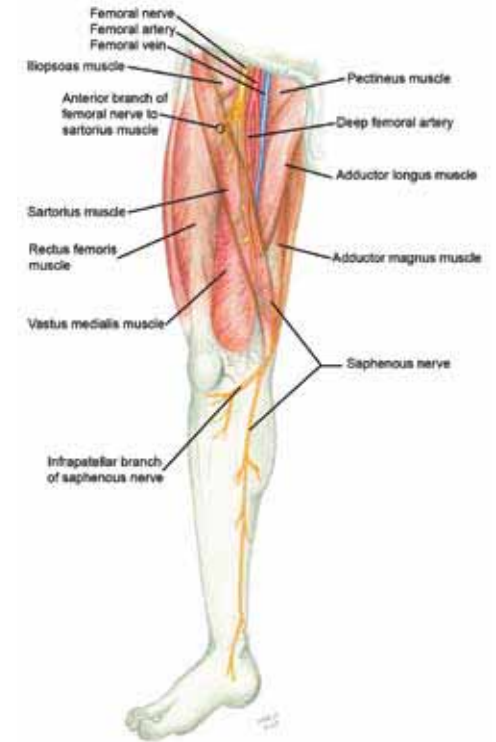


Figure 15-4. Dermatomes anesthetized with the femoral nerve block (dark blue)

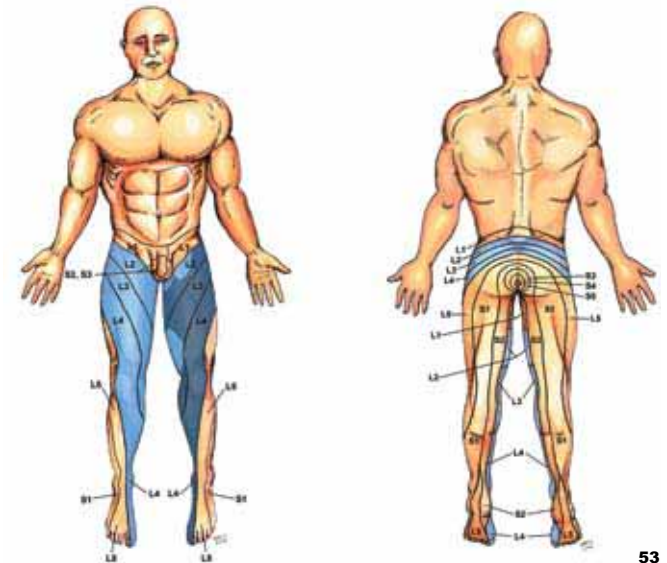


Figure 15-1

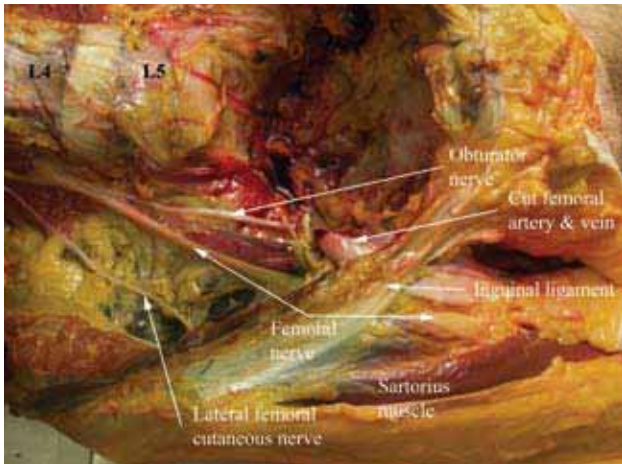
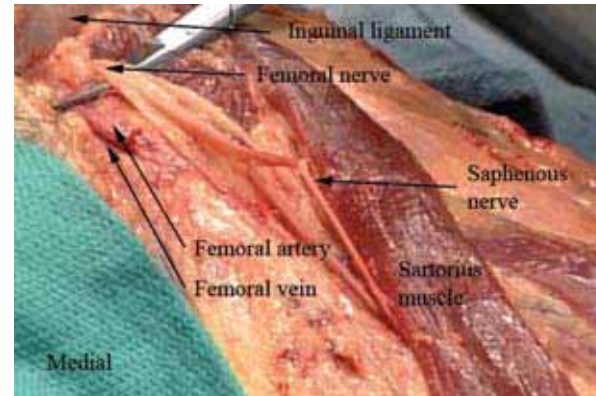


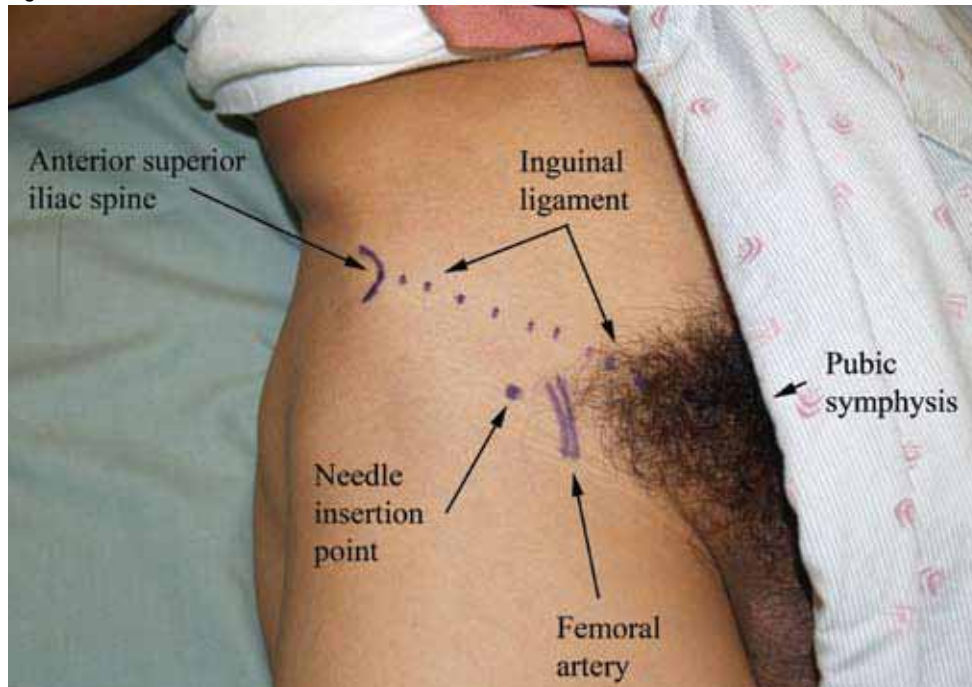
Figure 15-2



PROCEDURE

Landmarks. Place the patient supine, identify the anterior superior iliac spine and the pubic symphysis, and draw a line between these two landmarks. This line represents the inguinal ligament. The femoral nerve passes through the center of the line, which makes this landmark useful for positioning the needle in the inguinal crease, particularly in an obese patient. Then palpate the femoral pulse and mark it at the inguinal crease. Studies have demonstrated that the most successful point of needle entry is directly lateral (1–1.5 cm) to the artery in the inguinal crease. At this location the femoral nerve is wide and superficial, and the needle does not pass through significant muscle mass. Direct the needle cephalad toward the center of the inguinal ligament line (Figure 15-5).

Figure 15-5



Needles

- 22-gauge, 5-cm insulated needle.
- 18-gauge, 5-cm insulated Tuohy needle for catheter placement. The catheter is inserted 3 to 5 cm for the femoral block.

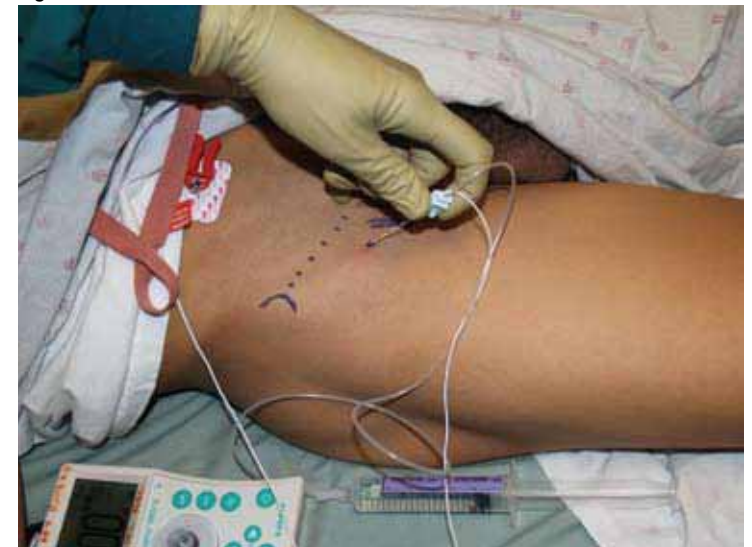Stimulation. The nerve stimulator is initially set at 1.0 to 1.2 mA. The needle is directed cephalad at approximately a 30° to 45° angle. A brisk “patellar snap” with the current at 0.5 mA or less is indicative of successful localization of the needle near the femoral nerve. The nerve is usually superficial, rarely beyond 3 cm from the skin (Figure 15-6).

Local Anesthetic. In most adults, 20 to 40 mL of local anesthetic will produce a successful femoral block.

Teaching Points. Studies have demonstrated that the anterior branch of the femoral nerve is usually encountered with the first needle pass, which results in stimulation of the sartorius muscle, often seen as contraction of the lower medial thigh. If this occurs, advance the needle tip until either the sartorius twitch is extinguished or a patellar snap is elicited before redirecting the needle. If the sartorius twitch is extinguished without the patellar snap, withdraw the needle toward the skin (without exiting the skin), and redirect it slightly lateral and slightly deeper than the original needle pass. The posterior branch of the femoral nerve is typically lateral and deep to the anterior branch.

The anesthetist should resist the urge to use the patient’s thigh as a hand rest while directing the needle. Stimulation of the femoral nerve can result in brisk vastus muscle twitching that can disrupt needle positioning.

Figure 15-6



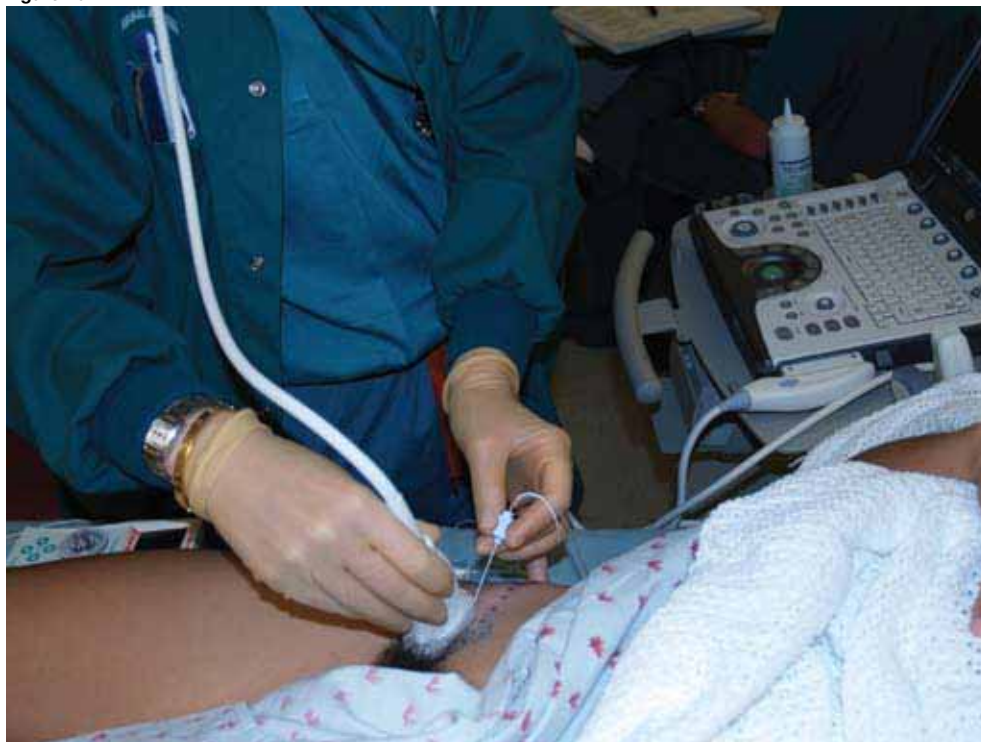BLOCK WITH ULTRASOUND PROBE

Probe. High frequency (5–12 MHz), linear.

Probe Position. Place the probe in the inguinal crease, parallel to the inguinal ligament. The nerve will be visualized as a hyperechoic, triangular-shaped structure immediately lateral to the femoral artery.

Approach. Insert the needle at the lateral end of the ultrasound probe and advance it parallel to the ultrasound beam, in full view, until it approaches the femoral nerve (Figure 15-7). This is the preferred approach at Walter Reed Army Medical Center because it allows visualization of the entire needle. Some providers opt to advance

Figure 15-7



the needle to the nerve from a short-axis view (visualizing the needle as a dot) as opposed to the long-axis view. Both approaches are acceptable. The femoral nerve is easily visualized near the femoral artery in most patients (Figure 15-8). The relatively superficial depth of the femoral nerve at the inguinal crease enhances visualization of the needle under ultrasound. A medial approach to the femoral nerve should be avoided because the femoral artery can obstruct the needle approach to the femoral nerve.

Injection. Ensure that the needle has penetrated through the fascia lata (which divides the subcutaneous tissues of the thigh from the underlying muscles and vessels) as well as the fascia iliaca (which surrounds the iliopsoas and femoral nerve). To ensure a successful block, the local anesthetic must either surround the femoral nerve completely or surround the medial, lateral, and inferior aspects of the nerve (Figure 15-9). If the local anesthetic is distributed only at the superior aspect of the nerve, the needle may not have crossed the fascia iliaca, the local anesthetic will be unable to properly penetrate the nerve, and the block may be delayed or fail.

Figure 15-8

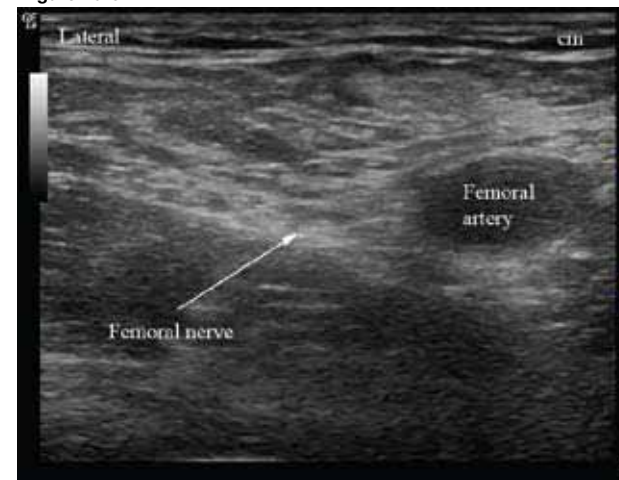
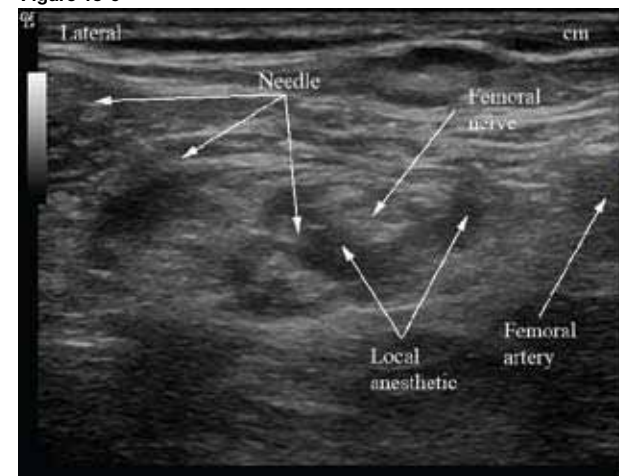


Figure 15-9



Teaching Point. Studies have demonstrated that use of the ultrasound can improve the femoral nerve block by decreasing the block latency by as much as 10 minutes, improving the sensory component of the block, and reducing the amount of local anesthetic needed to achieve block success.

16. INDIVIDUAL NERVE BLOCKS OF THE LUMBAR PLEXUS

LATERAL FEMORAL CUTANEOUS NERVE BLOCK

Introduction. The lateral femoral cutaneous (LFC) nerve is a purely sensory nerve derived from the L2–L3 nerve roots. It supplies sensory innervation to the lateral aspect of the thigh (Figure 16-1). Because it is one of six nerves that comprise the lumbar plexus, the LFC can be blocked as part of the lumbar plexus block. Most of the time, but not always, it can also be simultaneously anesthetized via a femoral nerve block. An occasional need arises to perform an individual LFC nerve block for surgery such as a thigh skin graft harvest or for the diagnosis of myalgia paresthetica (a neuralgia of the LFC nerve).

Anatomy. The LFC nerve emerges from the lumbar plexus, travels along the lateral aspect of the psoas muscle, and then crosses diagonally over the iliacus muscle. After traversing beneath the inguinal ligament, it enters the thigh and passes medially to the anterior superior iliac spine (ASIS). It is the rela-

Figure 16-1. Dermatomes anesthetized with the LFC block (dark blue)

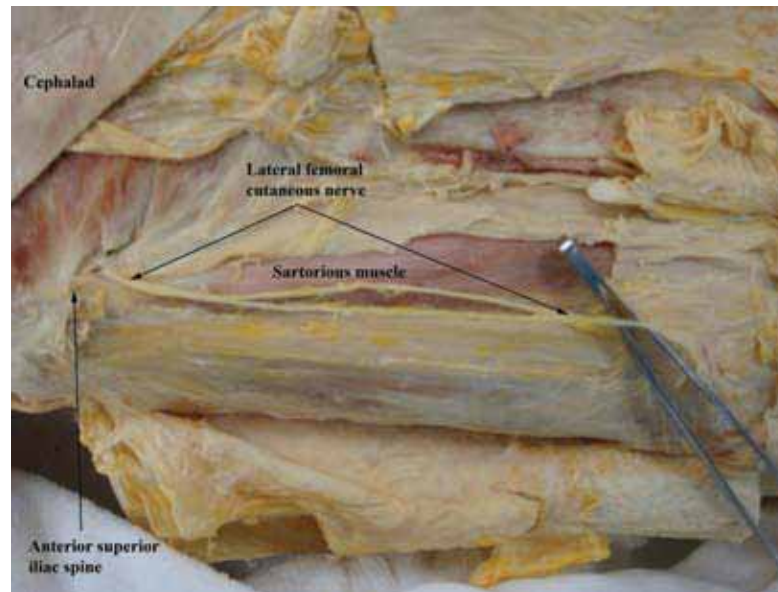
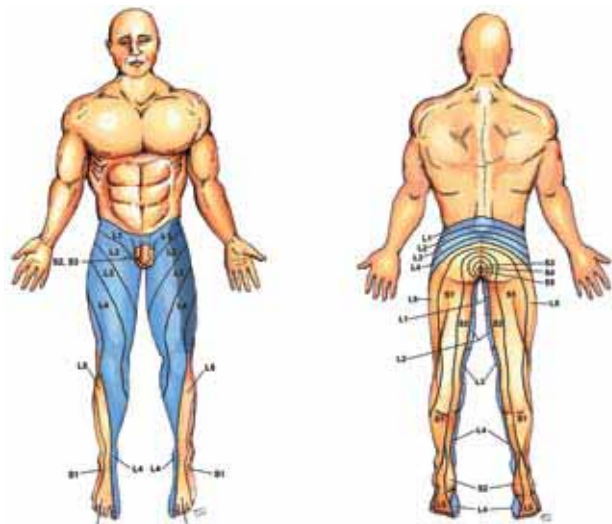


Figure 16-2

tionship of the nerve to the ASIS that anatomically defines this block (Figure 16-2).

Procedure. Because the LFC nerve is purely sensory, nerve stimulation is not typically used. Insert the needle perpendicular to all planes at a point 2 cm caudal and 2 cm medial to the ASIS. Advance the needle until a loss-of-resistance is felt; this signifies the penetration of the fascia lata. Inject 5 mL of local anesthetic at this location, then redirect the needle first medially and then laterally, injecting an additional 5 mL at each of these points (Figure 16-3).

Teaching Point. A useful procedure in both the pediatric and adult populations is a variation of the LFC nerve block, the fascia iliaca block. Like the femoral “3-in-1” block, the fascia iliaca block often fails to anesthetize the obturator nerve. To perform this procedure, draw a line from the ASIS to the pubic tubercle, and divide it into thirds. At the point where the lateral and middle thirds meet, draw a line 1 cm caudally, and insert the needle at this point. Two fascial “pops” will be felt, in-

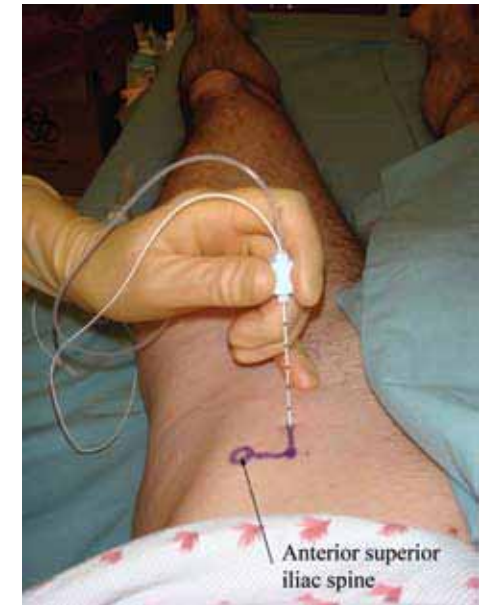


Figure 16-3

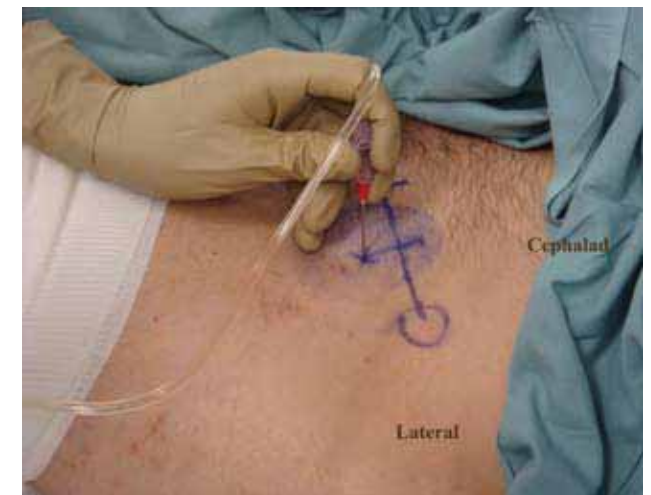


Figure 16-4

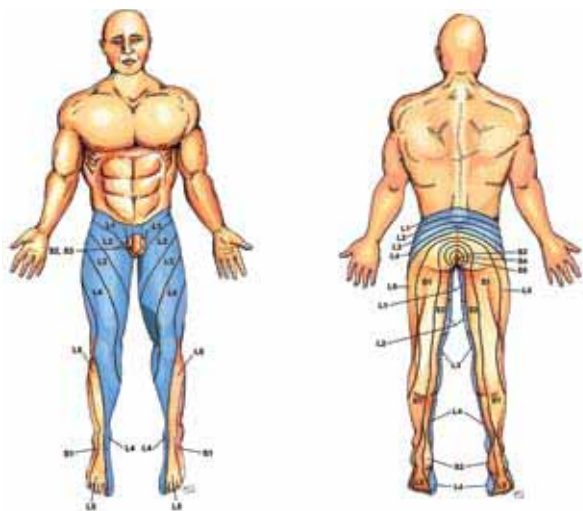
dicating the fascia lata and the fascia iliaca. After the second pop, drop the needle to a 30° angle, and advance it 1 cm. Slowly inject 30 mL of local anesthetic (Figure 16-4).

OBTURATOR NERVE BLOCK

Introduction. The obturator nerve is a mixed sensory and motor (mainly motor) nerve originating from the L2 through L4 anterior rami. It supplies sensory innervation to the medial aspect of the thigh (Figure 16-5) and motor innervation to the medial thigh muscles responsible for adduction of the leg (adductors longus, brevis, and magnus; gracilis and obturator externus muscles). In rare occasions an isolated obturator nerve block is performed; more often, the nerve may need to be blocked in conjunction with other anterior approaches to the lumbar plexus nerves, such as a femoral nerve block.

Anatomy. The obturator nerve travels as a single nerve from the lumbar region down toward the pelvis within the body of the psoas muscle. It crosses the pelvis vertically, exiting via the obturator foramen (immediately below the superior pubic

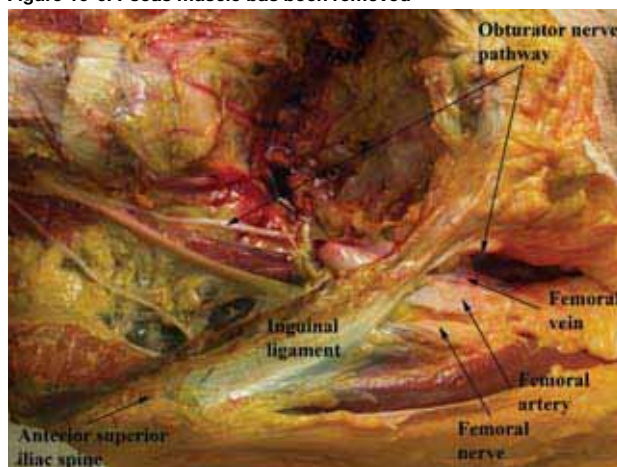
Figure 16-5. Dermatomes anesthetized with the obturator block (dark blue)



ramus), and divides into anterior and posterior terminal branches (Figure 16-6). The anterior branch supplies motor fibers to the anterior adductor muscles of the thigh as well as cutaneous fibers to the medial aspect of the thigh. The posterior branch, which lacks cutaneous fibers, supplies motor fibers to the deep adductor muscles of the thigh, as well as contributing to the innervation of the knee joint.

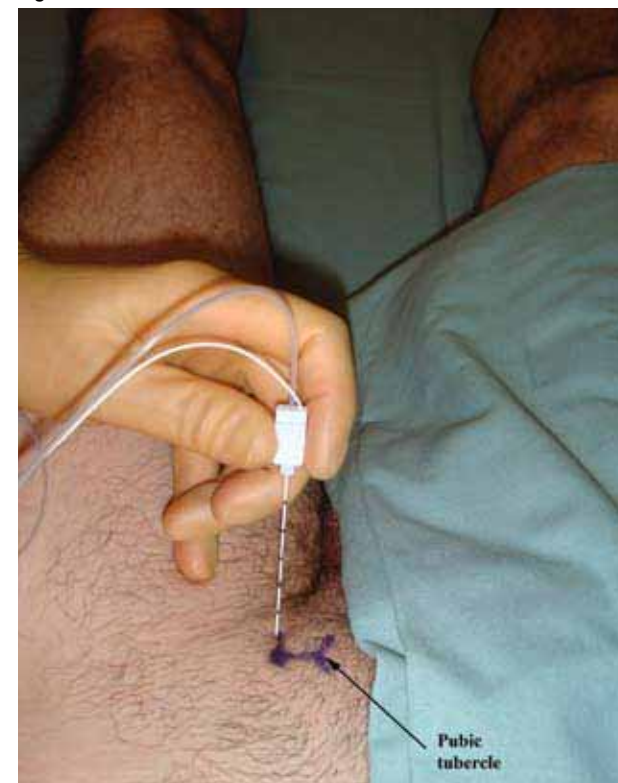
Procedure. Set the nerve stimulator to 1.5 mA. Place the patient in the supine position with the thigh partially abducted and the knee partially flexed. Palpate the pubic tubercle, and draw a line 2 cm lateral and 2 cm inferior to the tubercle. Insert a 5- to 10-cm stimulating needle perpendicular to the skin until it contacts the pubic ramus. Then redirect it posteriorly and slightly laterally to “walk off” the needle from the pubic ramus and into the obturator foramen. When the adductor muscles twitch, gradually decrease the stimulator until the twitch is still visible at 0.5 mA or less. Inject 5 to 10 mL of local anesthetic (Figure 16-7).

Figure 16-6. Psoas muscle has been removed



Teaching Point. The obturator nerve is often not blocked when a femoral or fascia iliaca block is administered. For less invasive surgeries, such as diagnostic knee arthroscopies, this may not be a problem; however, for more invasive lower extremity surgeries such as total knee replacements, the obturator nerve must be included in the lumbar plexus block. When the obturator nerve must be blocked, either a posterior approach to the lumbar plexus is utilized, or, if a femoral block is used, the obturator nerve is anesthetized separately.

Figure 16-7



Alternative Approach to the Obturator Nerve Block.

The anterior obturator branch supplies an articular branch to the hip and the anterior adductor muscles, and it provides cutaneous innervations to the lower medial aspect of the thigh. The posterior branch supplies the deep adductor muscles and often an articular branch to the knee joint. The accessory obturator nerve (L3 and L4) is present in a third of cases (8%–29% of human bodies) and sends a branch to the hip joint. When the accessory obturator nerve is not

present (71%–92% of cases), the posterior branch of the obturator nerve also sends a branch to the knee joint.

The inguinal interadductor obturator nerve block approach landmarks are the inguinal ligament, the femoral artery, and the long adductor muscle tendon. Draw a line immediately below the inguinal ligament from the medial edge of the femoral pulse to the medial border of the tendon of the long adductor muscle. Insert the needle at the midpoint of this line

(Figures 16-8 and 16-9). Insert a 21-gauge, 100-mm insulated needle slightly lateral and posterior, with a superior inclination. Carefully advance the needle until twitches of the anterior adductor muscles (anterior obturator branch) occur, and inject 5 to 7 mL of local anesthetic solution. Then advance the needle slowly a few millimeters in a slightly lateral direction until the posterior (major) adductor muscles twitch (posterior obturator branch), and inject another 5 to 7 mL of local anesthetic at this location.

Figure 16-8

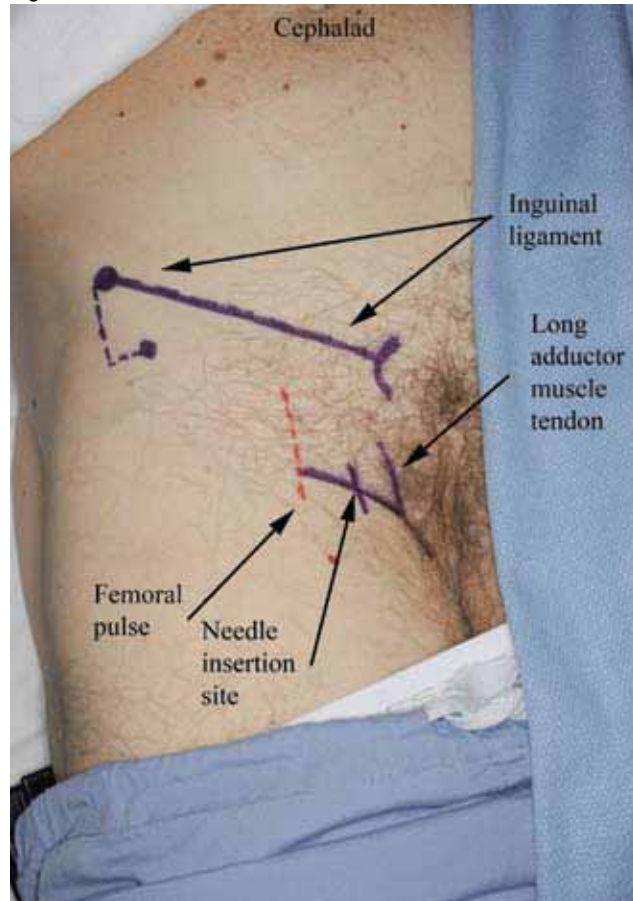
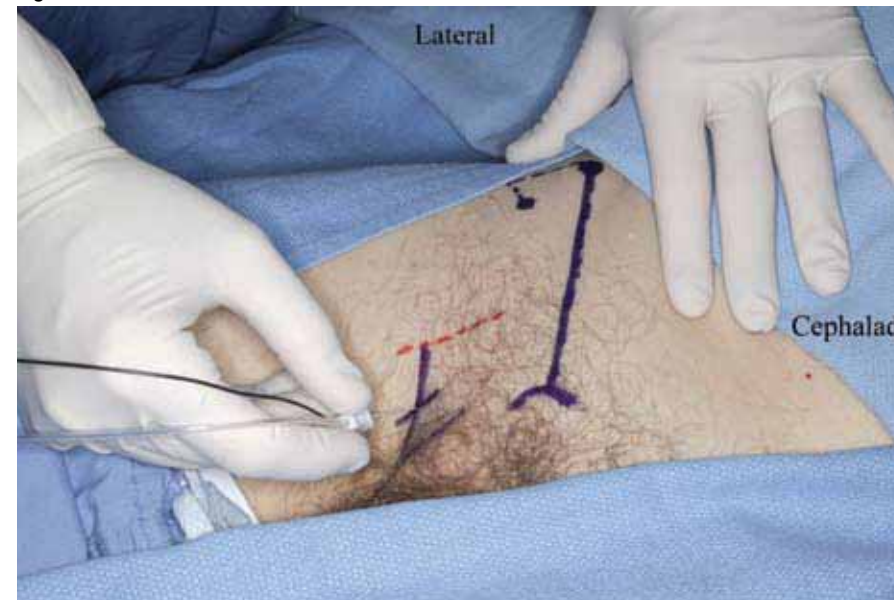


Figure 16-9



17. SCIATIC NERVE BLOCK: POSTERIOR AND ALTERNATIVE APPROACHES

INTRODUCTION

The sciatic nerve supplies motor and sensory innervation to the posterior aspect of the thigh as well as the entire lower leg, except for the medial leg, which is supplied by the saphenous nerve (the terminal branch of the femoral nerve). The sciatic nerve, formed from the anterior rami of spinal nerves L4–S3, is the largest nerve in the body. Because the sciatic nerve is so large, it can be blocked from several different locations along the lower extremity. Labat's sciatic nerve block is the classic approach, targeting the nerve in the gluteal region. Other sciatic nerve blocks include the anterior (Chapter 18) and lateral (Chapter 19) approaches, which allow the patient to remain in the supine position, as well as the parasacral and prone approaches. Raj's subgluteal approach is performed in the supine position with the hip flexed.

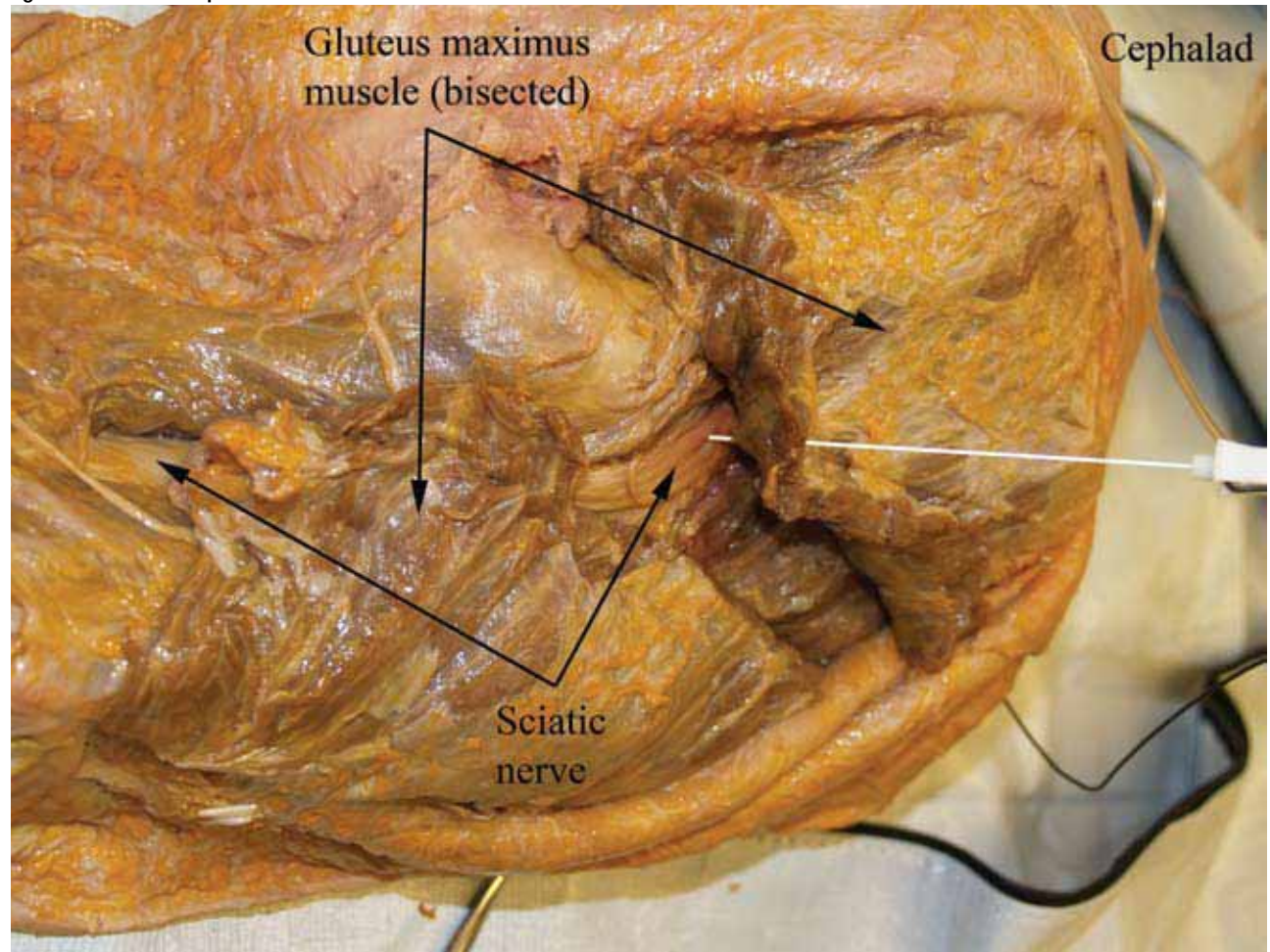
Sciatic nerve blocks require adequate set-up because this large nerve resists local anesthetic penetration, leading to longer block onset times. For complete anesthesia of the leg below the knee the saphenous nerve must also be blocked, either directly or via a femoral nerve block.

ANATOMY

This anatomy description applies to all approaches of the sciatic nerve block (through Chapter 19). The sciatic nerve arises from the ventral rami of L4 through S3, which forms most of the sacral plexus (L4–S4). The sciatic nerve is actually two nerves in close apposition, the tibial and common peroneal

(fibular) nerves. These nerves usually do not separate until the mid-thigh, although separation as proximal as the pelvis occurs in about 12% of patients. The sciatic nerve leaves the pelvis via the greater sciatic foramen, travels under the gluteus maximus (Figure 17-1), and continues distally

Figure 17-1. Dissected proximal sciatic nerve



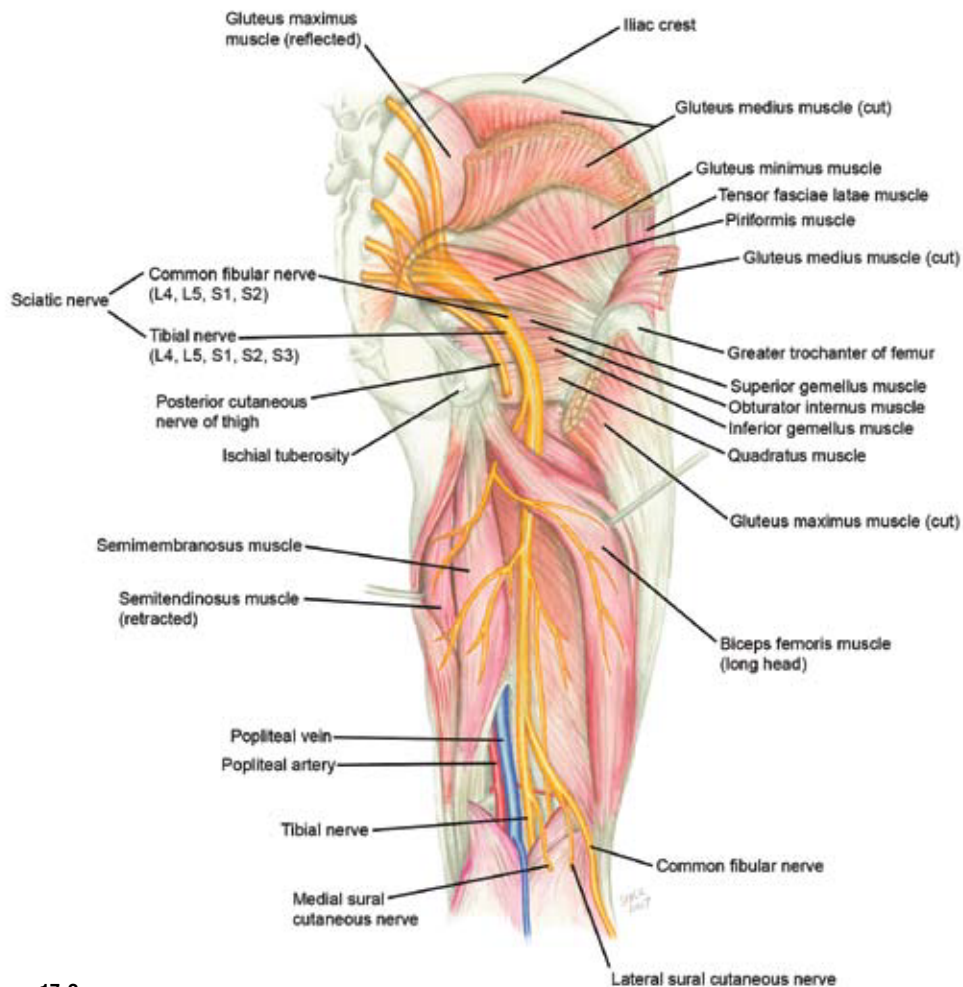


Figure 17-2

toward the posterior thigh between the greater trochanter and ischial tuberosity (Figure 17-2). Although the sciatic nerve does not innervate any muscles in the gluteal region, it does supply motor innervation

to the posterior thigh muscles as well as all muscles of the leg and foot. It also provides sensory innervation to the skin of most of the leg and foot (Figure 17-3).

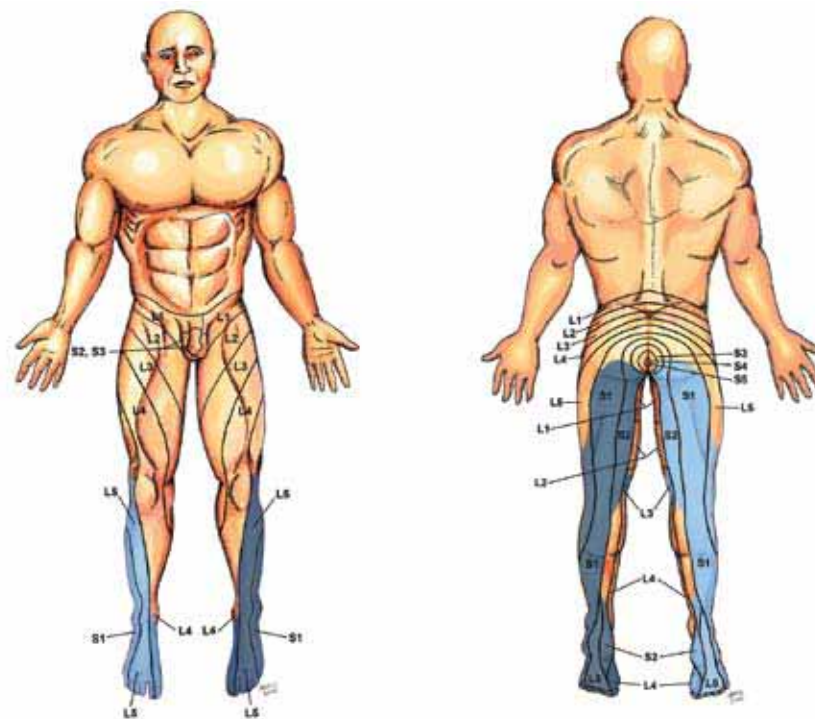


Figure 17-3. Dermatomes anesthetized with a proximal block of the sciatic nerve (dark blue)

Teaching Point. Of the various approaches to the sciatic nerve, Labat's posterior technique (first described in 1924) has the advantage of also blocking the posterior femoral cutaneous nerve. This nerve provides sensory innervation to the gluteus and uppermost medial and posterior thigh, and blocking it is important when thigh tourniquets are used for lower extremity procedures of long duration.

PROCEDURE

Landmarks. In Labat's classic approach, the patient is placed in lateral decubitus position (operative side up), and the leg is flexed at the knee. If the patient is unable to flex the leg, the leg should be extended at the hip as far as possible without producing patient discomfort. Draw a line between the greater trochanter to the posterior superior iliac spine (PSIS). Draw a second line from the greater trochanter to the patient's sacral hiatus (Winnie's modification). Determine the point of initial needle insertion by drawing a line perpendicular from the midpoint of the first line to its intersection with the second line. A fourth line can be drawn along the "furrow" formed by the medial edge of the gluteus maximus muscle and the long head of the biceps femoris muscle (Figure 17-4). The furrow represents the course of the sciatic nerve toward the lower leg. The triangle formed by the first, second, and fourth lines further defines initial needle placement, and subsequent adjustments of the needle within the triangle can improve success at sciatic nerve stimulation.

Needles

- 21-gauge, 10-cm insulated needle for the majority of patients. For obese patients, 15-cm needles may be needed.
- 18-gauge, 10-cm insulated Tuohy needle for catheter placement. Insert catheters 5 cm beyond the needle tip.

Stimulation. Set the nerve stimulator initially at 1.0 to 1.5 mA. Insert the needle perpendicular to all planes (Figure 17-5). Stimulation of the patient's gluteus maximus muscle is often encountered just before sciatic nerve stimulation. Patients often find this uncomfortable, and the needle should be advanced through gluteus stimulation without pause. Successful needle placement in proximity to the sciatic nerve is observed with plantar flexion/inversion (tibial nerve) or dorsiflexion/eversion (common peroneal nerve) with 0.5 mA or less of current. Occasionally, hamstring muscle twitching will be noted, which suggests the needle tip has

been placed too medial. Slight adjustment of the needle tip laterally will usually result in successful localization of the sciatic nerve.

Local Anesthetic. In most adults, 20 to 30 mL of local anesthetic is sufficient to block the plexus.

Teaching Points. The posterior approach to the sciatic nerve combined with a lumbar plexus block provides complete anesthesia of the lower extremity (a femoral nerve block often misses the obturator nerve). Labat's approach is well suited for continuous catheter techniques.

Studies of this posterior approach have demonstrated that plantar flexion of the foot (tibial nerve stimulation) resulted in a shorter onset time and more frequent success of the block versus dorsiflexion (common peroneal nerve).

The addition of the furrow line can be especially useful in obese patients, when palpation of traditional landmarks is difficult.

Figure 17-4. Landmarks for posterior approach to the sciatic nerve

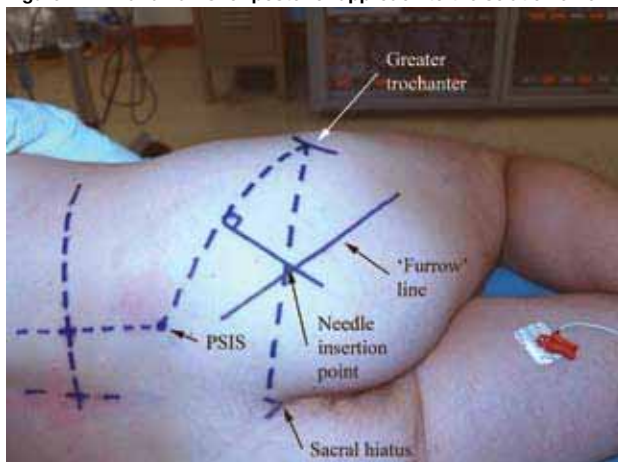
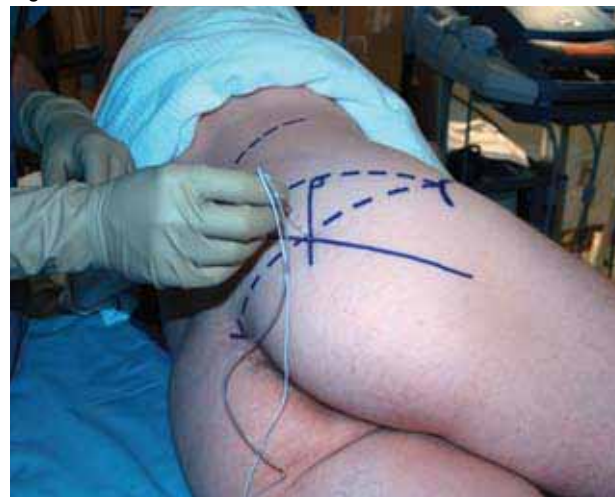

Figure 17-5



BLOCK WITH ULTRASOUND PROBE

Probe. Low frequency (2–5 MHz), curved, or high frequency (5–12 MHz), linear (a linear probe is used in Figures 17-6 to 17-8).

Probe Position. With the patient positioned in the lateral decubitus position, operative side up, draw a line connecting the greater trochanter with the ischial tuberosity. The sciatic nerve bisects the midpoint of this line. Place the probe directly on the line, which is perpendicular to the sciatic nerve, to allow a transverse view of the nerve (Figure 17-6). The ischial tuberosity (medial) and the greater trochanter (lateral) should be visible as hyperechoic curved structures on either side of the ultrasound screen. The sciatic nerve, which appears as a hyper-echoic elliptical structure, is located between these two landmarks (Figure 17-7).

Figure 17-6

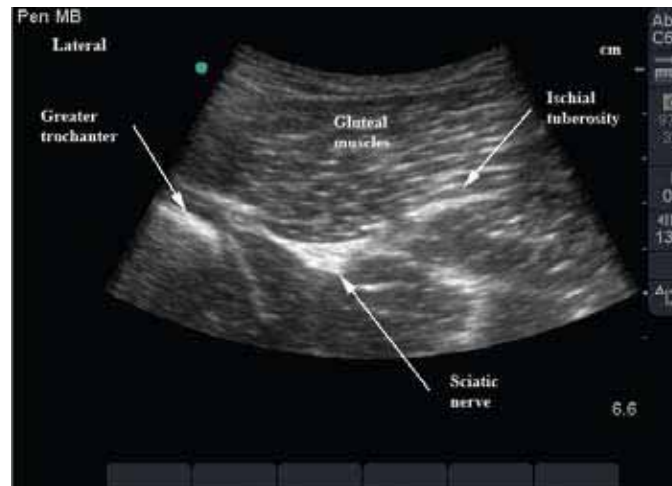
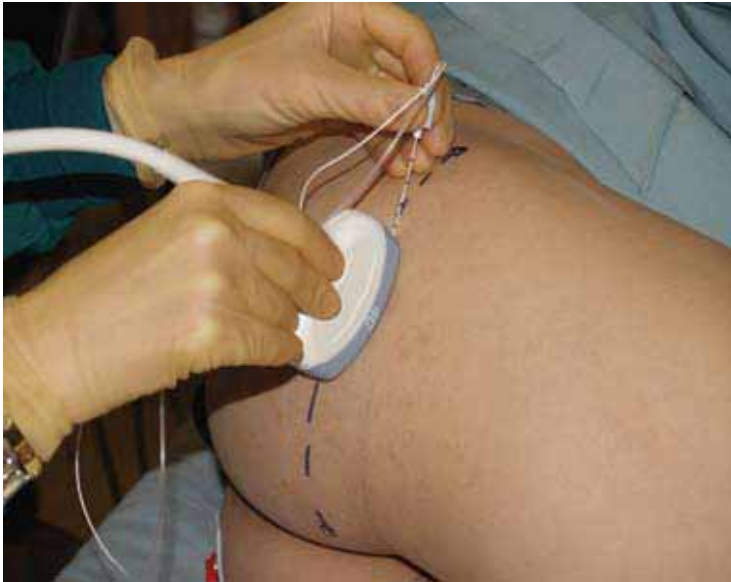


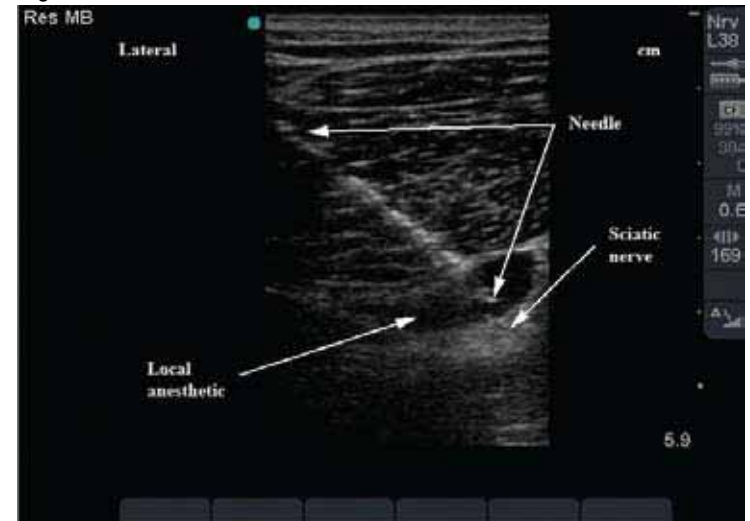
Figure 17-7

Teaching Point. To easily identify the sciatic nerve, use the low-frequency curved probe to identify both the greater trochanter and ischial tuberosity. If only one is visible, increase the depth on the ultrasound monitor to allow the other landmark to be observed. Once the sciatic nerve is identified, the depth can then be decreased to focus on the nerve only. A high-frequency linear probe can be used at this point to increase nerve resolution during insertion of the needle and injection of local anesthetic.

Approach. Insert the needle at the lateral aspect of the ultrasound probe for an in-plane approach. Lateral needle insertion is preferred to medial insertion because the inferior gluteal artery is located medial to the nerve and may interfere with needle advancement.

Injection. At this level, the sciatic nerve is located within a discrete space (the sub-gluteal space) located between the anterior surface of the gluteus maximus muscle and the posterior surface of the quadratus femoris muscle. If proper needle placement is achieved, the injection and spread of 20 to 30 mL of local anesthetic often surrounds the nerve, which is optimal. If this does not occur, the needle can be adjusted to achieve local spread all around the target nerve (Figure 17-8).

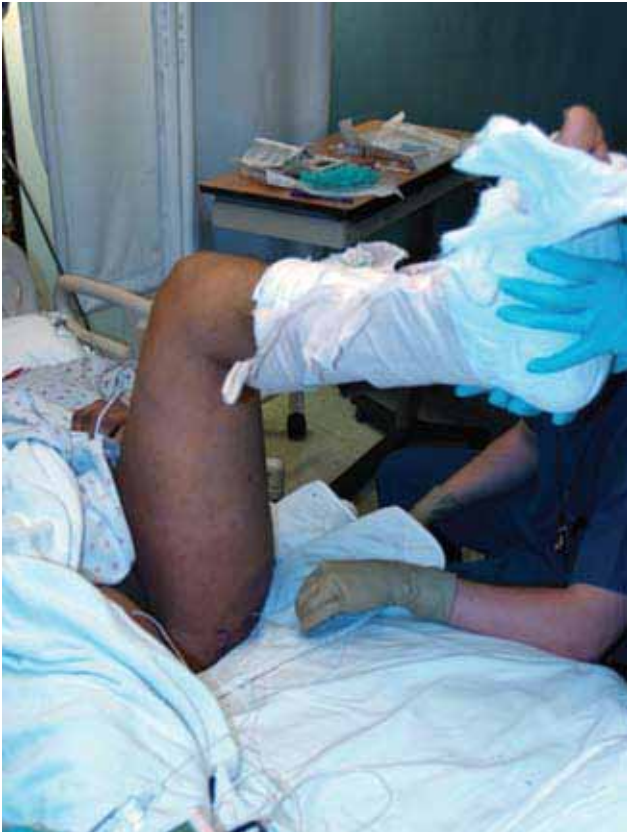Figure 17-8



ALTERNATIVE APPROACHES TO THE SCIATIC NERVE BLOCK

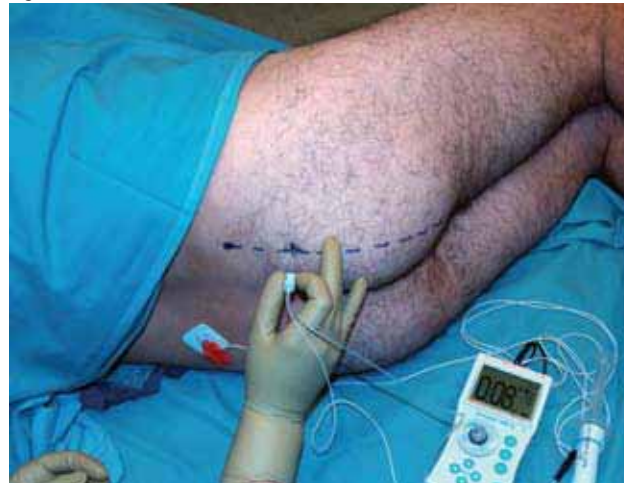Raj Technique. This posterior approach is unique because the patient remains in the supine position. The hip and knee are both flexed at a 90° angle, with the foot resting on a Mayo stand or held up by an assistant. By flexing the hip in this way, the gluteal muscles are flattened and the sciatic nerve becomes more superficial. Palpate the greater trochanter and ischial tuberosity, and draw a line connecting them. Insert a 10-cm needle at the midpoint of this line, at a perpendicular angle to the skin (Figure 17-9).

Figure 17-9



Parasacral Technique. This technique is the most proximal approach to the sciatic nerve, targeting the nerve in the greater sciatic foramen. Patients are placed in the lateral decubitus position. This technique typically blocks the obturator nerve, enabling the entire lower extremity to be anesthetized with a sciatic and femoral nerve block (without a lumbar plexus block). Landmarks are the PSIS and the ischial tuberosity. Draw a line connecting these two points, and insert a 10-cm needle 6 cm caudal to the PSIS. If bone is contacted, “walk off” the needle caudally until it advances through the sciatic foramen. The nerve is usually found at a depth of 6 to 7cm (Figure 17-10).

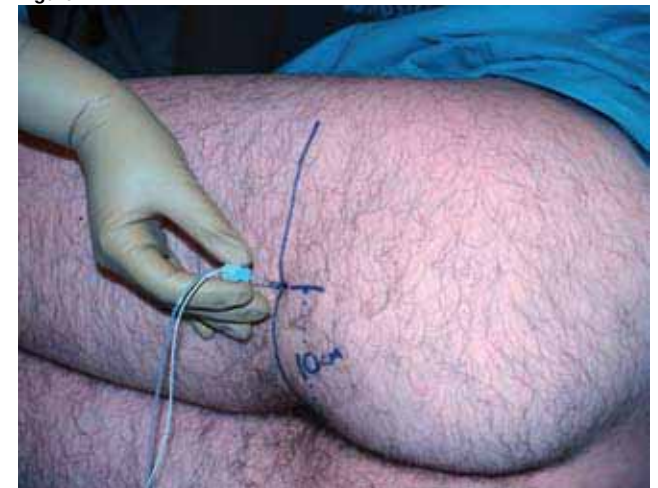
Figure 17-10



Midline Technique. Franco has described two techniques that target the sciatic nerve 10 cm lateral to the midline of the pelvis. The first, a midgluteal approach, is performed with the patient in the prone position. Insert a 10-cm needle at the midpoint of the intergluteal sulcus 10 cm lateral to the midline. Advance the needle parallel to midline and perpendicular to the table. If no response is elicited, adjust the needle slightly medial or lateral.

The second technique is a subgluteal approach with the patient in the lateral decubitus position, flexed at the hips and knees (as if performing a lateral neuraxial technique). Insert the needle in the subgluteal fold 10 cm from the intergluteal sulcus, directing it parallel to the bed (Figure 17-11).

Figure 17-11



18. SCIATIC NERVE BLOCK: ANTERIOR APPROACH

INTRODUCTION

The anterior approach to the sciatic nerve block is particularly useful in patients needing lower extremity anesthesia who are unable to assume the lateral decubitus position (Figure 18-1). This technique is a deep block that requires a 15-cm needle in adults. It can be associated with more patient discomfort than other approaches, and the location of the femoral artery anterior to the sciatic nerve in this position increases the risk of inadvertent arterial puncture. Continuous peripheral nerve catheters, although possible, are typically avoided using this approach.

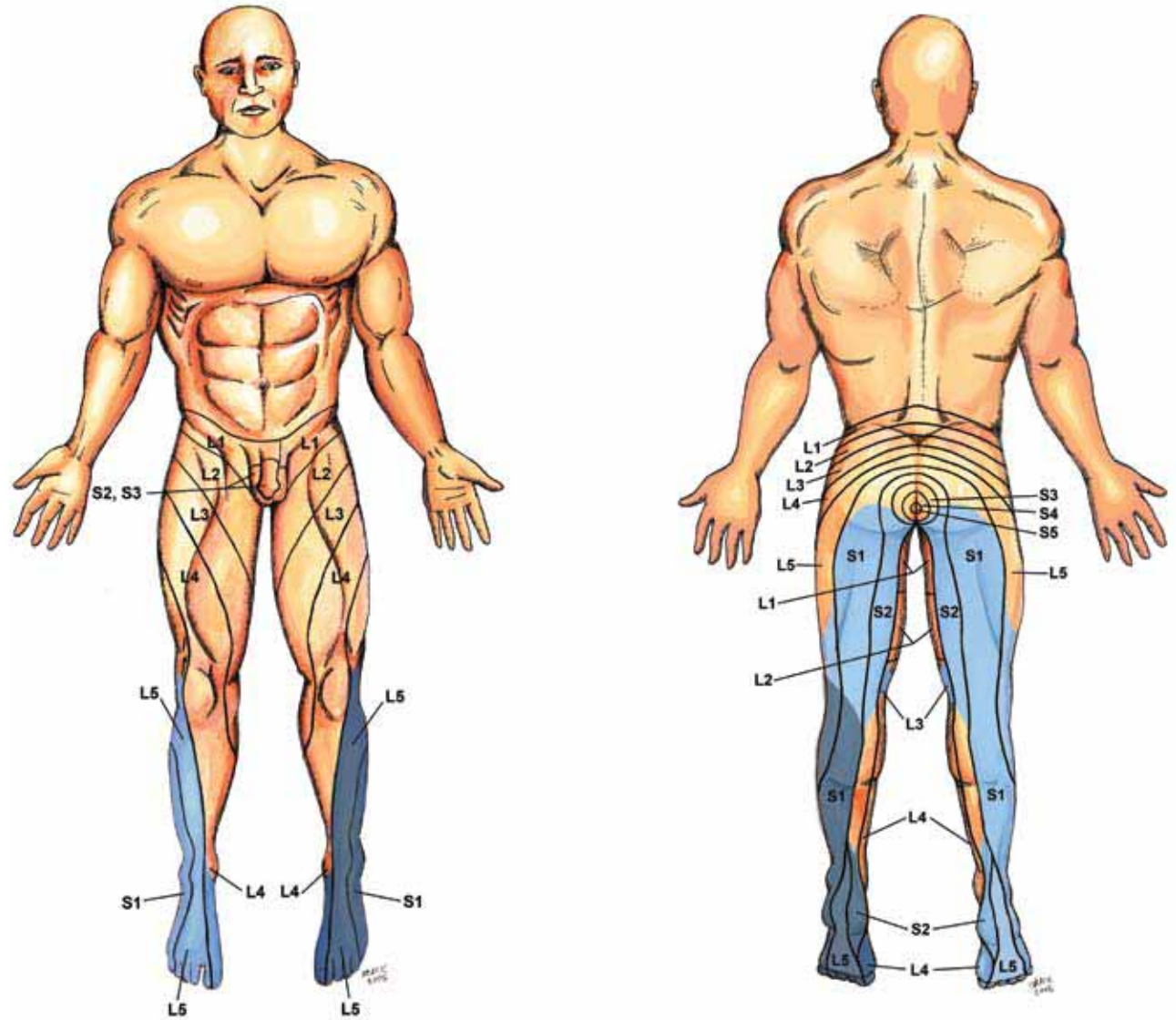


Figure 18-1. Dermatomes anesthetized with the anterior sciatic nerve block (dark blue)

PROCEDURE

Landmarks. With the patient positioned supine, draw a line from the anterior superior iliac spine to the pubic tubercle, and divide the line into thirds. Draw a second line, parallel to the first, medial from the cephalad aspect of the greater trochanter. Then, draw a third line perpendicular from the medial third of the first line to intersect the second line. The intersection, which will be located over the lesser trochanter of the femur, represents the point of initial needle insertion (Figures 18-2 and 18-3). Recent studies have suggested that the lesser trochanter obstructs the route to the sciatic nerve when the leg and foot are in neutral position; however, internal rotation of the leg by 45° exposes the nerve and allows the needle to pass through unobstructed.

Needles

- 21-gauge, 15-cm insulated needle.
- 18-gauge, 15-cm insulated Tuohy needle for catheter placement. Because of the depth of the block, catheters are not recommended; if used, they should be inserted 5 cm beyond the needle tip.

Stimulation. Set the nerve stimulator initially at 1.5 mA, and advance the needle perpendicular to all planes. If bone is contacted, withdraw the needle slightly and rotate the leg internally. Then advance the needle in the same plane as before until a twitch is elicited. If the needle again contacts bone, the initial insertion site may be distal to the lesser trochanter. In this case, slightly withdraw the needle, externally rotate the leg 45°, and then readvance the needle; this should allow a stimulation response to be elicited. Plantar flexion/inversion or dorsiflexion/eversion is sought at a current of 0.5 mA or less. Stimulation of the hamstring muscle suggests the needle is deep to the nerve (Figure 18-4).

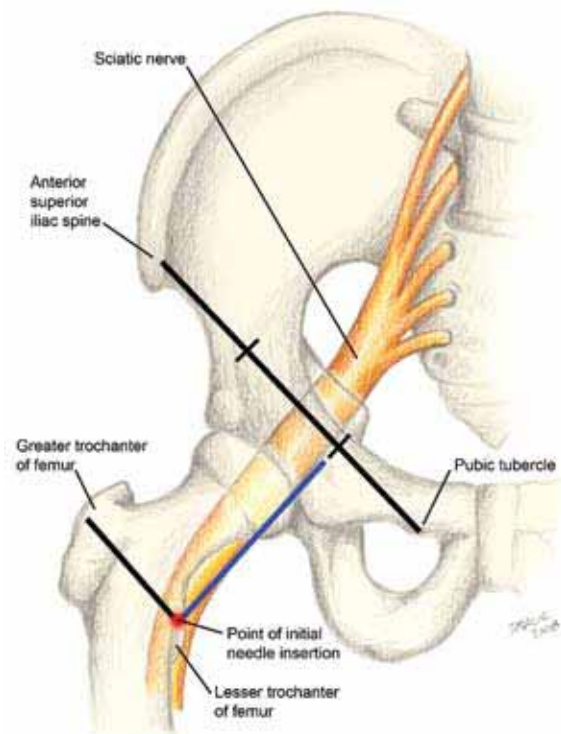


Figure 18-2. Landmarks for anterior sciatic nerve block

Figure 18-3

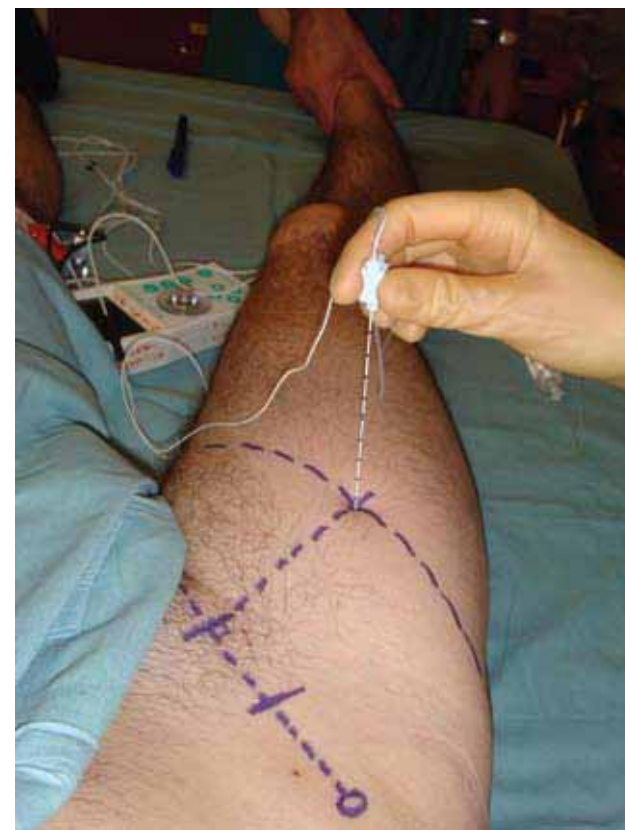
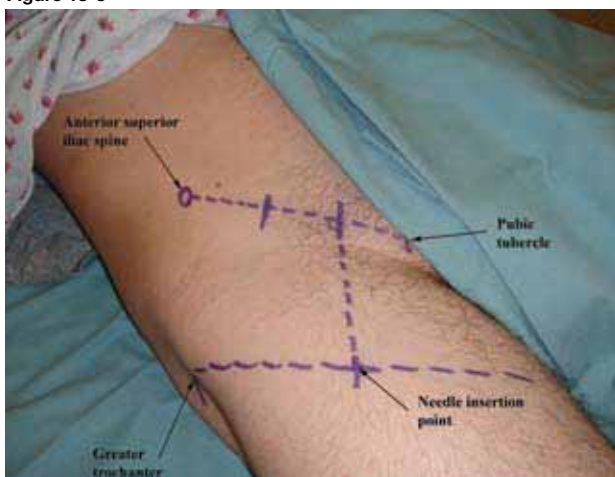


Figure 18-4

Local Anesthetic. In most adults, 30 to 40 mL of local anesthetic is sufficient.

Teaching Points. These blocks depend on local anesthetic volume for success. This approach does not block the posterior cutaneous nerve of the thigh, which may be a problem if a thigh tourniquet is used. A complete block of the lower leg requires the addition of a saphenous nerve block.

19. SCIATIC NERVE BLOCK: LATERAL APPROACH

INTRODUCTION

Like the anterior approach, the lateral approach to the sciatic nerve has the advantage of being performed with the patient in the supine position. Both approaches anesthetize the same dermatomes (see Figure 18-1). The lateral approach may be technically easier than the anterior block, and the needle depth is shallower, making it more comfortable for the patient. This block is typically done at a more distal location immediately cephalad to the popliteal fossa (Figure 19-1). Because this block is more distal than the posterior or anterior approaches to the sciatic nerve, the anesthetist must take care to ensure adequate anesthesia and analgesia of both components of the sciatic nerve (tibial and common peroneal). For this reason, larger volumes of local anesthetic are used to ensure adequate distribution.

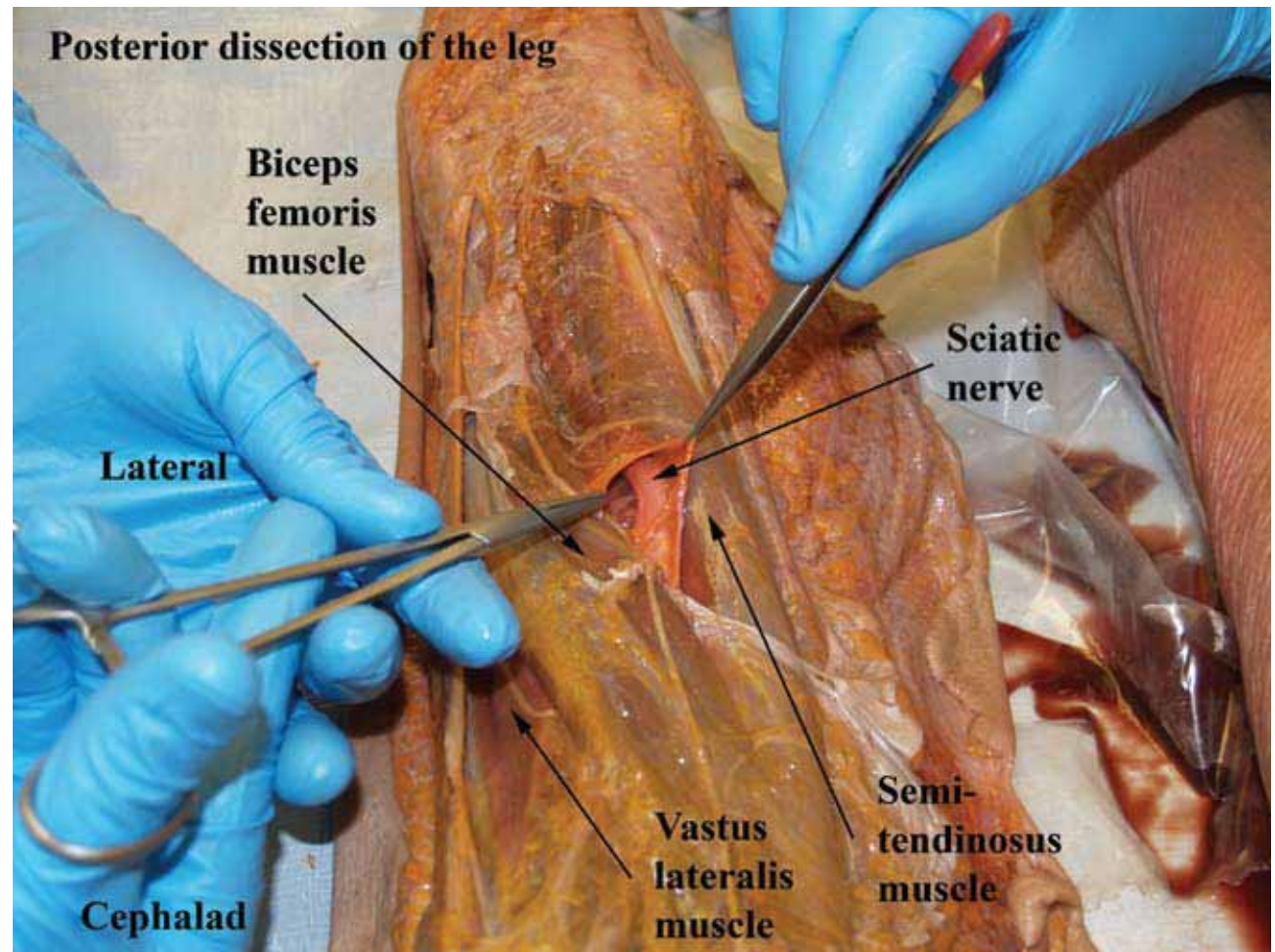


Figure 19-1

PROCEDURE

Landmarks. Palpate the popliteal crease and measure a distance of 10 cm cephalad in the groove between the vastus lateralis and the biceps femoris muscles of the thigh (Figure 19-2). If these landmarks are difficult to identify, flex the patient’s leg at the knee to further delineate the anatomy.

Needles

- 21-gauge, 10-cm insulated needle.
- 18-gauge, 10-cm insulated Tuohy needle for catheter placement. Catheters introduced 5 cm beyond the needle tip.

Figure 19-2

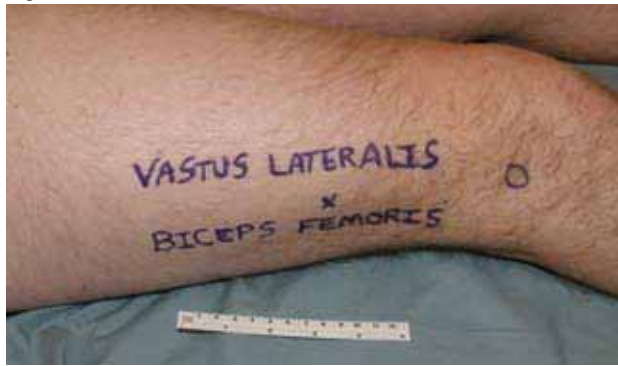
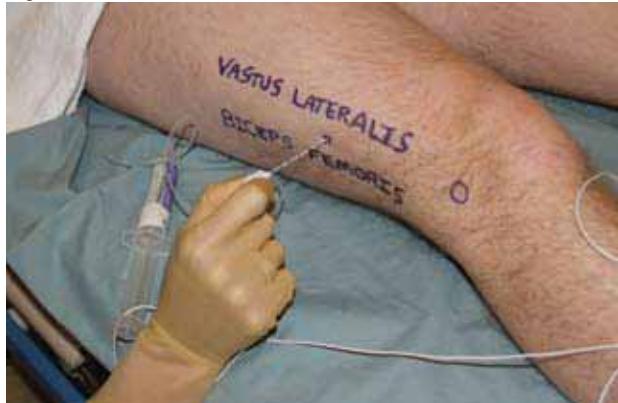


Figure 19-3

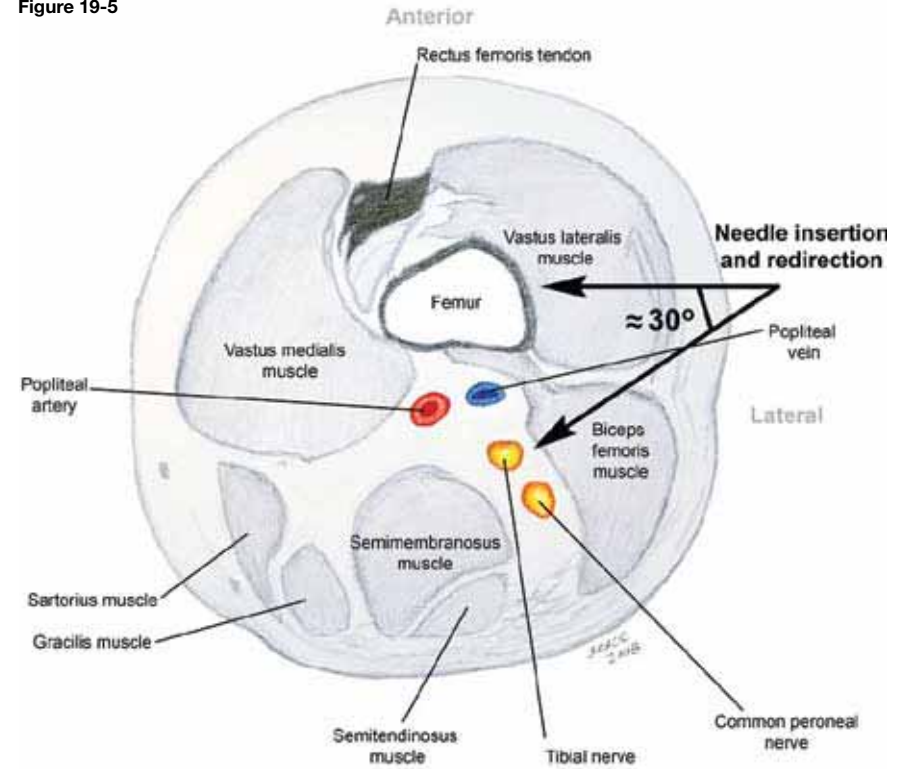


Stimulation. Set the nerve stimulator at 1.2 to 1.5 mA. After sterile preparation of the area, introduce needle and advance it in a horizontal plane until the femur is contacted (Figure 19-3). Upon contact, withdraw the needle back toward the skin and redirect it approximately 30° posterior to the original insertion site, advancing slowly until a stimulation pattern appears (Figures 19-4 and 19-5). The nerve is typically 1 to 2 cm beyond the point of initial femur contact. Studies have demonstrated that plantar flexion, as opposed to dorsiflexion, of the foot is a more desirable twitch to obtain with the lateral approach to the sciatic nerve, resulting in a more complete sensory block. Once plantar flexion is established, turn the stimulator current down to 0.5 mA and inject the local anesthetic.

Figure 19-4

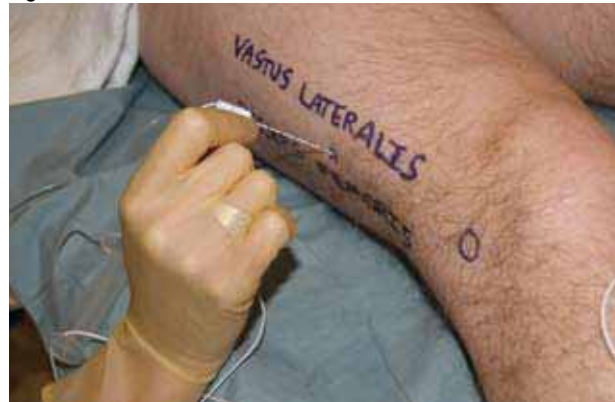

Figure 19-5



Local Anesthetic. In most adults, 40 mL of local anesthetic is sufficient.

Teaching Points. For the needle to gain proximity to the sciatic nerve from this approach, it must pass through the biceps femoris muscle. Local stimulation of this muscle is often seen, and advancing the needle tip further will cause this twitch to stop and foot or toe twitching to start. If stimulation of the vastus lateralis muscle is observed, the needle tip is too anterior and should be withdrawn toward skin and repositioned in a more posterior plane.

BLOCK WITH ULTRASOUND PROBE

Probe. Mid-frequency (5–12 MHz), linear.

Probe Position. Place the patient in the supine position with the foot and ankle resting on a stack of blankets; this will allow enough room to place the probe directly beneath the leg. Position the probe approximately 8 cm proximal and parallel to the popliteal crease (with a transverse view; Figure 19-6). Scan in the cephalad and caudad directions until the sciatic nerve is identified. Often, the popliteal artery is identified and can be used as a landmark for sciatic nerve location—the nerve is lateral to the artery. The sciatic nerve is seen as a round, hyperechoic structure (Figure 19-7). If two smaller round, hyperechoic structures are viewed, the probe is distal to the split of the tibial and peroneal nerve components and must be moved to a more proximal location on the leg.

Approach. Insert the 21-gauge needle at the lateral aspect of the ultrasound probe, allowing visibility of the entire needle shaft. *Note: needle adjustments seen*

Figure 19-6

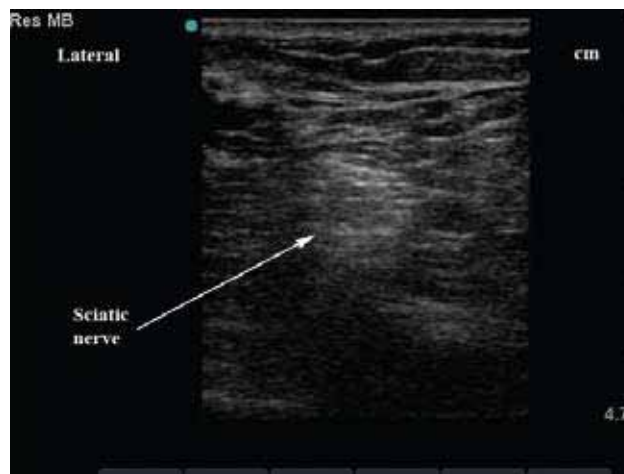
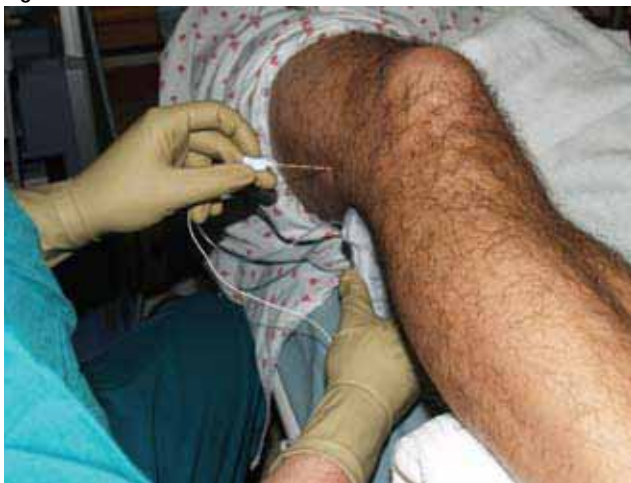
Figure 19-7

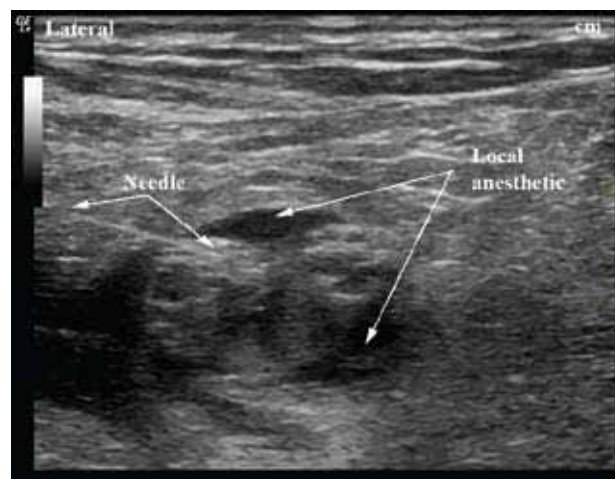


Figure 19-8

on the ultrasound screen are the reverse of the operator's hand movement, which can be confusing.

Injection. Inject 30 to 40 mL of local anesthetic, so that the sciatic nerve is completely embedded in a hypoechoic ring (Figure 19-8). If circumferential spread is incomplete, withdraw the needle and redirect it to contact any missed areas.

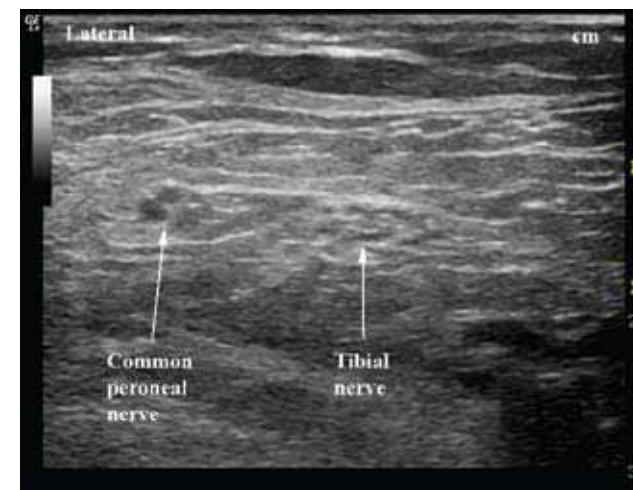

Figure 19-9

Teaching Points. To help identify the sciatic nerve, begin with probe placement just above the popliteal crease. Often, the tibial and peroneal components can be viewed as two hyperechoic round structures (Figure 19-9). Continue sliding the probe in the cephalad direction, and the two smaller structures will merge into the single structure of the sciatic nerve. This technique ensures that probe placement is proximal to the split of the nerve.

The low-frequency, curved probe is difficult to manipulate behind the leg. Usually, a linear, higher frequency probe is sufficient for adequate visualization of the sciatic nerve.

20. POPLITEAL NERVE BLOCK

INTRODUCTION

The popliteal nerve block is a block of the sciatic nerve in the popliteal fossa with the patient in the prone position. The block is ideal for surgeries of the lower leg, particularly the foot and ankle. It anesthetizes the same dermatomes as both the anterior and lateral approaches to the sciatic nerve (Figure 18-1). Unlike more proximal approaches to the sciatic nerve, the popliteal nerve block preserves hamstring function, allowing easier ambulation of the postoperative patient. Even so, patients should be cautioned against bearing weight on the blocked lower extremity for 24 hours, as with all blocks of the sciatic nerve.

ANATOMY

The popliteal fossa is bordered laterally by the biceps femoris muscle and medially by the semimembranosus muscle. It is the site where the sciatic nerve splits into its two major components, the tibial and common peroneal nerves (Figure 20-1). To avoid an incomplete nerve block, the needle entry site must be proximal to the splitting of these two nerves (Figure 20-2). Studies have demonstrated that the needle entry point should be 10 cm from the popliteal crease to optimize needle placement. Because of the possibility of needle placement distal to the bifurcation of the two nerves, a larger volume of local anesthetic is typically used with this approach (40–45 mL).

The sciatic nerve supplies motor innervation to the entire lower leg via the posterior tibial nerve, superficial and deep peroneal nerves, and the sural nerve. The sural nerve is sensory only. These major branches of the sciatic nerve also supply sensory innervation to the lower leg, except for the medial inner strip, which is supplied by the saphenous nerve (a branch of the femoral nerve).

Teaching Points. Vascular puncture and intravascular injection are rare with this block because the nerve is superficial to the popliteal artery and vein at this location.

For a complete sensory blockade of the lower extremity, the saphenous nerve must also be blocked, which can be done at the level of the popliteal fossa (see Chapter 21).

Figure 20-1

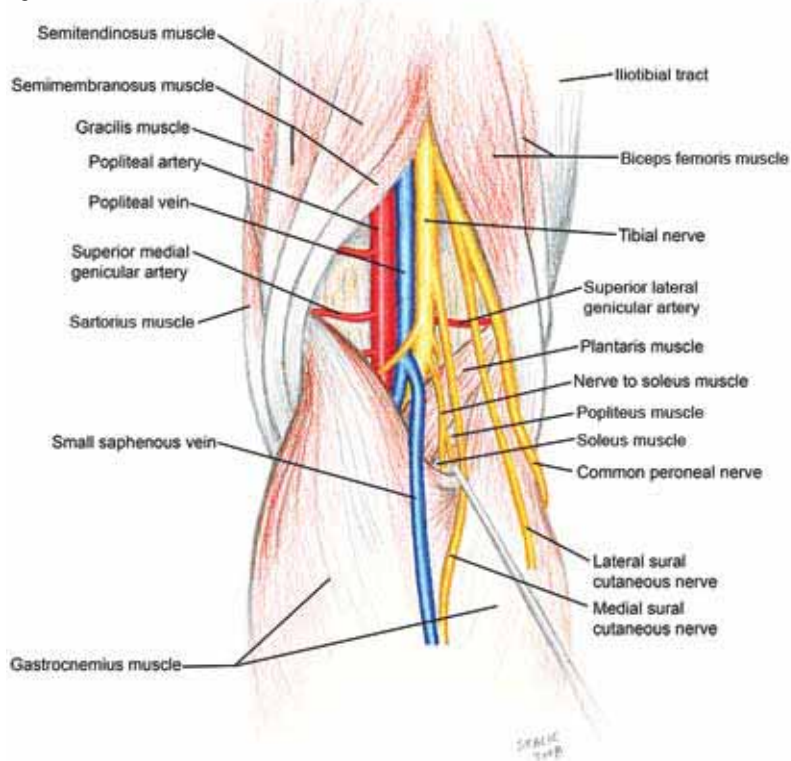
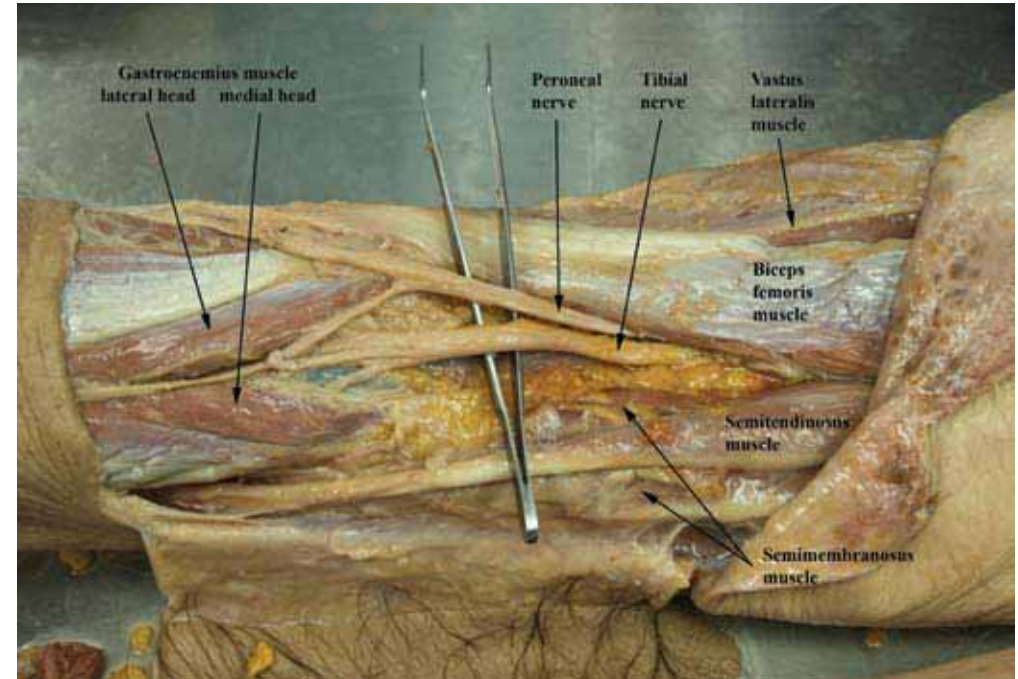


Figure 20-2



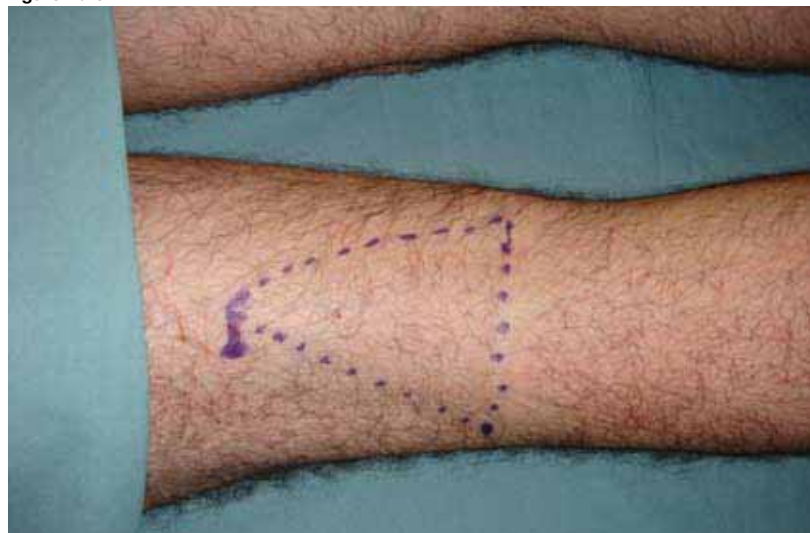
PROCEDURE

Landmarks. Place the patient in the prone position with the operative leg supported below the knee. The knee should be slightly bent and the foot resting freely above the bed. The popliteal fossa can be accentuated by having the patient bend the knee against resistance. The popliteal triangle is formed medially by the semitendinosus and semimembranosus muscles, laterally by the biceps femoris muscle, and at the base by the popliteal crease. Needle insertion should be at least 7-cm superior to the popliteal crease and approximately 1 cm lateral to the apex of the popliteal triangle (Figure 20-3). Insert the needle at a 45° to 60° angle to the skin in a cephalad direction (Figure 20-4).

Needles

- 21-gauge, 10-cm insulated needle.
- 18-gauge, 10-cm insulated Tuohy needle for catheter placement. Catheters inserted a minimum of 3 to 5 cm beyond the needle tip.

Figure 20-3



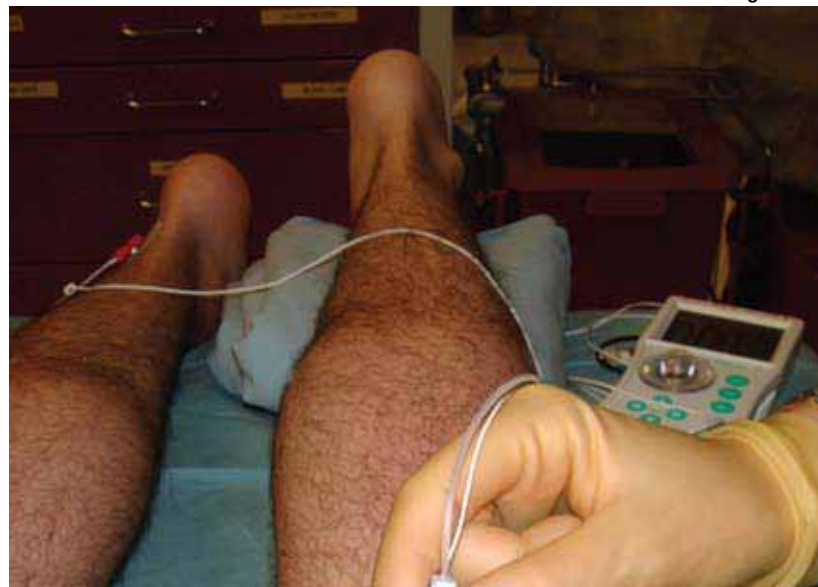Stimulation. Set the nerve stimulator initially between 1.0 and 1.2 mA. Inversion of the foot indicates stimulation of the tibial and deep peroneal nerves, eversion of the foot indicates stimulation of the superficial peroneal nerve, plantar flexion indicates stimulation of the posterior tibial nerve, and dorsiflexion indicates stimulation of the deep peroneal nerve. Studies have shown that inversion of the foot leads to the best sensory and motor block, and dorsiflexion of the foot is second best (in contrast to more proximal sciatic nerve blocks, where the nerve components are in close proximity, allowing injection of local anesthetic on any twitch in the sciatic distribution).

Occasionally, a local twitch of the biceps femoris muscle is elicited after needle insertion, indicating that needle placement is too lateral and must be redirected slightly medial. Conversely, if local twitching of the semitendinosus and semimembranosus muscles occurs, needle placement is too medial and must be redirected slightly more lateral.

Local Anesthetic. In most adults, 35 to 45 mL of local anesthetic is sufficient to block the nerves.

Teaching Points. If no motor response is obtained with initial stimulation, subsequent attempts should be made more lateral (rather than more medial, which causes a risk of inadvertent vascular penetration). The anesthesiologist should attempt to achieve stimulation in a position as cephalad in the popliteal fossa as possible, making it less likely that the sciatic nerve has divided at that point, and improving block success.

Figure 20-4

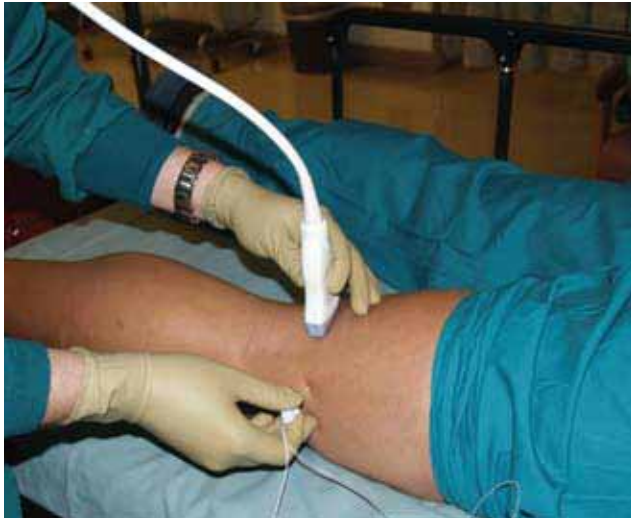

BLOCK WITH ULTRASOUND PROBE

Probe. High frequency (5–12 MHz), linear.

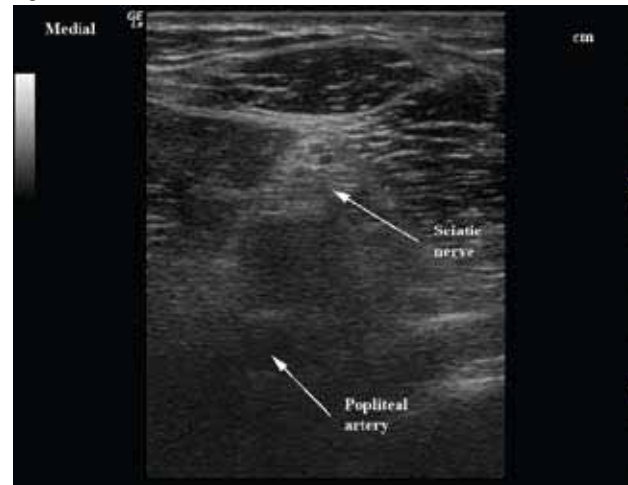Probe Position. A transverse plane (parallel to the popliteal crease) gives the best image of the sciatic nerve (Figure 20-5). Depending upon the location of the split of the sciatic nerve into its tibial and peroneal components, either one large or two smaller round hyperechoic structures will be seen. If the popliteal artery is visualized, the nerve will be lateral to the artery (Figure 20-6).

Figure 20-5



Approach. As with most ultrasound-guided blocks, an in-plane or out-of-plane approach is possible. Because the in-plane technique allows for complete visualization of the needle, it is the preferred approach at Walter Reed Army Medical Center. With the probe parallel to the popliteal crease and at a level proximal to the nerve split, insert the needle at the lateral aspect of the probe and advance it toward the nerve. After the sciatic sheath is penetrated and the nerve is stimulated, inject 40 mL of local anesthetic. Repositioning the needle may be necessary to ensure complete coverage of the nerve.

Figure 20-6

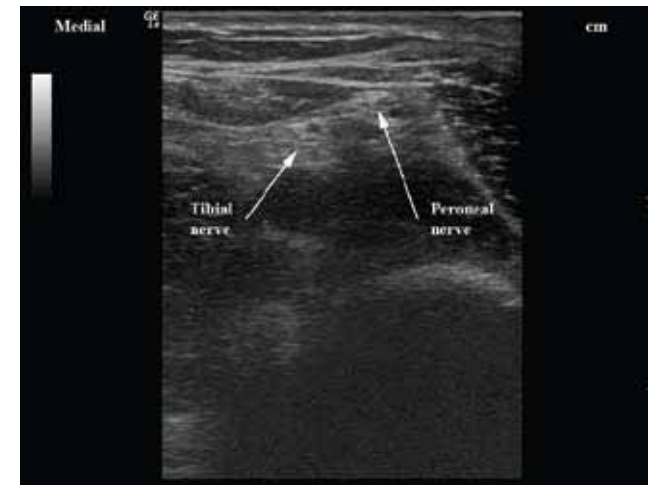

Teaching Points. For block success, the local anesthetic must be deposited proximal to the splitting of the sciatic nerve. By placing the probe at the popliteal crease and scanning the leg in the cephalad direction, both the tibial and peroneal components of the sciatic nerve can be visualized separately as they coalesce to form the sciatic nerve (Figure 20-7).

The popliteal block is performed in the same area as the lateral sciatic block; however, the patient is in a prone rather than a supine position. Scanning the nerve in the popliteal approach may be easier, although positioning the patient prone is more cumbersome.

The common peroneal and tibial nerves can be blocked distal to the sciatic nerve bifurcation using two separate injections of local anesthetic around each nerve.

Figure 20-7



21. SAPHENOUS NERVE BLOCK

INTRODUCTION

The saphenous nerve is the only nerve below the knee that is not derived from the sciatic nerve. Rather, it is a continuation of the femoral nerve (part of the lumbar plexus) extending the length of the lower extremity. It provides cutaneous innervation over the medial, anteromedial, and posteromedial areas of the lower leg; all other sensory and motor innervation to the lower leg is supplied by the sciatic nerve. Because it is a terminal branch of the femoral nerve, the saphenous nerve can be anesthetized with a lumbar plexus nerve block, or more commonly, a femoral nerve block. This nerve can also be individually blocked directly at the knee or the ankle (see Chapter 22, Ankle Block). The saphenous nerve block is frequently combined with a sciatic nerve block to anesthetize the entire lower leg.

ANATOMY

The saphenous nerve is the largest sensory branch of the femoral nerve, derived from the L3–4 nerve roots. Its cutaneous area of innervation spans from the medial lower leg just distal to the knee down to the medial malleolus, and in some patients as far down as the great toe (Figure 21-1). The nerve travels through the femoral triangle, lateral to the vessels, and then takes a more superficial path between the sartorius and gracilis muscles (Figure 21-2). Once past the knee, it proceeds caudally along the medial aspect of the leg, traveling with the great saphenous vein. The nerve is usually targeted to be anesthetized at the medial aspect of the knee.

Several different techniques of saphenous nerve block have been described, the most common being the transsartorial approach, which takes advantage of the nerve's location behind the sartorius muscle (Figure 21-3). Another technique is the paravenous approach, which takes advantage of the nerve's proximity to the saphenous vein, and a third is the simple field block, in which local anesthetic is deposited subcutaneously around the medial surface of the tibia. Recently, ultrasound-guided saphenous nerve blocks have been described that use the saphenous vein as an ultrasound landmark.

rius muscle (Figure 21-3). Another technique is the paravenous approach, which takes advantage of the nerve's proximity to the saphenous vein, and a third is the simple field block, in which local anesthetic is deposited subcutaneously around the medial surface of the tibia. Recently, ultrasound-guided saphenous nerve blocks have been described that use the saphenous vein as an ultrasound landmark.

Teaching Point. If a tourniquet will be used for the surgical procedure, its placement either above or below the knee must first be determined. For above-knee placement, a femoral nerve block is more appropriate to provide analgesia accommodating the tourniquet; for below-knee tourniquet placement, a saphenous nerve block is appropriate.

Figure 21-1

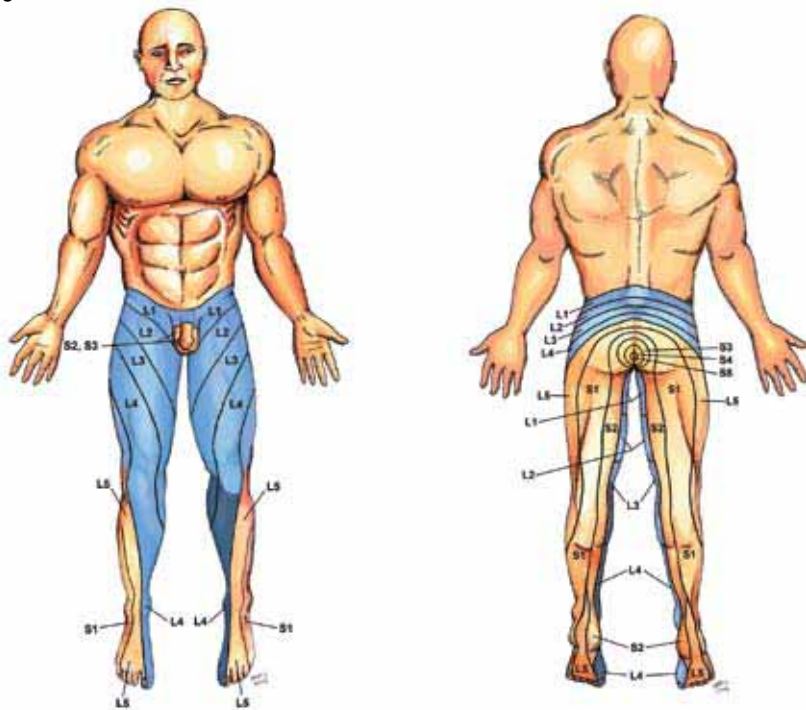
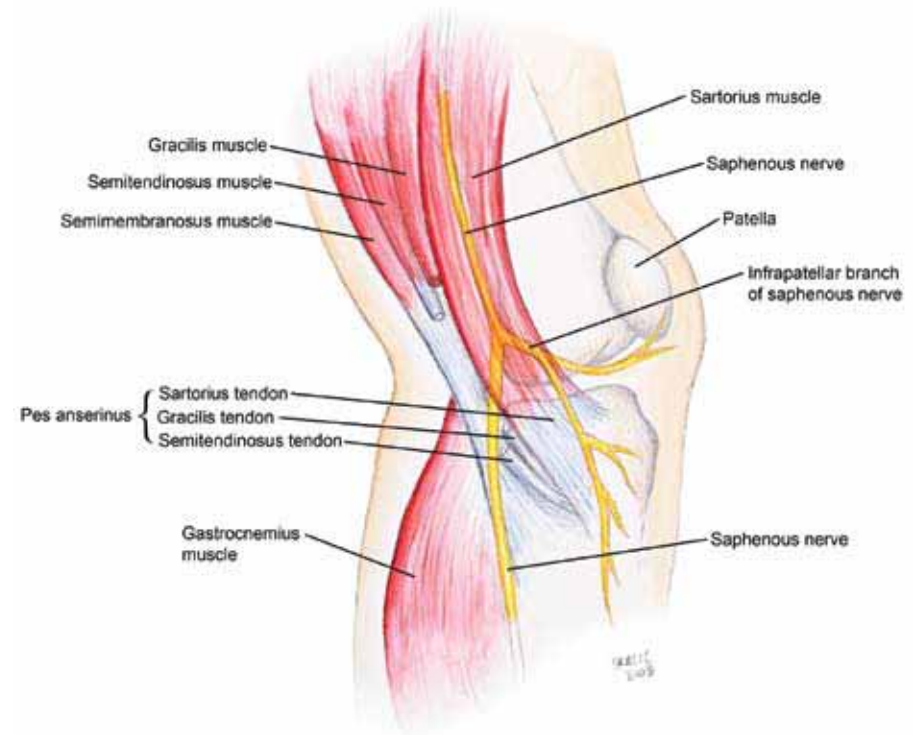


Figure 21-2



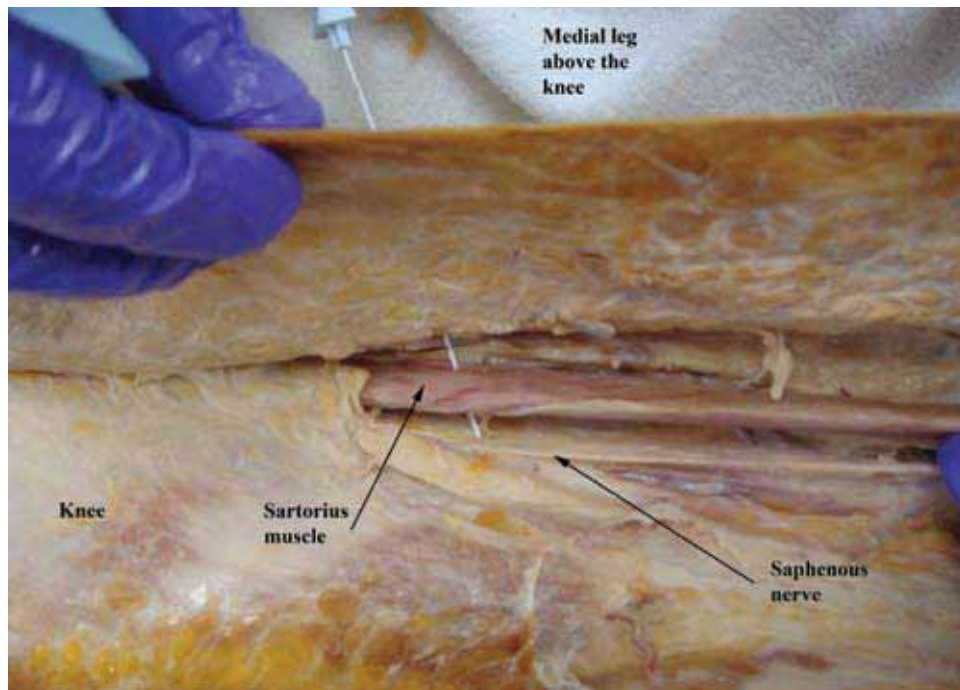


Figure 21-3

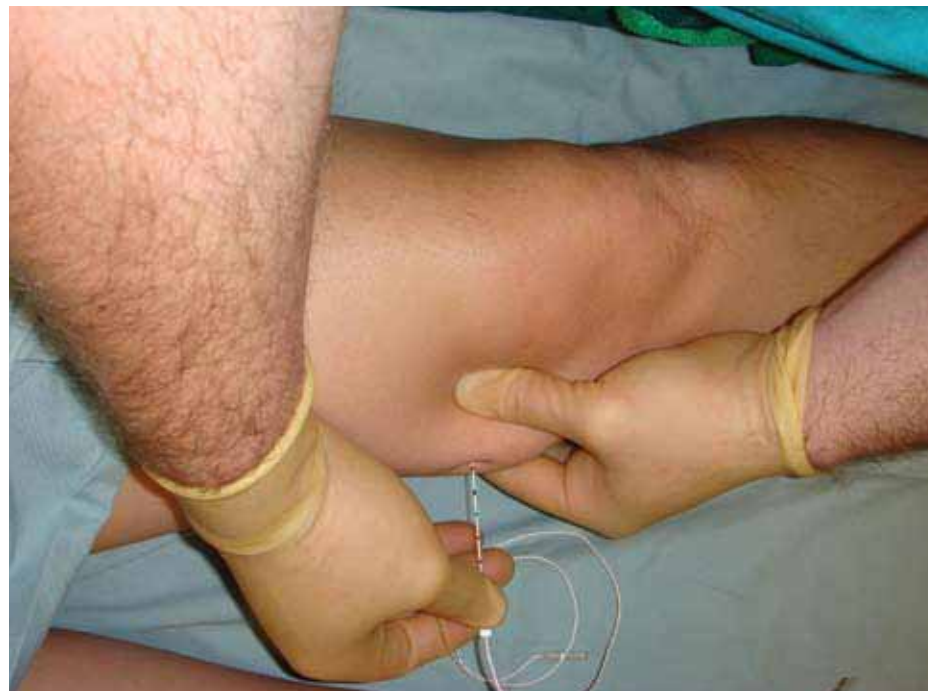

Figure 21-4

PROCEDURE

Transsartorial Approach. With the patient in the supine position and the leg extended and actively elevated 2 inches above the bed, the sartorius muscle is easily identified on the medial aspect of the leg, just above the knee. Insert the needle 1 to 2 cm above the patella, slightly posterior and caudad to the coronal plane, and pass it through the body of the sartorius muscle (Figure 21-4). Once a loss of resistance is appreciated (subsartorial adipose), perform gentle aspiration, and deposit 10 mL of local anesthetic. The distance from skin to loss of resistance is typically 1.5 to 3.0 cm.

Paravenous Approach. At the level of the tibial tuberosity, the saphenous nerve lies medial and

posterior to the vein. Place a tourniquet around the leg based on this anatomic relationship, and then place the leg over the side of the bed for 1 minute to allow time for the saphenous vein to become identifiable. Once the vein is either viewed or palpated along the medial aspect of the leg, deposit 5 mL of local anesthetic in the subcutaneous tissue on either side of the vein, just below the patella.

Below-Knee Field Block Approach. This approach is similar to the paravenous approach but encompasses a wider area. With the patient in the supine position, identify and palpate the tibial tuberosity (a bony prominence several centimeters distal to the patella). Inject 5 to 10 mL of local anesthetic into the subcutaneous tissue, beginning at the medial aspect

of the tibial tuberosity and ending at the medial aspect of the calf (gastrocnemius muscle).

Local Anesthetic. In most adults, 35 to 45 mL of local anesthetic is sufficient to block the nerves.

Teaching Point. Because the saphenous nerve has many smaller branches, it is often difficult to anesthetize the entire nerve at a single location at or distal to the knee. If the operative field will include the medial aspect of the lower leg, a femoral nerve block is recommended.

22. ANKLE BLOCK

INTRODUCTION AND ANATOMY

Five peripheral nerves supply the foot: the tibial nerve, the deep peroneal nerve, the superficial peroneal nerve, the sural nerve, and the saphenous nerve. All cross the ankle and are derived from the sciatic nerve except for the saphenous nerve, which is derived from the femoral nerve. The tibial and deep peroneal nerves supply deep structures of the foot and therefore must be blocked beneath the deep fascia of the ankle. The remaining nerves supply sensory innervation to the skin and can be blocked superficially (Figure 22-1). The ankle block works very well for foot and toe surgery and facilitates early ambulation.

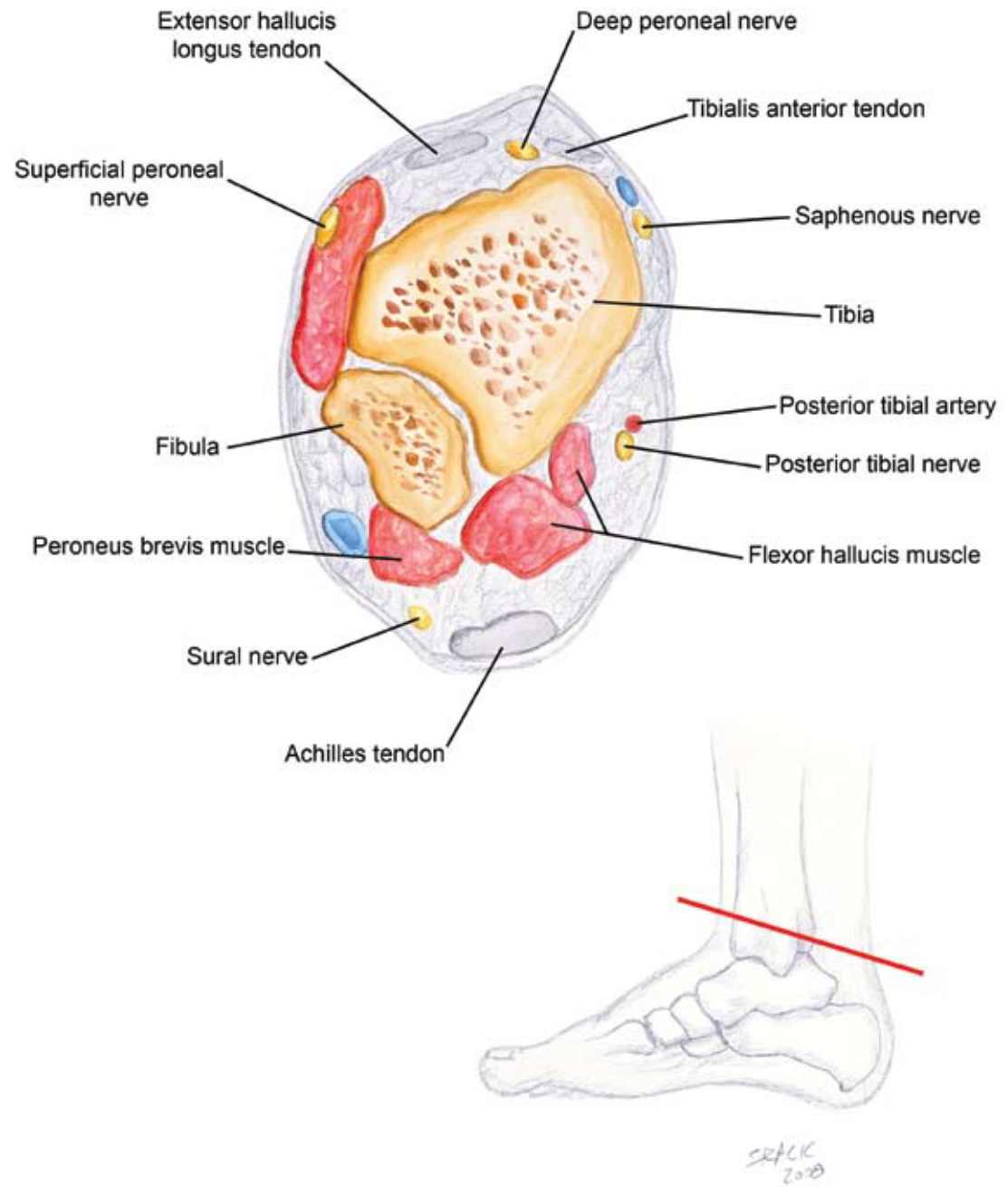


Figure 22-1

PROCEDURE

Landmarks

Tibial Nerve. This nerve is located posterior to the posterior tibial artery at the level of the medial malleolus. Palpate the artery and insert the needle passing posterior to the artery. A nerve stimulator can be used to help localize the nerve. The needle will typically contact the medial malleolus; after this contact occurs, slightly withdraw the needle. Inject 3 to 5 mL of local anesthetic (Figure 22-2).

Deep Peroneal Nerve. This nerve runs lateral to the dorsalis pedis artery at the level of the foot. Palpate the artery and insert the needle lateral to the artery. If bone is contacted, withdraw the needle slightly before injecting 2 to 4 mL of local anesthetic (Figure 22-3).

Superficial Peroneal Nerve. Inject a subcutaneous wheal of local anesthetic (5 mL) from the anterior border of the tibia to the lateral malleolus (Figure 22-4).

Figure 22-2

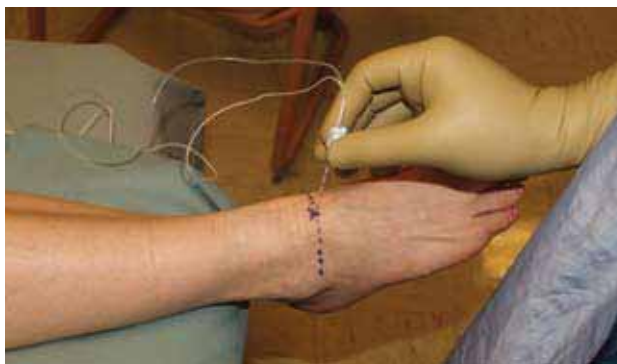
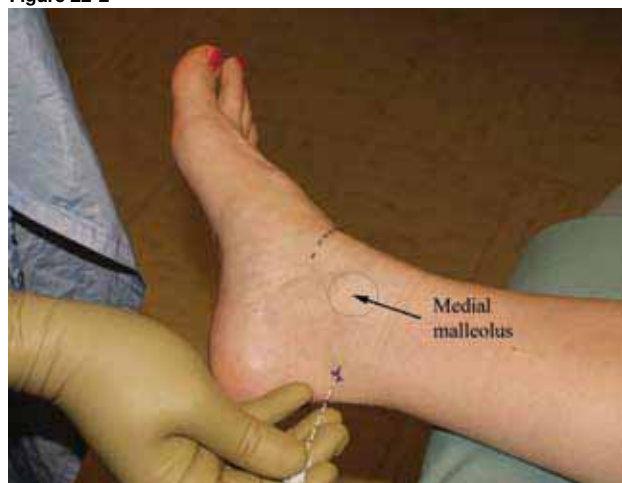
Figure 22-3

Saphenous Nerve. Inject a subcutaneous wheal of local anesthetic (5 mL), directing it posteriorly from the tibial ridge to the medial malleolus (Figure 22-5).

Sural Nerve. Insert the needle between the Achilles tendon and the lateral malleolus, and subcutaneously infiltrate 5 mL of local anesthetic along this course (Figure 22-6).

Needle. 22-gauge, 5-cm, b-bevel needle.

Figure 22-4

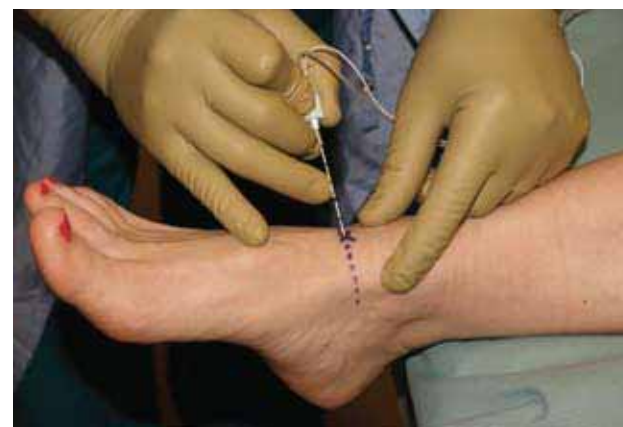
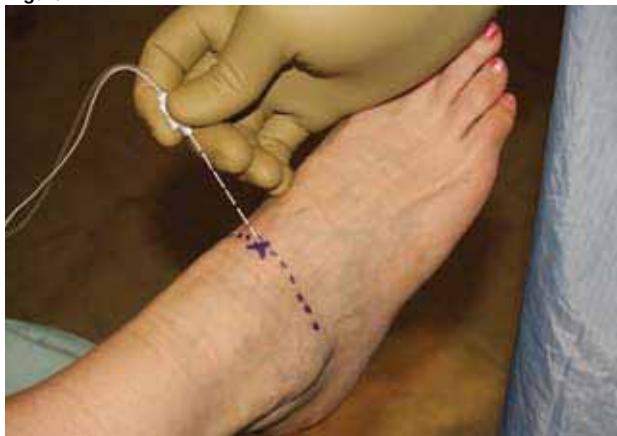
Figure 22-5

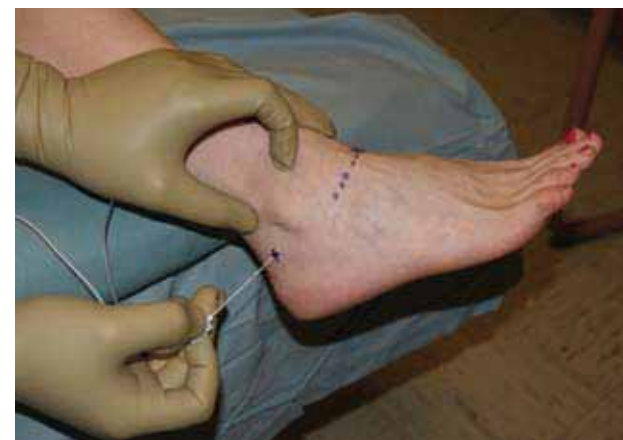

Figure 22-6

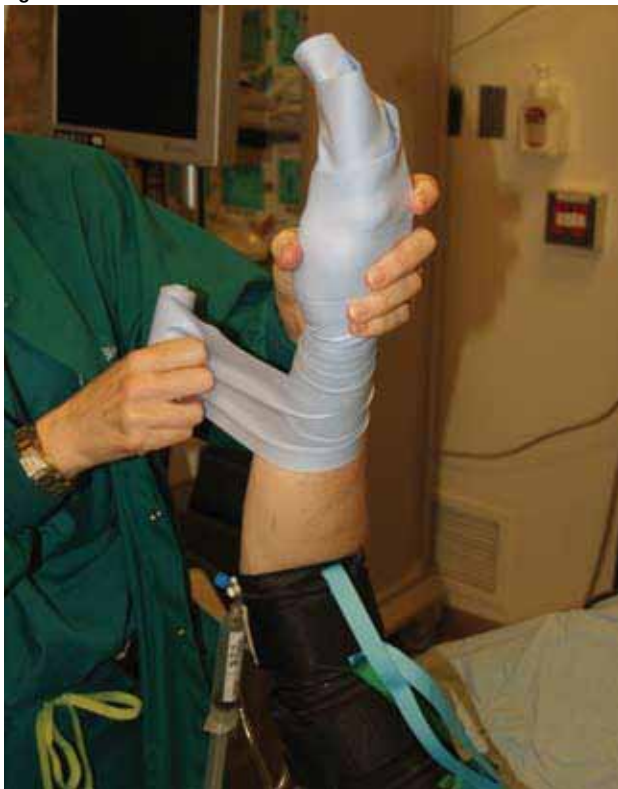Teaching Points. Do not use epinephrine-containing local anesthetic for this block. If a paresthesia is elicited, the needle should be redirected prior to injection because intraneural injection can cause significant damage in these small nerves. Injection around the ankle can be uncomfortable; preemptive analgesia can be very helpful.

23. BIER BLOCK

INTRODUCTION

Introduced by August Bier in 1908, the Bier block is a technique for intravenous regional anesthesia that can produce total analgesia of either the upper or lower extremity. It is best reserved for short procedures (less than 60 minutes) of the distal extremities. The technique is based on the premise that if circulation to the limb is blocked and local anesthetic is injected into venous vessels distal to the occlusion, the nerves that typically travel with blood vessels will be anesthetized as the drug diffuses into the extravascular space via retrograde flow. The duration of the block depends on the length of occlusion of the vessels.

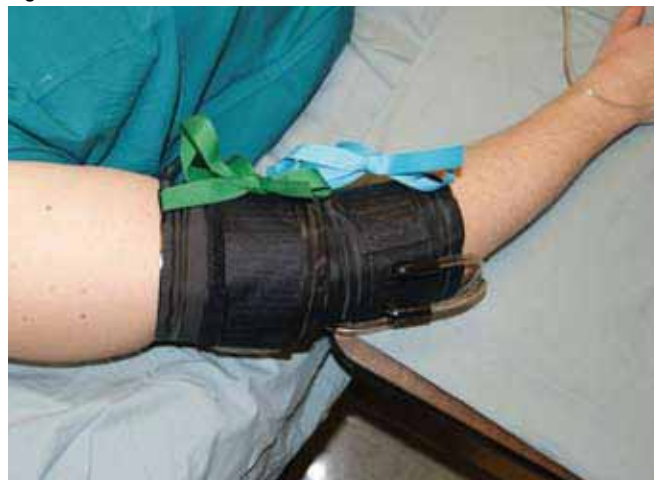Figure 23-1



PROCEDURE

Place a double-cuffed tourniquet on the upper arm of the operative extremity (do not inflate). Place an intravenous (IV) catheter in the hand of the operative extremity (a second IV on the nonoperative side should already be present). With the patient lying in the supine position, the operative arm is raised straight over the head for exsanguination (allow at least 1 minute for blood to evacuate). This maneuver is a very important part of the procedure because excess blood remaining in the arm will dilute the injected local anesthetic. While the arm remains raised, wrap an Esmarch elastic bandage from the fingertips proximally up to the tourniquet. This technique will expedite exsanguination (Figure 23-1). If an elastic bandage is not available, continue to hold the operative extremity above the patient's head for at least 4 to 5 minutes. Once the bandage has been placed or the appropriate amount of time has elapsed, inflate the proximal (upper) tourniquet to 250 mm Hg (or 100 mm Hg above the patient's systolic blood pressure), and remove the elastic bandage (Figure 23-2).

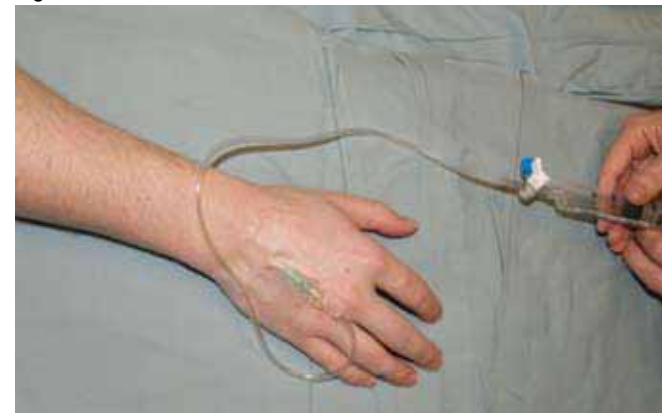Figure 23-2



Place the patient's arm on the table and slowly inject the local anesthetic (Figure 23-3). The patient's skin may appear to blanch in areas; this is normal.

Allow 10 minutes to elapse before the start of surgery. During the surgical procedure, if the patient begins to feel discomfort from the tourniquet (usually after 60 minutes), inflate the distal (lower) tourniquet and then deflate the proximal (upper) tourniquet.

Figure 23-3



Local Anesthetic. In most adults, 30 to 50 mL of 0.5% lidocaine (about 3 mL/kg) is sufficient. Use **nonepinephrine**-containing solution.

Teaching Points. Never deflate the tourniquet sooner than 20 minutes after injection, even if the surgery is shorter than that time period; the lidocaine has been injected intravenously and toxicity can occur with early cuff deflation. Because of the possibility of intravenous injection, epinephrine is not used in the local anesthetic solution. Short-acting, less toxic local anesthetics are employed (lidocaine or prilocaine). Do **not** use ropivacaine or bupivacaine.

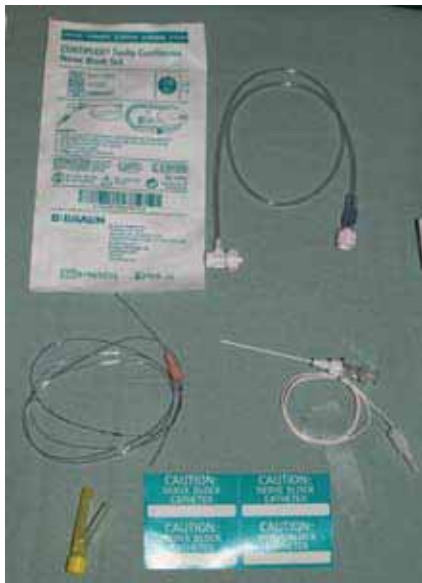24. CONTINUOUS PERIPHERAL NERVE BLOCK

INTRODUCTION

The continuous peripheral nerve block (CPNB) catheter allows the benefits of regional anesthesia to be extended beyond the 8 to 20 hours achieved with single-injection, long-acting local anesthetics. A CPNB is typically used to provide the following:

- anesthesia for surgery and prolonged analgesia postoperatively (eg, shoulder, hip, or knee arthroplasty);
- prolonged analgesia and anesthesia for patients with significant trauma who require multiple surgeries;
- diagnostic or therapeutic treatment for chronic pain syndromes; or
- pain control for patients during aggressive postoperative physical therapy and rehabilitation (eg, with use of a continuous passive motion device).

Figure 24-1. Contents of Contiplex Tuohy package (B Braun Melsungen AG, Melsungen, Germany; used with permission).



Only those with previous experience and competence in single-injection blocks should consider performing CPNB. Please see the chapters on single-injection blocks for the appropriate approaches and indications. Follow these chapters for anatomy, patient positioning, landmarks, needle advancement, and stimulation. *Note: The medical materials are displayed in this chapter for illustration purposes only and should not be considered an endorsement of any product.*

PROCEDURE

Equipment

- 18-gauge continuous block needle system (eg, the Contiplex Tuohy needle system, Figure 24-1 [B Braun Melsungen AG, Melsungen, Germany]) needles in 5-cm, 10-cm, and 15-cm lengths (Figure 24-2). This is an insulated Tuohy design with an uninsulated tip; the system includes the needle and an integrated stimulating wire and extension tubing with a diaphragm allowing for catheter insertion.
- Multiorifice catheter (comes with the Contiplex Tuohy)
- Nerve stimulator
- Chlorhexidine preparation
- Surgical marking pen
- Sterile drape
- Local anesthetic for tunneling
- 3-mL syringe and 25-gauge needle for local anesthetic infiltration
- No. 11 scalpel blade
- Skin adhesive (eg, Dermabond [Ethicon Inc, Somerville, NJ])
- Surgical skin adhesive strips (eg, Steri-Strips [3M, Saint Paul, Minn])
- Adhesive spray (eg, Hollister Medical Adhesive [Hollister Inc, Libertyville, Ill])

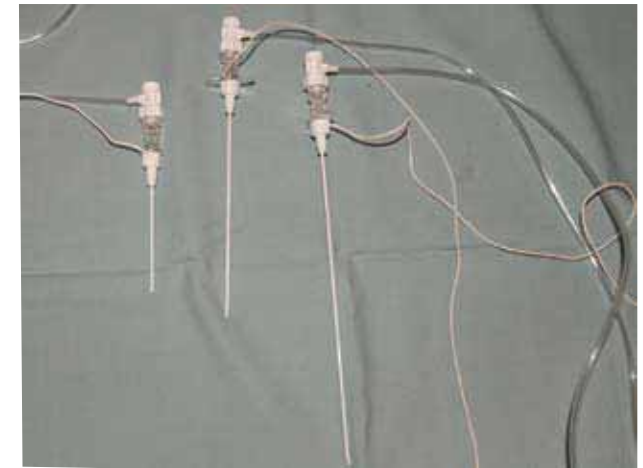

Figure 24-2. Contiplex needles, left to right: 5 cm, 10 cm, and 15 cm (B Braun Melsungen AG, Melsungen, Germany; used with permission)

- Transparent dressing (eg, Tegaderm [3M])
- AmbIT (Sorenson Medical Inc, West Jordan, Utah) CPNB infusion pump and tubing (Figure 24-3)
- 16-gauge Angiocath (BD Medical, Sandy, Utah) needle



Figure 24-3. AmbIT (Sorenson Medical Inc, West Jordan, Utah; used with permission) pump and tubing.

Infection Control

Regional blocks are placed under sterile conditions. Medical personnel should wear a mask, hat, and sterile gloves. A surgical gown can also be considered. Finally, an antimicrobial dressing (eg, BioPatch [Johnson & Johnson Wound Management, Ethicon Inc]) should be placed around the catheter site, if available.

Steps for Catheter Placement

- Position the patient as for a single-injection block, ensuring that the patient is on standard monitors and has intravenous access for medications.
- Landmarks for catheter placement are identical to those used for single-injection nerve blocks.
- After identifying skin landmarks, use a chlorhexidine sponge for skin disinfection (povidone-iodine solution is an alternative, although less effective, skin disinfectant) and repeat the preparation before draping the patient.
- Connect the venous valve side port to the Contiplex Tuohy needle. Flush the needle with local anesthetic solution, and attach the stimulating wire to the nerve stimulator.
- Remove the CPNB catheter from its package and place the catheter in a sterile and easily accessible position.
- Inject a local anesthetic skin wheal at the needle insertion site.
- Orient the block needle so that the bevel is parallel with the nerve or plexus to be blocked (Table 24-1). Note that the white wire coming from the needle hub is oriented in the same direction as the needle bevel. Thus, the wire provides a visual guide to bevel orientation at all

TABLE 24-1

NEEDLE AND CATHETER SPECIFICATIONS FOR VARIOUS NERVE BLOCKS

Block	Needle Length	Bevel Orientation	Distance to Thread Catheter
Interscalene	3.8 cm	Anterior and toward axilla	3 cm
Supraclavicular	5 cm	Anterior and toward axilla	3 cm
Infraclavicular	10 cm	Anterior and toward axilla	3 cm
Lumbar plexus	10 cm or (rarely) 15 cm	45° angle lateral and caudal	5 cm
Femoral	5 cm	Anterior and cephalad	5 cm
Sciatic posterior	10 cm or (rarely) 15 cm	Cephalad (toward sciatic notch)	5 cm
Sciatic lateral	10 cm	Cephalad	5 cm
Paravertebral	See Chapter 12, Paravertebral Nerve Block		

times. Proper orientation can facilitate catheter threading.

- Advance the needle using the same techniques as in a single-injection block, maintaining appropriate bevel orientation.
- When successful stimulation is achieved, inject local anesthetic using the same procedure as single-injection blocks. Care should be taken not to inject the anesthetic too fast.

Threading the Catheter

- Stabilize the Tuohy needle with one hand (it may be helpful to hold the needle with part of the hand braced against the patient).
- Hold the catheter at the distal tip and advance it through the center of the diaphragm. Continue to thread the catheter until it reaches the end of the needle (Table 24-2).

- Advance the catheter in small increments until it reaches the desired distance (see Table 24-1).

TABLE 24-2

CONTIPLEX TUOHY CATHETER PLACEMENT FOR EACH NEEDLE LENGTH

Needle Length	Distance for Catheter to Exit Needle, Extension Tubing, and Diaphragm
5 cm	10 cm
10 cm	15 cm
15 cm	20 cm (catheter markings end at 20 cm)

Ultrasound

Placing CPNBs under ultrasound is similar to single-injection block using ultrasound described in the individual block chapters. In addition, it may be more difficult to thread the catheter because the CPNB needle may be perpendicular rather than parallel to the nerve.

Teaching Points

- Use the nondominant hand to hold the needle. The hand is braced against the patient with the needle held at the most proximal end (Figure 24-4).
- Use the dominant hand to thread the catheter.
- Increased resistance to catheter threading at the needle tip is common, and increased force is often needed to pass the catheter beyond the needle tip.
- If the catheter will not advance, confirm that the bevel and needle opening are oriented parallel to the nerve or plexus.
- If the catheter still will not advance, try the following techniques:
 - Relax the hand on the needle, allowing it to assume a natural position, and then grip the needle and attempt to thread the catheter again.
 - Rotate the needle 45° and retry.
 - Put a slight backward tension on the needle and retry.
 - Finally, attempt to thread the catheter while simultaneously infusing a small amount of local anesthetic or normal saline through the needle extension tubing.

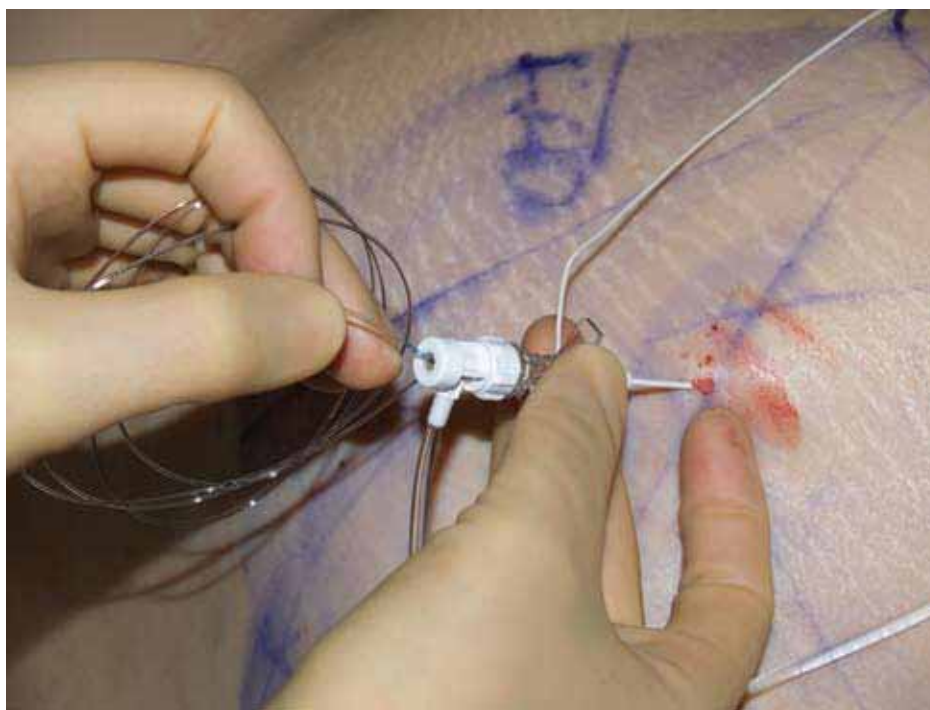


Figure 24-4. Stabilize the Tuohy needle with one hand. It is helpful to have one part of the hand braced against the patient and the other holding the proximal end of the needle near the diaphragm. Hold the catheter at the distal tip and push it through the center of the diaphragm.

Securing the Catheter

- If the catheter is not to be tunneled, hold the catheter steady while removing the needle (similar to an epidural catheter placement).
- Place the syringe connector on the end of the catheter, aspirate, and test dose the catheter with 5 mL of either 1.5% mepivacaine or 0.5% ropivacaine with 1:400,000 epinephrine.
- After a negative test dose (no increase in heart rate or aspiration of blood), ensure that the site is clean and dry. Use skin adhesive (Dermabond) to seal the area where the catheter exits the skin. Allow the adhesive to dry.
- Spray a light coating of spray adhesive around the catheter. Ensure that the area sprayed is

larger than the area of the transparent dressing (Tegaderm) that will be used to cover the site. Allow time for the spray adhesive to become sticky.

- Loop the catheter on the skin and apply three skin adhesive strips (Steri-Strips) to hold the catheter in place.
- Apply the transparent dressing over the catheter and skin strips, ensuring that all the edges of the dressing are completely adherent to the skin. **Do not place tape over or around the transparent dressing; this would result in tape burns from skin traction and loss of dressing adherence because of trapped moisture.**
- Label the catheter with side and type of CPNB infusion (eg, right femoral block) and date placed.

Tunneling the Catheter

CPNB catheters expected to remain in place for more than 3 days should be tunneled. Tunneling makes the catheter less likely to fall out and may decrease the risk of infection.

- After successfully threading the catheter, maintain a neutral catheter position and withdraw the needle 0.5 to 1 cm.
- Anesthetize the skin with local anesthetic along a track 2 to 4 cm lateral to the needle insertion site (Figure 24-5).

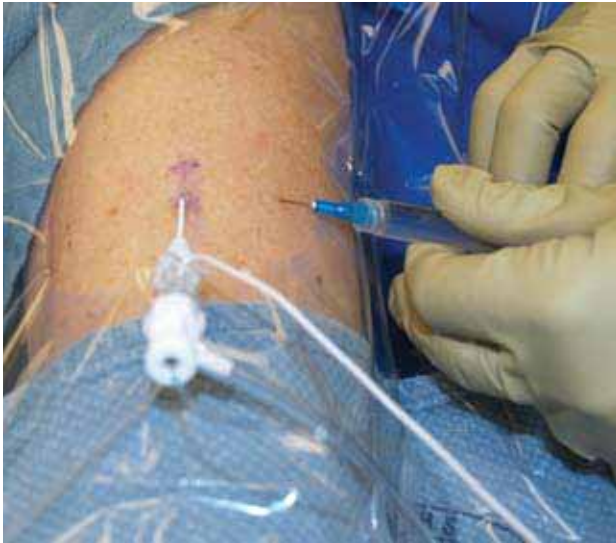

Figure 24-5. Create a local anesthetic skin wheal, starting 2 to 4 cm lateral to the needle position and moving in a straight line toward the needle insertion site.

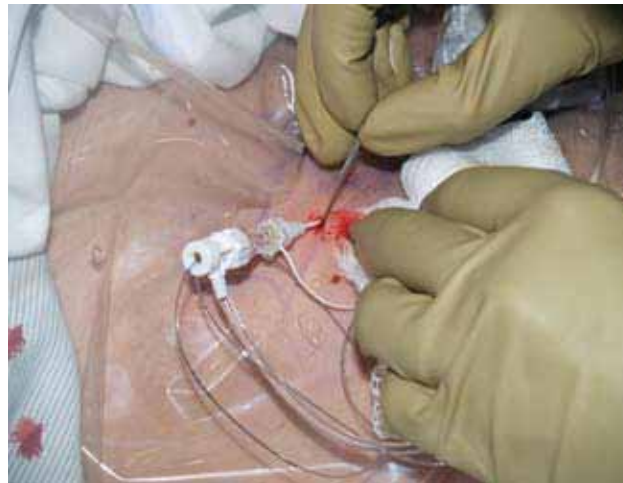

Figure 24-6. Make a skin nick with the no. 11 scalpel blade at the needle insertion site.

- Make a small skin nick with the no. 11 scalpel blade at the needle insertion site (Figure 24-6).
- Insert a 16-gauge Angiocath needle starting at the lateral aspect of the localized skin. The tip of the Angiocath should exit the skin incision made by the scalpel blade immediately adjacent to the Tuohy needle. Try to avoid leaving a skin bridge between the Angiocath and the Tuohy needle. Note that the CPNB needle is protecting the catheter during this procedure (Figure 24-7).

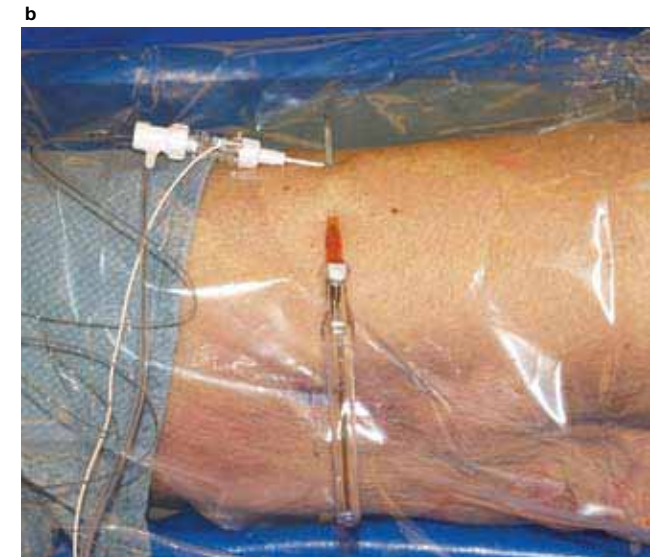
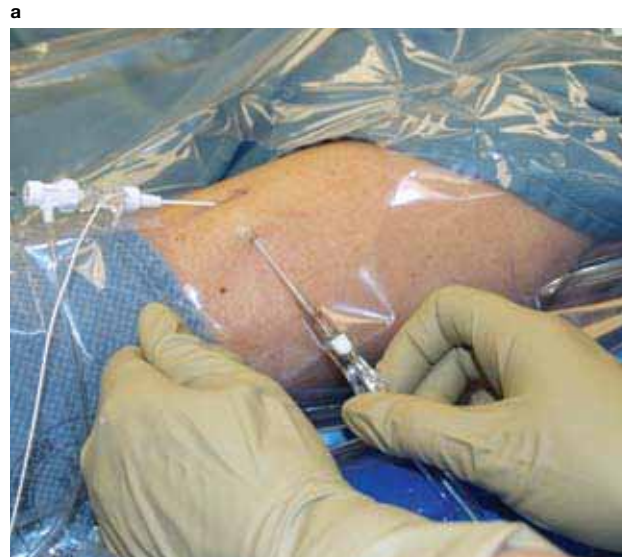

Figure 24-7. (a) Insert a 16-gauge Angiocath (BD Medical, Sandy, Utah; used with permission) needle starting at the lateral aspect of the localized skin wheal. (b) The tip of the Angiocath should exit the skin incision made by the scalpel blade immediately adjacent to the Tuohy needle.

- Remove the Angiocath needle and leave the Angiocath in place.
- Remove the Tuohy needle and leave the catheter in place.
- Thread the CPNB catheter through the tip of the Angiocath and pull the CPNB catheter through (Figure 24-8).

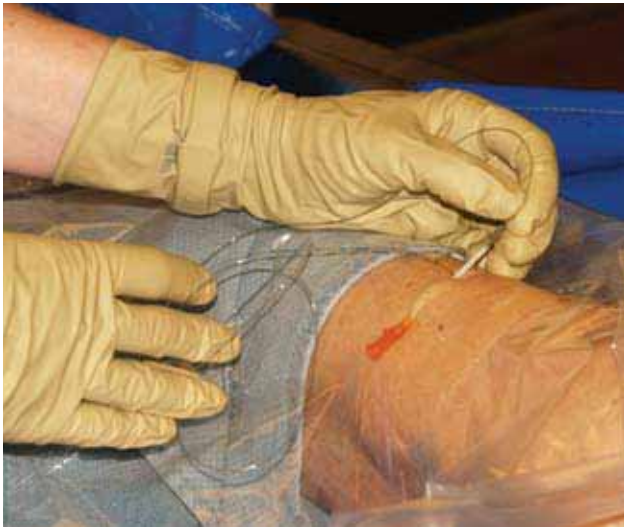

Figure 24-8. Thread the distal end of the CPNB catheter through the Angiocath, and pull the CPNB catheter through.

- Pull the regional anesthesia catheter until it seats within the skin nick. Do not allow the catheter to kink at this point (Figure 24-9a).
- Carefully remove the Angiocath without displacing the CPNB catheter (Figure 24-9b).
- Test dose the catheter.
- Clean and dry the CPNB catheter site. Glue both sites closed with skin adhesive glue (Figure 24-10).

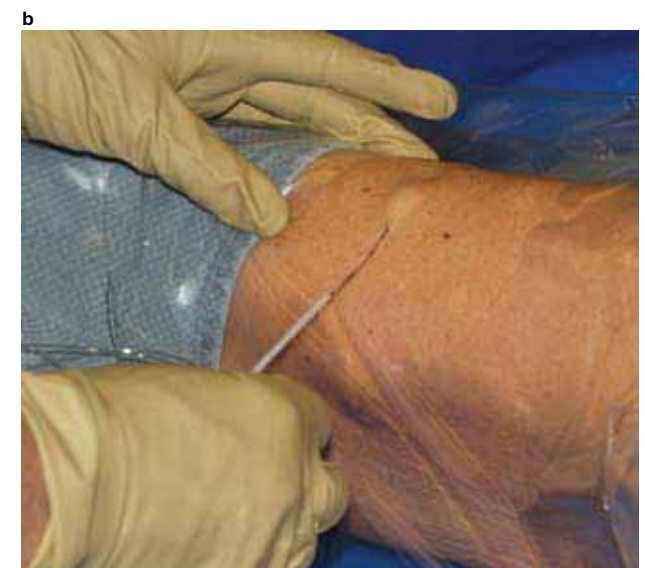
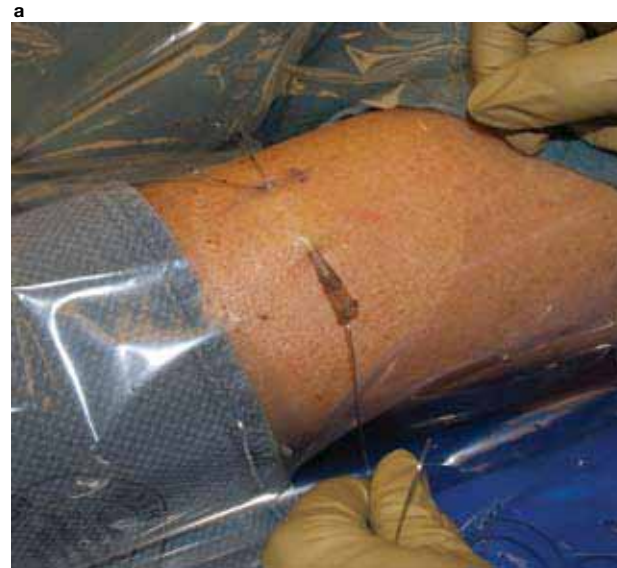
Figure 24-9. (a) Pull the regional anesthesia catheter until it seats within the skin nick, and (b) remove the Angiocath.

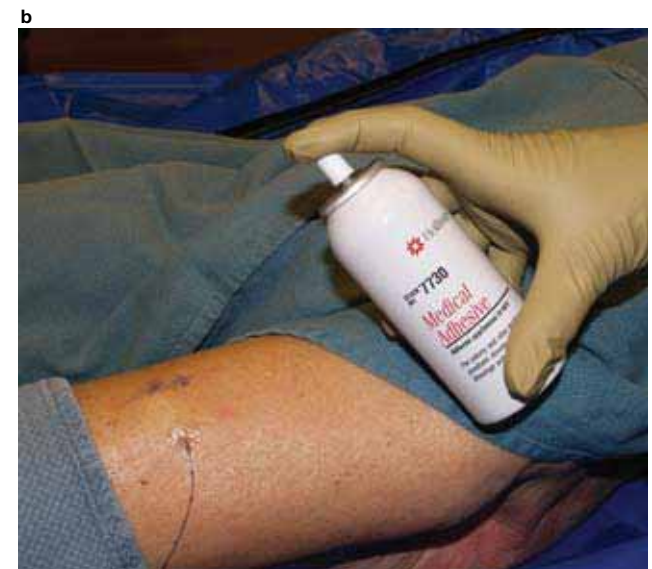
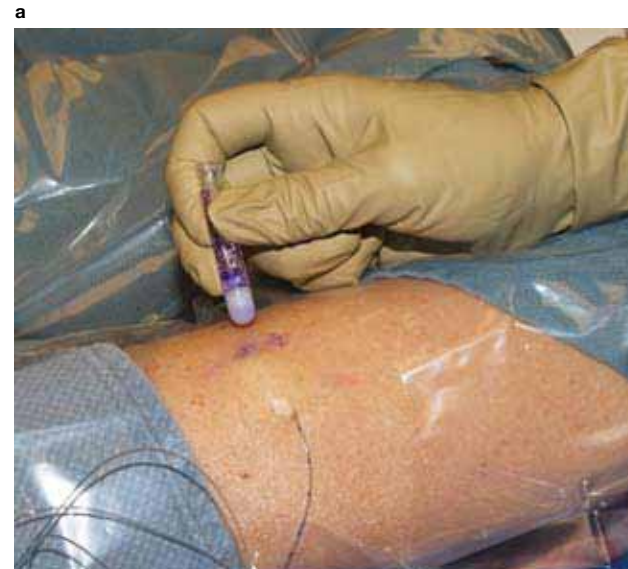
Figure 24-10. Clean and dry the CPNB catheter site. (a) Glue both sites closed with skin adhesive glue, and (b) spray a light coating of adhesive spray around the catheter.

- Secure the catheter as previously described (Figures 24-10b through 24-13).

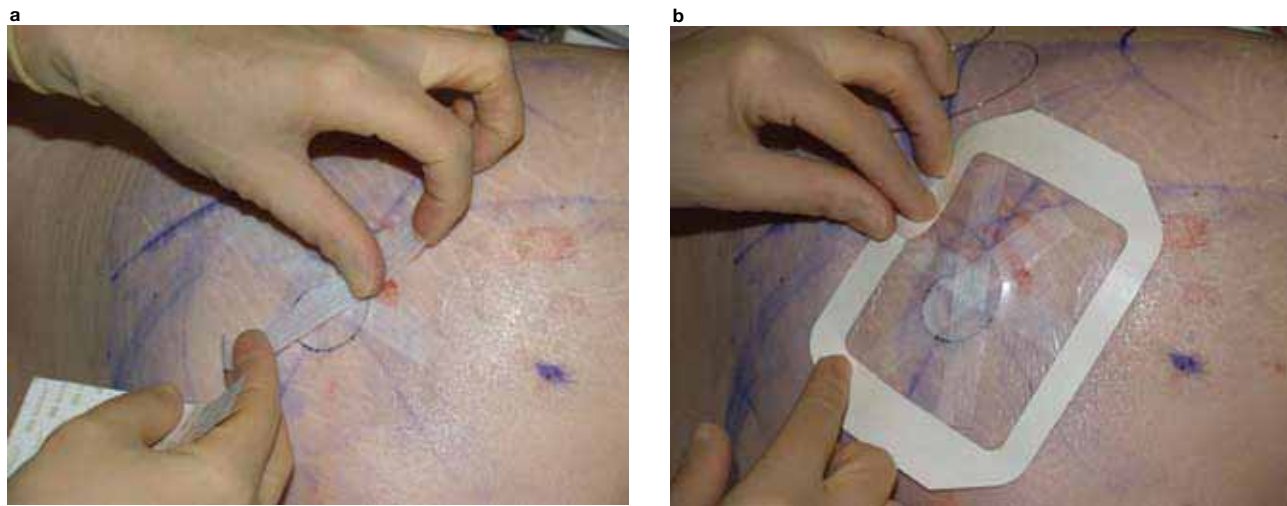


Figure 24-11. (a) Loop the catheter on the skin and apply three skin adhesive strips to hold the catheter in place. (b) Apply a transparent skin dressing over the area. Ensure that all edges of the skin dressing are completely adherent to the skin. The catheter dressing should not prevent visual inspection of the catheter site.

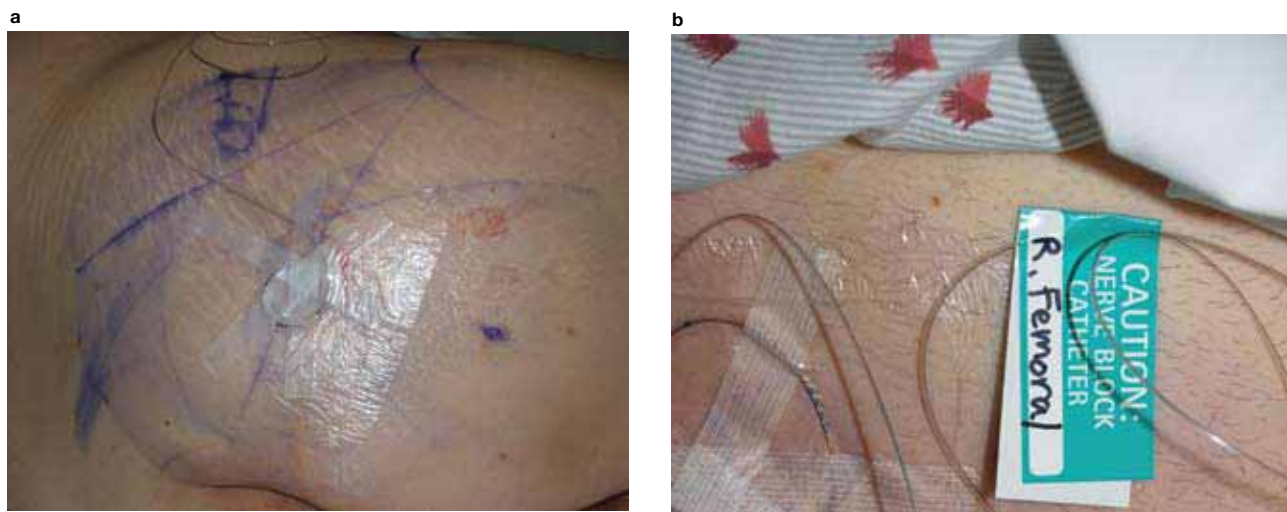


Figure 24-12. (a) Do not place tape around the clear skin dressing. (b) Label the CPNB catheter.



Figure 24-13. Start the local anesthetic infusion.

Continuous Paravertebral Catheters

Different equipment and techniques are required to place thoracic paravertebral catheters; for instance, a single orifice (open-tip) epidural catheter is used rather than a multiorifice catheter. The single orifice catheter is used because the paravertebral space is small and allows only 2 cm of catheter to be threaded into the space. If a multiorifice catheter were used for this block, at least one hole of the multiorifice catheter would be outside the paravertebral space and the local anesthetic infusion would leak out and track retrograde along the catheter path.

Equipment for Paravertebral Catheters

- 18-gauge Tuohy epidural needle (this has centimeter markings on the needle)
- Side port and diaphragm from the 18-gauge Contiplex Tuohy needle
- Single-orifice, open-tip, epidural catheter (Figure 24-14)
- 22-gauge Tuohy needle used for single injection paravertebral blocks

Landmarks for Paravertebral Catheters. Same as for a single-injection paravertebral block.

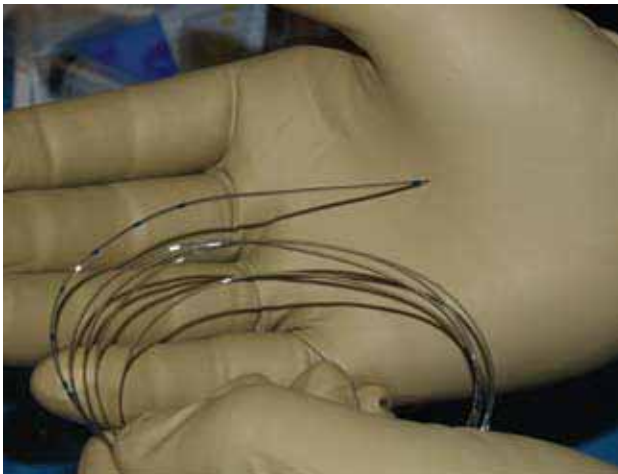


Figure 24-14. Single-orifice catheter.

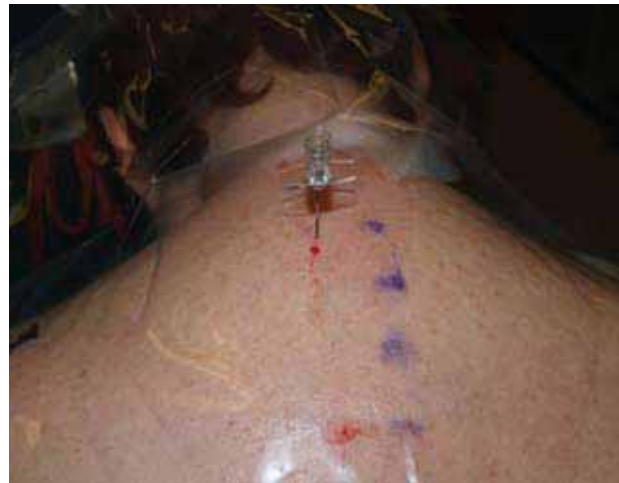

Figure 24-15. 22-gauge Tuohy needle used as a finder of the transverse process.

Procedure for Paravertebral Catheters

- Attach the side port of the Contiplex Tuohy needle to the 18-gauge epidural Tuohy needle.
- Use the 22-gauge single-injection Tuohy needle as a finder needle to locate the transverse process at the level where the catheter will be placed (Figure 24-15).
- Replace the finder needle with the 18-gauge epidural Tuohy needle.
- Enter the paravertebral space with the 18-gauge Tuohy needle in the same manner as for single injection paravertebral block (Figure 24-16).
- Slowly bolus 10 to 15 mL of an appropriate local anesthetic solution containing epinephrine through the 18-gauge Tuohy needle.
- Attempt to thread the single-orifice epidural catheter through the diaphragm and needle 2 cm

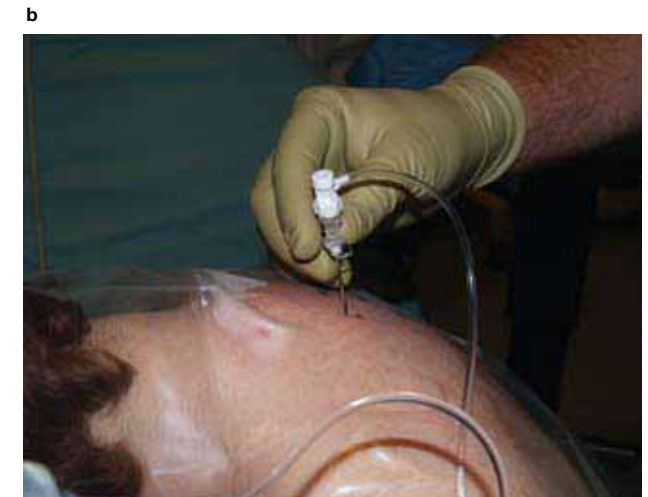
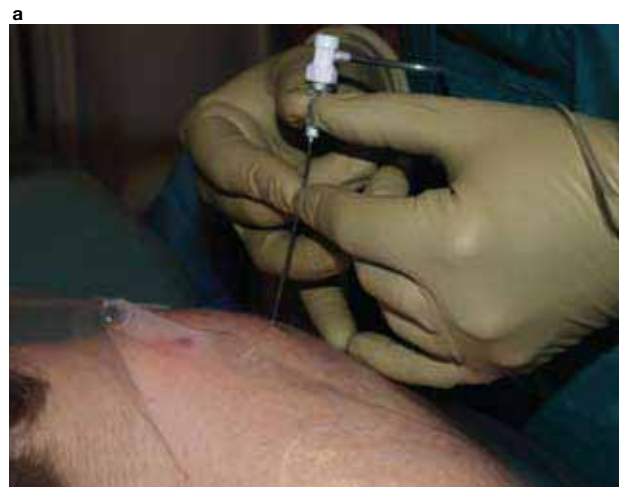
Figure 24-16. (a) 18-gauge epidural Tuohy needle with the side port of the Contiplex Tuohy needle attached. (b) Push the needle tip caudad to facilitate catheter threading.

DAILY MANAGEMENT

past the end of the Tuohy needle into the paravertebral space. *Note: The paravertebral space is small, and these catheters are frequently difficult to thread. A catheter that is very easy to thread may be in the intrapleural space.*

- If you are unable to thread the catheter, rotate the needle 90° laterally or angle the needle tip either cephalad or caudad. All three maneuvers are often required.
- After threading the catheter, remove the Tuohy needle, taking care not to withdraw the catheter as well.
- Attach the syringe connector to the catheter. Test dose the catheter with 5 mL of local anesthetic containing 1:400,000 epinephrine. If you cannot inject anesthetic through the catheter, the open tip of the catheter is likely pushed up against the rib. Pull the catheter back 0.25 cm and reattempt to inject.
- Secure the catheter in the same manner as a non-tunneled CPNB catheter. Pay particular attention to sealing the catheter exit site with skin adhesive glue. A watertight seal is necessary to prevent leakage of local anesthetic solution around the catheter.

INFUSIONS

The maximum number of catheters is usually two (on rare occasions three). Total infusion amounts (continuous plus bolus) greater than 20 mL/h are usually avoided. However, based on patient condition and the judgment of the provider, certain patients may receive more than 20 mL/h of 0.2% ropivacaine. See Chapter 3, Local Anesthetics, Table 3-3.

All patients with CPNB catheters must be evaluated at least once daily. A tracking system should be used to ensure that all such patients are clinically monitored by providers experienced with CPNB. The hospital or unit acute pain service is usually responsible for this activity. Routine management of CPNB catheters includes the following measures:

- Evaluate vital signs (including fever) for the last 24 hours.
- Assess any changes in the patient's medications that could affect the CPNB infusion, such as anticoagulants and adjunct pain medication.
- Evaluate sleep, pain score, and satisfaction with pain control.
- Inspect and palpate the catheter site for evidence of dislodgement or infection.
- Confirm that the correct local anesthetic medication is infusing in the correct patient.
- Confirm the desired infusion rate, bolus amount, lockout time, and local anesthetic bag volume.
- Appraise the patient for signs or symptoms of local anesthetic toxicity (see Chapter 3, Local Anesthetics).
- Initiate heel precautions for patients with sciatic catheters, who may be at increased risk for pressure ulcers of the heel. Ideally the heel should be elevated and off the bed at all times.
- Determine if the patient needs additional pain medications.
- Determine if the patient should be weaned from the catheter, or if the catheter should be removed.
- Generate a daily clinical note on each patient documenting management of the CPNB catheter.

ENOXAPARIN

Prophylactic enoxaparin (Lovenox, Sanofi-Aventis, Bridgewater, NJ) is defined as either 30 mg twice a day or 40 mg daily. In patients receiving prophylactic enoxaparin, delay placement or removal of CPNB catheters until 10 to 12 hours after the last enoxaparin dose. After removing a catheter, wait 2 hours before dosing with enoxaparin.

Therapeutic enoxaparin is defined here as anything greater than 30 mg twice a day. Usually therapeutic enoxaparin is either 1 mg/kg twice a day or 1.5 mg/kg daily. Delay the placement or removal of CPNB catheters until 24 hours after the last enoxaparin dose in patients receiving therapeutic enoxaparin. Do not place continuous lumbar plexus catheters in these patients. If a continuous lumbar plexus catheter is in place and the patient is subsequently started on therapeutic enoxaparin, removal of that catheter is recommended. Other CPNB catheters may be placed or continued in patients receiving therapeutic enoxaparin at the discretion of the provider, after thorough discussion with the patient and primary care team on the risks and benefits of CPNB placement or continued CPNB use.

If a CPNB catheter appears infected, use clinical judgment to determine whether to wait the recommended amount of time after the last enoxaparin dose before removing the catheter or to remove it immediately.

Patients may be taking a variety of anticoagulation medications. To date, no clear guidance exists on the use of CPNB catheters in patients taking anticoagulants (other than heparins). In patients with an international normalized ratio greater than 1.5, decisions must be balanced between the benefits of CPNB catheters for pain relief versus the risk of bleeding into the region of the body where the block is placed.

25. REGIONAL ANESTHESIA COMPLICATIONS

INTRODUCTION

Compared to general anesthesia, regional anesthesia offers numerous opportunities for better pain control and patient satisfaction. As regional anesthesia continues to gain acceptance, providers must be prepared to diagnose, and possibly treat, any complications that may arise with the use of peripheral nerve blocks. This chapter will evaluate the etiology, diagnostics, and treatment of nerve injury.

FUNCTIONAL ANATOMY OF THE PERIPHERAL NERVE

The peripheral nerve consists of a bundle of fascicles held together by a connective tissue sheath. The fascicles each contain numerous individual nerve fibers and blood vessels within a loose connective tissue called the endoneurium. Each fascicle is wrapped in a multilayered epithelial perineurium, and the fascicles are in turn surrounded by connective tissue called the epineurium. The health of the nerve depends on careful regulation of the endoneurium environment by the innermost layers of the perineurium and the endoneurial capillaries. The tight endothelial junctions of the nerve make up the blood–nerve barrier (Figure 25-1). Nerves are metabolically active, necessitating a rich vascular supply, which is regulated by the sympathetic nervous system. Blood flow for nerves has been estimated to be as high as 40 mL/100 g/min.

Each nerve fiber can be classified by size and whether or not it is myelinated. Myelinated motor A- α fibers are about 22 μ m in diameter and can conduct a nerve impulse at 120 m/s. These fibers originate in Rexed lamina IX of the ventral horn of the spinal cord and act as large motor neurons. Type B fibers, by contrast, are myelinated autonomic fibers that conduct at 14 m/s. Finally, C fibers, which conduct information on sensory pain

and temperature, are not myelinated and have a conduction velocity of 2 m/s. Almost all peripheral axons are surrounded by Schwann cells. If the particular Schwann cell that surrounds an axon produces myelin, the fiber is considered myelinated.

The generation of nerve impulses depends on the flow of specific ions across the plasma membrane of the nerve axon. The concentration of potassium (K) ions inside the cell is about 10 times greater than the extracellular K concentration. Conversely, the concentration of sodium (Na) ions outside the cell is 10 times greater than the intracellular Na concentration. Energy, in the form of an Na/K adenosine triphosphatase (ATPase) pump, is required to maintain this balance. A resting cell membrane permits a small net outflow of K ions, leaving the axons electrically negative while making the outside of the

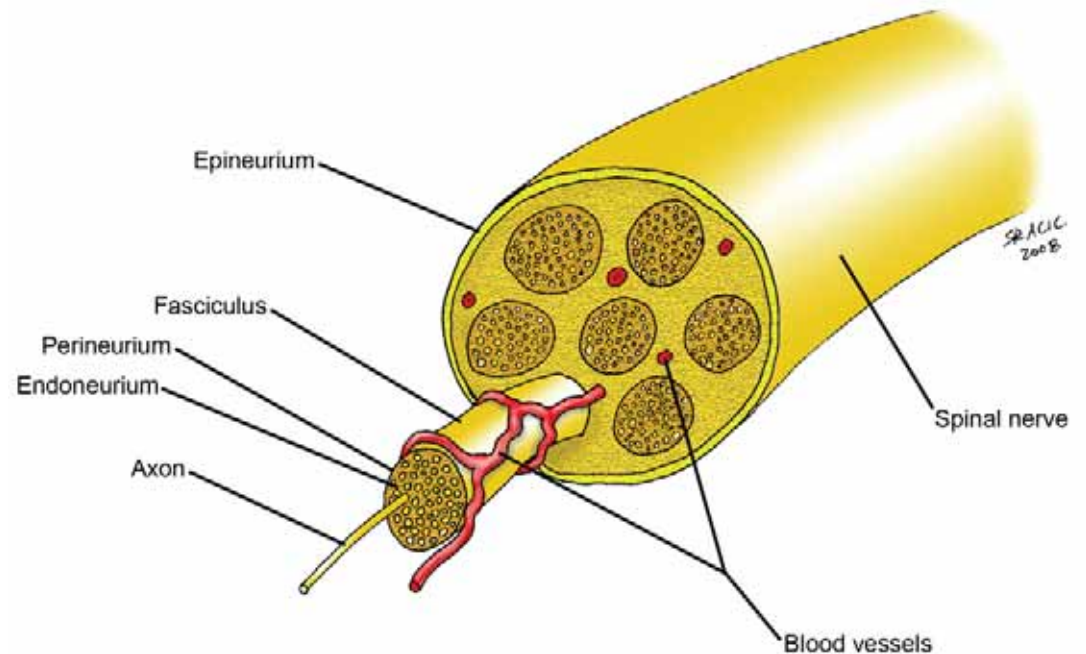


Figure 25-1

nerve electrically positive. This accounts for most of the -70 to -80 mV resting membrane potential measured in peripheral nerves. When a stimulus causes specific Na channels in the cell membrane to open, Na ions pass into and depolarize the nerve cell, allowing an action potential to be propagated down the nerve axon. The increased number of Na ions in the axon then terminate the action potential, causing the Na gradient to diminish, and closing the Na channels. Meanwhile, voltage-dependent K channels open and permit a large outward flow of K. With each nerve impulse, Na enters the nerve cell and K leaves it. The Na/K ATPase pump, which is activated by increased Na in the cell, removes the excess Na and reestablishes the resting membrane potential in preparation for the next action potential.

In large myelinated axons, impulses travel at 60 to 100 m/s and extend across distances of

60 to 100 mm, essentially jumping segments of the nerve between Ranvier's nodes (gaps in the nerve myelin sheath). About 3 to 5 Ranvier's nodes exist in this distance; therefore, local anesthetics need to block 3 to 5 nodes to be effective. Blockade of the Na channel itself is probably the major site of action of most local anesthetic agents used clinically for peripheral nerve block. Although the most proximal roots and the most distal components of nerves can be primarily sensory or motor, most peripheral nerve blocks are performed on mixed nerves; therefore, blockade of motor, sensory, and autonomic nerves should be anticipated.

EFFECTS OF LOCAL ANESTHETICS

Nerve Axons and Myelin Sheaths. In addition to blocking voltage-gated Na channels, local anesthetics have other effects on peripheral nerves, including a dose-related direct nerve toxicity to the nerve axon. The small unmyelinated fibers are more vulnerable to damage by local anesthetics than axons of the large myelinated nerves. The exact mechanism of action of this toxicity is unknown. Histologically, with increasing doses of local anesthetics, the epineurial sheath exposed to the local anesthetic becomes disrupted and permeable to granulocytes. These granulocytes infiltrate the subjacent endoneurium and cause edema formation in the endoneurial area. Damage to the supporting Schwann cell, particularly the unmyelinated fiber, can also be appreciated as lipid droplet accumulation in the cell. Injury to the Schwann cell may be temporary because these cells replicate quickly.

The physiologic mechanism behind the toxicity is likely a combination of inhibition of rapid axon transport, disruption of the axon microstructure, axonal degeneration, and ischemia. Additionally, local anesthetics can cause nerve ischemia by reducing nerve blood flow within endoneurial capil-

laries, perhaps by decreasing the production of natural vasodilating substances such as nitric oxide or prostaglandins.

Axon Transport and Nerve Growth Cones. As a nerve grows, it produces growth cones at the terminal end of the axon. The growth cone interacts with nerve growth factor and Schwann cells and helps dictate the rate and direction of growth. Local anesthetics induce growth cone collapse when applied at increasing concentrations. Local anesthetics also delay nerve growth by retraction of the filopodia (cytoplasmic projections) of the growth cones. Even at very low concentrations of local anesthetics, nerve axonal growth is delayed and axon transport is inhibited. The clinical significance of this growth inhibition by local anesthetics is unclear.

Role of Epinephrine. Epinephrine is used as an adjunct to local anesthetics for a variety of reasons: first, it can reduce plasma concentrations of local anesthetic agents; second, it can intensify anesthesia and analgesia; third, it reduces surgical bleeding; and finally, it increases block duration. With the addition of epinephrine, peak plasma concentrations of local anesthetic are both reduced and delayed.

Epinephrine toxicity following peripheral nerve block can be a concern in some patients. Injected local anesthetics containing epinephrine remain in higher concentrations within the affected area, thereby prolonging the duration of the block. Pathologic examination of nerves subjected to high local anesthetic concentrations reveals axonal degeneration in a dose-dependent fashion. This axonal degeneration is more severe if epinephrine is added to the local anesthetic. In laser Doppler flow studies of rat nerves, 2.0% lidocaine resulted in an 18% drop in nerve blood flow. When epinephrine 1:200,000 was added, an additional 20% drop in nerve blood flow was

observed. Therefore, when combined with lidocaine, epinephrine results in an additive decrease in nerve blood flow. Although the mechanism of epinephrine-enhanced local anesthetic nerve toxicity is unknown, a likely possibility is decreased blood flow to the nerve. Although epinephrine is useful as a marker of intravascular injection, it should be dosed sparingly and at dilute concentrations (1:400,000).

PERIPHERAL NERVE DAMAGE AFTER NERVE BLOCK

Etiology of Nerve Injury. In addition to direct local anesthetic toxicity, peripheral nerves can be damaged by needle injury, compression, stretch, ischemia, and complete transection. Direct needle trauma can be associated with significant nerve injury, especially if the needle penetrates the perineurium and enters the fascicle. The perineurium is very strong, and pressures as high as 1,000 mm Hg have been reported without rupture. The injection of local anesthetic into the fascicle not only causes direct axonal damage from the needle and local anesthetic toxicity, but also increases fascicular pressure to the point that endoneurial blood flow may be compromised. Studies in rat tibial nerves demonstrate that nerves can tolerate ischemia for up to 6 hours without permanent sequelae. If ischemia is combined with nerve compression, this time frame decreases to 4 hours.

Incidence of Nerve Injury. Borgeat et al (2004) published prospective results of 521 patients who had undergone interscalene block for shoulder surgery. Paresthesias, dysesthesias, pain unrelated to surgery, and muscle weaknesses were investigated at 10 days and 1, 3, 6, and 9 months after surgery. At 10 days postprocedure, 74 patients (14%) were symptomatic; 41 (7.9%) had symptoms at 1 month; 20 (3.9%) at 3 months; 6 (0.9%) at 6 months; and 1 (0.2%) at 9 months (no patients

had motor weakness). Electromyography (EMG) helped confirm eight sulcus ulnaris syndromes, four carpal tunnel syndromes, and one brachial plexus neuropathy. Additionally, one patient had pneumothorax, one suffered systemic local anesthetic toxicity, and one sustained axillary nerve damage during the surgery. In the conclusion the authors state, "Interscalene brachial plexus block performed with a standardized technical approach, material and drugs is associated with an incidence of short and long-term severe complications of 0.4%."

Brull et al (2007) reviewed 32 studies published between January 1, 1995, and December 31, 2005, with the primary intent of investigating neurologic complications of regional anesthesia. Based upon this review, the authors concluded that the rate of neuropathy after a peripheral nerve block is 3%. However, permanent neurologic injury after regional anesthesia is rare. Medical evidence suggests an assumed 0.4% rate of "rare" permanent neurologic injury after a peripheral nerve block is to be expected.

Peripheral nerve injuries are well documented after general anesthesia. Ben-David et al (2002), in a closed-claims analysis of upper extremity nerve injuries associated with anesthesia, found 61% associated with general anesthesia and 36% associated with regional anesthesia. Despite the uncommon occurrence of neurologic injury induced by peripheral nerve block, regional anesthesiologists may be called upon to evaluate postsurgical patients with neurologic complaints that likely have nothing to do with the regional anesthetic technique. When regional anesthesia is part of the anesthetic plan, anesthesiologists are often asked to make an assessment of neurologic symptoms and "rule out" the nerve block as the etiology. Regardless of the complication rate quoted to the patient, many neurological symptoms arising from the surgical procedure

will likely be initially attributed to a regional anesthetic block-induced neuropathy.

EVALUATION OF NERVE INJURY AFTER REGIONAL ANESTHESIA

When called to evaluate a patient with neurologic symptoms following a peripheral nerve block, the provider must be able to anatomically localize the region of the pathology and the nerves involved. A careful history, physical examination, electrophysiological tests, and neuroimaging can all help localize the lesion. Once the location of the lesion is determined, the etiology of the injury can be better ascertained and treatment instituted.

History. Determining whether the neurologic deficit existed before the anesthetic or surgery can help prevent false assumptions implicating the peripheral nerve block as the underlying cause of the deficit. Documentation of a normal neurologic examination prior to the nerve block procedure is very important. Preexisting severe peripheral neuropathy from a medical condition such as diabetes may predispose the patient to postoperative nerve injury with or without a peripheral nerve block. Regional anesthesia should be employed with caution in patients with preexisting neuropathy.

The patient should be asked to describe neurologic problems in detail. Symptoms of a nerve lesion may not become apparent for 2 to 3 weeks after initial injury because of confounding factors such as plaster casts, bandaging, and predictable postoperative pain. Details of the surgery, the block, and patient positioning during the procedure are important factors to discuss with the patient (consultants sometimes discover that the neurological complaint is not on the blocked side). The history should include exact determinations of weakness, sensory loss, and pain

sources. Additionally, determining if the symptoms are bilateral can be important in making the proper diagnosis, especially in blocks that have the potential for neural-axial spread.

Physical Examination. A careful physical examination of the patient with possible nerve injury is critical in making the proper diagnosis. This examination may reveal unrecognized explanations for the nerve injury other than the peripheral nerve block. The physical examination should include evaluation of strength, pin prick, fine touch, position sense, and reflexes. Evaluation for a sensory level in the abdomen or chest should be performed if neuraxial involvement is suspected. If muscle atrophy occurs on the first postoperative day, a preexisting condition is the most probable cause. Herniated discs can also occur after anesthesia, and it is worth evaluating the patient for clinical manifestations of the common radiculopathies.

Electrophysiologic Studies. Physiologic studies may be the next logical step in the evaluation of a peripheral nerve injury. EMG and nerve conduction studies can help localize a lesion found on physical examination (EMG studies rarely localize lesions that were not found first by physical examination) and may add some insight into the etiology of the nerve injury. However, the location of some nerves blocked by regional anesthesia procedures, such as the lumbar plexus block, makes them inaccessible to practical testing. In addition, EMG studies may be normal for up to 2 weeks after a nerve lesion.

Sensory-motor nerve conduction studies and EMG are the basic techniques used in electrodiagnosis to help determine the location and type of nerve lesion. Nerve conduction studies can be performed on either sensory or motor nerves. In either case, a nerve is stimulated and a response is recorded either in the innervated muscle

(motor conduction studies) or over another portion of the stimulated nerve (sensory nerve conduction studies). The latencies, amplitudes, conduction velocities, and direct evoked responses are recorded. Proximal nerves can be stimulated with a needle placed cutaneously through to the nerve root if a proximal nerve lesion is suspected. Conduction loss noted through a section of the nerve is suggestive of nerve damage localized to that section. Reduced amplitudes of evoked responses are seen in both axonal loss and demyelination. In axonal nerve injury, the latency of the impulse has minimal change. Compression injury usually causes a demyelination pattern on nerve conduction studies. Sensory studies are particularly helpful in the diagnosis of radicular nerve injury from a herniated disc.

Needle EMG is performed using a small needle electrode inserted into the muscle. At 10 to 14 days after muscles are denervated, changes in insertional activity, fibrillations, and fasciculations are appreciated on EMG.

Radiographic Studies. Neuroimaging—typically magnetic resonance imaging, computed tomography (CT) scans, bone scans, and (rarely) angiography—can be helpful in localizing a peripheral nerve lesion. Magnetic resonance neurography (MRN), a relatively new technique, is highly sensitive in detecting lesions in the peripheral nerves. MRN technology may someday provide images of such quality that the etiology of the injury can be identified visually. Likewise, improved ultrasound imaging technology may also advance diagnosis of nerve lesions.

TREATMENT OPTIONS

Treatments for neuropathies after regional anesthesia are either conservative or surgical. If severe nerve dysfunction occurs after peripheral nerve block, and the lesion has been localized by physical examination, neuroimaging, and electrophysiologic tests, surgical correction of the lesion should be considered. Based upon a retrospective series of 119 surgically treated femoral nerve lesions by Kim et al (2004), operative exploration in patients failing to demonstrate improvement on EMG at 3 to 4 months is recommended. Operative exploration of the nerve should include examination of the nerve by direct visualization and electrodiagnostic studies in the operating room. If conduction block is noted, a neurolysis including resection of the neuroma and reapproximation of the nerve and its fascicles should be performed. This procedure will enable healthy axons to grow slowly down the nerve within each fascicle. If no immediately reversible etiology is found, a physical therapy program should be instituted, with strength training and range-of-motion exercises to minimize contracture and muscle atrophy. Electrodiagnostics should be repeated at 6 weeks, 3 months, and 6 months after the event.

CONCLUSION

With the increasing use of regional anesthesia, providers must be prepared to evaluate patients for neurologic complications. What makes these rare regional anesthesia complications so unsettling is that the risk of permanent neurologic damage associated with the technique is often out of proportion to the surgical risk incurred by the patient. However, the benefits of regional anesthesia experienced by the vast majority of patients, particularly from a postoperative pain perspective, justify use of the procedure. The majority of neurologic injuries noted after regional anesthesia are not secondary to the block but result from pre-existing conditions, patient positioning, or from the surgery itself. Nevertheless, anesthesia providers will increasingly be called upon to evaluate nerve injury patients for diagnosis and treatment. The best defense against nerve injury induced by regional anesthesia is following proper procedures: slow, careful needle technique; spare use of epinephrine; and careful physical examination of the patient prior to the block.

Despite the great benefits regional anesthesia offers to patients, providers faced with a neurologic complication may be tempted to think, "If I had just done a general anesthetic, I would not have this problem." However, general anesthesia involves different rather than reduced risk. Through continued study and experience in regional anesthesia, the significant benefits of this technique can be achieved with maximal safety to patients.

26. ACUTE PAIN MANAGEMENT IN THE FIELD

INTRODUCTION

The management of pain in an austere environment depends on trained personnel who are motivated to aggressively treat acute pain. Efforts to improve perioperative pain management have centered on the development of acute pain service (APS) teams of healthcare professionals, usually directed by an anesthesiologist, who are organized and committed to the management of acute pain. The adoption of the APS model for effective pain management in austere environments by the US military is a logical approach. Without medical personnel tasked specifically with the APS function, pain treatment would revert to the low priority it has traditionally been given by surgeons and anesthesiologists. This is particularly true in the chaotic, high-stress, mass casualty medical environment of the battlefield or disaster scene.

Effective perioperative pain management depends on a multimodal approach to analgesia. Multimodal analgesia refers to the concept of using multiple analgesics and pain control technologies with different mechanisms of action. Not only will these components act synergistically to improve overall pain control, but this approach may also minimize the unwanted and possibly dangerous side effects of large doses of one medication. A significant advantage of multimodal analgesia in austere environments is the lower total dose needed for

each drug component. Additionally, the multimodal analgesic approach offers a departure from the traditional opioid-only option in field medicine.

The following discussion and recommendations on commonly available pain medications is predicated on the existence of an APS. These guidelines are not intended to supersede medication package insert information or the physician's training in prescribing pain medication. The guidelines presented in this chapter are intended to serve as a starting point, but the physician must individualize acute pain care to each patient's needs and according to the environmental conditions.

OPIOIDS

Morphine remains the gold standard analgesic to which all other medications are compared. The ease of morphine administration following the invention of hollow hypodermic needles and syringes in the 1850s enhanced use and acceptance of the drug as an effective treatment for traumatic pain. The use of morphine for pain was widespread during the American Civil War (1861–1865) and Franco-Prussian War (1870–1871), but a lack of understanding of opioid use and side effects led to morphine addiction in many soldiers (known as “soldier's disease”). Despite the potential for life-threatening side effects, the success of opioids in treating pain in field medicine is beyond dispute. The challenge is to develop acute pain protocols and technologies that emphasize the beneficial pain relief properties of opioids while minimizing their side effects.

Casualty care advances in patients emerging from the conflicts in Iraq and Afghanistan have changed pain management attitudes and practices in the field environment. Although the lethality of weapons and severity of wounds continue to increase, casualty survival has never been higher. US military casualties from Iraq and Afghanistan currently have a 90% survival rate, compared to 76% during the Vietnam War, 67% during the Civil War, and 58% during the Revolutionary War. The increased survival rate results from many factors, including emphasis on early, advanced, far-forward surgical care; improved surgical and critical care techniques; availability of blood products; advances in body armor; and rapid ground and air evacuation to major medical facilities within and outside of the war zone. The rapid movement of casualties in particular has rendered opioid-based pain management protocols less appealing: the crowded, low-light, deafening, jolting, environment of evacuation aircraft makes monitoring difficult and magnifies the difficulties of opioid-only pain control therapy. Healthcare providers in this situation are less likely to use adequate doses of morphine because of valid patient safety concerns. The high numbers of healthcare providers in the evacuation chain and long evacuation distances further complicate opioid use. Many of these issues can be addressed by a multimodal pain therapy protocol, tailored to the austere medicine scenario, in which opioids are only part of the overall pain medication plan (Tables 26-1 and 26-2).

TABLE 26-1
SUGGESTED DOSAGES OF OPIOIDS FOR ACUTE PAIN CONTROL IN THE 70-KG OPIOID-NAIVE MILITARY CASUALTY

Opioid	Intravenous/ Intramuscular*	PCA [†]	Oral	Epidural [‡]	Intrathecal [‡]	Plasma Half-life	Comments [§]
Morphine	5–15 mg every 3–4 h	1–2 mg every 6–12 min	10–30 mg every 2–3 h	1–4 mg	100–300 µg	3 h (1–5 h)	Principal medical alkaloid of opium; causes active metabolites, respiratory depression, and increased intracranial pressure
Hydro- morphine	2–3 mg every 3–4 h	0.2–0.8 mg every 8–12 min	2–3 mg every 4–6 h	0.5–1 mg	100–200 µg	2–3 h	Semisynthetic opioid, approximately 5 times more potent than morphine and a useful alternative
Fentanyl	25–100 µg every 5 min titrated to effect at bedside	25–50 µg every 8–12 min, rare applications	Sublingual preparation available	50–100 µg	12.5–25 µg	7 h (3–12 h)	Synthetic; novel delivery technologies are in development
Meperidine	75–150 mg every 2–3 h	10 mg every 6–12 min, rare applications	100–300 mg every 3 h	NA	NA	3–5 h	Toxic metabolite normeperidine can lead to seizures; increased risk of abuse due to rapid onset and associated “rush”
Methadone	5–10 mg every 8–12 h short term use	NA	5–15 mg every 8–12 h short- term use	NA	NA	24–36 h	Synthetic; exhibits NMDA receptor antagonist activity; long half-life provides more stable analgesia compared to more frequently dosed opioids; usually reserved for level 4 use
Codeine	15–60 mg every 4 h IM only	NA	30–60 mg every 4 h	NA	NA	2–4 h	Antitussive; combined with acetaminophen as Tylenol-3 [¶] ; ineffective in 10% of Caucasians
Oxycodone	NA	NA	10–20 mg every 4–6 h	NA	NA	3–4.5 h	Combined with aspirin as Percodan [¶] and acetaminophen as Percocet ^{**} ; high abuse potential
Tramadol	50–100 mg every 4–6 h	NA	50–150 mg every 4–6 h	NA	NA	5–7 h	Respiratory depression is not a common side effect; can decrease the seizure threshold

*Generally, the intramuscular administration of opioids should be avoided in favor of intravenous administration.

[†]PCA is a preferred method for opioid pain control when equipment is available and the patient is able to operate the PCA device.

[‡]Epidural/intrathecal infusions of narcotics should be avoided in patients who may be transported to the next level of care within 24 hours.

[§]Naloxone is an opioid antagonist that reverses systemic opioid effects (analgesia, sedation, respiratory depression, etc) and should be available when opioids are used. Naloxone doses (0.2–0.04 mg) are titrated to desired effect every 2 to 3 minutes. The effect is dose dependent, lasting 20 to 60 minutes.

[¶]Johnson & Johnson, New Brunswick, NJ.

[¶]DuPont Pharmaceuticals, Wilmington, Del.

^{**}Endo Pharmaceuticals, Chadds Ford, Pa.

IM: intramuscular

NA: not applicable

NMDA: *N*-methyl *D*-aspartate

PCA: patient-controlled analgesia

TABLE 26-2
EQUIANALGESIC OPIOID CONVERSION

Opioid	Intra-venous (mg)	Oral (mg)	Epidural (mg)	Intrathecal (mg)
Morphine	1	3	0.1	0.01
Hydro-morphone	0.2	0.6	0.02	0.002
Meperidine	10	3	NA	NA
Fentanyl	0.01	0.03	0.001	0.0001

NA: not applicable

N-METHYL D-ASPARTATE RECEPTOR ANTAGONISTS

Of the *N*-methyl *D*-aspartate (NMDA) antagonists, ketamine is the most commonly used and well-known example for use in austere conditions. It has been used extensively and exclusively for anesthesia in war casualties in a variety of conflicts and conditions. Ketamine's cardiovascular stimulating and bronchodilatory activity coupled with its profound amnestic and analgesic properties make it particularly useful in austere environments. For perioperative pain management, ketamine has been shown to provide an additive analgesic effect when used with other medications preemptively, in epidural catheters, and as an intravenous infusion following major surgery. Small-dose ketamine has been found to be a safe adjuvant to opioids when reduced narcotic use is desirable. A common concern among providers is ketamine's association with bad dreams, hallucinations, dizziness, dysphoria, disorientation, and confusion. However, recent evidence indicates no significant increase in central nervous system symptoms in patients receiving ketamine (via patient-controlled analgesia, intravenous infusion, continuous intravenous infusion, or epidural) compared to patients receiving opioids alone. Subanesthetic concentrations of ketamine can provide postoperative antihyperalgesia, analgesia, and an opioid-sparing effect when used in combination with opioid medications (Table 26-3).

TABLE 26-3
SUGGESTED DOSAGES OF KETAMINE FOR ACUTE PAIN CONTROL IN THE MILITARY CASUALTY*

Route	Dosage
Intravenous/Intramuscular	150–300 μ g/kg loading dose
Continuous infusion	1–14 μ g/kg/min
Oral	0.5 mg/kg
Epidural	30–60 mg
Intrathecal	NA

*The more active *S*-ketamine enantiomer is available. Ketamine is underutilized for acute pain control. Plasma half-life is 2.5 to 3 hours.
NA: not applicable

α_2 -ANTAGONISTS

Clonidine and dexmedetomidine are α_2 -adrenergic agonists that can produce a significant analgesic effect when used alone or in combination with other analgesics, without the respiratory depression associated with opioids. Clonidine's analgesic properties have been demonstrated whether the drug is administered intravenously, intrathecally, epidurally, intraarticularly, or as an adjunct to local anesthetics in a peripheral nerve block. The versatility of clonidine in providing anesthesia in a variety of clinical scenarios suggests it would be a useful addition to the field medicine medication list (Table 26-4). Dose-related side effects of clonidine include hypotension, bradycardia, and sedation. Dexmedetomidine, which is seven times more selective for α_2 -adrenergic receptors though of shorter duration than clonidine, has also been used for perioperative pain management, although profound sedation can complicate its use. One important consideration when using these medications in austere conditions is their propensity to suppress thermoregulatory responses, thus promoting the development of hypothermia.

TABLE 26-4

SUGGESTED DOSAGES OF α_2 -ADRENERGIC RECEPTOR AGONISTS FOR ACUTE PAIN MANAGEMENT IN THE MILITARY CASUALTY

α_2 -Adrenergic Receptor Agonist	Intravenous/ Intramuscular	Continuous Infusion	Oral	Epidural	Intrathecal	Plasma Half- life	Comments
Clonidine*	2–5 $\mu\text{g}/\text{kg}$	0.3 $\mu\text{g}/\text{kg}/\text{h}$ following loading bolus	2–5 $\mu\text{g}/\text{kg}$	3 $\mu\text{g}/\text{kg}$ added to local anesthetic	15–30 μg added to local anesthetic	12–16 h	Hypotension, sedation, and bradycardia are important side effects; additive effect when used with opioids
Dexmedetomidine	1 $\mu\text{g}/\text{kg}$	0.4 $\mu\text{g}/\text{kg}/\text{h}$ following loading bolus	NA	NA	NA	2 h	Pure α_2 -adrenergic agonist; increases incidence of sedation and bradycardia

*Clonidine, 1 $\mu\text{g}/\text{kg}$, added to local anesthetic injected for peripheral nerve blocks prolongs block analgesia with minimal (sedation) to no side effects. NA: not applicable

NONSTEROIDAL ANTIINFLAMMATORY DRUGS

Nonsteroidal antiinflammatory drugs (NSAIDs) are an important class of medications for austere environment analgesia when used as part of a multimodal pain management plan (Table 26-5). Acetaminophen (paracetamol) lacks some of the side effects associated with other NSAIDs, such as impaired platelet function, renal function, and bone growth. Although weak when used alone, acetaminophen enhances the analgesic effects of other NSAIDs and morphine when used concurrently. Oral NSAIDs block prostaglandin synthesis by inhibiting cyclooxygenase enzyme (COX) 1, thus reducing the inflammatory as well as the nociceptive response following injury (type 1 evidence). Newer (COX-2) NSAIDs lack the antiplatelet effects of the COX-1 NSAIDs, but have similar analgesic effects. Prolonged use of the COX-2 NSAIDs is controversial because of concerns over increased cardiovascular events.

However, COX-2 NSAIDs decrease the possibility of respiratory depression and over-sedation, and for short-term use in a field setting, their advantages as adjunct analgesics for reducing opioid requirements far outweigh their disadvantages. Long shelf-life, ease of transport, and low abuse potential are additional benefits of NSAIDs in an austere environment. Some US military units have developed “wound packs” containing acetaminophen, a COX-2, and a fluoroquinolone, which the soldier is instructed to consume following a penetrating extremity wound. This approach is too new to determine its effectiveness, but the concept of prepackaged pain medications for use under defined conditions during war or disaster warrants further research and development. Parenteral preparations of NSAIDs, which further the potential utility of these medications in field medicine, are also available.

TABLE 26-5

SUGGESTED DOSAGES OF NONSTEROIDAL ANTIINFLAMMATORY DRUGS FOR ACUTE PAIN MANAGEMENT IN THE MILITARY CASUALTY

NSAID	Intravenous/ Intramuscular	Oral	Plasma Half-life	Comments
Acetaminophen	NA	325–1,000 mg every 4–6 h up to 3,000 mg/day	1–4 h	Does not produce gastric irritation or alter platelet aggregation; weak antiinflammatory; hepatotoxic in large doses
Ketorolac	30 mg, then 15–30 mg every 6 h	10 mg every 4–6 h	5 h	30 mg intravenous is equivalent to 10 mg of morphine; moderate antiinflammatory activity; may cause life-threatening bronchospasm in asthma patients
Acetylsalicylic acid (aspirin)	NA	325–650 mg every 4–6 h	2–3 h	Antipyretic; low intensity pain; effective platelet activation inhibitor; useful for acute angina or myocardial infarction; can induce asthma in up to 20% of asthma patients
Ibuprofen	NA	400–800 mg every 8 h	2 h	Low incidence of gastrointestinal side effects
Naproxen	NA	250–500 mg every 12 h	12–15 h	Longer half-life allows twice daily dosing
Indomethacin	NA	25–50 mg every 8 h	4.5 h	Potent antiinflammatory
Celecoxib	NA	400 mg loading dose followed by 100–200 mg daily	11 h	Highly selective COX-2 inhibitor; greater cardiovascular risk than other NSAIDs

COX: cyclooxygenase

NA: not applicable

NSAID: nonsteroidal antiinflammatory drugs

ANTICONVULSANTS

Anticonvulsant medications such as gabapentin and pregabalin (in addition to the NMDA receptor antagonists already mentioned) are used in acute pain management as antihyperalgesic drugs to prevent the induction and maintenance of pain sensitization of the spinal cord dorsal horn and peripheral nerves following trauma (Table 26-6). In theory, preemptive analgesia, using a multimodal approach, can prevent or at least attenuate the unwanted neurophysiological and biochemical consequences of untreated pain. Gabapentin at a total dose of 3,000 mg in the first 24 hours following abdominal hysterectomy has been shown to significantly reduce morphine consumption with minimal side effects. Although definitive evidence is lacking, research has suggested that gabapentin use with other analgesic medications may protect the patient from central sensitization to pain following surgery. Gabapentin and pregabalin are currently used routinely in the pain management of US military casualties returning from Iraq and Afghanistan. Available evidence supports the inclusion of these medications in a field pain medicine plan.

TRICYCLIC ANTIDEPRESSANTS

Tricyclic antidepressants have been used to manage neuropathic pain for more than 20 years. Medications of this class act through the inhibition of norepinephrine and serotonin reuptake into postganglionic sympathetic nervous system nerve endings, enhancing the antinociceptive effects on these neurotransmitters. These medications are occasionally used following traumatic injury in combination with other pain medications as part of a multimodal approach. Early application of tricyclic antidepressants may have some benefit in preventing acute pain progression into chronic pain states (Table 26-7).

TABLE 26-6

SUGGESTED DOSAGES OF ANTICONVULSANTS FOR ACUTE PAIN MANAGEMENT IN THE MILITARY CASUALTY

Anticonvulsant	Oral Dosage	Plasma Half-life	Comments
Gabapentin (Neurontin*)	100–300 mg every 8 h gradually increased as needed up to 3,600 mg daily in 3 divided doses	5–7 h	Therapeutic effect on neuropathic pain believed to be due to action on voltage-gated N-type calcium ion channels; somnolence and fatigue are side effects; does not appear to interact with other medications
Pregabalin (Lyrica*)	75 mg every 12 h increased as needed up to 300 mg in 2 divided doses	5–6 h	Similar to gabapentin but more potent; fewer dose-related side effects

*Pfizer Inc, New York, NY

TABLE 26-7

SUGGESTED DOSAGES OF TRICYCLIC ANTIDEPRESSANTS FOR ACUTE PAIN MANAGEMENT IN THE MILITARY CASUALTY

Tricyclic Antidepressant	Oral	Plasma Half-life	Comments
Amitriptyline (Elavil*)	10–150 mg daily	12–24 h	Anticholinergic and sedative side effects; will enhance the response to other central nervous system depressants
Nortriptyline	25 mg every night up to a maximum of 150 mg every day	18–60 h	Fewer side effects; overactive or agitated patients may exhibit greater agitation

*Zeneca Pharmaceuticals, Wilmington, Del.

OTHER PAIN MEDICATIONS

Other nonopioid medications, such as adenosine, droperidol, magnesium, neostigmine, and opioid antagonists, have been successfully used in the management of postsurgical pain. However, the clinical advantages and disadvantages of these unconventional therapies will require further clarification before recommendations for use in an austere medical environment can be made. In addition to peripheral nerve blocks, local anesthetics can be very effective in the management of pain through subcutaneous injections around a wounded area or direct infusion into a wound using a catheter.

FUTURE PAIN CONTROL METHODS AND EQUIPMENT

Considerable effort to find methods other than intravenous morphine for pain management in battlefield scenarios has been made. Although the effectiveness of intravenous morphine is without question, the equipment and expertise to establish intravenous access may be lacking in austere battlefield or natural disaster situations. A possible alternative is transdermal delivery of fentanyl citrate, and a promising delivery device is the patient-controlled transdermal delivery system for fentanyl hydrochloride.

The credit-card-sized device is placed on the patient's skin with adhesive and activated by the patient pushing a button. The device then delivers a 40- μg fentanyl dose over a 10-minute period through a process of iontophoresis (the introduction of medication into tissue through means on an electric current). Unlike transdermal fentanyl patches that continuously deliver medication passively and are inappropriate for opioid naive patients, the patient-controlled transdermal delivery system functions similar to a patient-controlled analgesia machine, and the two devices have been shown to be equally effective for perioperative pain control following major surgery. Oral transmucosal fentanyl is another delivery method with potential for use in austere environments. In 2003, 22 soldiers involved in the Iraq conflict were treated after mild injury with oral fentanyl lozenges (1,600 μg) in a field setting. The treatment was effective, although three soldiers complained of nausea and one required naloxone for hypoventilation, emphasizing that novel delivery systems for opioids do not eliminate the potential dangerous side effects of these drugs.

The administration of ketamine or hydromorphone intranasally using unit-dose nasal applicators has received substantial attention by the military for far-forward pain control following injury. Opioid

use for pain can significantly degrade a soldier's ability to continue the mission because of its sedative effects. Theoretically, low-dose ketamine delivered intranasally reduces pain without substantially degrading performance. Although intranasal ketamine has been used successfully for breakthrough pain in chronic pain patients with minimal side effects, its abuse potential and possible cognitive effects in a high-stress environment warrants further study before recommendations on use in austere environments can be made. Intranasal delivery of hydromorphone does not change the side effects associated with opioids; however, this novel delivery system does not require intravenous access, which could be advantageous on the battlefield.

Finally, nonpharmacologic management of pain through proper splinting of fractures and protection of wounds from further jostling or impact is a vital consideration in any acute pain management plan. This is especially true during patient transport, when inadvertent impact or vibration can lead to extreme discomfort. The psychological benefits derived from healthcare provider attention to patient comfort during evacuation can greatly enhance the effectiveness of the multimodal pain care plan.

27. IMPROVING SURGICAL PAIN MANAGEMENT WITH MULTIDISCIPLINARY CARE

INTRODUCTION

For the last 2 centuries, morphine has been the single most relied-upon drug for the management of acute surgical pain. Fortunately, modern advances in anesthesia and analgesia have revolutionized this pain management approach. Today, multidisciplinary treatment plans have been identified as a principal factor in both modern-day pain control and optimization of recovery after surgery. Despite numerous medical and technological advances, post-surgical pain is often undertreated. An understanding of the physiology and complex, multifaceted nature of pain is necessary to identifying an optimal treatment plan, which often involves multiple therapeutic modalities. This balanced analgesic approach, known as multimodal analgesia, utilizes a combination of opioid and nonopioid analgesics that target different sites of the peripheral and central nervous system. The aim of multimodal analgesia is to optimize postoperative pain control while limiting the total amount of opioid administered to the patient, thereby minimizing adverse drug effects. This chapter will discuss recent advances in pain management and perioperative care that can improve the quality of postoperative recovery and reduce morbidity after major surgery.

PATHWAYS AND TYPES OF PAIN

The transduction of noxious stimuli involves both the peripheral and central nervous systems. It begins with peripheral nociceptors, which transmit signals along peripheral nerves through the dorsal root ganglia (Figure 27-1). Axons of myelinated A and unmyelinated C fibers synapse in the dorsal horn of the spinal cord, and pain signals are transmitted to the thalamus and cerebral sensory cortex via the ascending spinothalamic tracts. Descending modulation of pain is mediated through the dorsal

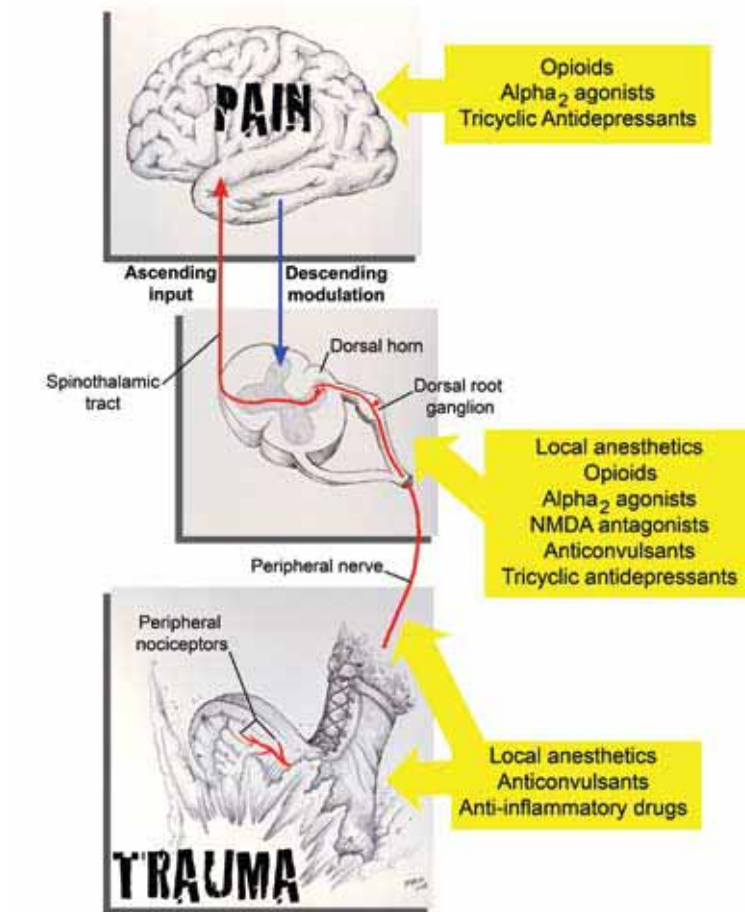


Figure 27-1. Transmission of pain signals

horn neurons. Medications used to manage pain act at specific areas along this pathway to reduce the intensity of the pain experience.

The different types of pain include somatic, visceral, inflammatory-mediated, and neuropathic pain. Each type responds to different treatment modalities; understanding their distinctions will aid in developing specific therapeutic interventions to maximize patient benefit. Optimal pain management requires a careful appraisal of the source of

pain, coupled with an appropriate selection of treatments for each patient. Complex pain cases require multimodal as well as interdisciplinary care. Coordination among healthcare providers before, during, and after a surgical procedure is a critical component of successful operative pain management.

Somatic and visceral pain result from stimulation of sensory receptors or nociceptors in response to noxious stimuli; they are distinguished by the location of their receptors and the nerve fibers that are stimulated. Somatic pain receptors are located within the skin and respond to environmental cues such as sharp, focused, painful stimuli. Examples of this type of pain include incisional or cutaneous burn-related pain. Visceral receptors are located in visceral organs (bladder, ureter, small and large bowel, etc) and respond to internal cues such as dilation of the bowel or inflammation from infection. Visceral fibers are slow-conducting unmyelinated C fibers that join autonomic and somatic nerves entering the central nervous system. Visceral pain can either be localized to the site of tissue damage or be

sensed at a distant anatomic region from the source of tissue injury, a phenomenon called “referred pain.” Neuropathic pain is related to the sensory perception of pain associated with peripheral or central nerves. Nerve injuries caused by stretching, compression, or cancer invasion are often the precursors to neuropathic pain, and may pose formidable treatment challenges.

Inflammatory mediators have been identified in pain pathways. Substance P, a neurotransmitter

involved in the perception of pain, is also a mediator in the neuroinflammatory cascade. Interferons and cytokines (interleukin-1, interleukin-6 and tumor necrosis factor- α) are proinflammatory mediators thought to decrease the threshold for pain stimulation and increase the intensity of the response. Interruption of the inflammatory cascade is a potential adjunct for achieving optimal pain control.

PREOPERATIVE PATIENT ASSESSMENT

An adequate history and physical examination are critical to identifying the cause of a patient's pain as well as ensuring that appropriate treatment modalities are employed (Table 27-1). Assessment of pain should include several factors: location, severity, quality, radiation, duration of onset, aggravating and mollifying events, and associated symptoms. The healthcare provider must ascertain whether or not the patient experiences chronic pain or takes chronic medications such as narcotics, nonsteroidal antiinflammatory drugs (NSAIDs), anxiolytics, or gabapentin. Patients with chronic pain or history of opioid use or drug abuse may have a tolerance of narcotic-based pain medications and may require substantially greater doses of narcotics than opioid-naïve patients. Conversely, others may limit the amount of pain medication they take because of fear of drug dependency.

Acute, severe, and undertreated pain is associated with many adverse systemic effects including increased myocardial oxygen demand, reduced functional residual capacity, hypoxemia, and gastrointestinal ileus. Some patients with severe, poorly controlled operative site pain may develop long-term central sensitization. This condition may serve as the basis for chronic pain syndromes wherein noxious stimuli are accompanied by an exaggerated pain response, or hyperalgesia, and painless stimuli are perceived as painful, a phenomenon known as allodynia.

TABLE 27-1

PREOPERATIVE MEASURES TO ASSESS AND CONTROL PAIN

-
- History and physical examination
 - specifics about pain: location, severity, quality of pain, radiation, onset and duration, aggravating and mollifying factors, and associated symptoms
 - history of chronic pain
 - medications: opioids, NSAIDs, anxiolytics, gabapentin, narcotics, antidepressants
 - history of drug use and abuse
 - Patient education and reassurance that pain will be controlled
 - Consider anxiolytics: midazolam (1–5 mg) 10 minutes prior to procedure
 - Preemptive pain control
 - regional anesthesia with peripheral nerve blocks
 - neuraxial blockade (spinal, lumbar epidural, and thoracic epidural)
 - systemic medications (NSAIDs, opioids)
-

NSAID: nonsteroidal antiinflammatory drugs

PAIN CONTROL AT EACH OPERATIVE STAGE

Preoperative. The physiologic response to surgery involves a “sympathetic surge,” a profound activation of the sympathetic nervous system that is thought to contribute to afferent pain signals. This stress response is a well-established sequence of physiologic and molecular events that include fever, tachycardia, tachypnea, hypertension, gastrointestinal ileus, hypercoagulability, protein catabolism, and immunosuppression. Circulating cytokines and neuroendocrine mediators are also involved. The response lasts approximately 3 to 4 days from the

time of induction of general anesthesia.

The goal of preemptive pain control is to blunt the physiologic response to surgery as well as to decrease the level of overall pain. Specifically, effective preemptive analgesia reduces the surgical nociceptor input (pain) while simultaneously preventing an ensuing sensitization of the nervous system throughout the perioperative period. The efficacy of preemptive multimodal analgesia depends on the interruption of the transduction of noxious stimuli at multiple sites along the pain pathway. Sites targeted by preemptive analgesia include peripheral nociceptors, preganglionic peripheral nerves, the dorsal horn of the spinal cord, and the sensory cortex and limbic system (see Figure 27-1).

Adequate arterial perfusion and partial pressure of oxygen are critical to tissue healing, and vasoconstriction is a threat to normal healing. Measures to control peripheral vasoconstriction should be initiated prior to the operation and include cessation of smoking; controlling fear, pain, and anxiety; correcting hypertension; maintaining normal circulating blood volume; and maintaining normothermia. Preoperative reassurance that pain will be treated aggressively should be a goal of all members of the operative team. Administration of an anxiolytic at least 30 minutes before surgery has been shown to decrease both anxiety and postoperative pain throughout the first postoperative week in a randomized placebo-controlled trial of patients who had outpatient surgery under general anesthesia.

The use of perioperative NSAIDs in preemptive analgesia is preferred over narcotics to limit adverse side effects (nausea, vomiting, urinary retention, cognitive dysfunction, respiratory depression). The use of NSAIDs is often combined with infiltration of the wound with a long-acting local anesthetic (eg, bupivacaine). Continuation of NSAID analgesia for at least 24 hours after

surgery is considered essential in order to achieve effective postoperative control of peripheral nociceptive pain. In addition, NSAIDs may achieve a long-term effect by inhibiting sensitization of the central nervous system.

Intraoperative. Optimal preemptive pain control involves measures taken prior to the surgical incision, and continues into the postoperative period (Table 27-2). Injection of medications into the subcutaneous tissue underlying the intended incision site reduces postoperative analgesic requirements. Long-acting local anesthetics such as bupivacaine are most commonly used, but ketorolac, tramadol, and morphine have also been used for preincisional analgesia.

Operative site infection is an established potent stimulus for proinflammatory cytokines and chemokines. Prophylactic antibiotics are administered within 60 minutes of incision, re-dosed during major operations, and continued for 24 hours postoperatively. Operations undertaken for infectious etiology, such as abscess, cholecystitis, appendicitis, and diverticulitis, should focus on control of the pathologic source. Infectious complications can be minimized by expeditious surgery; gentle tissue handling; maintenance of normothermia, partial pressure of oxygen, and perfusion pressures; judicious use of antibiotic irrigation; avoidance of fluid overload; and changing gloves and instruments before wound closure. Sympatholytic effects of epidural anesthesia reduce the physiologic stress response to surgery, improve perfusion, reduce hypoxemia, limit blood loss (thereby decreasing transfusion requirements), counteract the prothrombotic state of surgery, and optimize pain control and secondary sensitization.

Meticulous surgical technique and hemostasis are fundamental aspects of postoperative pain control. Blood within the intraperitoneal cavity irritates the peritoneum and causes visceral pain.

TABLE 27-2

INTRAOPERATIVE MEASURES BY THE SURGEON TO CONTROL PAIN

-
- Preincision analgesia: subcutaneous injection prior to operation at incision site, use
 - bupivacaine (10–30 mL of 0.25%),
 - Prevention of infection and systemic inflammatory cascade, includes
 - preoperative antibiotics 60 minutes prior to incision (appropriate to operation)
 - expeditious surgery
 - gentle tissue handling
 - maintenance of normothermia
 - adequate tissue perfusion (minimizing peripheral vasoconstriction)
 - adequate tissue oxygen partial pressure
 - judicious use of antibiotic irrigation
 - avoidance of fluid overload
 - different gloves, instruments, and possibly gowns prior to closure of incision
 - Meticulous hemostasis (avoidance of operative site hematoma), prevents
 - visceral irritation
 - hematoma formation.
 - Intraoperative peritoneal or pleural administration of local anesthetics, use
 - bupivacaine (15 mL of 0.5% with 1:100,000 epinephrine; 2–5 mL per laparoscopic port site) or
 - ropivacaine (20 mL of 7.5 mg/mL; 4 mL per intercostal space)
-

Postsurgical hematomas that form in anatomically confined areas such as the groin continually stimulate peripheral nociceptors, resulting in pain that is difficult to control. Unless it is resorbed over time, a pain hematoma may require reoperation for surgical evacuation.

Blockade of afferent pain signals not only blunts pain but also reduces the amount of postoperative narcotic required, ultimately improving the quality of recovery. Intraperitoneal and intrapleural administration of local anesthetic has been shown to control visceral pain better than systemic medication. Recent advances in minimally invasive surgery have translated into smaller surgical incisions, reduced stress response and narcotic requirement, and decreased wound complications, all of which lead to a more rapid postoperative recovery.

Postoperative. Parenteral analgesics are commonly administered postoperatively, because patients are often restricted from oral intake after major surgery. However, fast-track rehabilitation is challenging the surgical dogma that restricts oral intake for prolonged periods until passage of flatus or stool has been achieved. Opioid medications (eg, morphine sulfate, fentanyl, Dilaudid [Abbott Laboratories, Abbott Park, Ill]) are among the most common perioperative analgesics administered because of their time-tested efficacy. However, adverse side effects including sedation, nausea, pruritis, and impairment of gastrointestinal motility, make preemptive analgesia an attractive alternative. Multimodal perioperative analgesia using several different drug mechanisms of action facilitates dose reductions in all the pain medications used and early discontinuation of narcotic analgesics, providing better analgesia while minimizing the unwanted side effects of any one drug class.

The method of narcotic delivery impacts the success of pain control. As needed,

nurse-administered medication may result in unacceptable gaps in postoperative analgesia and fail to establish a therapeutic baseline level of pain control. Intravenous patient-controlled anesthesia, which allows timely patient-directed narcotic administration, has a continuous baseline dosing function to limit the peaks of pain intensity in the postoperative period. Multiple studies have documented improved pain outcomes with patient-controlled anesthesia as compared to nurse-titrated medication, but no consensus has been reached about improvements in postoperative complications. Transdermal narcotic administration provides more consistent administration of medication but has a delayed onset of action.

SUMMARY

Comprehensive preoperative assessment by the surgeon and anesthesiologist is the key first step to optimizing operative outcomes. Many perioperative measures fundamental to optimizing patient outcomes are intuitive: gentle tissue handling, minimizing blood loss, preventing hypothermia, administering prophylactic antibiotics within 1 hour of incision, judicious antibiotic irrigation of contaminated sites, minimizing peripheral vasoconstriction, limiting use of drains, ensuring high arterial partial pressure of oxygen, minimizing fluid overload, limiting the physiologic stress response to surgery, and optimizing control of pain.

Emphasis on multidisciplinary approaches to pain management can significantly improve pain care plans beyond pharmacologic measures. Coordination among the primary team, anesthesia, acute pain nursing, pharmacy, mental health, physical and rehabilitative medicine, and the family is a vital component of any inpatient pain care activity. For example, although a dense block of a patient's upper extremity may provide excellent pain relief, if the patient has no motor function in the limb to participate in physical therapy, this modality may not be in the best interest of the patient's overall recovery and health. Effective acute pain management requires the existence of an acute pain service staffed with motivated professionals dedicated to the effective treatment of pain using a multimodal approach.

28. INTERVENTIONAL CHRONIC PAIN TREATMENT IN MATURE THEATERS OF OPERATION

IMPACT OF NONBATTLE-RELATED INJURIES AND TREATMENT

Acute nonbattle injuries (NBIs) and chronic pain conditions that recur during war have been termed the “hidden epidemic” by the former surgeon general of the US Army, James Peake. Since statistics have been kept, the impact of NBIs on unit readiness has increased. In World War I, NBI was the fourth leading cause of soldier attrition. In World War II and the Korean conflict, NBIs were the third leading cause of morbidity. By the Vietnam War, NBIs had become the leading cause of hospital admissions, where they have remained ever since. However, increasing evidence demonstrates that in-theater management of NBIs and recurrent chronic pain syndromes can improve return-to-duty rates.

The current system of military treatment levels, designed to facilitate the rapid evacuation of wounded soldiers based on their medical condition and needs, was developed in World War II—predating the establishment of pain management as a medical specialty. No personnel are currently deployed specifically for pain management (acute or chronic) at level-III combat support hospital (CSH) facilities in either Iraq or Afghanistan. Instead, anesthesiologists and other pain specialists are deployed in their primary specialties and are expected to provide pain management services as needed in addition to their regular full-time duties. This situation has resulted in a varying standard of pain management care in theaters of operation. The modern CSH has key infrastructure such as radiology services (eg, fluoroscopy, radiography, computed tomography) and full surgical, laboratory, and pharmacy support, which can facilitate chronic pain clinical services if properly staffed.

The most common presenting complaints of NBI during Operation Iraqi Freedom have been radicular leg pain, axial low back pain (LBP), nonradicular leg

pain, nonradicular arm pain, groin pain, noncardiac chest pain, and neck pain. The most common diagnoses conferred on these patients were lumbosacral radiculopathy, recurrence of postsurgical pain, lumbar facetogenic pain, myofascial pain, neuropathic pain, and lumbar degenerative disc disease.

The most common noninterventional treatments have been nonsteroidal antiinflammatory drugs (NSAIDs; > 90%); physical therapy referral (for back pain, neck pain, and leg pain); muscle relaxants (for

spinal and myofascial pain); and anticonvulsants and tricyclic antidepressants (usually prescribed for radicular and other forms of neuropathic pain). The large majority of patients received at least one interventional procedure. The most frequently employed nerve blocks were lumbar transforaminal epidural steroid injections (ESIs), trigger point injections, cervical ESIs, lumbar facet blocks, various groin blocks, and plantar fascia injections. Table 28-1 lists procedures for common nerve blocks conducted in

TABLE 28-1
PROCEDURES FOR COMMON NERVE BLOCKS CONDUCTED IN THEATER

Injection	Injectate Volume* (mL)	Need for Fluoroscopy?	Comments
Cervical ESI	2–4	Yes	Use of local anesthetic controversial. Cervical TFESI may result in death or paraplegia and should not be done in austere environment.
Interlaminar lumbar ESI	3–5	Strongly advised	Performing blind ESI associated with a high likelihood of injectate failing to reach targeted area.
Transforaminal lumbar ESI	2–3	Yes	Superior outcomes compared to interlaminar ESI.
Intraarticular facet blocks	Cervical: 1 Lumbar: 1–2	Yes	Likelihood of relief higher in patients with acute inflammatory process.
Trochanteric bursa injection	3–5	No	Similar outcomes for fluoroscopically and landmark-guided injections.
Sacroiliac joint block	2–4	Yes	< 25% chance of intraarticular spread in landmark-guided injections.
Lateral epicondylar injection	0.5–1.5	No	Mixed results for treatment.
Subacromial bursa injection	4–10	Advised	May use posterior or anterolateral approach; 50%–80% accuracy rate for blinded injections.
Piriformis muscle injection	3–8	Yes	May use nerve stimulator to locate sciatic nerve (adjacent to muscle) if fluoroscopy is not available. Injection of local anesthetic may cause sciatic nerve weakness.
Carpal tunnel injection	1–2	No	Not superior to NSAID treatment after 2 months.
Greater occipital nerve injection	2–4	No	Difficult to clinically distinguish from referred cervical pain.

ESI: epidural steroid injection. NSAID: nonsteroidal antiinflammatory drug. TFESI: transforaminal epidural steroid injection.

*Volume of injectate consists of 1 to 2 mL of depot (long-acting) corticosteroid plus local anesthetic.

theater. Significantly, when treated in theater, 94.7% of soldiers returned to their units. Differences in return-to-duty rates support aggressive pain management in forward-deployed areas.

TRIAGING PATIENTS FOR TREATMENT

As a result of limited pain management resources, coupled with the risk involved with soldier transport, healthcare providers must triage NBI pain patients based on the anticipated risk-benefit ratio. Soldiers with acute or recurrent overuse injuries (eg, tendonitis or bursitis) can usually be handled at a level I facility such as a battalion aid station. For soldiers who require more sophisticated interventions, the battalion or brigade surgeon must decide whether a medical evacuation to a CSH is warranted. This decision is based upon several factors: the likelihood of quick resolution of the pain issue, the soldier's motivation to remain in theater, the soldier's military occupational specialty, the probability of recurrence, the commander's desire to keep the soldier in theater, the treatment capabilities at the CSH, and the risk of medical evacuation.

CHRONIC PAIN CONDITIONS ENCOUNTERED IN THE FIELD

Low Back Pain. LBP is the most common complaint likely to be encountered by the pain practitioner deployed to the CSH. Its high incidence is probably caused by a combination of factors encountered in theater: the heavy loads service members must carry, frequent transportation over rough terrain in military vehicles with stiff suspensions, heavy individual body armor, sleep deprivation, and the high degree of psychosocial stressors faced by soldiers deployed to combat zones. Among the various causes of LBP, radiculopathy from nerve root irritation may be the most commonly encountered condition.

A mainstay interventional treatment for LBP is ESI. ESIs exert their beneficial effects through their antiinflammatory properties, inhibition of the enzyme phospholipase A2, and suppression of ectopic discharges from injured neurons. Although ESIs have been successfully used to treat axial back pain, ideal candidates for the procedure are those with pain of less than 6 months' duration, leg pain greater than back pain, young age, intermittent pain, and absence of concomitant spinal stenosis. The use of fluoroscopic guidance is highly recommended for interlaminar ESIs and is required for transforaminal ESIs. ESIs performed without the fluoroscope have a high technical failure rate, even when performed by experienced practitioners. Transforaminal ESIs, although technically more challenging than interlaminar ESIs, are generally associated with superior outcomes because medication is deposited directly over the affected nerve root (Figure 28-1).

Patients suspected of radicular pain should receive computed tomography (CT) scans of the appropriate spine level. Whereas magnetic resonance imagery (MRI) is the gold standard for imaging soft tissue and disc anatomy, CT scans are sensitive at determining the presence of disc pathology. Although ESIs are considered by many practitioners to be the best interventional therapy for radicular pain, controversy exists regarding their long-term efficacy.

Zygapophyseal Joint Pain. Lumbar zygapophyseal (facet) joint pain accounts for approximately 15% of patients with chronic axial LBP. Typical presentation is a dull aching pain, usually bilateral, that radiates from the low back into the buttocks and thigh. Although the history and physical examination can be suggestive of facet joint pain, an analgesic response to fluoroscopically guided low-volume diagnostic blocks, of either the zygapophyseal joints themselves or the medial branches that innervate them, is the gold standard for diagnosis. The interventional treatment of facetogenic pain consists of either intraarticular injections with corticosteroid, which may benefit a small percentage of patients with an acute inflammatory component, or more frequently radiofrequency denervation of the nerves that innervate the painful joints. Because of the lack of radiofrequency capability, combination diagnostic/therapeutic intraarticular facet injections are recommended in theater. In patients with radiological evidence of an acute inflammatory process, intraarticular corticosteroids may afford up to 3 months of excellent pain relief (Figure 28-2).

Figure 28-1. Lateral fluoroscopic view demonstrating needle position for L4-5 transforaminal epidural steroid injection.

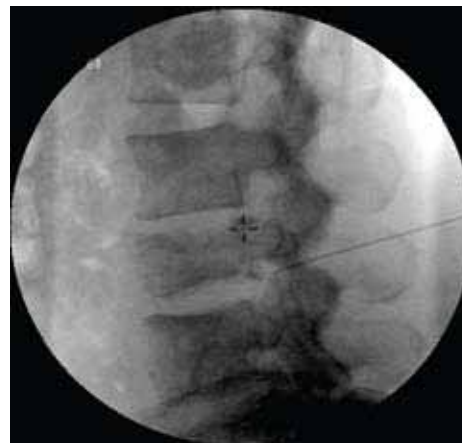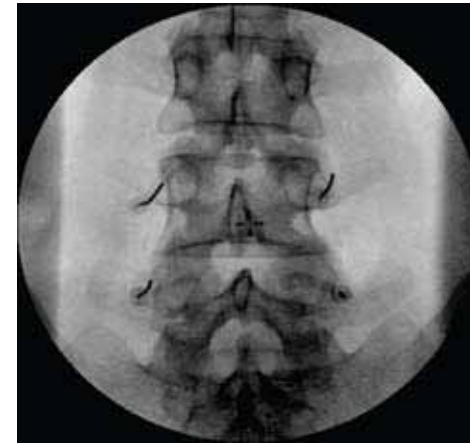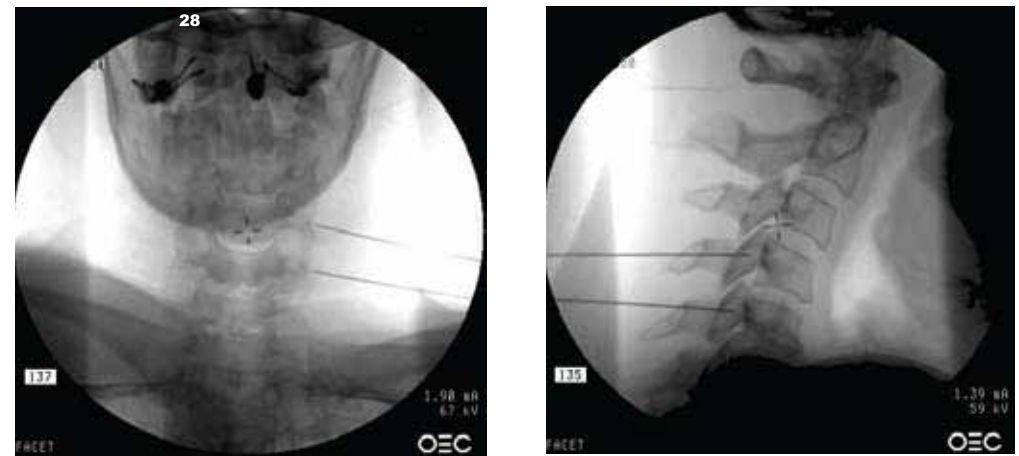


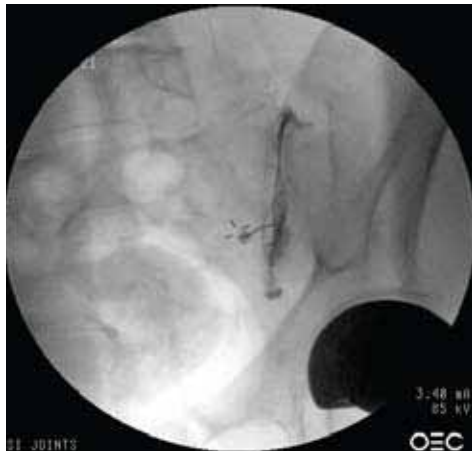Figure 28-2. Antero-posterior fluoroscopic view demonstrating needle position for bilateral L3 and L4 facet joint (medial branch) nerve blocks.



Sacroiliac Joint Pain. Sacroiliac (SI) joint pain is a frequent source of axial LBP, accounting for roughly 15% to 20% of cases. Compared to other causes of back pain, SI joint pain is more likely to result from a specific inciting event such as a fall, motor vehicle accident, or airplane jump. The primary pain generator in younger patients with documented SI joint pain tends to be extraarticular (ie, surrounding ligaments or muscles). The typical presentation of SI joint pain is a unilateral aching pain in the low back or buttock. SI joint pain, typically associated with tenderness overlying the affected joint, is often reproducible. In patients with SI joint pain, multiple studies have demonstrated good intermediate- to long-term pain relief with intraarticular or periarticular injections of corticosteroid with local anesthetic. Previous studies have demonstrated that radiographic guidance is necessary to achieve accurate placement in or around the joint (Figure 28-3).

Figure 28-3. Antero-posterior fluoroscopic view demonstrating a right side sacroiliac joint injection.



Figures 28-4 and 28-5. Antero-posterior and lateral fluoroscopic views demonstrating right-sided C4 and C5 facet joint (medial branch) nerve blocks.

Myofascial Pain. Myofascial pain accounts for a significant percentage of axial LBP cases, with an estimated prevalence of around 20%. Frequently, muscle spasm is superimposed on a more acute, underlying condition. The hallmark of treatment of myofascial pain is physical therapy to identify and treat the underlying cause, and pharmacotherapy with muscle relaxants and NSAIDs. When discrete bands of contracted muscle are palpable, trigger point injections can provide excellent relief.

Spinal Stenosis and Degenerative Disc Disease. Spinal stenosis and degenerative disc disease are other common causes of LBP, with a higher incidence among the elderly. Whereas ESIs can sometimes provide pain relief for these conditions, the benefit is often incomplete and transient. Less frequent sources of back and leg pain that need to be ruled out include osteomyelitis, vertebral fractures, and acute or worsening spondylolisthesis.

Cervical Spine Pain. An estimated 16% to 22% of adults suffer from chronic neck pain, with a higher prevalence seen in women. Among patients with chronic neck pain, approximately 30% report a history of neck injury, most commonly the result of a motor vehicle accident. In military pain clinics, neck pain and cervicogenic headaches account for about 10% to 15% of NBIs.

Numerous predisposing factors for neck pain are prevalent in soldiers, including prolonged static loads (from body armor), abnormal postures (secondary to body armor or in snipers), work-related stress, and full-force exertion. In patients with acute neck or upper thoracic pain, the etiology is likely to be myofascial in origin. In chronic axial neck pain or whiplash injury, the facet joints are the most common source of pain. Myofascial pain can be treated with muscle relaxants, NSAIDs, tricyclic antidepressants, short-term duty modification, and trigger point injections. For cervical facetogenic pain, intraarticular steroids can provide intermediate-term relief in patients with an acute inflammatory process (Figures 28-4 and 28-5).

Cervical radiculopathy typically manifests as neck pain radiating down one or both arms in a dermatomal distribution, sometimes accompanied by weakness and sensory changes. Similar to lumbar radicular pain, cervical radiculopathy can be treated with cervical ESIs (Figures 28-6 and 28-7). Because of reports of death and paralysis, cervical transforaminal ESIs are not recommended in an austere environment. Possible causes of cervicogenic headaches that may be amenable to injection therapy include atlantooccipital and atlantoaxial joint pain. Occipital neuralgia, a frequent cause of occipital headaches, is best diagnosed and treated with injections containing local anesthetic and corticosteroid (Figure 28-8).

Nonradicular Leg Pain. Nonradicular leg pain (eg, piriformis syndrome, plantar fasciitis, and greater trochanteric bursitis [TB]) accounts for approximately 10% of pain clinic visits from NBIs. Many of these conditions tend to be as-

Figures 28-6 and 28-7. Antero-posterior and lateral fluoroscopic views demonstrating a C5-6 epidural steroid injection.

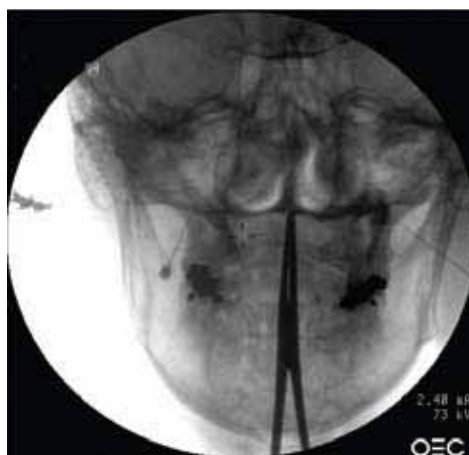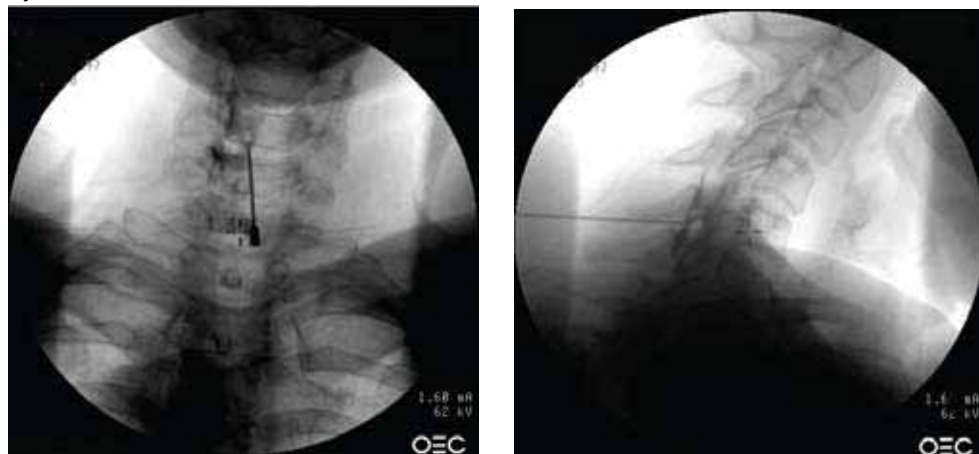


Figure 28-8. Needle position demonstrating bilateral greater occipital nerve blocks.

sociated with overuse of the affected body part. Piriformis syndrome tends to present as unilateral buttock pain and, depending on the extent of sciatic nerve involvement, pain extending into

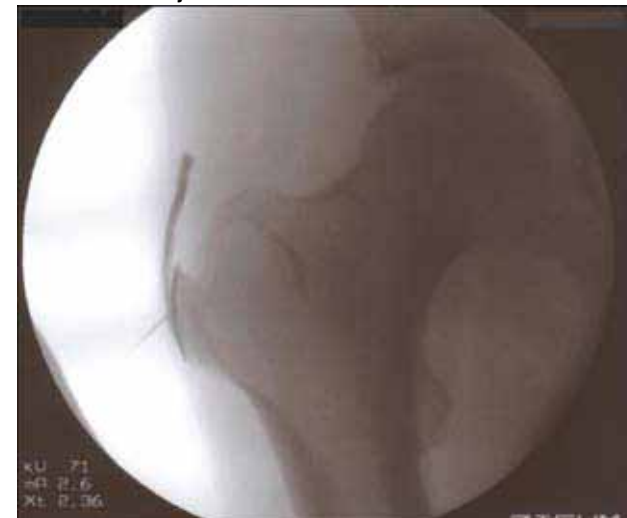the lower leg. The diagnosis of piriformis syndrome is predicated on a positive response to fluoroscopically guided intramuscular injection. In addition to their diagnostic utility, these injections can also be therapeutic.

TB is a clinical diagnosis characterized by the association of lateral hip pain, tenderness to palpation, and pain

provocation by various movements. Sometimes called “pseudosciatica,” TB can radiate into the distal thigh but rarely extends below the knee. Risk factors for TB include coexisting lumbar spine pathology, gait and postural abnormalities, leg length discrepancy, female gender, and advanced age. It is important to note that a majority of patients clinically diagnosed with TB have no MRI evidence of bursa inflammation. In these patients, the true pain generator is often tendonitis, muscle tears, or trigger points (Figure 28-9).

Plantar fasciitis has a lifetime prevalence of almost 10% in the general population but tends to be more common in soldiers. Risk factors include excessive walking or running, especially in the early morning, on uneven surfaces, or wearing heavy backpacks; having flat feet or high arches; being overweight; and being middle age or older. Conservative treatment includes rest, night splints or orthotics, stretching

Figure 28-9. Antero-posterior fluoroscopic view demonstrating trochanteric bursa injection.



exercises, and NSAIDs. Corticosteroid injections may also relieve plantar fasciitis symptoms.

Less Common Pain Complaints. Nonradicular arm pain is less frequently encountered than nonradicular leg pain. Aside from complex regional pain syndrome, which is rarely encountered in soldiers at level III facilities, other causes of nonradicular arm pain include medial and lateral epicondylitis (“tennis elbow”), tendonitis, bursitis, and carpal tunnel syndrome. Injection of any of these overuse inflammatory conditions with corticosteroid and local anesthetic may result in significant pain relief and functional improvement. Since these injections are targeted by palpation and landmarks, they can usually be done in the field.

Lastly, male groin pain, abdominal pain, and female pelvic pain are the least likely pain conditions to improve with the interventional therapy available in theater. Common to all three of these conditions is the diagnostic dilemma each poses, the lack of any reliable pharmacologic or interventional treatments, and the high prevalence of coexisting psychopathology. When a surgical scar is present, scar injections with corticosteroid and local anesthetic may afford pain relief by virtue of releasing entrapped nerves or suppressing ectopic discharges from injured neurons. Even in soldiers who will require medical evacuation, short-term relief can often be obtained with nerve blocks. Most of these blocks tend to be landmark-guided, so fluoroscopy is generally not necessary (see Table 28-1).

SUMMARY

In modern combat, the most common cause of soldier attrition is not battle-related injuries, but rather acute and recurrent NBIs similar to those encountered in civilian pain clinics. Although recent evidence indicates that higher return-to-unit rates can be obtained with forward-deployed interventional pain management capabilities, these techniques are not always practical early in warfare. Chronic pain management in the operational setting is fraught with a unique and often dynamic set of challenges, but the procedures can provide considerable benefit in a mature theater of war with deployment of personnel and equipment as described in this chapter.

29. AIR TRANSPORT OF THE CRITICALLY INJURED PATIENT: CONTROLLING PAIN DURING TRANSPORT AND FLIGHT

INTRODUCTION

Contemporary warfare has brought both advancements and new challenges for acute pain management in the combat setting. Although survivability has increased secondary to improvements in body armor, the necessarily exposed limbs of soldiers have become even more vulnerable to progressively more destructive explosive devices. The lethality of improvised explosive devices, explosively formed penetrators, and other weapons has clearly increased during the course of the current conflict. Rapid patient evacuation out of the battlefield, far-forward advanced surgical capabilities, and rapid air evacuation of combat wounded to critical care facilities outside of the war theater are the key factors resulting in a less than 10% died-of-wound rate. Historically, the relatively austere medical environment of the US Air Force (USAF) evacuation aircraft (Figure 29-1) made the management of acute pain in multitrauma patients particularly difficult.

Today, the ability to evacuate patients from the battlefield has evolved into the most efficient transport and medically capable system in history. At the core of this system lies the USAF aeromedical evacuation system (AES). With the inclusion of the critical care air transport team (CCATT), the AES has been described as a 6,000-mile-long intensive care unit in the sky, stretching from staging areas in the Middle East to the continental United States.

Although CCATTs focus on the critical care patient, the majority of injured soldiers require AE transport without mechanical ventilation, inotropic medications, or other measures typically associated with critical care. However, these patients often have sustained massive injury, such as multiple amputations of limbs and complicated orthopedic injuries. Although “hemodynamically stable,” these patients still have acute needs for in-flight monitoring and aggressive pain management.



Figure 29-1. Interior of air evacuation aircraft.

The US military experience with evacuating casualties by air dates to World War I. Until recently, advances in pain management during evacuation have not kept pace with advances in casualty resuscitation and transport. This chapter will address the historical casualty transport capabilities of the military, advances in patient care enroute, and the addition of advanced pain management during evacuation. Specific challenges encountered in patient care while traveling for hours for thousands of miles on military aircraft will also be addressed.

HISTORICAL TRANSFORMATION OF THE AIR FORCE ENROUTE CARE PLATFORM

The World War I air evacuation efforts led to the organization of an integrated AES by the US Army Air Corps during World War II. This system included nurses with specific AE training serving on cargo aircraft returning from the theater of battle.

By the 1990s the AES included command and control functions, trained crews, mobile facilities for staging patients pre-flight, and extensive logistical support. The system could rapidly deploy, set up, and evacuate large numbers of stable casualties, but it lacked the intrinsic capability to manage critically ill casualties, instead relying on medical attendants, supplies, and equipment provided by the sending medical facility. The requirement to provide these resources was a particular challenge for small field hospitals with limited personnel, which cannot lose personnel without seriously degrading their capability. This problem became evident in Somalia when the surge of combat casualties on

October 3–4, 1993, overwhelmed the medical response capabilities, casualties accumulated, and the most critical patients could not be immediately evacuated. Following Operation Desert Storm in 1990, calls were made for the addition of AE physicians and equipment capable of managing unstable patients in flight.

JOINT ENROUTE CARE SYSTEM

The current joint enroute care system includes contributions from each of the US military services and, in many cases, from coalition military medical services as well. Casualties are evacuated through five levels of care with increasing capability, from self care and buddy care with initial management at aid stations close to the point of injury, through advanced rehabilitative care at military and Veterans Administration medical centers in the United States.

Casualty evacuation (CASEVAC), a term used by all services, refers to the movement of unregulated casualties by nonmedical units aboard nonmedical ground vehicles, without enroute care by medical professionals. The casualty is taken from the point of injury to the most appropriate medical facility; typically level I or level II facilities. The CASEVAC mission may involve care under fire, and speed and security are more important than advanced enroute care. In the US military, CASEVAC is overwhelmingly an Army, Marine Corps, or Navy mission.

Medical evacuation (MEDEVAC) refers to a US Army capability involving designated rotary-wing aircraft and specially trained enlisted medical crewmembers. In MEDEVAC casualties are transported aboard medical helicopters under the care of combat medics with advanced flight training. Constituting a paramedic level of care, this capability can be used from the point of injury to a medical facility, or between facilities.

Strategic evacuation (STRATEVAC) is primarily the domain of the USAF. AES refers to the regulated movement of casualties from level II or III through level V facilities by fixed-wing USAF aircraft. Staging facilities at hubs of the AES serve as buffers, allowing casualties to be housed, fed, and prepared for flight at a location from which they can be rapidly loaded as aircraft become available. Basic medical care and wound care, as well as basic (oral and intravenous [IV] bolus) pain control, are provided at these locations. Patients waiting at the hubs typically have minor injuries preventing them from immediately returning to duty. Aboard the aircraft, an AE crew, consisting of flight nurses and AE medical technicians who have undergone specialized training, manages the patients. The care given by an AE crew is limited by the large number of patients they are tasked to manage and their level of medical training. If a patient requires more care than this basic level, the sending facility has historically been responsible for providing a medical attendant

during evacuation. Today, for casualties who are critically ill or injured, the AE system provides the medical attendants in the form of the CCATT.

The AE function can be categorized as tactical evacuation (TACEVAC) within a military theater of operations or STRATEVAC between theaters of operation. The most commonly used aircraft for TACEVAC is the C-130 Hercules (Figure 29-2). This aircraft is capable of operating from unimproved airfields and in hostile locations. The C-130 flies at 318 knots at 20,000 feet, with a maximum ceiling of 23,000 feet. It has the capacity for up to 74 litter patients, but does not have onboard oxygen systems, mandating that oxygen to be carried onboard as a portable liquid oxygen system or a compressed gas. The electrical system provides 400 Hz AC power through specially configured outlets, limiting its direct utility for medical devices. Therefore AE/CCATT must rely on battery power, or power provided through an electrical converter, which limits the total amperage output for medical equipment use. Lighting and environmental control systems are minimal, requiring additional measures for patient warming and visualization of patient care. Lastly, access to patients is limited to 180°.

The C-17 Globemaster III (Figure 29-3) has the unique quality of being an excellent aircraft for both TACEVAC and STRATEVAC. It has a speed of 450 knots at an altitude of 28,000 feet, with an unrefueled range of 2,400 nautical miles and unlimited range with aerial refueling. This range makes it useful for transoceanic missions. The C-17 can also utilize small, unimproved airfields with runways as short as 3,500 feet long and 90 feet wide. The aircraft's interior is well lit, and the system of litter stanchions provides 360° access to critical patients. The C-17 contains built-in systems that provide medical oxygen at 50 psi and 60 Hz AC electric power through standard US outlets. Currently the work-



Figure 29-2. C-130 Hercules

horse in patient transport, the C-17 can be rapidly configured from use as a cargo aircraft to accommodate 36 litter patients.

PIECES OF THE ENROUTE CARE PUZZLE

The USAF is solely responsible for the transport of injured US military from the theater of operation to their home station. This requires the ability to transport and provide ongoing care during long distance flights lasting from 2 to 5 days. The system relies on available USAF aircraft that are temporarily converted into AE-capable platforms as the need

Figure 29-3. C-17 Globemaster III



arises. USAF teams involved in patient transport include the aircraft crew, AE medics, and the CCATT.

Until the mid-1990s, most if not all injured patients requiring AE transport had to be relatively stable for transport. Very little care was performed in the aircraft due to limited capabilities of the medical AE teams. For example, if a patient in Germany had an uncomplicated exploratory laparotomy, he or she would have to stay at the hospital where the surgery was performed until considered stable for transport, which would have been anywhere from 3 to 5 days postoperation. If patients required any special care or pain medicine other than oral or intermittent IV bolus, a medical attendant would have to travel with them to manage their care during transport. Early AE teams typically consisted of a mix of registered nurses and medical technicians, specifically trained for air transport of the medical patient. A typical AE team included two nurses and three technicians; an expanded team consisted of three nurses and four technicians. The personnel assigned to AE varied from outpatient clinic personnel to critical care personnel, and the patient care abilities and comfort levels of AE team members ranged vastly. Anything other than basic care was limited by the makeup of the AE team. The typical AE transport had a patient load of anywhere from 1 to over 50 patients, depending on the types of patients, whether they were ambulatory or not, and the aircraft available. To support this method of AE, the holding capabilities of medical facilities in and out of theater had to be robust, which was logistically difficult to support and often not in the best interest of the patient.

During the 1980s and early 1990s, Dr Paul K Carlton Jr, a surgeon and later the USAF surgeon general, developed capability for the rapid effective stabilization and transport of significantly injured or traumatized casualties. Carlton based his method on his experience at Wiesbaden, Germany, receiving casualties from the embassy bombing in Beirut,

Lebanon. In 1994 Carlton and Dr Joseph C Farmer, a medical intensivist, launched the CCATT program, consisting of teams with a critical care physician, critical care nurse, and respiratory therapist, accompanied by the supplies and equipment necessary to create a critical care environment that would move with the patient during evacuation. Team members were specifically trained to provide specialized care in the high-altitude, extreme aircraft environment, with emphasis on the “AE environment.” The concept of CCATT is to manage stabilizing casualties—those who have undergone initial resuscitation but remain critically ill. A physician was included on the team to provide continuous medical decision-making, so that therapies could be titrated to the patient’s condition, new therapies started if required, and patients could continue progressing toward stability without interruption or setback for transport. Having a CCATT physician available during an AE mission also allowed better medical care for the non-CCATT patients, including pain management.

The timing of CCATT development allowed the US military healthcare system to adjust its doctrine in response to changing military strategy. During the Cold War, US forces prepared for large battles in predictable locations supported by established hospitals with the capacity to hold large numbers of casualties until they had completed convalescence and were returned to duty. After the Cold War ended, the US military became engaged in a large number of activities ranging from humanitarian and peacekeeping operations to combat. These operations often arose quickly, took place in unpredictable locations, and in some cases changed locations rapidly; establishing large-capacity hospitals whenever and wherever needed became impossible. Instead, the military needed to deploy small, high-capability, limited-holding-capacity facilities that could stabilize and evacuate casualties with far less logistic support. To accomplish this objective,

medical personnel needed to be able to evacuate even unstable casualties safely, and CCATT offered that capability.

Enroute Pain Management. Despite advances made in the enroute care system, one aspect in need of improvement involved patients who were not critical enough for CCATT but had significant pain secondary to their injuries, which was worsened by the vibration, bouncing, and noise of the continuously moving aircraft transport environment. Due to the aircraft environment and external forces, patients frequently experienced inadequate pain control during bus transport and the aeroevacuation flight.

The aerospace environment presents numerous physiological and psychological challenges, especially with trauma patients, to medical personnel. Altitude changes, extremes of temperature, noise, vibration, lighting, power, space, and equipment restrictions are just a few of these issues. Constant vibration and the cramped conditions aboard the aircraft can make a painful injury excruciating. Appropriate padding and securing of wounded extremities help to reduce pain and protect the patient from compression injuries. Some injured military members have even gone as far as posting signs saying, “Don’t bump the stump!” Attention to such simple details goes far in the management of pain in this complex environment.

Until recently, oral medication or intermittent morphine (bolus IV) were essentially the only pain management therapies available for injured soldiers during transport. Medications for pain carried on a routine AE mission included acetaminophen; ibuprofen; Tylenol 3 (McNEIL-PPC Inc, Fort Washington, Pa); Percocet (Endo Pharmaceuticals, Chadds Ford, Pa); Demerol (Sanofi-Aventis, Bridgewater, NJ); and morphine. Patients were provided written orders for either oral pain medication or IV morphine. This was the AE standard of care until mid-2002. Despite having served the military

well in the past, this type of pain management fails in today's complex evacuation systems.

In a typical AE mission, patients are held in a centralized location before transport via ambulance bus (AMBUS [Figure 29-4]) to the aircraft, where they are loaded as either ambulatory or litter patients. After taxi and takeoff, a safe altitude must be reached before patient care can be given, a process lasting about 60 minutes. At the end of the mission, all personnel must remain seated during approach, landing, and taxi, which also takes about 60 minutes. Unloading patients from the aircraft onto an AMBUS and transport lasting 60 to 90 minutes to the receiving facility is the next evacuation step. At the receiving facility, unloading patients from the AMBUS into the facility for admission and room assignment adds additional time before patient care resumes. During the time of landing, taxi, loading, transport, unloading, and in-processing at the receiving facility, pain control received by the patient is minimal (Figure 29-5).

The problem of patients enduring extended time between pain medication administration was identi-

Figure 29-4. Loading patient into AMBUS.

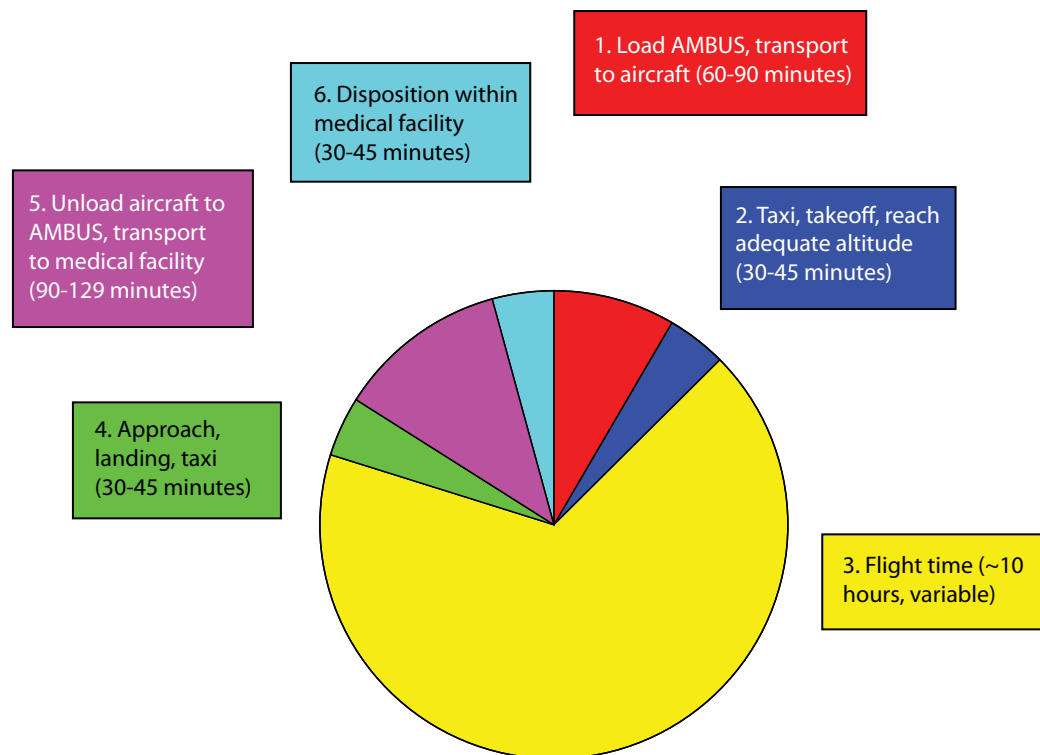
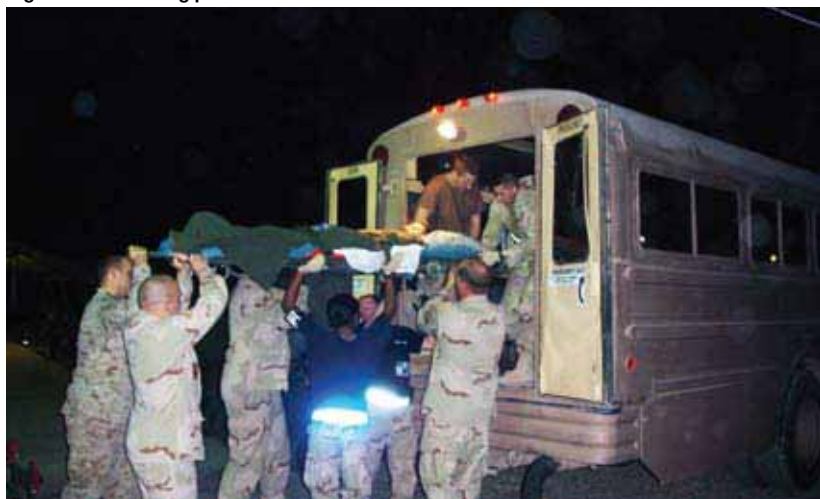

Figure 29-5. Proportionate stages of transport during air evacuation

fied early in Operation Enduring Freedom and Operation Iraqi Freedom, secondary to the large numbers of patients arriving at the various receiving facilities (Landstuhl Regional Medical Center, Germany; Walter Reed Army Medical Center, Bethesda Naval Medical Center, and Malcolm Grow Medical Center, Andrews Air Force Base, in the Washington, DC, area; and Brook Army Medical Center, San Antonio, Tex) in extreme amounts

of pain. An early attempt to combat this problem involved anesthesia pain teams meeting casualties as they arrived at receiving facilities. However, although the teams treated the immediate pain on arrival, the pain endured from aircraft approach to facility arrival was not treated. Anesthesia teams then began greeting the aircraft on arrival to provide pain medication (oral or IV) prior to AMBUS loading and transport. Both measures helped significantly but did not adequately address the issue of pain during transport as a whole, and the extended periods of time between dosing were not adequately resolved.

The casualty pain issues on AE flights prompted

the triservice (Army, Navy, and USAF) anesthesia community to band together to identify and provide solutions to this problem of pain during transport. The result was the formation of the first triservice military organization specifically concentrating on management of pain in combat casualties—the Military Advanced Regional Anesthesia and Analgesia (MARAA) committee—organized in early 2002 to develop, recommend, and implement advanced pain initiatives to be placed in the AE environment.

Military Advanced Regional Anesthesia and Analgesia Initiatives. The first therapy advocated by MARAA was the continuous peripheral nerve block (CPNB), which had already proved successful for pain control but was not allowed in the AES due to lack of a medical attendant to monitor the infusion. MARAA developed a training platform for CPNBs during AE and obtained airworthiness testing and approval for the Stryker PainPump (Stryker; Kalamazoo, Mich) for the infusions. The addition of CPNBs into the AES in 2003 significantly improved the pain management of many evacuating casualties. CPNB on military aircraft has enjoyed an excellent safety record in wounded soldiers since it was first introduced on October 7, 2003. To date over 1,500 injured airmen, soldiers, sailors, and marines have benefited from this technique. However, CPNBs are appropriate only for a patient population with isolated extremity injuries, and MARAA continued developing further pain management techniques for the AES. Although none of the techniques would be considered new in a US medical facility, the application of these proven pain technologies in AE has greatly enhanced pain management in this difficult medical environment.

The second initiative was the institution of patient-controlled analgesia (PCA) for transport in 2004. PCA is common in civilian hospitals, where

it is well monitored by trained nursing staff on a routine basis, whereas clinical capabilities in AE teams are unpredictable. MARAA realized that the pump selected for this mission had to be small, user-friendly, safe, and pass airworthy certification for acceptance onto military aircraft. In addition, the pump had to be relatively inexpensive and require no medical maintenance. MARAA members found the ambIT PCA pump (Sorenson Medical Inc, West Jordan, Utah) to be the best interim choice for rapid implementation of this technology.

The third initiative by MARAA was epidural analgesia for AE patient care in late 2004. Implementation of epidural analgesia enroute also required a user-friendly, fail-safe pump with simple instructions for monitoring and care. Today the pump utilized for all three pain management techniques is the ambIT infusion pump. Labels are provided in the packaging to identify the type of infusion, as well as instructions for troubleshooting and reprogramming the infusions if required. Specific rules, training, and safeguards are in place for infusion while enroute (available to the public at www.arapmi.org and to military account holders at <https://kx.afms.mil/Anesthesiology>). All pain techniques are followed and managed by the various military anesthesia departments while enroute. Pain care information on individual casualties is updated and tracked via the Regional Anesthesia Tracking System (RATS), a secure Web-based tool available at all medical facilities along the AE chain. Providers of regional anesthesia and other pain care technologies input and update the database online so subsequent providers will have accurate information to make patient care decisions. RATS has been used for nearly 1,000 patients. Efforts are underway to transition the RATS system into the Theater Medical Data Store system, which is being developed as the electronic military medical record of the future.

Enroute Patient Packaging. AE mission variables include flight durations that range from 1 to more than 18 hours, significant physiologic flux demanding provider treatment flexibility, and a constantly changing mission pace that necessitates rapid assessment and prioritization of care in a medically austere environment. This practice is very different from the static hospital ward experience in the United States. Experience has shown that the independent, hands-on practitioner mind-set and skill sets of anesthesiologists and emergency physicians adapt well to the care of patients in the CCATT environment, specifically for ongoing resuscitation, required procedure, and pain management. The patient care approach these physicians bring into the development and maintenance of the CCATT program has also been a major benefit.

To package a patient for multihour transport, attention must be paid to multiple issues including prevention of pressure sores, prevention of further injury, spinal immobilization, prevention of injury from attached equipment, stabilizing extremity fractures, prevention of “blocked” extremity injury, external fixator padding and stabilization, and prevention of dislodgment of catheters or kinking of tubing, in addition to pain management. These duties are usually associated with nursing but are the responsibility of the caregiver team in the air transport arena. Patients typically require increases in pain medication during air transport because of the aircraft’s constant motion, compared to the stable hospital environment. An easy technique to evaluate the effectiveness of the pain control (PCA, epidural, CPNB) is to shake the patient’s hospital bed to see if it causes increased pain; if so, pain dosing during AE may need to be increased 10% to 20%.

Airworthy Certification. Medical equipment on military aircraft must meet stringent criteria of airworthiness and interoperability. The major testing hurdles before approval for in-flight use include

interface with the aircraft oxygen and electrical systems; assessment of how the device functions across the cabin altitude range of a typical mission (sea level to 8,000 feet) and with rapid decompression to flying altitude; whether the device produces electromagnetic emissions that interfere with aircraft systems; whether electromagnetic emissions from the aircraft interfere with device function; and effect of vibration on the device. Another important consideration is how the equipment interfaces with that used by military ground facilities prior to AE transport. The goal is to eliminate the necessity of changing out patient-applied support devices such as intravenous drip sets, pressure transducers, disposable oximeter probes, monitoring equipment, and pain infusion pumps. Device swap-outs slow down urgent care, waste supplies, and introduce opportunity for error. Patient-applied support devices are designed to be left with the transported patient until

no longer needed and then returned to the system. A robust logistics system tracks the devices while in use, and then ensures their return into the enroute care system.

CONCLUSION

Arguably the most significant advances in AE pain management in decades have been the expansion of regional anesthesia strategies, both neuraxial and peripheral, in the military air transport arena. Patients are now routinely transported with epidural catheters, CPNB catheters, and PCA pumps. Indeed, the synergism of systemic opioid via PCA, combined with the targeted (but nonrespiratory depressant) effects of CPNB therapy, seems to offer the most powerful degree of pain relief available to multitrauma patients.

The evolution in AE pain management represents

a revolutionary change in thinking about battlefield management of pain. Aggressive treatment of pain is now part of every wounded soldier's care plan. Certification of an airworthy portable infusion pump paved the way for implementation of PCA, epidural, and CPNB regional anesthesia during AE on military aircraft.

Ensuring that all acute pain management options are exercised as early as possible in the AE chain is critical. Building on the lessons of combat trauma, both military and civilian anesthesiologists can increase use of new pain management techniques for the acutely injured. The experience in pain management during combat AE has brought innovative and effective pain management solutions into common military use. MARAA continues to aggressively monitor and recommend further additions to the toolbox of pain therapies available for treating wounded service members.

30. BASIC PEDIATRIC REGIONAL ANESTHESIA

INTRODUCTION

Military anesthesia providers often encounter pediatric patients while delivering medical care in the field. The application of regional anesthesia in children can be extremely useful in austere situations, particularly when limited resources are available (eg, scarce oxygen supply, lack of postoperative analgesics, insufficient postoperative nursing expertise). Prior to providing any pediatric regional anesthetic, the provider should not only be experienced in the specific regional anesthesia technique but also be comfortable with pediatric patient care, because almost all pediatric regional anesthesia is done while the child is either heavily sedated or under general anesthesia. To provide safe anesthetic services to pediatric patients, medical staff must recognize the myriad physiologic and pharmacologic differences between pediatric and adult patients.

DIFFERENCES BETWEEN PEDIATRIC AND ADULT PATIENTS

Pharmacokinetics. Local anesthetics preferentially bind to α -1 acid glycoprotein (AAG) found in plasma. Neonates have very low levels of AAG, 20% to 40% of normal adult values. Normal levels are not reached until 1 year of age. Low levels of AAG lead to higher serum levels of unbound local anesthetic, and this “free” drug is responsible for toxicity. Infants also have decreased clearance and a longer elimination half-life of local anesthetic compared to adults. All these factors contribute to the increased general risk of local anesthetic toxicity resulting from a preponderance of free drug circulating in the pediatric patient’s plasma during regional anesthesia.

Developmental and Anatomic Differences.

Myelination is not complete until 12 years of age. Incomplete myelination allows for better pen-

etration of local anesthetic into the nerve fibers. Reduced milligram doses from dilute local anesthetic solutions can provide a complete block in children. Also, loose fascial attachments around the nerves facilitate the spread of local anesthetic. Consequently, a regional block in children may spread further than the provider intends. Additionally, because the local anesthetic spreads easily in children, the duration of the block may be shortened compared to an adult. In general, as the patient’s age increases, local anesthetic latency of onset and duration of action increases as well. Table 30-1 lists anatomic differences between children and adults.

PEDIATRIC REGIONAL ANESTHESIA

All blocks should be conducted with intravenous access and with standard American Society of Anesthesiology monitoring applied. Appropriate resuscitation equipment should also be available. In austere environments, adjustments to this standard may be necessary, based on the availability of medical equipment.

Caudal Block

Indications. Use for patients < 8 years old to provide intraoperative and postoperative analgesia for

abdominal and lower extremity surgery.

Positioning. Place the child in the lateral decubitus position with knees pulled up toward the chest.

Landmarks. Bilateral posterior superior iliac spine (PSIS) and sacral hiatus (SH). These three points should form an equilateral triangle. The SH is bounded by the sacral cornua. The sacral cornua are palpable on either side of the midline about 1 cm apart.

Technique. After sterile preparation and drape, insert a 20-gauge or 22-gauge angiocatheter at a 70° angle to the skin over the SH. A pop will be felt as the needle passes through the sacrococcygeal membrane. Once the sacrococcygeal membrane is pierced, drop the needle angle to 20° to 40° from the skin and advance the needle and the catheter 2 to 4 mm. Then advance the catheter off the needle (the catheter should advance easily). A stimulating needle can also be used. If the stimulating needle is in the caudal space, anal sphincter activity will be visible with a stimulation of 1 to 10 mA. If using a stimulating needle, do not advance greater than 2 to 4 mm past the sacrococcygeal membrane to prevent risk of dural puncture.

Drug Dosing. See Table 30-2.

TABLE 30-1
ANATOMIC DIFFERENCES BETWEEN PEDIATRIC AND ADULT PATIENTS

Age	End of Spinal Cord	End of Dural Sac	Intercristal Line	CSF Volume	Intercranial vs Spinal CSF (%)
Neonate	L3	S4	L5–S1	NA	NA
1 Year	L1	S2	L4–L5	4 mL/kg	50
Adult	L1	S2	L3–L4	2 mL/kg	25

CSF: cerebrospinal fluid
NA: not applicable

TABLE 30-2
PEDIATRIC DRUG DOSING FOR CAUDAL OR EPIDURAL BLOCKS

Age	Bupivacaine	Ropivacaine	Clonidine	Fentanyl
Single Injection				
< 1 yr old	0.25%, 1 mL/kg	0.2%, 1.2 mL/kg	1.0–1.5 µg/kg	2 µg/mL
> 1 yr old	0.25%, 1 mL/kg, max 20 mL	0.2–0.5%, max 20 mL or 3.5 mg/kg	1.0–1.5 µg/kg	2 µg/mL
Continuous Injection				
< 3 mo old	0.0625%–0.125%, 0.2 mg/kg/h	0.1%–0.2%, 0.2 mg/kg/h	0.12–0.2 µg/kg/h	1–2 µg/mL
< 1 yr old	0.125%, 0.3 mg/kg/h	0.1–0.2%, 0.3 mg/kg/h	0.12–0.2 µg/kg/h	1–2 µg/mL
> 1 yr old	0.125%, 0.3–0.4 mg/kg/h	0.1%–0.2%, 0.4 mg/kg/h	0.12–0.2 µg/kg/h	1–2 µg/mL

Lumbar Epidural

Indications. Use to provide anesthesia and or continuous analgesia for abdominal or lower extremity surgery in children of any age.

Positioning. Place the child in the lateral decubitus position with knees pulled up toward the chest.

Landmarks. Intercristal line (posterior line between the superior aspect of the two iliac crests).

Technique. After sterile preparation and drape, insert a short, 18-gauge Tuohy or Crawford needle with a 20-gauge epidural catheter. Loss of resistance with saline is the preferred technique. Catheters can frequently be threaded from the lumbar to the thoracic level with the Tuohy bevel directed cephalad. If catheters will be threaded to the thoracic level, the distance must be measured prior to insertion. Depth to the epidural space can be determined as follows:

- Neonate ≈ 1 cm
- Children 10 kg–25 kg ≈ 1 mm/kg

- Children > 25 kg: $0.8 + (0.05 \times \text{wt [kg]}) = \text{depth in cm}$

Drug Dosing. General pediatric estimate of dosing for caudal or epidural injections: 0.25% ropivacaine or bupivacaine, 1 mL/kg bolus, max 20 mL. Table 30-2 provides more specific information.

Subarachnoid Block

Indications. Lower abdominal and lower extremity procedures lasting less than 90 minutes. Subarachnoid block is an extremely effective and useful technique in resource-limited environments. Children have remarkable hemodynamic stability under spinal anesthesia.

Positioning. Lateral decubitus or seated. Careful attention must be paid to avoid excessive neck flexion in young infants, which causes airway obstruction.

Technique. After sterile preparation, a short (1.5–2 in) 25- or 22-gauge spinal needle should be used at the L4–L5 or L5–S1 interspace in infants. The L3–L4

interspace is acceptable in children greater than 1 year of age.

Drug Dosing. See Table 30-3. Hyperbaric or isobaric solutions should be used.

Possible Complications. Postdural puncture headaches are rare in children. Dose for blood patch: 0.3 mL/kg blood.

Teaching Points. Do not lift the child's legs in the air after the block or a high spinal will occur.

Although the local anesthetic dose may appear large, recall that children have a large cerebrospinal fluid volume relative to adults (see Table 30-1). The duration of the block increases with the patient's age.

TABLE 30-3
PEDIATRIC SPINAL DOSING

Age	Bupivacaine (mg/kg)	Tetracaine* (mg/kg)	Ropivacaine (mg/kg)
Infants	0.5–1.0	0.5–1.0	0.5–1.0
1–7 yrs old [†]	0.3–0.5	0.3–0.5	0.5
> 7 yrs old [†]	0.2–0.3	0.3	0.3–0.4

*With tetracaine, use epinephrine wash (epinephrine aspirated from vial and then fully expelled from the syringe prior to drawing up local anesthetic) to increase duration up to 120 minutes.

[†]Additives: clonidine 1–2 µg/kg for children > 1 year of age.

Peripheral Nerve Block

Indications. Perioperative analgesia for upper extremity, lower extremity, thoracic, or breast surgery.

Drug Dosing. Local anesthetics for these blocks are dosed by weight rather than by a set volume. The maximum dose of bupivacaine is 2.5 mg/kg. Slightly higher dosing for ropivacaine (10% higher) may be acceptable. Children less than 8 years of age should receive 0.25% bupivacaine or 0.2% ropivacaine. If the peripheral nerve block (PNB) is placed after general anesthesia is induced, do not use neuromuscular blocking agents until after the block is placed. When performing a continuous peripheral nerve block, do not exceed the maximum doses

TABLE 30-4

DRUG DOSING FOR PEDIATRIC SINGLE-INJECTION PERIPHERAL NERVE BLOCK*

Block	Dose Range (mL/kg)	Midrange Dose (mL/kg)	Maximum Volume (mL)
Parascalene	0.2–1.0	0.5	20
Infraclavicular	0.2–1.0	0.5	20
Axillary	0.2–0.5	0.3	20
Paravertebral	0.5–1.0	0.7	5
Femoral	0.2–0.6	0.4	17
Proximal sciatic	0.3–1.0	0.5	20
Popliteal	0.2–0.4	0.3	15
Lumbar plexus	0.3–1.0	0.5	20

*Children < 8 yrs: 0.2% ropivacaine or 0.25% bupivacaine. Children > 8 yrs: 0.5% ropivacaine or 0.5% bupivacaine. Do not exceed maximum recommended doses of local anesthetic.

listed for continuous caudal or epidural local anesthetic. Table 30-4 provides local anesthetic dosing for pediatric PNBs.

Upper Extremity Blocks

Three upper extremity blocks are commonly performed in children: (1) the parascalene block, (2) the infraclavicular block, and (3) the axillary block. The supraclavicular block is not recommended for use in children.

Parascalene Block

The parascalene block was developed to provide a safer alternative in children to the supraclavicular block.

Positioning. Place the patient supine with a

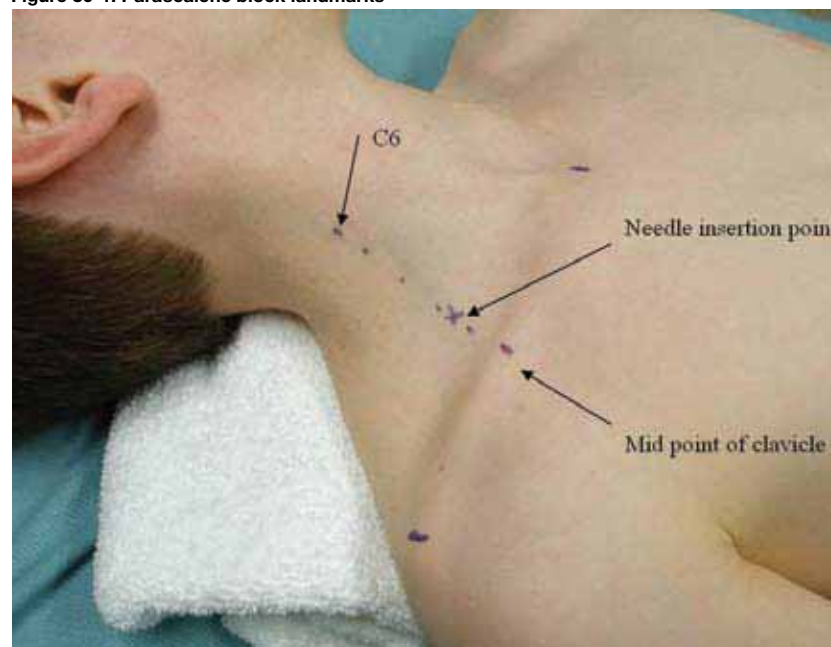
rolled towel under the shoulder and arm at the side.

Landmarks. Midpoint of the clavicle, posterior border of the sternocleidomastoid, and the transverse process of C6. The level of C6 is at the same level as the cricoid cartilage. Draw a line between the transverse process of C6 and the midpoint of the clavicle (Figure 30-1).

Technique. The needle puncture site is at the point between the lower one third and upper two thirds of this line. Insert the stimulating needle perpendicular to the skin and directed posteriorly until upper extremity twitches are noted. If no twitches are elicited, redirect the needle laterally. Then inject an appropriate dose (based on child's age and weight) of local anesthesia. Depth of plexus ≈ 1–2 cm.

Equipment. 22-gauge, 5-cm stimulating needle.

Figure 30-1. Parascalene block landmarks



Infraclavicular Block

Positioning. Place the patient supine with the operative extremity at the side and head turned to the opposite side.

Landmarks and techniques. Two approaches are used in children for the infraclavicular block: (1) the **deltopectoral groove approach**, with the same landmarks and technique as in an adult, and (2) the **mid-clavicular approach**, in which the midpoint of the clavicle is the landmark. Insert the needle at a 45° angle to the skin, pointed toward the axilla. A 22-gauge, 5-cm needle is used for children under 40 kg.

Axillary Block

Positioning. Same as adult.

Landmarks. Same as adult.

Technique. Same as adult, but use a 22-gauge, 5-cm needle.

Lower Extremity Blocks

Lower extremity blocks include the femoral, lumbar plexus, and sciatic blocks.

Femoral Block

The position, landmarks, and desired motor response with simulation are the same as in an adult. Use a 22-gauge, 5-cm or 1.5-in (3.8-cm) needle.

Lumbar Plexus Block

Only practitioners with experience with this technique should use this block in children.

Position. Lateral decubitus position with the knees pulled up toward the chest.

Landmarks. Draw a line between the spinous process of L4 and the ipsilateral PSIS. The needle insertion point is at the point between the medial two thirds and the lateral one third of the line (Figure 30-2).

Technique. Advance a 5- or 10-cm stimulating needle parallel to the bed until quadriceps twitches are elicited. If the needle contacts the L5 process, withdraw and redirect it cephalad. Average depth to plexus: 2.5 cm (5-kg child) to 6.5 cm (50-kg child).

Sciatic Block

Multiple approaches to the sciatic nerve block may be used in children. Which approach to use should be determined by provider experience with any particular technique.

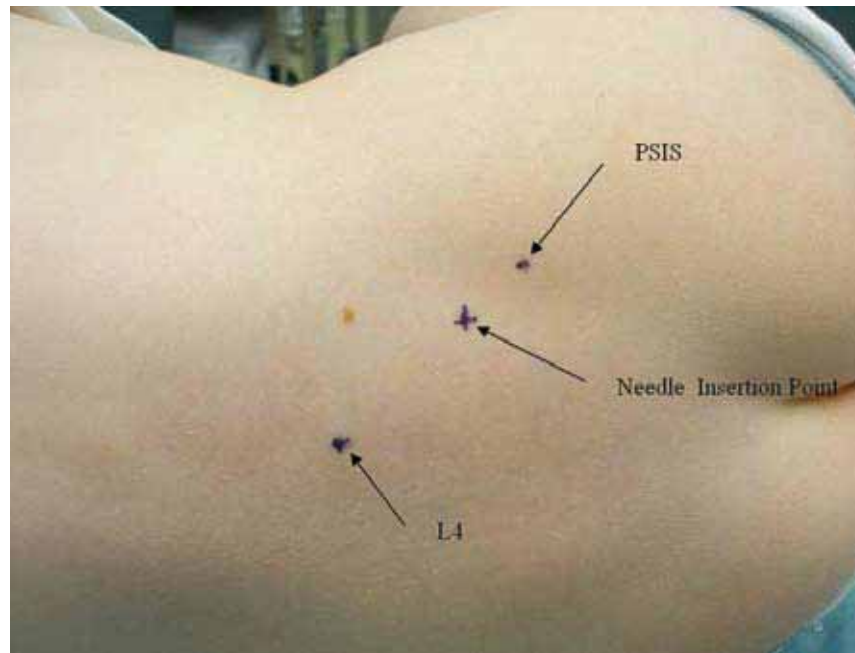


Figure 30-2. Lumbar plexus block landmarks. PSIS: posterior superior iliac spine.

- Posterior or classic sciatic block. The positioning, landmarks, and technique are the same as for an adult. Average distance to the nerve: 2 cm (5-kg child) to 4.5 cm (50-kg child).
- Raj or infragluteal sciatic block. The positioning, landmarks, and technique are the same as for an adult.
- Popliteal sciatic block. This is the most commonly reported as well as the safest approach to the sciatic nerve in children.

Positioning. The popliteal approach to the sciatic nerve can be done in the prone, lateral (operative leg up), or supine position, with an assistant elevating the leg. To appreciate the appropriate stimulation pattern of the tibial nerve, the patient's foot and ankle must be free to move.

Landmarks. The popliteal crease, the biceps femoris tendon, and the tendons of the semimembranosus and semitendinosus muscles.

Technique. Bisect the triangle formed by the landmarks. The needle insertion point is 1 cm below the apex of the triangle and 0.5 cm lateral to the bisecting line. Needle length is 5 cm for a small child or 10 cm for a larger child. Direct the needle cephalad at a 70° angle to the skin until plantar flexion is elicited. Distance from the popliteal crease to the bifurcation of the sciatic nerve: $27 + (4 \times \text{age in years}) = \text{distance in mm}$.

Thoracic Paravertebral Block

Indications. Anesthesia and analgesia for breast and chest wall procedures.

Positioning. Sitting or lateral decubitus.

Landmarks. Spinous process. Needle insertion point is 1 to 2 cm lateral to the superior aspect of the spinous process.

Technique. Same as for an adult, but use a 22-gauge Tuohy needle. The insertion point should be 0.5 to 1 cm past the transverse process. Estimated depth to the paravertebral space: $20 + (0.5 \times \text{wt [kg]}) = \text{depth in mm}$.

INJECTION TECHNIQUE FOR PEDIATRIC REGIONAL ANESTHESIA

Use the following for all pediatric regional anesthesia except the subarachnoid block:

- Aspirate prior to injection.
- Inject test dose (0.5–2 mL) of local anesthetic solution containing 0.5 $\mu\text{g}/\text{kg}$ of epinephrine.
- Look for signs of positive test dose (tachycardia is not reliably seen in patients under general anesthesia):
 - ST segment elevation,
 - T-wave amplitude of $> 25\%$, or
 - blood pressure elevation.
- Inject the remaining volume of local anesthetic slowly (120–180 seconds).
- Aspirate every 3 to 5 mL.
- Continue to closely monitor electrocardiograph and blood pressure during injection.
- Carefully test dose any catheter prior to bolusing or starting a continuous infusion.

Teaching Point. Review Figure 45-8 in *Miller's Anesthesia*, 6th edition, showing the distance from skin to plexus or nerve for common PNBs correlated with patient weight.

31. ACUTE PAIN NURSING IN THE FIELD

INTRODUCTION

“Austere environment” can be defined many ways. The term is used here to refer to the contemporary battlefield, but similar conditions are found in disaster-relief scenarios and the developing world—military nurses or physicians may find themselves in any of these places. Providing health care under these circumstances has challenges unique to each environment as well as common to all austere environments. Today’s combat support hospital (CSH) is the best example of the military’s effort to compensate for the lack of physical infrastructure in the field. Designed to deliver an array of advanced healthcare services usually restricted to fixed facilities, the CSH is a testament to current technology’s capabilities, relative portability, and self-contained packaging. Although CSH technology is impressive, mission success depends less on equipment and more on the personnel assigned to it. Nurses in particular are a vital element of the CSH system. Despite the CSH’s technical advances in casualty care, its austere environment still complicates medical care delivery, including pain management. For any successful acute pain management program to work on the battlefield, nursing service must be an integral part of the plan.

Nursing service plays a key role in the management of acute pain from the perspective of clinical practice. This chapter will outline the clinical roles and responsibilities of an acute pain nurse based on a 4-week orientation for the acute pain service (APS) at Walter Reed Army Medical Center. How these acute pain nursing skills transfer to the field environment will also be addressed.

ACUTE PAIN NURSING ROLES AND RESPONSIBILITIES

Acute pain nurses should be on staff around the clock. Under the direction of the physician consultant, APS nurses conduct the following activi-

ties: bolus continuous peripheral nerve block and epidural catheters, discontinue catheters, adjust flow rates on the infusion pumps, change dressings, educate patients and families, and make recommendations to the attending staff based on their daily assessments. Walter Reed APS nurses are also trained in the maintenance of specialized equipment.

APS nurses are taught clinical skills that incorporate daily checks on several aspects of acute pain management. These include pain infusion pump troubleshooting, evaluation of the remaining infusion volume and repletion if necessary, and most importantly, assessment of pain intervention success (Table 31-1). The continuous reevaluation of all changes in treatment plans made by the APS team is a key component of the nurse’s role. This role involves returning to the bedside not only to assess effectiveness of an intervention, but also to document the result in the patient record. If a

TABLE 31-1

“ABCDE” OF PAIN ASSESSMENT AND MANAGEMENT

-
- A**sk about the pain regularly; assess pain systematically.
 - B**elieve the patient’s report of pain and what relieves it.
 - C**hoose pain control options appropriate for the patient’s circumstances.
 - D**eliver intervention in a timely manner.
 - E**valuate effectiveness of the intervention within 30 minutes or less, depending on the acuity of the patient and the treatment. If further intervention is required, reassess, initiate treatment, and/or obtain consult if indicated.
-

Reproduced from: Jacox AR, Carr DB, Payne R, et al. *Clinical Practice Guideline No. 9: Management of Cancer Pain*. Rockville, Md: Agency for Health Care Policy and Research, US Department of Health and Human Services, US Public Health Service; 1994. AHCPR Publication 94-0592. Available at: <http://www.ahrq.gov/news/gduser.htm>. Accessed August 10, 2005.

change has not had the desired effect, it is up to the nurse to relay this information to the team with suggestions for therapy changes.

The responsibility of recommending treatment changes is a role uniquely suited to an advanced practice registered nurse with specialty training in pain management, although this does not preclude other nurses from working in pain management. The Military Advanced Regional Anesthesia and Analgesia working group encourages and supports all nurses who have an interest in the specialty to participate to the fullest degree possible. However, it is recommended that the nursing leadership of an APS be a masters-prepared registered nurse.

APS nurses also review all pain service patient medication lists for possible redundancies or contraindications (eg, anticoagulation regimens coupled with peripheral nerve catheters). Any questions or concerns are referred to the attending APS staff. In short, the nurses implement the APS team plans and serve as the eyes and ears of the acute pain physicians (Tables 31-2 and 31-3). An additional major component of the APS nurse role is nursing staff education (Table 31-4). APS nurses work to improve pain treatment safety through ward nurse education in infusion pumps, peripheral nerve blocks, basic pain medication pharmacology, and appropriate APS utilization.

Morning pain nursing rounds consist of the above assessment, troubleshooting, and technical problem solving. Teaching rounds are accomplished in the afternoon with APS nurses, attending staff, residents, and fellows. Multidisciplinary rounds occur once a week, when key team members such as pharmacy, physical therapy, and social services professionals are invited to consult. This multidisciplinary approach to pain management assures continuity of care and improved overall pain management.

APS nurses also spend time educating patients and their families on the disease of pain. Educating patients about anticipated discomfort for specific surgeries or injuries, as well as explaining pain

TABLE 31-2
SKILLS OF THE ACUTE PAIN NURSE

- Infusion pump operation (CPNB and IV PCA):
 - adjusts flow rates
 - changes infusion bags
 - clearing the history
 - changes batteries
- Epidural and peripheral nerve catheters:
 - bolus doses catheters
 - assesses for local anesthetic toxicity and efficacy of intervention
 - discontinues catheters
- Epidural and CPNBs:
 - sets up and assists in placement
 - uses nerve stimulator to assist in placement of CPNB
- Knows about most commonly used peripheral nerve blocks:
 - indications
 - areas of coverage
- Working knowledge of local anesthetic medications:
 - preparation
 - use
 - side effects
- Discusses other common medications used in multimodal pain control:
 - classifications
 - indications
 - dosages
 - side effects

CPNB: continuous peripheral nerve block
IV: intravenous
PCA: patient controlled analgesia

TABLE 31-3
PRINCIPLES AND COMPONENTS OF PAIN ASSESSMENT

Principles	Components
Accept patient self-reports of pain.	Location
Screen for pain routinely.	Intensity
Use the same rating scale over time (eg, VAS).	Duration
Document and track scores over time.	Onset
Reassess routinely to determine efficacy of interventions.	Radiation
Consider individual cultural differences, values and beliefs.	Alleviating factors
	Exacerbating factors

VAS: verbal analogue scale

TABLE 31-4
COMMON MYTHS AND BARRIERS TO PAIN MANAGEMENT

Myth	Truth
The best judge of pain is the physician or nurse.	The patient's self-report is the most reliable indicator.
The same type of pain affects different people in the same way.	Identical injuries can be described differently by sensation and intensity.
The patient who reports pain early will be provided pain relief quickly.	Stoicism is highly valued by many societies and by the military.
All nurses and physicians know how to treat pain.	Although improving, training for physicians and nurses in pain management is minimal and pain is undertreated in the majority of the patients.

therapies is a primary responsibility. Nurses discuss realistic pain expectations during treatment, what alternatives may—or may not—be available, anticipated side effects of medications used, and toxic symptoms to be addressed immediately (Table 31-5). The success of a pain treatment plan often hinges on the rapport nurses develop with the patient and family through daily interaction.

The psychosocial, behavioral, and emotional impact of battle-acquired traumatic injuries has been well documented. If an explosive device is powerful enough to blow apart an armored vehicle—even without a documented traumatic brain injury—it is now assumed that a pressure wave-induced, subclinical traumatic brain injury has occurred.

TABLE 31-5
SIDE EFFECTS OF PAIN INFUSIONS TO ADDRESS IMMEDIATELY

- Shortness of breath
- Difficulty swallowing
- Redness, warmth, tenderness, or discharge at site of catheter insertion
- Temperature > 101.0° F
- Dizziness or light-headedness
- Metallic taste in the mouth
- Ringing in the ears
- Catheter dislodgement
- Patient expressions of impending doom
- Pain out of proportion to the clinical injury or out of character for the patient's history
- Seizure activity

This assumed injury, along with the posttraumatic stress disorder diagnosed in up to 20% of returning soldiers, complicates an already challenging pain management scenario. This is an area of patient care where the pain nurses' interpersonal skills are often needed most.

The APS nurse is on the clinical frontlines, working daily with grievously wounded individuals who are often in extreme pain. Even when optimum pain control (a verbal analogue scale of ≤ 4 on scale of 0–10) has been achieved, the nurses spend much of their time listening to, grieving with, teaching, and emotionally supporting patients and their families. The APS nurse should also be knowledgeable about complementary alternative medicine and encourage patients to utilize these techniques (eg, relaxation, meditation, massage, acupuncture, hypnosis). Pain management nursing requires an individual willing to work with patients who are often at their behavioral worst—in significant pain—and still provide soothing human contact that cannot be found in a pill or injection.

ACUTE PAIN NURSING IN THE FIELD

The role of the APS nurse in theater is somewhat different than that of the APS nurse in a fixed facility. Although essential responsibilities remain unchanged, it is reasonable to expect that nurse–patient interactions will be relatively brief in the present rapid evacuation casualty environment. The APS must balance the need to manage intractable pain with maintaining hemodynamic stability; supplies may be limited and difficult to replace; and personnel shortages may send medical and nursing staff in many directions. In this setting pain management might be considered an unreasonable luxury; however, although no definitive studies have yet linked aggressive acute pain treatment to improved patient outcomes, evidence continues to support this theory. The working premise of the Military Advanced Regional Anesthesia and Analgesia or-

ganization is that early and aggressive treatment of acute pain improves long-term outcomes and may attenuate chronic pain syndromes.

Pain management at the CSH level is complicated by many factors. The autonomic signs of pain (tachycardia, hypertension, and diaphoresis) are difficult to distinguish from hypovolemia, ischemia, or other physiologic disturbances. Treating pain in the presence of marked hemodynamic instability is even more difficult. Assuming a patient is able to communicate, the most reliable assessment tool is the self-report of pain. The verbal analogue scale is the simplest, most familiar, and easiest to document.

CONCLUSION

APS is currently nonexistent or severely constrained on the battlefield and in the evacuation chain; however, anecdotal evidence collected at Walter Reed indicates that pain during evacuation is a common complaint in stable patients. A recent survey of 106 combat wounded arriving from the battlefields of Iraq and Afghanistan revealed an average verbal analogue scale pain score of 5.3 (± 2.3), and less than 50% claimed they received relief from their pain during transport. The need for a team of dedicated pain physicians and nurses in this environment is apparent. The nurse's role on this team would be similar to that in a fixed facility but with added responsibilities. The nurse may be tasked with identifying soldiers in need of pain management; bringing these individuals to the staff's attention; arranging and assisting with procedures, follow-up, and evaluation on intervention efficacy; charting; and communicating with air evacuation teams. In the clinic or on the battlefield, the role of the military APS nurse in a military environment is both challenging and evolving, but it is also rewarding and essential to providing wounded soldiers the excellent pain management they deserve.

COMMONLY USED TERMS AND ABBREVIATIONS

Acute pain: a mechanism the body uses to protect itself from further tissue damage following an external injury, internal malfunction, infection, acute inflammation, and/or ischemic event. Normally acute pain is self-limiting and treatable with pharmaceuticals, removal of the cause, or resolution of the illness. Acute pain can become maladaptive when the body is overwhelmed with painful stimuli, leading to chronic pain conditions.

Addiction: the compulsion to engage in a behavior on a continuous basis in spite of the negative consequences. Commonly used in referring to substance abuse. Addiction is different from drug dependency and tolerance.

Afferent nerve: receptor nerves that carry impulses, painful or otherwise, from the periphery of the body to the central nervous system.

Allodynia: the perception of pain to a stimulus that is usually considered nonpainful. An example would be the feeling of light touch, which is otherwise pleasant, being interpreted by the patient as painful. Many patients with neuropathic pain find the feel of clothing against their skin to be painful.

CAM: complimentary and alternative medicine (acupuncture, massage, herbal supplements, hypnosis, etc)

Chronic pain: a constellation of symptoms contributing to degrees of disability ranging from moderate but manageable pain to complete disability resulting in loss of employment, psychosocial issues, and medication dependency. Chronic pain is distinguished from acute pain in the duration of symptoms (> 6 months) and/or the healing of the predisposing injury/illness without resolution of the pain.

CPNB: continuous peripheral nerve block; refers to catheter placement with or without a continuous infusion running.

Dependence: drug dependency may occur after legal, long-term use of a medication in which abrupt cessation will result in unpleasant physical withdrawal symptoms. An individual can be drug dependent and not addicted.

Efferent nerve: nerves that carry impulses away from the central nervous system to the periphery, the “effector” nerves or motor neurons.

Endorphins: naturally occurring, endogenous opioids that act as the body’s internal pain management system, providing mild analgesia and a sense of well-being. Most commonly associated with the “runner’s high.”

Gate control theory: the idea that pain is felt, transmitted, modulated, and interpreted by a complex system of excitatory and inhibitory pathways composed of a series of neurons (first, second, third, and fourth order) in both the peripheral and central nervous systems. With acceptance of the gate control theory different types of pain were able to be defined, pharmacologic targeting of specific pathways became commonplace, and the role of inhibitory neurotransmission took on significance.

Hyperalgesia: an increased sensitivity to painful stimuli.

Multimodal pain management: the use of more than one pain management therapy. This may or may not include an intravenous PCA, a regional nerve block, CAM, or an assortment of medications. Once the primary source of discomfort has been determined, the goal is to treat it from many different mechanisms of action to maximize the effect of therapy while minimizing the side effects of each individual treatment.

Neuropathic pain: pain that is a direct result of damage to neurons. Although presentation can vary, it usually presents as an intense burning, sharp, stabbing, and lancinating pain. Patients often describe the pain as “electric shock-like.” These patients are often predisposed to allodynia and hyperalgesia.

Nocioceptors: nerve endings responsible for nociception or the ability to perceive painful stimuli. As opposed to mechanoreceptors, which monitor change in physical structure (eg, touch); thermoreceptors, which monitor changes in ambient temperature; and proprioceptors, which monitor body positioning in space.

Opioid rotation: Anderson et al (2001) defined opioid rotation as “the practice of converting from one opioid to another as clinical circumstances warrant.” The primary reasons for changing are loss of analgesic efficacy and management of side effects. The most commonly rotated narcotics are morphine and hydromorphone.

Pain threshold: the least experience of pain that a subject can recognize or the lowest level of stimulation that is perceived as painful.

Pain tolerance: the greatest level of pain that a patient is willing to tolerate.

Paresthesia: loss of normal sensation in a given distribution of the skin. Usually described as “pins and needles”; transient numbness; a tingling sensation. It is most commonly felt as the limb being “asleep.” Paresthesias are usually transient but can become chronic and generally not painful.

PCA: patient-controlled analgesia. The use of a mechanical pump controlled by the patient that provides on-demand infusion of pain medication (usually opioid). The device requires input of the infusion basal rate, bolus amount, and lock-out interval.

PCB: patient-controlled bolus. Specifically refers to the setting on the pain pumps allowing the patient to deliver a preset dose of local anesthetic during CPNB.

Phantom pain: although commonly neuropathic in nature, the term is used to describe painful sensations that arise from an absent limb or body part. Phantom limb pain varies greatly among individuals and can be absent, manageable, or totally disabling.

Phantom sensation: term used to describe a constellation of sensations (nonpainful) arising from an absent limb or body part. Here, phantom limb sensation is distinguished from phantom limb pain.

PNB: peripheral nerve block, also called a “single-injection” nerve block. **Pseudoaddiction:** the term used to describe an iatrogenic syndrome that mimics behaviors usually associated with addiction. It usually results from inadequately treated pain, leading to patient demands for medication that are erroneously interpreted by the care team as excessive.

Somatic pain: also called musculoskeletal, somatic refers to pain associated with bone, muscle, joints, skin, and connective tissue. Usually localized in nature.

Stump pain: pain localized to the amputee’s stump, frequently caused by hypertopic ossification growth, pressure from prosthetic devices, and residual wound closure/incisional pain. This pain tends to be musculoskeletal in nature but varies from patient to patient.

Tolerance: when an individual begins to require larger doses of a medication to achieve the same effect. This may be due to psychological dependence or physiologic upregulation of receptor activity and/or metabolism of the medication. Tolerance results in lack of drug efficacy if the dose is not increased. Opioid rotation may also be considered.

Visceral pain: pain of the viscera or internal organs. Most commonly described as a diffuse, pressure-like sensation, constant, aching in nature and difficult for the patient to localize except to the general area of the abdomen and/or pelvis.

Wind-up phenomena: a phrase used to describe a state of hyperexcitability and dramatically increased sensitivity (hyperalgesia) to pain as a result of continuous exposure to overwhelmingly painful stimuli. It is believed that the wind-up phenomena results in actual cortical remapping within 36 hours, predisposing the individual to chronic pain syndromes.

32. NOVEL MEDICAL ACUPUNCTURE TREATMENTS FOR ACTIVE COMBAT UNITS ON THE BATTLEFIELD

INTRODUCTION

Acupuncture has been employed in China since the second century BC to treat acute and chronic medical problems. The technique was introduced to Europe in the 16th century. In these regions, the benefits of acupuncture in treating musculoskeletal injuries are well documented, and acupuncture is widely practiced alongside mainstream Western medicine. Moreover, because of the convenience and cost-effectiveness in treating various training injuries among the military population, countries such as China, Japan, Korea, and France have incorporated acupuncture into their military medical armamentarium.

Although its introduction to American medicine has been very recent, acupuncture has steadily gained popularity. The alternative medical paradigm underlying acupuncture energetics (the use of acupuncture to move *qi*—pronounced “chi”—or life force within the human system) provides for a novel approach to treating difficult problems faced by physicians in such specialties as pain management, sports medicine, rheumatology, and internal medicine. Research has provided various possible explanations for acupuncture’s effectiveness, including the release of enkephalins and endorphins during needle stimulation with activation or suppression of various areas of the brain found on functional magnetic resonance imaging (MRI).

Acupuncture offers unique advantages as an adjunct to traditional medicine in treating conditions such as posttraumatic stress disorder, phantom limb pain, and neuropathy. It is portable, cost-effective, adaptable to harsh environments, and requires minimal training. These qualities are particularly useful to battalion surgeons (physicians embedded with active infantry units). Typically, battalion surgeons work in a tactically isolated battle zone with limited medical resources and capability. In addition,

as a sole provider for the battalion, the battalion surgeon has the daunting task of triaging all forms of trauma, as well as managing the day-to-day physical and mental health of the troops with the goal of maintaining critical mission readiness. An additional advantage acupuncture offers over traditional pain medications is the lack of side effects such as dizziness, somnolence, cardiac depression, gastrointestinal disturbance, and allergies that can potentially interfere with a soldier’s ability to execute mission critical tasks.

Many people who are unfamiliar with acupuncture have raised legitimate concerns over issues such as potential infection from needles, pain with needle insertion, and lack of evidence supporting acupuncture in the Western medical literature. Although acupuncture has been used in many Asian countries as a standard of medicine for over 2,000 years, it is only in the last several decades that the United States has been introduced to its conventions. Studies suggest that acupuncture needles, which are both sterile and disposable, involve minimal risk of infection. Also, because the needles are blunt tip and small bore (smaller than a 27-gauge needle), they typically cause minimal pain with insertion.

Acupuncture should not be thought of as a replacement for traditional medical treatment, but rather as an adjunct to enhance traditional medicine as part of a multimodal pain plan. It can potentially provide military pain management physicians with another medical tool to further improve the care of the troops on the battlefield. The remainder of this chapter does not provide a treatise on acupuncture energetics, but rather describes examples of several “tried and true” acupuncture treatments that have been effective during early 21st century conflicts.

ACUPUNCTURE NEEDLES

Acupuncture needles consist of a blunt-tip stainless steel shaft and coiled handle. Each needle is sterilely packaged inside a hollow guide tube and held in place with a small plastic chad (Figure 32-1).

Figure 32-1. SEIRIN L-type acupuncture needle with insertion tube (SEIRIN-America, Weymouth, Mass). Each L-type needle has a 20-mm stainless steel handle with either a 30-mm, 40-mm, or 60-mm needle length (also made of stainless steel), and the gauge is available in 0.20 mm, 0.25 mm, or 0.30 mm, so the practitioner may choose the best size for each patient and each acupuncture point. Photograph: Courtesy of SEIRIN-America, Weymouth, Mass.



The handles of acupuncture needles are often heated with a heat lamp or moxibustion to further amplify the treatment. Moxibustion is a technique that employs smoldering mugwort herb (moxa), rolled inside a long paper stick, to heat needles after they have been inserted. It requires well-ventilated space and has a pungent odor, so it is typically more suitable in field settings. Acupuncture treatment can also be done through ear access points with auricular pins (Figure 32-2).



Figure 32-2. ASP brand auricular pins (Lhasa OMS Inc, Weymouth, Mass); inset: detail of tip. Photograph: Courtesy of SEIRIN-America, Weymouth, Mass.

NEEDLE INSERTION TECHNIQUE

Although acupuncture needles do not cut the skin, practitioners may still prefer to wipe the skin with alcohol or iodine before insertion. Also, medical prudence must be exercised so that needles are not inserted into an area of dermatopathology (eg, cellulitis, tinea pedis, eczema).

Various methods are used to insert acupuncture needles. One technique begins with holding the guide tube between the thumb and the index finger of the nondominant hand and placing it at the insertion site (Figure 32-3a). The chad is removed with the dominant hand, and using one gentle but firm tap on the end, the needle is inserted into the skin (Figure 32-3b). Once the epidermis is traversed, the practitioner uses brisk rotation of the coil of the needle while gently pushing the needle deep into the dermis, often into the muscular layer. The insertion of the needle is complete when the patient feels a deep aching sensation with rotation of the needle. At the same time, the provider will feel more resistance with each rotation of the needle, known as “needle grabbing,” or *de qi* sensation, signifying, according to traditional Chinese theory, the engagement of the patient’s acupuncture energetics.

The second method begins with removing the needle from the guide tube, holding it between the dominant thumb and the index finger like a pencil (Figure 32-4a), and aligning it along the length of the extended third finger (Figure 32-4b). While keeping the tip of the needle close to the tip of the third finger and using the finger as a guide, the needle is inserted in one motion. It is often useful to use the nondominant hand to stretch out the skin at the insertion site, so that insertion can be achieved perpendicularly to the skin. This technique can be more difficult than the first and often requires more practice to master; however, patients often find it more comfortable.

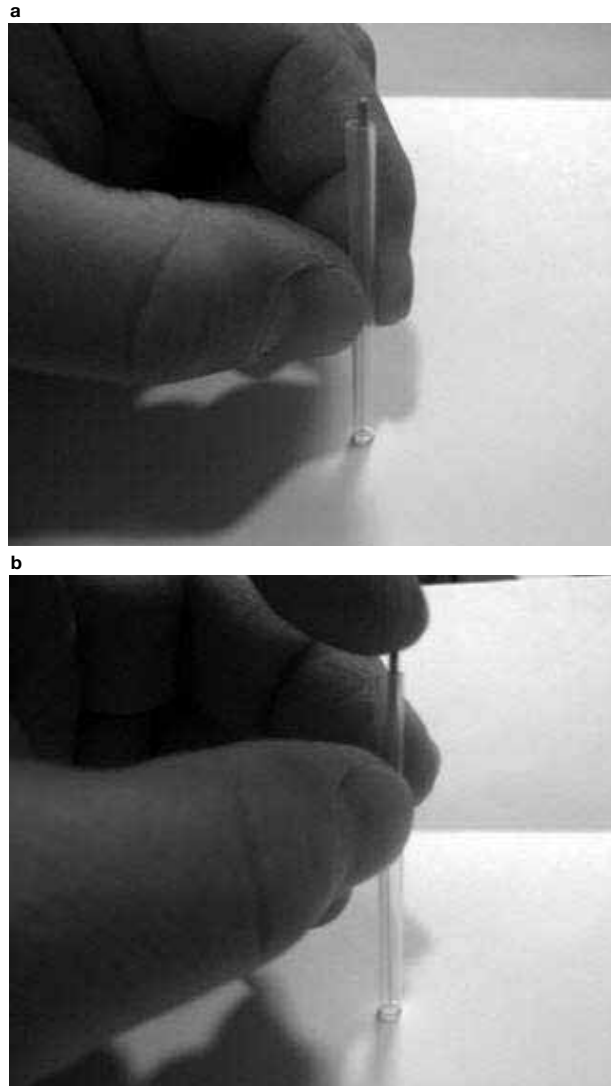


Figure 32-3




Figure 32-4

BATTLEFIELD ACUPUNCTURE

Auricular acupuncture was revolutionized in the United States by Air Force Colonel Richard Niemtow's battlefield acupuncture technique. In this technique, points on the ears are accessed with ASP (Aiguille Semi-Permanent) needles to activate corresponding areas in the brain that have been shown by functional MRI to modulate both acute and chronic pain, mainly the thalamus and cingulate gyrus, respectively (Figure 32-5). Preloaded in an injector, the ASP pins can be placed at the site of insertion by a gentle push of the guide tube. Because the pins can be left in the skin for 2 to 3 days, an alcohol pad should be used to clean the area before insertion.

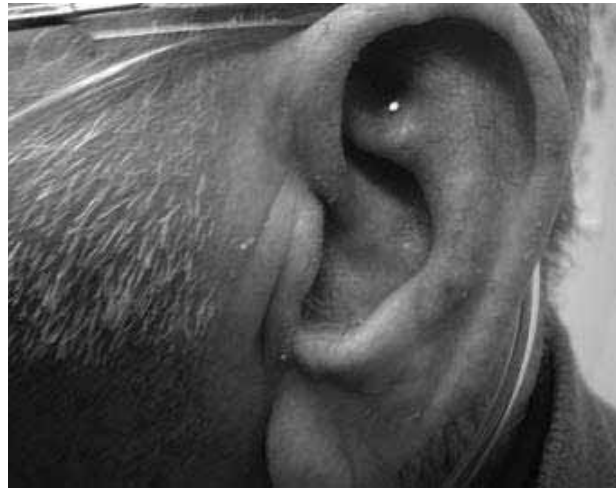

Figure 32-5. Battlefield acupuncture. Photograph: Courtesy of Colonel Richard Niemtow.

TREATMENTS

Severe Heat Exhaustion, Heat Stroke, Shock, Unconsciousness, Acute Muscular and Lower Back Spasm

Acupuncture point: Governor vessel 26 (GV26), located on the face at the midline, at the junction of the upper third and lower two thirds of the distance from the nose to the lip (Figure 32-6).

GV26, a potent reviving point for patients with extreme heat exhaustion and shock, can be used in a mass casualty setting. Place the acupuncture needle into the GV26 point directed toward the center of the head, and vigorously rotate it clockwise while achieving *de qi* sensation. This sensation is usually felt at an approximate depth of 2 cm. Continue rotating the needle clockwise until the patient is revived, after which the needle should be removed. This procedure should only be instituted following standard trauma protocols initiated by the medical unit.

In addition to use in shock, the GV26 point can be used to revive patients following a vasovagal episode. GV26 is also an excellent point for relieving

ing pain from acute muscle spasm. Physicians embedded in a mobile unit often have limited or difficult-to-access medical supplies. When a patient develops acute lower back or other muscular

a

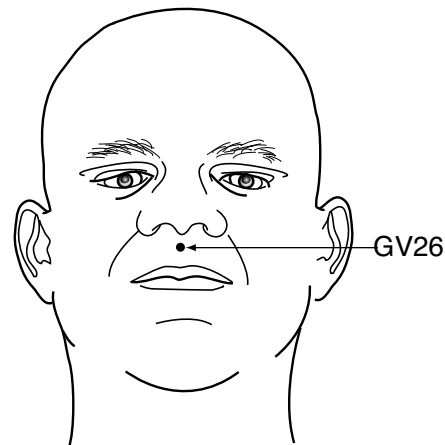


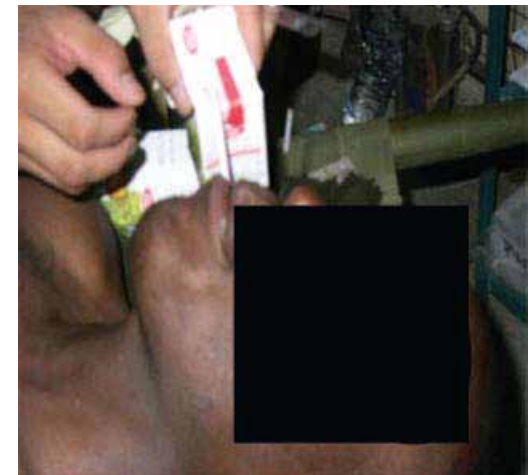Figure 32-6

spasm and is unable to ambulate, placing a needle in GV26 and having the patient rotate it while slowly standing up and walking restores function within minutes, without parenteral or sedating medications.

b



c



Tension Headaches, Neck Pain, Shoulder Pain

Acupuncture points (Figure 32-7):

- Small intestine 11 (SI11), located at the middle of the infraspinous fossa in the infraspinatus muscle.
- Small intestine 12 (SI12), located in the middle of the supraspinous fossa.
- Gallbladder 21 (GB21), located in the middle belly of the trapezius.
- Triple heater 15 (TH15), located at the levator scapula insertion at the superior angle of the scapula.

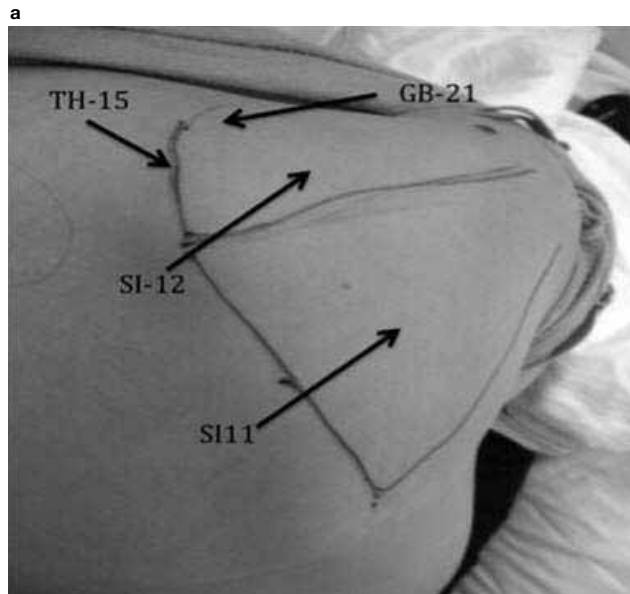
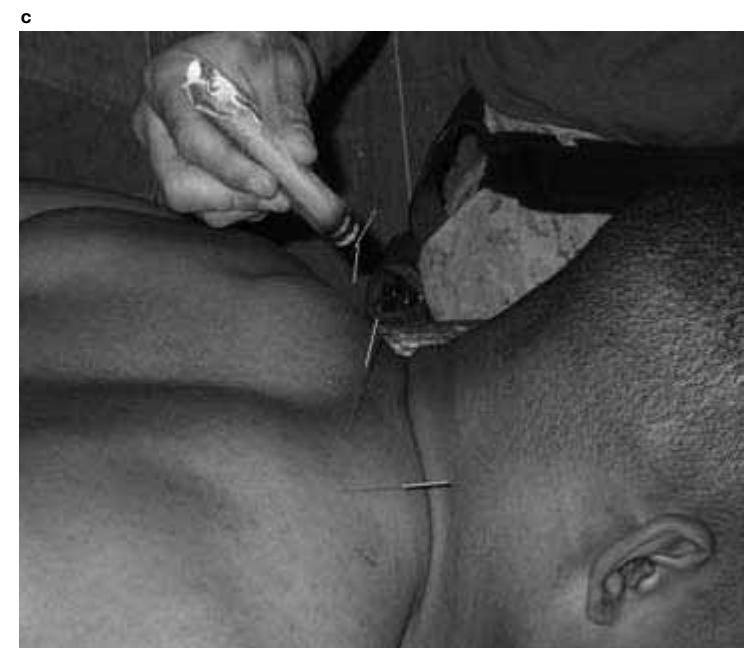
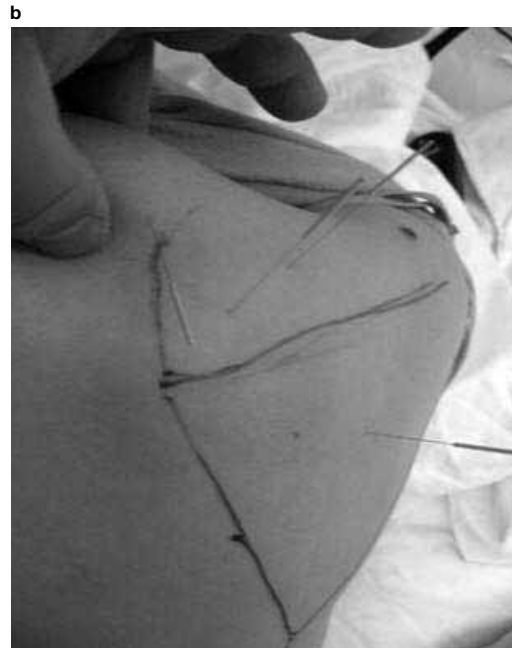
Figure 32-7

These are outstanding points for relieving severe shoulder and neck strain and tension headaches. SI11 is inserted perpendicularly into the depression in the infraspinous fossa. SI12 is inserted at the middle of the supraspinous fossa, into the supraspinatus trigger point. GB21 is inserted into the middle belly of the trapezius. To reduce concern for pneumothorax, grasp the anterior and posterior belly of the trapezius muscle and lift it off the rib cage, so that the needle can be inserted parallel to the plane of the rib cage. TH15 is inserted into the levator

scapula insertion at the superior scapular angle. The depth of levator scapula can vary depending on the musculature of individuals, but the *de qi* sensation is typically felt before the needle is deeply inserted.

Often an area of erythema appears around the site after insertion of acupuncture needles into an activated trigger point. This is neither a side effect nor a histamine release; rather, the erythema correlates to the severity of the trigger tension. Once the trigger activation has been eased, normal skin color will return.



Hyperadrenergic States, Combat Stress, Insomnia, Anxiety, Agitation

Acupuncture points:

- Liver 3 (LR3), located in the dorsum of the foot, on the first interosseous space of the metatarsus, in a depression distal to the intermetatarsal joint between the first and second metatarsal bones (Figures 32-8a, b).
- Heart 3 (HT3), located in the anterior antecubital region, at the ulnar end of the cubital crease (Figures 32-8c, d).
- Governor vessel 20 (GV20), located at the midsagittal point, a depression on the head at the intersection of lines drawn from the inferior ear lobes through the superior apices of the bilateral ear lobes (Figure 32-8e).

With the constant threat of enemy attacks and frequent combat missions, many troops develop early signs of combat stress such as insomnia, agitation, and panic attacks. Combinations of bilateral LR3, HT3, and GV20 provide a calming effect on panic symptoms, often allowing the patient to fall asleep. In fact, more patients preferred acupuncture to the traditional beta-blockers, selective serotonin reuptake inhibitors, and zolpidem. LR3 can be found by sliding the thumb between the first and second interosseous space until it falls into a depression. HT3 is best accessed when the elbow is flexed. GV20 can be identified by placing the middle finger on the inferior end of the ear lobe and the tips of the thumbs together over the midsagittal line while the hands traverse through the superior apices of each ear. Needles used at these points should not be heated, which could overstimulate an already hyperadrenergic state. If necessary, keep the patient warm with a warming blanket. Leave the needles in place for 15 to 20 minutes and then remove them. A successful protocol in the deployed setting involved repeating the treatment twice a week until the patients' symptoms abated.

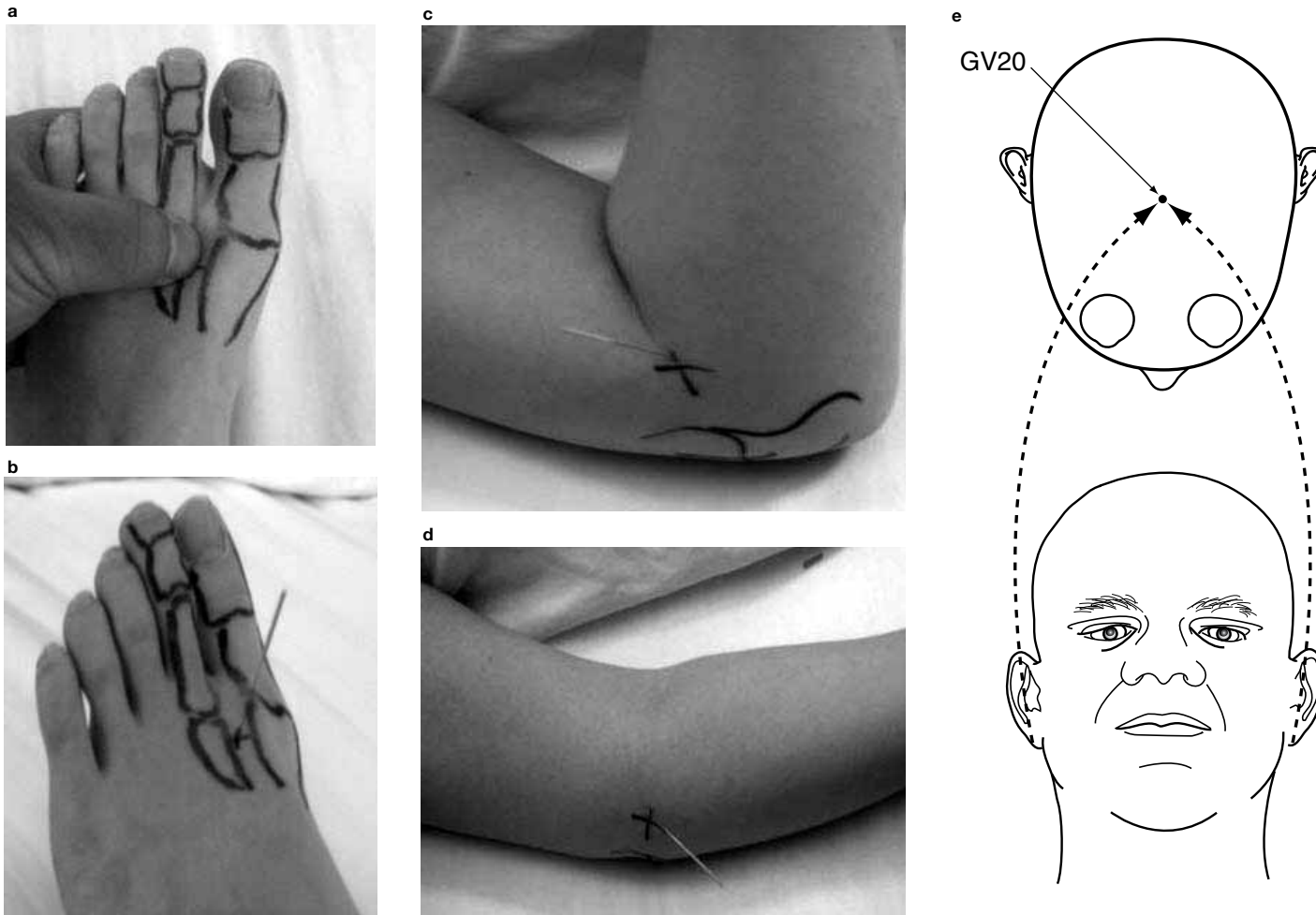


Figure 32-8

Soft Tissue Injuries and Ankle Sprains

At many functional points and trigger points, typically found in muscles and depressions in the skin, the strain and stress of underlying tissues can be reduced with the insertion of acupuncture needles into the surrounding tissue (Figure 32-9). Enough acupuncture energetic points traverse the body that a needle placed subcutaneously or into the trigger

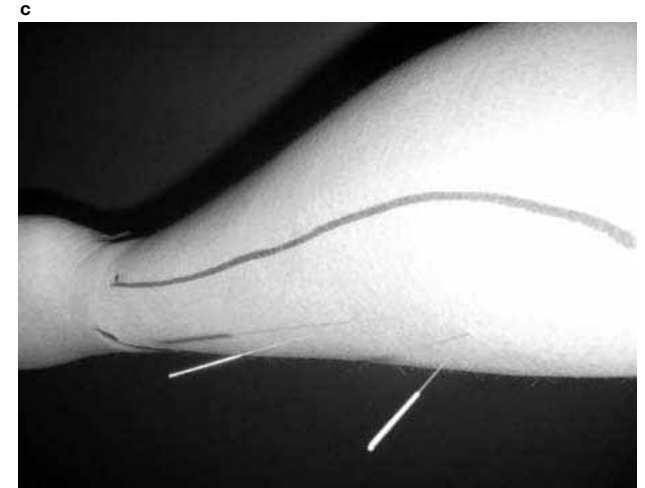
points of a muscle will reduce pain and swelling. The needles can be heated with moxibustion to improve efficacy and left in place for 15 to 20 minutes.

Traditional treatment of ankle sprains is not feasible in an active combat zone, due to the need for immobilization, lack of ice, and prolonged recovery period. An acupuncture protocol employing three

or four needles inserted immediately into the soft tissue surrounding the area of edema and pain can reduce swelling within 24 hours and restore the patient's functional status. Most muscles strains were reduced with one to two needles placed into the most tender part of the muscles for 15 to 20 minutes, often with moxibustion.

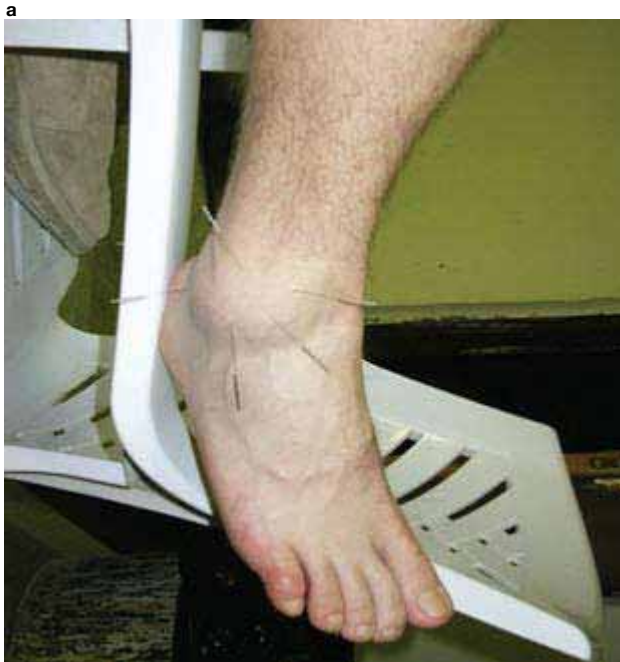

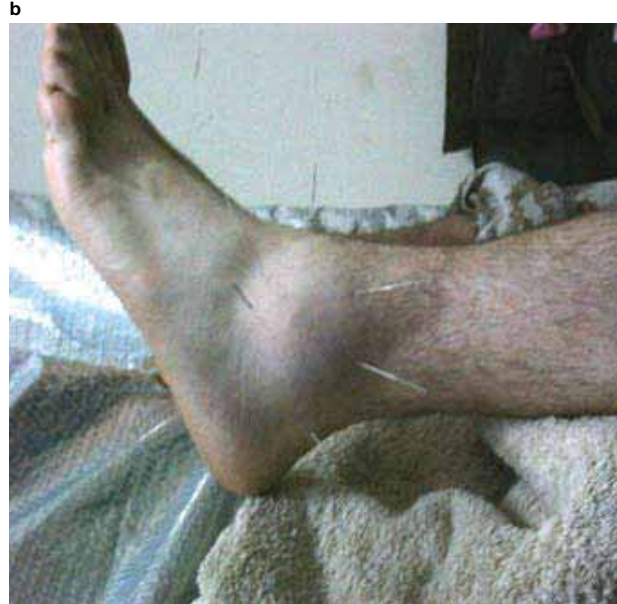Figure 32-9



Physical Fatigue and Emotional Exhaustion

Acupuncture point: “Ming men” governor vessel 4 (GV4), located at the interspinal space of the L2 and L3 spinal processes (two lateral depressions can be found by sliding thumbs bilaterally from the GV4 point, Figure 32-10). Because this point is in the large paraspinal muscles, needles can be inserted deeper than usual. Insert the needles until the *de qi* sensation is felt, heat them with moxa for 10 to 20 minutes, and remove them. With a steady swinging motion of the moxa from needle to needle, patients should feel energized and lower backaches relieved.




Figure 32-10

Chronic Pain and Recurring Acute Pain

Niemtzow’s battlefield acupuncture can help individuals who require frequent referrals to specialists, are often placed on light duty status, or have chronic pain syndromes but are otherwise capable of performing their duties. After cleaning the ear with an alcohol pad, the practitioner should place ASP pins starting with the cingulate gyrus, thalamus, and omega-2 points on one ear (Figure 32-11), and then the next ear. The “Shen men” and point zero points typically provide a calming and balancing effect on the patient. While the pins are in place, the surrounding skin must be observed for any possible sign of infection. Patients should be reassured that the pins will come out by themselves.

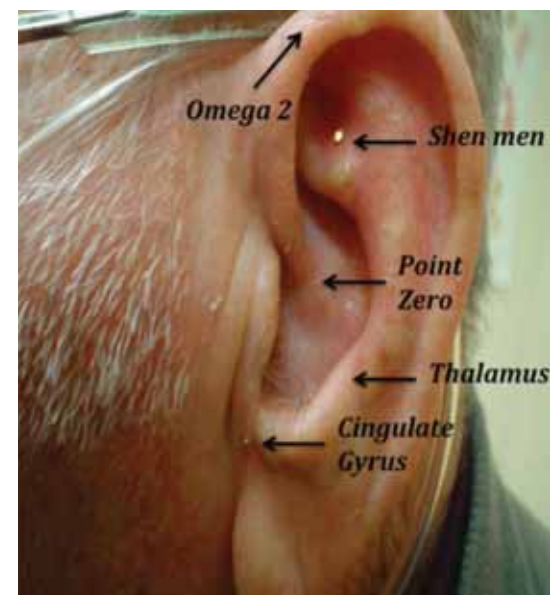


Figure 32-11. Photograph: Courtesy of Colonel Richard Niemtow.

FURTHER READING

Chapter 1

Connor JT. Military medicine, its technology and transition in the mid-twentieth century. *Mil Med.* 2004;169:ix–xi.

Silberman S. The painful truth. *Wired.* 2005;2(13):112–123.

Chapter 3

Buckenmaier CC III, Bleckner LL. Anaesthetic agents for advanced regional anaesthesia: a North American perspective. *Drugs.* 2005;65:745–759.

Tetzlaff JE. The pharmacology of local anesthetics. *Anesthesiol Clin North America.* 2000;18:217–233.

Chapter 4

Dabu A, Chan V. *A Practical Guide to Ultrasound Imaging for Peripheral Nerve Blocks.* Toronto, Canada: University of Toronto; 2004.

De AJ, Sala-Blanch X. Peripheral nerve stimulation in the practice of brachial plexus anesthesia: a review. *Reg Anesth Pain Med.* 2001;26:478–483.

Grau T. Ultrasonography in the current practice of regional anaesthesia. *Best Pract Res Clin Anaesthesiol.* 2005;19:175–200.

Marhofer P, Greher M, Kapral S. Ultrasound guidance in regional anaesthesia. *Br J Anaesth.* 2005;94:7–17.

Chapter 5

Evans H, Steele SM, Nielsen KC, Tucker MS, Klein SM. Peripheral nerve blocks and continuous catheter techniques. *Anesthesiol Clin North America.* 2005;23:141–162.

Lanz E, Theiss D, Jankovic D. The extent of blockade following various techniques of brachial plexus block. *Anesth Analg.* 1983;62:55–58.

Neal JM, Hebl JR, Gerancher JC, Hogan QH. Brachial plexus anesthesia: essentials of our current understanding. *Reg Anesth Pain Med.* 2002;27:402–428.

Chapter 6

Pandit JJ, Bree S, Dillon P, Elcock D, McLaren ID, Crider B. A comparison of superficial versus combined (superficial and deep) cervical plexus block for carotid endarterectomy: a prospective, randomized study. *Anesth Analg.* 2000;91:781–786.

Pandit JJ, Dutta D, Morris JF. Spread of injectate with superficial cervical plexus block in humans: an anatomical study. *Br J Anaesth.* 2003;91:733–735.

Winnie AP, Ramamurthy S, Durrani Z, Radonjic R. Interscalene cervical plexus block: a single-injection technic. *Anesth Analg.* 1975;54:370–375.

Chapter 7

Chan VW: Applying ultrasound imaging to interscalene brachial plexus block. *Reg Anesth Pain Med.* 2003;28:340–343.

Silverstein WB, Saiyed MU, Brown AR. Interscalene block with a nerve stimulator: a deltoid motor response is a satisfactory endpoint for successful block. *Reg Anesth Pain Med.* 2000;25:356–359.

Urmey WF, McDonald M. Hemidiaphragmatic paresis during interscalene brachial plexus block: effects on pulmonary function and chest wall mechanics. *Anesth Analg.* 1992;74:352–357.

Winnie AP. Interscalene brachial plexus block. *Anesth Analg.* 1970;49:455–466.

Chapter 8

Chan VW, Perlas A, Rawson R, Odukoya O. Ultrasound-guided supraclavicular brachial plexus block. *Anesth Analg.* 2003;97:1514–1517.

Franco CD, Vieira ZE. 1,001 subclavian perivascular brachial plexus blocks: success with a nerve stimulator. *Reg Anesth Pain Med.* 2000;25:41–46.

Neal JM, Moore JM, Kopacz DJ, Liu SS, Kramer DJ, Plorde JJ. Quantitative analysis of respiratory, motor, and sensory function after supraclavicular block. *Anesth Analg.* 1998;86:1239–1244.

Winnie AP, Collins VJ. The subclavian perivascular technique of brachial plexus anesthesia. *Anesthesiology.* 1964;25:353–363.

Chapter 9

Lecamwasam H, Mayfield J, Rosow L, Chang Y, Carter C, Rosow C. Stimulation of the posterior cord predicts successful infraclavicular block. *Anesth Analg.* 2006;102:1564–1568.

Ootaki C, Hayashi H, Amano M. Ultrasound-guided infraclavicular brachial plexus block: an alternative technique to anatomical landmark-guided approaches. *Reg Anesth Pain Med.* 2000;25:600–604.

Rodriguez J, Barcena M, Rodriguez V, Aneiros F, Alvarez J. Infraclavicular brachial plexus block effects on respiratory function and extent of the block. *Reg Anesth Pain Med.* 1998;23:564–568.

Wilson JL, Brown DL, Wong GY, Ehman RL, Cahill DR: Infraclavicular brachial plexus block: parasagittal anatomy important to the coracoid technique. *Anesth Analg.* 1998;87:870–873.

Chapter 10

Coventry DM, Barker KF, Thomson M. Comparison of two neurostimulation techniques for axillary brachial plexus blockade. *Br J Anaesth.* 2001;86:80–83.

Retzl G, Kapral S, Greher M, Mauritz W. Ultrasonographic findings of the axillary part of the brachial plexus. *Anesth Analg.* 2001;92:1271–1275.

Spence BC, Sites BD, Beach ML. Ultrasound-guided musculocutaneous nerve block: a description of a novel technique. *Reg Anesth Pain Med.* 2005;30:198–201.

Chapter 11

Dilger JA, Wells RE, Jr. The use of peripheral nerve blocks at the elbow for carpal tunnel release. *J Clin Anesth.* 2005;17:621–623.

McCartney CJ, Xu D, Constantinescu C, Abbas S, Chan VW. Ultrasound examination of peripheral nerves in the forearm. *Reg Anesth Pain Med.* 2007;32:434–439.

Chapter 12

Karmakar MK. Thoracic paravertebral block. *Anesthesiology.* 2001;95:771–780.

Klein SM, Bergh A, Steele SM, Georgiade GS, Greengrass RA. Thoracic paravertebral block for breast surgery. *Anesth Analg.* 2000;90:1402–1405.

Naja MZ, Gustafsson AC, Ziade MF, et al. Distance between the skin and the thoracic paravertebral space. *Anaesthesia.* 2005;60:680–684.

Naja MZ, Ziade MF, El Rajab R, El Tayara K, Lonnqvist PA. Varying anatomical injection points within the thoracic paravertebral space: effect on spread of solution and nerve blockade. *Anaesthesia.* 2004;59:459–463.

Chapter 13

Enneking FK, Chan V, Greger J, Hadzic A, Lang SA, Horlocker TT. Lower-extremity peripheral nerve blockade: essentials of our current understanding. *Reg Anesth Pain Med.* 2005;30:4–35.

Evans H, Steele SM, Nielsen KC, Tucker MS, Klein SM. Peripheral nerve blocks and continuous catheter techniques. *Anesthesiol Clin North America.* 2005;23:141–162.

Chapter 14

Awad IT, Duggan EM. Posterior lumbar plexus block: anatomy, approaches, and techniques. *Reg Anesth Pain Med.* 2005;30:143–149.

Capdevila X, Coimbra C, Choquet O. Approaches to the lumbar plexus: success, risks, and outcome. *Reg Anesth Pain Med.* 2005;30:150–162.

Farny J, Drolet P, Girard M. Anatomy of the posterior approach to the lumbar plexus block. *Can J Anaesth.* 1994;41:480–485.

Kirchmair L, Entner T, Kapral S, Mitterschiffthaler G. Ultrasound guidance for the psoas compartment block: an imaging study. *Anesth Analg.* 2002;94:706–710.

Chapter 15

Gray AT, Collins AB, Schafhalter-Zoppoth I. An introduction to femoral nerve and associated lumbar plexus nerve blocks under ultrasonic guidance. *Techniques Reg Anesth Pain Manage.* 2004;8:155–163.

Marhofer P, Nasel C, Sitzwohl C, Kapral S. Magnetic resonance imaging of the distribution of local anesthetic during the three-in-one block. *Anesth Analg.* 2000;90:119–124.

Nielsen KC, Klein SM, Steele SM. Femoral nerve blocks. *Techniques Reg Anesth Pain Manage.* 2003;7:8–17.

Vloka JD, Hadzic A, Drobnik L, Ernest A, Reiss W, Thys DM. Anatomical landmarks for femoral nerve block: a comparison of four needle insertion sites. *Anesth Analg.* 1999;89:1467–1470.

Chapter 16

Bouaziz H, Vial F, Jochum D, et al. An evaluation of the cutaneous distribution after obturator nerve block. *Anesth Analg.* 2002;94:445–449.

Capdevila X, Biboulet P, Bouregba M, Barthelet Y, Rubenovitch J, d'Athis F. Comparison of the three-in-one and fascia iliaca compartment blocks in adults: clinical and radiographic analysis. *Anesth Analg.* 1998;86:1039–1044.

Hopkins PM, Ellis FR, Halsall PJ. Evaluation of local anaesthetic blockade of the lateral femoral cutaneous nerve. *Anaesthesia.* 1991;46:95–96.

Chapter 17

Bollini CA, Moreno M. Sciatic nerve block. *Techniques Reg Anesth Pain Manage.* 2006;10:163–172.

Chan VW, Nova H, Abbas S, McCartney CJ, Perlas A, Xu DQ. Ultrasound examination and localization of the sciatic nerve: a volunteer study. *Anesthesiology.* 2006;104:309–314.

Karmakar MK, Kwok WH, Ho AM, Tsang K, Chui PT, Gin T. Ultrasound-guided sciatic nerve block: description of a new approach at the subgluteal space. *Br J Anaesth.* 2007;98:390–395.

Chapter 18

Chelly JE, Delaunay L. A new anterior approach to the sciatic nerve block. *Anesthesiology.* 1999;91:1655–1660.

Ericksen ML, Swenson JD, Pace NL. The anatomic relationship of the sciatic nerve to the lesser trochanter: implications for anterior sciatic nerve block. *Anesth Analg.* 2002;95:1071–1074.

Vloka JD, Hadzic A, April E, Thys DM. Anterior approach to the sciatic nerve block: the effects of leg rotation. *Anesth Analg.* 2001;92:460–462.

Chapter 19

Domingo-Triado V, Selfa S, Martinez F, et al. Ultrasound guidance for lateral midfemoral sciatic nerve block: a prospective, comparative, randomized study. *Anesth Analg.* 2007;104:1270–1274.

Hadzic A, Vloka JD. A comparison of the posterior versus lateral approaches to the block of the sciatic nerve in the popliteal fossa. *Anesthesiology*. 1998;88:1480–1486.

Taboada MM, Alvarez J, Cortes J, Rodriguez J, Atanassoff PG. Lateral approach to the sciatic nerve block in the popliteal fossa: correlation between evoked motor response and sensory block. *Reg Anesth Pain Med*. 2003;28:450–455.

Chapter 20

Benzon HT, Kim C, Benzon HP, et al. Correlation between evoked motor response of the sciatic nerve and sensory blockade. *Anesthesiology*. 1997;87:547–552.

Sinha A, Chan VW. Ultrasound imaging for popliteal sciatic nerve block. *Reg Anesth Pain Med*. 2004;29:130–134.

Vloka JD, Hadzic A, April E, Thys DM. The division of the sciatic nerve in the popliteal fossa: anatomical implications for popliteal nerve blockade. *Anesth Analg*. 2001;92:215–217.

Chapter 21

Benzon HT, Sharma S, Calimaran A. Comparison of the different approaches to saphenous nerve block. *Anesthesiology*. 2005;102:633–638.

De Mey JC, Deruyck LJ, Cammu G, De Baerdemaeker LE, Mortier EP. A paravenous approach for the saphenous nerve block. *Reg Anesth Pain Med*. 2001;26:504–506.

van der WM, Lang SA, Yip RW. Transsartorial approach for saphenous nerve block. *Can J Anaesth*. 1993;40:542–546.

Chapter 22

Myerson MS, Ruland CM, Allon SM. Regional anesthesia for foot and ankle surgery. *Foot Ankle*. 1992;13:282–288.

Schurman DJ. Ankle-block anesthesia for foot surgery. *Anesthesiology*. 1976;44:348–352.

Chapter 23

Colbern E. The Bier block for intravenous regional anesthesia: technic and literature review. *Anesth Analg*. 1970;49:935–940.

Hilgenhurst G. The Bier block after 80 years: a historical review. *Reg Anesth*. 1990;15:2–5.

Chapter 24

Liu SS, Salinas FV. Continuous plexus and peripheral nerve blocks for postoperative analgesia. *Anesth Analg*. 2003;96:263–272.

Chapter 25

Brull R, McCartney CJ, Chan VW, El-Beheiry H. Neurological complications after regional anesthesia: contemporary estimates of risk. *Anesth Analg*. 2007;104:965–974.

Buckenmaier CC III, Shields CH, Auton AA, et al. Continuous peripheral nerve block in combat casualties receiving low-molecular weight heparin. *Br J Anaesth*. 2006;97:874–877.

Ho M, Ganapathy S. Is peripheral/plexus block safe in the anticoagulated patient? *Techniques Reg Anesth Pain Manag*. 2006;10:56–61.

Horlocker TT, Wedel DJ, Benzon H, et al. Regional anesthesia in the anticoagulated patient: defining the risks (the second ASRA Consensus Conference on Neuraxial Anesthesia and Anticoagulation). *Reg Anesth Pain Med*. 2003;28:172–197.

Chapter 26

Buckenmaier CC, McKnight GM, Winkley JV, et al. Continuous peripheral nerve block for battlefield anesthesia and evacuation. *Reg Anesth Pain Med*. 2005;30:202–205.

Shorten G, Carr DB, Harmon D, Puig MM, Browne J. *Postoperative Pain Management*. Philadelphia, Pa: Saunders Elsevier; 2006.

Chapter 27

Apfelbaum JL, Chen C, Mehta SS, Gan TJ. Postoperative pain experience: results from a national survey suggest postoperative pain continues to be undermanaged. *Anesth Analg*. 2003;97:534–540.

Perkins FM, Kehlet H. Chronic pain as an outcome of surgery. A review of predictive factors. *Anesthesiology*. 2000;93:1123–1133.

Rathmell JP, Wu CL, Sinatra RS, et al. Acute post-surgical pain management: a critical appraisal of current practice, December 2–4, 2005. *Reg Anesth Pain Med*. 2006;31:1–42.

Chapter 28

Cohen SP, Griffith S, Larkin TM, Villena F, Larkin R. Presentation, diagnoses, mechanisms of injury, and treatment of soldiers injured in Operation Iraqi Freedom: an epidemiological study conducted at two military pain management centers. *Anesth Analg*. 2005;101:1098–1103.

White RL, Cohen SP. Return-to-duty rates among coalition forces treated in a forward-deployed pain treatment center: a prospective observational study. *Anesthesiology*. 2007;107:1003–1008.

Chapter 29

Warren J, Fromm RE, Orr RA, Rotello RC, Horst HM. American College of Critical Care Medicine: guidelines for the inter- and intrahospital transport of critically ill patients. *Crit Care Med*. 2004;32:256–262.

Chapter 30

Dalens B, Vanneuville G, Tanguy A. A new parascapular approach to the brachial plexus in children: comparison with the supraclavicular approach.

FURTHER READING

Anesth Analg. 1987;66:1264–1271.

Puncuh F, Lampugnani E, Kokki H. Use of spinal anaesthesia in paediatric patients: a single centre experience with 1132 cases. *Paediatr Anaesth.* 2004;14:564–567.

Schuepfer G, Johr M. Psoas compartment block in children: Part I—description of the technique. *Paediatr Anaesth.* 2005;15:461–464.

Chapter 31

Frenette L. The acute pain service. *Crit Care Clin.* 1999;15:143–150.

Ready LB. Acute pain: lessons learned from 25,000 patients. *Reg Anesth Pain Med.* 1999;24:499–505.

Werner MU, Soholm L, Rotboll-Nielsen P, Kehlet H. Does an acute pain service improve postoperative outcome? *Anesth Analg.* 2002;95:1361–1372.

Chapter 32

Han J. Physiology of acupuncture: review of thirty years of research. *J Alter Compl Med.* 1997;3:s-101–s-108.

Kaptchuk TJ. Acupuncture: theory, efficacy, and practice. *Ann Intern Med.* 2002;136:374–383.

Niemtzow RC. Battlefield acupuncture. *Medical Acupuncture.* 2007;19(4):225–228. http://www.liebertpub.com/publication.aspx?pub_id=233. Accessed July 1, 2008.

ABBREVIATIONS AND ACRONYMS

AAG: α_1 -acid glycoprotein	MRI: magnetic resonance imaging
ACLS: advanced cardiac life support	MRN: magnetic resonance neurography
AE: aeromedical evacuation	ms: millisecond
AES: aeromedical evacuation system	NBI: nonbattle injury
AMBUS: ambulance bus	NMDA: N-methyl D-aspartate
APS: acute pain service	NSAID: nonsteroidal antiinflammatory drug
ASIS: anterior superior iliac spine	PCA: patient-controlled analgesia
ASP: semipermanent needle (French)	pK: dissociation constant
ATPase: adenosine triphosphatase	PNB: peripheral nerve block
CASEVAC: casualty evacuation	PNS: peripheral nerve stimulator
CCATT: critical care air transport team	PSIS: posterior superior iliac spine
COX: cyclooxygenase	PVB: paravertebral nerve block
CPNB: continuous peripheral nerve block	RATS: Regional Anesthesia Tracking System
CSH: combat support hospital	PSIS: posterior superior iliac spine
CT: computed tomography	SCM: sternocleidomastoid muscle
EMG: electromyography	SH: sacral hiatus
ESI: epidural steroid injection	SI: sacroiliac
FVC: forced vital capacity	STRATEVAC: strategic evacuation
IV: intravenous	TACEVAC: tactical evacuation
LBP: low back pain	TB: trochanteric bursitis
LFC: lateral femoral cutaneous	TFESI: transforaminal epidural steroid injection
MARAA: Military Advanced Regional Anesthesia and Analgesia	USAF: US Air Force
MEDEVAC: medical evacuation	WRAMC: Walter Reed Army Medical Center