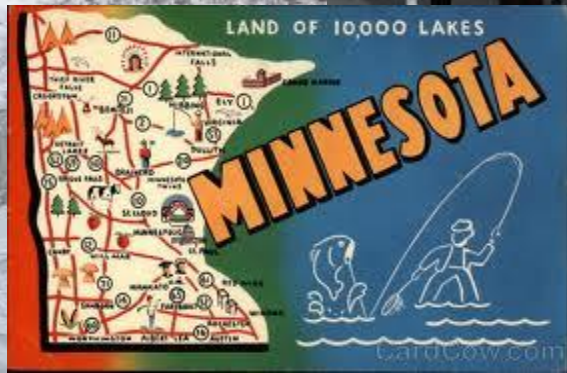

Mitrofanoffs, Maces and Bladder Augmentations (Oh My!)



**TIPS AND TRICKS TO MANAGE THE
PROBLEMS.**

**ANNE BOISCLAIR-FAHEY, DNP, RN, CNP
UNIVERSITY OF MINNESOTA**



Financial Disclosure



- I do have a financial relationship with CURE Medical
- I will be discussing the use of several different medical companies' products whom I do not have a financial relationship with.

Learning Objectives



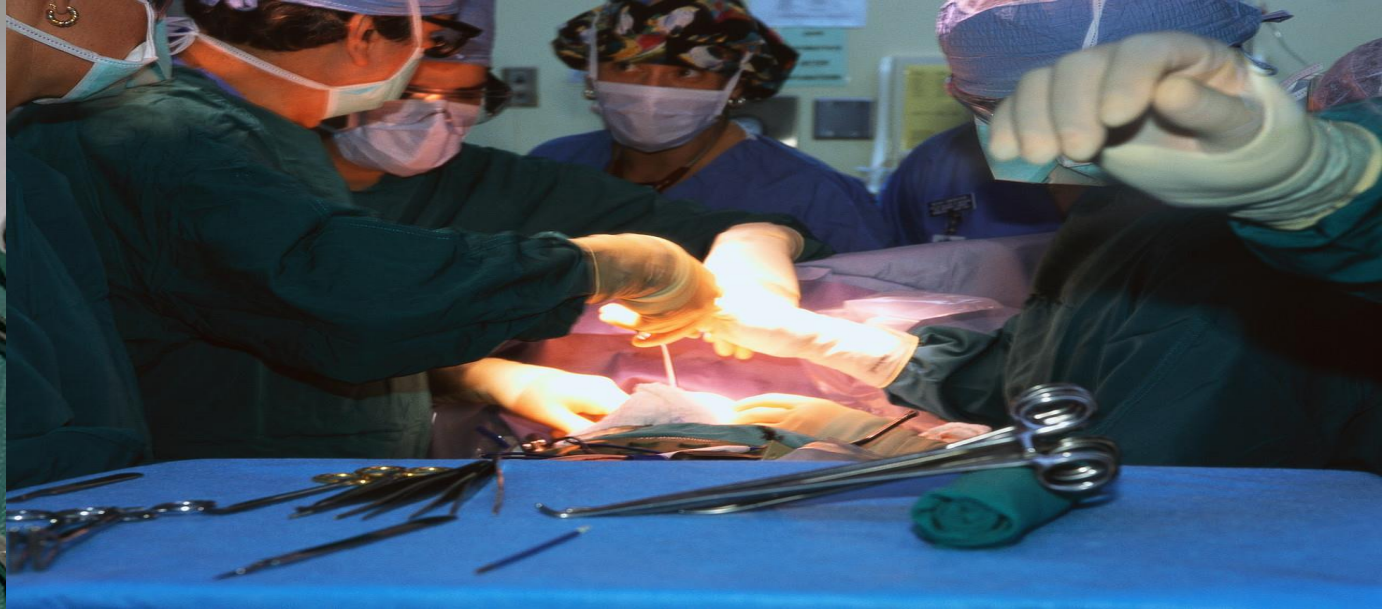
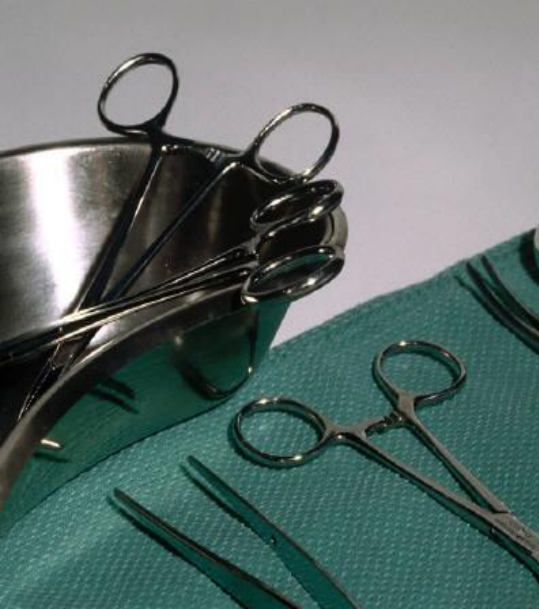
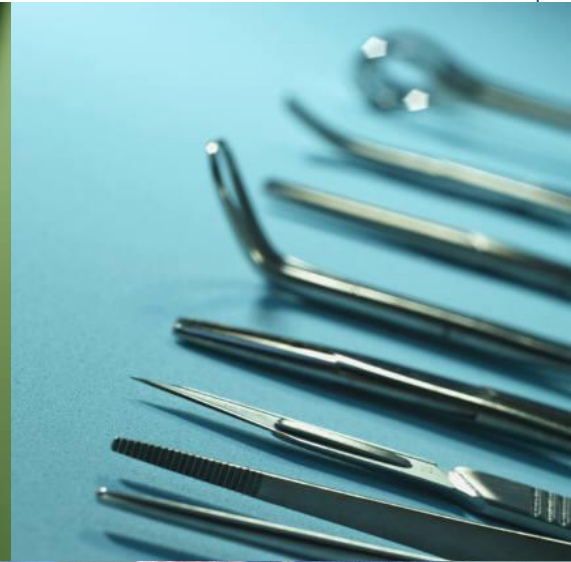- At the end of this talk, the learner will be able to:
 - Understand the surgical procedures used to create a Mitrofanoff, Mace and Bladder Augmentation
 - Demonstrate knowledge on how to decrease the risk of developing bladder stones
 - Manage stomal stenosis
 - Successfully catheterize a Mitrofanoff channel with false passages
 - Manage MACE irrigations for successful output

Neurogenic Bowel and Bladder



- Patients with Spina Bifida or spinal cord injury have neurogenic bowel and bladder
- Stool soiling and urinary incontinence is common and affects their quality of life
- Surgical procedures are performed to protect the kidneys, manage the urinary incontinence, and stool soiling
- This talk discusses in detail those surgical procedures, and management of those problems

Surgical Procedures



Surgical Procedures



- **Bladder Surgical Procedures**
 - Mitrofanoff procedure
 - Monti Procedure
 - Bladder Augmentation

- **Bowel Surgical Procedures**
 - ACE or MACE procedure
 - Cecostomy with Chait tube

Bladder Surgical Procedures

Bladder Management: Mitrofanoff Procedure



- **Mitrofanoff**

Procedure that involves using the appendix, ureter or some other tubular structure to create a catheterizable stoma for bladder emptying.

- The distal end of the “tube” is implanted into the posterior wall of the bladder. The other end is brought out through the belly button or small stoma so intermittent catheterization can easily be performed

Bladder Management: Monti Procedure



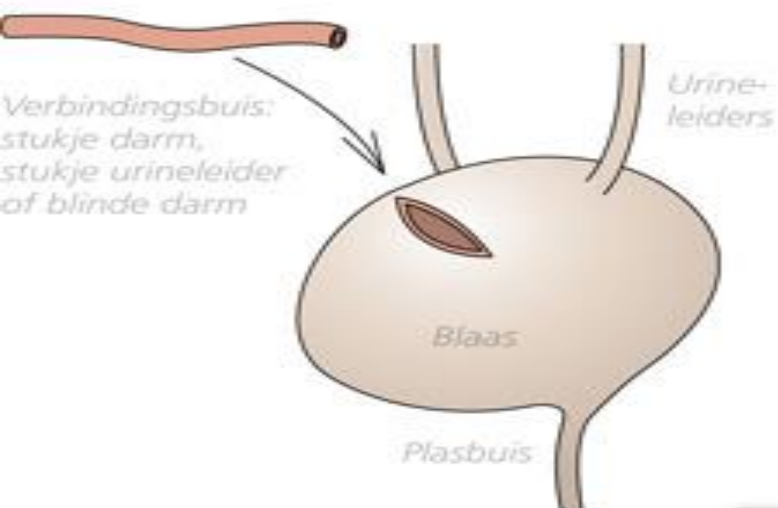
- **Monti**

This procedure creates an alternative urinary conduit using a portion of the ileum between the bladder and the abdominal wall.

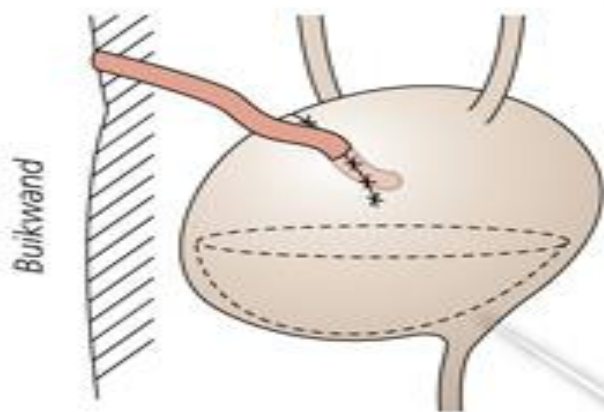
- Same as Mitrofanoff, but uses ileum instead of appendix or ureter
- Tube is “fashioned” by using a portion of ileum sewing or stapling the edges together to create a catheterizable, tubular channel

MITROFANOFF: EEN CONTINENT URINESTOMA

Tussen de blaas en de buikwand wordt een nieuwe verbinding gemaakt.



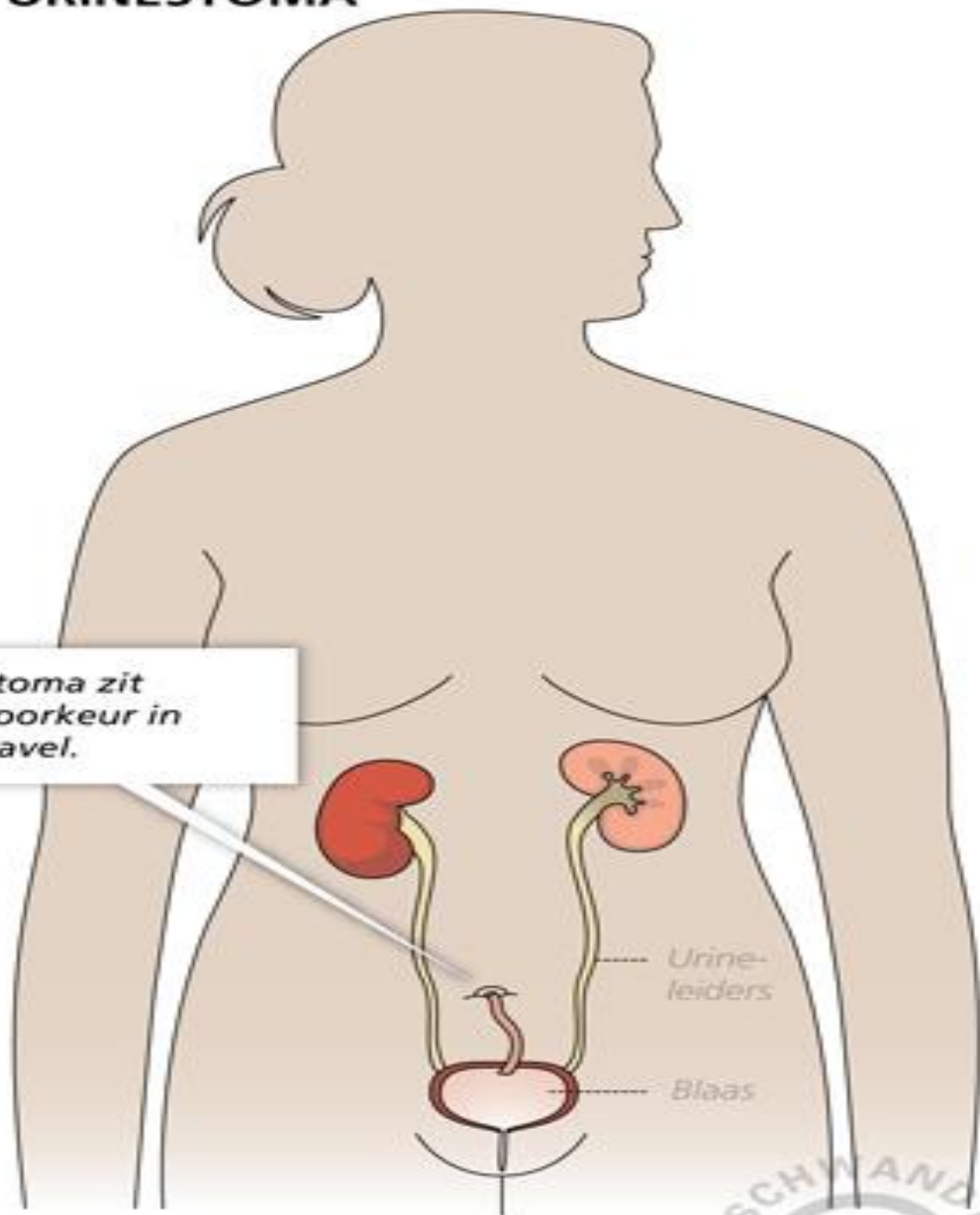
1. De nieuwe verbinding wordt aan de blaas en aan de buikwand vastgezet.



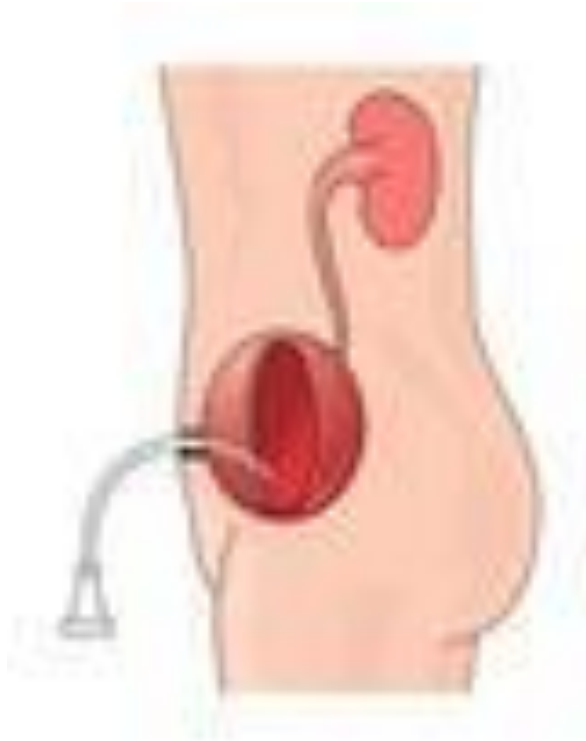2. Als de blaas vol is, wordt de verbindingsbuis dichtgedruwd, zodat de urine niet zomaar naar buiten kan stromen.

De stoma zit bij voorkeur in de navel.

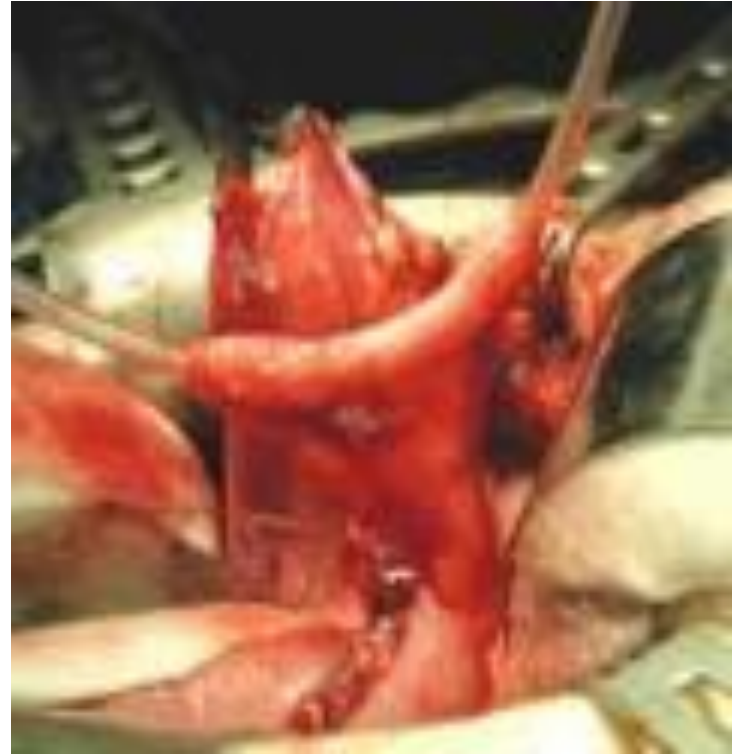De blaas zelf blijft het reservoir voor urine.



Creating a Mitrofanoff or Monti



shutterstock · 24128797



Stoma Locations

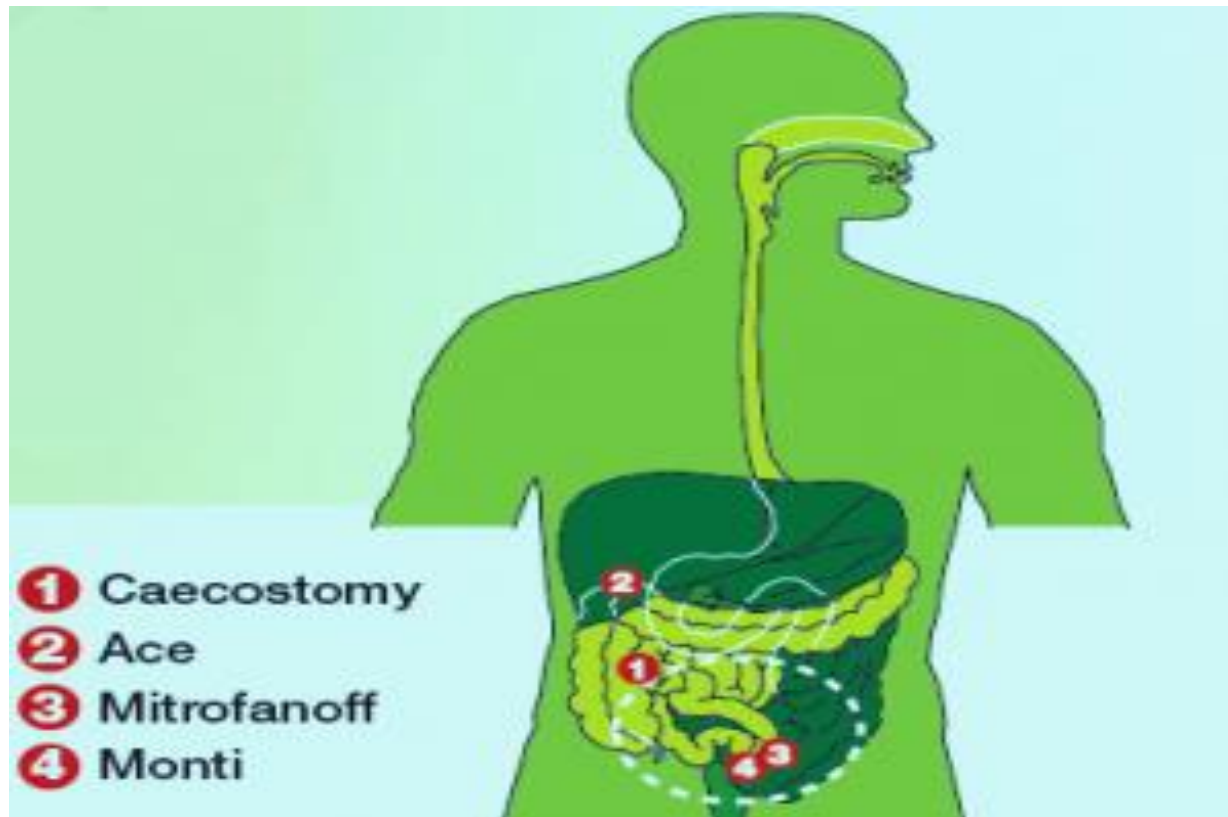

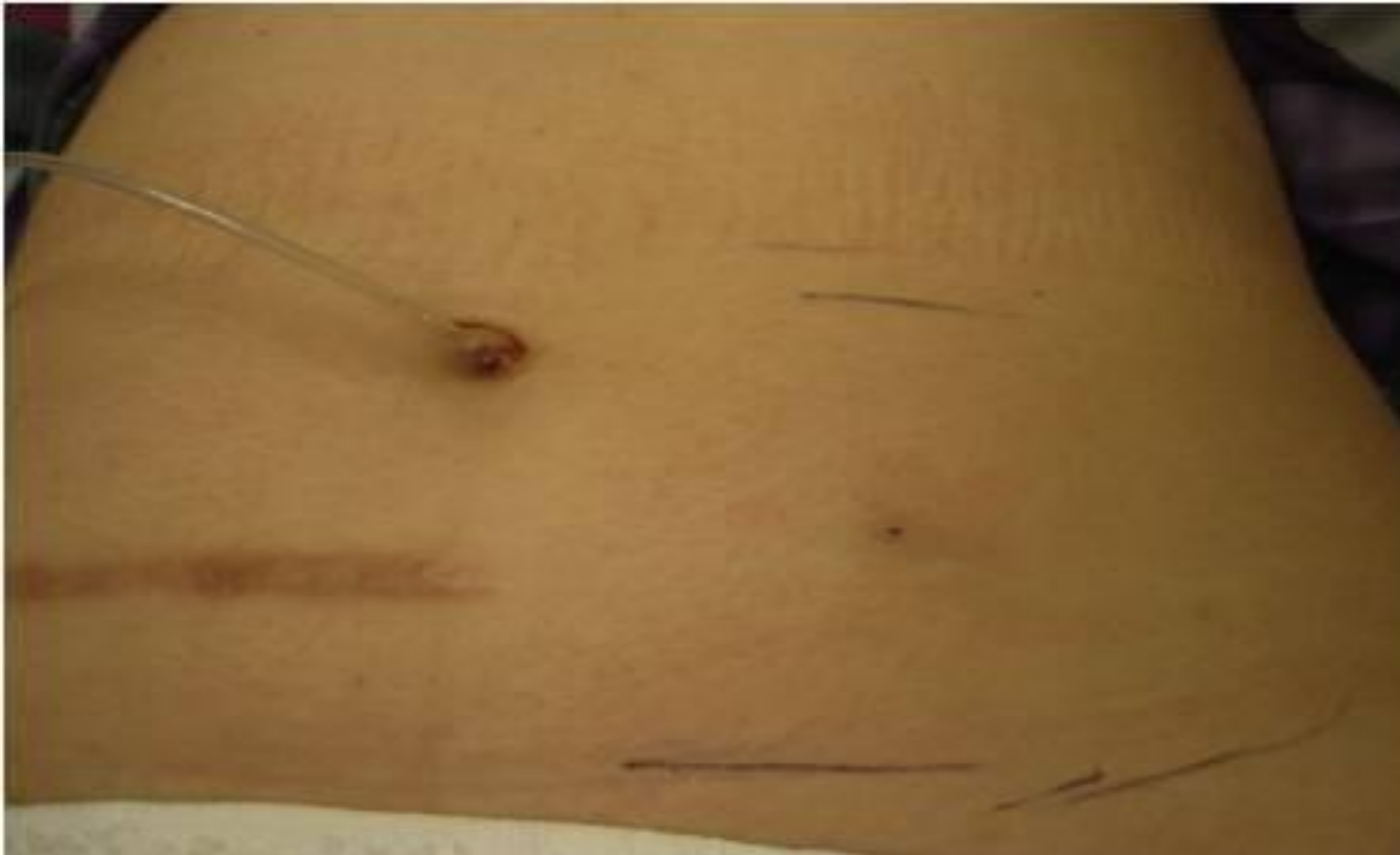


Figure 2

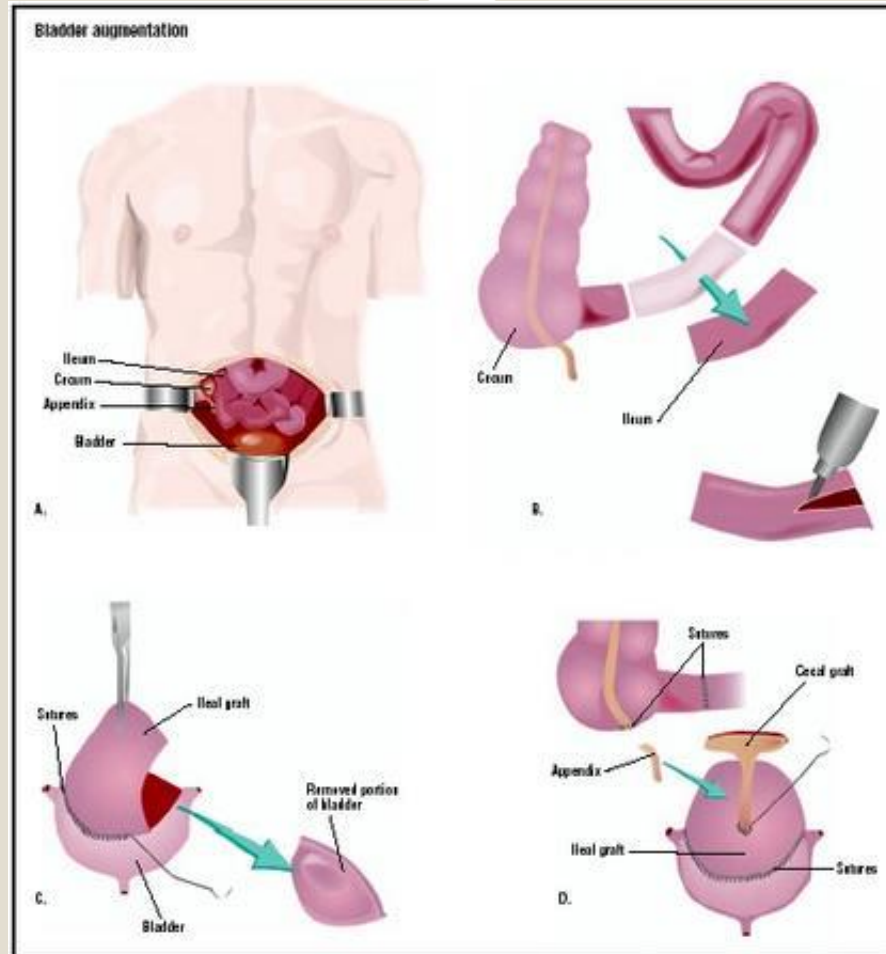
Status post sigmoid colostomy, demonstrating antegrade colon irrigation.

Bladder Augmentation



- The bladder is enlarged with a piece of colon, ileum, or ureter. Most often colon is used
- Bladder is enlarged so urine is stored at low pressures. Risk of upper tract involvement is reduced
- If colon or ileum is used, the bladder will secrete mucous forever since these organs secrete mucous and will need to be irrigated every day
- If ureter is used, mucous will not be secreted
- Bladder cannot contract on its own, intermittent catheterization will need to be performed forever

Bladder Augmentation



Management of Mitrofanoff/Monti

Management of Mitrofanoff/Monti



- Catheterization occurs every 3-4 hours during the day
- Catheter style and size are chosen by urologist or nurse
- Catheterization is a clean technique
- Some patients with poor kidney function use continuous overnight urinary drainage through a catheter

Continuous Urinary Drainage at Night through Mitrofanoff



- Catheter is placed at bedtime and drained into a second diaper or urinary drainage bag.
- Catheter is removed in the AM and CIC is performed throughout the day.
- If a foley catheter is used, do not inflate balloon. If a catheter accidentally is pulled or falls out with a balloon inflated, the balloon can disrupt the Mitrofanoff channel.

Continuous Urinary Drainage at Night through Mitrofanoff/Monti



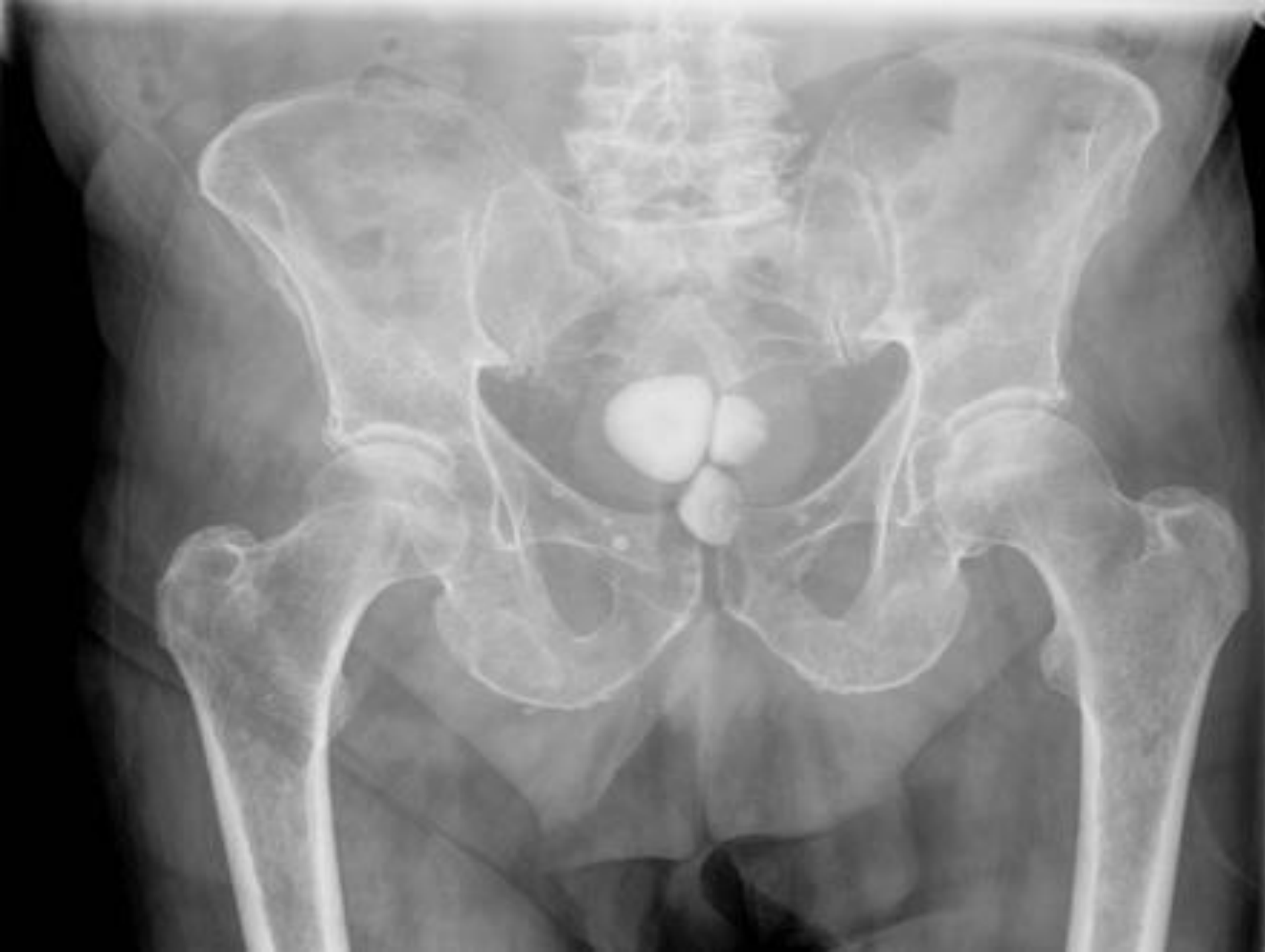- In some states, Medical Assistance will only pay for 4 foley catheters a month.
- Instead of a Foley catheter, use a 16 inch long straight self catheter with funnel end at night
- Some self catheter brands have funnel ends that do not easily connect to a drainage bag.
- CURE brand catheters connect easily to a leg or overnight drainage bag
- A piece of tegaderm works well to adhere the catheter to the skin so catheter is secure.

Bladder Augmentation Management

Potential Problems, Bladder Augmentations



- An Augmented bladder needs daily irrigation with normal saline to clear the mucous that the colon segment creates
 - Poor irrigation habits increases bladder stones and urinary tract infections
 - Bladder stones are surgically removed by opening the bladder
 - Bladder Perforations
 - ✦ If patient's bladder is over distended, a bladder perforation can occur which is a medical emergency



VP Shunt
Tubing



Spina Bifida

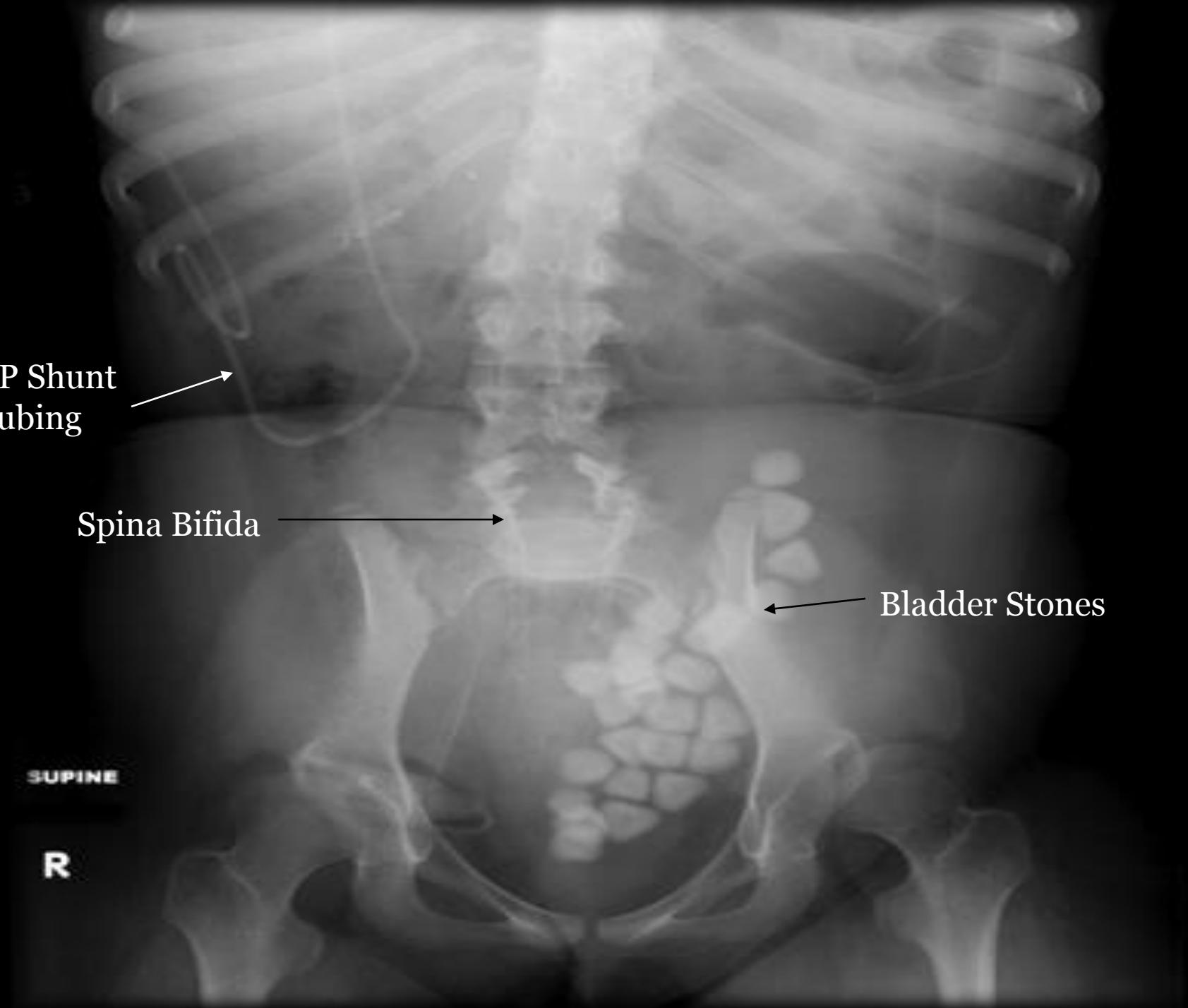


Bladder Stones

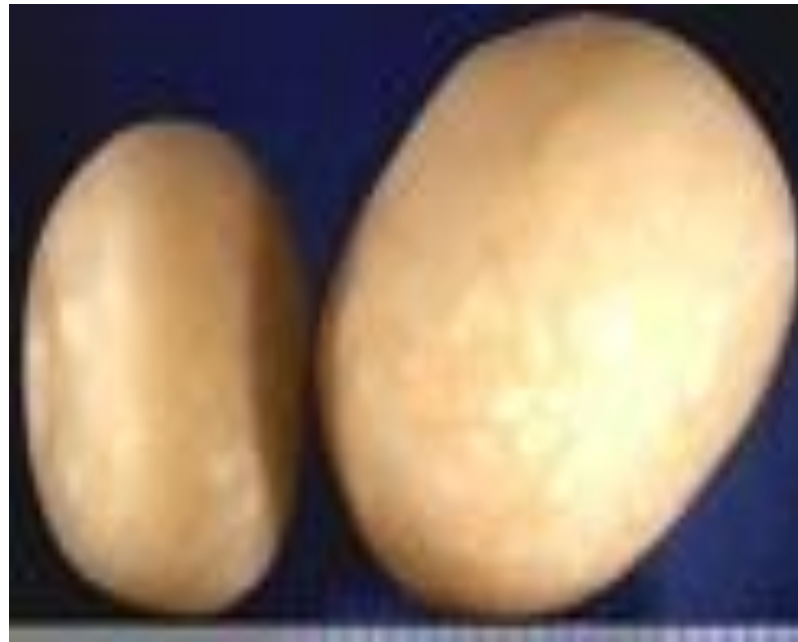

SUPINE

R



Bladder Stones



Bladder Irrigation, Normal Saline



- Purchasing bottled normal saline is expensive
- Normal Saline can be made:
 - 1 gallon distilled water purchased at grocery store
 - 8 measuring teaspoons of table salt
 - Shake until salt is dissolved
 - Store at room temperature

Bladder Irrigation



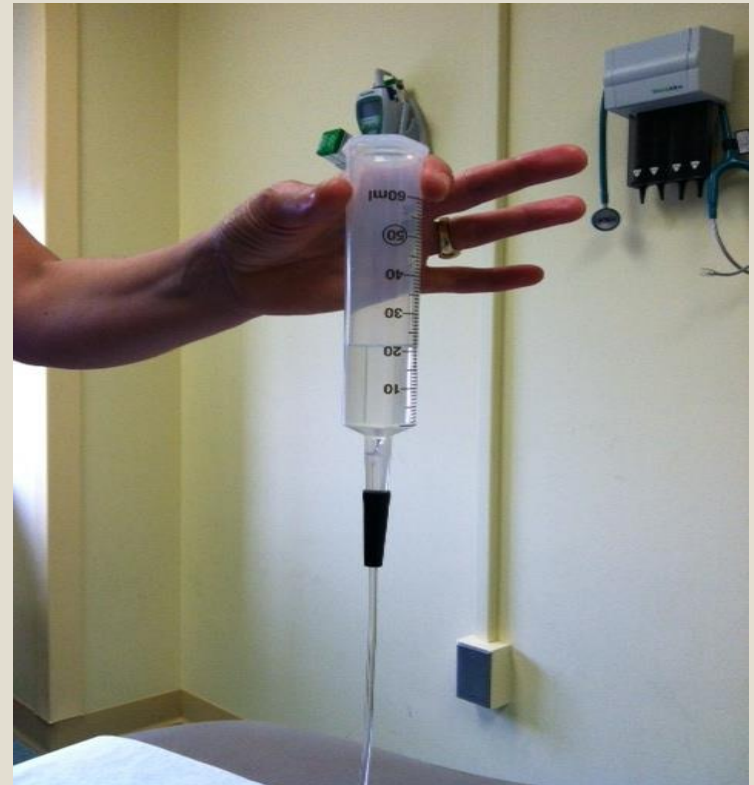
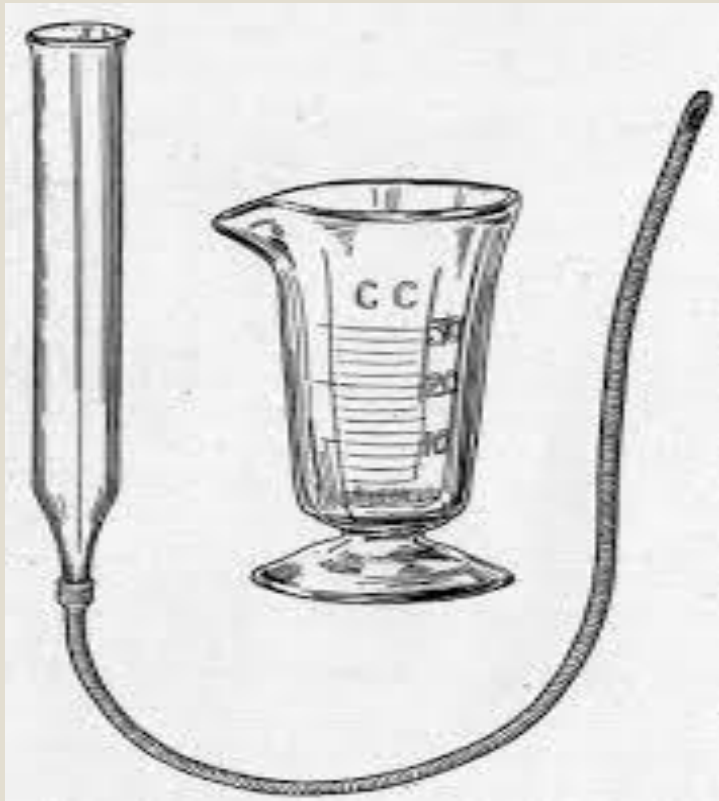
- Initially after bladder augmentation surgery, family is taught to irrigate catheters with a small amount of normal saline, usually 30 ml.
- Once all catheters are removed and patient starts CIC, family needs to be taught to increase volume of normal saline to irrigate the bladder effectively to remove the mucous

Bladder Irrigation



- Irrigate bladder by gravity method
- Use a 60 ml catheter tipped syringe
- Catheterize patient, draining urine
- When bladder is empty, place barrel of syringe on end of catheter
- Pour normal saline into barrel of syringe until bladder is full

Irrigation Supplies



Bladder Irrigation



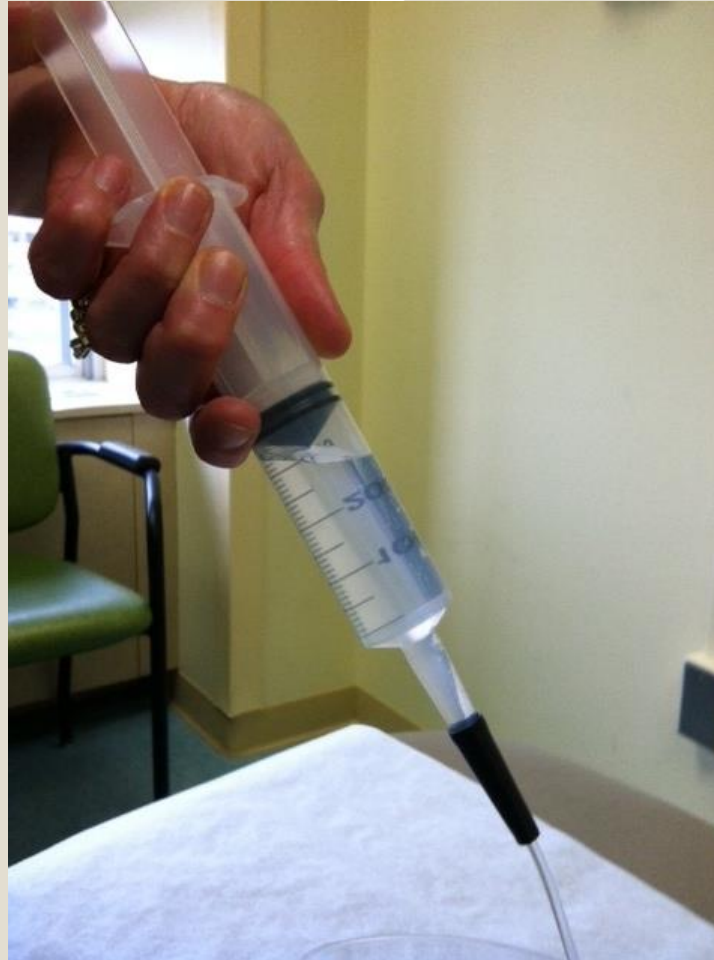- Teach families to irrigate with enough normal saline to fill bladder
- If patient usually holds 350 ml of urine, bladder should be irrigated with a similar amount of normal saline
- Bladder usually has been augmented with a piece of colon which has rugae or multiple folds. It is important to distend the bladder with enough normal saline to clean all of the folds.

Bladder Irrigation Drainage



- Once normal saline is in bladder, remove syringe barrel and replace plunger
- Aspirate the remaining normal saline out of bladder
- Aspiration will allow more mucous to be removed
- If there is a large amount of mucous, repeat irrigation process until clear.
- Bladder irrigation should be done at least daily
- Dairy consumption increases mucous production

Aspirate Irrigation out of Bladder



Bowel Surgeries

Bowel Surgeries: (M)ACE



- **(M)ACE**
(Malone) Antegrade Continence Enema (MACE) procedure creates a stoma with a channel through the abdominal wall into the colon to perform bowel washouts.
- Channel uses ileum or appendix
- Same principle as the Mitrofanoff, but tunnel is implanted into the wall of the ascending colon to facilitate emptying the colon.
- Channel is catheterized and normal saline enemas are given daily

Farrugia and Malone, 2010

Bowel Surgery: Cecostomy with Chait tube



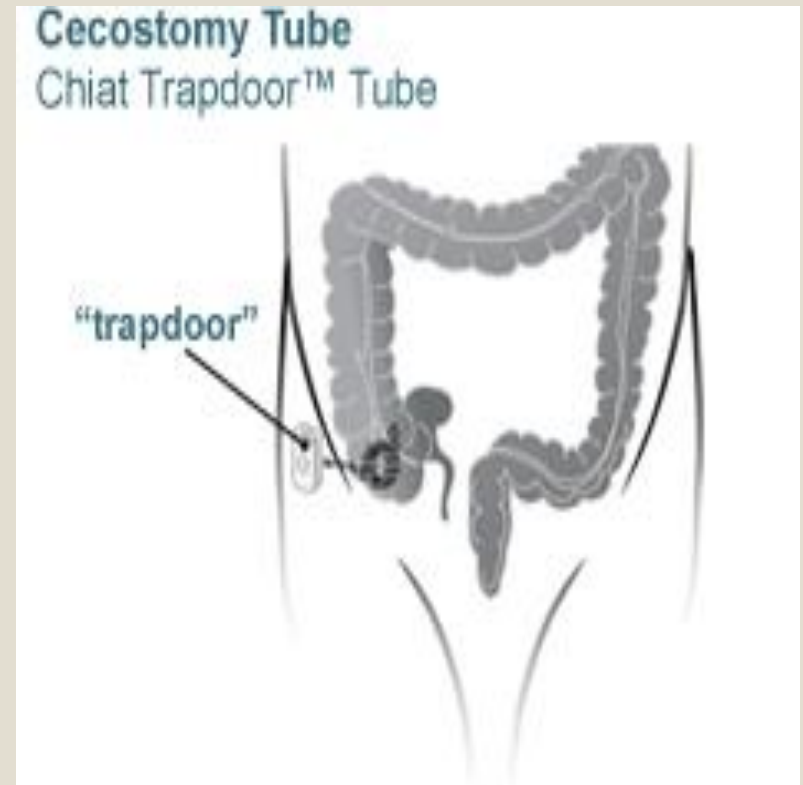
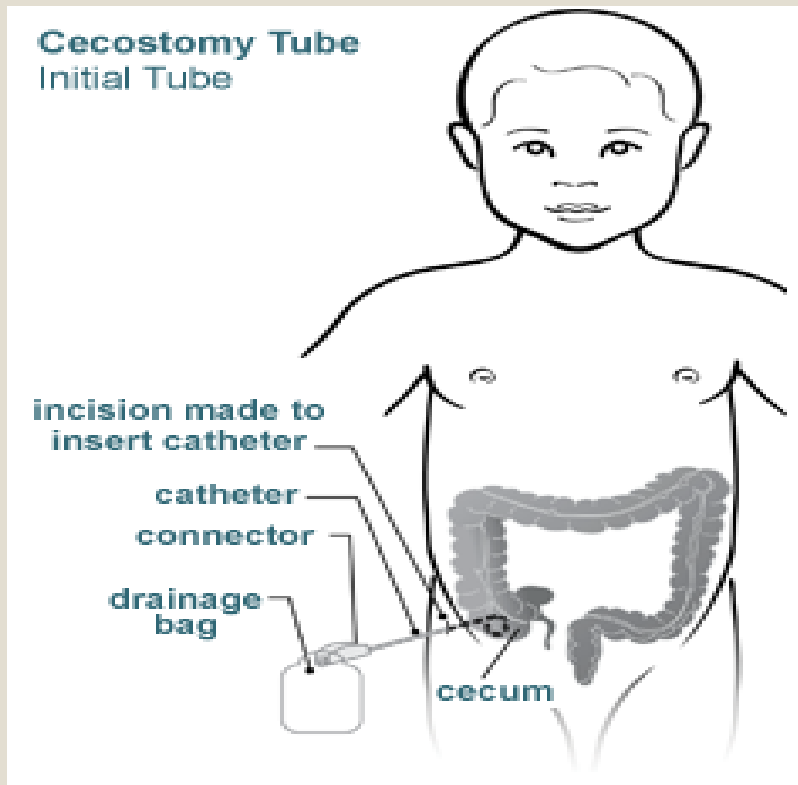
- **Cecostomy**

- This procedure is used to create a tract directly into the cecum to connect it to the abdominal wall to perform bowel washouts.
- Initial tube is left to drainage for approximately 2 months

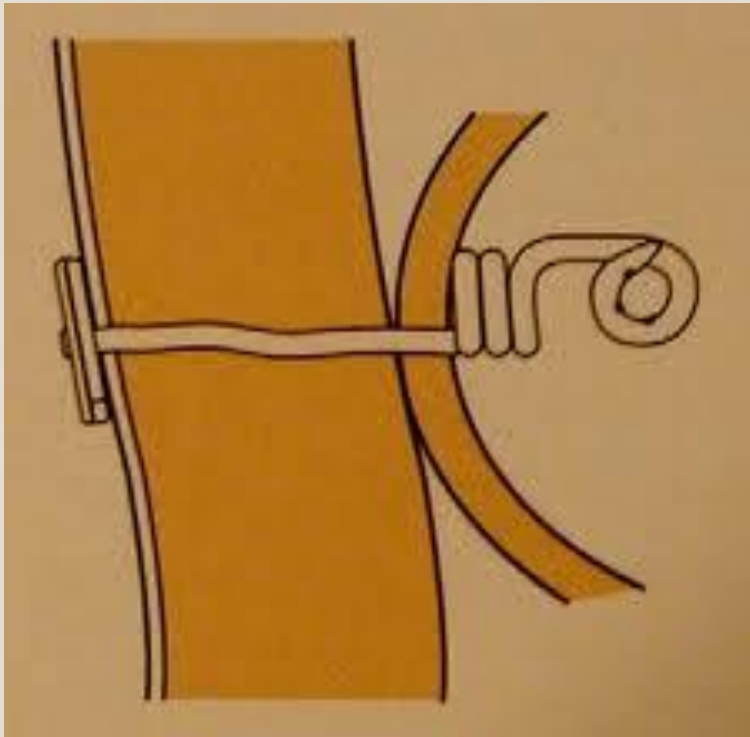- **Chait Tube**

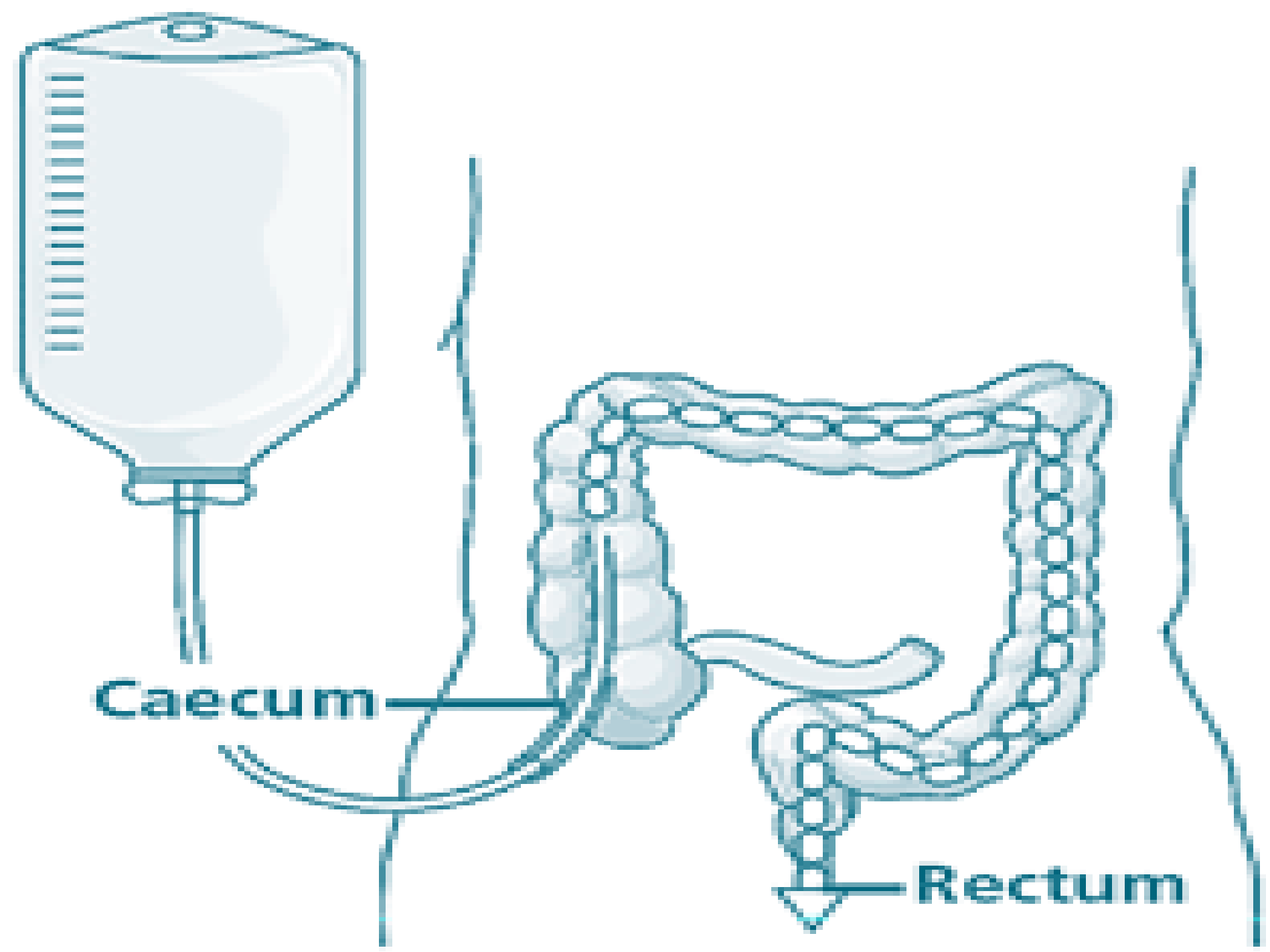
- Flat faced tube that replaces the initial tube
- Sits flush against the skin
- Allows the normal saline flush to flow through.
- Chait tube stays in the cecostomy and is replaced 1-2 times per year.

Cecostomy with Chait tube



Chait Trapdoor™





Pros and Cons of MACE and Cecostomy



Pros and Cons of MACE

- **Pros**
 - Continent
 - Can put chait tube in place
- **Cons**
 - Stomal Stenosis
 - False passages can develop
 - Longer surgery
 - Longer hospital stay

Pros and Cons of Cecostomy

- **Pros**
 - Shorter surgery
- **Cons**
 - Fecal leakage
 - Parent dissatisfaction
 - Foreign object (chait tube) needs be in place
 - Replacement of chait tube yearly

Bowel Evacuation Management

Bowel Management (M)ACE



- Catheter is passed into the MACE stoma and a normal saline enema is given through the catheter. Stool is passed through the rectum about 30-60 minutes later
- Facilitates independence, can perform enema without an aide
- Stoma is continent of stool
- Allows child to wear underwear

Bowel Management: Chait Trapdoor

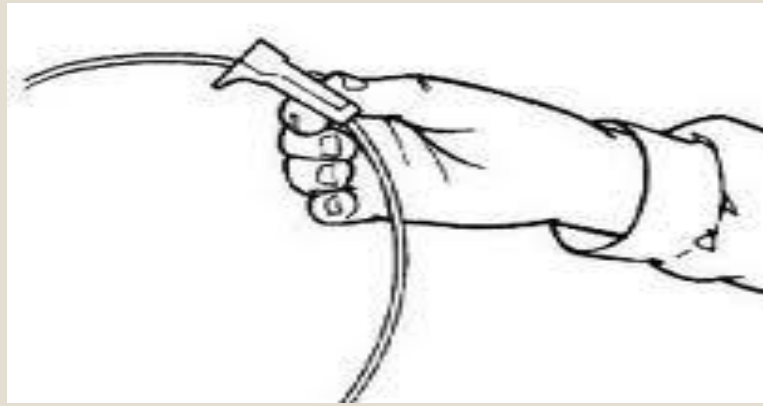


- Same as MACE
- Chait trap door is opened.
- Adapter/catheter is attached
- Normal Saline is infused

Bowel Evacuation Management



- Perform bowel irrigations at the same time each day with normal saline
- Clean procedure
- Use a Kangaroo bag or enteral feeding bag to pour the normal saline in
- Attach feeding bag tube into end of catheter or Chait
- Open roller clamp so normal saline will flow



Bowel Evacuation Management to Improve Output



- Most bowel irrigations are done daily, some patients can perform them every 48 hours
- Perform irrigations usually after a warm meal
- Use enough normal saline to evacuate bowels
- Can take 45 minutes- 2 hours

Bowel Evacuation Management to Improve Output



- To improve output:
 - Warm normal saline in microwave
 - Take Miralax daily or other stool softener
 - High fiber diet with good water intake (water bottle at school)
 - Use of glycerin (5-30ml of glycerin) mixed with equal parts of normal saline. Place in MACE/Chait and let sit for 15 minutes
 - ✦ Flush with Normal Saline
 - Use pediatric fleets enema in MACE/Chait catheter
 - ✦ Flush with Normal Saline
 - Use of Go-Lytely in MACE/Chait

Potential Problems with Mitrofanoffs and MACEs

Potential Problems with Mitrofanoff and ACE



- **Stomal Stenosis**

- 30% of patients with continent stomas experience stomal stenosis over time
- It becomes more and more difficult to get the catheter in
- Catheter sizes may need to decrease which increases the time to drain the bladder or irrigate the bowel

Preventing Stomal Stenosis



- To help prevent stomal stenosis, start catheterization with the largest French size catheter the MACE or Mitrofanoff will accept.
- MACE irrigation occurs once a day.
- For several months after Mitrofanoff and MACE surgery, have parents place a catheter into MACE stoma when they catheterize the Mitrofanoff. This will help keep the MACE open until it is completely healed.

Tips on how to deal with Stomal Stenosis



- When parents cannot get a catheter into the stoma:
 - Have parents try catheterizing in lying or sitting position
 - Have child soak in bathtub in warm water for 10 minutes
 - Try passing catheter while in tub
 - Try a coudé tipped catheter
 - Try next French size down straight catheter
 - If they get a smaller size catheter in, have them leave it in for 5 minutes then have them remove it and try placing the next size up.

Tips on how to deal with Stomal Stenosis




- Once they get the catheter past the stomal stenosis and into channel, have them leave it in place for a week, capped off.
- Removed cap intermittently to empty bladder

Tips on how to deal with Stomal Stenosis



- ACE Stopper
- Can be used for MACE or Mitrofanoff
- Can be purchased through Marian Medical
- The ACE stopper has a flat top to it that sits flush against the skin
- Can also use a catheter with a knot tied at the end, knot does not lie flush against the skin.



ACE Stoppers



- **ACE Stopper** - Medicina's ACE stoppers are made of implantable grade silicone that are used to plug/seal stoma sites at various parts of the body.
- Come in a variety of lengths and widths depending on the size of the stoma. They all have a circular 15mm skin disc and can perform two functions:
 - ACE stoppers form a seal in between insertions of the catheter if the stoma is leaking
 - ACE stoppers maintain the patency of the stoma if the catheter insertion is difficult or the site closes in between catheter insertions
- <http://marianmedicalonline.com/products/ace-stoma-device/>

ACE Stoppers



- ACE Stoppers sold by
 - Marian Medical in Louisville
 - 3600 Chamberlain Lane, Suite 122
Louisville, KY 40241
 - Phone 502-425-6363
 - Fax 502-425-6543

<http://marianmedicalonline.com/products/ace-stoma-device/>

ACE Stopper Sizes



- 8FR Ace Stopper, Length 15mm
- 8FR Ace Stopper, Length 30mm
- 8FR Ace Stopper, Length 60mm
- 10FR Ace Stopper, Length 15mm
- 10FR Ace Stopper, Length 30mm
- 10FR Ace Stopper, Length 60mm
- 12FR Ace Stopper, Length 30mm
- 12FR Ace Stopper, Length 60mm
- 12FR Ace Stopper, Length 100mm
- 14FR Ace Stopper, Length 30mm

<http://marianmedicalonline.com/products/ace-stoma-device/>

False Passages in Mitrofanoff or ACE



- A false passage occurs when a catheter hits the sidewall of the Mitrofanoff or ACE and over time causes a divet or dimpling in the wall.
- Bleeding can occur
- Usually occurs because:
 - catheters are being passed too forcefully
 - Inadequate or no lubricant is being used
- When passing the catheter, the catheter can then get caught in the false passage.
- Multiple attempts to catheterize the bladder can make the false passages worse.

Tips For Channels with False Passages



- Use a coudé tipped catheter
- Try a prelubricated catheter
- If catheter is not prelubricated apply liberal amounts of water soluble lubricant
- Use a larger catheter
- When catheterizing a male with false passages, guide the catheter from the outside of the penis while inserting it.

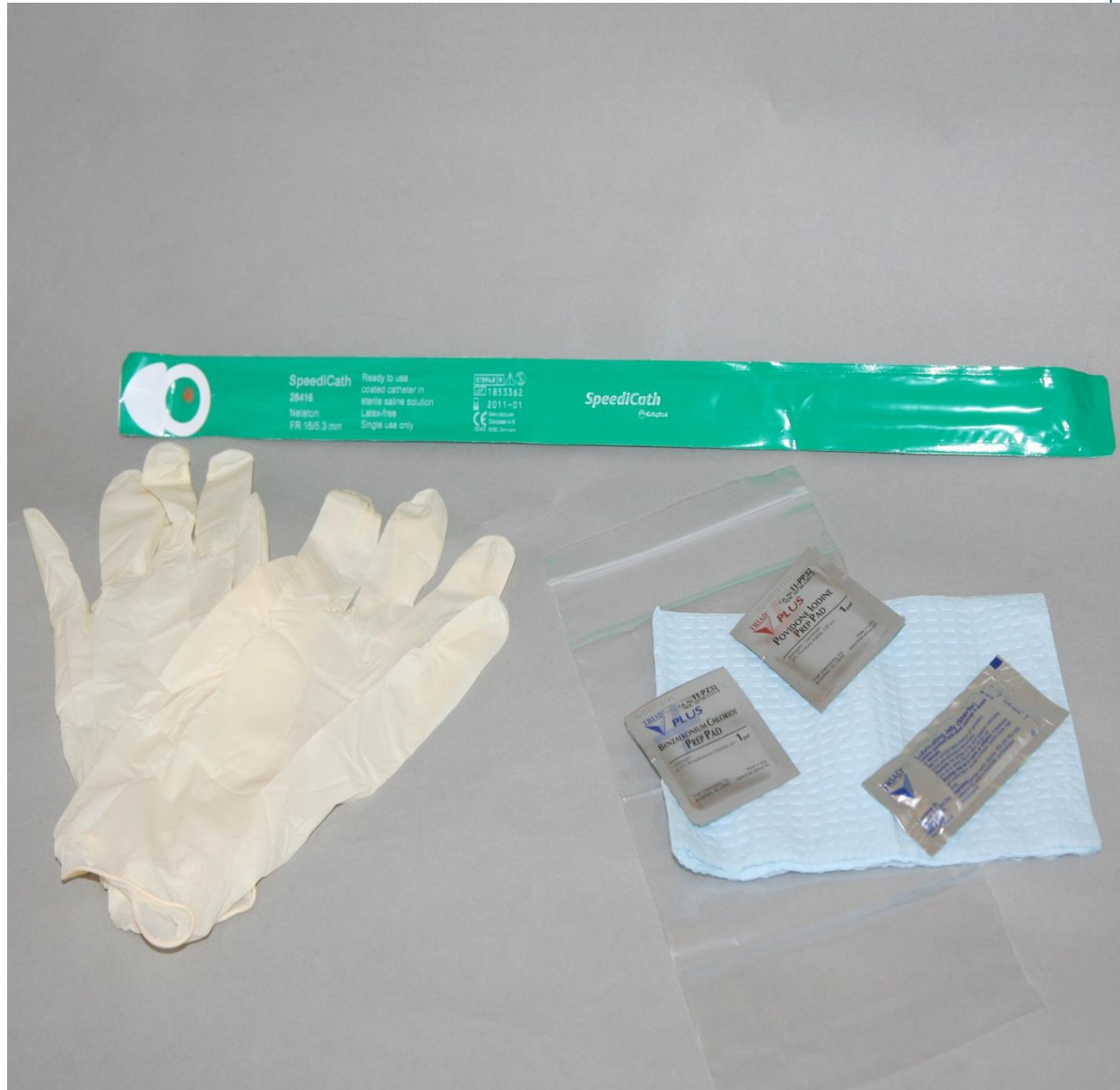Coudé tipped





Prelubricated Catheters

Hydrophilic coating allows ease of insertion past the false passage.



Coloplast SpeediCath

Tips For Channels with False Passages



- If patient uses a soft catheter (Coloplast 100 series) try a stiffer catheter
- If they use a stiffer catheter, try a softer one.
- Fill catheter tipped syringe with normal saline. Place 16 inch catheter with funnel end in tip of stoma. Gently fill channel with normal saline (this will be messy). Pass the catheter into channel while continuously irrigating the inside of the channel. The water fills the false passages and allows the catheter to pass.

Tips For Channels with False Passages



- Once you get the catheter in place, leave it there for a couple weeks.
- If you cannot get the catheter in, patient may need to be taken to OR for scoping and catheter placement.
- Sometimes the false passages are so bad that the channel looks like Swiss Cheese
- Complete surgical redo of Mitrofanoff or ACE is then required.

Age of Independence

AGE of Independence



- Technical skill of catheterizing can be learned by age 7
- Total responsibility for cathing, irrigating ACE and bladder should not be given to child until late teen or early twenties
- Adolescents want to be normal like their peers.
 - Their self care is often ignored, abbreviated or not done on a regular schedule
 - This causes UTI's, bladder stones, false passages, bowel impaction, bladder perforation and even death

Important for Parents



- Parent's understanding of "supervising" their child's care well into late teens
- If wheel chair bound, observe skin on regular basis looking for pressure sores
- Make sure cathing and irrigating is being done correctly and at prescribed intervals
- Make sure supplies are always on hand
- By being actively involved in child's care, risk of problems are reduced

References



- Barqawi, A., Furness, P., Erregon, A., Koyle, M. New Innovations in Continent Catheterizable Stomas. www.medscape.com/viewarticle/447774_print. Retrieved 3/19/13
- Coloplast SpeediCath. <http://www.180medical.com/catheters.aspx?id=432>
- Farrugia, M., Malone, P., Educational article: The Mitrofanoff Procedure. Journal of Pediatric Urology. 2010 Aug;6(4):330-7.
- Marian Medical Inc., <http://marianmedicalonline.com/products/ace-stoma-device/>
- Subramaniam, S. Taylor, C. The use of an Ace Stopper in Catheterisable Channels Virtually Eliminates the incidence of Meatal Stenosis. Journal of Pediatric Urology, [Volume 4, Supplement 1](#) , Page S39, April 2008

