



Thomas Jefferson University
Jefferson Digital Commons

Modern Surgery, 4th edition, by John Chalmers Da
Costa

Rare Medical Books

1903

Modern Surgery - Chapter 31. Diseases of the Skin and Nails

John Chalmers Da Costa
Jefferson Medical College

Let us know how access to this document benefits you

Follow this and additional works at: http://jdc.jefferson.edu/dacosta_modernsurgery

 Part of the [History of Science, Technology, and Medicine Commons](#)

Recommended Citation

Da Costa, John Chalmers, "Modern Surgery - Chapter 31. Diseases of the Skin and Nails" (1903).
Modern Surgery, 4th edition, by John Chalmers Da Costa. Paper 14.
http://jdc.jefferson.edu/dacosta_modernsurgery/14

This Article is brought to you for free and open access by the Jefferson Digital Commons. The Jefferson Digital Commons is a service of Thomas Jefferson University's [Center for Teaching and Learning \(CTL\)](#). The Commons is a showcase for Jefferson books and journals, peer-reviewed scholarly publications, unique historical collections from the University archives, and teaching tools. The Jefferson Digital Commons allows researchers and interested readers anywhere in the world to learn about and keep up to date with Jefferson scholarship. This article has been accepted for inclusion in *Modern Surgery, 4th edition, by John Chalmers Da Costa* by an authorized administrator of the Jefferson Digital Commons. For more information, please contact: JeffersonDigitalCommons@jefferson.edu.

XXXI. DISEASES OF THE SKIN AND NAILS.

Dermatitis venenata results from irritants and from garments containing arsenic, but is generally due to rhus-poisoning. Rhus-poisoning arises from the poison-oak, the poison-ash, the poison-ivy, and other species of sumach. Actual touching of the plants is not always necessary.

The **symptoms** are burning and itching, redness and edema of the face and hands. A vesicular eruption begins between the fingers, and the eruption and the inflammation spread widely over the body. There may be slight fever.

The **treatment**, when a moderate area is involved, comprises the application of cloths wet with black wash or lead-water and laudanum. If an extensive area is involved, apply *grindelia robusta* (5iv to Oj of water) or moisten the surface frequently with sweet spirits of niter. Oxid of zinc ointment containing 10 gr. of carbolic acid to ʒj gives great relief. A 1:8 solution of *phénol sodique* allays pain and itching.

Furuncle, or boil, is an acute and circumscribed inflammation of the deep layer of the true skin and the subcutaneous cellular tissue following on bacterial infection of a hair-follicle or a sebaceous gland. A boil is caused by infection of a hair-follicle through a slight wound (by scratching, shaving, etc.) with the *staphylococcus pyogenes aureus*. Boils are very common in individuals with Bright's disease, diabetes, gout, tuberculosis, and disorders of menstruation and digestion; and crops of boils are apt to appear during convalescence from typhoid fever. Boils are commonest in the spring, and sometimes an epidemic of furunculosis appears in a hospital, a jail, or an asylum.

The **symptoms** of a boil are as follows: a red elevation appears, which stings and itches; this elevation enlarges and becomes dusky in color; a pustule forms, that ruptures and gives exit to a very little discharge which forms a crust. Inflammatory infiltration of adjacent connective tissue advances rapidly, and the boil in about three days consists of a large, red, tender, and painful base capped by a pustule and a little crusted discharge. In rare instances, at this stage, absorption occurs, but in most cases the swelling increases, the discoloration becomes darker, the skin becomes edematous, the pain becomes fierce and pulsatile, and the center of the boil becomes raised. About the seventh day rupture occurs, pus flows out, and a "core" of necrosed tissue is found in the center of a ragged opening. This core consists of the sebaceous gland and hair-follicle, which have undergone coagulation necrosis (Warren). In a day or two more the core will be discharged, and healing by granulation will begin. A *blind boil* lasts only three or four days and has no core. The constitution often shows reaction during the progress of a boil. Boils may be either single or multiple. The development of one boil after another, or the formation of several boils at once, is known as "furunculosis." Boils are commonest upon the neck and the back.

The **treatment** consists of crucial incision, removal of necrotic tissue, irrigation with peroxid of hydrogen and corrosive sublimate, and the application of hot antiseptic fomentations.

Aleppo boils (endemic boils of the tropics) are papules appearing upon the exposed parts of the body. These papules, which ulcerate and do not

cicatrizate for at least a year, are due to a pathogenic bacterium and leave ineradicable scars.

Carbuncle (benign anthrax) is a circumscribed infectious inflammation of the deeper layer of the true skin and of the subcutaneous tissue, with fibrinous exudation, multiple foci of necrosis arising, and the tissue adjacent to each necrotic plug becoming gangrenous. The infection takes place through a hair-follicle. It is really a boil with extensive infiltration of adjacent tissues. A boil may become a carbuncle, and pus from a carbuncle inoculated into a healthy person may cause either a boil or a carbuncle. The causative organism seems to be the staphylococcus pyogenes aureus. Carbuncle is most common in the upper part of the back and on the back of the neck. In this region the skin is very thick; the hair-follicles hold only downy hair, are shallow, and project but a short distance into the cutis vera. Columns of fatty tissue run from the subcutaneous tissue in an oblique direction to join the point and sides of the hair-follicle. These columns are known as columnæ adiposæ and each one contains a sweat-gland (Fig. 502). When pus runs down one of these columns it seeks an outlet; it cannot spread easily to the sides, so it slowly works its way to the deeper tissue and from one to another interspace and finds its way to the surface through other fatty columns (Warren's "Surgical Pathology") (Fig. 503). When pus finds its way to the surface, an opening forms, hence the numerous foci of pointing; finally a large opening forms (Fig. 504). Carbuncles are most common in the spring of the year. In persons with diabetes and Bright's disease carbuncles not unusually occur.



Fig. 502.—Columna adiposa (Warren).

The local **symptoms** in the beginning resemble those of a boil, but the constitution sympathizes from the very start (a chill and a septic fever) and the pain is usually severe. The inflammatory area begins as a papule with an indurated base, it enlarges enormously, is boggy to the touch, is dusky in color, is edematous, and the skin is not freely movable over the deeper parts. In a few days many pustules appear, each pustule marking the site of a focus of necrosis. Large vesicles filled with bloody serum very frequently form. In some cases, about the tenth day, the pustules rupture, the necrotic plugs are discharged, and the case slowly progresses toward cure; but in many cases the carbuncle spreads at the periphery while pustules are rupturing near the center of inflammation, and pus forms in the deeper tissues, reaching the surface through many small openings, each of which is partly blocked by a plug of dead tissue. A carbuncle in this stage resembles a honeycomb (Fig. 504), discharges bloody pus, and large masses of skin and subcutaneous tissue are destroyed. The entire carbuncular mass may become gangrenous,

and a sudden and almost complete cessation of pain points to this complication. An ordinary carbuncle remains acute for about three weeks, but healing requires a month more. The most dangerous situations in which to have a carbuncle are the face and neck (tends to produce septic phlebitis, septic clots in the facial, jugular, or ophthalmic veins, or in the cerebral sinuses, or infective emboli). The mortality of facial carbuncle is at least 50 per cent. The most usual positions for carbuncle are the neck, the back, and

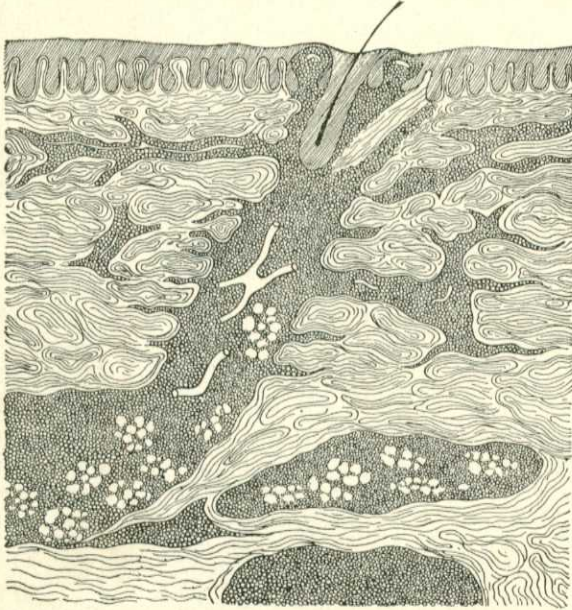


Fig. 503.—Infiltration of columna adiposa and subcutaneous tissue with pus in carbuncle (Warren).

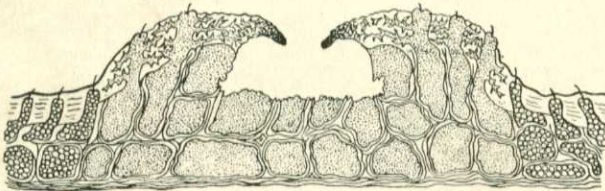


Fig. 504.—Diagram of a carbuncle (Warren).

the buttocks. The diagnosis of carbuncle is made by noting the multiple foci of necrosis and the profound constitutional involvement. A carbuncle may produce death by causing septicemia, pyemia, or profuse hemorrhage.

Treatment.—Some have suggested the treatment of a carbuncle in an early stage by injecting from five to thirty drops of carbolic acid (80 per cent.) into and around the inflammatory mass. The best treatment is thorough extirpation while the patient is anesthetized. The entire area of the infection is thus removed, and the large wound heals by granulation and is subsequently skin-grafted. A useful plan, frequently employed, is as follows:

Give ether, make free crucial incisions, remove dead and necrosing tissue with the scissors and forceps, curet pockets, arrest hemorrhage by pressure and hot water, cauterize with *pure* carbolic acid, dust with iodoform, pack with iodoform gauze, and dress with hot antiseptic fomentations. Cover the gauze with a piece of some impermeable material and lay a hot-water bag upon the dressing. Every day, or several times a day, remove the dressings, wash with peroxid of hydrogen, irrigate with corrosive sublimate solution, dust with iodoform, and reapply the iodoform gauze and antiseptic fomentation. Keep up this treatment until sloughs are separated, then dress with dry antiseptic gauze. Secure sleep by morphin, give quinin, milk-punch, and nourishing diet, and maintain the action of the bowels and kidneys.

Erysipelas.—(See page 166.)

Clavus, or Corn.—A corn is a tender, painful, and circumscribed thickening of the epidermis, and is commonest over one of the joints of the toes. *Hard* corns are situated on exposed parts of the digits; *soft* corns appear between the digits, where the parts are kept constantly moist. Corns are caused by pressure.

Treatment.—The wearing of well-fitting boots will usually cause a corn upon the toe to disappear. Soak the feet often in water containing bicarbonate of sodium, dry them, and apply a circular corn-plaster to the corn to take off the pressure of the boot. Another method is to touch the corn with iodine every night and pare away the hard tissue every morning. An old and valuable plan is to paint the corn every night with a mixture composed of salicylic acid, ℥iiss; extract of cannabis indica, gr. x; and collodion, ℥j, and to scrape this mixture away every morning. *Soft* corns are treated by washing the feet often with ethereal soap, drying, gently removing the sodden epithelium, dusting the toes with borated talc, and placing absorbent cotton between the digits. Incurable soft corns require the removal of the skin from the adjacent sides of the two toes and suturing them together (thus converting two toes into one). In inflamed corns employ rest and lead-water and laudanum, and let out pus when it forms. Remember that in old persons the cutting of a corn may cause senile gangrene. In the inflamed and painful feet of a person who has corns nothing gives so much relief as washing the feet with ethereal soap, soaking in hot water, and wrapping the feet for half an hour in cloths wet with a mixture composed of linseed oil and lime-water, each, ℥ij, and spirits of camphor, ℥j.

Warts.—(See page 267.)

Onychia is inflammation of the matrix of the nail. A "run-around" is suppuraton of the matrix at the root of the nail, of traumatic origin. It requires incision, trimming away of the buried edge of the nail, and packing with iodoform gauze.

Malignant onychia, which is inflammation and ulceration of the entire matrix, occurs only in a person of dilapidated constitution. This condition requires removal of the entire nail, cauterization of the matrix, dressing with iodoform gauze, and the internal use of stimulants, tonics, and nourishing diet.

Ingrowing toe-nail is due either to lateral hypertrophy of the edge of the nail or to forcing of the soft tissues over the margin of the nail. The condition is treated by splitting the nail, removing the ingrown piece, the soft tissue at the margin, and the adjacent matrix, and dressing antiseptically.