

Needle EMG Response of Lumbar Multifidus to Manipulation in the Presence of Clinical Instability

JOHN TUNNELL, PT, OCS, COMT, FAAOMPT

Numerous definitions of clinical instability exist; as defined by Bogduk, instability occurs when at any time during movement, there is a change in the ratio of translation to rotation at a segment¹. Panjabi described instability as the inability of the spine to maintain its pattern of displacement under physiologic loads². Actual determination of the presence of clinical instability remains controversial^{3,4}. Subjective reports from patients with clinical instability may include reports of long-term intermittent pain, increased pain with transitional movements, feelings of giving way or locking, pain with sustained positions, and a condition that is progressively worsening⁵⁻⁹. Signs of clinical instability include mild to moderate loss of trunk motion, Gower's sign, lateral shift, absence of neurological signs, and hypermobility with segmental stress testing^{6,7,9-11}.

It has been proposed that this clinical problem may prove difficult to rehabilitate because of a decrease in the recruitment and cross-sectional area of the multifidus¹² and an alteration in normal segmental articular mechanoreceptor input^{10,13-18}. Several studies have suggested that activity of the trunk muscles is altered in the presence of lower back pain^{15,17,19-22}.

Recruitment of the multifidus has been reported as an essential component during rehabilitation of patients with lower back pain²⁰⁻²². However, it has also been proposed that restoration of normal articular motion precedes attempts at strengthening^{7,23}, that segmental control is necessary for spinal stability^{7,8,21,22,24-26}, and that multifidus activity is not directly related to direction of forces placed on the spinal column^{20,21,27-29}. Other reports have suggested that reflexive muscular activity of the multifidus is diminished

with laxity in the viscoelastic structures of the feline spine¹⁹, with prolonged positioning or loading^{19,30}, and that multifidus recovery is not automatic following an episode of low back pain³¹.

Recent reports have suggested that multifidus function may be affected with spinal manipulation¹³ and that mechanical forces may alter EMG activity of the multifidus¹⁶. Additional studies have documented changes in strength³²⁻³⁴, muscular activity³⁵⁻³⁷, neuromuscular reflex³⁸, and pain sensitivity³⁹ following manipulation. It has not been reported that treatment focused at restoring normal articular motion or stimulating local mechanoreceptors will affect multifidus function when measured using needle EMG.

This case report attempts to identify the immediate changes in multifidus activity measured with needle EMG following manipulation of the lumbar spine that is targeted at a level identified as having decreased muscle bulk of the multifidus, abnormal findings in the biomechanical examination, and a decrease in trunk rotational control and strength. Findings may provide clinicians/researchers with ideas for further investigation into treatment of clinical instability.

Patient Characteristics

The patient was a 49-year-old male working as a golf course supervisor who attended therapy with an acute onset of low

ABSTRACT: A proposed mechanism for the persistence of low back pain due to clinical instability is a decrease in control of local spinal musculature, more specifically decreased recruitment of multifidus. Altered segmental mechanoreceptor input has been proposed as a contributing factor responsible for a decrease in local muscle recruitment. In this case report, immediate changes in the recruitment of the deep multifidus following manipulation were examined using needle EMG and isometric testing of trunk rotational force. Trunk rotational force appeared to improve while the multifidus demonstrated a decrease in activity as measured by needle EMG. No specific conclusions can be drawn from this report; however, the results do suggest that immediate multifidus function may be influenced with manipulation, resulting in improved muscular control of the trunk.

KEYWORDS: Instability, Manipulation, Multifidus, Needle EMG

Clinical Director, Excel Therapy Specialists, Broken Arrow, OK

Address all correspondence and requests for reprints to: John Tunnell, jtunnell@exceltherapyok.com

back pain 3 days prior. The patient reported having a 20-year history of intermittent low back pain of a similar nature, in which the pain usually lasted for 1–2 weeks and then resolved spontaneously. This pain was usually brought on with trivial activities or motions. He recalled no specific injury to his low back.

During these episodes, and as reported at the time of examination, he experienced a loss of trunk motion and moderate to severe pain in the left lower lumbar region. He reported having morning pain and stiffness, which usually resolved after a couple of hours of being up and about. He did not tolerate standing or sitting for periods greater than 2–3 hours without pain beginning. He denied any changes in bladder function, referred or radiating symptoms, sensory changes, or loss of strength or control of the lower extremities. He denied any relevant medical history. He rated his pain as a 6 on a 0–10 numeric rating scale and described it as *moderately severe* at the time of examination.

Examination

Observation

The patient stood with a flexed and left deviated trunk position. No other obvious deformities or malpositioning were noted.

Lumbar Scan

A lumbar scan was performed as proposed in the curriculum taught by the North American Institute of Orthopaedic Manual Therapy (NAIOMT)^{7,9,10}, consisting of range of motion of the lumbar spine and lower extremities with overpressure and resistance, and provocative testing (compression, torsion, traction, and postero-anterior shear testing) of the lumbar spine and of the sacroiliac region. The neurological component of the examination consisted of testing sensation to light touch, long tract involvement (clonus and Babinski's), tendon reflexes for L3-S1, slump and straight leg raise testing, and strength testing of root levels L2-S1.

Visual range of motion examination revealed a loss of right side-bending

and extension. Gower's sign (walking the hands back up the thighs) was present with return from flexion. No deficits were noted with the neurological examination. Left torsion and postero-anterior shear testing revealed a painful hypermobility at the L4 segment. Palpation along the lumbar multifidus revealed an apparent area of hypotonicity at the right L4 region.

Biomechanical Examination

Following the scanning examination, a biomechanical examination consisting of passive intervertebral motion testing and segmental stress testing was performed. Passive accessory intervertebral motion testing revealed a loss of extension and right side-bending at L4-5 with a pathomechanical end feel^{9,10,40}. Specific stress testing at L4-5 revealed increased laxity to anterior and left rotation stressors^{7,9}. No abnormal findings were noted above L4 or at L5-S1 with intervertebral motion and stress testing. Following Meadows' proposal of assessment of clinical instability¹⁰, trunk rotation motor control was then assessed in sitting, with the patient asked to resist an isometric force into both right and left trunk rotation in neutral. A decrease in initial trunk resistance to a manually applied isometric force was found with right rotation in neutral. Testing in the flexion or extension quadrants was not performed because the deficit was discovered in the neutral position.

A handheld force transducer (Tech Medical Onsite Commander Portable Force Gauge, JTech Medical, Salt Lake City, UT) was used at this point to quan-

tify trunk rotation strength (Figure 1). The patient was asked to resist an isometric force into right and left rotation, which was repeated three times in each direction. These data were gathered to serve as a comparison to post-EMG/manipulation trunk rotation forces (Table 1).

Clinical Impression

The history given by the patient, combined with the findings of the examination, appeared to indicate the presence of clinical instability. There were no subjective reports, medical history, or examination findings to indicate systemic involvement, neurological involvement, or impending neurological compromise. The pain was well localized and did not refer. Hip motion was full bilaterally in all directions and quadrants. Palpation revealed an obvious hypotonicity of the multifidus to the right of L4.

Articular assessment revealed hypermobility at L4-5 with anterior and left rotation stress testing, with a hypomobility in right side-bending and extension. The end-feel of this hypomobility was pathomechanical. Trunk rotational control and strength were also diminished in right rotation.

If the assumption can be made that clinical instability is caused by a breakdown of the structure of the disc or surrounding structures, it appears possible that there is increased translation present at a particular segment during movement, allowing it to become *the proverbial locked back*. The decision to manipulate in this case study was based on the history, clinical presentation, and

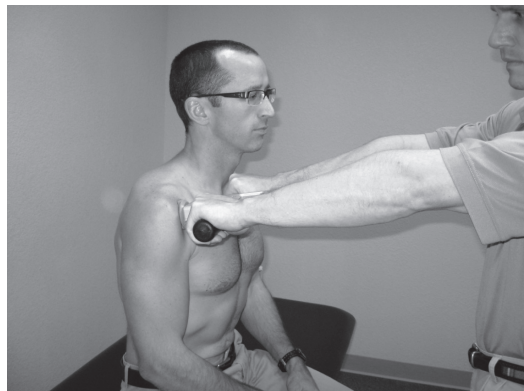


FIGURE 1.
Testing of trunk rotation strength with handheld dynamometer.

TABLE 1. Pre-manipulation and post-manipulation neutral position trunk rotation force measured by handheld force transducer.

	Pre-manipulation maximum (pounds)	Pre-manipulation average (pounds)	Post-manipulation maximum (pounds)	Post-manipulation average (pounds)
<u>Right rotation</u>				
Trial 1	8	4	28	16
Trial 2	16	8	28	22
Trial 3	16	10	26	20
<u>Left rotation</u>				
Trial 1	18	12	26	16
Trial 2	16	8	22	16
Trial 3	20	14	26	20

end-feel in an attempt to return the segment to a neutral position.

Intervention

A signed release was obtained from the patient after the EMG procedure was explained by the physician, and the proposed treatment was explained by the therapist. A free-run EMG of 10 milliseconds/division with a filter setting of 20Hz–10,000Hz, and sensitivity set at 500 μ v/division (Nicolet Viking Quest, Nicolet Biomedical, Madison, WI), to test for recruitment of the deep lumbar multifidus was then performed by the physician. While the reliability and validity of EMG to determine muscle activity remains controversial^{41,42}, the use of needle EMG for attempted assessment of multifidus function has been reported superior to surface EMG⁴³. Prior to the EMG, an explanation of the procedure was given again by the physician to the patient, and the patient again gave verbal consent to participate.

The patient was placed in a prone position; the previously noted area of apparent hypotonicity at L4 was then identified by the therapist and marked by the physician. The EMG needle was inserted by the physician at the marked area to the right side of the L4 spinous process to the deep layer of the multifidus at a 45° angle until the base of the L4 transverse process was encountered, then retreating until the needle tip was no longer in bony contact. The ground electrode was then attached adjacent to

the right side of the spinous processes of L1-2 over the paraspinal muscles without marking.

After a period of less than 1 minute following needle insertion, a baseline EMG reading was obtained by the physician to determine resting tone of the multifidus, which was verbally reported as *zero* by the physician. The patient then performed a modified Biering-Sorensen test and held the position for approximately 10 seconds while a reading of multifidus EMG activity was obtained by the physician. The Biering-Sorensen test has been previously reported as one method of assessing erector spinae and multifidus strength⁷.

After the pre-intervention reading was obtained, the ground electrode was removed along with the wire to the EMG needle. The needle was left in place in an attempt to keep the needle in the same location so that EMG data could be collected again from the same motor neuron pool. Removal of the ground electrode and needle wire was to ensure the patient was not connected to the EMG machine during manipulation to avoid inadvertent electrical shock.

The patient was then placed in left side-lying, an explanation of the proposed manipulation was given to the patient, and his verbal consent was obtained before proceeding. A neutral position high-velocity/low-amplitude manipulation in left side-lying was chosen based on the history²³ and clinical presentation⁴⁴⁻⁴⁶.

As an increased laxity to left rota-

tion and anterior stressors were found during the segmental stress tests, the patient was placed in a left side-lying position. This position theoretically provides a right rotational stress that allows a specific lumbar segment to be targeted for manipulation; thereby avoiding additional stress in the direction of perceived hypermobility.

A high-velocity/low-amplitude manipulation was chosen because of the pathomechanical^{23,40} end-feel that was encountered during the biomechanical examination. With the patient in left side-lying, the neutral position of L4-5 was found by using the therapist's left arm to position the patient's legs to move the lumbar spine, with the right hand palpating for the neutral position. The therapist's palpating hand changed from the right to the left, so that a neutral extension lock from above, down to but not into L4, could be performed with the right hand, by drawing the patient's left arm vertically.

The therapist's palpation hand then changed to the right, and the patient's right hip was flexed until the right knee was ahead of the left thigh, which allowed the patient's pelvis to begin to rotate to the left, up and into the L4-5 segment. Once the manipulation position was obtained, an overpressure was applied and held for 10 seconds. No pain, discomfort, or other symptoms were reported by the patient during the overpressure. A neutral position, high-velocity/low-amplitude manipulation targeting the L4-5 segment was per-

formed (Figure 2). A single audible click was noted, which was also felt under the therapist's superior thumb at L4. The process from patient set-up to manipulation took approximately 30 seconds.

Immediately following the manipulation, the patient returned to the prone position. The needle wire was re-attached, and the ground electrode was re-attached over the right L1-2 paraspinals by the physician. After a period of less than 1 minute, multifidus EMG resting tone was again measured and verbally reported as *zero* by the physician. As before, the patient was then asked to perform the modified Biering-Sorensen test holding for a period of 10 seconds, while the EMG reading of multifidus recruitment was obtained by the physician. The needle and ground electrode were removed after the final reading was obtained.

Outcome

Immediately following the removal of the needle and ground electrode, the biomechanical examination was conducted again, and it revealed normal passive accessory intervertebral motion at the L4-5 segment^{9,40}. Visual assessment of trunk range of motion was full, without deviation, and reported as painless by the patient. The patient reported

an immediate improvement in his symptoms and movement ability, rating his pain as 0 on a 0–10 numeric pain rating scale. Trunk control was assessed as described previously; the response to a manually applied isometric force by the therapist appeared to improve, and the handheld force transducer was used again. Trunk rotational strength appeared to improve, in particular right rotation (Table 1). As shown in Table 2, the results of the EMG demonstrated less activity of the multifidus post-manipulation compared to pre-manipulation readings.

The patient reported a long history of similar occurrences as described in this report. Short-term prognosis would appear fair, with unguarded movements or trauma being the most likely to result in another episode. While long-term outcome following treatment designed to enhance multifidus recruitment in combination with addressing articular dysfunction or arthrogenic influence is unknown, long-term prognosis of this particular patient remains guarded.

Discussion

The results of trunk rotation strength appear to support the initial hypothesis that manipulation can affect trunk muscular control in addition to improve-

ments in the subjective, objective, and biomechanical examinations. Although numerous variables exist that could compromise the readings, from use of a handheld force transducer for assessment of trunk strength, it did appear that the amount of rotation force generated by the patient improved. Handheld dynamometers have been shown to be a reliable method of assessing strength⁴⁷⁻⁴⁹, although the use as described in this case report has not been widely reported.

While the extent of the response to initial manual loading of the trunk into either left or right rotation could not be accurately assessed due to the limitations of the equipment available, it was noted by both the patient and therapist that a more immediate and controlled response to loading was present with initiation of resistance into right rotation. Use of more sophisticated and sensitive equipment might demonstrate more accurate measurement of trunk forces generated at the initial onset of rotational loading.

The EMG data, however, did not support the hypothesis that multifidus EMG activity would increase following manipulation. Theoretically, it is a possibility that manipulation of the segment either allowed for improvement in the efficiency of multifidus recruitment resulting in a lower output noted with EMG testing, or quite simply that reduction in pain resulted in less local muscle activation. It has previously been reported that weakened subjects produce higher EMG readings to generate a given absolute force⁵⁰, and that removal of neurogenic inhibition may affect strength after mobilization⁵¹.

Several factors could have affected the post-manipulation EMG results such as less volitional effort by the patient, inadvertent repositioning of the EMG needle during the set-up for the manipulation, lack of specific marking and control of the ground electrode position, or repositioning of the needle during the manipulation. The initial introduction of the EMG needle may have also caused an increase in activity of the multifidus, which would not reflect true multifidus activity pre-manipulation compared to post-manipulation read-

FIGURE 2. Neutral position gapping manipulation technique as described by Pettman⁴⁴.

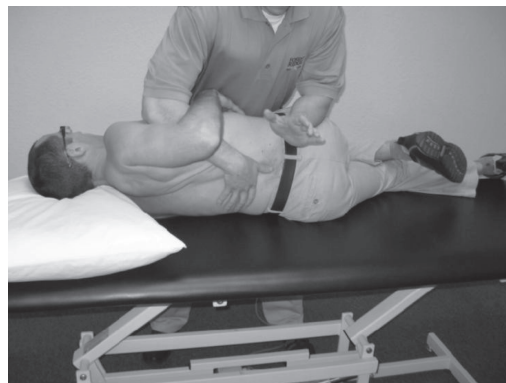

TABLE 2. Needle EMG readings pre-manipulation and post-manipulation.

	Pre-manipulation EMG reading	Post-manipulation EMG reading
Recruitment frequency	8Hz	8Hz
Motor unit action potentials	3–4	2
Amplitude	1500–3500 microvolts	500–1000 microvolts

ings. Further study is needed to elucidate this possibility.

It is also unknown if manipulative techniques that do not attempt to direct and control forces to a particular level, such as one described by Flynn et al⁵², would provide the same or different results, or if this particular patient would have tolerated such forces^{23,44}. Further study examining manipulative techniques and outcomes in this particular patient population would appear necessary. It is also unknown what differences might be noted with comparison of rehabilitative ultrasound imaging to needle EMG testing in this specific patient population¹³. Additionally, examination of responses of the superficial multifidus to manipulation would be warranted. No definitive conclusions can be drawn from this case report; however, the results here suggest that immediate multifidus function may be influenced with manipulation, resulting in improved muscular control of the trunk.

Conclusion

This case report attempted to identify immediate changes in multifidus motor activity measured by needle EMG and trunk rotational strength measured with a handheld force gauge following manipulation of the lumbar spine. This was based on the clinical observation of improved trunk control and strength following either mobilization or manipulation of a segment perceived to have hypotonicity of the adjacent multifidus and abnormal accessory motion. While trunk strength appeared to improve, EMG measurement revealed less multifidus recruitment post-intervention compared to pre-intervention readings. Further study examining the effect of mobilization or oscillation of a segment may provide additional information on possible arthrogonic influence on the multifidus.

Acknowledgements

This case report was originally completed as part of the fellowship requirements for the North American Institute of Orthopaedic Manual Therapy (NAIOMT). The author would also like

to thank Timothy Pettingell, MD for performing the EMG study and providing the EMG data for this case report.

REFERENCES

1. Bogduk N. *Clinical Anatomy of the Lumbar Spine and Sacrum*. 3rd ed. Sydney, Australia: Churchill Livingstone, 1997.
2. Panjabi M, White A. *Clinical Biomechanics of the Spine*. 2nd ed. Philadelphia: JB Lippincott, 1990.
3. Hicks GE, Fritz JM, Delitto A, Mishock J. Interrater reliability of clinical examination measures for identification of lumbar segmental instability. *Arch Phys Med Rehabil* 2003;84:1858-1864.
4. Abbott JH, McCane B, Herbison P, Moginie G, Chapple C, Hogarty T. Lumbar segmental instability: A criterion-related validity study of manual therapy assessment. *BMC Musculoskelet Disord* 2005;6:56.
5. Biely S, Smith S, Silfies S. Clinical instability of the lumbar spine: Diagnosis and intervention. *Ortho Phys Ther Prac* 2006; 3:11-18.
6. Cook C, Brismee J, Sizer P. Subjective and objective descriptors of clinical lumbar spine instability: A Delphi study. *Man Ther* 2006;11:11-21.
7. Dutton M. *Orthopaedic Examination, Evaluation, & Intervention*. St. Louis, MO: McGraw-Hill, 2004.
8. O'Sullivan P. Lumbar segmental "instability": Clinical presentation and specific stabilizing exercise management. *Man Ther* 2000;5:2-12.
9. Pettman E. *NAIOMT Level 2 Intermediate Lower Quadrant*. Berrien Springs, MI: NAIOMT, 2003.
10. Meadows J. *NAIOMT Level 3 Advanced Lower Quadrant*. Dallas, TX: NAIOMT, 2007.
11. Paris S. Physical signs of instability. *Spine* 1985;10:277-279.
12. Richardson C, Hodges P, Hides J. *Therapeutic Exercise for Lumbopelvic Stabilization*. 2nd ed. Sydney, Australia: Churchill Livingstone, 2004.
13. Brenner A, Gill N, Buscema C, Kiesel K. Improved activation of lumbar multifidus following spinal manipulation. *J Ortho Sports Phys Ther* 2007;37:613-619.
14. Cassisi J, Robinson M, O'Connor P, MacMillan M. Trunk strength and lumbar paraspinal muscle activity during isometric exercise in chronic low back pain. *Spine* 1993;18:245-251.
15. Danneels L, van der Straeten G, Cambier D, Witvrouw E, Cuyper H. CT imaging of trunk muscles in chronic low back patients and healthy control subjects. *Euro Spine J* 2000;9:266-272.
16. Holm S, Indahl A, Solomonow M. Sensorimotor control of the spine. *J Electro Kines* 2002;12:219-234.
17. Elfving B, Dederich A, Nemeth G. Lumbar muscle fatigue and recovery in patients with long-term low back trouble: Electromyography and health related factors. *Clin Biomech* 2003;18:619-630.
18. Hodges P, Mosely G. Pain and motor control of the lumbopelvic region: Effect and possible mechanisms. *J Electro Kines* 2003;13: 361-370.
19. Gedalia U, Solomonow M, Zhou B, Baratta R, Lu Y, Harris M. Biomechanics of increased exposure to lumbar injury caused by cyclic loading. Part 2. Recovery of reflexive muscular stability with rest. *Spine* 1999; 24:2461-2467.
20. Hodges P, Richardson C. Altered trunk muscle recruitment in people with low back pain with upper limb movement at different speeds. *Arch Phys Med Rehabil* 1999;80: 1005-1012.
21. Hodges P, Richardson C. Inefficient muscular stabilization of the lumbar spine associated with low back pain: A motor control evaluation of transversus abdominus. *Spine* 1996;21:2640-2650.
22. Vleeming A, Mooney V, Dorman T, Snijders C, Stoeckart R. *Movement, Stability & Low Back Pain: The Essential Role of the Pelvis*. Sydney, Australia: Churchill Livingstone, 1999.
23. Meadows J. *Orthopedic Differential Diagnosis in Physical Therapy*. St. Louis, MO: McGraw-Hill, 1999.
24. Hides J, Jull G, Richardson C. Long-term effects of specific stabilizing exercises for first-episode low back pain. *Spine* 2001;26:243-248.
25. Jull G, Richardson C. Motor control problems in patients with spinal pain: A new direction for therapeutic exercise. *J Manipulative Physiol Ther* 2000;23:115-117.
26. Wohlfart D, Jull G, Richardson C. The relationship between dynamic and static function of abdominal muscles. *Aust Physiother* 1993;39:9-13.
27. Hodges P, Cresswell A, Daggfeldt K, Thorstensson A. Three-dimensional preparatory

- trunk motion precedes asymmetrical upper limb movement. *Gait Posture* 2000;11:92–101.
28. Mosely G, Hodges P, Gandevia S. Deep and superficial fibers of the lumbar multifidus are differentially active during voluntary arm movements. *Spine* 2002;27:29–36.
 29. Ng J, Richardson C. Reliability of electromyographic power spectral analysis of back muscle endurance in healthy subjects. *Arch Phys Med Rehabil* 1996;77:259–264.
 30. Jackson M, Solomonow M, Zhou B, Baratta R, Harris M. Multifidus EMG and tension-relaxation recovery after prolonged static lumbar flexion. *Spine* 2001;7:715–723.
 31. Hides J, Richardson C, Jull G. Multifidus muscle recovery is not automatic after resolution of acute, first-episode low back pain. *Spine* 1996;21:2763–2769.
 32. Cleland J, Stowell T, Selleck B. Short-term effects of thoracic manipulation on lower trapezius muscle strength. *J Man Manip Ther* 2004;12:82–90.
 33. Keller T, Colloca C. Mechanical force spinal manipulation increases trunk muscle strength assessed by electromyography: A comparative clinical trial. *J Manipulative Physiol Ther* 2000;23:585–595.
 34. Metcalfe S, Reese H, Sydenham R. Effect of high-velocity low-amplitude manipulation on cervical spine muscle strength. *J Man Manip Ther* 2006;14:152–158.
 35. Gill N, Teyhen D, Lee I. Improved contraction of the transversus abdominus immediately following lumbopelvic manipulation: A case study using real-time ultrasound imaging. *Man Ther* 2007;3:280–285.
 36. Herzog W, Scheele D, Conway P. Electromyographic responses of back and limb muscles associated with spinal manipulative therapy. *Spine* 1999;24:146–153.
 37. Suter E, McMorland G, Herzog W, Bray R. Decrease in quadriceps inhibition after sacroiliac joint manipulation in patients with anterior knee pain. *J Manipulative Physiol Ther* 1999;22:149–153.
 38. Colloca C, Keller T. Stiffness and neuromuscular reflex response of the human spine to postero-anterior manipulative thrusts in patients with low back pain. *J Manipulative Physiol Ther* 2001;24:489–500.
 39. George S, Bishop M, Bialosky J, Zeppieri G, Robinson M. Immediate effects of spinal manipulation on thermal pain sensitivity. *BMC Musculoskeletal Disorders* 2006;7:68.
 40. Kaltenborn F, Evjenth O. *Manual Mobilization of the Joints. Volume 2: The Spine*. 4th ed. Minneapolis, MN: OPTP, 2003.
 41. Kim BJ, Date ES, Derby R, et al. Electromyographic technique for lumbar multifidus examination: A comparison of previous techniques used to localize the multifidus. *Arch Phys Med Rehabil* 2005;86:1325–1329.
 42. Kendall R, Werner RA. Interrater reliability of the needle examination in lumbosacral radiculopathy. *Muscle Nerve* 2006;34:238–241.
 43. Stokes IA, Henry SM, Single RM. Surface EMG electrodes do not accurately record from lumbar multifidus muscles. *Clin Biomech* 2003;18:9–13.
 44. Pettman E. *Manipulative Thrust Techniques: An Evidence-Based Approach*. Abbotsford, Canada: Aphema, 2006.
 45. Pettman E. *NAIOMT Level 3 Advanced Lower Quadrant*. Berrien Springs, MI: NAIOMT, 2003.
 46. Bronfort G, Haas M, Evans RL, Bouter LM. Efficacy of spinal manipulation and mobilization for low back pain and neck pain: A systematic review and best evidence synthesis. *Spine* 2004;4:335–356.
 47. Roy MA, Doherty TJ. Reliability of hand-held dynamometry in assessment of knee extensor strength after hip fracture. *Am J Phys Med Rehabil* 2004;83:813–818.
 48. Wang CY, Olson SL, Protas EJ. Test-retest strength reliability: Hand-held dynamometry in community-dwelling elderly fallers. *Arch Phys Med Rehabil* 2002;83:811–815.
 49. Kilmer DD, McCrory MA, Wright NC, Rosko RA, Kim HR, Aitkens SG. Hand-held dynamometry reliability in persons with neuropathic weakness. *Arch Phys Med Rehabil* 1997;78:1364–1368.
 50. Gaudreault N, Arseneault A, Larivière C, Deserres S, Rivard C. Assessment of the paraspinal muscles of subjects presenting an idiopathic scoliosis: An EMG pilot study. *BMC Musculoskeletal Dis* 2005;6:14.
 51. Makofshy H, Panicker S, Abbruzzese J, et al. Immediate effect of grade IV inferior hip joint mobilization on hip abductor torque: A pilot study. *J Man Manip Ther* 2007;15:103–111.
 52. Flynn T, Fritz J, Whitman J, Wainner R, Mangel J, Rendeiro D. A clinical prediction rule for classifying patients with low back pain who demonstrate short-term improvement with spinal manipulation. *Spine* 2002;27:2835–2843.