

CHAPTER 80

Nerve Entrapment Syndromes

Robert J. Spinner

INTRODUCTION

The diagnosis of a nerve entrapment lesion arising at the elbow can be relatively straightforward if the history, physical examination, electromyographic (EMG), and imaging studies, when indicated, all confirm the diagnosis and the localization of the lesion.^{12,52,47,87,95,138} However, when the history and physical examination do not correspond or the electrophysiologic or imaging studies do not support a specific clinical diagnosis, then problems can arise. Therefore, one must apply the same systematic, thoughtful approach to the care of every patient. One can then put all of the data of the clinical puzzle together to offer appropriate treatment.

Sometimes, historical information can be misleading. For example, it is not uncommon for an elderly patient to say that his or her fingers are “stiff” when in reality the fingers are numb. Stiffness suggests an arthritic process, whereas numbness suggests involvement of the peripheral neurologic system in the pathologic process.

Other times, physical findings may be difficult to interpret. Persistent pain about the lateral aspect of the elbow that is resistant to all forms of conservative treatment as well as operative treatment directed to the lateral epicondyle may represent resistant lateral epicondylitis, entrapment of the posterior interosseous nerve alone, or both entities. In this instance, EMG studies, more commonly than not, do not help establish the diagnosis of resistant “tennis elbow” due to posterior interosseous nerve compression or localize the pathologic process. If both conditions are believed to be present on clinical grounds, then management of both lesions needs to be addressed simultaneously to relieve the patient’s symptoms.

Other issues may confound the clinical picture and the treating physician:

1. Simultaneous peripheral nerve compressions may occur, whether from related or unrelated causes.²⁵ For example, a diabetic patient may present with symptoms related to concurrent carpal tunnel syndrome and cubital tunnel syndrome. An active individual

may present with well-defined symptoms of ulnar nerve compression at the elbow; electrical studies, however, may have normal results in the ulnar nerve but reveal changes of carpal tunnel syndrome (which may be either subclinical or less symptomatic to the patient). Post-traumatic thickening of the brachial fascia in the distal arm can produce a simultaneous median and lateral antebrachial nerve compression. When more than one nerve is suspected in the neural compression process, a more proximal lesion such as the brachial plexus, must be ruled out as the site of the pathologic process.

2. A nerve can be compressed at more than one level; that is, a “double crush” lesion may exist. This most commonly occurs at the neck and the wrist but can also occur at other locations such as the thoracic outlet and the cubital tunnel.
3. Two separate neurologic processes may coexist. For example, a patient who is wheelchair-bound from a syringomyelia may develop hand atrophy, which represents new bilateral ulnar nerve compression rather than progression of the syringomyelia. Thus, on occasion, it is necessary to direct one’s conservative or surgical attention to two nerves, two sites on one nerve, or even two neurologic conditions to address the patient’s presenting symptoms and new neurologic findings.

Some patients are prone or predisposed to sequential neural compression lesions. There are predisposing factors for multiple neural entrapment lesions. A group of substances, such as sorbitol, can cause an increase in intrafascicular pressure, which can predispose a patient with diabetes mellitus to a neural compression lesion. Hereditary neuropathies also occur; despite genetic advances, the mechanism of dysfunction is not fully understood. Congenital anomalies of the elbow, such as from a lacertus fibrosus variant or a ligament of Struthers, may result in nerve compression lesions. Developmental changes from hypertrophied muscles may lead to compressive neuropathies, such as a pronator syndrome in an athlete. Trauma may induce a nerve compression syndrome either acutely or chronically, either from bony or associated soft tissue changes.

Recurrent neural compression lesions also occur. A physician may successfully care for an individual’s neural compression only for another nerve compression to arise a few months or years later that affects the same peripheral nerve or another nerve.^{132,159,198} Usually, technical factors at surgery can prevent recurrent lesions. Free gliding of the nerve with elbow flexion and extension and forearm rotation helps prevent late postoperative symptoms. If a nerve is fixed by adhesions or scarring or at a fracture site, it is not just a matter of entrapment. A traction neuritis can exist as well. As the joint moves, the nerve is tethered and can be stretched.

If the ulnar nerve is transposed anteriorly (especially if it has not been transposed in a straight line), ulnar neuritis can develop at a later date. Similarly, if the medial epicondyle is resected and the nerve becomes adherent to the medial epicondylectomy site, resistant ulnar nerve neuritis can develop after the primary surgery.

Certain principles apply to the surgical management of entrapment lesions. Wide exposure is often necessary to define the normal anatomy and the pathologic region. The nerve should be identified in a healthy region proximally and distally both grossly and microscopically; only then should the nerve be traced to the pathologic region. Surgery should be guided by the use of internervous planes, and gentle handling of the nerve is critical. During the wide decompression, care must be given to the cutaneous nerves. Patients who have entrapment lesions are prone to develop symptomatic postoperative skin neuromata; their initial symptoms related to the nerve compression lesion may disappear postoperatively to be replaced by a different type of neuromatous pain. In particular, at the elbow level, the medial cutaneous nerve of the forearm is susceptible

during ulnar nerve transposition and median nerve decompression, and the posterior cutaneous nerve of the forearm is at risk with posterior interosseous nerve neurolysis. In the majority of cases of nerve compression, external neurolysis is the usual operative intervention. Internal neurolysis, when indicated, should be limited to the neural segment and the internal region clinically involved. The perineurium should rarely, if ever, be violated. Nerves should be placed in healthy beds away from scar tissue. Intraoperative nerve action potentials may help in the management of more advanced lesions. Postoperative care should emphasize early mobilization. Early motion can improve neural gliding. The development of a stiff joint can undo an otherwise successful nerve decompression.

A detailed understanding of the complex normal anatomy of this region and the "common" variants is essential for proper diagnosis and treatment of these conditions (Fig. 80-1). Careful history, serial examinations and EMG studies, and at times, imaging modalities can usually localize the lesion or lesions. Early, accurate diagnosis and treatment are important for effective overall management of nerve compression lesions.

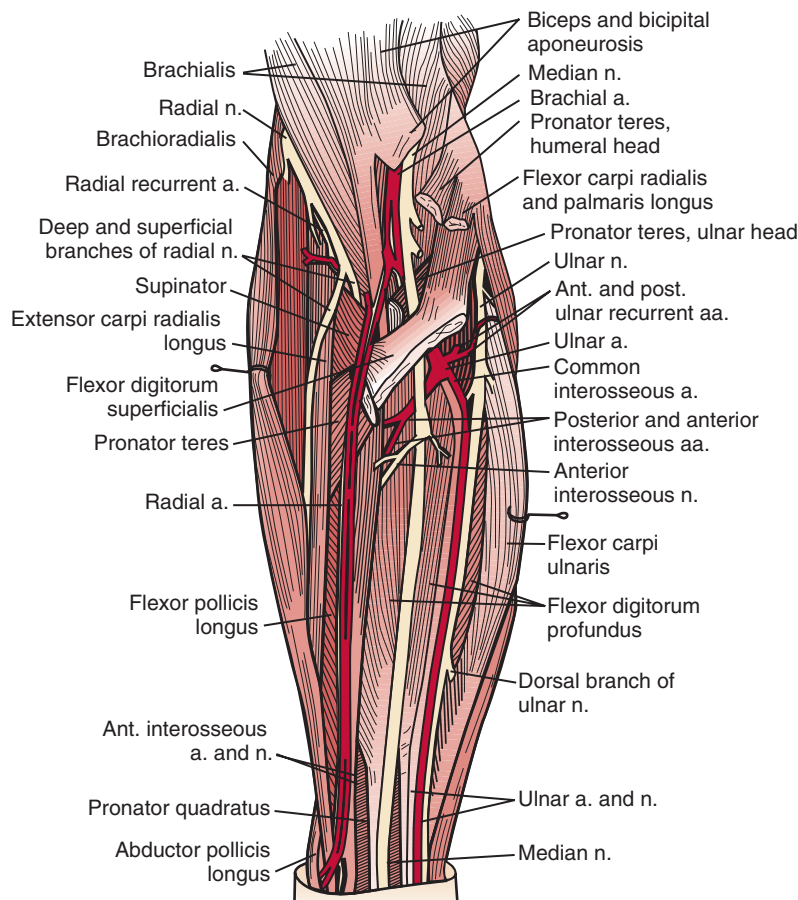


FIGURE 80-1 Major neurovascular and muscular relationships of the elbow region. (Redrawn from Hollinshead, W. H.: *Anatomy for Surgeons*, 3rd ed. Vol. 3. New York, Harper & Row, 1982.)

Understanding the degree of nerve injury can help a physician predict recovery patterns and guide management.

NEUROPHYSIOLOGY OF NERVE COMPRESSION LESIONS

Nerve compression may be categorized as first-, second-, third-, or fourth-degree neural lesions. This method was first described by Sir Sydney Sunderland.¹⁸⁴ The earlier classification of Sir Herbert Seddon (1943)¹⁵⁷ uses the terms *neurapraxia*, *axonotmesis*, and *neurotmesis* and can be correlated with Sunderland's classification in the following manner. A first-degree lesion is a neurapraxic lesion. A second-degree or mild third-degree lesion is an axonotmetic lesion. The neurotmetic lesion encompasses all of the fourth-degree lesions (the neuroma in continuity) and the advanced third-degree lesions. I prefer using Sunderland's classification when correlating clinical problems with the underlying nerve fiber pathologic condition present (Table 80-1).¹⁵⁹

With neural compression lesions, it is rare to have a pure first-, second-, or third-degree lesion. Most often, these lesions are mixed. One of the degrees of injury usually predominates in a particular case.¹⁵⁸ The lesion mix can be determined by serial physical examinations, preoperative and postoperative serial EMG studies, and knowledge of the duration of the partial or complete nerve compression lesions. A fourth-degree nerve compression lesion is found most often when motor and sensory complete paralysis of a particular nerve has existed for more than 18 months.

The factors that affect return of nerve function following entrapment lesions are (1) the nerve fiber pathology, (2) the duration of the lesion and whether it is complete or partial, (3) the status of the end organs (i.e., motor and sensory), and (4) the level of the lesion.¹²⁰ When a nerve is entrapped, it is the peripheral fibers that are the most vulnerable to the pathologic process. Similarly, the heavy myelinated fibers are more susceptible to compressive forces.

There appear to be several types of first-degree injury. These lesions are correlated best when both the nerve fiber pathologic processes and the clinical recovery following neurolysis are analyzed temporally. There are ionic⁹⁶ and vascular^{40,109,117} lesions of nerve fibers that respond to release by prompt recovery within, at times, hours of surgery. There is a structural first-degree lesion, described by Gilliatt and colleagues⁶⁴ and Ochoa,¹⁵⁶ in which there is segmental injury to the nerve fiber consisting of segmental demyelination and remyelination of just a few nodal segments of the fibers. In this instance, the entire recovery process takes 30 to 60 days. The clinical implications of this particular lesion are as follows: whether the lesion is high or low in the nerve, it takes 30 to 60 days for neural function to be restored.

In contrast, in the second-degree lesion of nerve compression, there is degeneration from the point of injury distally. Regeneration of the nerve fibers occurs within the intact basement membrane. This usually progresses at the rate of 1 mm or more a day from the site of the lesion. A low second-degree lesion recovers much more rapidly than a high lesion with second-degree compression. A second-degree brachial plexus injury often takes at least 15 months before the intrinsic muscles in the hand recover, and they often do not recover fully. The more proximal extrinsic muscles of the forearm recover function at about the ninth to the 12th month following a second-degree entrapment lesion of the brachial plexus.

Third-degree injury due to neural entrapment occurs most frequently when other mechanical factors affecting nerves, such as traction and friction, are superimposed on the compression neuropathologic process. In the third-degree lesion, there is increased fibrosis in and about the nerve fibers that causes further structural change and neural dysfunction. Nerves move with motion of the limb. If their mobility is restricted by adherence of the nerve about a joint, as for example at the site of a supracondylar fracture in which the ulnar nerve adheres to the posterior aspect of the distal humerus, movement of the joint without movement of the nerve can cause traction neuritis of the ulnar nerve, which, in turn, can produce a stovepipe appearance of the nerve. A markedly thickened ulnar nerve can be the source of chronic pain even when it is intact and functioning.

RADIAL NERVE

The radial nerve and its major branches, the posterior interosseous nerve and the superficial radial nerve, are vulnerable to compression forces from the level of the lateral head of the triceps through the region of the elbow, proximal forearm, and even into the distal

TABLE 80-1 Correlation of Seddon and Sunderland Classification of Nerve Injuries*

Seddon	SUNDERLAND (DEGREE)				
	First	Second	Third	Fourth	Fifth
Neurapraxia					
Axonotmesis					
Neurotmesis					

*Shaded areas indicate equivalent terms.

forearm.^{27,53,153} Depending on which branch of the nerve is involved at the elbow, either pure motor (posterior interosseous nerve) or sensory (superficial radial nerve) paralysis can occur; rarely, motor and sensory involvement can be due to a process in the proximal forearm affecting both branches rather than the radial nerve itself.

Relevant Anatomy

The radial nerve in the distal arm passes anteriorly, 10 cm proximal to the lateral epicondyle (Fig. 80-2).⁸⁰ At the level of the radiocapitellar joint, it divides into its major branches, the deep and the superficial radial nerves. In this passage, the radial nerve passes just deep to the fascia of the brachioradialis. Above the elbow, the radial nerve innervates the brachioradialis and the extensor carpi radialis longus. The motor branch to the

extensor carpi radialis brevis arises from the superficial radial nerve in 58% of the population.¹⁵⁵ It frequently arises as a separate terminal branch of the radial nerve with the posterior interosseous and superficial radial nerves.

At the elbow, the deep branch passes between the two heads of the supinator muscle, where it becomes the posterior interosseous nerve.³¹ The proximal edge of the supinator forms an arch for the posterior interosseous nerve, the arcade of Frohse. The superficial radial nerve passes superficial to the supinator muscle. It is covered anteriorly by the brachioradialis. Recurrent vessels of the radial artery cross superficial and deep to these radial nerve branches. The posterior interosseous nerve courses in a dorsoradial direction in the proximal forearm. As it passes through the supinator, it innervates this muscle by multiple branches. Approximately 6 to

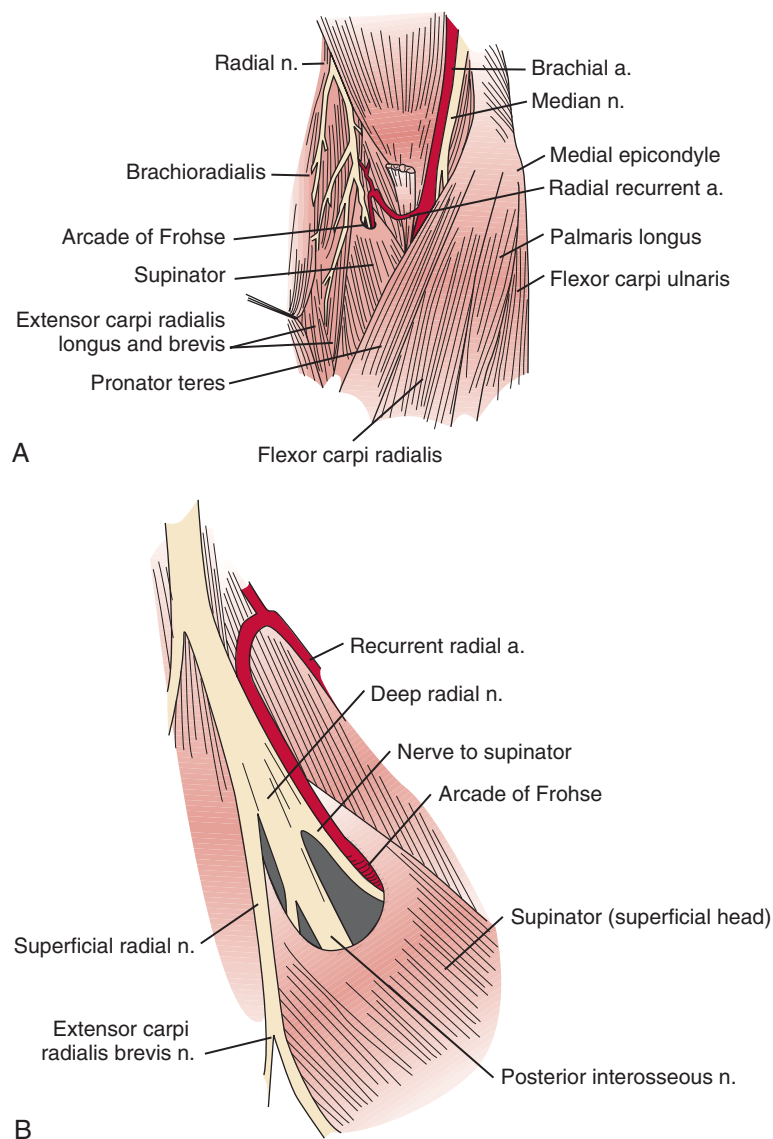


FIGURE 80-2 **A**, Dissection of the anterior aspect of the elbow demonstrating the anatomic relationship with the radial nerve. **B**, An enlarged view of the antecubital fossa shows the relationship of the posterior interosseous nerve to the supinator muscle and the arcade of Frohse. Note how the proximal superficial radial nerve is spared from compression by the arcade. (Redrawn from Spinner, M.: *Injuries to the Major Branches of Peripheral Nerves of the Forearm*, 2nd ed. Philadelphia, W. B. Saunders, 1978.)

8 cm below the elbow joint, this nerve emerges from the supinator muscle, where it divides into its terminal motor branches to the extensor digitorum communis, extensor digiti minimi, extensor carpi ulnaris, abductor pollicis longus, extensor pollicis longus and brevis, and extensor indicis proprius.

Posterior Interosseous Nerve Syndrome

In cases of a high bifurcation, the deep branch may be compressed at the lateral intermuscular septum, 4 cm proximal to the lateral epicondyle. There is focal tenderness and often wrist and finger extensor weakness. In these rare cases, the superficial radial nerve lies anterior to the lateral intermuscular septum.

The deep branch can be compressed by a fibrous band or thickened proliferating rheumatoid synovium from the radiocapitellar joint,^{18,114,116} the radial recurrent artery, or the leading tendinous edge of the extensor carpi radialis brevis.¹¹⁹ Next, the posterior interosseous nerve can be compressed at the arcade of Frohse,^{54,118,154,152,165,168,196} the most common site of compression. It may also be compressed by fibrotic bands within the midportion of the supinator²⁶ and its distal end. Other causes of compression include adhesions at the anterior aspect of the distal humerus, muscular anomalies, vascular aberrations,⁴¹ bursae,² inflammatory thickening, and adherence of the extensor carpi radialis brevis¹¹⁹ tendinous origin to the proximal edge of the supinator on its radial side.^{19,20} Some have identified focal constriction within the posterior interosseous nerve.^{71,94} Posterior interosseous nerve palsy may result from fractures^{124,179} or fracture-dislocations (Fig. 80-3).^{122,171} Tardy posterior interosseous nerve palsy may also occur years after unreduced Monteggia fracture-dislocations^{75,105} or after radial osteomyelitis (Fig. 80-4).¹⁷⁶ Tumors may compress the nerve primarily, which can be secondarily compressed by a structure such as the arcade of Frohse.^{7,11,17,151,178,200}

Classically, the clinical presentation of this nerve paralysis is thought to be typically motor because the posterior interosseous nerve basically carries motor fibers destined to innervate the extensor digitorum communis, extensor digiti minimi, extensor carpi ulnaris, abductor pollicis longus, extensor pollicis longus and brevis, and extensor indicis proprius. However, pain simulating lateral epicondylitis is also recognized as a common early presentation (see later discussion).¹⁹ Because of the segmental innervation of the supinator, the proximal or distal location of the compression of this nerve in the supinator can be determined by evaluating the electromyogram occasionally. Fibrillations in the supinator muscle suggest that the compression is proximal, at the arcade of Frohse. The pattern of involvement of this nerve varies depending on whether the entire nerve is compressed or whether there is a partial

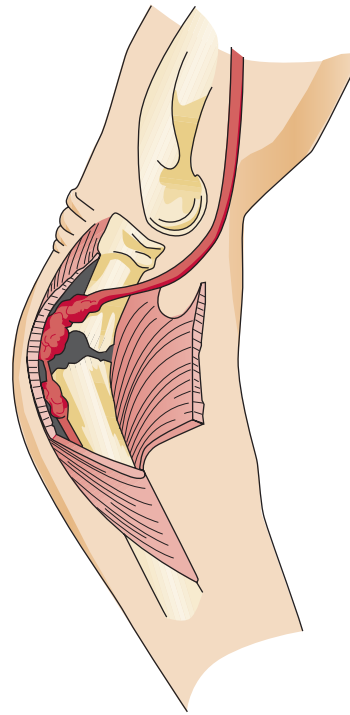


FIGURE 80-3 Fractures of the proximal radius often demonstrate posterior angulation, which places the posterior interosseous nerve in jeopardy. (Redrawn from Spinner, M., and Spinner, R. J.: Management of nerve compression lesions of the upper extremity. In Omer, G. E., Spinner, M., and Van Beek, A. L. [eds.]: Management of Peripheral Nerve Problems, 2nd ed. Philadelphia, W. B. Saunders, 1998.)

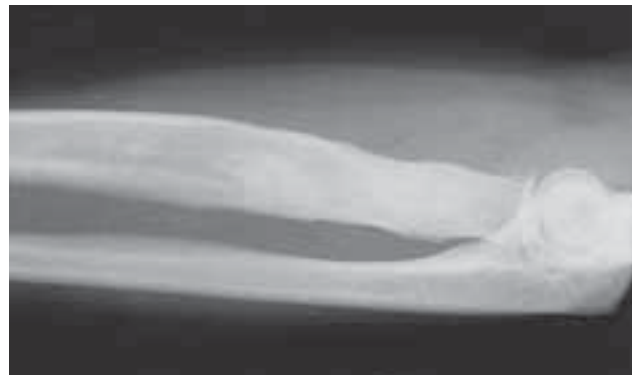

FIGURE 80-4 This patient presented with a partial posterior interosseous nerve palsy. Plain films showed thickened cortices and a widened radial metaphysis, bony changes from an old osteomyelitis. (From Spinner, R. J., and Spinner, M.: Tardy posterior interosseous nerve palsy due to childhood osteomyelitis: A case report. *J. Hand Surg.* 22A:1049, 1997.)

paralysis. When the entire posterior interosseous nerve is compressed, the fingers and thumb cannot extend at the metacarpophalangeal level and the wrist deviates in a radial direction with wrist extension (because the branches to the extensor carpi radialis longus and brevis

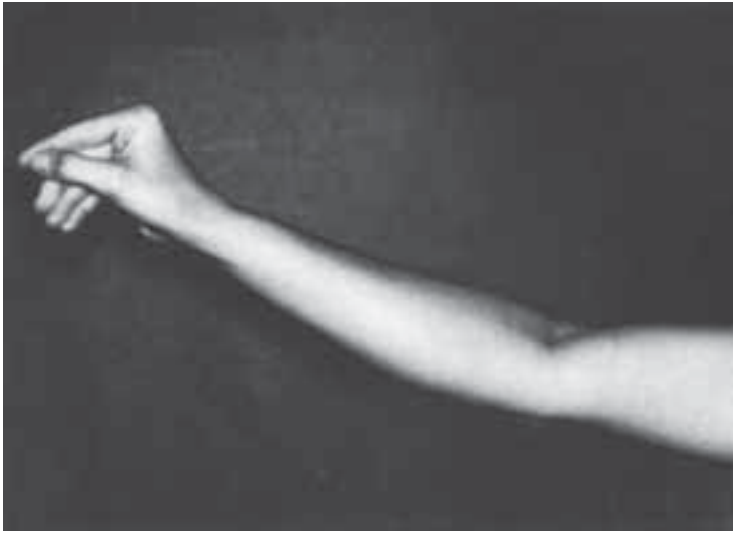


FIGURE 80-5 Patient with a complete posterior interosseous nerve paralysis showing inability to extend the fingers at the metacarpophalangeal joints as well as an inability to extend the thumb. The patient can dorsiflex his wrist. Wrist dorsiflexion is in a radial direction through the intact extensor carpi radialis longus, which is innervated at or above the elbow. Sensation in the hand is intact. (From Spinner, M.: *Injuries to the Major Branches of Peripheral Nerves of the Forearm*, 2nd ed. Philadelphia, W. B. Saunders, 1978.)

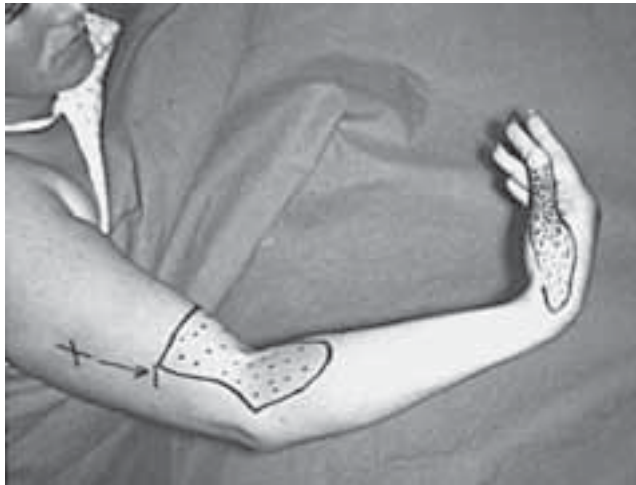

FIGURE 80-6 This patient has a complete radial nerve paralysis at the mid-arm level. Note the wristdrop with loss of finger extension at the metacarpophalangeal joints. The brachioradialis is paralyzed. Sensory loss is present in the autonomous zone of the radial nerve, that is, the dorsum of the thumb and first web space. In addition there is sensory loss in the distributions of the posterior cutaneous nerve of the forearm and the lower lateral cutaneous nerve of the arm.

usually take off more proximally) (Fig. 80-5).^{15,197} An untreated partial paralysis commonly evolves into a complete paralysis. Wristdrop signifies a lesion proximal to the posterior interosseous nerve branch (Fig. 80-6).

With partial paralysis, some of the digits, for example the fourth and fifth fingers at the metacarpophalangeal joints, do not extend but the others do.^{41,66,78,126} This attitude looks like a "pseudoulnar" claw hand. In reality, there is no clawing but only a drop at the metacarpo-

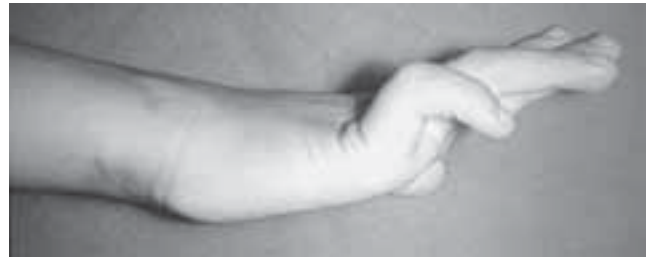

FIGURE 80-7 This patient has a complete low ulnar nerve palsy of the right hand with typical ulnar nerve clawing of the ring and little fingers. Note in this type of ulnar nerve palsy that there is hyperextension at the metacarpophalangeal joint typically seen with a claw finger. If a digit cannot be passively hyperextended at the metacarpophalangeal joint, a claw finger would not develop in the event of a low ulnar nerve paralysis. Sensation is absent in the palmar aspect of the little finger and ulnar half of the ring finger. Sensibility on the dorsal side is intact. (From Spinner, M., and Spinner, R. J.: *Management of nerve compression lesions of the upper extremity*. In Omer, G. E., Spinner, M., and Van Beek, A. L. [eds.]: *Management of Peripheral Nerve Problems*, 2nd ed. Philadelphia, W. B. Saunders, 1998.)

phalangeal joint and no true hyperextension of the metacarpophalangeal joints of the fourth and fifth fingers, as is present in a typical ulnar nerve palsy (Fig. 80-7).

Understanding the branching pattern of the posterior interosseous nerve can assist in further localization of partial lesions. Different patterns of presentation have been described and localized.^{72,77,173,181} These include dropped finger (all) and thumb deformity; dropped long-ring, and little finger (and extensor carpi ulnaris) deformity; dropped thumb (abductor pollicis longus,

extensor pollicis brevis and longus, and extensor indicis proprius) deformity; and dropped long and ring fingers only ("sign of the horns"). If surgery is entertained for incomplete lesions, the exit of the supinator should also be explored. In both partial and complete posterior interosseous nerve paralysis, sensation in the autonomous region on the dorsum of the first web space of the hand is uninvolved.

On occasion, isolated superficial radial nerve entrapment may occur in the elbow or proximal forearm region, but it is more commonly involved in the distal forearm or wrist. Isolated radial sensory paresthesias are usually secondary to irritations to the nerve in the region of the radial styloid. A compression neuropathy may occur in which this nerve penetrates the deep fascia in the midforearm between the brachioradialis and extensor carpi radialis longus.³⁷ Focal tenderness usually identifies the involved site.

Plain radiographs may be helpful in showing a fat stripe of a lipoma or a bony lesion in the vicinity of the radial neck (see Fig. 80-4). Ultrasound or magnetic resonance imaging (MRI) may demonstrate an occult ganglion or elucidate a palpable mass by its imaging characteristics (Fig. 80-8).¹⁷⁸ MRI is helpful in demonstrating denervation atrophy and hyperintensity in the nerve, which may help confirm a diagnosis or localization of nerve compression, or both. Electrical studies

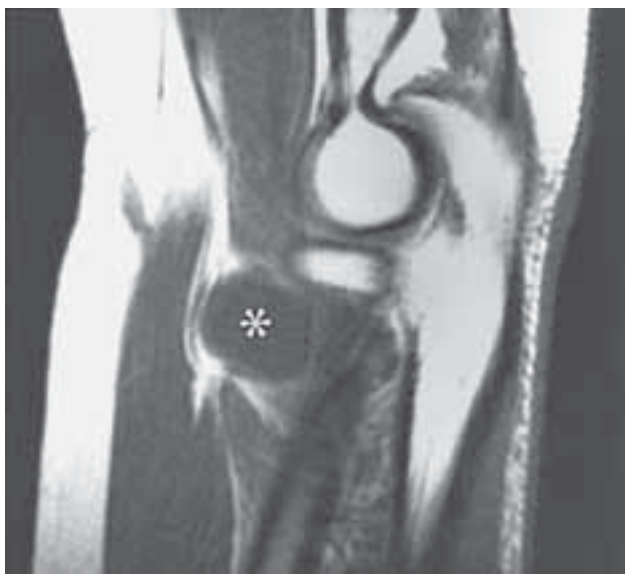


FIGURE 80-8 This patient had a near complete posterior interosseous nerve palsy associated with a 2.5 cm mass. Plain radiographs were unremarkable. Sagittal T1 (a)-weighted MR images show a mass (*) iso-intense to muscle in the region of the radial neck and the supinator muscle (S). (From Spinner, R. J., Lins, R. E., Collins, A. J., and Spinner, M.: Posterior interosseous nerve compression due to an enlarged bicipital bursa confirmed by MRI. *J. Hand Surg.* 18B:753, 1993.)

typically demonstrate denervational changes in the muscles innervated by the posterior interosseous nerve. If there are no EMG abnormalities in the supinator, then one should have a suspicion that the compression lesion of the posterior interosseous nerve is at the distal end of this muscle rather than at its proximal end. The brachioradialis and the extensor carpi radialis longus and brevis should not reveal any abnormalities in the typical posterior interosseous nerve syndrome because these muscles are innervated by the radial nerve proximal to the arcade of Frohse. Because of the overlap of posterior interosseous nerve syndrome with many cases of Parsonage-Turner syndrome, EMG should examine other muscles (e.g., shoulder muscles) to identify a more diffuse neurologic process that would favor the diagnosis of an inflammatory disease. The favorable response of operative decompression in some patients with posterior interosseous nerve "entrapment" may well be due to a favorable natural history of Parsonage-Turner syndrome. I believe that Parsonage-Turner syndrome is underrecognized. For this reason, I recommend performing decompression after 6 months of observation in patients with spontaneous onset of symptoms in whom mass lesions are not discovered and there has not been any clinical recovery.

Resistant Tennis Elbow (Radial Tunnel Syndrome)

For the most part, resistant tennis elbow is caused by degeneration or fascial tears at the lateral epicondyle. On occasion, persistent complaints have been attributed to either compression of the posterior interosseous nerve or to a combination of nerve compression and persistent localized epicondylitis.^{20,153,165} Resistant pain localized to the proximal forearm should suggest that entrapment of the adjacent posterior interosseous nerve may be an unrecognized factor.

Physical findings frequently reveal tenderness, both over the lateral epicondyle and anteriorly over the course of the nerve as it passes through both heads of the supinator. On occasion, pain can be localized to the distal end of the supinator posteriorly at the junction of the middle and upper thirds of the proximal forearm. Pain may be increased with resisted active supination of the forearm or with resisted extension of the long finger with the elbow extended. There are no sensory abnormalities in the hand.

EMG studies in cases of resistant tennis elbow due to entrapment of the posterior interosseous nerve are often normal, even if the condition has been present for months and with definite clinical findings. Conduction delays are observed rarely. Stress testing as described by Werner¹⁹⁵ has sometimes been helpful in confirming the diagnosis. Fibrillations in the muscles innervated by the posterior interosseous nerve are usually sparse, but if

present, they are most likely in the extensor indicis proprius. If fibrillations are widespread in the more severe lesions, weakness of the finger extensors and extensor carpi ulnaris is also usually evident.

Patients suspected of having coexisting lateral epicondylitis and posterior interosseous nerve compression, who fail conservative treatment, should have both conditions treated simultaneously. Patients with persistent pain after surgery for lateral epicondylitis should be suspected of having posterior interosseous nerve compression.¹²¹

Preferred Operative Exposure for the Entire Course of the Posterior Interosseous Nerve

When exposure of the entire posterior interosseous nerve is needed, the plane between the extensor carpi radialis brevis and the extensor digitorum communis (Fig. 80-9) is developed. The incision begins 5 cm proximal to the lateral epicondyle and passes over the lateral epicondyle down to the region of the origin of the outcropping muscles (abductor pollicis longus, extensors pollicis longus and brevis). The aponeurotic plane between the extensor carpi radialis brevis and the exten-

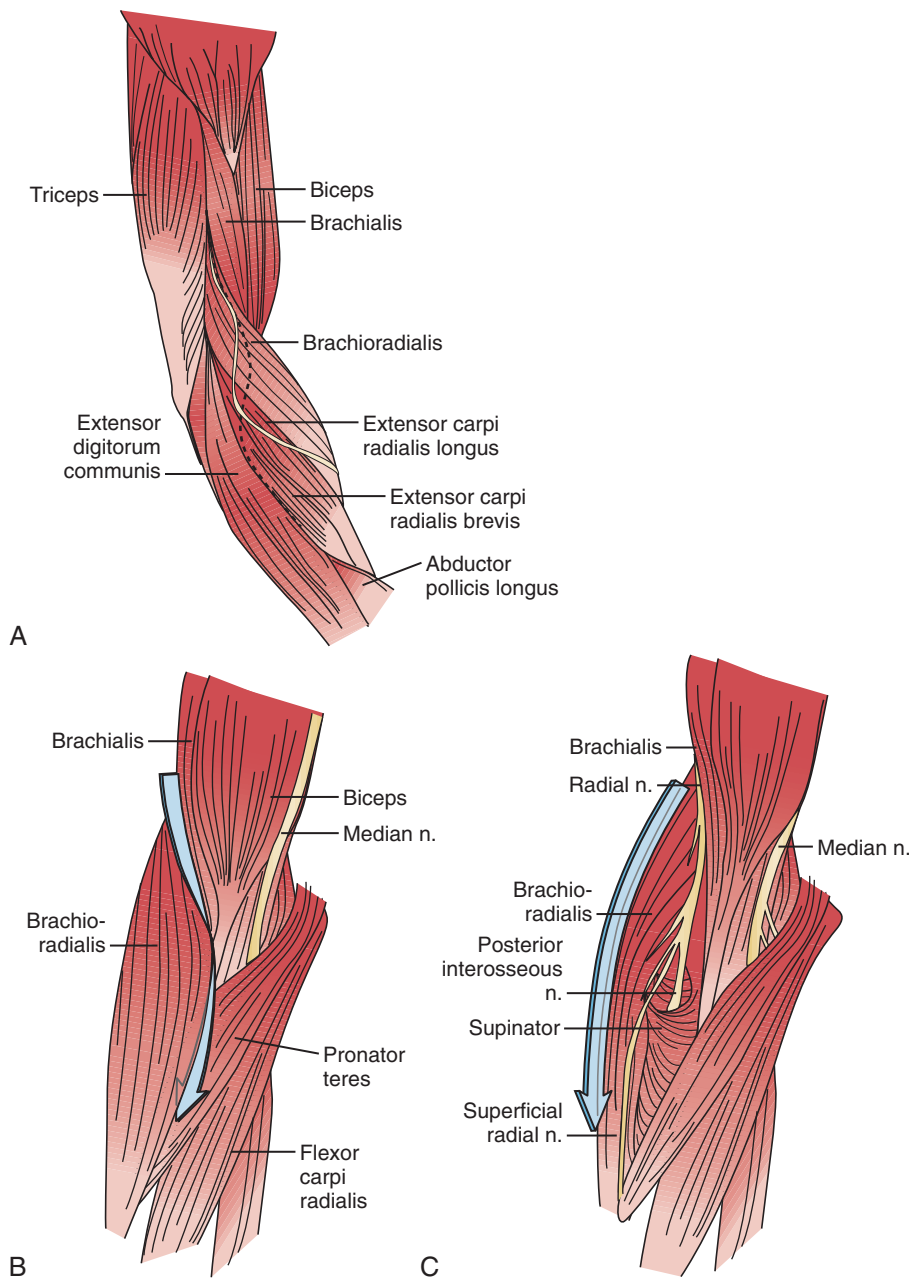


FIGURE 80-9 **A**, Incision for extensile exploration of the radial nerve is helpful for exploring the radial nerve, the proximal half of the posterior interosseous nerve, and the superficial radial nerve. **B**, The interval between the brachioradialis and the brachialis and pronator teres is developed. **C**, The radial nerve and its major forearm branches, the posterior interosseous and the superficial branches are exposed. (Redrawn from Spinner, M.: *Injuries to the Major Branches of Peripheral Nerves of the Forearm*, 2nd ed. Philadelphia, W. B. Saunders, 1978.)

or digitorum communis is developed from distal to proximal (Fig. 80-10). Identification of the plane is facilitated by passive motion of the fingers while the wrist is held steady, and the plane can be developed by blunt dissection. The supinator muscle is seen in the depth of the wound as these muscles are liberated. To gain complete exposure to the proximal end of the supinator, the extensor carpi radialis brevis tendon can be detached from its origin at the lateral epicondyle. At times, the distal portion of the origin of the extensor carpi radialis longus is detached, if necessary, for complete exposure of the underlying arcade of Frohse. This is facilitated with elbow flexion. Adherence of the tendinous origin of this muscle to the lateral portion of the supinator muscle is frequently found and is freed to give exposure to the proximal end of the supinator. One can identify the posterior interosseous nerve by flexing the elbow and by palpating the nerve's course as it passes obliquely through the supinator in a dorsoradial direction. By gently spreading longitudinally through the fat on both sides of the nerve with a right-angled hemostat, the

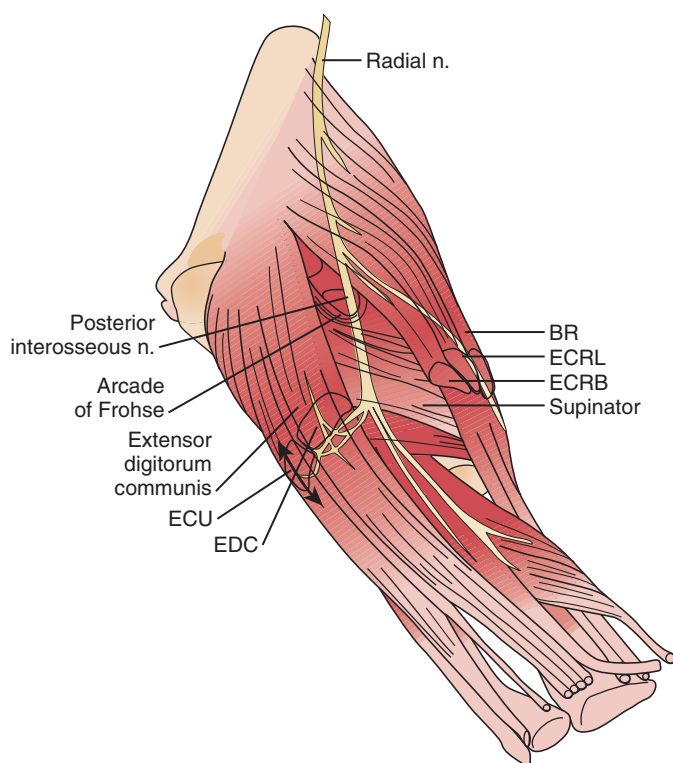


FIGURE 80-10 Details of the innervation provided by the posterior interosseous nerve. The nerve may be traced to the supinator showing the terminal branches (BR, brachioradialis; ECRB, extensor carpi radialis brevis; ECRL, extensor carpi radialis longus; ECU, extensor carpi ulnaris). (Redrawn from Spinner, M.: *Injuries to the Major Branches of Peripheral Nerves of the Forearm*, 2nd ed. Philadelphia, W. B. Saunders, 1978.)

nerve can be isolated. Because there are recurrent vessels in the vicinity, dissection must be gentle. Any vessels crossing the nerve should be clamped and tied individually. When the posterior interosseous nerve is identified proximal to the arcade of Frohse, a vasoloop is passed about it so that its identity and continuity are maintained. The arcade of Frohse may be found to be thickened. A hemostat is placed deep to the arcade but superficial to the nerve, and the arcade is incised, liberating the most proximal portion of the nerve. If further surgery is necessary, the entire posterior interosseous nerve can be traced and brought into direct view. Compression of the proximal and distal region has been described, as well as compression of the nerve in its midportion.¹⁷⁷ Epineurotomy of the posterior interosseous nerve at the site of its compression on occasion may be deemed necessary. Microsurgical technique should be used when this is indicated.

The detailed anatomy of the nerve supply to the extensor digitorum communis is important because this muscle obtains its innervation from branches of the terminal portion of the posterior interosseous nerve that run at right angles to the plane of the forearm in the distal portion of the proximal third of the forearm (see Fig. 80-10).¹⁷⁵ The operating surgeon should not sweep the planes between the extensor digitorum communis and the supinator because these branches are vulnerable. Furthermore, strong retraction posteriorly of the extensor digitorum communis in this area could damage the nerve supply to this important muscle.

The tendinous origin of the extensor carpi radialis brevis tendon is not reattached. Increasingly it has been recognized that the thick tendon of origin of this muscle in its distal prolongation passes directly over the arcade of Frohse. The combination of frictional and compressive irritation from this structure may be a major factor in the development of the radial tunnel syndrome. For this reason, a 3- to 4-cm portion of its most proximal tendinous origin may be excised. The tourniquet is released, and hemostasis is obtained. If the patient had lateral epicondylar pain and tenderness preoperatively, then at this time, the lateral epicondyle can be drilled or a small portion excised. The skin is closed, and the arm is immobilized in long arm plaster splints with the elbow at 90 degrees, the forearm in mid-position, and the wrist in a functional position. The immobilization is continued for 2 weeks, and the limb is gradually mobilized.

If a limited approach to the proximal portion of the supinator is needed, I prefer an anterior exposure of the posterior interosseous nerve. The lesion localized to the arcade of Frohse is approached by developing the plane proximal to the elbow between the brachialis and brachioradialis (see Fig. 80-9). Distal to the elbow, the anatomic dissection is continued, and the plane between the brachioradialis and the pronator teres is developed.

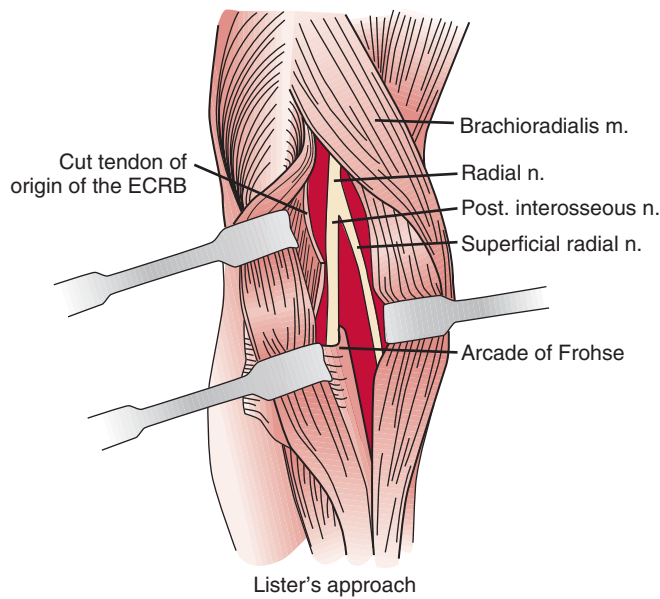


FIGURE 80-11 An extensile exposure of the forearm to demonstrate the radial nerve may be accomplished by the surgical excisions shown here. The data outlined by Lister may be used to aid in performing an extensile exposure to the radial tunnel.

If the dissection is difficult because of scarring or muscle anomalies, the superficial radial nerve can be identified distally and traced proximally to the main radial nerve and then to the deep branch. Any obstructing collateral vessels are ligated. The proximal third of the posterior interosseous nerve can be best visualized with this exposure. If necessary, the rest of the nerve can be followed by a separate posterior approach.

A longitudinal transmuscular approach through the brachioradialis has been popularized by Lister and associates.¹⁰⁷ It provides direct access to the nerve from the radiohumeral level to the midsupinator (Fig. 80-11).

When there has been prior surgery in the region, an anterior and separate posterior incision may be necessary to expose the radial nerve and its branches safely.

ULNAR NERVE

Relevant Anatomy

At the elbow, the ulnar nerve⁹⁰ passes posterior to the medial epicondyle through the cubital tunnel. The cubital tunnel retinaculum¹⁵⁷ (Fig. 80-12) seems to be the predominant site of pathology for patients with primary symptoms. In the proximal arm, the nerve descends in the anterior compartment. In the majority of upper extremities, the ulnar nerve crosses from the anterior to the posterior compartment in the distal arm. The anatomy of the region (about 8 cm proximal to the medial epicondyle), corresponding to the so-called arcade of

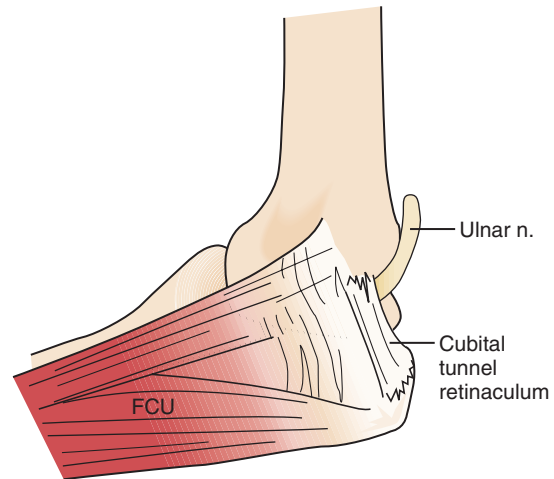


FIGURE 80-12 The cubital tunnel retinaculum seems to be the predominant site of pathology for patients with primary ulnar nerve symptoms at the elbow. (Redrawn from O'Driscoll, S. W., Horii, E., Carmichael, S. W., and Morrey, B. F.: The cubital tunnel and ulnar neuropathy. *J. Bone Joint Surg.* 73B:613, 1991.)

Struthers, is controversial.¹⁶⁴ The ulnar nerve, similarly, passes from posterior to the medial epicondyle to the anterior compartment of the forearm a few centimeters distal to the medial epicondyle and the cubital tunnel.

In the arm, there usually are no branches of the ulnar nerve of significance. Occasionally there is a variant high take-off of a motor branch to the flexor carpi ulnaris in the distal arm. The dorsal cutaneous nerve of the forearm, the sensory branch to the dorsoulnar aspect of the hand, rarely has been observed to arise in the proximal rather than the distal forearm. At the elbow level, the first branch is usually an expendable articular branch that arises just distal to the medial epicondyle; next are usually varying branches of the flexor carpi ulnaris and the motor branch to the fourth and fifth flexor digitorum profundus muscles. Stimulation of these branches can help the physician in deciphering whether the branch is a motor branch to an end organ or an articular branch. In addition, fascicular mobilization of these branches can be performed safely for a distance up to 6 cm to facilitate ulnar nerve transposition.¹⁹²

Etiology

Ulnar nerve compression lesions may be due to many factors.^{4,69,110,140,141,189,190} At the elbow level, spontaneous compression neuritis is well known as the cubital tunnel syndrome.⁴⁹ It is second only to carpal tunnel syndrome in its frequency.

Ulnar nerve lesions may be due to compression, stretch, traction, friction, or a combination of these. Direct pressure on the posterior aspect of the elbow can compress the nerve and is seen in patients follow-

ing coma, in surgical cases, or even in those who use wheelchairs. Flexion of the elbow may exacerbate symptoms, because it causes tightening and narrowing of the cubital tunnel and traction-related deformation of the nerve.⁶⁰ The tendinous origin of the flexor carpi ulnaris can compress this nerve between its ulnar and humeral heads with elbow flexion.⁶ Extrinsic pressure on the nerve may result from the anconeus epitrochlearis,^{29,102} a variant muscle crossing the ulnar nerve in the region of the medial epicondyle, or from adhesions. Tumors¹⁵⁰ such as ganglia^{14,89} may also be a causative factor.

A hypermobile ulnar nerve can produce symptoms.²⁵ This usually occurs during elbow flexion, as the nerve dislocates from the undersurface of the medial epicondyle to a position anterior to the epicondyle. Snapping of the medial triceps^{45,75,149,154,175} may be found in association with a dislocating ulnar nerve, and this can result in elbow pain, snapping, and ulnar nerve symptoms (Figs. 80-13 and 80-14). Persistent pain after an otherwise successful ulnar nerve transposition may represent unrecognized snapping of the triceps.

Bony changes at the elbow, whether acute or chronic, can result in ulnar nerve symptoms. Fracture-dislocations, medial epicondylar fractures, arthritic changes from osteoarthritis or rheumatoid arthritis,^{45,104} callus, heterotopic bone, and spurs have been implicated. Both cubitus valgus and varus deformities^{1,56,188} may produce late ulnar nerve symptoms at the elbow.

Iatrogenic causes of secondary ulnar nerve compression are numerous and related to technical factors.⁵⁷ Compression may occur when the ulnar nerve is trans-

posed anteriorly and is insufficiently mobilized, proximally or distally.^{169,170} After a previous transposition, secondary compression can be found proximally at the level of the so-called arcade of Struthers or distally where the ulnar nerve passes in the region of the common aponeurosis for the humeral head of the flexor carpi ulnaris and the origin of the flexor digitorum superficialis.⁸⁶ If these aponeurotic areas are not released sufficiently both proximally and distally (Fig. 80-15), then potential secondary sites of entrapment are created, which can produce symptoms.¹⁷² The medial intermuscular septum should be excised because it, too, is a common cause of secondary ulnar nerve entrapment. However and whenever, the ulnar nerve is transposed, it should be transposed anteriorly without kinking. Tight slings used to maintain the nerve in an anterior position may result in secondary compression.^{105,108} Furthermore, traction neuritis can result when the nerve is transposed into a groove in the flexor-pronator group of muscles. When the nerve heals in the muscular groove, the longitudinal fibrotic aponeuroses of flexor muscles of the medial aspect of the elbow can produce secondary traction neuritis.

Clinical Presentation

A patient with an ulnar nerve lesion at the elbow typically presents with a combination of elbow pain and sensory and motor complaints. It usually begins with intermittent paresthesias in the ring and little fingers that are aggravated by elbow flexion and frequently awaken the patient. Sensory loss in the ring and little fingers of the hand usually occurs later, but sensory loss in the

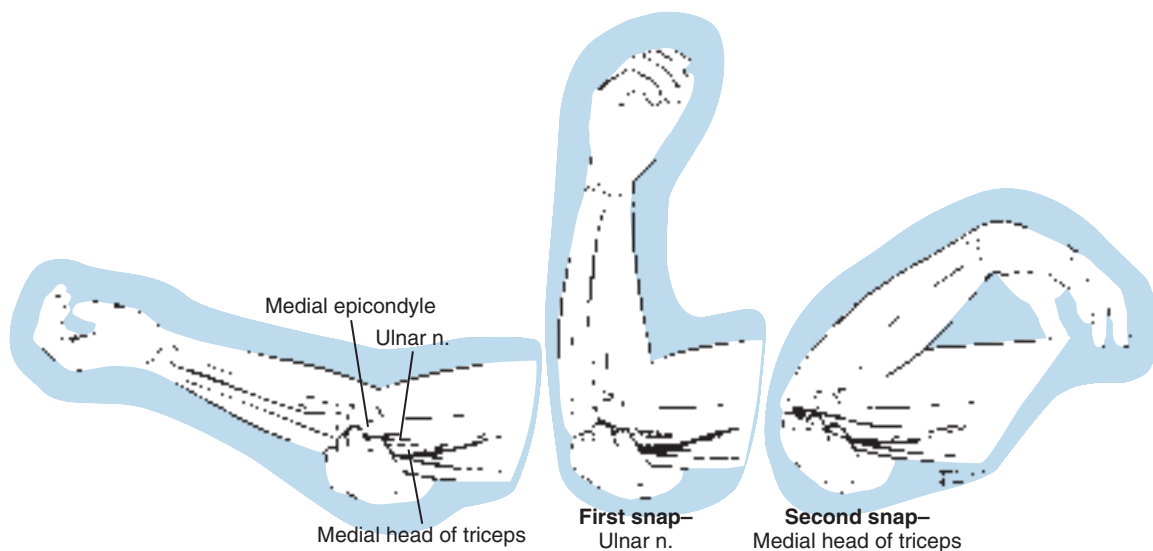


FIGURE 80-13 The ulnar nerve can be palpated within the cubital tunnel with the elbow in extension. Then with passive or active flexion of the elbow, the examiner can assess whether the ulnar nerve or another structure, such as a portion of the medial head of the triceps or an anomalous triceps tendon, moves anterior to the medial epicondyle. (Redrawn from Spinner, R. J., and Goldner, R. D.: Snapping of the medial head of the triceps and recurrent dislocation of the ulnar nerve: Anatomical and dynamic factors. *J. Bone Joint Surg.* 80A:239, 1998.)

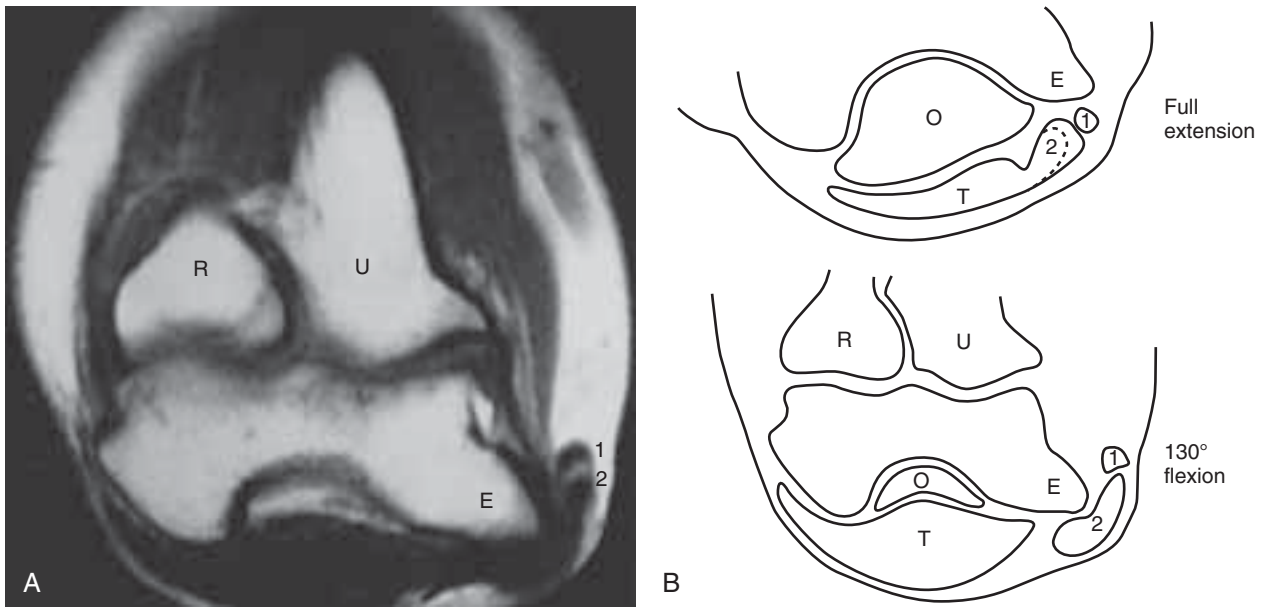


FIGURE 80-14 **A**, Magnetic resonance imaging can demonstrate a snapping triceps and dislocating ulnar nerve. Here the ulnar nerve (1) and a portion of the medial head of the triceps (2) are anterior to the medial epicondyle (E) with the elbow fully flexed. Computed tomography or real-time ultrasonography can also confirm the diagnosis. Imaging, however, is not necessary for confirmation of a diagnosis. Patients undergoing ulnar nerve surgery should be examined preoperatively and intraoperatively, with the elbow in flexion and extension, so that the surgeon can evaluate whether the medial head of the triceps snaps over the medial epicondyle. R, radius; U, ulna. **B**, Corresponding artist drawing shows the position of the ulnar nerve and the medial head of the triceps to the medial epicondyle in full extension and flexion. O, olecranon; T, triceps. (**A** from Spinner, R. J., Hayden, F. R., Jr., Hipps, C. T., and Goldner, R. D.: Imaging the snapping triceps. *AJ.R. Am. J. Roentgenol.* 167:1550, 1996; **B** redrawn from Khoo, D., Carmichael, S. W., and Spinner, R. J.: Ulnar nerve anatomy and compression. *Orthop. Clin. North Am.* 27:317, 1996.)

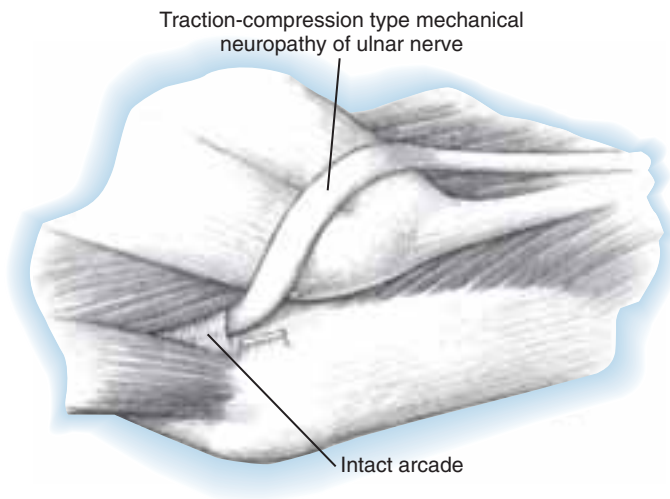


FIGURE 80-15 Tethering of the ulnar nerve may result from a previous (incomplete) decompression. (From Spinner, M., and Spinner, R. J.: *Nerve decompression*. In Morrey, B. F. [ed.]: *Master Techniques in Orthopaedic Surgery: The Elbow*, 2nd ed. Philadelphia, Lippincott Williams & Wilkins, 2002.)

dorsoulnar aspect of the hand is a classic localizing sign. Usually, there are no sensory abnormalities in the forearm. The sensory fibers and the intrinsic motor fibers lie more peripherally than the fibers of the flexor digitorum profundus or the flexor carpi ulnaris and may explain their vulnerability early on. Motor weakness

may be progressive in both the extrinsics and the intrinsics; at times, significant motor findings can be present with minimal sensory symptoms. With paralysis of the flexor digitorum profundus to the ring and little fingers, there is usually minimal clawing or no clawing of the ring and little fingers. With partial lesions, clawing may

be more pronounced if the flexor digitorum profundus muscles are intact and the intrinsic muscles are atrophic.^{115,182} However, if the metacarpophalangeal joints of the ring and little fingers cannot hyperextend because of innate tightness of the volar plates, then clawing will also not be observed.

A mechanical lesion of the ulnar nerve at the elbow may present with different clinical patterns in different patients because of the presence or absence of neural anomalies and the extent of involvement of the nerve. There are numerous variations in fibers carried within the ulnar nerve at the elbow level.¹⁶⁹ In 15% of upper extremities, the median nerve will carry many of the intrinsic motor fibers to pass from the median nerve or the anterior interosseous nerve branch of the median nerve to the ulnar nerve in the midforearm.

The sensory pattern typical of an ulnar nerve lesion at the elbow with diminished or absent sensation on the dorsoulnar aspect of the hand¹⁰⁰ may not be observed. This may occur when other sensory nerves take over the area usually supplied by the dorsal cutaneous branch of the forearm. One variant sensory pattern is observed when the superficial radial nerve not only innervates the dorsal radial aspect of the hand but also extends to supply the dorsoulnar aspect. Furthermore, sensation in all of the ring and middle fingers can be affected in some complete ulnar nerve lesions.

Differential Diagnosis

In the differential diagnosis, a nerve lesion that involves the cervical foramina, as in cervical arthritis, can present with ulnar nerve type symptoms. Restriction and pain on movement of the neck, positive foraminal compression maneuvers, arthritic changes seen radiographically, and cervical paravertebral muscle electrical abnormalities are usually noted. Short segment stimulation may be effective in isolating the level of the compression to the ulnar nerve at the elbow.⁴⁶

Another frequent site for exclusion is the thoracic outlet. The medial components of the plexus (lower trunk, or C8 and T1) are most frequently involved. Radiation of paresthesias along the inner aspect of the arm with symptoms extending to the ring and little fingers is a common neural presentation. Clinical signs characteristic of thoracic outlet syndrome, including a positive percussion sign, or a positive Adson or Wright test, or hyperabduction maneuver, or the presence of an arterial bruit with abduction or extension, may help localize the pathologic process to the thoracic outlet, but one should also be aware of the presence of false-positive physical examination findings in the normal population. EMG studies in patients with neurogenic (or true) thoracic outlet syndrome have abnormalities beyond the ulnar nerve territory, whereas those with thoracic outlet symptoms (or disputed thoracic outlet

syndrome) have normal EMG studies. The absence of ulnar F-wave abnormalities and cervical paravertebral fibrillations and the presence of an ulnar nerve conduction delay distally across the elbow can be suggestive findings of a lesion at the elbow. However, double crush lesions can occur and patients who have persistent symptoms after elbow surgery may have a more proximal lesion.

Entrapment in the hand is much less common than entrapment at the elbow; entrapment in the forearm is even rarer. Depending on the level of nerve involvement, varying clinical signs and symptoms become manifest. In a full-blown lesion in Guyon's canal, there is usually more significant ("paradoxical") clawing of these digits because the flexor digitorum profundus is functioning (see Fig. 80-7). The sensation on the dorsoulnar aspect of the hand is intact, whereas the palmar aspect of the hand may have some hypesthesia. Lesions of the ulnar nerve in the proximal forearm have findings similar to those at the elbow, whereas in the middle and distal forearm, symptoms depend on the relationship of the lesion to the motor branch of the flexor digitorum profundus and the dorsal cutaneous branch of the forearm. A lesion distal to the take-off of the motor branch of the flexor digitorum profundus is usually seen in patients with clawing. A lesion proximal to the dorsal cutaneous branch presents with numbness in the dorsoulnar aspect of the hand.

Conservative Treatment

In the milder cases, a trial of conservative treatment is often helpful. Avoidance of prolonged elbow flexion, especially at night, is helped by an elbow splint with the elbow maintained in a semiflexed position of about 60 degrees. During the day, resting the elbow on a table should be avoided. A 4- to 6-week trial of these measures is worthwhile.

Operative Treatment

There are several different approaches for the surgical intervention of the ulnar nerve: simple decompression, medial epicondylectomy, subcutaneous, intramuscular and submuscular transposition and endoscopic or arthroscopic techniques. Many surgeons over the years have passionately advocated a particular technique under all circumstances, whereas others have suggested that the choice of operative procedure⁵² should be fitted to the patient's symptoms and the EMG findings. Despite these opinions, recent prospective studies performed in primary cases have not demonstrated any statistical differences between simple decompression and the different types of anterior transposition.^{8,10,61,128,202} As a result, simple decompression in these cases is becoming more commonly performed. In secondary cases, submuscular transposition is the procedure of choice.

For mild and moderate ulnar nerve compression, I perform a simple release of the cubital tunnel.²⁴ If the nerve is noted to dislocate intraoperatively after release, I perform an anterior subcutaneous translocation, the same procedure that I perform currently in most patients with severe ulnar neuropathy. If the patient has no fat in the subcutaneous tissue, or in revision surgery, I prefer the Learmonth procedure, the submuscular anterior translocation of the ulnar nerve.^{101,105} I do not perform submuscular transposition in patients with rheumatoid arthritis or in those with post-traumatic medial bony changes.

Preferred Operative Exposure for Simple Decompression of the Ulnar Nerve

Under monitored anesthetic care, the ulnar nerve is exposed through a 4- to 5-cm posteromedial incision to the elbow centered at the level of the olecranon groove. The ulnar nerve is identified just proximal to the elbow. A vasoloop is placed around the ulnar nerve. With the nerve protected, it is traced through the cubital tunnel retinaculum and a portion of the flexor carpi ulnaris. An occult lesion, such as a joint-related ganglion is looked for posterior to the nerve without circumferential mobilization of the nerve. The medial intermuscular septum is not resected. Proximal release is not done. The stability of the nerve and the position of the medial triceps is assessed with passive elbow range of motion.

Preferred Operative Exposure for Anterior Transposition of the Ulnar Nerve

The incision extends 5 cm proximal to the medial epicondyle and 4 cm distal to the medial epicondyle on the

posteromedial side of the elbow (Fig. 80-16A). The V-shaped flap formed at the elbow level is undermined subcutaneously and is retracted medially. The medial cutaneous nerves of the forearm and arm are identified and preserved by vasoloops about them. Avoidance of injury to them is important because patients afflicted with ulnar entrapment lesions are vulnerable to symptomatic postoperative skin neuromata.⁵⁸ The plane between the subcutaneous fat and the brachial and antebrachial fascia in the distal arm is delineated and undermined. The medial intermuscular septum is seen, and the ulnar nerve is identified just posterior to the medial intermuscular septum in the distal third of the arm. In approximately 70% of limbs, muscular fibers of the medial head of the triceps have been reported to cross the ulnar nerve and attach to the so-called arcade of Struthers, 8 cm proximal to the medial epicondyle. If these muscular fibers of the medial head of the triceps are noted, it is a clear indication that the ulnar nerve must be liberated in this area (see Fig. 80-16B). The medial intermuscular septum is cleared posteriorly of muscular fibers to the level of the humerus. Anteriorly, the medial intermuscular septum is separated with care from the neurovascular bundle. The inferior ulnar collateral vessels, which penetrate the intermuscular septum, can be preserved, and the medial intermuscular septum is excised (see Fig. 80-16C). The ulnar nerve is mobilized. Its external longitudinal vessels are kept in continuity with the nerve. The transverse components of the vascular supply can be cauterized, preferably with a bipolar unit, keeping the external and internal vascular supply intact. At the level of the posterior aspect of the medial epicondyle, the ulnar nerve is liberated and an articular branch to the adjoined surface is sacrificed. One or two

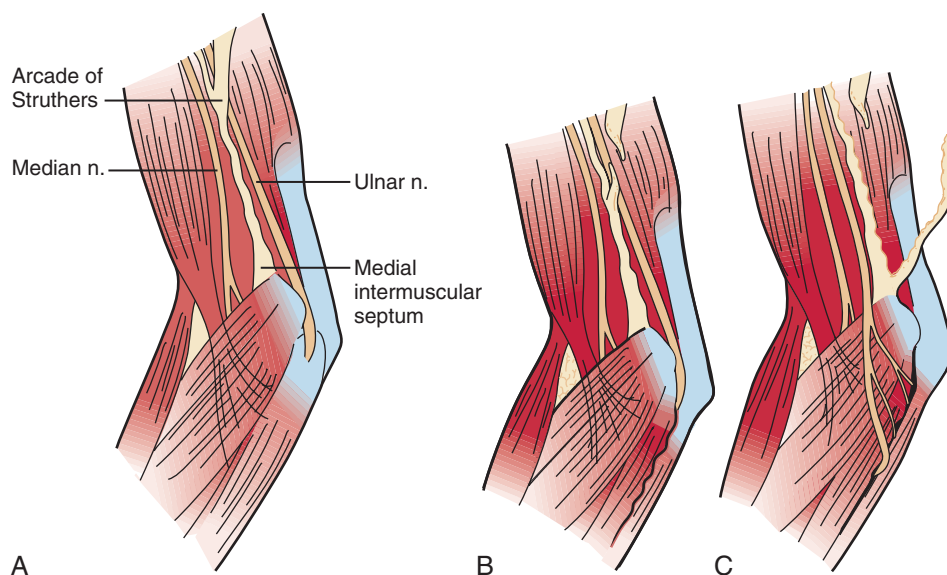


FIGURE 80-16 **A**, Anterior translocation of the ulnar nerve requires exposure of the medial intermuscular septum and the so-called arcade of Struthers. **B**, The arcade has been released. **C**, A portion of the medial intermuscular septum is then removed, and the ulnar nerve is brought forward anterior to the flexion axis of the elbow. (Redrawn from Spinner, M.: *Injuries to the Major Branches of Peripheral Nerves of the Forearm*, 2nd ed. Philadelphia. W. B. Saunders, 1978.)

rubber bands are placed about the ulnar nerve to aid in the dissection. Distal to the medial epicondyle, the ulnar nerve is identified as it passes through the cubital tunnel. The tendinous arch for the origin of the flexor carpi ulnaris of the humerus and ulna in the proximal region is identified. The humeral attachment is detached, and the interval between the common aponeurosis of the flexor carpi ulnaris humeral head and the flexor digitorum superficialis is defined. The ulnar nerve is identified distally, deep to the flexor carpi ulnaris. Its common fibrous aponeurosis is liberated to free the ulnar nerve in the proximal forearm. The multiple branches of the flexor carpi ulnaris are preserved. The motor branch to the flexor digitorum profundus of the ring and little fingers is also identified and preserved. The ulnar nerve is mobilized in the proximal third of the forearm with the use of loupe magnification and microsurgical technique to permit nontethered anterior translocation.⁶⁷ At this point, the nerve can be placed in a subcutaneous plane or placed in a submuscular position. A loose fasciadermal sling⁴⁴ or the medial intermuscular septum¹⁴⁵ may be used to stabilize the ulnar nerve; before wound closure, the elbow should be passively flexed and extended to ensure that ulnar nerve compression has been eliminated and to check that snapping of the medial portion of the triceps is not present.¹⁷³ If snapping of the medial triceps is identified either preoperatively or intraoperatively, one can trans-

pose laterally or excise the offending dislocating portion of the medial triceps.

To proceed with the Learmonth procedure, the median nerve is identified proximal to the lacertus fibrosus in the distal arm and a rubber band is placed around it (Fig. 80-17). The median nerve is found deep to the brachial fascia at the elbow level medial to the brachial artery. The lacertus fibrosus in the proximal forearm is incised longitudinally. The next step in the dissection is to detach the muscles of the flexor-pronator group 1 cm distal to the medial epicondyle. To accomplish this, a tonsillar clamp is placed from the radial side of the flexor-pronator group of muscles 1 cm distal to the medial epicondyle and passed medially deep to the flexor-pronator group of muscles to exit in the region of the cubital tunnel. The tonsillar clamp is passed superficial to the ulnar collateral vessels on the anterior aspect of the medial side of the forearm. The flexor-pronator origin is incised sharply. The brachial fascia is identified. By a combination of sharp dissection and periosteal stripping, the flexor-pronator group of muscles is stripped distally. The tourniquet is released. Any additional bleeding is brought under control either by ties or with the bipolar electrocautery. The ulnar nerve is translocated anteriorly adjacent to the median nerve, and the flexor-pronator origin is repaired (Fig. 80-17B). Z-lengthening or advancement of the flexor-pronator origin can also be performed.^{33-35,135} The subcutaneous

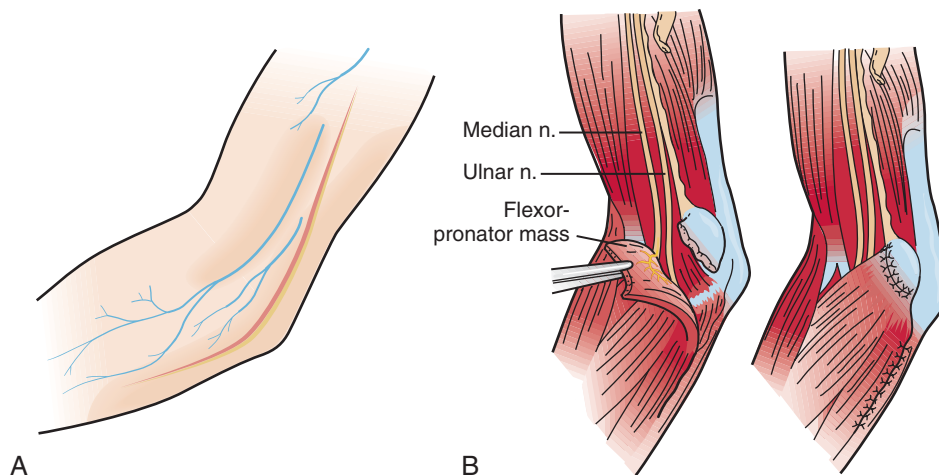


FIGURE 80-17 **A**, Extensive skin incision is employed for translocation of the ulnar nerve. This allows exposure of the proximal aspect of the medial intermuscular septum and the so-called arcade of Struthers. **B**, Submuscular translocation (Learmonth) technique requires proximal dissection of the ulnar nerve and release of the medial intermuscular septum approximately 8 cm proximal to the flexor-pronator muscle group, which is elevated from the medial epicondyle. The ulnar nerve is brought forward to lie next to the median nerve. The flexor-pronator group is then reattached to the medial epicondyle. Particular care is taken not to injure the anterior interosseous branch of the median nerve, which arises in this region. (Redrawn from Spinner, M.: *Injuries to the Major Branches of Peripheral Nerves of the Forearm*, 2nd ed. Philadelphia. W. B. Saunders, 1978.)

tissues and skin are closed with either interrupted or subcuticular sutures. After a submuscular transposition, the elbow is immobilized in a semiflexed position with the forearm in midposition and the wrist in neutral; the fingers and thumb are free. The immobilization is continued for 7 days followed by progressive active extension in a blocking splint.

I do not have direct experience with medial epicondylectomy^{28,55,63,84,85,158} and do not like intramuscular transposition for ulnar nerve neuritis, although other surgeons have reported success with these techniques. Endoscopic and arthroscopic techniques are being employed by some surgeons.^{79,95,144,187}

MEDIAN NERVE

The median nerve at the level of the elbow may on occasion be susceptible to a compressive neuropathy from the level of the supracondylar process proximally to the flexor superficialis arch distally. Between these

levels, the ligament of Struthers, the lacertus fibrosus, the deep head of the pronator teres, variant muscles, distended bursae, or vascular malformations may produce symptomatic median nerve compression.

Relevant Anatomy

The median nerve lies beneath the brachial fascia on the medial aspect of the arm resting on the brachialis muscle (Fig. 80-18).⁸⁰ The brachial artery and veins lie laterally in close proximity and adjacent to the biceps tendon. The medial intermuscular septum lies posteriorly and attaches to the medial epicondylar flare. The median nerve passes first alongside the humeral origin of the pronator teres and then beneath it to lie on the deep surface. It most often passes between the humeral head and the ulnar head of the pronator muscle but may pass deep to both heads, or the ulnar head may be absent. Fibrous arches may play a role in the nerve compression.⁵⁹ The motor branches of the pronator teres usually arise from the medial aspect of the nerve beneath the

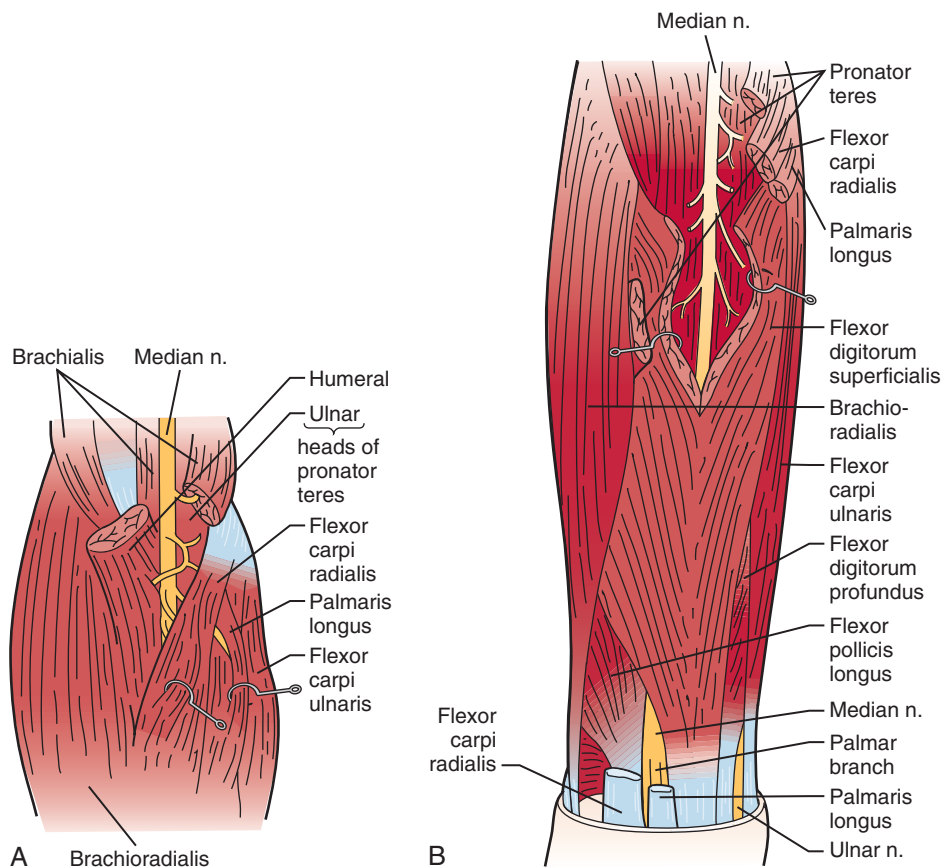


FIGURE 80-18 **A**, As the median nerve enters the forearm, it gives off branches to the humeral and ulnar heads of the pronator teres, which originate from the medial aspect of the nerve. **B**, The median nerve is followed deeper into the forearm. The anterior interosseous nerve is shown entering the forearm under the flexor digitorum superficialis. The nerves to the flexor-pronator group are demonstrated. (Redrawn from Hollinshead, W. H.: *Anatomy for Surgeons*, 2nd ed, Vol. 3. New York, Harper & Row, 1969.)

upper margin of the muscle but variably arise above the antecubital area. The branch to the ulnar head may arise from the main branch or as a separate branch from the median nerve. The anterior interosseous branch arises deep and usually laterally at the level of the deep head of the pronator teres and in close approximation to the bifurcation of the radial and ulnar arteries from the brachial artery.^{68,81} The main branch of the median nerve next passes beneath the tendinous arch of origin of the flexor digitorum superficialis and lies in close approximation to the deep surface of this muscle (see Fig. 80-18B). The anterior interosseous nerve runs onto the index flexor digitorum profundus muscle and the flexor pollicis longus.¹¹²

The pronator teres usually arises from the common origin of the medial epicondyle but may extend proximally along the medial epicondylar flare. The lacertus fibrosus passes from the biceps tendon to the antebrachial fascia obliquely over the flexor-pronator group of muscles.

Altered anatomy, whether from anatomic variation or a pathologic condition, may play an important part in causing nerve compression syndromes.^{51,98} The most important for median nerve compression about the elbow are the supracondylar process and ligament of Struthers,¹⁸⁰ the Gantzer muscle,^{5,59} the palmaris profundus,¹⁶⁹ the flexor carpi radialis brevis,¹⁶⁹ a variant lacertus fibrosus (Fig. 80-19),¹⁷⁴ and vascular perforation or tethering of the nerve.¹⁵ Distal humeral fracture or dislocation is well known to cause median nerve injury.^{106,146}

Supracondylar Process

Compression of the median nerve at the level of the distal humerus may occur when the nerve passes beneath the osseous process,¹¹⁵ which extends obliquely midanteriorly and continues to the medial epicondyle as the ligament of Struthers.⁶² (Ulnar nerve compression may rarely occur in association with a supracondylar process and the ligament of Struthers.) Muscle hypertrophy or strenuous use may facilitate the irritant effect of this structure.⁸⁰ The supracondylar process has been a compressive factor in approximately 40 case reports. The supracondylar spur may be associated with proximal extension of the humeral head of the pronator teres, which may also be a factor in compression of the median nerve.

Pronator Syndromes

The pronator syndrome has been described as a neural compression syndrome within the proximal forearm.^{70,82,83,92,123,161,194} It is a controversial disorder. The symptoms are often vague, consisting of discomfort in the forearm with occasional proximal radiation into the arm. A fatigue-like pain description may be elicited. Numbness of the hand in the median distribution is

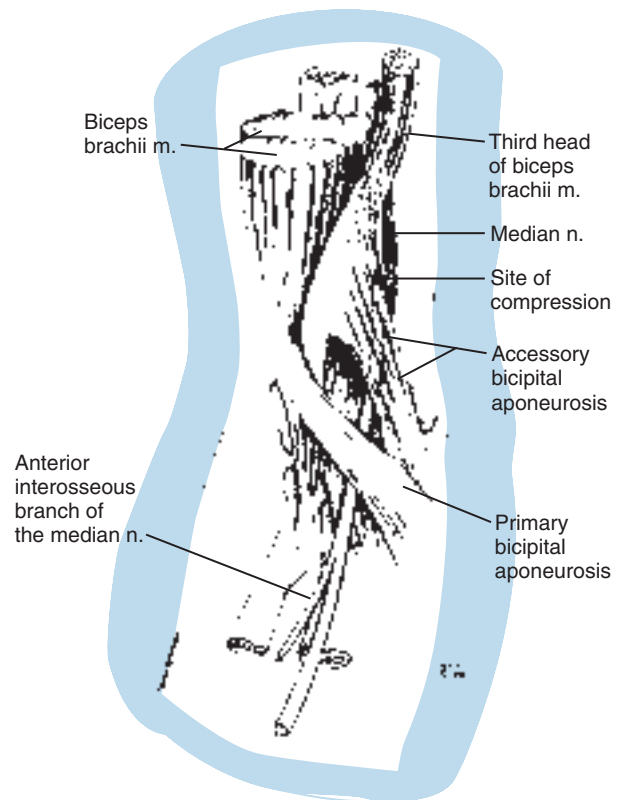


FIGURE 80-19 An accessory bicipital aponeurosis from the third head of the biceps has compressed the median nerve, resulting in both anterior interosseous and main branch motor weakness without sensory symptoms. (From Spinner, R. J., Carmichael, S. W., and Spinner, M.: Partial median nerve entrapment in the distal arm because of an accessory bicipital aponeurosis. *J. Hand Surg.* 16A:236, 1991.)

often secondary. Repetitive strenuous motions, such as industrial activities, weight training, or driving, often provoke the symptoms. Nocturnal symptoms are infrequent. Numbness may affect all or part of the median distribution. Occasionally, patients may insist on emphasizing numbness of the little finger or the “whole hand.”

Women seem to be at greater risk than men of developing these symptoms, especially if they are exposed to highly repetitive, moderately strenuous industrial occupations in which alternate pronosupinatory motions are required. The symptoms usually develop insidiously, but occasionally a specific event or sudden onset of pain in the forearm is associated with heightened susceptibility to muscular stress.

Acute symptoms should be distinguished from the typical pattern of a more chronic “pain syndrome.” An expanding hematoma such as following venipuncture can result in acute compression of the median nerve by the lacertus fibrosus. Renal dialysis patients with arteriovenous fistulae have been reported to develop median

nerve symptoms suddenly that localize to the elbow level. Pronator syndrome may also occur following crushing or contusion of the proximal forearm or stretching of the spastic musculature by casting in patients with cerebral palsy.

Diagnosis is often delayed because of the vague, poorly related history, lack of easily observed findings, and association with workers' compensation evaluation. At times, the patient seems more interested in recriminatory action against his or her employer than with resolution of the problem.

Physical Examination Physical findings are often subtle, and several observations have been suggested to help to make the diagnosis:

1. An indentation of the flexor-pronator muscle mass below the medial epicondyle suggests that the lacertus fibrosus exerts a constrictive effect at that level.^{70,97,117,185} The indentation may be increased by active or passive pronation of the forearm. This should be compared with the opposite arm (Fig. 80-20).

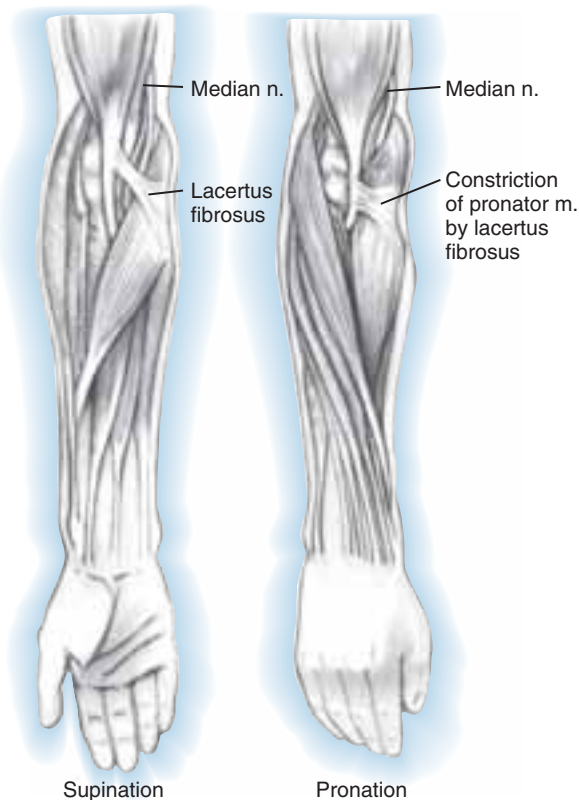


FIGURE 80-20 When the arm pronates, contraction of the pronator muscle may result in indentation of this structure by the lacertus fibrosus. Such a process may give rise to entrapment of the median nerve and the so-called pronator syndrome.

2. The flexor-pronator musculature feels indurated or tense in comparison with the opposite arm or with resisted pronation. Most patients with this syndrome have well-developed forearm musculature.⁷⁰
3. Resisted pronation for 60 seconds may initiate the symptoms by contracting the flexor-pronator muscle (Fig. 80-21).
4. Resisted elbow flexion and forearm supination may elicit similar symptoms, also presumably by tensing the lacertus fibrosus. Variations in the lacertus fibrosus may be recognized by a separate protrusion in the medial aspect of the antecubital space during resisted flexion. An accessory lacertus fibrosus has shown a tendency to invoke weakness affecting the anterior interosseous nerve fibers within the median nerve.¹⁷⁴
5. Resisted flexion of the middle finger proximal interphalangeal joint by tightening the fibrous arch of the origin of the superficialis muscle may also induce symptoms, although this test seems to be positive far less frequently than the previous two.
6. Direct pressure by the examiner's hand over the proximal portion of the pronator teres approximately 4 cm distal to the antebrachial crease while exerting moderate resistance to pronation has also been useful. It should be compared with results of a similar test on the asymptomatic forearm.
7. The median nerve is sensitive to direct pressure, tapping, or rolling beneath the finger in the antecubital space.
8. Occasionally, passive stretching of the finger and wrist flexors will accentuate the symptoms, but this is unlikely to be positive before the preceding tests.
9. Weakness of the median innervated muscles is infrequent, but careful comparison of strength between the two hands is indicated. The flexor pollicis longus and index finger flexor digitorum profundus are the most likely to show weakness.

It is important to verify whether these tests mimic or reproduce exactly the symptoms that brought the patient to the physician. This syndrome is most likely to be confused with carpal tunnel syndrome, and unfortunately, the two conditions may occur simultaneously, or one may antedate the other, suggesting a susceptibility factor. Some factors that may help to differentiate between the two syndromes are indicated in Table 80-2. Obviously, careful clinical judgment is required to ensure the correct diagnosis. Indications for surgery depend largely on the severity of the patient's symptoms. Aside from avoidance of the activities associated with aggravation of the symptoms, there is little available nonoperative treatment. A mixture of lidocaine and hydrocortisone instilled near the nerve may produce temporary beneficial effect and provide an additional diagnostic aid if

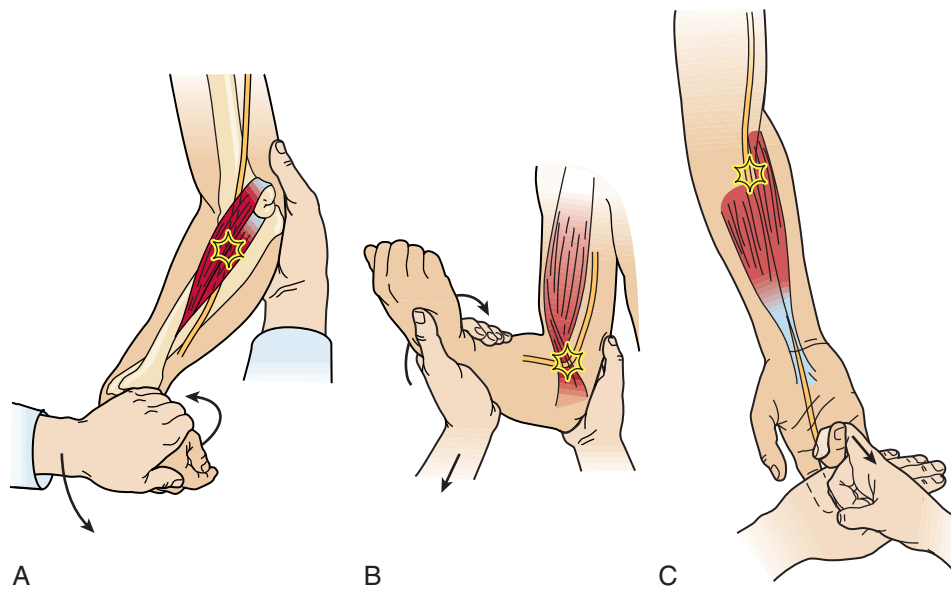


FIGURE 80-21 Described features of the physical examination that help to demonstrate the so-called pronator syndrome. **A**, Proximal forearm pain is increased by resistance to pronation and elbow flexion as well as to flexion of the wrist. **B**, Pain in the proximal forearm that is increased by resistance to supination is also suggestive of compression by the lacertus fibrosus. **C**, Resistance of the middle finger flexor produces pain in the proximal forearm when compression of the median nerve occurs at the flexor digitorum superficialis arch. (Redrawn from Spinner, M.: *Injuries to the Major Branches of Peripheral Nerves of the Forearm*, 2nd ed. Philadelphia, W. B. Saunders Co., 1978.)

TABLE 80-2 Comparison of Findings Between the Carpal Tunnel Syndrome and the Pronator Syndrome

	Carpal Tunnel Syndrome	Pronator Syndrome
Nocturnal symptoms	+	–
Muscular fatigue	–	+
Proximal radiation	±	+
Thumb paresthesias	±	+
Thenar atrophy	+	–
Phalen's sign	+	–
Pronator signs	–	+
Electromyography	+	–

effective. An increasing number of surgeons have advocated carpal tunnel release before pronator release,⁵ whereas others are releasing both areas simultaneously.¹²⁵

Electromyography EMG findings as an aid in the diagnosis of the pronator syndrome have been disappointing.¹⁶ Findings that adequately supported the diag-

nosis were found in only 10% of patients with the diagnosis of pronator syndrome. Slowed conduction velocity across the median nerve below the elbow is seldom detected. The best explanation for this is the size and complexity of the nerve, which is insufficiently compressed to prevent a stimulus progressing at normal velocities down a significant number of fascicles of the nerve. The slowed impulses in affected fascicles are blurred and dampened in the recording. Muscle studies are seldom specific. Isolated fibrillations, particularly in the pronator teres, have been observed. Insertional changes are often nonspecific. Electrical studies are useful in ruling out the presence of another entrapment site or underlying peripheral neuropathy.

Intraoperative studies of conduction velocities and voltages were carried out before and after median nerve release in 10 forearms in the early part of one series.⁷⁰ Significant increases in recorded velocities or voltages at the distal electrodes were noted in only five instances after decompression. Newer techniques may improve the diagnostic acuity of EMG, but at this time, the history and physical examination must be relied on for the diagnosis.

Operative Findings The median nerve seldom shows the flattening, indentation, or pseudoneuroma formation so common at the carpal tunnel. The lacertus fibrosus is usually apparent in its course from the biceps tendon

to its interdigitations with the longitudinally directed fibers of the antebrachial fascia over the proximal third of the flexor-pronator muscle group. An indentation of the pronator teres is apparent with passive pronation (see Fig. 80-20). At times, this finding may be dramatic. The compression may even be due to an accessory bicipital aponeurosis. After release of the lacertus fibrosus and antebrachial fascia, the median nerve is apparent lying adjacent to the humeral head of the pronator teres (Fig. 80-22).

The median nerve is followed under the humeral head of the pronator teres, where it encounters the ulnar head of the muscle, which varies considerably in size. It may be primarily a fleshy head, but usually the tendon of origin of the muscle arises laterally and crosses the nerve. It may vary from a structure measuring 1 or 2 mm in diameter to a band of 1 or 2 cm in width. This structure lies just distal to the overlying lacertus fibrosus. Occasionally, the tendon arises medially, thus allowing the nerve to pass under rather than through the prona-

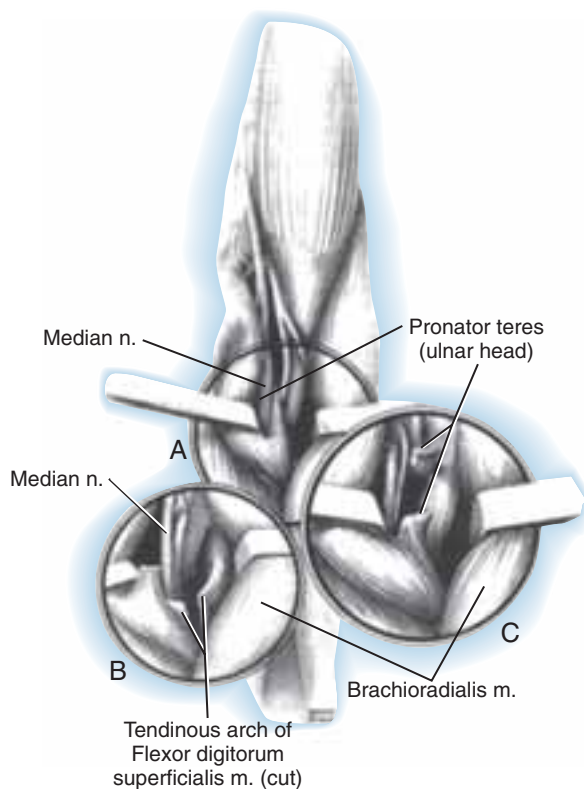


FIGURE 80-22 **A**, Release of the lacertus fibrosus reveals the median nerve as it enters the pronator teres muscle. **B**, Release of the ulnar head sometimes reveals a tight arch of the flexor digitorum superficialis muscle. **C**, If the ulnar head of the pronator teres is the offending part, it is released.

tor teres. Sometimes no ulnar head is discernible, and forearms with this arrangement may be less susceptible to the condition. In the majority of patients with the pronator syndrome, the combination of a tight tendinous band of the ulnar head associated with hypertrophy of the flexor-pronator musculature, which is constricted by the enveloping antebrachial fascia and lacertus fibrosus, produce the combination of pressure and tension on the nerve that induces symptoms.

The fibrous arch of origin of the flexor digitorum superficialis lies 1 to 2 cm distal to the deep head of the pronator teres (see Fig. 80-22B). This, too, may be a constriction, especially when there is a large sharp edge to the band and hypertrophy of both the deep flexors and overlying muscle groups. This structure can be a cause of pronator syndrome. In a similar fashion, variant or vestigial muscles such as the Gantzer muscle, palmaris profundus, or flexor carpi radialis brevis may act to produce constriction. Less common factors that act to compress the median nerve are vascular malformations or distention of the bicipital bursa. The nerve may be perforated by a branch of the radial artery and accompanying veins or overlain by a taut vascular bridge. Some authors^{74,129} have recommended microsurgical interfascicular dissection of the median nerve in the distal arm and elbow region in suspected cases of pronator or anterior interosseous nerve syndromes where no obvious sign of median nerve compression is identified.

Anterior Interosseous Nerve Syndrome

Isolated paresis or paralysis of the anterior interosseous nerve gained modern acceptance following the report of Kiloh and Nevin in 1952 and is often referred to as the Kiloh-Nevin syndrome.⁹¹ It was perhaps originally described by Tinel in 1918,¹⁸⁶ and a number of authors have cited case reports or small series.^{48,99,111,151,148,162,167} Several larger series have recently been reported.^{156,159,166} Both complete and incomplete presentations have been described.⁷⁶

The cause of this problem may be an acute demyelination episode similar to those seen in the brachial plexus as in Parsonage-Turner syndrome or brachial plexitis.^{142,199} An initial period of nonoperative therapy is therefore warranted, to allow time for improvement of symptoms which would be characteristic of Parsonage-Turner syndrome, or the development of other neurologic findings, which might suggest another diagnosis.

Symptoms Commonly, a deep unremitting pain in the proximal forearm initiates the symptoms, which subside within 8 to 12 hours. The patient may then note a lack of dexterity or weakness of pinch that fails to resolve. If the patient was seen previously, diagnoses from tendinous rupture to multiple sclerosis may have been

entertained, particularly if the onset has been insidiously painless. Spontaneous improvement has been reported in some instances in which the patient had an apparently demyelinating etiology.^{58,195}

Physical Findings In complete cases, the findings are those associated with denervation of the classic distribution of the anterior interosseous nerve to the flexor pollicis longus, the index and middle finger flexor digitorum profundus, and the pronator quadratus. The stance of the thumb and index finger when attempting to pinch is characteristic (Fig. 80-23). Because of an inability to flex the distal joints, they are approximated in hyperextension along their distal phalanges. Pinch is weak, and manipulative facility is impaired. Isolated testing shows marked weakness or paralysis of the flexor pollicis longus and index finger flexor digitorum profundus (see Fig. 80-23B). The middle finger is usually less affected, depending on the relative contributions of the ulnar and median nerves to the profundi. Thumb to little finger opposition is unaffected. In incomplete cases, usually the flexor pollicis longus or the index finger profundus is affected. Incomplete lesions are frequently misdiagnosed as a tendon rupture and electrodiagnosis is especially helpful both in establishing neural dysfunction but also excluding polyneuropathy or wider median nerve dysfunction. They may occur spontaneously or follow fracture fixation.⁸⁸

Special care must be taken in all cases to rule out Parsonage-Turner syndrome. As with posterior interos-

seous nerve palsy, patients with anterior interosseous nerve syndrome may demonstrate subtle features suggestive of an inflammatory type disorder. Inciting events may be blamed for causation of the neurologic deficit, when in fact they may be "innocent bystanders." Other findings elicited on history (periscapular pain), clinical examination (shoulder muscle weakness), electrophysiologic testing (patchy fibrillations in muscles beyond the anterior interosseous nerve territory) and MRI studies (denervation in other muscles) may be helpful in identifying more widespread neural involvement. These features should be sought out which would be suggestive of a diagnosis of Parsonage-Turner syndrome.

Weakness in pronation is seldom a recognizable complaint of the patient because it is submerged in the general discomforts of weakness and clumsiness of the extremity. The pronator quadratus is tested by placing both elbows against the side and resisting pronation with the elbow flexed to a right angle. This effectively reduces the strength contribution of the pronator teres humeral head, allowing relative isolated testing of the pronator quadratus.

Tenderness over the proximal forearm is usually absent, and sensory disturbance is not apparent. EMG findings of fibrillations are present in the affected muscles. In one study, all patients had electrical changes; the pronator quadratus was most consistently affected.¹⁵⁹

Nerve variations such as the Martin-Gruber anastomosis may occur between the anterior interosseous nerve and the ulnar nerve, as well as between the

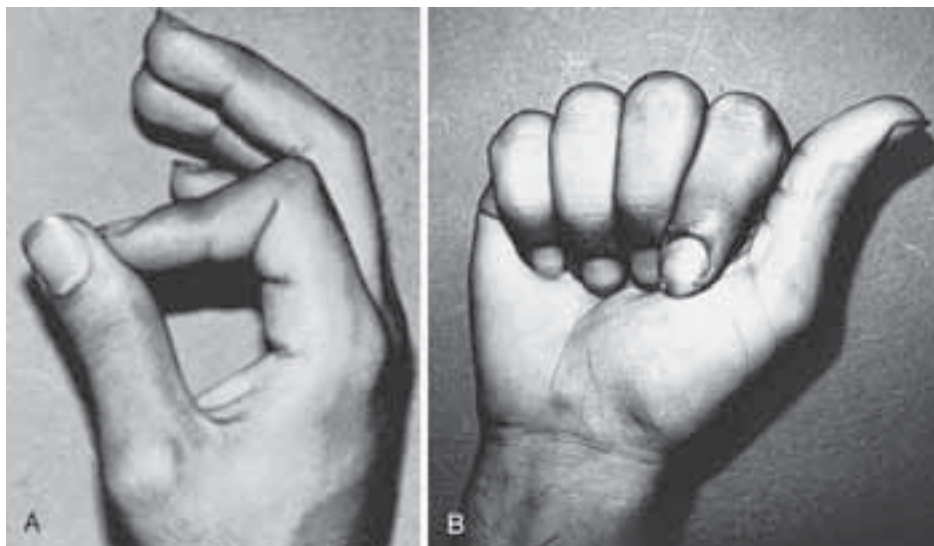


FIGURE 80-23 **A**, Anterior interosseous nerve syndrome demonstrating the characteristic pinch attitude. **B**, The patient is unable to flex the terminal phalanx of the thumb or index finger. Sensation is intact. There is some weakness of the flexor digitorum profundus of the middle finger, which in this patient is supplied and motored enough to flex the distal joint through a branch of the ulnar nerve in the proximal forearm. (**A** from Spinner, M.: *Injuries to the Major Branches of Peripheral Nerves of the Forearm*, 2nd ed. Philadelphia. W. B. Saunders Co., 1978.)

median and ulnar nerves. These fibers are likely to innervate intrinsic muscle on the radial aspect of the hand. Therefore, it is necessary to differentiate partial apparent ulnar paralysis from the anterior interosseous nerve syndrome.

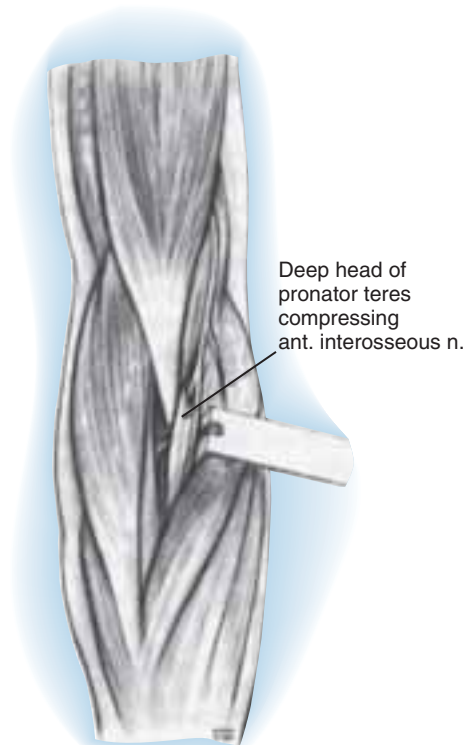
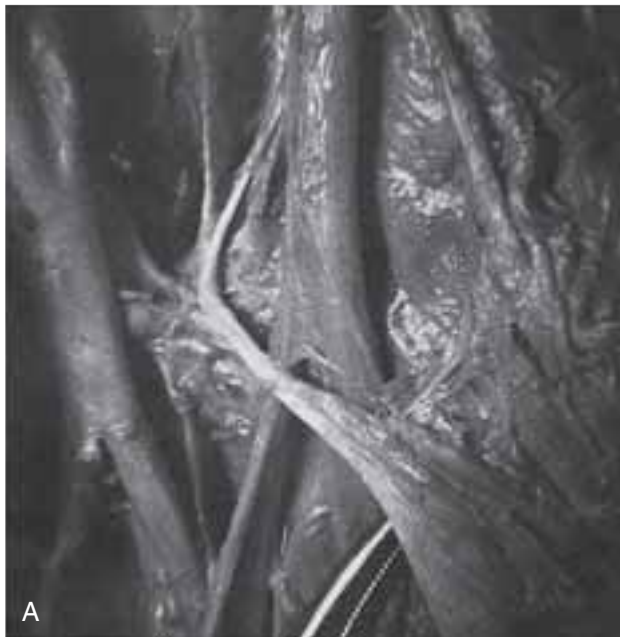
An observation period of at least 6 months is indicated in most instances before surgical exploration is considered.

Operative Findings The operative findings reported are similar to those described earlier for the pronator syndrome. The usual finding is a constriction due to the tendon or origin of the ulnar head of the pronator teres across the posterolateral aspect of the anterior interosseous nerve as it separates from the median nerve (Fig. 80-24). There may be a fibrous reaction in the area that is probably associated with the acute episode of pain, suggesting a localized vascular reaction such as thrombosis or ischemia.

Preferred Treatment for Exposure of the Median Nerve

The spectrum of median nerve problems at the elbow suggests that the initial incision should be adaptable to unsuspected findings. A longitudinally oriented incision is curved at the antecubital crease or zigzagged to increase exposure and decrease tension on the scar line during healing. The medial antebrachial cutaneous nerve should be sought and protected. Major veins are retracted after ligating communicating veins. The plane over the brachial and antebrachial fascia is cleared to observe the effect of the lacertus fibrosus on passive pronation. A deep indentation of the flexor-pronator group is significant.

If the pronator teres is prolonged proximally, the muscle often covers the median nerve above the elbow. The medial intermuscular septum and the brachial fascia tend to envelop the nerve in this situation. A true ligament of Struthers may be present if there is a supracon-



Kiloh Nevin syndrome
ant. interosseous n. compression
B

FIGURE 80-24 Compression of the anterior interosseous nerve can occur at its entrance to the pronator muscle near its origin. **A**, Cadaveric specimen demonstrates a thin tendinous origin of the deep head of the pronator teres as it crosses over the take-off of the anterior interosseous nerve branch from the median nerve. **B**, Artistic rendition. (**A** from Spinner, M.: *Injuries to the Major Branches of Peripheral Nerves of the Forearm*, 2nd ed. Philadelphia, W. B. Saunders Co., 1978.)

dylar process. Although such a diagnosis is usually made radiographically, palpation of the lower humerus through this incision may indicate an unsuspected supracondylar process.

The median nerve is identified proximal to the lacertus fibrosus in the distal arm. The lacertus is incised, and the median nerve is traced distally. The tendinous origin of the pronator teres should be detached. Arches over the pronator teres and the flexor digitorum superficialis are released. The plane between the pronator teres and the flexor carpi radialis is used. This plane can be identified distally and the median nerve can then be traced in a distal to proximal direction.

All of these potential sites of entrapment should be explored, because multiple sites of entrapment could be present. It may be important to extend the incision proximally in certain instances; hence, draping to the axilla and the use of a sterile tourniquet are wise precautions.

CUTANEOUS NERVES

Lateral Antebrachial Nerve

Compression neuropathy of the lateral antebrachial cutaneous nerve is a recently recognized syndrome.^{9,50,50,65,145} This cutaneous branch may also be injured at surgery or with injections.²⁰¹

Relevant Anatomy The musculocutaneous nerve, after supplying the coracobrachialis, biceps, and brachialis muscles, continues in the interval between the last two muscles as a sensory nerve to supply the skin over the anterolateral aspect of the forearm, often as far as the thenar eminence. It emerges from beneath the biceps tendon laterally and penetrates the brachial fascia just above the elbow crease to course down the forearm (Fig. 80-25).

Clinical Findings Bassett and Nunley describe both acute and chronic problems.⁹ A distinct mechanism of injury consisting of elbow hyperextension and pronation or resisted elbow flexion and pronation was elicited from their patients; presumably, the nerve was compressed between the biceps tendon and the brachialis fascia because both the nerve and the tendon were rendered taut by the forearm position. Burning dysesthesia in the distribution of the nerve is seen acutely. In chronic phases, the patient complains of a vague discomfort in the forearm with some dysesthetic qualities that are sometimes made worse by supinopronatory activities with the elbow extended.

On physical examination, a dysesthetic area on the anterolateral aspect of the forearm can be elicited by gently stroking across the skin transversely with a blunt point. Tenderness to direct pressure on the lateral aspect

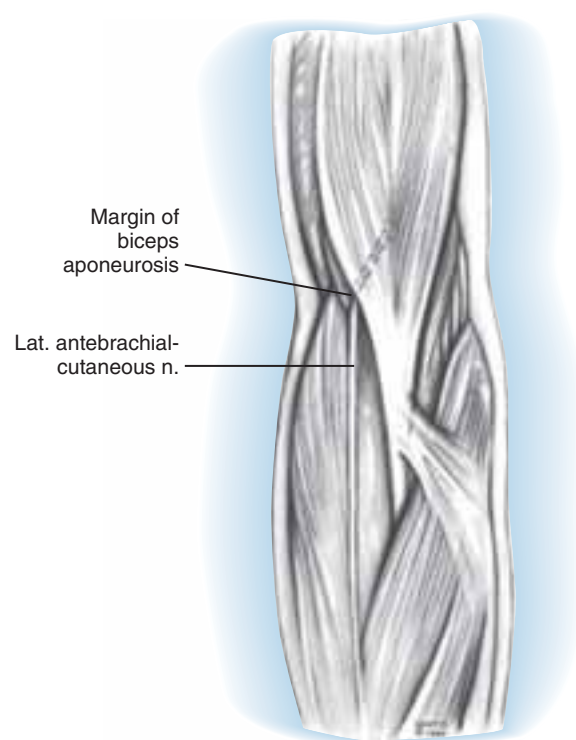


FIGURE 80-25 The lateral antebrachial cutaneous nerve has been reported to be compressed at the lateral margin of the biceps aponeurosis at the level of the lateral epicondyle.

of the bicipital tendon just proximal to the elbow crease is characteristic¹²⁷; loss of extension and pronation is often exhibited with this maneuver. The sensory action potential may exhibit a prolonged latency or diminished amplitude.⁵⁰

Treatment For the acute injury, rest, splinting, avoidance of extension-pronation, and anti-inflammatory medication are indicated. Corticosteroidal injections at the area of tenderness may help if exacerbation occurs. In chronic syndromes or those failing to respond to nonoperative measures, surgical decompression is appropriate. Under tourniquet control, a zigzag incision across the lateral aspect of the elbow crease allows exposure of the lateral antebrachial nerve. The site of compression usually occurs where the nerve emerges beneath the bicipital tendon. A tight band of antebrachial fascia at the elbow crease has been noted to alter the course of the nerve to an acute angle. Release of the brachial fascia and excision of a triangular portion of the bicipital tendon at the point of impingement is recommended. Obliteration of vascular markings at the site of compression may be noted. A neuroma, if present, can be excised and allowed to retract.

Results Symptoms may subside after an acute episode, but the nerve thereafter is apparently more susceptible to further irritation. Surgical decompression can often produce relief of pain, improvement in sensibility, and restoration of motion.

Medial Antebrachial Cutaneous Nerve

The posterior branch of the medial antebrachial cutaneous nerve has received some attention because of its course near the medial epicondyle. This has obvious clinical significance. Neuromata occur relatively frequently after ulnar nerve surgery⁵⁸ but may also occur following treatment of medial epicondylitis.¹⁵⁰ A recent anatomic study¹⁴⁷ describes the course of this cutaneous nerve and its variations. Rare cases of compressive lesions have also been reported.^{21,160} Patients present with sensory disturbance in the posteromedial forearm or pain at the medial aspect of the elbow or both.

Posterior Antebrachial Cutaneous Nerve

Nerve lesions of the posterior antebrachial cutaneous branch (a branch of the radial nerve at or near the spiral groove) do occur. Patients may present with isolated sensory abnormalities in the dorsolateral forearm or lateral elbow pain, or both. Several cases^{22,36,42} have been reported, occurring either spontaneously or following surgery. The nerve emerges from the lateral triceps and has a variable relationship with the lateral intermuscular septum. It then courses over the brachioradialis near the lateral epicondyle. Its course makes it particularly vulnerable in surgery for lateral epicondylitis or posterior interosseous nerve releases, and even following humeral fracture reduction and fixation, demonstrating the nerve's vulnerability more proximally. Excision of the neuroma or decompression of the nerve branch can relieve the symptoms.

References

1. Abe, M., Ishizu, T., Okamoto, M., and Onomura, T.: Tardy ulnar nerve palsy caused by cubitus varus deformity. *J. Hand Surg.* 20A:5, 1995.
2. Agnew, D. H.: Bursal tumor producing loss of power of forearm. *Am. J. Med. Sci.* 46:404, 1863.
3. Al-Qattan, M. M.: Gantzer's muscle. An anatomical study of the accessory head of the flexor pollicis longus muscle. *J. Hand Surg.* 21B:269, 1996.
4. Amadio, P. C.: Anatomical basis for a technique of ulnar nerve transposition. *Surg. Radiol. Anat.* 8:155, 1986.
5. Amadio, P. C.: Operations I no longer do (well, hardly ever). *J. Hand Surg.* 27B:155, 2002.
6. Apfelberg, D. B., and Larson, S. J.: Dynamic anatomy of the ulnar nerve at the elbow. *Plast. Reconstr. Surg.* 51:76, 1973.
7. Barber, K. W., Jr., Bianco, A. J., Jr., Soule, E. H., and MacCarty, C. S.: Benign extramural soft tissue tumors of the extremities causing compression of nerves. *J. Bone Joint Surg.* 44A:98, 1982.
8. Bartels, R. H., Verhagen, W. I., van der Wilt, G. J., Meulstee, J., van Rossum, L. G., and Grotenhuis, J. A.: Prospective randomized controlled study comparing simple decompression versus anterior subcutaneous transposition for idiopathic neuropathy of the ulnar nerve at the elbow: Part 1. *Neurosurgery* 56:522, 2005.
9. Bassett, F. H., and Nunley, J. A.: Compression of the musculocutaneous nerve at the elbow. *J. Bone Joint Surg.* 64A:1050, 1982.
10. Biggs, M., and Curtis, J. A.: Randomized, prospective study comparing ulnar neurolysis in situ with submuscular transposition. *Neurosurgery* 58:296, 2006.
11. Bowen, T. L., and Stone, K. H.: Posterior interosseous nerve paralysis caused by a ganglion at the elbow. *J. Bone Joint Surg.* 48B:774, 1966.
12. Boyes, J. H.: *Bunnell's Surgery of the Hand*, 5th ed. Philadelphia, J.B. Lippincott Co., 1970, p. 418.
13. Braun, R. M., and Spinner, R. J.: Spontaneous bilateral median nerve compression in the distal arm. *J. Hand Surg.* 16A:244, 1991.
14. Brooks, D. M.: Nerve compression by simple ganglia. *J. Bone Joint Surg.* 34B:391, 1952.
15. Bryan, F. S., Miller, L. S., and Panijaganond, P.: Spontaneous paralysis of the posterior interosseous nerve: A case report and review of the literature. *Clin. Orthop. Relat. Res.* 80:9, 1971.
16. Buchthal, F., Rosenflack, A., and Trojaborg, W.: Electrophysiological findings in entrapment of the median nerve at wrist and elbow. *J. Neurol. Neurosurg. Psychiatry.* 37:340, 1974.
17. Busa, R., Adani, R., Marcuzzi, A., and Caroli, A.: Acute posterior interosseous nerve palsy caused by a synovial haemangioma of the elbow joint. *J. Hand Surg.* 20B:652, 1995.
18. Campbell, C. S., and Wulf, R. F.: Lipoma producing a lesion of the deep branch of the radial nerve. *J. Neurosurg.* 11:310, 1954.
19. Capener, N.: Posterior interosseous nerve lesions. *Proceedings of the Second Hand Club.* *J. Bone Joint Surg.* 46B:361, 1964.
20. Capener, N.: The vulnerability of the posterior interosseous nerve of the forearm. *J. Bone Joint Surg.* 48B:770, 1966.
21. Chang, C. W., and Oh, S. J.: Medial antebrachial cutaneous neuropathy: Case report. *Electromyogr. Clin. Neurophys.* 28:3, 1988.
22. Chang, C. W., and Oh, S. J.: Posterior antebrachial cutaneous neuropathy. Case report. *Electromyogr. Clin. Neurophysiol.* 30:3, 1990.
23. Childress, H. M.: Recurrent ulnar-nerve dislocation at the elbow. *Clin. Orthop. Relat. Res.* 108:168, 1975.
24. Clark, C. B.: Cubital tunnel syndrome. *J. A. M. A.* 241:801, 1979.
25. Cohen, B. E.: Simultaneous posterior and anterior interosseous nerve syndromes. *J. Hand Surg.* 7:398, 1982.
26. Comtet, J. J., and Chambaud, D.: Paralysie "spontanée" du nerf inter-osseux posterier par lesion inhabituelle. Deux observations. *Rev. Chir. Orthop.* 61:533, 1975.

27. Comtet, J. J., Chambaud, D., and Genety, J.: La compression de la branche posterier du nerf radial. Une etiologie meconnue de certaines paralysies et de certaines spicondylalgies rebelles. *Nouv. Presse Med.* 5:1111, 1976.
28. Craven, P. R., Jr., and Green, D. P.: Cubital tunnel syndrome. *J. Bone Joint Surg.* 62A:986, 1980.
29. Dahners, L. E., and Wood, F. M.: Anconeus epitrochlearis, a rare cause of cubital tunnel syndrome: a case report. *J. Hand Surg.* 9A:579, 1984.
30. Davidson, J. J., Bassett, F. H. III, and Nunley, J. A.: Musculocutaneous nerve entrapment revisited. *J. Shoulder Elbow Surg.* 7:250, 1998.
31. Davies, F., and Laird, M.: The supinator muscle and the deep radial (posterior interosseous) nerve. *Anat. Rec.* 101:243, 1948.
32. Dawson, D. M., Hallett, M., and Millender, L. H.: *Entrapment Neuropathies*, 2nd ed. Boston, Little, Brown & Co., 1990.
33. Dellon, A. L.: Techniques for successful management of ulnar nerve entrapment at the elbow. *Neurosurg. Clin. North Am.* 2:57, 1991.
34. Dellon, A. L., and Coert, J. H.: Results of the musculofascial lengthening technique for submuscular transposition of the ulnar nerve at the elbow. *J. Bone Joint Surg.* 85A:1514, 2003.
35. Dellon, A. L., and Coert, J. H.: Results of the musculofascial lengthening technique for submuscular transposition of the ulnar nerve at the elbow. *J. Bone Joint Surg.* 86A(suppl 1 Pt 2):169, 2004.
36. Dellon, A. L., Kim, J., and Ducic, I.: Painful neuroma of the posterior cutaneous nerve of the forearm after surgery for lateral humeral epicondylitis. *J. Hand Surg.* 29A:387, 2004.
37. Dellon, A. L., and Mackinnon, S. E.: Radial-sensory nerve entrapment in the forearm. *J. Hand Surg.* 11A:199, 1986.
38. Dellon, A. L., and Mackinnon, S. E.: Injury to the medial antebrachial cutaneous nerve during cubital tunnel surgery. *J. Hand Surg.* 10B:33, 1985.
39. Dellon, A. L., and Mackinnon, S. E.: Musculoaponeurotic variations along the course of the median nerve in the proximal forearm. *J. Hand Surg.* 12B:359, 1987.
40. Dennny-Brown, D., and Brenner, C.: Paralysis of nerve induced by direct pressure and by tourniquet. *Arch. Neurol. Psychiatry* 51:1, 1944.
41. Dharapak, C., and Nimberg, G. A.: Posterior interosseous nerve compression. Report of a case caused by traumatic aneurysm. *Clin. Orthop.* 101:225, 1974.
42. Doyle, J. J., and David, W. S.: Posterior antebrachial cutaneous neuropathy associated with lateral elbow pain. *Muscle Nerve* 16:1417, 1993.
43. Dreyfuss, U., and Kessler, I.: Snapping elbow due to dislocation of the medial head of the triceps. A report of two cases. *J. Bone Joint Surg.* 60B:56, 1978.
44. Eaton, R. G., Crowe, J. F., and Parkes, J. C., III: Anterior transposition of the ulnar nerve using a non-compressing fasciadermal sling. *J. Bone Joint Surg.* 62A:820, 1980.
45. Erhlich, G. E.: Antecubital cysts in rheumatoid arthritis: a corollary to popliteal (Baker's) cysts. *J. Bone Joint Surg.* 54A:165, 1972.
46. Escobar, P. L.: Short segment stimulations in ulnar nerve lesions around elbow. *Orthop. Rev.* 12:65, 1983.
47. Eversmann, W. W., Jr.: Entrapment and compression neuropathies. In Green, D. P. (ed.): *Operative Hand Surgery*, 2nd ed. New York, Churchill Livingstone, 1988, p. 1423.
48. Farber, J. S., and Bryan, R. S.: The anterior interosseous nerve syndrome. *J. Bone Joint Surg.* 50A:521, 1968.
49. Feindel, W., and Stratford, J.: The role of the cubital tunnel in tardy ulnar palsy. *Can. J. Surg.* 1:296, 1958.
50. Felsenthal, G., Mondell, D. L., Reischer, M. A., and Mack, R. H.: Forearm pain secondary to compression syndrome of the lateral cutaneous nerve of the forearm. *Arch. Phys. Med. Rehabil.* 65:139, 1984.
51. Flory, P. J., and Berger, A.: Die akzessorische brachialissehneselten Ursache des Pronator Teres-Syndroms. *Handchir.* 17:270, 1985.
52. Foster, R. J., and Edshage, S.: Factors related to outcome of surgically managed compressive ulnar neuropathy at the elbow level. *J. Hand Surg.* 6:181, 1981.
53. Freundlich, B. D., and Spinner, M.: Nerve compression syndrome in derangements of the proximal and distal radioulnar joints. *Bull. Hosp. Joint Dis.* 19:38, 1968.
54. Frohse, F., and Frankel, M.: Die Muskeln des menschlichen Armes. In *Bardelenbens Handbuch der Anatomie des Menschlichen*. Jena, Fisher, 1908.
55. Froimson, A. I., and Zahrawi, F.: Treatment of compression neuropathy of the ulnar nerve at the elbow by epicondylectomy and neurolysis. *J. Hand Surg.* 5:391, 1980.
56. Fujioka, H., Nakabayashi, Y., Hirata, S., Go, G., Nishi, S., and Mizuno, K.: Analysis of tardy ulnar nerve palsy associated with cubitus varus deformity after a supracondylar fracture of the humerus: a report of four cases. *J. Orthop. Trauma* 9:435, 1995.
57. Gabel, G. T., and Amadio, P. C.: Reoperation for failed decompression of the ulnar nerve in the region of the elbow. *J. Bone Joint Surg.* 72A:213, 1990.
58. Gaitzsch, G., and Chamay, A.: Paralytic brachial neuritis or Parsonage-Turner syndrome anterior interosseous nerve involvement. Report of three cases. *Ann. Chir. Main* 5:288, 1986.
59. Gantzers, C. F. L.: *De Musculorum Varietates*, thesis. Berliani, J. F. Starckie, 1815.
60. Gelberman, R. H., Yamaguchi, K., Hollstien, S. B., Winn, S. S., Heidenreich, F. P., Jr., Bindra, R. R., Hsieh, P., and Silva, M. J.: Changes in interstitial pressure and cross-sectional area of the cubital tunnel of the ulnar nerve with flexion of the elbow. An experimental study in human cadavera. *J. Bone Joint Surg.* 80A:492, 1998.
61. Gervasio, O., Gambardella, G., Zaccone, C., and Branca, D.: Simple decompression versus anterior submuscular transposition of the ulnar nerve in severe cubital tunnel syndrome: a prospective randomized study. *Neurosurgery* 56:108, 2005.
62. Gessini, L., Jandolo, B., and Pietrangeli, A.: Entrapment neuropathies of the median nerve at and above the elbow. *Surg. Neurol.* 19:112, 1983.
63. Geutjens, G. G., Langstaff, R. J., Smith, N. J., Jefferson, D., Howell, C. J., and Barton, N. J.: Medial epicondylectomy or ulnar nerve transposition for ulnar neuropathy at the elbow? *J. Bone Joint Surg.* 78B:777, 1996.

64. Gilliatt, B. W., Ochoa, J., Rudge, P., and Neary, D.: The cause of nerve damage in acute compression. *Trans. Am. Neurol. Assoc.* 99:71, 1974.
65. Gillingham, B. L., and Mack, G. R.: Compression of the lateral antebrachial cutaneous nerve by the biceps tendon. *J. Shoulder Elbow Surg.* 5:330, 1996.
66. Goldman, S., Honet, J. C., Sobel, R., and Goldstein, A. S.: Posterior interosseous nerve palsy in the absence of trauma. *Arch. Neurol.* 21:435, 1969.
67. Graf, P., Hawe, W., and Biemer, E.: Gefäßversorgung des n. ulnaris nach Neurolyse im Ellenbogenbereich. *Handchir.* 18:204, 1986.
68. Gunther, S. F., DiPasquale, D., and Martin, R.: The internal anatomy of the median nerve in the region of the elbow. *J. Hand Surg.* 17A:648, 1992.
69. Harrelson, J. M., and Newman, M.: Hypertrophy of the flexor carpi ulnaris as a cause of ulnar-nerve compression in the distal part of the forearm. Case report. *J. Bone Joint Surg.* 57A:554, 1975.
70. Hartz, C. R., Linscheid, R. L., Gramse, R. R., and Daube, J. R.: Pronator teres syndrome: compressive neuropathy of the median nerve. *J. Bone Joint Surg.* 63A:885, 1981.
71. Hashizume, H., Inoue, H., Nagashima, K., and Hamaya, K.: Posterior interosseous nerve paralysis related to focal radial nerve constriction secondary to vasculitis. *J. Hand Surg.* 18B:757, 1993.
72. Hashizume, H., Nishida, K., Nanba, Y., Shigeyama, Y., Inoue, H., and Morito, Y.: Non-traumatic paralysis of the posterior interosseous nerve. *J. Bone Joint Surg.* 78B:771, 1996.
73. Hashizume, H., Nishida, K., Yamamoto, K., Hirooka, T., and Inoue, H.: Delayed posterior interosseous nerve palsy. *J. Hand Surg.* 20B:655, 1995.
74. Haussmann, P., and Patel, M. R.: Intraepineurial constriction of nerve fascicles in pronator syndrome and anterior interosseous nerve syndrome. *Orthop. Clin. North Am.* 27:339, 1996.
75. Haws, M., and Brown, R. E.: Bilateral snapping triceps tendon after bilateral ulnar nerve transposition for ulnar nerve subluxation. *Ann. Plast. Surg.* 34:550, 1995.
76. Hill, H. A., Howard, F. M., and Huffer, B. R.: The incomplete anterior interosseous nerve syndrome. *J. Hand Surg.* 10A:4, 1985.
77. Hirachi, K., Kato, H., Minami, A., Kasashima, T., and Kaneda, K.: Clinical features and management of posterior interosseous nerve palsy. *J. Hand Surg.* 23B:413, 1998.
78. Hobhouse, N., and Heald, C. B.: A case of posterior interosseous paralysis. *Br. Med. J.* 1:841, 1936.
79. Hoffmann, R., and Siemionow, M.: The endoscopic management of cubital tunnel syndrome. *J. Hand Surg.* 31B:23, 2006.
80. Hollinshead, W. H.: *Anatomy for Surgeons, Vol. 3, The Back and Limbs*, 3rd ed. New York, Harper and Row, 1982.
81. Jabaley, M. E., Wallace, W. H., and Heckler, F. R.: Internal topography of major nerves of the forearm and hand: a current view. *J. Hand Surg.* 5:1, 1980.
82. Jebson, P. J. L., and Engber, W. D.: Radial tunnel syndrome: long-term results of surgical decompression. *J. Hand Surg.* 22A:889, 1997.
83. Johnson, R. K., Spinner, M., and Shrewsbury, M. M.: Median nerve entrapment syndrome in the proximal forearm. *J. Hand Surg.* 4:48, 1979.
84. Jones, R. E.: Medial epicondylectomy for ulnar nerve compression syndrome at the elbow. *Clin. Orthop.* 139:174, 1979.
85. Kaempffe, F. A., and Farbach, J.: A modified surgical procedure for cubital tunnel syndrome: partial medial epicondylectomy. *J. Hand Surg.* 23A:492, 1998.
86. Kane, E., Kaplan, E. B., and Spinner, M.: Observations of the course of the ulnar nerve in the arm. *Ann. Chir.* 27:487, 1973.
87. Kaplan, E. B.: *Functional and Surgical Anatomy of the Hand*, 2nd ed. Philadelphia, J.B. Lippincott Co., 1965.
88. Keogh, P., Khan, H., Cooke, E., and McCoy, G.: Loss of flexor pollicis longus function after plating of the radius. *J. Hand Surg.* 22B:375, 1997.
89. Keret, D., and Porter, K. M.: Synovial cyst and ulnar nerve entrapment: a case report. *Clin. Orthop.* 188:215, 1984.
90. Khoo, D., Carmichael, S. W., and Spinner, R. J.: Ulnar nerve anatomy and compression. *Orthop. Clin. North Am.* 27:317, 1996.
91. Kiloh, L. G., and Nevin, S.: Isolated neuritis of the anterior interosseous nerve. *Br. Med. J.* 1:859, 1952.
92. Kopell, H. P., and Thompson, W. A. I.: Pronator syndrome. *N. Engl. J. Med.* 259:713, 1958.
93. Kopell, H. P., and Thompson, W. A.: *Peripheral Entrapment Neuropathies*. Baltimore, Williams & Wilkins, 1963.
94. Kotani, H., Miki, T., Senzoku, F., Nakagawa, Y., and Ueo, T.: Posterior interosseous nerve paralysis with multiple constrictions. *J. Hand Surg.* 20A:15, 1995.
95. Krishnan, K. G., Pinzer, T., and Schackert, G.: A novel endoscopic technique in treating single nerve entrapment syndromes with special attention to ulnar nerve transposition and tarsal tunnel release: clinical application. *Neurosurgery* 59(1 Suppl 1):ONS89, 2006.
96. Kuzynski, K.: Functional micro-anatomy of the peripheral nerve trunks. *Hand* 6:1, 1974.
97. Laha, R. K., Lunsford, L. D., and Dujovny, M.: Lacertus fibrosus compression of the median nerve. A case report. *J. Neurosurg.* 48:838, 1978.
98. Lahey, M. D., and Aulicino, P. L.: Anomalous muscles associated with compression neuropathies. *Orthop. Rev.* 15:19, 1986.
99. Lake, P. A.: Anterior interosseous nerve syndrome. *J. Neurosurg.* 41:306, 1974.
100. Learmonth, J. R.: A variation of the radial branch of the musculo-spiral nerve. *J. Anat.* 53:371, 1919.
101. Learmonth, J. R.: Technique for transplanting the ulnar nerve. *Surg. Gynecol. Obstet.* 75:792, 1942.
102. LeDouble, A. F.: *Traite des Variations du Systeme Musculaire de l'Homme*. Paris, Schleicher, 1897.
103. Leffert, R. D.: Anterior submuscular transposition of the ulnar nerves by the Learmonth technique. *J. Hand Surg.* 7:147, 1982.
104. Leffert, R. D., and Dorfman, H. D.: Antecubital cyst in rheumatoid arthritis. Surgical findings. *J. Bone Joint Surg.* 54A:1555, 1972.

105. Lichter, R. L., and Jacobsen, T.: Tardy palsy of the posterior interosseous nerve with a Monteggia fracture. *J. Bone Joint Surg.* 57A:124, 1975.
106. Lipscomb, P. R., and Burleson, R. J.: Vascular and neural complications in supracondylar fractures in children. *J. Bone Joint Surg.* 37A:487, 1955.
107. Lister, G. D., Belsole, R. B., and Kleinert, H. E.: The radial tunnel syndrome. *J. Hand Surg.* 4:52, 1979.
108. Lluch, A. L.: Ulnar nerve entrapment after anterior transposition at elbow. *N. Y. State J. Med.* 75:75, 1975.
109. Lundborg, G.: Ischemic nerve injury. Experimental studies on intraneural microvascular pathophysiology and nerve function in a limb subjected to temporary circulatory arrest. *Scand. J. Plast. Reconstr. Surg. [Suppl.]* 6:1, 1970.
110. Macnicol, M. F.: Extraneural pressures affecting the nerve at the elbow. *Hand* 14:5, 1982.
111. Maeda, K., Miura, T., Komada, T., and Chiba, A.: Anterior interosseous nerve paralysis. Report of 13 cases and review of Japanese literature. *Hand* 9:165, 1977.
112. Mangini, U.: Flexor pollicis longus muscle. Its morphology and clinical significance. *J. Bone Joint Surg.* 42A:467, 1960.
113. Mannerfelt, L.: Studies on the hand in ulnar nerve paralysis. A clinical-experimental investigation in normal and anomalous innervation. *Acta Orthop. Scand. Suppl.* 87:1966.
114. Marmor, L., Lawrence, J. F., and Dubois, E.: Posterior interosseous nerve paralysis due to rheumatoid arthritis. *J. Bone Joint Surg.* 49A:381, 1967.
115. Marquis, J. W., Bruwer, A. J., and Keith, H. M.: Suprcondyloid process of the humerus. *Proc. Staff Meeting Mayo Clin.* 37:691, 1957.
116. Marshall, S. C., and Murray, W. R.: Deep radial nerve palsy associated with rheumatoid arthritis. *Clin. Orthop. Relat. Res.* 103:157, 1974.
117. Martinelli, P., Gabellini, A. S., Poppi, M., Gallassi, R., and Pozzatti, E.: Pronator syndrome due to thickened bicipital aponeurosis. *J. Neurol. Neurosurg. Psychiatry* 45:181, 1982.
118. Mayer, J. H., and Mayfield, P. H.: Surgery of the posterior interosseous branch of the radial nerve. *Surg. Gynecol. Obstet.* 84:979, 1947.
119. Millender, L. H., Nalebuff, E. A., and Holdsworth, D. E.: Posterior interosseous nerve syndrome secondary to rheumatoid synovitis. *J. Bone Joint Surg.* 55A:753, 1973.
120. Miller, R. G.: Acute versus chronic compressive neuropathy. *Muscle Nerve* 7:427, 1984.
121. Morrey, B. F.: Reoperation for failed surgical treatment of refractory lateral epicondylitis. *J. Shoulder Elbow Surg.* 1:47, 1992.
122. Morris, A. H.: Irreducible Monteggia lesion with radial-nerve entrapment. *J. Bone Joint Surg.* 46A:608, 1964.
123. Morris, H. H., and Peters, B. H.: Pronator syndrome: Clinical and electrophysiological features in seven cases. *J. Neurol. Neurosurg. Psychiatry* 39:461, 1976.
124. Mowell, J. W.: Posterior interosseous nerve injury. *Int. Clin.* 2:188, 1921.
125. Mujadzic, M., Papanicolaou, G., Young, H., and Tsai, T. M.: Simultaneous surgical releases of ipsilateral pronator and carpal tunnel syndromes. *Plast. Reconstr. Surg.* 119:2141, 2007.
126. Mulholland, R. C.: Non-traumatic progressive paralysis of the posterior interosseous nerve. *J. Bone Joint Surg.* 48B:781, 1966.
127. Naam, N. H., and Massoud, H. A.: Painful entrapment of the lateral antebrachial cutaneous nerve at the elbow. *J. Hand Surg.* 29A:1148, 2004.
128. Nabhan, A., Ahlhelm, F., Kelm, J., Reith, W., Schwerdtfeger, K., and Steudel, W. I.: Simple decompression or subcutaneous anterior transposition of the ulnar nerve for cubital tunnel syndrome. *J. Hand Surg.* 30B:521, 2005.
129. Nagano, A., Shibata, K., Tokimura, H., Yamamoto, S., and Tajiri, Y.: Spontaneous anterior interosseous nerve palsy with hourglass-like fascicular constriction within the main trunk of the median nerve. *J. Hand Surg.* 21A:266, 1996.
130. Nakamura, I., and Hoshino, Y.: Extraneural hemangioma: a case report of acute cubital tunnel syndrome. *J. Hand Surg.* 21A:1097, 1997.
131. Nakano, K. K., Lundergan, C., and Okihira, M. M.: Anterior interosseous nerve syndromes. *Arch. Neurol.* 34:477, 1977.
132. Narakas, A. O.: The role of thoracic outlet syndrome in the double crush syndrome. *Ann. Chir. Main Memb. Super.* 9:331, 1990.
133. Nicolle, F. V., and Woolhouse, F. M.: Nerve compression syndromes of the upper limb. *J. Trauma* 5:315, 1965.
134. Nielsen, H. O.: Posterior interosseous nerve paralysis caused by fibrous band compression at the supinator muscle: a report of four cases. *Acta Orthop. Scand.* 47:304, 1976.
135. Nouhan, R., and Kleinert, J. M.: Ulnar nerve decompression by transposing the nerve and Z-lengthening the flexor-pronator origin. *J. Hand Surg.* 22A:127, 1997.
136. Ochoa, J.: Schwann cell and myelin changes caused by some toxic agents and trauma. *Proc. Soc. Med.* 67:3, 1976.
137. O'Driscoll, S. W., Horii, E., Carmichael, S. W., and Morrey, B. F.: The cubital tunnel and ulnar neuropathy. *J. Bone Joint Surg.* 73B:613, 1991.
138. Omer, G., Spinner, M., and Van Beek, A. L.: *Peripheral Nerve Problems*, 2nd ed. Philadelphia, W. B. Saunders Co., 1998.
139. Omer, G. E., and Spinner, M.: Peripheral nerve testing and suture techniques. *In American Academy of Orthopedic Surgeons, Vol. 24. Instructional Course Lectures.* St. Louis, C.V. Mosby Co., 1975, p. 122.
140. Osbourne, G.: Compression neuritis of the ulnar nerve at the elbow. *Hand* 2:10, 1970.
141. Osbourne, G.: The surgical treatment of tardy ulnar neuritis. *J. Bone Joint Surg.* 39B:782, 1957.
142. Parsonage, M. J., and Turner, J. W.: Neuralgic amyotrophy: The shoulder girdle syndrome. *Lancet* 1:973, 1948.
143. Patel, M. R., Bassini, L., and Magill, R.: Compression neuropathy of the lateral antebrachial cutaneous nerve. *Orthopedics* 14:173, 1991.
144. Porcellini, G., Paladini, P., Campi, F., and Merolla, G.: Arthroscopic neurolysis of the ulnar nerve at the elbow. *Chir. Organi Mov.* 90:191, 2005.

145. Pribyl, C. R.: Use of the medial intermuscular septum as a fascial sling during anterior transposition of the ulnar nerve. *J. Hand Surg.* 23A:500, 1998.
146. Pritchard, D. J., Linscheid, R. L., and Svien, H. J.: Intra-articular median nerve entrapment with dislocation of the elbow. *Clin. Orthop.* 90:100, 1973.
147. Race, C. M., and Saldana, M. J.: Anatomic course of the medial cutaneous nerves of the arm. *J. Hand Surg.* 16A:48, 1991.
148. Rask, M. R.: Anterior interosseous nerve entrapment: report of seven cases. *Clin. Orthop.* 142:176, 1979.
149. Reis, N. D.: Anomalous triceps tendon as a cause for snapping elbow and ulnar neuritis: a case report. *J. Hand Surg.* 5:361, 1980.
150. Richards, R. R., and Regan, W. D.: Medial epicondylitis caused by injury to the medial antebrachial cutaneous nerve: a case report. *Can. J. Surg.* 32:366, 1989.
151. Richmond, D. A.: Lipoma causing a posterior nerve lesion. *J. Bone Joint Surg.* 35B:83, 1953.
152. Riordan, D. C.: Radial nerve paralysis. *Orthop. Clin. N. Am.* 5:283, 1974.
153. Roles, N. C., and Maudsley, R. H.: Radial tunnel syndrome. Resistant tennis elbow as a nerve entrapment. *J. Bone Joint Surg.* 54B:499, 1972.
154. Rolfsen, L.: Snapping triceps tendon with ulnar neuritis. Report on a case. *Acta Orthop. Scand.* 41:74, 1970.
155. Salisbury, C. R.: The nerve to the extensor carpi radialis brevis. *J. Surg.* 26:95, 1938.
156. Schantz, K., and Riegels-Nielsen, P. R.: The anterior interosseous nerve syndrome. *J. Hand Surg.* 17B:510, 1992.
157. Seddon, H. J.: Three types of nerve injury. *Brain* 66:257, 1943.
158. Seradge, H., and Owen, H.: Cubital tunnel release with medial epicondylectomy factors influencing the outcome. *J. Hand Surg.* 23A:483, 1998.
159. Seror, P.: Anterior interosseous nerve lesions. Clinical and electrophysiological features. *J. Bone Joint Surg.* 78B:238, 1996.
160. Seror, P.: Forearm pain secondary to compression of the medial antebrachial cutaneous nerve at the elbow. *Arch. Phys. Med. Rehab.* 74:540, 1993.
161. Seyfarth, H.: Primary myoses in the m. pronator teres as cause of lesion of the n. medianus (the pronator syndrome). *Acta Psychiatr. Neurol. Scand. Suppl.* 74:251, 1951.
162. Sharrard, W. J. W.: Anterior interosseous neuritis. Report of a case. *J. Bone Joint Surg.* 50B:804, 1968.
163. Sharrard, W. J. W.: Posterior interosseous neuritis. *J. Bone Joint Surg.* 48B:777, 1966.
164. Siqueira, M. G., Martin, R. S.: The controversial arcade of Struthers. *Surg. Neurol.* 64(S1):17, 2005.
165. Somerville, E. W.: Pain in the upper limb. Proceedings of the British Orthopaedic Association. *J. Bone Joint Surg.* 45B:621, 1963.
166. Sood, M. K., and Burke, F. D.: Anterior interosseous nerve palsy. A review of 16 cases. *J. Hand Surg.* 22B:64, 1997.
167. Spinner, M.: The anterior interosseous nerve syndrome: with special attention to its variations. *J. Bone Joint Surg.* 52A:84, 1970.
168. Spinner, M.: The arcade of Frohse and its relationship to posterior interosseous nerve paralysis. *J. Bone Joint Surg.* 50B:809, 1968.
169. Spinner, M.: *Injuries to the Major Branches of Peripheral Nerves of the Forearm*, 2nd ed. Philadelphia, W. B. Saunders Co., 1978.
170. Spinner, M.: Nerve decompression. In Morrey, B. F. (ed.): *Master Techniques in Orthopedic Surgery. The Elbow*. New York, Raven Press, 1994.
171. Spinner, M., Freundlich, B. D., and Teicher, J.: Posterior interosseous nerve palsy as a complication of Monteggia fracture in children. *Clin. Orthop. Relat. Res.* 58:141, 1968.
172. Spinner, M., and Kaplan, E. B.: The relationship of the ulnar nerve to the medial intermuscular septum in the arm and its clinical significance. *Hand* 8:239, 1976.
173. Spinner, R. J., Berger, R. A., Dyck, P. J., Carmichael, S. W., and Nunley, J. A.: Isolated paralysis of the extensor digitorum communis associated with the posterior (Thompson) approach to the proximal radius. *J. Hand Surg.* 23A:135, 1998.
174. Spinner, R. J., Carmichael, S. W., and Spinner, M.: Partial median nerve entrapment in the distal arm because of an accessory bicipital aponeurosis. *J. Hand Surg.* 16A:236, 1991.
175. Spinner, R. J., and Goldner, R. D.: Snapping of the medial head of the triceps and recurrent dislocation of the ulnar nerve. Anatomical and dynamic factors. *J. Bone Joint Surg.* 80A:239, 1998.
176. Spinner, R. J., and Spinner, M.: Tardy posterior interosseous nerve palsy due to childhood osteomyelitis: a case report. *J. Hand Surg.* 22A:1049, 1997.
177. Sponseller, P. D., and Engber, W. D.: Double-entrapment radial tunnel syndrome. *J. Hand Surg.* 8A:420, 1983.
178. Steiger, R., and Vogelien, E.: Compression of the radial nerve by an occult ganglion. Three case reports. *J. Hand Surg.* 23B:420, 1998.
179. Strachan, J. C. H., and Ellis, B. W.: Vulnerability of the posterior interosseous nerve during radial head resection. *J. Bone Joint Surg.* 53B:320, 1971.
180. Struthers, J.: On a peculiarity of the humerus and humeral artery. *Monthly J. Med. Sci.* 8:264, 1848.
181. Suematsu, N., and Hirayama, T.: Posterior interosseous nerve palsy. *J. Hand Surg.* 23B:104, 1998.
182. Sunderland, S.: The innervation of the flexor digitorum profundus and lumbrical muscles. *Anat. Rec.* 83:317, 1945.
183. Sunderland, S.: Nerve lesions in the carpal tunnel syndrome. *J. Neurol. Neurosurg. Psychiatry* 39:615, 1976.
184. Sunderland, S.: *Nerves and Nerve Injuries*. Baltimore, Williams & Wilkins Co, 1968, p. 749.
185. Swiggett, R., and Ruby, L. K.: Median nerve compression neuropathy of the lacertus fibrosus: report of three cases. *J. Hand Surg.* 11A:700, 1986.
186. Tinel, J.: *Nerve Wounds*. New York, William Wood, 1918, p. 183.
187. Tsai, T. M., Chen, I. C., Majd, M. E., and Lim, B. H.: Cubital tunnel release with endoscopic assistance: results of a new technique. *J. Hand Surg.* 24A:21, 1999.

188. Uchida, Y., and Sugioka, Y.: Ulnar nerve palsy after supracondylar humerus fracture. *Acta Orthop. Scand.* 61:118, 1990.
189. Vanderpool, D. W., Chalmers, J., Lamb, D. W., and Whiston, T. B.: Peripheral compression lesions of the ulnar nerve. *J. Bone Joint Surg.* 50B:792, 1968.
190. Wadsworth, T. G.: The external compression syndrome of the ulnar nerve at the cubital tunnel. *Clin. Orthop. Relat. Res.* 124:189, 1977.
191. Wartenberg, R.: Cheiralgia paresthetica (isolierte Neuritis des Ramus superficialis nervi radialis). *Z. Neurol. Psychiatry* 141:145, 1932.
192. Watchmaker, G. P., Lee, G., and Mackinnon, S. E.: Intra-neural topography of the ulnar nerve in the cubital tunnel facilitates anterior transposition. *J. Hand Surg.* 19A:915, 1994.
193. Werner, C. O.: Lateral elbow pain and posterior interosseous nerve entrapment. *Acta Orthop. Scand.* [Suppl] 174:1, 1979.
194. Wertsch, J. J., and Melvin, J.: Median nerve anatomy and entrapment syndromes: A review. *Arch. Phys. Med. Rehabil.* 63:623, 1982.
195. Wertsch, J. J., Sanger, J. R., and Matloub, H. S.: Pseudo-anterior interosseous nerve syndrome. *Muscle Nerve* 8:68, 1985.
196. Whitely, W. H., and Alpers, B. J.: Posterior interosseous palsy with spontaneous neuroma formation. *Arch. Neurol.* 1:226, 1959.
197. Woltman, H. W., and Learmonth, J. R.: Progressive paralysis of the nervus interosseus dorsalis. *Brain* 57:25, 1934.
198. Wood, V. E., and Biondi, J.: Double-crush nerve compression in thoracic-outlet syndrome. *J. Bone Joint Surg.* 72A:85, 1990.
199. Wong, L., and Dellon, A. L.: Brachial neuritis presenting as anterior interosseous nerve compression—implications for diagnosis and treatment: a case report. *J. Hand Surg.* 22A:536, 1997.
200. Wu, K. T., Jordan, F. R., and Eckert, C.: Lipoma. A cause of paralysis of deep radial (posterior interosseous) nerve. Report of a case and review of the literature. *Surgery* 75:790, 1974.
201. Yuan, R. T., and Cohen, M. J.: Lateral antebrachial cutaneous nerve injury as a complication of phlebotomy. *Plast. Reconstr. Surg.* 76:299, 1985.
202. Zlowodzki, M., Chan, S., Bhandari, M., Kallianen, L., and Schubert, W.: Anterior transposition compared with simple decompression for treatment of cubital tunnel syndrome. A meta-analysis of randomized, controlled trials. *J. Bone Joint Surg.* 89:2591, 2007.