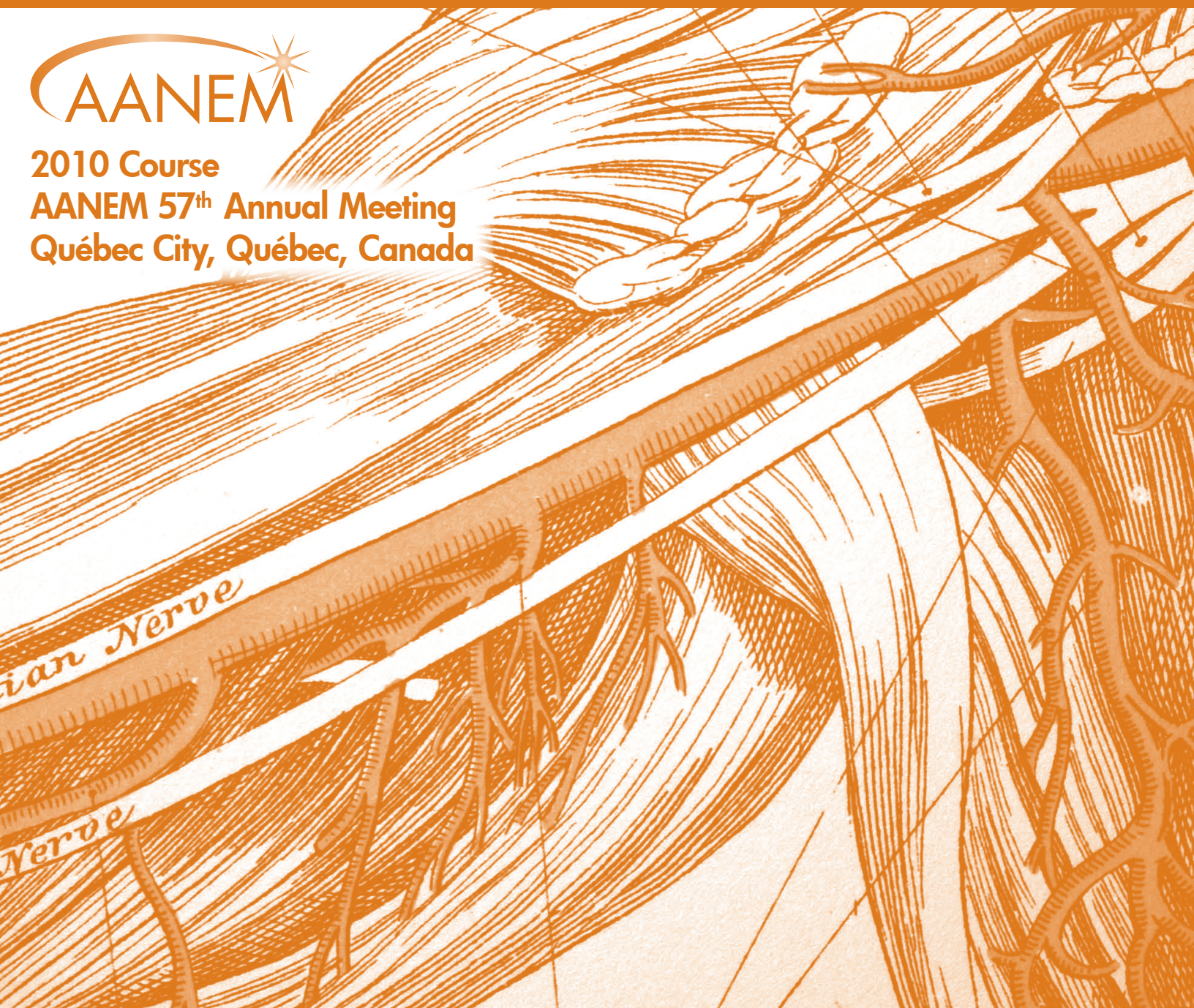


Neuroanatomy for Nerve Conduction Studies

AANEM

2010 Course
AANEM 57th Annual Meeting
Québec City, Québec, Canada



Neuroanatomy for Nerve Conduction Studies

Kimberley Butler, R.NCS.T, CNIM, R. EP T.

Jerry Morris, BS, MS, R.NCS.T.

Kevin R. Scott, MD, MA

Zach Simmons, MD

AANEM 57th Annual Meeting
Québec City, Québec, Canada



Copyright © October 2010
American Association of Neuromuscular
& Electrodiagnostic Medicine
2621 Superior Drive NW
Rochester, MN 55901

Neuroanatomy for Nerve Conduction Studies

Contents

CME Information	iv
Faculty	v
The Spinal Accessory Nerve and the Less Commonly Studied Nerves of the Limbs Zachary Simmons, MD	1
Ulnar and Radial Nerves Kevin R. Scott, MD	13
The Tibial and the Common Peroneal Nerves Kimberley B. Butler, R.NCS.T., R. EP T., CNIM	21
Median Nerves and Nerves of the Face Jerry Morris, MS, R.NCS.T.	27

Course Description

This course is designed to provide an introduction to anatomy of the major nerves used for nerve conduction studies, with emphasis on the surface landmarks used for the performance of such studies. Location and pathophysiology of common lesions of these nerves are reviewed, and electrodiagnostic methods for localization are discussed. This course is designed to be useful for technologists, but also useful and informative for physicians who perform their own nerve conduction studies, or who supervise technologists in the performance of such studies and who perform needle EMG examinations..

Intended Audience

This course is intended for Neurologists, Physiatrists, and others who practice neuromuscular, musculoskeletal, and electrodiagnostic medicine with the intent to improve the quality of medical care to patients with muscle and nerve disorders.

Learning Objectives

Upon conclusion of this program, participants should be able to:

- (1) describe anatomy as it pertains to common sites of entrapment.
- (2) improve their ability to perform nerve conduction studies.

Activity Profile

This enduring material activity is a reproduction of the printed materials from a course at the AANEM Annual Meeting (October 6-9, 2010). Physician participation in this activity consists of reading the manuscript(s) in the book and completing the clinical and CME questions.

Release Date: January 10, 2011

Expiration Date: January 10, 2014. Your request to receive *AMA PRA Category 1 Credits*[™] must be submitted on or before the credit expiration date.

Duration/Completion Time: 2 hours

Accreditation and Designation Statements

The American Association of Neuromuscular and Electrodiagnostic Medicine (AANEM) is accredited by the Accreditation Council for Continuing Medical Education to provide continuing medical education for physicians.

The AANEM designates this enduring material for a maximum of 2.0 *AMA PRA Category 1 Credit(s)*[™]. Physicians should claim only the credit commensurate with the extent of their participation in the activity.

Neuroanatomy for Nerve Conduction Studies

Faculty

Kimberley B. Butler, R.NCS.T, R. EP T., CNIM

Electroneurodiagnostic Technologist

Hartford Health Care

Willimantic, Connecticut

Ms. Butler has 30 years experience working in medicine. Originally a cardiac technologist and cardiac monitor technician, she has gone on to perform electroencephalograms (EEGs), long-term monitoring (LTM), intraoperative monitoring (IOM), evoked potentials (EPs), and now nerve conduction studies (NCSs). She has served on many boards and at one time was chair of the American Association of Electrodiagnostic Technologists (AAET) Examination Committee. She speaks and teaches regularly on board review courses, as well as a host of other topics. She has been published many times, including articles in *Muscle & Nerve*. Currently, she is branching into a new area, video urodynamics and pelvic floor neurophysiology.

Jerry Morris, MS, R.NCS.T.

Electrodiagnostic Technologist

Neurodiagnostic Laboratory

Willis-Knighton Medical Center

Shreveport, Louisiana

Mr. Morris has more than 25 years of experience teaching at various electrodiagnosis seminars and as a guest speaker for engagements across the United States and Canada. Topics have included neuromuscular junction disease, entrapment and generalized neuropathies, late responses (F waves and H reflexes), blink reflexes, myopathies, basic to advanced nerve conduction study (NCS) electrode placement, and anatomy and physiology of the nervous system. He is currently a member of the American Association of Neuromuscular & Electrodiagnostic Medicine (AANEM), the American Society of Electroneurodiagnostic Technologists (ASET), and the American Association of Electrodiagnostic Technologists (AAET). His past positions in these organizations include: AAET—past president, past member of the Board of Directors, and past member of the Examination Committee; ASET—past member of the Board of Directors, Program Chair of the 2009 Annual Meeting, and member of the Membership Committee. He is currently developing online an NCS course for ASET to be published in 2010. He was the ASET Theda Sannit Educational Award recipient for 2008.

Dr. Simmons is a consultant for Neuralstem, Inc. Any conflict of interest was resolved according to ACCME Standards.

All other authors/faculty have nothing to disclose.

Course Chair: Zachary Simmons, MD

The ideas and opinions expressed in this publication are solely those of the specific authors and do not necessarily represent those of the AANEM.

Kevin R. Scott, MD, MA

*Associate Professor of Neurology
Department of Neurology
Pennsylvania State College of Medicine
Milton S. Hershey Medical Center
Hershey, Pennsylvania*

Dr. Scott received his medical degree from Wake Forest University School of Medicine. He completed a neurology residency and a neurophysiology fellowship training at Pennsylvania State College of Medicine. He is currently an associate professor of neurology specializing in neuromuscular medicine and clinical neurophysiology. He is the program director of the Clinical Neurophysiology and Clinical Neuromuscular Fellowship programs at Pennsylvania State College of Medicine. Dr. Scott is an American Board of Electrodiagnostic Medicine Diplomate.

Zachary Simmons, MD

*Professor of Neurology
Department of Neurology
Pennsylvania State College of Medicine
Milton S. Hershey Medical Center
Hershey, Pennsylvania*

Dr. Simmons received his medical degree from the University of Florida, and then trained in neurology at the University of Iowa and in neuromuscular diseases and electromyography at the University of Michigan. He now serves as professor of neurology at Pennsylvania State Hershey Medical Center, where he is the director of the Neuromuscular Program and the Clinical Neurophysiology Laboratory. He founded and directs the Hershey Medical Center ALS Clinic. Active research programs under his supervision include studies of quality of life, cognitive function, and the development of evidence-based practice protocols for patients with amyotrophic lateral sclerosis. Dr. Simmons has served on the AANEM Training Program, Workshop, and Program Committees, has been chair of the ABEM Maintenance of Certification Committee, and currently is chair of the ABEM Examination Committee. Dr. Simmons is an American Board of Electrodiagnostic Medicine Diplomate.

Please be aware that some of the medical devices or pharmaceuticals discussed in this handout may not be cleared by the FDA or cleared by the FDA for the specific use described by the authors and are “off-label” (i.e., a use not described on the product’s label). “Off-label” devices or pharmaceuticals may be used if, in the judgement of the treating physician, such use is medically indicated to treat a patient’s condition. Information regarding the FDA clearance status of a particular device or pharmaceutical may be obtained by reading the product’s package labeling, by contacting a sales representative or legal counsel of the manufacturer of the device or pharmaceutical, or by contacting the FDA at 1-800-638-2041.

The Spinal Accessory Nerve and the Less Commonly Studied Nerves of the Limbs

Zachary Simmons, MD

Professor of Neurology
Department of Neurology
Pennsylvania State College of Medicine
Milton S. Hershey Medical Center
Hershey, Pennsylvania

INTRODUCTION

In addition to the major nerves of the upper extremity, lower extremity, and face, there are a number of less commonly studied nerves which are useful for localizing lesions within the brachial or lumbosacral plexus or for helping to distinguish plexopathies from radiculopathies, particularly when used in conjunction with the needle electromyography (EMG) examination. Electrodiagnostic (EDX) technologists and physicians should develop a basic understanding of the anatomy and EDX assessment of these nerves, with particular knowledge of causes and sites of injury, and the utility of EDX testing in the assessment of lesions of these nerves. The spinal accessory nerve, though not a “limb” nerve like the others presented in this course, is a nerve that is subject to injury, and for which EDX assessment can play an important role.

SPINAL ACCESSORY NERVE

Anatomy

The spinal accessory nerve is composed of cranial and spinal portions. The spinal portion originates from motor neurons at the C1-C5 levels. Rootlets from these levels proceed superiorly and fuse and then enter the skull through the foramen magnum. They join with the cranial portion of the nerve (fibers from cranial nerve X), and then exit the skull through the jugular foramen, splitting into the cranial and spinal divisions. The cranial portion joins the vagus nerve to innervate laryngeal and pharyngeal muscles. The spinal division descends into the posterior triangle of the neck (an area bounded by the posterior border of the sternocleidomastoid [SCM] muscle, the upper trapezius muscle, and the clavicle), passing deep to the superior portion of the SCM and innervating this muscle. After innervating

the SCM muscle, the nerve is superficial just posterior to the posterior border of the SCM muscle at the midpoint of that muscle, making it easily accessible to surface stimulation at this level. It then continues distally to innervate the trapezius muscle.

In the neck the spinal accessory nerve is joined by additional nerve fibers from C1-C4 through communication with the cervical plexus. These fibers preferentially innervate the trapezius muscle. These direct innervations from C1-C4 is the reason that there may be variable weakness of the trapezius muscle involving lesions of the spinal accessory nerve.

Lesions: Etiology

The lesion etiology usually is iatrogenic, due to surgical procedures in the posterior cervical triangle, most commonly lymph node biopsy. Tumor excision is the next most common cause, but there are many other possible etiologies, as listed in Table 1.^{1,2} Some cases are idiopathic.³

Lesions: Clinical Presentation

Most commonly the lesion is distal, resulting in atrophy and weakness of the trapezius muscle, with resulting shoulder drop. On examination, the patient demonstrates mild scapular winging (displacement of scapula laterally and slightly upward), especially when the arm is abducted. There is apparent weakness of shoulder abduction and external rotation as a result of poor shoulder fixation. Pain may occur due to traction on the brachial plexus as a result of the dropped shoulder. Less commonly, there is a more proximal lesion, resulting in weakness of the SCM muscle, leading to weakness of neck flexion and contralateral turning of the head and neck.

Table 1 Causes of spinal accessory neuropathy

Surgery
Lymph node biopsy
Tumor excision
Carotid endarterectomy
Face lift surgery
Radiation
Trauma
Stretch or contusion
Penetrating wounds such as lacerations
Bullet wounds
Compression
Shoulder strap
External tumors
Intrinsic nerve tumors
Weight lifting
Peripheral neuropathy
Leprosy
Mononeuritis multiplex
Idiopathic brachial plexopathy (neuralgic amyotrophy, Parsonage-Turner syndrome)
Idiopathic

Electrodiagnostic Testing⁴ (see Fig. 1)

Recording electrodes

- Active electrode (E1): over the belly of the trapezius muscle. That is, on the trapezius muscle approximately 5 cm lateral to the C7 spinous process on a line between this structure and the acromion.
- Reference electrode (E2): over the acromion process at the shoulder joint.

Stimulator

- Just posterior to the middle of the SCM muscle, midway between the mastoid process and the clavicle. The anode is positioned superior to the cathode.

Normal values

- Onset latency: 1.8-3.0 ms for a distance of 5.0-8.2 cm.
- Amplitude: compare to contralateral side.

Utility of Electrodiagnostic Testing

Nerve conduction studies (NCSs) of the spinal accessory nerve are used in conjunction with the needle EMG examination for two main purposes:

1. To distinguish a spinal accessory neuropathy from a mechanical injury to the shoulder joint. In a spinal accessory neuropathy, NCSs of the spinal accessory nerve will be abnormal. On needle examination, the trapezius muscle will demonstrate denervation, and the SCM muscle may demonstrate denervation, depending on the location of the lesion.

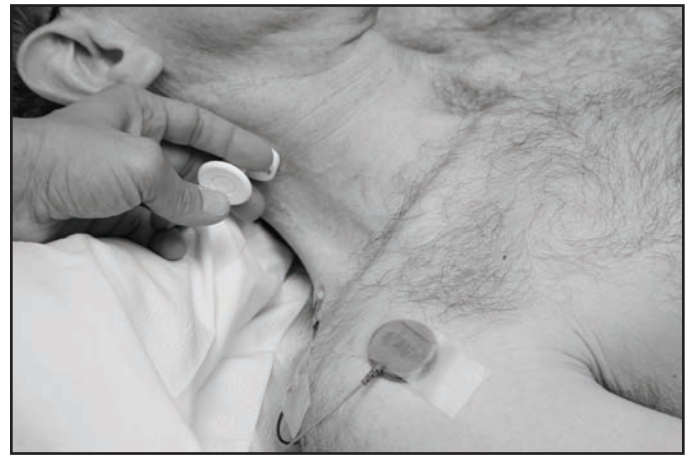

Figure 1 Nerve conduction study of the accessory nerve. Stimulation is just posterior to the sternocleidomastoid muscle.

2. To distinguish a spinal accessory neuropathy from a more widespread process affecting other nerves and muscles of the shoulder girdle. Because weakness of the trapezius muscle may destabilize the scapula and produce shoulder girdle weakness, a needle examination should be performed on the supraspinatus, infraspinatus, deltoid, rhomboid, and cervical paraspinal muscles.

THE BRACHIAL PLEXUS: THE KEY TO UNDERSTANDING UPPER EXTREMITY NEUROPATHIES

The upper extremity receives its entire motor and sensory innervation from the brachial plexus. The brachial plexus runs behind the clavicle and pectoral muscles as it courses from the neck into the arm. It is divided into:

- Roots (C5-T1)
- Trunks (upper, middle, and lower)
- Divisions (anterior and posterior from each trunk)
- Cords (medial, lateral, and posterior)
- Branches (nerves)

Brachial plexopathies have many etiologies. Trauma is the most common cause, but there are a wide range of nontraumatic causes of partial or complete brachial plexopathies (Table 2). A few deserve special mention. Radiation-induced brachial plexopathies are dose-related, often are painless, appear years after radiation, progress indolently, and are associated with myokymic discharges on needle EMG examination. Idiopathic brachial plexopathy (neuralgic amyotrophy, or Parsonage-Turner syndrome) is believed to have an autoimmune pathogenesis and often is preceded by a viral illness or immunization. The onset usually is intensely painful, followed by resolution of the pain in conjunction with the appearance of weakness that usually affects the plexus in a patchy distribution, often not following a clearly localizable pattern of trunk, division, or cord involvement. For example, the long thoracic nerve and anterior interosseous nerve are particularly likely to be affected.^{5,6} True neurogenic thoracic outlet syndrome is rare, and usually is caused by a fibrous band running from a rudimentary cervical rib to the first thoracic rib, entrapping the lower trunk of the brachial plexus.⁷

Table 2 Causes of Brachial Plexopathy

Trauma
Motor vehicle accidents
Bicycle accidents
Penetrating trauma—knife or gunshot injuries
Birth—traction of newborns during delivery
Invasion/compression by neoplasms
Pancoast tumor at the lung apex invading lower plexus
Metastatic tumor to lymph nodes
Direct nerve infiltration by lymphoma and leukemia
Tumors of the nerve sheath—schwannomas, neurofibromas
Compression by nonneoplastic structures
Hematoma
Aneurysm
Arteriovenous malformation
Radiation-induced plexopathy
Perioperative traction, particularly to lower plexus
Thoracic outlet syndrome producing lower plexopathy
Idiopathic

MEDIAL ANTEBRACHIAL CUTANEOUS NERVE

Anatomy

The medial antebrachial cutaneous (MAC) nerve arises from the medial cord of the brachial plexus, just proximal to the takeoff of the ulnar nerve. It is also called the medial cutaneous nerve of the forearm. It is strictly a sensory nerve, supplying sensation to the medial portion of the forearm.

Lesions: Etiology

MAC neuropathies generally arise from lesions that affect the lower trunk or medial cord of the brachial plexus. Although there are many causes of brachial plexopathy (Table 2), several are particularly likely to affect the lower trunk or medial cord: 1) trauma in which the arm and shoulder are pulled up; 2) invasion of the plexus by a Pancoast tumor at the lung apex; 3) stretch injuries of the lower plexus during chest surgery such as coronary artery bypass surgery; and 4) thoracic outlet syndrome entrapping the lower trunk of the plexus.

Lesions: Clinical Presentation

MAC neuropathy occurs in lesions of the medial cord or lower trunk of the brachial plexus. Medial cord lesions produce weakness of all ulnar nerve-innervated muscles and of C8- to T1-innervated muscles supplied by the median nerve. Clinically this leads to weakness of grip due to weakness of hand muscles and

inability to fully flex the fingers and thumb. There is sparing of the finger and wrist extensors, which are C8-innervated radial nerve muscles, because these arise from the posterior cord. Sensory loss occurs in the distribution of the medial arm (median brachial cutaneous nerve), medial forearm (medial antebrachial cutaneous nerve), and the medial hand and digits 4-5 (ulnar sensory nerve). The MAC nerve also is damaged in lesions of the lower trunk of the brachial plexus, which produces the deficits noted above, plus weakness of C8-innervated radial nerve muscles (extensor indicis proprius, extensor pollicis brevis, extensor carpi ulnaris), leading to partial weakness of thumb, finger, and wrist extension.

Electrodiagnostic Testing^{8,9} (see Fig. 2)

Recording electrodes

- Active electrode (E1): on the medial forearm, 12 cm distal to the stimulation site, on a line between the stimulation site and the ulnar aspect of the wrist.
- Reference electrode (E2): 3-4 cm distal to E1.

Stimulator

- In the medial portion of the antecubital fossa, midway between the tendon of the biceps brachii muscle and medial epicondyle.

Normal values (Preston)⁹

- Amplitude $\geq 5 \mu\text{V}$
- Conduction velocity $\geq 50 \text{ m/s}$
- Distal peak latency $\leq 3.2 \text{ ms}$

Normal values (Pribyl)⁸

- Amplitude $\geq 10 \mu\text{V}$
- Conduction velocity $\geq 41.7 \text{ m/s}$
- Distal peak latency mean 2.1 ms

Notes

- The nerve is superficial, and maximal responses usually can be obtained at low levels of stimulation.
- Side-to-side comparisons of the symptomatic and asymptomatic side are more useful than absolute values.

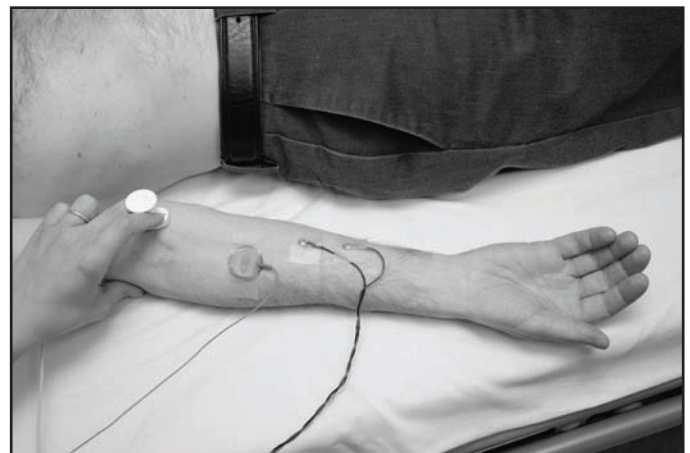

Figure 2 Nerve conduction study of the medial antebrachial cutaneous nerve. Stimulation is in the medial portion of the antecubital fossa.

Utility of Electrodiagnostic Testing

1. To distinguish a radiculopathy from a plexopathy: Radiculopathy, a lesion at the nerve root level, produces pain and numbness in a manner similar to that of brachial plexopathy, but the EDX findings are different. The MAC nerve can be used to distinguish a C8-T1 root lesion from a lesion of the medial cord or lower trunk of the brachial plexus. In radiculopathy, because the lesion occurs proximal to the dorsal root ganglion, sensory NCSs are normal, even in the distribution of the numbness. That is because the nerve is intact from the level of its cell body to the level of the skin. In plexopathies (or in peripheral nerve lesions), the lesion occurs at or distal to the dorsal root ganglion, so that the sensory NCSs are abnormal, because of axon loss from the level of the cell body to the skin. A needle examination of the paraspinal muscles can also help distinguish radiculopathy from plexopathy, because these are denervated in radiculopathy but not plexopathy.
2. To distinguish lower trunk plexopathy from medial cord brachial plexopathy: The MAC sensory response will be abnormal in a lower trunk or medial cord brachial plexus lesion. It cannot be used to distinguish one from the other. A needle examination is needed. In a lower trunk lesion, radial C8-innervated muscles (extensor indicis proprius, extensor pollicis brevis, extensor carpi ulnaris) will be involved.
3. To distinguish ulnar neuropathy from lower trunk or medial cord brachial plexopathy: The MAC nerve will be involved in the plexopathies, but spared in an isolated ulnar neuropathy.

MUSCULOCUTANEUS AND LATERAL ANTEBRACHIAL CUTANEUS NERVES

Anatomy

Once again, consider the brachial plexus. The musculocutaneous nerve arises from the lateral cord of the brachial plexus. It pierces the coracobrachialis muscle to run between the biceps and brachialis muscles. It innervates three muscles—the coracobrachialis, biceps brachii, and brachialis muscles—before continuing as a pure sensory nerve, the lateral antebrachial cutaneous (LAC) nerve, which supplies sensation to the lateral forearm.

Lesions: Etiology

Musculocutaneous nerve lesions most commonly are caused by trauma to the shoulder and upper arm, especially fractures of the proximal humerus from falls or sports injuries. In such cases, other nerves usually are damaged as well. For example, primary shoulder dislocations or fractures of the humeral neck may result in injuries to several nerves, including the axillary, suprascapular, radial, and musculocutaneous nerves.¹⁰ Other forms of trauma, including gunshot wounds and lacerations, also may produce musculocutaneous nerve lesions. Isolated nontraumatic lesions of the musculocutaneous nerve are rare, usually occurring as it passes through the coracobrachialis muscle. Causes include weightlifting or other vigorous

physical exercise,^{11,12} as well as surgery, pressure during sleep, and malpositioning during anesthesia.^{13,14} Rare cases of musculocutaneous nerve compression have included repeated carrying of items on the shoulder with the arm curled around the item, or osteochondroma of the humerus compressing the musculocutaneous nerve.⁹ The musculocutaneous nerve may also be involved in idiopathic brachial plexopathy.

Isolated injury of the LAC sensory nerve can occur. It may be entrapped, usually at the elbow, where it is compressed by the biceps aponeurosis and tendon against the brachialis muscle.^{13,15} Other causes of isolated LAC injury include hyperextension injury of the elbow, such as during sports, and antecubital phlebotomy.¹⁶

Lesions: Clinical Presentation

Patients with musculocutaneous neuropathies present with weakness of elbow flexion, an absent biceps reflex, and sensory alteration in the distribution of the LAC nerve (lateral forearm), whereas those with an isolated LAC neuropathy demonstrate the sensory alteration, but with normal muscle strength and reflexes. Patients in whom the LAC nerve is entrapped at the elbow present with pain in the anterolateral aspect of the elbow region which is worsened by pronation of the arm and extension at the elbow.^{13,15,17}

Musculocutaneous neuropathy occurs in lesions of the lateral cord or upper trunk of the brachial plexus. Lateral cord lesions produce weakness of all muscles innervated by the musculocutaneous nerve (see above) and of C6-C7 innervated median nerve muscles, producing weakness of forearm pronation (pronator teres) and wrist flexion (flexor carpi radialis). Sensory loss occurs in the LAC distribution and in the palmar aspect of the lateral hand and in digits 1-3 (median sensory nerve). Lesions of the upper trunk, which is formed from roots C5-C6, result in the deficits above, plus weakness of muscles not innervated by the lateral cord, including the deltoid muscle (innervated by the axillary nerve), the supraspinatus and infraspinatus muscles (innervated by the suprascapular nerve), and the brachioradialis muscle (innervated by the radial nerve). Sensory loss is found in the lateral upper arm (axillary nerve) and in the lateral hand and digits 1-3 (median and radial sensory branches) as well as the LAC sensory distribution. Biceps and brachioradialis reflexes are depressed or absent.

Electrodiagnostic Testing

Musculocutaneous nerve^{9,18} (see Fig. 3)

Recording electrodes

- Active electrode (E1): over the biceps, just distal to the midpoint of the muscle.
- Reference electrode (E2): distally to E1 in the antecubital fossa, over the biceps tendon.

Stimulator

- Erb's point.

Normal values (Preston)⁹

- Latency ≤ 5.7 ms at distance 23-29 cm, using calipers.

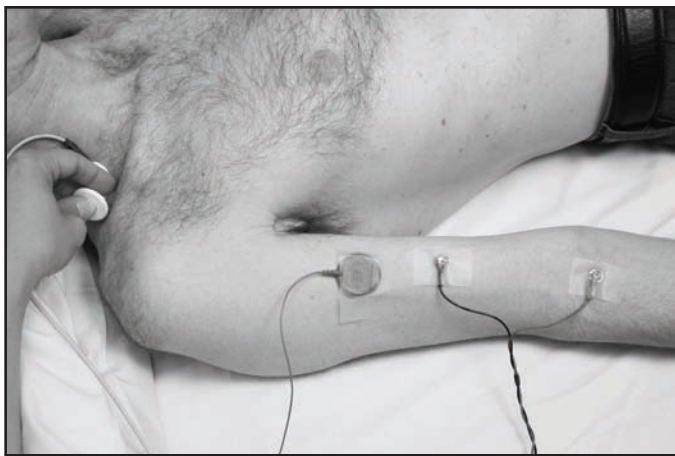


Figure 3 Nerve conduction study of the musculocutaneous nerve. Stimulation is at Erb's point.

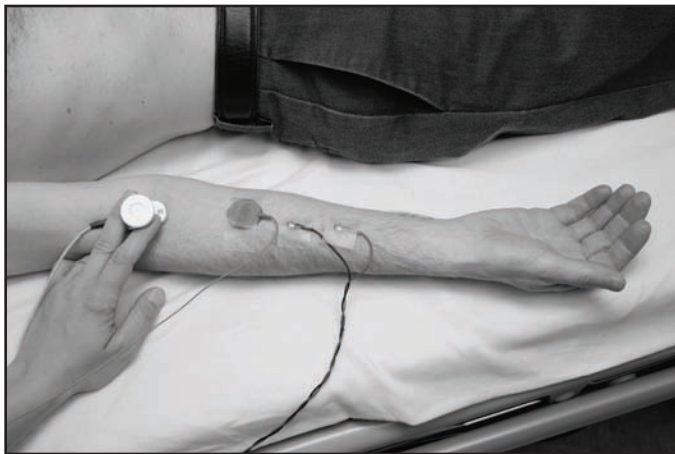

Figure 4 Nerve conduction study of the lateral antebrachial cutaneous nerve. Stimulation is in the lateral portion of the antecubital fossa.

Normal values (Kraft)¹⁸

- Latency ≤ 5.7 ms at distance of 23.5-29.0 cm (calipers), 28.0-41.5 cm (tape, arm at side), or 26.0-35.5 cm (tape, arm abducted 90 degrees)

Normal values (Oh)¹⁹

- Latency 5.5-6.7 ms at distance of 25-33 cm, using calipers.

Note

- Supramaximal stimulation is difficult to achieve. Best to compare symptomatic to asymptomatic side.

Lateral antebrachial cutaneous nerve⁹ (see Fig. 4)

Recording electrodes

- Active electrode (E1): on the lateral forearm, 12 cm distal to the stimulation site, on a line between the stimulation site and the radial pulse.
- Reference electrode (E2): 3-4 cm distal to E1.

Stimulator

- Lateral portion of the antecubital fossa, just lateral to the tendon of the biceps brachii muscle.

Normal values (Preston)⁹

- Amplitude ≥ 10 μ V
- Conduction velocity ≥ 55 m/s
- Peak latency ≤ 3.0 ms

Normal values (Spindler and Felsenthal)²⁰

- Amplitude ≥ 12 μ V
- Conduction velocity ≥ 57.8 m/s
- Distal peak latency ≤ 2.5 ms

Notes

- The nerve is superficial, and maximal responses usually can be obtained at low levels of stimulation.
- Side-to-side comparisons of the symptomatic and asymptomatic side are more useful than absolute values.

Utility of Electrodiagnostic Testing

1. To distinguish a radiculopathy from a plexopathy: As with the MAC nerve, studies of the LAC nerve can be used in this manner. Specifically, they can be used to distinguish a C5-C6 root lesion from a lesion of the lateral cord or upper trunk of the brachial plexus. In root lesions, the LAC sensory response will be normal, whereas in lesions of the lateral cord or upper trunk the LAC sensory responses will be of low amplitude or absent. A needle examination of the paraspinal muscles can also help determine this because these are denervated in radiculopathy but not plexopathy.
2. To distinguish isolated musculocutaneous nerve involvement from upper trunk or lateral cord brachial plexopathy. The lateral antebrachial cutaneous sensory response and the musculocutaneous nerve study will be abnormal in all three of these types of lesions. Other NCSs and the needle examination are needed to make further distinction. Lateral cord lesions will result in an abnormal median sensory response. Denervation will be present on needle examination of all muscles innervated by the musculocutaneous nerve and of C6-C7 innervated median nerve muscles, such as the pronator teres and flexor carpi radialis. In an upper trunk lesion, the abnormalities noted above will be present, plus the radial sensory response will be of low amplitude or absent, and the needle examination will demonstrate denervation of muscles not innervated by the lateral cord, including the deltoid muscle (innervated by the axillary nerve), the supraspinatus and infraspinatus muscles (innervated by the suprascapular nerve), and the brachioradialis muscle (innervated by the radial nerve).

AXILLARY NERVE

Anatomy

The axillary nerve arises from C5-C6 fibers that course through the upper trunk to the posterior cord of the brachial plexus and leaves the axilla through the quadrilateral space formed by the humerus, teres minor muscle, teres major muscle, and the long head of the triceps muscle. It innervates the deltoid and teres minor muscles and has a branch that supplies sensation to the lateral shoulder as the superior lateral cutaneous nerve of the arm.

Lesions: Etiology

The most common cause of this type of lesion is trauma, including shoulder dislocations, fractures of the humeral neck,¹⁰ blunt trauma to the shoulder in contact sports,²¹ gunshot wounds, and injections. Compression may produce an axillary neuropathy during general anesthesia or by sleeping with the arms above the head. The nerve may be entrapped within the quadrilateral space by muscular hypertrophy and repetitive trauma in athletes such as tennis players and baseball pitchers.^{22,23,24} As for other upper extremity neuropathies, idiopathic brachial plexopathy may be a cause.

Lesions: Clinical Presentation

Patients with an axillary neuropathy present with partial weakness of shoulder abduction and external rotation, motions which are partially maintained by the supraspinatus and infraspinatus muscles, respectively. Atrophy of the deltoid region of the upper arm may result. There is sensory loss over the lateral aspect of the upper arm.

Electrodiagnostic Testing^{18,25} (see Fig. 5)

Recording electrodes

- Active electrode (E1): middle deltoid
- Reference electrode (E2): distally to E1, over the deltoid tendon.

Stimulator

- Erb's point.

Normal values¹⁸

- Latency ≤ 5.0 ms at a distance of 14.8-21.0 cm (calipers), 20.0-26.5 cm (tape, arm at side), or 17.5-25.3 cm (tape, arm abducted 90 degrees).

Notes

- Compare symptomatic to asymptomatic side.
- May be technically difficult to obtain supramaximal stimulation.

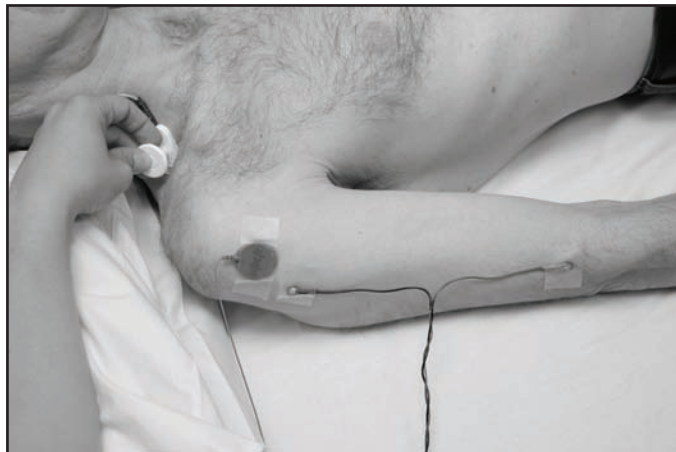

Figure 5 Nerve conduction study of the axillary nerve. Stimulation is at Erb's point.

Utility of Electrodiagnostic Testing

1. To distinguish a radiculopathy from a plexopathy: Sensory NCSs are not performed on the axillary nerve. But, because it arises from the upper trunk and the posterior cord of the brachial plexus, sensory studies of nerves that arise from these structures should be performed: median sensory nerve from the thumb (upper trunk, lateral cord), LAC nerve (upper trunk, lateral cord), and radial sensory nerve (upper trunk, posterior cord). Abnormalities in these indicate plexopathy, while sparing of these is indicative of C5-C6 radiculopathy. Needle examination of the cervical paraspinal muscles is also helpful. Denervation of these muscles is indicative of radiculopathy.
2. To distinguish an isolated axillary neuropathy from an upper trunk or posterior cord brachial plexopathy: As with assessment for radiculopathy above, because the axillary nerve is derived from the upper trunk and posterior cord, sensory nerves that originate in these portions of the brachial plexus should be studied. Lesions in the posterior cord will produce abnormal findings in the axillary nerve and the radial sensory nerve, but will spare the median and LAC nerves (lateral cord). On needle examination, denervation will be present in muscles innervated by the axillary nerve (deltoid and teres minor) and by radial-innervated muscles such as the triceps, brachioradialis, extensor carpi radialis, extensor digitorum communis, extensor digiti minimi, extensor carpi ulnaris, extensor pollicis longus and brevis, and extensor indicis muscles. Upper trunk lesions will result in abnormal findings not only in the axillary nerve and the radial sensory nerve, but also in the median sensory and LAC nerves, which derive from the posterior cord. Needle examination will demonstrate denervation in muscles supplied by the axillary nerve (deltoid and teres minor) and in other muscles which derive all or part of their innervations at the C5-C6 levels, such as the supraspinatus, infraspinatus, biceps, some radial-innervated muscles (brachioradialis, extensor carpi radialis, and triceps) and some median-innervated muscles (pronator teres and flexor carpi radialis).

SUPRASCAPULAR NERVE

Anatomy

The suprascapular nerve arises from the upper trunk of the brachial plexus, supplied by the C5 and C6 nerve roots. It passes through the suprascapular notch of the scapula, an area covered by the transverse scapular ligament, and supplies motor branches to the supraspinatus muscle. Then, it continues around the spinoglenoid notch of the scapular spine (bounded by the scapula spine medially and the spinoglenoid ligament [inferior transverse scapular ligament] laterally) to supply motor branches to the infraspinatus muscle. There are no cutaneous sensory fibers.

Lesions: Etiology

The suprascapular nerve may be entrapped as it passes through the suprascapular notch, or, less commonly, as it passes through the

spinoglenoid notch.^{26,27} Causes of suprascapular nerve entrapment also include mass lesions such as ganglion cysts, sarcomas, and metastatic carcinomas.^{9,28-31} Traumatic causes of suprascapular neuropathy include shoulder dislocation or protraction or scapular fracture,^{32,33} as well as injuries that generally produce more widespread damage to the brachial plexus such as stretch, gunshot, and penetrating injuries. Weightlifters may suffer suprascapular neuropathies, probably due to repetitive movement of the scapula. Other athletic activities involving overhand activities can predispose individuals to suprascapular entrapment, particularly at the spinoglenoid notch. Such injuries are particularly common in professional volleyball players,^{34,35} but also are seen in baseball pitchers and dancers.^{36,37} As with many other upper extremity neuropathies, the suprascapular nerve also may be affected in idiopathic brachial plexopathy.

Lesions: Clinical Presentation

Entrapment at the suprascapular notch usually is accompanied by pain, most prominently along the superior aspect of the scapula and radiating to the posterior and lateral shoulder. The pain may be referred to the arm, neck, or upper anterior chest wall^{9,27} and may be exacerbated by shoulder movements. The suprascapular notch may be tender to palpation. When suprascapular nerve is injured or when it is entrapped at the suprascapular notch, the clinical manifestation is primarily weakness of shoulder external rotation (infraspinatus muscle weakness). Shoulder abduction (supraspinatus muscle) is weakened only slightly, because of preservation of the deltoid muscle. Atrophy may be noted, particularly of the infraspinatus muscle, which is only partly covered by the overlying trapezius muscle. If entrapment occurs at the spinoglenoid ligament, then only infraspinatus weakness occurs, resulting in weakness of shoulder external rotation but no weakness of shoulder abduction. There is no cutaneous sensory alteration.

Electrodiagnostic Testing¹⁸ (see Figs. 6 and 7)

Recording electrodes

- Active electrode (E1): A monopolar needle in the supraspinatus or infraspinatus muscle. Do not use a surface electrode, as the trapezius muscle is more superficial and covers the intended muscles.
- Reference electrode (E2): Distally over shoulder joint.

Stimulator

- Erb's point.

Normal values

- Recording from supraspinatus muscle: latency ≤ 3.7 ms at a distance of 7.4-12 cm (calipers) or 9.0-13.8 cm (tape, arm at side or abducted 90 degrees).
- Recording from infraspinatus muscle: latency ≤ 4.2 ms at a distance of 10.0-15.0 cm (calipers) or 15.0-19.5 cm (tape, arm at side or abducted 90 degrees).

Notes

- Compare symptomatic to asymptomatic side.
- May be technically difficult to obtain supramaximal stimulation.

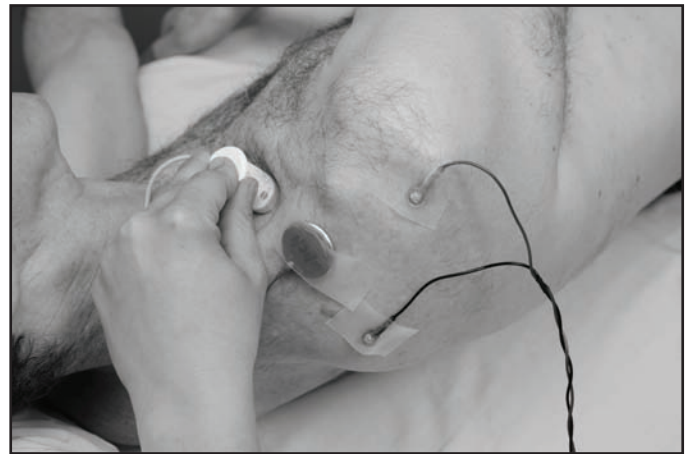


Figure 6 Nerve conduction study of the suprascapular nerve, recording from the supraspinatus muscle. Usually a needle rather than surface recording electrode is used. Stimulation is at Erb's point.

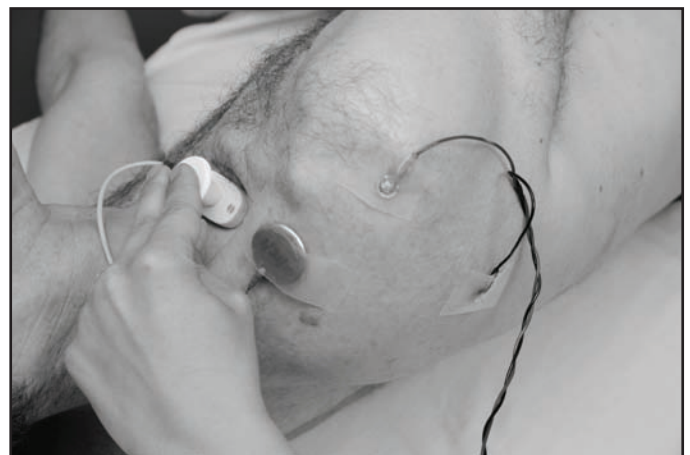

Figure 7 Nerve conduction study of the suprascapular nerve, recording from the infraspinatus muscle. Usually a needle rather than surface recording electrode is used. Stimulation is at Erb's point.

Utility of Electrodiagnostic Testing

1. To distinguish a radiculopathy from a plexopathy: Because the suprascapular nerve arises from the upper trunk of the brachial plexus, studies of sensory nerves that pass through the upper trunk should be performed, including studies of the median sensory nerve from the thumb (upper trunk, lateral cord), LAC sensory nerve (upper trunk, lateral cord), and radial sensory nerve (upper trunk, posterior cord). Abnormalities in these indicate plexopathy, while sparing of these is indicative of C5-C6 radiculopathy. Needle examination of the cervical paraspinal muscles is also helpful. Denervation of these muscles is indicative of radiculopathy.
2. To distinguish an isolated suprascapular neuropathy from an upper trunk brachial plexopathy: As with assessment for radiculopathy above, sensory nerves that originate in the upper trunk of the brachial plexus should be studied. Upper trunk lesions will produce abnormal responses from the median sensory, radial sensory, and lateral antebrachial cutaneous sensory nerves. On needle examination, denervation will be dependent on the location of the lesion

in the plexus. In addition to checking the supraspinatus and infraspinatus muscles, the examiner should also check the deltoid and brachioradialis muscles (upper trunk, posterior cord), biceps brachii muscle (upper trunk, lateral cord), and pronator teres and flexor carpi radialis muscles (upper trunk, lateral cord). Paraspinal muscles will be spared.

3. To differentiate a lesion at the suprascapular notch from one at the spinoglenoid notch: Damage by trauma or entrapment at the suprascapular notch generally produces a prolonged latency to both the supraspinatus and infraspinatus muscles on the symptomatic side compared to the asymptomatic side.²⁷ Entrapment at the spinoglenoid notch produces selective prolongation of the latency to the infraspinatus muscle only.²⁶

THE LUMBOSACRAL PLEXUS: THE KEY TO UNDERSTANDING LOWER EXTREMITY NEUROPATHIES

The lower extremity receives its entire motor and sensory innervations from the lumbosacral plexus, which has an upper and lower part. The upper part, or lumbar plexus, is located in the retroperitoneum, behind the psoas muscle, and is formed from L1-L4 nerve roots. It gives rise to six major nerves: the iliohypogastric, ilioinguinal, genitofemoral, lateral femoral cutaneous, femoral, and obturator. The lower part, which has been called lower lumbosacral plexus or the sacral plexus, is formed from L5-S3 nerve roots, plus a component from L4 (which also supplies the lumbar plexus). L4 and L5 combine to form the lumbosacral trunk. It gives rise to four major nerves: the sciatic, superior gluteal, inferior gluteal, and posterior cutaneous nerve of the thigh.

The specific nerves discussed in this section may be affected as part of a more widespread lumbosacral plexopathy. As with brachial plexopathy, lumbosacral plexopathy may result from trauma, an assortment of compressive and infiltrative causes, surgery, and radiation. Retroperitoneal hemorrhage, usually characterized by bleeding into the psoas muscle, occurs in 4.3-6.6% of patients receiving heparin,³⁸ and also is seen in hemophiliacs. Diabetic radiculoplexus neuropathy (diabetic amyotrophy) usually begins with upper lumbar pain, followed by rapidly progressive distribution in a lower thoracic and upper lumbar distribution as the pain resolves.^{39,40} Postpartum lumbosacral plexopathy is thought to be due to compression of the lumbosacral trunk by the head of the fetus.⁴¹ Radiculoplexus neuropathy may also be idiopathic (neuralgic amyotrophy), presumably autoimmune, similar to that seen in idiopathic brachial plexopathy.⁴² Table 3 lists the major causes.

FEMORAL AND SAPHENOUS NERVES

Anatomy

The femoral nerve is derived from L2-L4 nerve roots that course through the lumbar plexus. It gives off branches to the psoas and then the iliacus muscles, then runs deep to the inguinal ligament. About 4 cm distal to the inguinal ligament, it divides into anterior and posterior divisions. The anterior division gives rise to the medial

Table 3 Causes of lumbosacral plexopathy

Trauma—usually from traction
Pelvic fractures
Hip fractures and dislocations
Invasion/compression
Retroperitoneal hematoma
Tumor/neoplasm
Endometriosis
Surgery
Traction during total hip replacements and other pelvic/hip procedures
Retraction injuries
Positioning during surgery
Radiation
Postpartum
Diabetes
Idiopathic

and intermediate cutaneous nerves of the thigh and to the branches innervating the sartorius and pectineus muscles. The posterior division supplies the quadriceps femoris muscles (vastus medialis, vastus lateralis, vastus intermedius, and rectus femoris muscles) and then continues as the saphenous nerve, a pure sensory nerve.

The saphenous nerve passes through Hunter's canal (subsartorial canal) in the distal third of the thigh. It is bounded by the vastus medialis muscle laterally, and by the adductor longus and magnus muscles medially. The roof is formed by a connective tissue bridge between these two muscle groups, over which lies the sartorius muscle. It exits by piercing through this connective bridge to become subcutaneous about 10 cm proximally to the femur's medial epicondyle. Once subcutaneous, the nerve gives off an infrapatellar branch to supply cutaneous sensation to the infrapatellar region. The remainder of the nerve continues on as the main trunk of the saphenous nerve to supply sensation to the medial calf and foot.

Lesions: Etiology

The causes of femoral neuropathy are many and may occur in isolation or as part of a more widespread lumbosacral plexopathy (Table 4).^{9,43} As with many neuropathies, traumatic injuries are not uncommon. Perioperative damage may occur as a result of the surgery itself or of positioning during surgery.^{44,45} When the hip is flexed and externally rotated, such as occurs when patients are placed in the lithotomy position during gynecological procedures, urological procedures, or during labor and delivery, there is compression of the femoral nerve by the inguinal ligament.⁴⁶ Retroperitoneal hematomas and diabetic amyotrophy, discussed above as a cause of lumbosacral plexopathy, may present with prominent femoral nerve involvement.^{9,43}

The saphenous nerve can be damaged selectively, without involvement of the motor branches of the femoral nerve, via entrapment where it pierces the connective tissue roof of Hunter's canal.^{47,48,49} Other causes of selective saphenous nerve damage include periopera-

Table 4 Causes of femoral neuropathy

Trauma
Gunshot
Knife
Stretch/traction
Injections
Perioperative damage
Traction with abdominal or pelvis retractors
Positioning, particularly lithotomy position
Inadvertent transection
Nerve ischemia during renal transplantation
Compression
Tumors or other masses
Hematoma formation after femoral artery catheterization
Retroperitoneal hemorrhage
Nerve infarction secondary to vasculitis
Diabetic amyotrophy

tive damage, either as a direct result of damage during varicose vein surgery and arthroscopic procedures of the knee, or secondary to stretch or compression from improper positioning. Proximal tibial fractures have been implicated in selective saphenous nerve damage, as have neurilemmomas.⁵⁰ Some of these causes may selectively damage the infrapatellar branch of the saphenous nerve.

Lesions: Clinical Presentation

Damage of the femoral nerve above the inguinal ligament causes weakness of hip flexion, resulting in difficulty lifting the leg at the hip, so that the patient drags the leg when walking. Lesions either above or below the inguinal ligament cause weakness of knee extension. In such cases, the knee will buckle, causing falls, and patients often experience difficulty climbing stairs, arising from a chair, or arising from a squatting position unless they push with the arms. When walking, patients may hyperextend the knee to lock it and prevent the leg from buckling. Examination reveals a depressed or absent patellar reflex. Involvement of the saphenous nerve produces sensory disturbances over the medial calf and foot; a lesion isolated to the infrapatellar branch of the saphenous nerve can produce sensory disturbances restricted to the medial leg just below the knee.

Electrodiagnostic Testing

Femoral nerve^{9,51} (see Fig. 8)

Recording electrodes

- Active electrode (E1): over the quadriceps muscle, usually rectus femoris or vastus medialis.
- Reference electrode (E2): quadriceps tendon at the patella.

Stimulator

- Below the inguinal ligament, just lateral to the femoral artery.

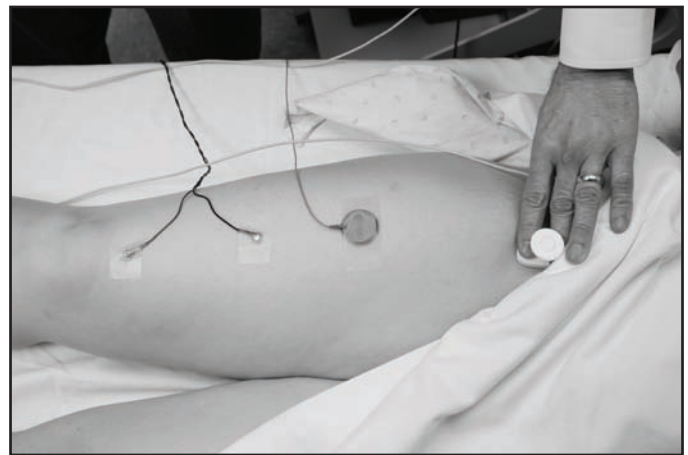


Figure 8 Nerve conduction study of the femoral nerve. Stimulation is below the inguinal ligament, just lateral to the femoral artery.

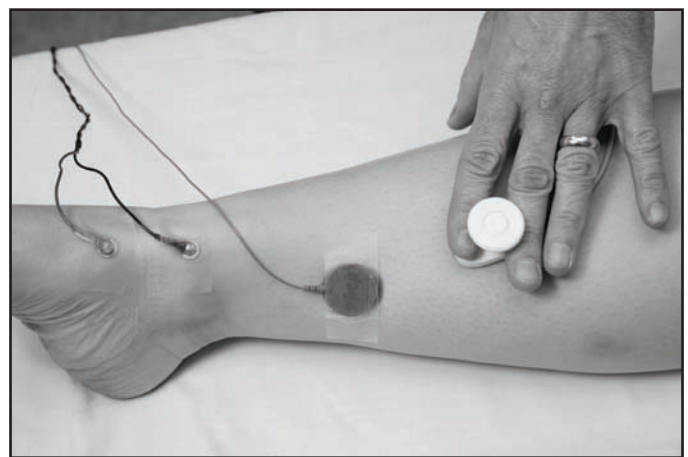


Figure 9 Nerve conduction study of the saphenous nerve. Stimulation is in the medial calf, between the medial gastrocnemius muscle and tibia.

Normal values

- Amplitude ≥ 3.7 mV (age < 40 years), ≥ 0.8 mV (age > 40 years) (to vastus medialis muscle)

Notes

- Amplitudes vary a great deal between individuals. Compare side-to-side for each patient.

Saphenous nerve^{9,52} (see Fig. 9)

Recording electrodes

- Active electrode (E1): halfway between the tibialis anterior tendon and the medial malleolus, 14 cm distal to the stimulator.
- Reference electrode (E2): 3-4 cm distal to E1.

Stimulator

- On the medial calf, in the groove between the medial gastrocnemius muscle and tibia, 14 cm proximal to the recording electrodes.

Normal values

- Amplitude ≥ 4 μ V (Preston),⁹ 9.0 ± 3.4 μ V (Wainapel).⁵²
- Conduction velocity ≥ 40 m/s (Preston),⁹ ≥ 38.3 m/s (Wainapel).⁵²
- Distal peak latency ≤ 4.4 ms (Preston and Wainapel).^{9,52}

Notes

- Response may be very small or absent, particularly in those over 40 years of age.
- Side-to-side comparison is important. Averaging may be helpful.

Utility of Electrodiagnostic Testing

When comparing amplitude side to side, a lower amplitude can indicate axon loss or may indicate loss of muscle, as occurs in quadriceps muscle atrophy in inclusion body myositis. A significantly prolonged latency on one side relative to the other may indicate focal demyelination between the points of stimulation and recording.

Femoral and saphenous nerve studies can be used to distinguish a femoral neuropathy from a lumbosacral plexopathy and from L2-L4 radiculopathy. In femoral neuropathy, the saphenous nerve response will be of low amplitude, compared to the contralateral asymptomatic side, or will be absent. This will be true also in a lumbar plexopathy if the lesion involves the femoral nerve. In radiculopathy, the saphenous response will be normal because the injury is proximal to the dorsal root ganglion. The needle examination in femoral neuropathy will reveal denervation of the quadriceps femoris muscles (vastus medialis, lateralis, intermedius, and rectus femoris muscles). If the lesion in a femoral neuropathy is proximal to the inguinal ligament, then the iliopsoas muscle will reveal denervation. In plexopathy, there will be denervation on needle examination in L2-L4 innervated muscles not supplied by the femoral nerve, such as the adductors (L2-L4) and the tibialis anterior muscle (L4-L5). Other muscles outside the L2-L4 distribution should be explored to determine whether the area of denervation is more widespread, suggesting a broader plexopathy, including muscles supplied by the peroneal, tibial, sciatic, superior gluteal, and inferior gluteal muscles. Needle examination of the paraspinous muscles is important to assess for radiculopathy, particularly if the saphenous response is normal.

LATERAL FEMORAL CUTANEOUS NERVE

Anatomy

The lateral femoral cutaneous nerve is derived from the L2-L3 nerve roots. It usually passes under the inguinal ligament but superficial to the sartorius muscle, just medial and inferior to the anterior superior iliac spine. However, there are several possible anatomic variants: 1) over the anterior iliac crest, 2) between two slips of the inguinal, 3) deep to the sartorius muscle, and 4) through the sartorius muscle.⁵³ It supplies sensation to the skin over the anterolateral thigh. This is strictly a cutaneous sensory nerve, without a motor component.

Lesions: Etiology

Entrapment of the lateral femoral cutaneous nerve may occur as it passes under the inguinal ligament, or at any of the other four sites described above. It may also be entrapped as it passes through the deep fascia distal to the region of the inguinal ligament and sartorius muscle. Entrapment is most common in patients who are obese or wear tight-fitting clothing, including tight or wide belts, or tight

pants or underpants. Other less common causes of lateral femoral cutaneous neuropathy include compression of the lumbosacral plexus by tumors and other mass lesions, perioperative damage during pelvic osteotomies, such as those done for hip dysplasia, acetabular insufficiency, and Perthes' disease, and damage during removal of bone for grafting from the ilium. Trauma may be a cause, usually in association with a more widespread lumbosacral plexopathy or with damage to other nerves arising from the plexus.^{53,54}

Lesions: Clinical Presentation

Patients develop an area of sensory disturbance over the anterolateral thigh, described variously as a numbness, burning, pain, or tingling. This is known as meralgia paresthetica. The discomfort may be worsened by rubbing or touching the skin over this area. There may be pain to palpation around the area of the inguinal ligament. No weakness, no muscle atrophy, no reflex changes are present on examination.

Electrodiagnostic Testing^{9,55} (see Fig. 10)

Recording electrodes

- Active electrode (E1): anterolateral thigh, 12 cm distal to stimulator.
- Reference electrode (E2): 3-4 cm distal to E1.

Stimulator

- 1 cm medial to the anterior superior iliac spine, above the inguinal ligament. A monopolar needle electrode may need to be used for stimulation if the patient is not thin.

Normal values (Butler et al)⁵⁵

- Latency ≤ 3.0 ms
- Amplitude ≥ 10 μ V

Notes

- May be difficult to obtain in many normal individuals, particularly obese ones.
- Side to side comparison is necessary.
- If no response can be obtained on the asymptomatic side, there is no value in testing the symptomatic side.

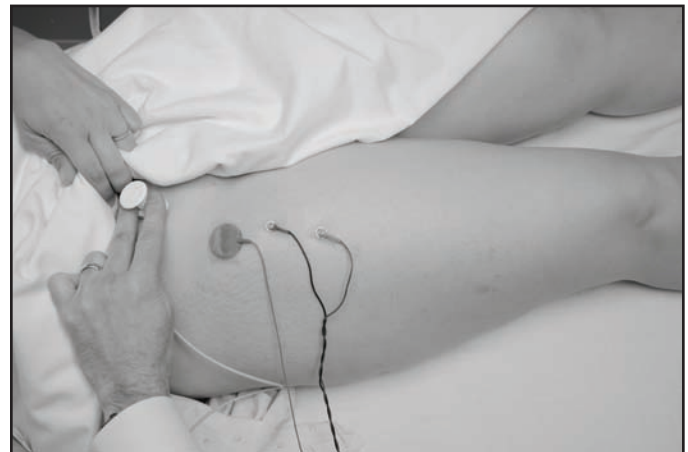

Figure 10 Nerve conduction study of the lateral femoral cutaneous nerve. Stimulation is slightly medial to the anterior superior iliac spine, above the inguinal ligament.

Utility of Electrodiagnostic Testing

Generally this nerve is tested only when the patient demonstrates sensory disturbances over the relevant area of skin. In such cases, testing of this nerve plays a role in differentiation of an isolated lateral femoral cutaneous neuropathy from an L2-L3 radiculopathy or a lumbar plexopathy. If the sensory response on the symptomatic side is significantly lower in amplitude than on the asymptomatic side, this helps to exclude a radiculopathy. Testing of the saphenous response will help determine whether there is more widespread involvement of the lumbar plexus. If that is normal, then it is more likely that this is an isolated lesion of the lateral femoral cutaneous nerve or that involvement of the plexus has spared the femoral nerve. However, because the lateral femoral cutaneous response may be difficult to obtain accurately and reliably, a needle examination of the proximal leg muscles should be used to assess whether a more widespread lumbosacral plexopathy is present. Needle examination of the lumbar paraspinous muscles should be done to assess for radiculopathy.

REFERENCES

- Donner TR, Kline GD. Extracranial accessory nerve injury. *Neurosurg* 1983;32:907-911.
- Swann KW, Heros RC. Accessory nerve palsy following carotid endarterectomy: report of two cases. *J Neurosurg* 1985;63:630-632.
- Eisen A, Bertrand G. Isolated accessory nerve palsy of spontaneous origin: a clinical and electromyographic study. *Arch Neurol* 1972;27:496-502.
- Cherington M. Accessory nerve: conduction studies. *Arch Neurol* 1968;18:708-709.
- Tsairis P, Dyck PJ, Mulder D. Natural history of brachial plexus neuropathy. *Arch Neurol* 1972;27:109-117.
- Suarez GA. Immune brachial plexus neuropathy. In: Dyck PJ, Thomas PK, eds. *Peripheral neuropathy*, 4th ed. Philadelphia: Elsevier; 2005. 2299-2307.
- Levin KH, Wilbourn AJ, Maggiano HJ. Cervical rib and median sternotomy-related brachial plexopathies: a reassessment. *Neurology* 1998;50:1407-1413.
- Pribyl R, You SB, Jantra P. Sensory nerve conduction velocity of the medial antebrachial cutaneous nerve. *Electromyogr Clin Neurophysiol* 1979;19:41-46.
- Preston DC, Shapiro BE. *Electromyography and Neuromuscular Disorders*. Philadelphia: Elsevier; 2005.
- De Laat EAT, Visser CPJ, Coene LNJEM, Pahlplatz PVM, Tavy DIJ. Nerve lesions in primary shoulder dislocations and humeral neck fractures: a prospective clinical and EMG study. *J Bone Joint Surg Br* 1994;76:381-383.
- Braddom RL, Wolfe C. Musculocutaneous nerve injury after heavy exercise. *Arch Phys Med Rehabil* 1978;59:290-293.
- Mastaglia FL. Musculocutaneous nerve injury after strenuous physical activity. *Med J Aust* 1986;145:153-154.
- Davidson JJ, Bassett FH, Nunley JA. Musculocutaneous nerve entrapment revisited. *J Shoulder Elbow Surg* 1998;7:250-255.
- Dumitru D, Zwarts MJ. Brachial plexopathies and proximal mononeuropathies. In: Dumitru D, Amato AA, Zwarts M, eds. *Electrodiagnostic medicine*, 2nd ed. Philadelphia: Hanley & Belfus; 2002. 777-836.
- Bassett FH, Nunley JA. Compression of the musculocutaneous nerve at the elbow. *J Bone Joint Surg Am* 1982;64:1050-1052.
- Sander HW, Conigliari M, Masdeu JC. Antecubital phlebotomy complicated by lateral antebrachial cutaneous neuropathy. *N Engl J Med* 1998;339:2024.
- Felsenthal G, Mondell DL, Reischer MA, Mack RH. Forearm pain secondary to compression syndrome of the lateral cutaneous nerve of the forearm. *Arch Phys Med Rehabil* 1984;65:139-141.
- Kraft GH. Axillary, musculocutaneous and suprascapular nerve latency studies. *Arch Phys Med Rehabil* 1972;53:383-387.
- Oh SJ. *Clinical electromyography: nerve conduction studies*, 3rd ed. Philadelphia: Lippincott Williams & Wilkins; 2003.
- Spindler HA, Felsenthal G. Sensory conduction in the musculocutaneous nerve. *Arch Phys Med Rehabil* 1978;59:20-23.
- Perlmutter GS, Leffert RD, Zarins B. Direct injury to the axillary nerve in athletes playing contact sports. *Am J Sports Med* 1997;25:65-68.
- Cahill BR, Palmer RE. Quadrilateral space syndrome. *J Hand Surg* 1983;8:65-69.
- Redler MR, Ruland LJ, McCue FC. Quadrilateral space syndrome in a throwing athlete. *Am J Sports Med* 1986;14:511-513.
- McKowen HC, Voorhies RM. Axillary nerve entrapment in the quadrilateral space. *J Neurosurg* 1987;66:932-934.
- Currier DP. Motor conduction velocity of axillary nerve. *Phys Ther* 1971;51:503-509.
- Aiello I, Serra G, Traina GC, Tugnoli V. Entrapment of the suprascapular nerve at the spinoglenoid notch. *Ann Neurol* 1982;12:314-316.
- Post M, Mayer J. Suprascapular nerve entrapment: diagnosis and treatment. *Clin Orthop* 1987;223:126-136.
- Ganzhorn RW, Hocker JT, Horowitz M, Switzer HE. Suprascapular nerve entrapment: a case report. *J Bone Joint Surg Am* 1981;63:492-494.
- Thomason RC, Schneider W, Kennedy T. Entrapment neuropathy of the inferior branch of the suprascapular nerve by ganglia. *Clin Orthop* 1982;166:185-187.
- Moore TP, Fritts HM, Quick DC, Buss DD. Suprascapular nerve entrapment caused by supraglenoid cyst compression. *J Shoulder Elbow Surg* 1997;6:455-462.
- McCluskey L, Feinberg D, Dolinskas C. Suprascapular neuropathy related to glenohumeral joint cyst. *Muscle Nerve* 1999;22:772-777.
- Zoltan JD. Injury to the suprascapular nerve associated with anterior dislocation of the shoulder: case report and review of the literature. *J Trauma* 1979;19:203-206.
- Toon TN, Bravois M, Guillen M. Suprascapular nerve injury following trauma to the shoulder. *J Trauma* 1981;21:652-655.
- Antoniadis G, Richter H-P, Rath S, Braun V, Moese G. Suprascapular nerve entrapment: experience with 28 cases. *J Neurosurg* 1996;85:1020-1025.
- Ferreti A, DeCarli A, Fontana M. Injury of the suprascapular nerve at the spinoglenoid notch: the natural history of infraspinatus atrophy in volleyball players. *Am J Sports Med* 1998;26:759-763.
- Ringel SP, Treihaf M, Carry M, Fisher R, Jacobs P. Suprascapular neuropathy in pitchers. *Am J Sports Med* 1990;18:80-86.
- Kukowsky B. Suprascapular nerve lesion as an occupational neuropathy in a semiprofessional dancer. *Arch Phys Med Rehabil* 1993;74:768-769.
- Mant MJ, O'Brien BD, Thong KL, Hammond GW, Birtwhistle RV, Grace MG. Haemorrhagic complications of heparin therapy. *Lancet* 1977;1:1133-1135.
- Bastron J, Thomas J. Diabetic polyradiculopathy: clinical and electromyographic findings in 105 patients. *Mayo Clin Proc* 1981;56:725-732.
- Dyck PJB, Norell JE, Dyck PJ. Microvasculitis and ischemia in diabetic lumbosacral radiculoplexus neuropathy. *Neurology* 1999;53:2113-2121.

41. Katirji B, Wilbourn AJ, Scarberry SL, Preston DC. Intrapartum maternal lumbosacral plexopathy: foot drop during labor due to lumbosacral trunk lesion. *Muscle Nerve* 2002;26:340-347.
42. Dyck PJB, Norell JE, Dyck PJ. Non-diabetic lumbosacral radiculoplexus neuropathy: natural history, outcome and comparison with the diabetic variety. *Brain* 2001;124:1197-1207.
43. Dumitru D, Zwarts MJ. Lumbosacral plexopathies and proximal mononeuropathies. In: Dumitru D, Amato AA, Zwarts M, eds. *Electrodiagnostic medicine*, 2nd ed. Philadelphia: Hanley & Belfus; 2002. 837-883.
44. Rushton FG, Politi VL. Femoral nerve injury from abdominal retractors. *Can Anaesth Soc J* 1958;5:428-437.
45. Winkleman NW. Femoral nerve complications after pelvic surgery. *Am J Obstet Gynecol* 1958;75:1063-1065.
46. Sinclair RH, Pratt JH. Femoral neuropathy after pelvic operation. *Am J Obstet Gynecol* 1972;112:404-407.
47. Kopell HP, Thompson WAL. Knee pain due to saphenous nerve entrapment. *N Engl J Med* 1960;263:351-353.
48. Worth RM, Kettelkamp DB, Defalque RJ, Duane KU. Saphenous nerve entrapment. A cause of medial knee pain. *Am J Sports Med* 1984;12:80-81.
49. Dumitru D, Windsor RE. Subsartorial entrapment of the saphenous nerve in a competitive female bodybuilder. *Phys Sport Med* 1989;17:116-125.
50. Goldner JL, Hall RL. Nerve entrapment syndromes of the low back and lower extremities. In: Omer GE, Spinner M, van Beek AL, eds. *Management of peripheral nerve problems*, 2nd ed. Philadelphia: WB Saunders; 1998. 554-584.
51. Stohr M, Schumm F, Ballier R. Normal sensory conduction in the saphenous nerve in man. *Electroencephalogr Clin Neurophysiol* 1978;44:172-178.
52. Wainapel SF, Kim DJ, Ebel A. Conduction studies of the saphenous nerve in healthy subjects. *Arch Phys Med Rehabil* 1978;59:316-319.
53. Macnicol MF, Thompson WJ. Idiopathic meralgia paresthetica. *Clin Orthop* 1990;254:270-274.
54. Williams PH, Trzil KP. Management of meralgia paresthetica. *J Neurosurg* 1991;74:76-80.
55. Butler ET, Johnson EW, Kaye AZ. Normal conduction velocity in lateral femoral cutaneous nerve. *Arch Phys Med Rehabil* 1974;55:31-32.

Ulnar and Radial Nerves

Kevin R. Scott, MD, MA

Associate Professor of Neurology
 Department of Neurology
 Pennsylvania State College of Medicine
 Milton S. Hershey Medical Center
 Hershey, Pennsylvania

PART I: ULNAR NEUROPATHY

Anatomy

The ulnar nerve is derived from the C8-T1 nerve roots. Nearly all ulnar nerve fibers travel through the lower trunk and medial cord of the brachial plexus.¹ During its descent through the medial arm, the ulnar nerve does not give off any branches until it reaches the elbow. At the elbow, the ulnar nerve travels through the groove formed by the medial epicondyle and olecranon process of the ulnar bone, and passes deep to the humeroulnar aponeurotic arcade (HUA), better known as the cubital tunnel. Here, muscular branches to the flexor carpi ulnaris (FCU) and flexor digitorum profundus (FDP)—ring and little finger—arise, while the main trunk of the ulnar nerve continues its descent to the wrist.²

Approximately 5 cm proximal to the wrist, the main ulnar nerve gives rise to two sensory branches. The dorsal ulnar cutaneous sensory branch travels beneath the FCU to provide sensation over the dorsomedial aspect of the hand. The palmar cutaneous sensory branch provides sensation over the hypothenar area of the hand and nails.²

The ulnar nerve then enters Guyon's canal at the wrist. Guyon's canal, also known as the ulnar canal, is a small anatomical space formed by the pisiform and hamate bones. The ulnar artery travels with the ulnar nerve through this space on their way into the hand. Here, digital branches arise that provide sensation to the palmar aspect of the medial ring and little finger. In addition, motor branches arise to innervate the hypothenar muscles (opponens digiti minimi, abductor

digiti minimi [ADM], and flexor digiti minimi), palmar and dorsal interossei, 3rd and 4th lumbricals, adductor pollicis, and the deep head of the flexor pollicis brevis muscles.²

Clinical Features of Ulnar Nerve Dysfunction

Ulnar Neuropathy at the Elbow

This neuropathy is the second most common entrapment neuropathy after carpal tunnel syndrome. Typical symptoms include numbness and tingling in the distribution of the ulnar nerve. Some patients report elbow pain that radiates into the ulnar aspect of the hand. In some cases, only sensory symptoms are present.¹ Impaired sensation in the fingertips is the most common sensory deficit. Sensory loss in the ulnar palm is less frequent.³ An early sign may be inability to adduct the little finger (Wartenberg's sign). In more severe cases, there will be weakness of handgrip and atrophy of the intrinsic hand muscles. Weakness of the first dorsal interosseous muscle (hand) (FDIH) is more frequent (84%) than weakness of the ADM muscle (76%).⁴ Weakness of the FDP and FCU muscles occur in 56% and 20%, respectively.⁴ In severe cases, clawing of the ring and little finger can develop. Deep tendon reflexes are usually preserved in this type of neuropathy. Various provocative maneuvers have been described that may increase the diagnostic yield. These include sustained manual pressure over the cubital tunnel, sustained elbow flexion, and flexion combined with manual pressure. Combined flexion with manual pressure over the cubital tunnel has been reported to have the highest sensitivity (91%).⁵ The differential diagnosis in a patient sus-

pected of an ulnar neuropathy at the elbow includes: a lower trunk or medial cord brachial plexopathy, a C8–T1 radiculopathy, or an ulnar neuropathy at some location other than the elbow. Some common causes of ulnar neuropathy at the elbow are listed in Table 1.

Electrophysiology. As with other mononeuropathies, the electrodiagnostic (EDX) study should localize the abnormalities to the ulnar nerve. Evaluation of the ulnar nerve requires recording ulnar sensory and motor responses. As with all nerve conduction studies, limb temperatures should be maintained within the reference range ($> 32^\circ$) and documented.

Ulnar sensory responses are obtained and are usually compared to the median and radial sensory responses in order to exclude a diffuse polyneuropathy. The antidromic ulnar sensory study (See Fig. 1) is performed using ring electrodes to record from the little finger. Ring electrodes are placed with G1 over the proximal metacarpal-phalangeal (MCP) joint, and G2 placed 3–4 cm away over the distal MCP joint.¹ The ulnar nerve is then stimulated proximal to the wrist adjacent to the FCU tendon.¹ The distance between the stimulation site and the G1 electrode will be dependent on the normative values used in the practitioner's laboratory. Typically, this distance ranges from 11–14 cm.

At times, a dorsal ulnar cutaneous sensory study may also be performed (See Fig. 2), particularly if there is the confounding possibility of wrist pathology. This study is performed using standard disc electrodes. G1 is placed over the web space between the ring and little fingers, while G2 is placed 3–4 cm distal over the little finger.¹ This nerve is stimulated 8–10 cm proximally. The stimulation site lies just proximal to and slightly below the ulnar styloid.¹ Because this nerve arises proximal to the wrist, it may be involved in ulnar neuropathies at the elbow but will be normal when the ulnar nerve is entrapped at the wrist.

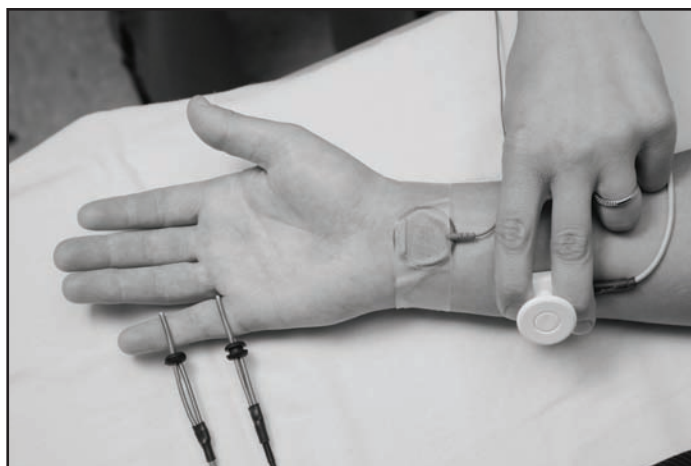


Figure 1 Ulnar sensory conduction study (antidromic). **Antidromic conduction:** The recording electrodes are placed 3–4 cm apart on the little finger on the proximal and distal phalanges, the proximal electrode being the active recording electrode. A ground is placed over the wrist crease. The distal stimulation site is over the ulnar nerve at the wrist 14 cm from the active recording electrode, with the cathode distal to the anode. Proximal ulnar sensory nerve conduction velocity can be determined by stimulating proximally either below or above the elbow, but this is rarely done in the author's. **Orthodromic conduction:** The recording electrodes are placed 3–4 cm apart over the ulnar nerve at the wrist toward the flexor carpi ulnaris tendon, 14 cm proximal to the stimulating electrode, with the active recording electrode distal to the reference electrode. The stimulating electrodes are placed over the little finger in the same positions as for the recording electrodes with antidromic stimulation, placing the cathode 3–4 cm proximal to the anode. The ground is again placed on the wrist crease.

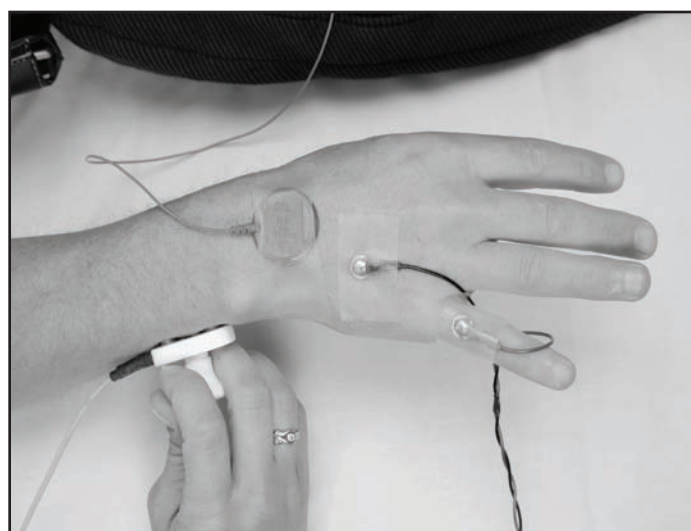


Figure 2 Dorsal ulnar cutaneous sensory study. The active recording electrode is placed over the web space between the little and ring fingers (you can feel the bones come together like a V). The reference electrode is placed 3–4 cm distal over the little finger. The ground is placed between the recording electrode and the stimulation site. The nerve is stimulated slightly proximal and inferior to the ulnar styloid with the hand pronated, 8 cm proximal to the active recording electrode, with the cathode distal to the anode.

Table 1 Common causes of ulnar neuropathy at the elbow

1. Old fracture with joint deformity
2. Recent elbow trauma without fracture
3. Habitual leaning on elbow
4. Occupational repetitive flexion/extension
5. Congenital variations of HUA architecture
 - A. Absent HUA with nerve prolapse
 - B. Hypertrophy of retinaculum
 - C. Anconeus epitrochlearis muscle
6. Diabetes mellitus
7. Hereditary neuropathy with liability to pressure palsies
8. Rheumatoid arthritis
9. Iatrogenic
 - A. Malpositioning during surgery
 - B. Nerve infarction during transposition

HUA = humeroulnar aponeurotic arcade

The ulnar motor study is next and its focus is to demonstrate or refute the presence of focal demyelination at the elbow. Demyelination across the elbow segment is characterized by either focal slowing

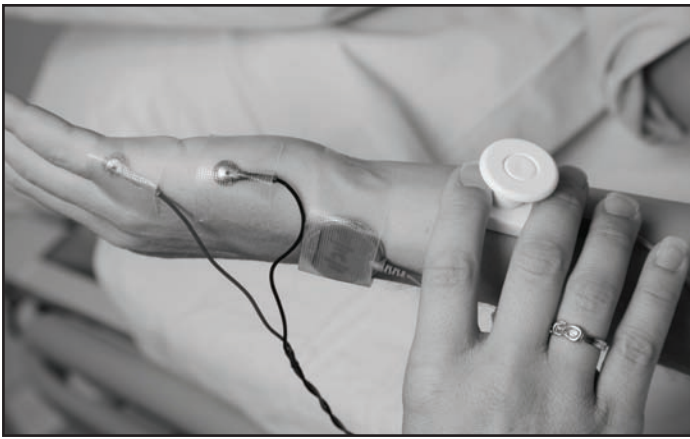


Figure 3 Ulnar motor conduction study in the abductor digiti minimi muscle stimulating at the wrist. The active recording electrode is placed over the hypothenar muscles approximately one-half way between the distal wrist crease across the ulnar border of the wrist and the distal transverse palmar crease across the ulnar border of the hand, so as to be over the belly of the muscle. The inactive electrode is placed over the hypothenar tendon at the level of the M-P joint on the little finger. The ulnar nerve is stimulated over the flexor carpi ulnaris tendon with the cathode distal to the anode, at a distance of 7 cm from the cathode stimulation site to the active recording electrode. The ground is placed over the wrist crease. The proximal stimulation sites are over the ulnar nerve distal and proximal to the medial epicondyle, with a distance of approximately 10-12 cm between the distal and proximal sites, and with the elbow flexed to 90 degrees. Conduction velocity can also be determined by stimulating the ulnar nerve in the upper arm and in the supraclavicular fossa (Erb's point).

(i.e., a motor nerve conduction velocity < 50 m/s, or a motor nerve conduction velocity that is > 10 m/s slower than the below elbow to wrist conduction velocity) or conduction block. When performing the ulnar motor study, it is important to understand that elbow position is crucial. The flexed (at 70-90 degrees) elbow position should be utilized because it has been shown to be more sensitive than testing with the elbow extended.^{6,7}

The ulnar motor study can be recorded from either the ADM (See Figs. 3-5) and/or FDIH (See Fig. 6) muscles. Recording over the FDIH muscle may be more sensitive than the ADM muscle.^{7,8} Using standard disc electrodes, G1 is placed over the belly of the muscle being recorded while G2 is placed 3-4 cm distal over the MCP joint.¹ The ulnar nerve is then stimulated at up to four sites: 1) wrist (W): this site is just proximal to the wrist adjacent to the FCU tendon (See Fig. 3); 2) below elbow (BE): this site lies 3-4 cm distal to the medial epicondyle (See Fig. 4); 3) above elbow (AE): this site lies approximately 10-12 cm proximal to the below elbow site, in the space between the biceps and triceps muscles (See Fig. 5); and less commonly, 4) axilla (A): this site lies in the proximal axilla, medial to the biceps muscle, and over the axillary pulse.¹ Remember that measurement across the elbow segment must follow the curved path of the ulnar nerve—imprecise measurements are one of the most common causes of technical error. Also be aware that the AE and axilla stimulation sites may require higher current intensities to achieve supramaximal stimulation.

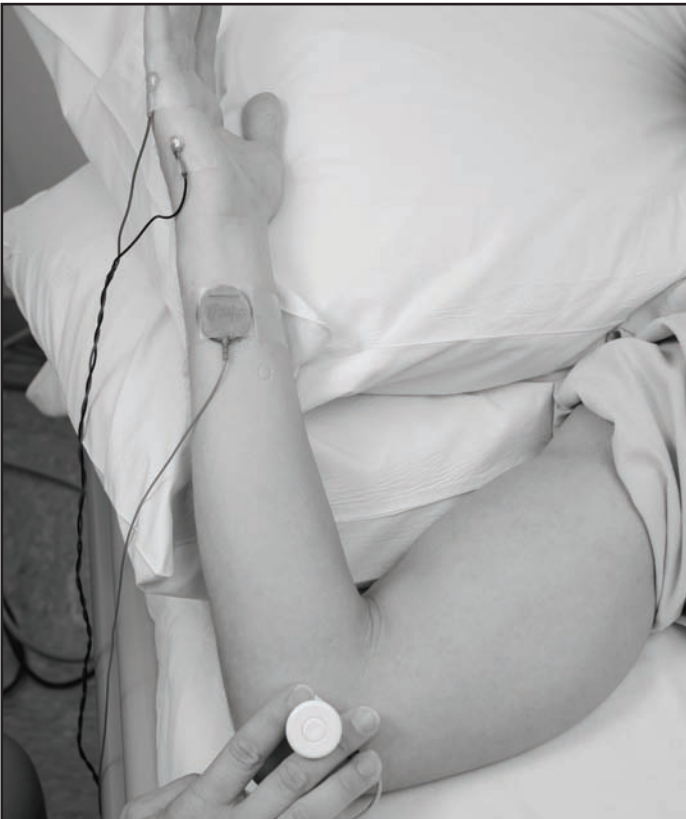

Figure 4 Ulnar motor conduction study in the abductor digiti minimi muscle stimulating below elbow.

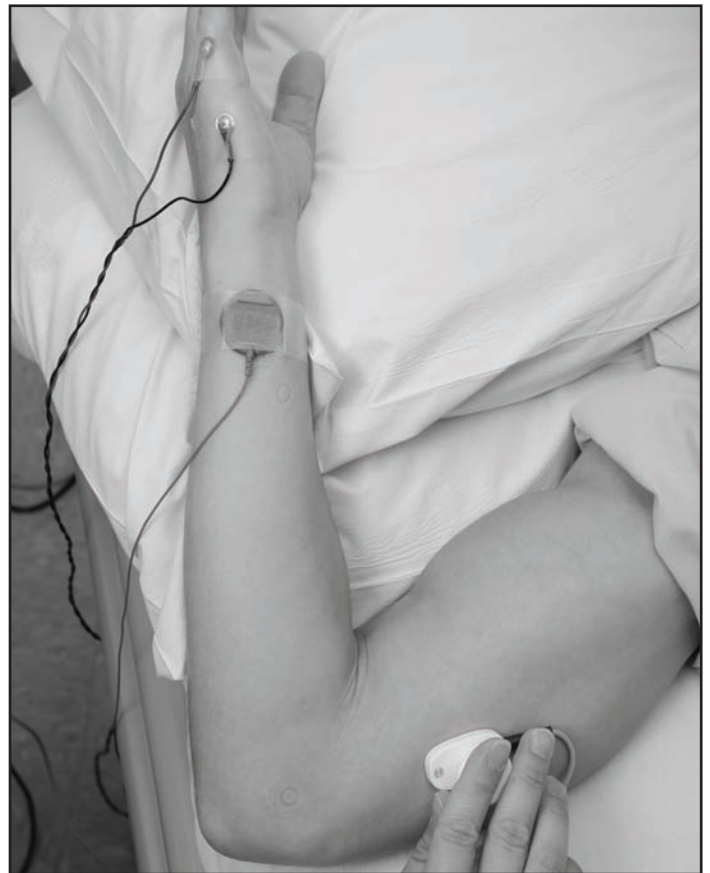

Figure 5 Ulnar motor conduction study in the abductor digiti minimi muscle stimulating above elbow.

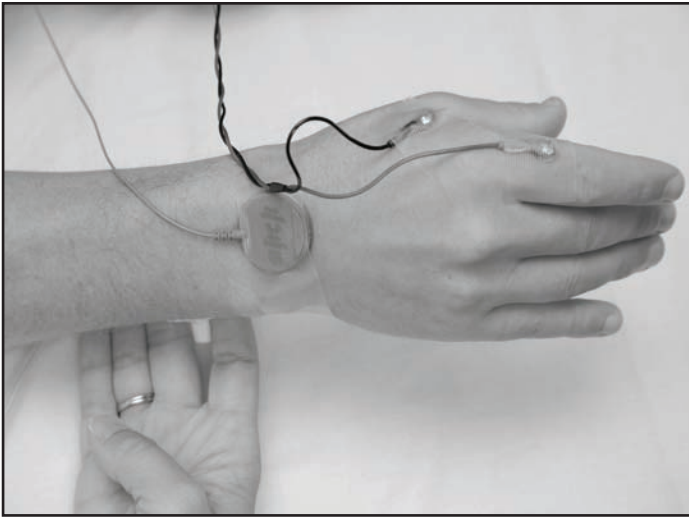


Figure 6 Ulnar motor conduction study recording at the first dorsal interosseous muscle.

In certain cases, inching across the elbow can be performed to demonstrate focal demyelination.^{7,9} The setup is identical to ulnar motor studies recording from the ADM and FDIH muscles. Recording is performed at the W and BE sites as described above. The BE–AE section is then divided into 1–2 cm segments and individual motor responses are obtained at each increment.¹ The most convincing abnormality would be a change in latency and/or a change in compound muscle action potential (CMAP) amplitude (> 20%), morphology, or area across the BE–AE segment.⁷

Evaluation of the ulnar nerve with nerve conduction studies should include the routine studies shown in Table 2. Should routine nerve conduction studies not localize the lesion, additional techniques may be helpful to consider. These may include: 1) repeating the ulnar motor study, while recording from the FDIH muscle; 2) ulnar motor study using inching techniques across the elbow segment; 3) sensory or mixed nerve studies across the elbow; 4) comparing the dorsal ulnar cutaneous sensory responses between the affected and asymptomatic limb; and 5) comparing the medial antebrachial cutaneous sensory response between affected and asymptomatic sides if there is reason to suspect a brachial plexopathy. In most cases the lesion is at the elbow, however, lesions at the wrist or more proximal locations (brachial plexus or root) should be excluded by the EDX study.

Treatment. The treatment of patients with ulnar neuropathy at the elbow may consist of conservative or surgical measures. Nonoperative management should include avoidance of pressure on the elbow and/or prolonged elbow flexion and utilization of an elbow splint. In certain cases, steroid injections into the cubital tunnel may be helpful. In patients who have significant or progressive neurological deficits, surgical decompression is recommended. There are a number of procedures utilized.³

Ulnar Neuropathy at the Wrist

Entrapment of the ulnar nerve at the wrist is rare relative to compression at the elbow. The common site of entrapment occurs within

Table 2 Electrodiagnostic evaluation of ulnar neuropathy at the elbow¹

1. Nerve conduction studies (See Figs. 1-6)
 - A. Ulnar nerve studies
 - i. Ulnar motor study, stimulating at the wrist, below elbow, and above elbow sites while recording from the abductor digiti minimi muscle.
 - ii. Ulnar F responses.
 - iii. Ulnar sensory study stimulating at the wrist while recording from the little finger.
 - B. Median nerve studies
 - i. Median motor study stimulating at the wrist and elbow sites while recording from the abductor pollicis brevis muscle.
 - ii. Median F responses.
 - iii. Median sensory study stimulating at the wrist while recording from the thumb.
2. Needle electromyography
 - A. Routine
 - i. At least one ulnar-innervated muscle distal to the wrist (e.g., first dorsal interosseous or abductor digiti minimi)
 - ii. Two ulnar-innervated muscles of the forearm (e.g., flexor digitorum profundus III/IV and flexor carpi ulnaris).
 - B. If testing of any of the routine muscles is abnormal, then additional needle examination should include:
 - i. At least two nonulnar, lower trunk, C8-T1 muscles (e.g., abductor pollicis brevis, flexor pollicis longus, extensor indicis proprius).
 - ii. C8 and T1 paraspinal muscles.

Table 3 Clinical syndromes produced by ulnar nerve compression within the canal of Guyon^{1,9}

1. Combined motor and sensory syndrome (Type 1). A lesion at the proximal portion of the canal may involve both motor and sensory divisions. Weakness of all ulnar innervated hand muscles and loss of sensation over the palmar little and medial ring fingers occurs. Cutaneous sensation over the hypothenar and dorsomedial surfaces of the hand should be spared.
2. Pure sensory syndrome (Type 2). Clinically, there is loss of sensation over the palmar surface of the little and medial ring fingers. Sensation is spared over the hypothenar eminence. Motor fibers are not affected. There is no weakness associated with this lesion.
3. Pure motor syndromes.
 - A. Lesion affecting the deep palmar and hypothenar motor branches (Type 3). This lesion affects the motor trunk proximal to the takeoff of the hypothenar branches. As a result, all ulnar innervated muscles of the hand are involved. Because the sensory branch is not affected, sensation is spared.
 - B. Lesion affecting the deep palmar motor branch only (Type 4). Clinically, there is weakness of lumbricals 1 and 2, as well as ulnar-innervated muscles of the thenar eminence. This type of lesion spares the muscles of the hypothenar eminence.
 - C. Lesion affecting only the distal deep palmar motor branch (Type 5). This type of lesion occurs just proximal to the branches innervating the adductor pollicis and first dorsal interosseous muscles resulting in weakness of these muscles.

Guyon's canal. Five different syndromes have been described secondary to entrapment in this region (See Table 3). Patients may present with sensory and/or motor involvement confined to the distal ulnar nerve distribution. They may have sensory loss, paresthesias, or pain in the region supplied by the distal ulnar sensory branch. The region supplied by the dorsal ulnar cutaneous sensory branch is spared. Motor deficits are limited to the muscles of the hand with sparing of the proximal ulnar-innervated muscles. Examination may demonstrate weakness with atrophy or fasciculations of the intrinsic hand muscles. Tinel's sign may be present over Guyon's canal.

The electrophysiology in this entrapment is often complex. Table 4 outlines a testing protocol for possible ulnar nerve lesions at the wrist. The set up for these studies are the same as for evaluations at the elbow, with the addition of lumbrical–interosseous (See Fig. 7) comparisons. This study allows us to compare ulnar to median nerve conduction across the wrist due to the fact that the 2nd lumbrical muscle (median innervated) overlies the 1st palmar interosseous muscle (ulnar innervated). With this study, disc electrodes are placed with G1 just lateral to the middle of the 3rd metacarpal and G2 over the MCP joint of the index finger. The median nerve and the ulnar nerve are stimulated supramaximally at their usual wrist locations using identical distances.¹

Table 4 Electrodiagnostic evaluation of ulnar neuropathy at the wrist¹

<p>1. Nerve conduction studies (See Figs. 1-7)</p> <p>A. Ulnar nerve studies</p> <ul style="list-style-type: none"> i. Ulnar motor study stimulating at the wrist, below elbow, and above elbow sites while recording from the abductor digiti minimi muscle. ii. Ulnar motor study (bilateral) stimulating at the wrist while recording from the first dorsal interosseous muscle. iii. Ulnar F responses. iv. Ulnar sensory study stimulating at the wrist while recording from the little finger. v. Dorsal ulnar cutaneous sensory study stimulating forearm while recording from the dorsolateral hand. <p>B. Median nerve studies</p> <ul style="list-style-type: none"> i. Median motor study stimulating at the wrist and elbow sites while recording from the abductor pollicis brevis muscle. ii. Median F responses. <p>C. Ulnar–median comparison studies</p> <ul style="list-style-type: none"> i. Lumbrical (2nd)–interosseous (first palmar) comparison study. <p>2. Needle Electromyography</p> <p>A. Routine</p> <ul style="list-style-type: none"> i. One deep palmar motor muscle (e.g., first dorsal interosseous). ii. One hypothenar branch muscle (e.g., abductor digiti minimi). iii. Two forearm muscles (e.g., flexor carpi ulnaris and flexor digitorum profundus III/IV). <p>B. If testing of any of the routine muscles is abnormal, then additional needle examination should include:</p> <ul style="list-style-type: none"> i. At least two nonulnar lower trunk, C8-T1 muscles (e.g., abductor pollicis brevis, flexor pollicis longus, and extensor indicis proprius).
--

Table 5 summarizes typical EDX findings in each of the various syndromes. Magnetic resonance imaging (MRI) may be useful in detecting structural abnormalities affecting the ulnar nerve in Guyon's canal. A variety of different causes have been described.¹¹ A ganglion cyst or traumatic wrist injury account for the majority of cases.¹² In cases in which a structural lesion is identified, surgical removal is recommended. In certain cases, surgical exploration may be considered even when MRI fails to identify a lesion.

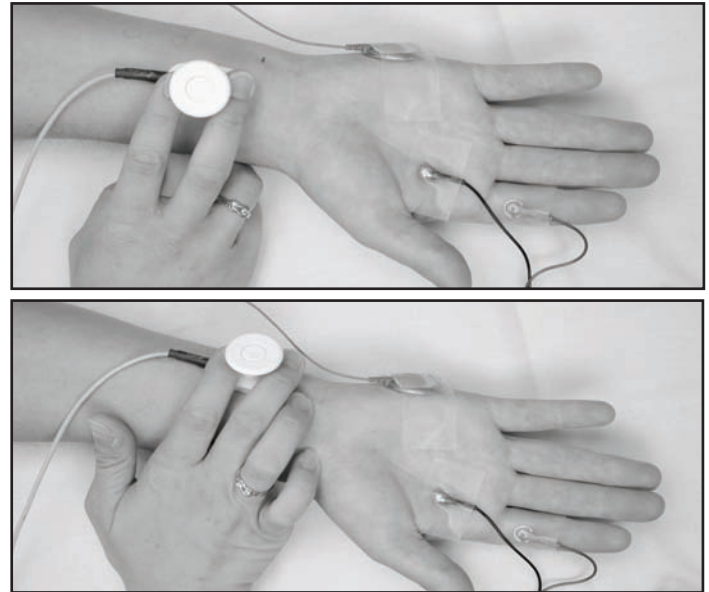


Figure 7 Lumbrical–interosseous motor study. **Top:** Stimulating the median nerve recording at the 2nd lumbrical muscle. **Bottom:** Stimulating the ulnar nerve at the recording interosseous muscle.

Table 5 Nerve conduction study findings in ulnar neuropathy at the wrist¹⁰

<p>1. Combined motor and sensory syndrome (Type 1). Decreased ulnar sensory amplitude. Ulnar motor amplitude is decreased with prolonged distal latency. Needle electromyography (EMG) shows denervation of all intrinsic hand muscles.</p> <p>2. Pure sensory syndrome (Type 2). Decreased ulnar sensory amplitude. Ulnar motor study will be normal. Needle EMG is normal.</p> <p>3. Pure motor syndromes</p> <p>A. Lesion affecting the deep palmar and hypothenar motor branches (Type 3). Ulnar sensory response is normal. Ulnar motor amplitude is decreased with prolonged distal latency. Needle EMG shows denervation of all intrinsic hand muscles.</p> <p>B. Lesion affecting the deep palmar motor branch only (Type 4). Ulnar sensory response is normal. Ulnar motor amplitude is decreased with prolonged distal latency when recording from the first dorsal interosseous muscle. Needle EMG shows denervation of the first dorsal interosseous muscle with sparing of the hypothenar muscles.</p> <p>C. Lesion affecting only the distal deep palmar motor branch (Type 5). Ulnar sensory response is normal. Ulnar motor amplitude is decreased with prolonged distal latency when recording from the first dorsal interosseous muscle. Needle EMG shows denervation of the first dorsal interosseous and abductor pollicis muscles with sparing of the hypothenar muscles.</p>
--

PART II: RADIAL NEUROPATHY

Anatomy

The radial nerve receives fibers from all three trunks of the brachial plexus (C5-T1 roots). The posterior divisions of these three trunks unite to form the posterior cord, which, in turn, gives off the radial nerve. The radial nerve exits the lateral wall of the axilla and travels distally through the proximal arm, just medial to the humerus.

Proximally, three sensory nerves arise from the radial nerve: the posterior cutaneous nerve of the arm, the lower lateral cutaneous nerve of the arm, and the posterior cutaneous nerve of the forearm. These nerves provide sensation to the posterolateral portions of the arm, as well as a small strip along the middle posterior aspect of the forearm. Muscular branches arise next to supply the long, lateral, and medial triceps muscles, as well as the anconeus muscle. Moving distally, the radial nerve wraps around the humerus, traveling in the spiral groove, before giving off additional branches to the supinator, the long head of the extensor carpi radialis, and the brachioradialis muscles.

A few centimeters further, the radial nerve divides into the superficial radial sensory nerve and the posterior interosseous nerve (PIN). The superficial radial sensory nerve travels along the radius, and emerges approximately 5-8 cm proximal to radial styloid to provide sensation over the dorsolateral hand and proximal portions of the dorsal aspect of the thumb, index, middle, and ring fingers. The PIN travels through the supinator muscle and passes under the Arcade of Frohse. The PIN, in turn, supplies muscular branches to the short head extensor carpi radialis, extensor digitorum communis, extensor carpi ulnaris, abductor pollicis longus, extensor indicis proprius, extensor pollicis longus, and extensor pollicis brevis muscles.^{1,2,3,4}

Radial Neuropathy at the Axilla

Radial neuropathy at the axilla results from prolonged compression of the nerve as it courses through the axilla. A common presentation is the patient on crutches who uses them incorrectly thereby applying prolonged pressure to the axilla. Because the lesion occurs proximal to muscular branches supplying the triceps muscle group, the clinical presentation is similar to radial neuropathy at the spiral groove (see below), with the addition of triceps muscle weakness. Additionally, sensory disturbance extending into the posterior arm and forearm due to compression of the posterior cutaneous sensory nerves of the forearm and arm is usually seen.^{1,3}

Radial Neuropathy at the Spiral Groove

Radial neuropathy at the spiral groove is the most common site of radial nerve injury. This usually occurs in the person who has draped an arm over a chair or bench during deep sleep or intoxication ("Saturday Night Palsy"). Other cases can occur after strenuous muscular effort, fracture of the humerus, or infarction

from vasculitis. Patients with this particular entrapment, typically present with wrist and finger drop and decreased sensation over the posterolateral hand in the distribution of the superficial radial sensory nerve. Patients typically have weakness of supination and elbow flexion. However, elbow extension (triceps muscle) will be spared.^{1,3}

Posterior Interosseous Neuropathy

Patients with posterior interosseous neuropathy also present with wrist drop. However, there are several distinct features of this entrapment that distinguish it from lesions at the spiral groove. In a posterior interosseous neuropathy, there is sparing of radial-innervated muscles proximal to the takeoff of the posterior interosseous nerve (triceps, anconeus, brachioradialis, and long head of the extensor carpi radialis muscles). Entrapment usually occurs at the proximal tendinous border of the supinator (Arcade of Frohse). When the patient extends the wrist, they may do so weakly, and with radial deviation. This occurs because the extensor carpi ulnaris is weak, but the extensor carpi radialis is preserved. These patients typically do not experience sensory deficits. Patients may complain of forearm pain resulting from the deep sensory fibers of the PIN that supply the interosseous membrane and joint capsule.^{1,3}

Superficial Radial Sensory Neuropathy

In the forearm, the superficial radial sensory nerve travels subcutaneously next to the radius. Its superficial location makes it susceptible to injury. Sensory disturbances occur over the dorsolateral surface of the hand and fingers. Various objects such as tight fitting bands, watches, bracelets, or handcuffs may lead to a superficial radial neuropathy. As this is a pure sensory neuropathy, these patients do not develop weakness.^{1,3}

Differential diagnosis of wrist drop. The differential diagnosis of wrist drop should include the various radial nerve lesions discussed above. In addition, more proximal lesions such as a posterior cord brachial plexopathy, C7-C8 radiculopathy, or even a central lesion should be considered. A careful clinical examination is invaluable in localizing the lesion causing wrist drop.

Electrophysiology. The electrodiagnostic (EDX) study should identify the presence of a radial neuropathy and properly localize the level of dysfunction. The radial motor study should be performed and compared to the contralateral side. A protocol outlining EDX recommendations for evaluating radial neuropathy is outlined in Table 1.

The radial sensory study (See Fig. 1) is most commonly performed using disc electrodes placed over the superficial radial nerve. G1 is placed over the nerve in the region of the anatomic snuffbox as it travels over the extensor tendons of the thumb. The nerve can often be palpated as it is very superficial in this location. G2 is placed 3-4 cm distal over the thumb. The superficial radial sensory nerve is then stimulated 10 cm proximal over the distal midradius.¹

Table 1 Electrodiagnostic evaluation for evaluating radial neuropathy¹

<p>1. Nerve conduction studies (See Figs. 1-5)</p> <p>A. Radial nerve studies</p> <ol style="list-style-type: none"> i. Radial motor study stimulating at the forearm, elbow, below spiral groove, and above spiral groove sites while recording from the extensor indicis proprius muscle. ii. Superficial radial sensory study. Stimulating at the forearm while recording over the extensor tendons of the thumb. Bilateral studies are recommended. <p>B. Median nerve studies</p> <ol style="list-style-type: none"> i. Median motor study stimulating at the wrist and below elbow sites while recording from the abductor pollicis brevis muscle. ii. Median sensory study stimulating at the wrist while recording from the 1st digit. iii. Median F responses. <p>C. Ulnar nerve studies</p> <ol style="list-style-type: none"> i. Ulnar motor study, stimulating at the wrist, below elbow, and above elbow sites while recording from the abductor digiti minimi muscle. ii. Ulnar F responses. iii. Ulnar sensory study stimulating at the wrist while recording from the 5th digit. <p>2. Needle electromyography</p> <p>A. At least two posterior interosseous nerve-innervated muscles (e.g., extensor indicis proprius, extensor carpi ulnaris, extensor digitorum communis).</p> <p>B. At least two radial-innervated muscles proximal to the posterior interosseous nerve, but distal to the spiral groove (e.g., brachioradialis, long head extensor carpi radialis).</p> <p>C. At least one radial-innervated muscle proximal to the spiral groove (e.g., triceps).</p> <p>D. At least one nonradial, posterior cord-innervated muscle (e.g., deltoid).</p> <p>E. At least two nonradial, C7-innervated muscles (e.g., flexor carpi radialis, pronator teres, flexor pollicis longus, or cervical paraspinal muscles).</p>
--

The radial motor study is performed using disc electrodes with G1 placed over the belly of the extensor indicis proprius muscle (approximately 2-3 finger breadths proximal to the ulnar styloid) while G2 is placed over the ulnar styloid. The radial nerve can then be stimulated in four locations: 1) forearm (See Fig. 2): over the ulna approximately 4-6 cm proximal to G1; 2) elbow (See Fig. 3): in the groove between the brachioradialis and biceps muscles; 3) below spiral groove (See Fig. 4): at the midlateral arm between the triceps and biceps muscles; and 4) above spiral groove (See Fig. 5): over the proximal posterior humerus near the axilla.¹ Comparison of the radial compound muscle action potential (CMAP) with the asymptomatic side is most useful.

Examine at least: two PIN-innervated muscles (e.g., extensor indicis proprius, extensor carpi ulnaris, or extensor digitorum communis muscles); two radial-innervated muscles that are proximal to the PIN, but distal to the spiral groove (e.g., long head

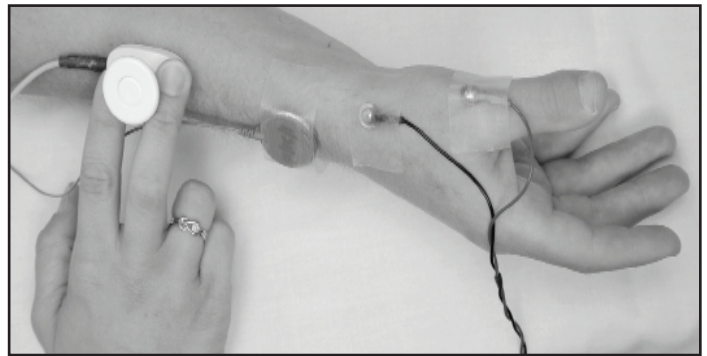


Figure 1 Radial sensory conduction study. The active recording electrode is placed over the palpable portion of the superficial radial nerve. The nerve can be palpated over the extensor pollicis longus tendon. The inactive or reference electrode is placed 3-4 cm distally on the thumb. The ground is placed over the dorsum of the wrist between the stimulating and recording electrodes. The nerve is stimulated the dorsal edge of the radius, 10 cm from the active recording electrode, with the cathode distal to the anode.

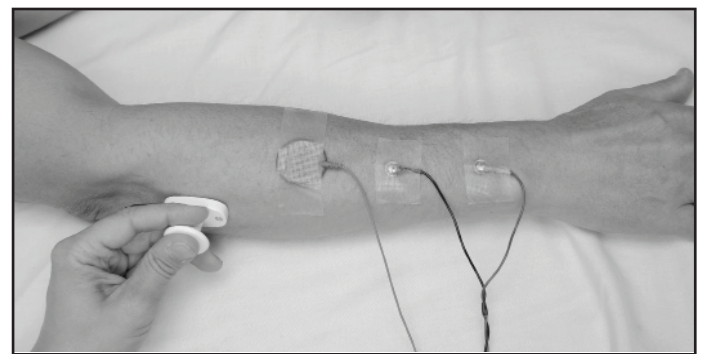


Figure 2 Radial motor conduction study recording from the extensor indicis proprius stimulating at the forearm. The recording electrodes are placed over the belly of the extensor indicis proprius muscle with the active electrode over the belly of the muscle and the reference electrode at least 3 cm distal to the active electrode, over the tendon. The ground is placed between the recording electrodes and the stimulation site on the forearm. The nerve is stimulated distally over the lateral forearm, with the cathode distal to the anode. There is no fixed distance. The radial nerve is stimulated more proximally at the elbow, lateral to the biceps tendon, beneath the brachioradialis muscle. It can be stimulated more proximally over the lateral aspect of the arm at the spiral groove, and also in the supraclavicular fossa (Erb's point). Proximal stimulation may be associated with an initial positive deflection of the compound muscle action potential because of activation of other muscles innervated by the radial nerve.

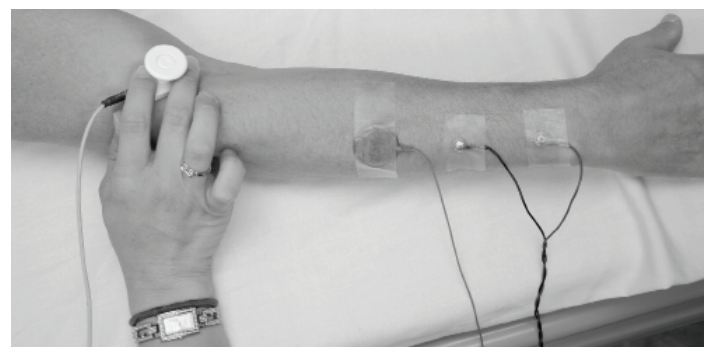


Figure 3 Radial motor conduction study recording from the extensor indicis proprius stimulating at elbow.

of extensor carpi radialis, brachioradialis); two nonradial nerve, C7-innervated muscles (e.g., pronator teres, flexor pollicis longus, flexor carpi radialis, or cervical paraspinal muscles); one radial-innervated muscle proximal to the spiral groove (e.g., triceps muscle); and one nonradial, posterior cord-innervated muscle (e.g., deltoid).¹ Table 2 summarizes the EDX abnormalities that can be encountered in the various radial nerve lesions discussed.

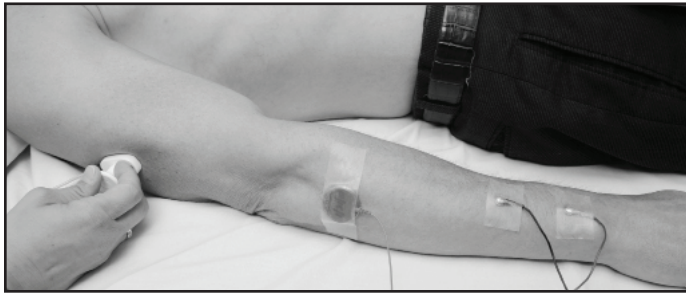


Figure 4 Radial motor conduction study recording from the extensor indicis proprius stimulating below spiral groove.

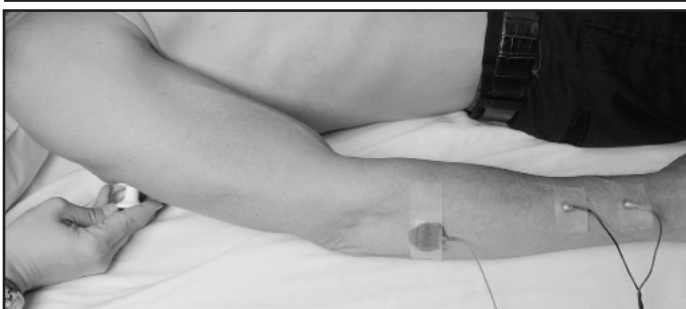

Figure 5 Radial motor conduction study recording at the extensor indicis proprius stimulating above spiral groove.

Table 2 Electrodiagnostic findings in radial neuropathy¹

1. Posterior interosseous neuropathy
A. Nerve conduction studies. Superficial radial sensory response is normal. Radial motor study may show low amplitude response (if axonal) or conduction block at the elbow (if demyelinating).
B. Needle electromyography (EMG). Denervation in the extensor indicis proprius, extensor digitorum communis, and extensor carpi ulnaris muscles
2. Radial neuropathy at the spiral groove
A. Nerve conduction studies. Superficial radial sensory response is low (if axonal). Radial motor study may show low amplitude response (if axonal) or conduction block at the spiral groove (if demyelinating).
B. Needle EMG. Denervation as in posterior interosseous neuropathy plus long head extensor carpi radialis, brachioradialis, and supinator muscles.
3. Radial neuropathy at the axilla
A. Nerve conduction studies. Superficial radial sensory response is low (if axonal). Radial motor study may show low amplitude response (if axonal).
B. Needle EMG. Denervation as in spiral groove, plus triceps muscle.

REFERENCES (PART I)

1. Preston DC, Shapiro BE. *Electromyography and neuromuscular disorders: clinical-electrophysiologic correlations*, 2nd ed. Philadelphia: Elsevier, Butterworth-Heinemann; 2005.
2. Ellis H, Standring S, Gray HD. *Gray's anatomy: the anatomical basis of clinical practice*. St. Louis: Elsevier, Churchill Livingstone; 2005.
3. Bradshaw DY, Shefner JM. Ulnar neuropathy at the elbow. *Neurol Clin* 1999 Aug;17(3):447-461. [PMID: 10393748].
4. Stewart JD. The variable clinical manifestations of ulnar neuropathies at the elbow. *J Neurol Neurosurg Psychiatry* 1987 Mar;50(3):252-258. [PMID: 3031220].
5. Novak CB, Lee GW, MacKinnon SE, Lay L. Provocative testing for cubital tunnel syndrome. *J Hand Surg Am* 1994 Sep;19(5):817-820. [PMID: 7806810].
6. Kothari MJ, Preston DC. Comparison of the flexed and extended elbow positions in localizing ulnar neuropathy at the elbow. *Muscle Nerve* 1995 Mar;18(3):336-340. [PMID: 7870113].
7. AANEM. Practice parameter for electrodiagnostic studies in ulnar neuropathy at the elbow. In: *Guidelines in electrodiagnostic medicine*. Rochester, MN: American Association of Electrodiagnostic Medicine; Reviewed and updated July 2008. <http://www.aanem.org/documents/UlnarNeur.pdf>.
8. Kothari MJ, Heistand M, Rutkove SB. Three ulnar nerve conduction studies in patients with ulnar neuropathy at the elbow. *Arch Phys Med Rehabil* 1998 Jan;79(1):87-89. [PMID: 9440424].
9. Campbell WW, Pridgeon RM, Sahni SK. Short segment incremental studies in the evaluation of ulnar neuropathy at the elbow. *Muscle Nerve* 1992 Sep;15(9):1050-1051. [PMID: 1518514].
10. Wu JS, Morris JD, Hogan GR. Ulnar neuropathy at the wrist. Case report and review of the literature. *Arch Phys Med Rehabil* 1985 Nov;66(11):785-788. [PMID: 4062532].
11. Kothari MJ. Ulnar neuropathy at the wrist. *Neurol Clin* 1999 Aug;17(3):463-476. [PMID: 10393749].
12. Shea JD, McClain EJ. Ulnar-nerve compression syndrome at and below the wrist. *J Bone Joint Surg* 1969 Sep;51(6):1095-1103. [PMID: 5805411].

REFERENCES (PART II)

1. Preston DC, Shapiro BE. *Electromyography and neuromuscular disorders: clinical-electrophysiologic correlations*, 2nd ed. Philadelphia: Elsevier, Butterworth-Heinemann; 2005.
2. Ellis H, Standring S, Gray HD. *Gray's anatomy: the anatomical basis of clinical practice*. St. Louis: Elsevier, Churchill Livingstone; 2005.
3. Wheelless CR. *Wheelless' textbook of orthopaedics*; 2009. http://www.wheellessonline.com/ortho/radial_nerve.
4. Carlson N, Logigian EL. Radial neuropathy. *Neurol Clin* 1999 Aug;17(3):499-523. [PMID: 10393751].

The Tibial and the Common Peroneal Nerves

Kimberley B. Butler, R.NCS.T., R. EP T., CNIM

Electroneurodiagnostic Technologist

Hartford Health Care

Willimantic, Connecticut

INTRODUCTION

The major motor nerves of the lower extremities include the sciatic nerve, which becomes the tibial and the common peroneal nerves. The common peroneal nerve eventually splits into the superficial peroneal and deep peroneal nerves. Other important lower extremity nerves include the femoral nerve and the obturator nerve.

The major proximal sensory nerves of the lower extremity include the lateral femoral cutaneous nerve, and the terminal sensory branch of femoral nerve, the saphenous nerve. The “gold standard” of sensory nerve conduction studies (NCSs) in the lower extremities is the sural nerve, which most literature agrees has contributions from both the tibial and the common peroneal nerves. Other important sensory nerves of the lower extremity are the terminal sensory nerve branches of the common peroneal nerve, in particular the superficial peroneal sensory nerve.

All of these nerves have in common an origin from the lumbosacral plexus. Although not as important in localization during NCSs as the brachial plexus, a good overall knowledge base of the lumbosacral plexus is important. At first glance, the lumbosacral plexus can be a bit intimidating, a giant snarl that seems daunting to break down into pieces small enough to reproduce. The best way is to break it down into two separate plexi: the lumbar plexus and the sacral plexus. Because the focus here is on the peroneal and posterior tibial nerves, this paper will concentrate on the sacral plexus as this is the area from which most of the axons originate and thus give rise to these nerves.

BASIC NERVE LOCALIZATION

The sciatic nerve is formed by the union of the L4-S2 roots. It is important to be aware that the sciatic nerve actually is two separate nerves traveling together: the common peroneal nerve, which originates from the posterior division of the sacral plexus, and the posterior tibial nerve, which originates from the anterior division of the sacral plexus. As the two nerves travel together down the thigh, the peroneal portion is lateral to the tibial. Knowing the placement of these nerves is important when encountering lesions of the sciatic nerve (see below). Another important anatomical fact is although the superior and inferior gluteal nerves arise from similar nerve roots, they do not travel with the sciatic nerve. This is important in localization, because a lesion involving an L5 root would impact both L5-innervated muscles supplied by the sciatic nerve and the gluteal nerves, whereas a lesion localized to the sciatic nerve would spare the gluteal nerve-supplied muscles. Another clinical point of interest is the lumbosacral trunk, a small branch which connects the lumbar plexus to the sacral plexus. This lumbosacral trunk arises from the L4 root level and travels with the sciatic nerve. Of interest, the only muscle which is supplied by the sciatic nerve and commonly thought to contain a significant L4 component is the tibialis anterior.

Dermatomes

Dermatomes are the areas of cutaneous sensation supplied by the individual nerve root levels. The dermatomes are relatively easy to

remember and extremely helpful from a clinical perspective. If you remember that the dermatome (which supplies the lateral aspect of foot posterior to the medial malleolus) is S1, then you know that the sural nerve derives its axons from the S1 root level. They are also helpful in assessing involvement of individual nerve roots in radicular lesions. If the patient complains of sensory changes on the dorsum of the foot, an understanding of the L5 dermatomal pattern distribution allows a differential diagnosis with possibility of L5 nerve root involvement. Another simple way to remember the dermatome arrangement is to envision the human body with the arms out stretched and the legs positioned into a split and then send it through a meat slicer at a deli! The dermatomes for the most part form fairly straight lines, and, hence, could be easy to identify and thus to remember.

Cutaneous Distribution

Understanding the cutaneous distribution of individual lower extremity sensory nerves also is important in localization. Lesions of individual peripheral nerves have distinct areas of sensory changes. A solid understanding of dermatomes will give rise to a list of differential diagnoses. In the earlier case of an individual with numbness of the dorsum of the foot, this area of distribution is not only the L5 root dermatome but also the sensory distribution of the superficial peroneal sensory nerve. This knowledge will provide a good starting point to design a planned study with a differential diagnosis of L5 root involvement versus peroneal nerve palsy. These cutaneous distributions are addressed further in the discussion of individual nerves.

INDIVIDUAL NERVES AND COMMON NERVE CONDUCTION STUDIES

Working from proximal to distal starting with the sciatic nerve, individual nerves and the NCSs commonly performed will now be addressed. First, a note on normal values. There are a number of published normal values which can be utilized depending on the preference of the examiner. The most important aspect of normal values is that the exact technique the original author described be reproduced. This includes recording and stimulation sites and set distal stimulation sites. Although some laboratories routinely utilize "anatomical" sites for distal stimulation most literature recommend using a set distance with published normal values to be the best technique. As stated earlier, the sciatic nerve arises from root levels L4-S2. It is two separate nerves traveling side by side. The peroneal portion lies more to the lateral and the tibial stays more to the medial side. This is an important point because oftentimes in a lesion of the sciatic nerve, the peroneal portion will be more involved clinically because of its fascicle placement, which is more lateral and thus more prone to pressure type injury. In the upper thigh the sciatic nerve innervates (supplies) the semimembranosus, semitendinosus, biceps femoris, and adductor magnus muscles. Most needle electromyography (EMG) studies of this muscle group is performed on the long and short heads of the biceps femoris. An important point of localization here is that the long head is innervated by the tibial portion of the sciatic nerve and the short head is innervated by the peroneal portion. The short head of the biceps

femoris is the only muscle above the knee innervated by the peroneal nerve. The clinical importance of this will be discussed below.

Any local entrapment or injury of the sciatic nerve in the upper thigh generally is produced by trauma. Prolonged pressure may produce a syndrome referred to as rhabdomyolysis, the breakdown of muscle fibers resulting in the release of muscle fiber contents (myoglobin) into the bloodstream which can have severe consequences not only to muscle but also to the kidneys. Trauma can also be caused by knife and gun shot wounds, hematomas, and iatrogenic injury, such as stretch injuries following hip replacement and other surgeries.

At about the level of the knee, in the popliteal fossa the sciatic nerve bifurcates into the tibial and the common peroneal nerve. The tibial nerve descends deep into the calf, and the common peroneal wraps around the fibular head laterally.

The tibial nerve originates from the L5, S1, and S2 nerve roots. It innervates the plantar flexors and invertors of the foot at the ankle. The sensory nerves arising from the tibial nerves are the medial and lateral plantar nerves which provide cutaneous sensation to the bottom of the foot, the calcaneal nerve which provides cutaneous sensation to the bottom of the heel, and the sural communicating branch to the sural nerve. The important tibial-innervated muscles in the lower leg include the medial gastrocnemius (S1-S2), the lateral gastrocnemius (L5-S1), the soleus (S1-S2), the tibialis posterior (L5-S1), the flexor hallucis longus (L5-S1-S2), and the flexor digitorum longus (L5-S1-S2) muscles. At the level of the medial malleolus, the tibial nerve divides into the medial and lateral plantar nerves. These two nerves innervate most of the muscles of the foot, similar to the median and ulnar nerves in the hand. The discussion below illustrates medial and lateral plantar innervated muscles.

Motor NCSs of the tibial nerves are performed routinely and are fairly easy. Most literature recommends using the abductor hallucis (AH) muscle on the medial aspect of the foot, two finger widths distal to the navicular bone, as an active recording site (G1) and reference (G2) placed distally using the "belly tendon" method, ensuring that the reference is completely off the muscle. The fascicles of the lateral plantar nerve can be evaluated by placing the recording electrodes on the lateral aspect of the foot over the abductor digiti minimi (ADM) muscle. Stimulation is conducted at a preset distance from G1 posterior to the medial malleolus. Proximal stimulation is conducted in the popliteal fossa (see Fig. 1). Because the nerve at times lies very deep at the popliteal fossa, increased pressure and increased stimulus duration is often required to overcome this potential submaximal stimulation. Generally, a compound muscle action potential (CMAP) of at least 50% of the amplitude of the CMAP acquired distally is considered acceptable. Careful observation to ensure plantar (downward) flexion should be noted. When dealing with difficult cases, placing an ancillary electrode into the anode insertion of the stimulator and placing the surface electrode anteriorly (on the knee) may help in acquiring adequate stimulation to depolarize the nerve.

Sensory contributions of the tibial nerve include the sural communicating branch, which provides cutaneous sensation to the lateral

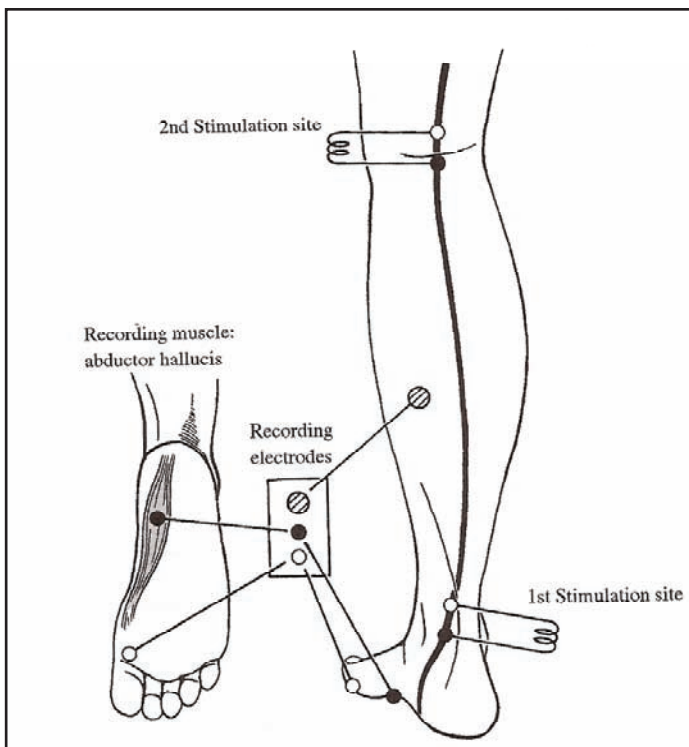


Figure 1 Tibial motor study.³

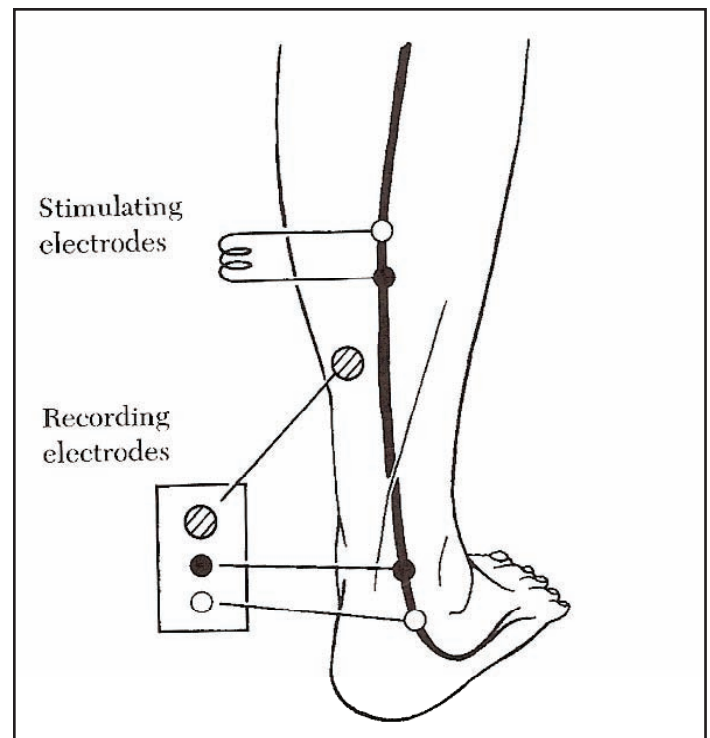


Figure 2 Sural sensory study.³

aspect of the foot, the medial and lateral plantar nerves, and the calcaneal nerve. As stated earlier, the sural nerve is considered the gold standard of sensory responses that can be recorded in the lower extremity. Although primarily from tibial nerve, it is thought to have some contributions from the deep peroneal nerve as well. Routine nerve conduction velocity (NCV) studies of the sural nerve can be recorded placing G1 just posterior to the lateral malleolus and G2 3-4 cm distal. Stimulation is performed midcalf at a set distance (often 14 cm) (see Fig. 2). Medial and lateral plantar responses can also be recorded routinely, both antidromically and orthodromically. The orthodromic technique is performed by placing G1 on the main trunk of the tibial nerve at the level of the ankle and G2 3-4 cm proximal. Stimulation is then performed on both the medial and lateral aspect of the plantar surface of the foot (see Fig. 3). Generally speaking this study is performed with a “side-to-side” comparison rather than a pre-set distance technique. Technical difficulty can occur because of high resistance of the plantar surface of the foot creating stimulus artifact. Although some literature has reported performing NCSs on the calcaneal nerve, the possibility of volume conduction from the main trunk of the tibial nerve makes its reliability questionable.

Injuries to the posterior tibial nerve in the lower leg are often traumatic in nature: direct trauma, such as knife or gun shot injuries, and stretch injuries involving the knee, which often involve both the common peroneal and tibial nerves. In such cases, often the peroneal is more involved than the tibial nerve. Some injuries result in a compartment syndrome, which is the compression of nerves, blood vessels, and muscle inside a closed space (compartment) within the body, leading to tissue death due to lack of oxygenation as the blood vessels are compressed by the raised pressure within the compartment. Again, both the tibial and peroneal nerves are in-

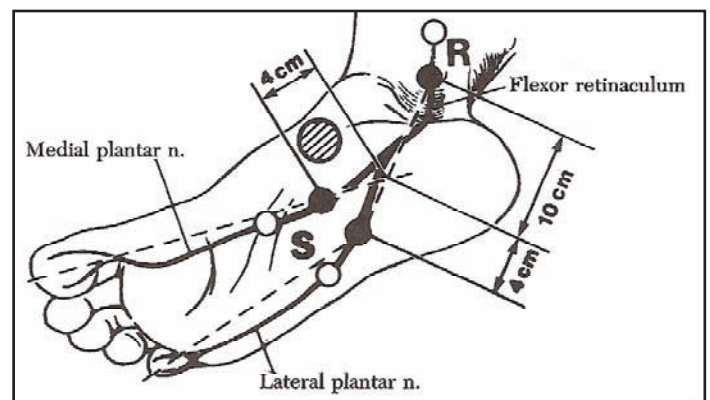


Figure 3 Orthodromic method for medial and lateral plantar studies.³

involved but oftentimes the fascicles of the peroneal nerve have a predilection to sustain more severe injury. Distal tibial nerve injuries at the ankle, including “tarsal tunnel syndrome,” often resemble carpal tunnel-like syndrome in their symptomatology. Iatrogenic injury following surgery can also produce injury to the tibial nerve in the lower leg and foot.

The common peroneal nerve originates from the L4, L5, and S1 root levels. It bifurcates below the knee into the deep peroneal and superficial peroneal nerves. The level of this bifurcation can vary somewhat, having a potentially large impact on selective fascicular involvement in peroneal nerve injuries at the fibular head. Normal variations of bifurcation of the common peroneal nerve can affect which muscles are clinically weak in a peroneal palsy. Recording from various deep and superficial peroneal-innervated muscles may be helpful in such cases.

The deep peroneal nerve travels deeply into the anterior compartment of the foreleg and innervates the muscles of ankle dorsiflexion, including the tibialis anterior, extensor hallucis longus, and peroneus tertius muscles. In the foot it innervates the extensor digitorum brevis (EDB) and the first dorsal interosseous (FDI) muscles and provides cutaneous sensation to the wedge between the first and second toes. The superficial peroneal nerve innervates muscles of ankle eversion, including the peroneus longus and peroneus brevis. It provides cutaneous sensation to the dorsum of the foot and to the lateral lower leg.

Injuries to the common peroneal nerve and its branches include many of the same types of injuries affecting the posterior tibial nerve, such as direct trauma. Because of its position it often has a predilection to compression injuries and often is more clinically involved in lesions affecting both the tibial and peroneal nerves. The common peroneal nerve is also subject to compression at the fibular head, where it becomes quite superficial, and may be damaged in stretch injuries involving the knee and in compartment syndromes. Distal superficial peroneal nerve injuries sometimes referred to as anterior tarsal tunnel syndrome and iatrogenic injury are all seen.

NCSs of the deep peroneal nerve are commonly performed recording from the EDB using the belly tendon method of motor NCSs. Stimulation is performed at the ankle at a preset distance and below and above the fibular head (see Fig. 4). Conduction velocities are measured between the ankle and a site below the fibular head, and from below to above the fibular head. The distance between the below and above fibular head segment ideally should be around 10 cm but often a shorter distance is required to ensure no volume conduction to the posterior tibial nerve. Careful observance of the

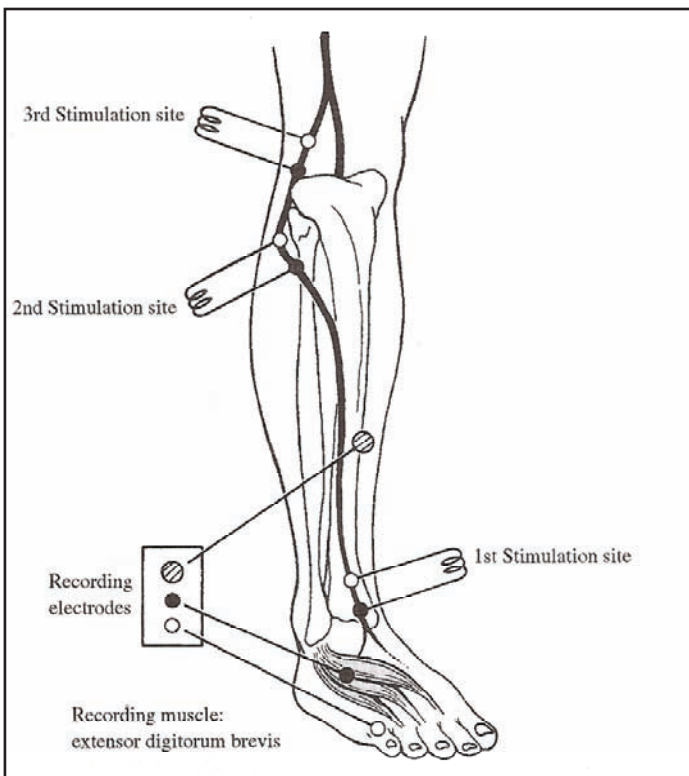


Figure 4 Common peroneal motor study.³

clinical movement of the foot to stimulation is critical to avoid volume conduction response. When performing deep peroneal motor studies from the EDB, the examiner should always be on the look out for possible accessory peroneal anomaly. This occurs when the lateral aspect of EDB is innervated by fibers following the superficial rather than the deep peroneal nerve. In such instances, higher amplitude is noted with proximal rather than with distal stimulation. To confirm, stimulate just posterior to lateral malleolus. If an accessory peroneal anomaly is present a small CMAP will be recorded from the EDB (see Fig. 5). Motor studies also can be acquired recording from the tibialis anterior and the peroneus longus while stimulating at the fibular head. Such studies can be very helpful in acquiring additional information about selective fascicular involvement to individual muscles innervated by both the deep and superficial peroneal nerve. Such information may be very helpful in confirming localization of a peroneal palsy. Oftentimes conduction block (abnormal amplitude drop over a short segment) or focal slowing of conduction velocity may be noted.

Sensory NCSs of the superficial peroneal nerve can be performed both antidromically and orthodromically. The antidromic method is performed by placing the active (G1) electrode over the dorsum of the foot slightly lateral to midline. The reference electrode is placed 3-4 cm distal. Stimulation is performed at a preset distance in the groove just posterior to the insertion of the peroneus longus (see Fig. 6). This sensory study can be invaluable in evaluating demyelination in peroneal nerve injury at the fibular head. In a purely demyelinating lesion, everything below the lesion will be completely normal. If a patient presented with a completely flaccid foot unable to dorsiflex the foot at all, a normal superficial peroneal sensory study would strongly suggest a demyelinating injury at the fibular head. This is because there is a conduction block-type injury and the axons themselves remain intact. This type of scenario (i.e., a normal superficial peroneal sensory study and a completely flaccid foot) would suggest a complete conduction block. When performing motor studies on this type of injury no response would be obtained at the stimulation site above the site of the injury (e.g., the fibular head). Such lesions are often incomplete or "mixed" type lesions. In a partial conduction block injury, for instance, an abnormal amplitude CMAP would be obtained above the site of the lesion. Usually, at least a 50% drop in amplitude is needed to diagnose partial conduction block. Milder injuries can cause weakness and sensory change. If only the largest myelinated axons were affected, a slowing in conduction velocity may be the only abnormality noted. Usually a slowing of greater than 10% is considered significant. Because certain fascicles can be affected differently, performing studies from multiple muscles may be helpful. It is not unusual to note partial conduction block to some fascicles and only conduction slowing to others. For practical purposes, no reliable sensory study routinely is obtained from the deep peroneal nerve.

From an electrodiagnostic (EDX) standpoint, the short head of the biceps femoris should be mentioned in the discussion of peroneal nerve palsy localized at the fibular head as it is the only muscle innervated by the peroneal portion of the sciatic nerve above the knee. This is extremely useful in localizing peroneal mononeuropathies. In severe (complete) peroneal neuropathies in which the NCSs are not helpful in localizing the lesion to the fibular head needle examination of the short head of the biceps femoris maybe

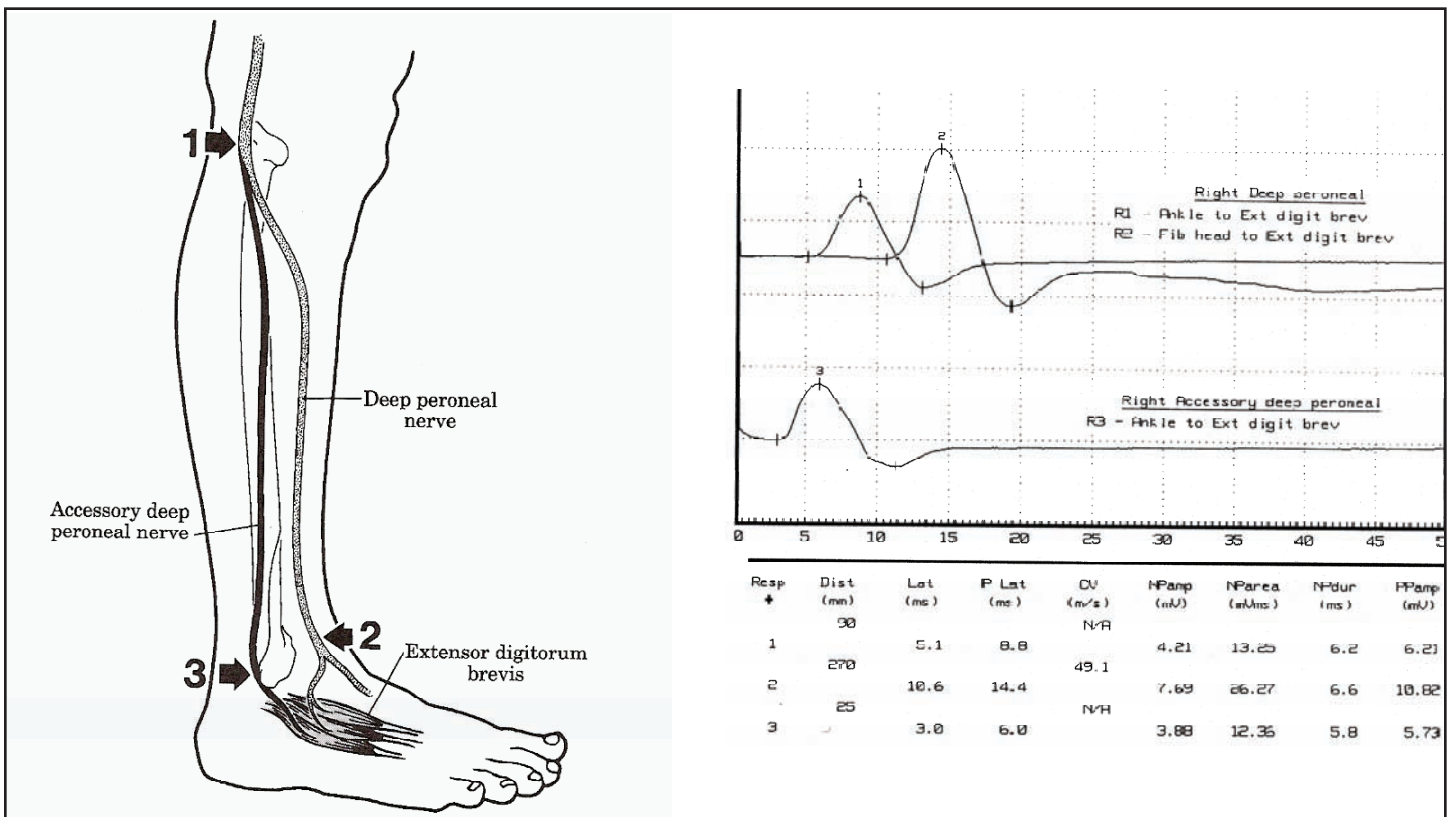


Figure 5 Accessory peroneal study.³

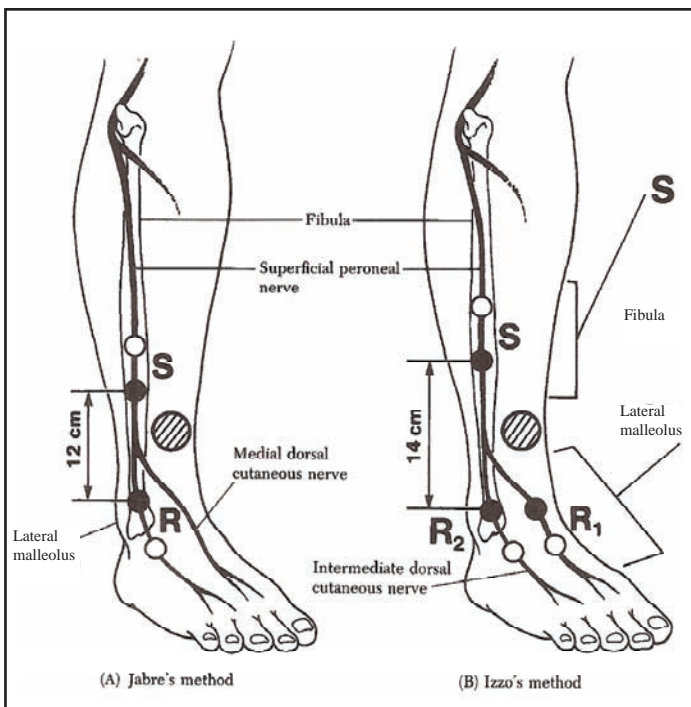


Figure 6 Superficial peroneal sensory studies.³

All figures used with permissions from Oh.³

SUGGESTED READING

1. DeLagi EF, Perotto A. Anatomic guide for the electromyographer, 2nd ed. Springfield, IL: Charles C. Thomas; 1980.
2. Wilbourn AJ, Aminoff MJ. AAEM Minimonograph #32: The electrodiagnostic evaluation in patients with radiculopathies. Muscle Nerve 1998;21:1612-1631.
3. Oh S. Clinical electromyography, nerve conduction studies, 3rd ed. Philadelphia: Lippincott Williams & Wilkins; 2002.
4. Stewart J. Focal peripheral neuropathies, 2nd ed. Philadelphia: WB Saunders; 1993.

the only localizing evidence. A normal needle examination of this muscle indicates that the lesion is distal to the branch supplying this muscle, and this is likely at or below the fibular head.

Median Nerves and Nerves of the Face

Jerry Morris, MS, R.NCS.T.

Electrodiagnostic Technologist
Neurodiagnostic Laboratory
Willis-Knighton Medical Center
Shreveport, Louisiana

PART ONE: FACIAL NERVE, TRIGEMINAL NERVE, AND BLINK REFLEXES: ANATOMY, TECHNIQUES, AND APPLICATIONS

Anatomy

For electrodiagnostic (EDX) studies on the face, two particular studies may be performed. The first study, the facial nerve motor study, uses cranial nerve (CN VII). Even though the facial nerve has both sensory and motor components, this discussion will focus only on the motor component. The second study, the blink reflex study, utilizes the sensory portion of the trigeminal nerve (CN V) a motor and sensory nerve, and the motor component of the facial nerve (CN VII).

Trigeminal Nerve

The trigeminal nerve (CN V) is the largest of the cranial nerves. It is composed of three divisions, hence the name trigeminal. The third division is the mandibular division which has both motor and sensory components. The second division is the maxillary division which has only a sensory component. The first division is the ophthalmic division, also a purely sensory division. The ophthalmic division forms three nerves: the nasociliary, lacrimal, and frontal nerves. The frontal nerve then becomes the supraorbital nerve, the nerve stimulated in blink reflex studies. The supraorbital nerve emerges onto the forehead at the supraorbital notch, just above the eye. It then sends medial and lateral branches to the skin of the eyelid and scalp (see Figs. 1 and 2).

Facial Nerve

The facial nerve (CN VII) has both sensory and motor components. The sensory portion includes taste from the anterior two thirds of the tongue. The motor component becomes the nerve of facial expression.

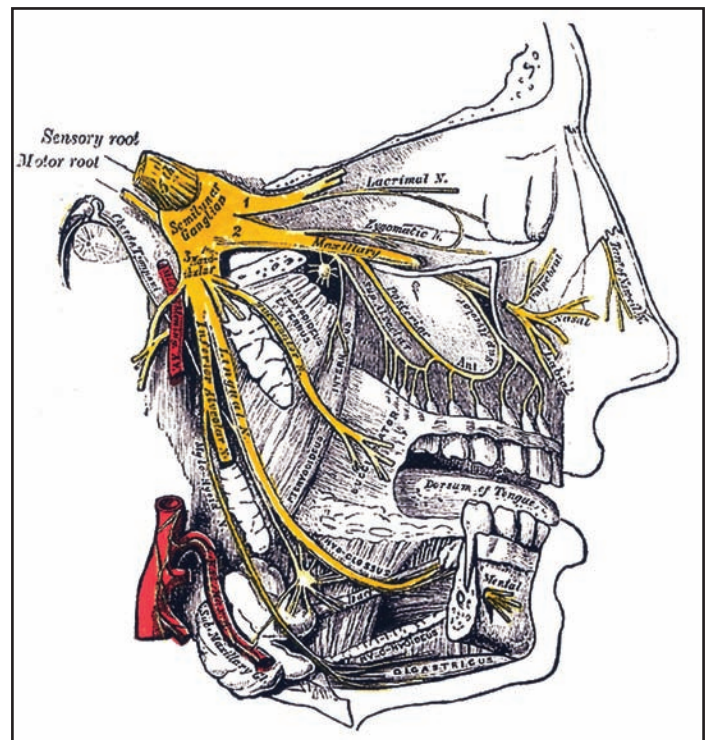


Figure 1 Trigeminal nerve.

From wikipedia.org (originally from *Gray's Anatomy*, fig. 778).

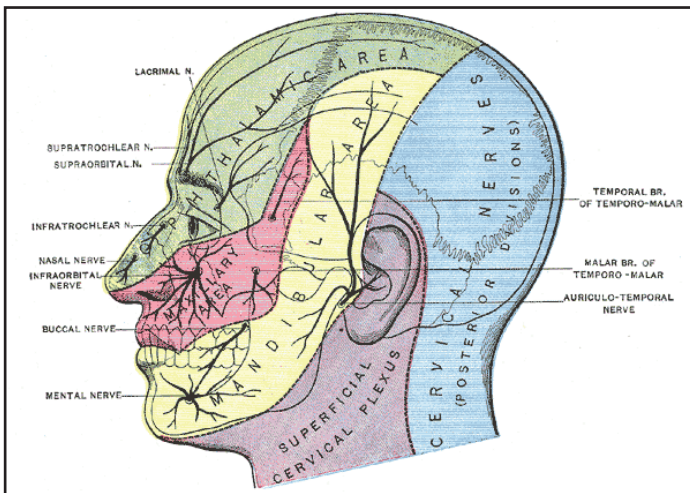


Figure 2 Dermatome distribution of the trigeminal nerve.

From wikipedia.org (originally from *Gray's Anatomy*, fig. 784).

The facial nerve motor components arise from the pons while the sensory component arises from the nervus intermedius. The facial nerve leaves the brainstem at the cerebropontine angle (CPA) and enters the petrous temporal bone and the internal auditory meatus. It then courses through the facial canal and emerges at the stylomastoid foramen. It then passes through, but does not innervate, the parotid gland. It then divides into five branches on the face. From top to bottom they are the temporal branch, the zygomatic branch, the buccal branch, the marginal mandibular branch, and the cervical branch.

The temporal branch innervates the frontalis muscle which elevates the eyebrows and wrinkles the forehead. The temporal and zygomatic branches innervate the orbicularis oculi muscle, the muscle that closes the eyelids. This muscle will be the recording site for blink reflex studies and one of the sites for facial motor studies. The buccal branch then innervates two muscles, the nasalis which flattens the nose and flares the nostrils and the orbicularis oculi which purses the lips. This is the "kissing muscle." The marginal mandibular branch innervates the mentalis muscle which elevates the skin of the chin. The cervical branch innervates the platysma muscle which draws the corner of the mouth inferiorly as in sadness and fright and draws down the skin of the lower lip when grimacing (see Fig. 3 and 4).

Technique

In performing a facial study, the orbicularis oculi muscle will be used as the active recording site. The reference electrode will be the orbicularis oculi muscle on the side opposite the stimulation site. The ground is placed on the chin. Once one side is completed, switch the stimulator to the other side while switching the active recording and reference electrodes. Always perform side-to-side comparisons. Use a sweep speed of between 2-5 ms/div, a gain of 500 μ V to 2 mV, and motor nerve filter settings of 1.6 Hz-8 kHz (low to high). The stimulator is placed slightly off the mandible. This is where the facial nerve emerges from the skull at the stylomastoid foramen. Once the maximal response is obtained, the

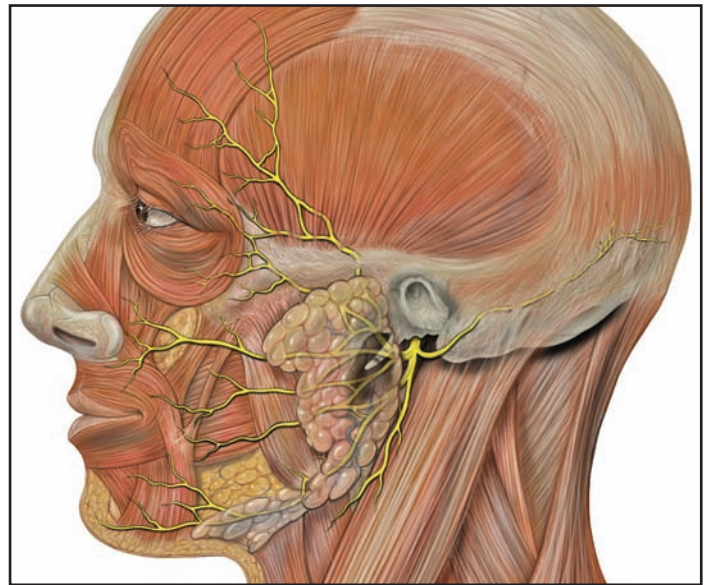


Figure 3 Facial nerve branches.

From wikipedia.org, Patrick J. Lynch, medial illustrator, with permission.

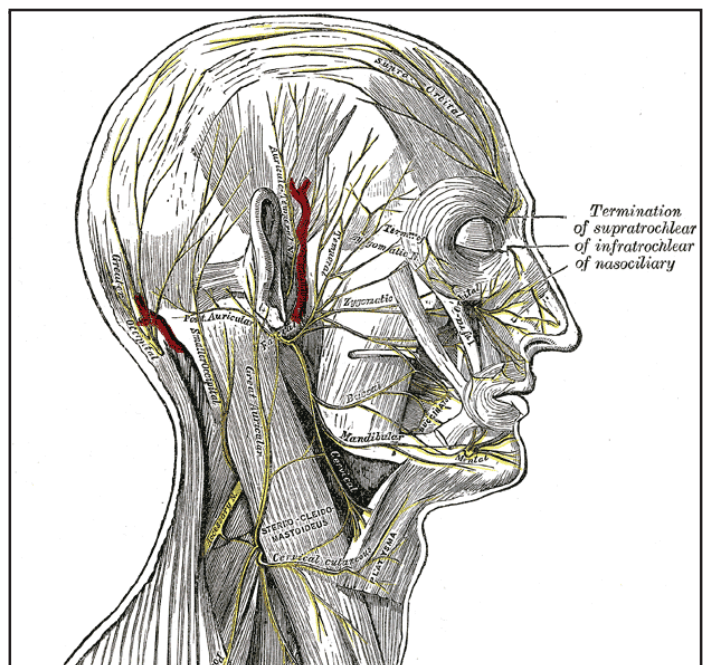


Figure 4 Facial nerve.

From wikipedia.org (originally from *Gray's Anatomy*, fig. 790).

distal latency is measured from the onset of the response. The amplitude is measured from the baseline to the peak of the negative deflection. Normal distal latencies should be between 3-4 ms with amplitudes between 1-4 K. Most often in abnormalities the amplitude drops by greater than 50% when compared to the other side. The latency may also be prolonged by 20-30% on the affected side (see Figs. 5 and 6).

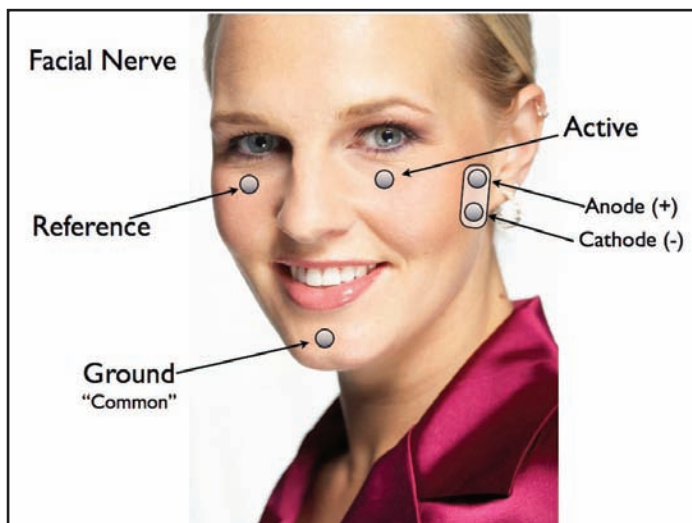


Figure 5 Placement of electrodes in a facial study.

© 2010 Jupiterimages Corporation

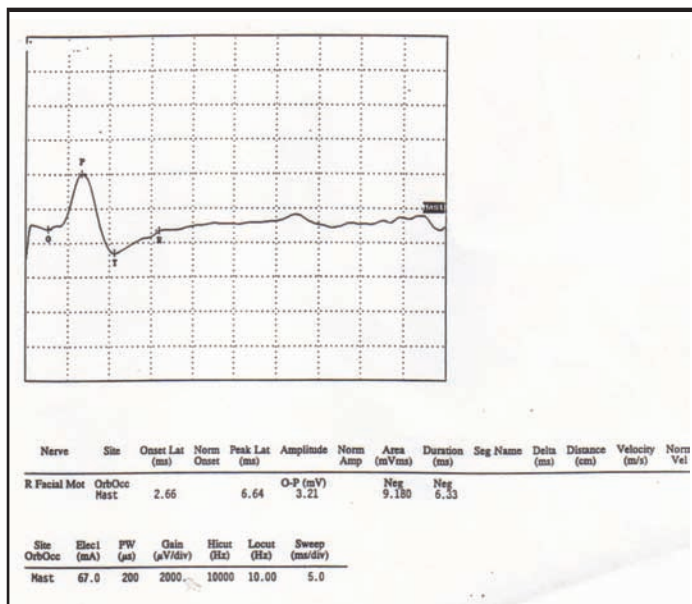


Figure 6 Facial motor nerve study of the orbicularis oculi muscle.

Amp = amplitude, Elect = electrical, Lat = latency, Mast = mastoid, Mot = motor, Norm = normal, OrbOcc = orbicularis oculi, PW = pulse width, R = right, Seg = segment, Vel = velocity

Applications

The facial nerve motor study is most often helpful in patients with Bell's palsy (cranial mononeuropathy of CN 7). This usually affects one side and is characterized weakness of the entire side of the face, with inability or weakened ability to wrinkle the forehead, close the eye, or smile on the affected side. Many causes have been found for Bell's palsy:

- Early Guillain-Barré syndrome
- Any trauma, especially to the ear area

- Infections of the ear
- Diabetes
- CPA tumors
- Viral infections
- No cause determined (the majority of cases)

The facial nerve may be used as a proximal nerve to stimulate for repetitive stimulation. Many patients with myasthenia gravis demonstrate a decrement on repetitive nerve stimulation here despite normal repetitive stimulation studies of more distal nerves such as the median and ulnar nerves of the hand. The setup for this procedure is the same with multiple stimuli given instead of single shocks. Exercise is performed by tightly closing the eyes (see Fig. 7).

Blink Reflex

A blink reflex is a polysynaptic reflex consisting of two components. The afferent arc of this reflex is the stimulation of the sensory division of the trigeminal nerve and the efferent arc is the corresponding motor axon response by the facial nerve. This arc checks two cranial nerves: the 5th or trigeminal nerve and the 7th or facial nerve. Blink reflexes are one of the least understood of the cranial EDX procedures, probably because their mechanisms and pathways are poorly understood. With a little knowledge and time, the blink reflex may become one of the easiest EDX tests to perform. It will also provide added information to the physician about certain neuropathies and diseases involving the face. Two components of the response will show up on the stimulated side and one component on the opposite side in normal subjects. Delays in these components will help locate the area of the lesion and help the physician with diagnosis.

Technique

In recording blink reflexes, both eyes may be set up at the same time. For Channel 1, place an active recording electrode on the orbicularis oculi muscle, just directly below the pupil of the eye. The reference electrode is placed on the outer canthus of the eye. For Channel 2, repeat the above procedure for the other eye. The ground is placed on either the chin or the forehead, between the two recording sites.

Care should be used in stimulating for the blink reflex. If possible, a smaller stimulator with smaller prongs needs to be used. This area of stimulation above the eye is very sensitive therefore, it is essential to be very careful while stimulating. Place the cathode directly over the supraorbital branch of the trigeminal nerve at the point on the eyebrow where the nerve goes through the frontal notch. This notch can be felt by rubbing a finger along the upper eyebrow. The cathode should be on the forehead. Sweep speeds should be between 10-15 ms/div with a gain setting of between 100-500 µV. Use sensory study stimulus intensity, allowing 3-4 s

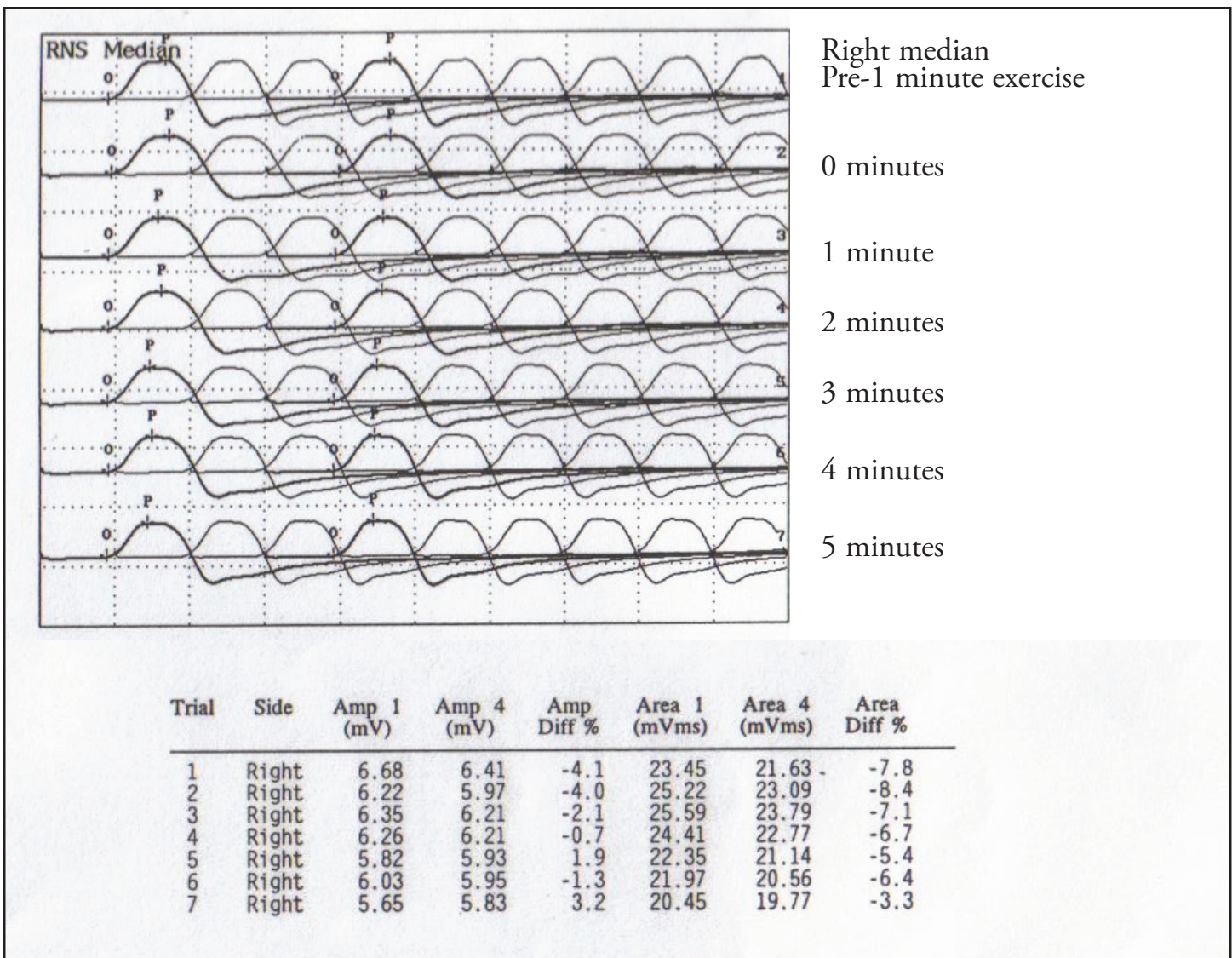


Figure 7 Repetitive nerve stimulation of the facial nerve.

Amp = amplitude, Diff = difference

between shocks. In normal subjects an R1 component should appear between 8-13 ms ipsilaterally. An R2 component should also appear between 28-42 ms ipsilaterally. In addition, an R2 component should appear between 29-44 ms contralaterally. Give several series of stimuli, rotating the anode until the best response is obtained. When finished with stimulation on this side, leave the recording electrodes where they are and stimulate the opposite side. This allows observation of the R1 response on this side as well. This R1 component is thought to be a response of the pathway between the trigeminal nerve sensory nucleus and the ipsilateral facial nerve (disynaptic response). It is only seen on the side of stimulation. The R2 component is a representation of the polysynaptic connection between the trigeminal nerve spinal nucleus and the facial nerve nuclei bilaterally. Thus, in normal subjects, it should be seen on both sides. Latencies from R1 and R2 should be seen on both sides. Latencies from R1 and R2 should be compared on a side-to-side basis. Although amplitudes of R1 and R2 are not measured, it may be useful to notice if there is a side-to-side amplitude difference,

providing that the stimulus and recording parameters are the same (see Figs. 8 and 9).

Applications

Blink reflexes are performed in conjunction with facial nerve stimulation. Several proven usages for blink reflexes have been recognized:

- The blink reflex is a more sensitive study than the facial nerve study alone. It provides information about both proximal and distal conduction within the facial nerve.
- Blink reflexes are especially helpful in evaluating Bell's palsy.
- Blink reflexes may aid the diagnosis of early Guillain-Barré syndrome, because this may be the earliest detectable abnormality.

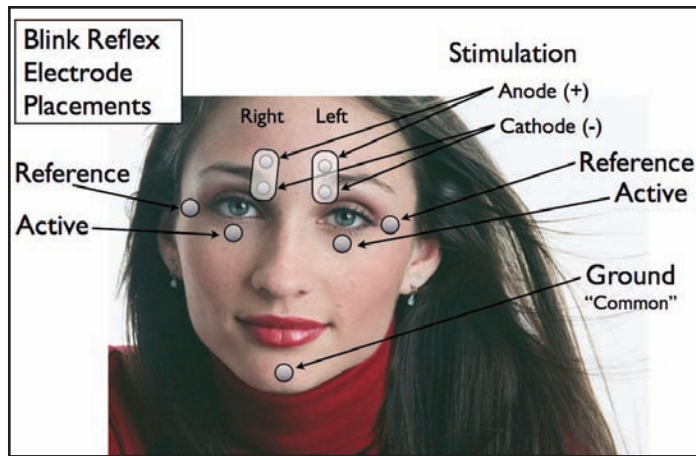


Figure 8 Blink reflex electrode placements.

© 2010 Jupiterimages Corporation

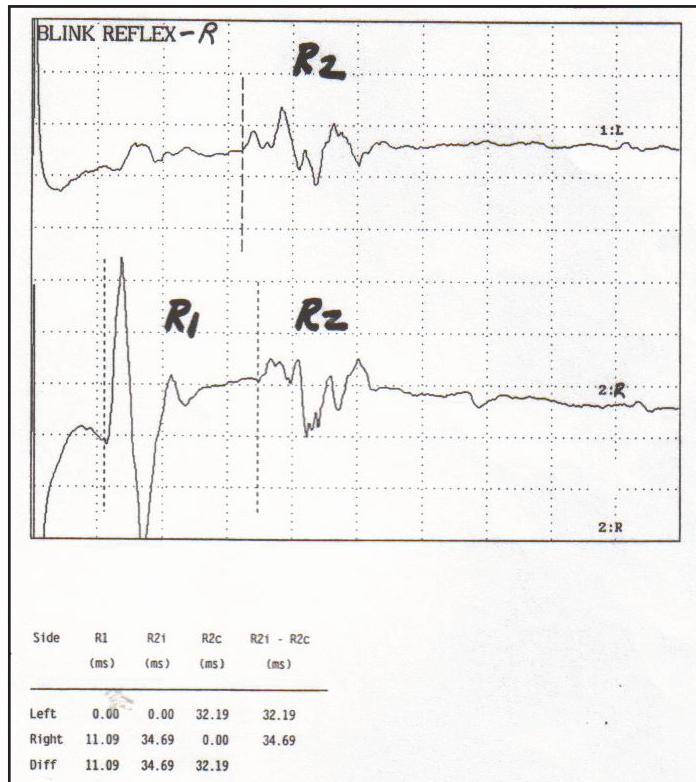


Figure 9 Blink reflex study.

Diff = difference

mality. It may also aid in diagnosing other demyelinating diseases such as multiple sclerosis.

- Blink reflexes are extremely helpful in diagnosing CPA tumors such as acoustic neuromas.

PART TWO: THE MEDIAN NERVE: ANATOMY, TECHNIQUES, AND ENTRAPMENTS

Anatomy

The median nerve arises from C6-T1 roots. It is formed by the lateral and medial cords of the brachial plexus. After exiting the plexus, the median nerve travels with the brachial artery down the medial aspect of the biceps muscle to the biceps tendon. It then courses down the center of the forearm, innervating the pronator teres muscle and the flexor muscles of the forearm, and branches off to form the anterior interosseus nerve, a pure motor nerve. It then passes between the flexor carpi radialis and palmaris longus tendons. It next passes through the carpal tunnel, a region located distal to, and in the middle of, the wrist crease. The motor branch then innervates the abductor pollicis brevis (APB) and the thenar eminence. The sensory branches then provide sensation to the palm, the thumb, the index, and the middle fingers. It also provides sensation to the lateral aspect of the 4th finger. The sensory potential from the thumb may be used to specifically access the C6-C7 nerve roots, upper and/or middle trunk, and lateral cord of the brachial plexus (see Fig. 10).

Median Motor Nerve Study Technique

The following is the procedure for the median motor nerve study (see Fig. 11).

Recording electrodes

- Active: Place over the center of the APB muscle, one-third of the distance between the metacarpal–carpal crease and the metacarpal–phalangeal joint of the thumb.
- Reference: Place on the metacarpal–phalangeal joint, 4-5 cm distal to the active.
- Ground: Place on the back of the hand.

Stimulating electrodes

- Distal: Place 6.5-8 cm proximal to the active electrode between the flexor carpi radialis and palmaris longus tendons.
- Proximal: Place over the brachial pulse at the elbow, between the biceps tendon and the medial epicondyle.

Measurements

- Distances, latencies, and amplitudes of all sites.
- Conduction velocity between wrist and elbow.

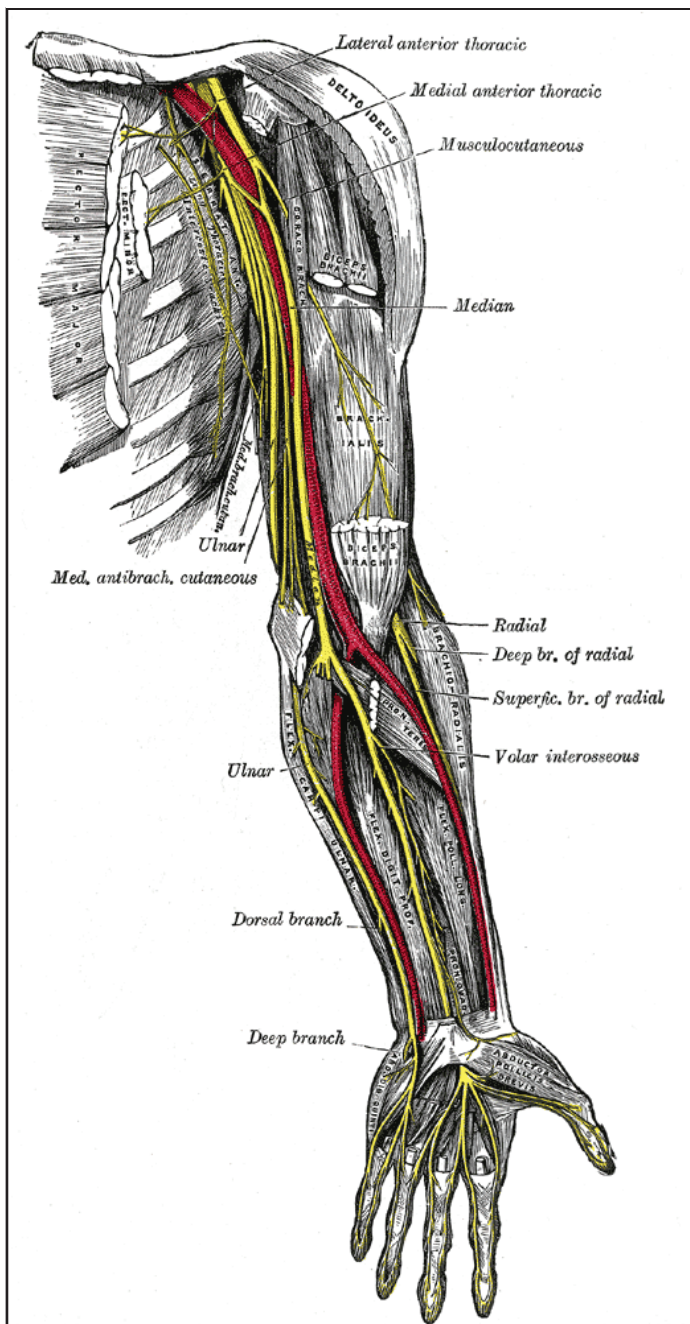


Figure 10 The median nerve.

From wikipedia.org (originally from *Gray's Anatomy*, fig. 816).

Median Orthodromic Sensory Nerve Study Technique for the Index Finger

The following is the procedure for the median orthodromic sensory nerve study of the index finger (see Fig. 12).

Recording electrodes

- Active: Place between the flexor carpi radialis and palmaris longus tendons 11-13 cm from the stimulation site.

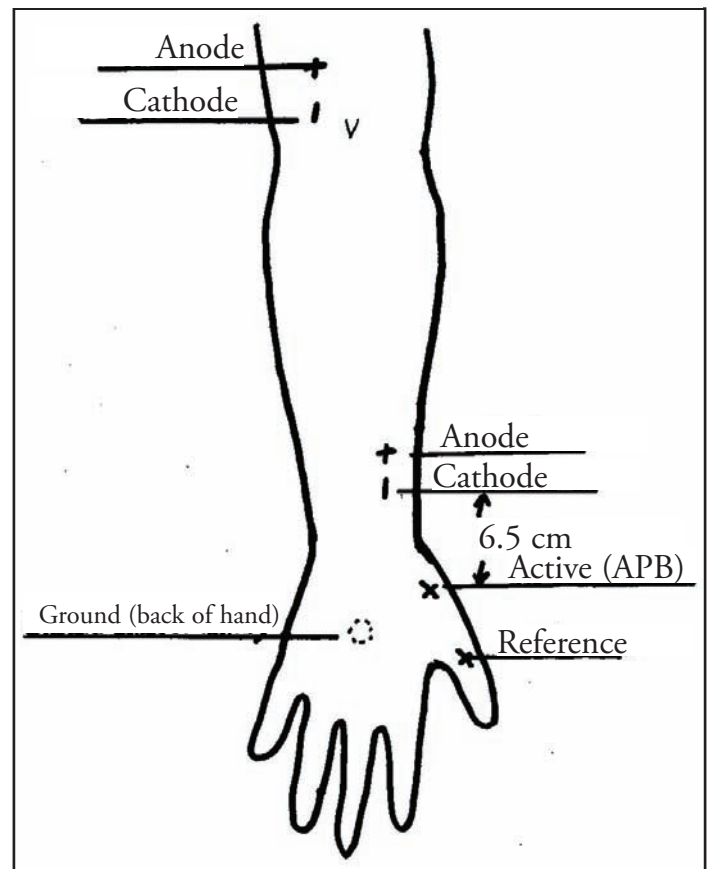


Figure 11 Electrode placement for a median motor nerve study.

APB = abductor pollicis brevis

- Reference: Place 3-4 cm proximal to the active site.
- Ground: Place on the back of the hand.

Stimulating electrodes

- Cathode: Place on the proximal phalanx of the index finger.
- Anode: Place on the middle phalanx of the index finger.

Measurements

- Distances, amplitudes, and latencies for sites.

Median Antidromic Sensory Nerve Study Technique for the Index Finger

The procedure for the median antidromic sensory nerve study for the index finger is the reverse of the procedure for the orthodromic study.

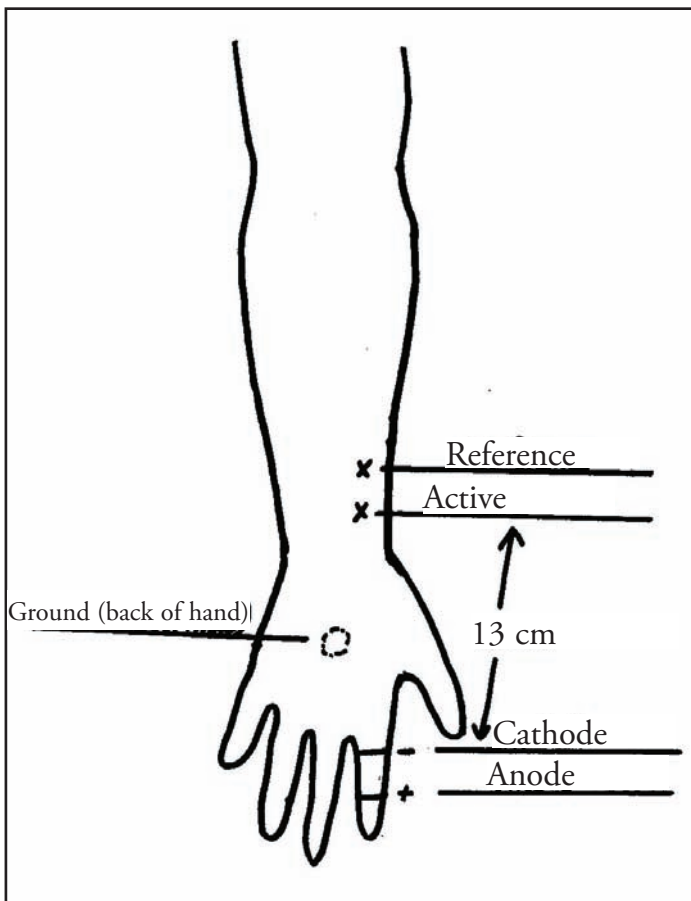


Figure 12 Electrode placement for a median orthodromic sensory nerve study of the index finger.

Median Palmar Sensory Nerve Study Technique

The following is the procedure for the median palmar sensory nerve study (see Fig. 13).

Recording electrodes

- Place the electrodes the same as for median orthodromic sensory nerve studies.

Stimulating electrodes

- Place on the thenar crease and the 2nd metacarpal interspace in the palm. Place them 8-10 cm from the active electrode.

Measurements

- Distances, amplitudes, and latencies for each site.

Median Orthodromic Sensory Nerve Study Technique for the Thumb

The following is the procedure for the median orthodromic sensory nerve study for the thumb. This study may be used to assess C6-C7 roots, upper or middle trunk, and lateral cord of the brachial plexus.

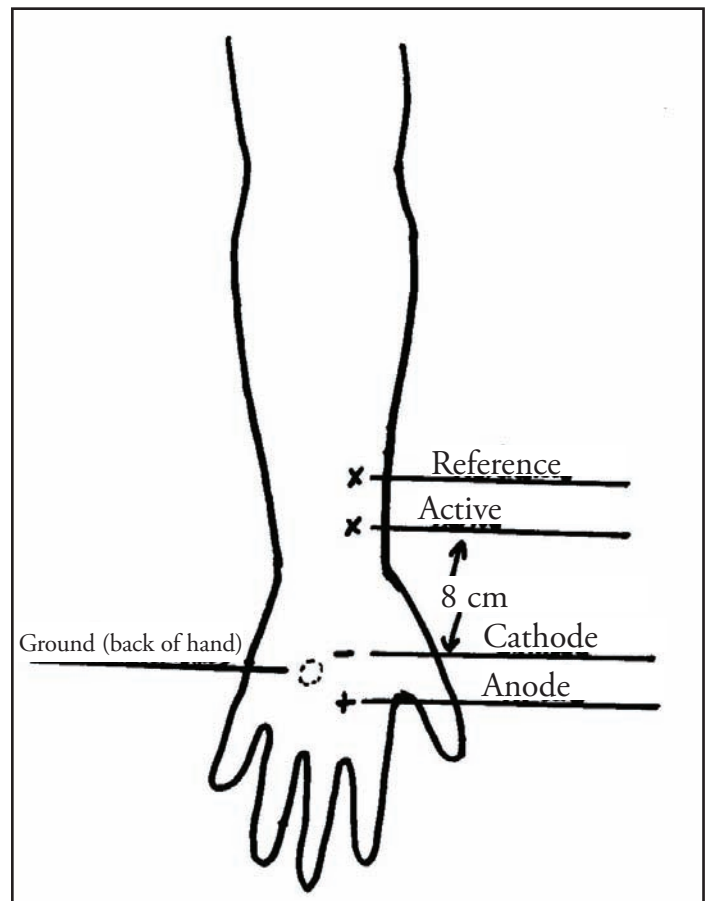


Figure 13 Electrode placement for a median palmar sensory nerve study.

Recording electrodes

- Place the electrodes the same as for median orthodromic sensory nerve studies.

Stimulating electrodes

- Cathode: Place at the base of the thumb.
- Anode: Place at the interphalangeal joint.

Measurements

- Distances, amplitudes, and latencies for each site.

Median Nerve Entrapments

A common diagnosis in the neurodiagnostic laboratory is that of carpal tunnel syndrome (CTS). This is entrapment of the median nerve at the wrist. The nature of CTS will be discussed in detail later in this course. However, one must remember there are also three other sites along the median nerve that it may become trapped (see Fig. 14).

The following are the median nerve entrapment sites from distal to proximal:

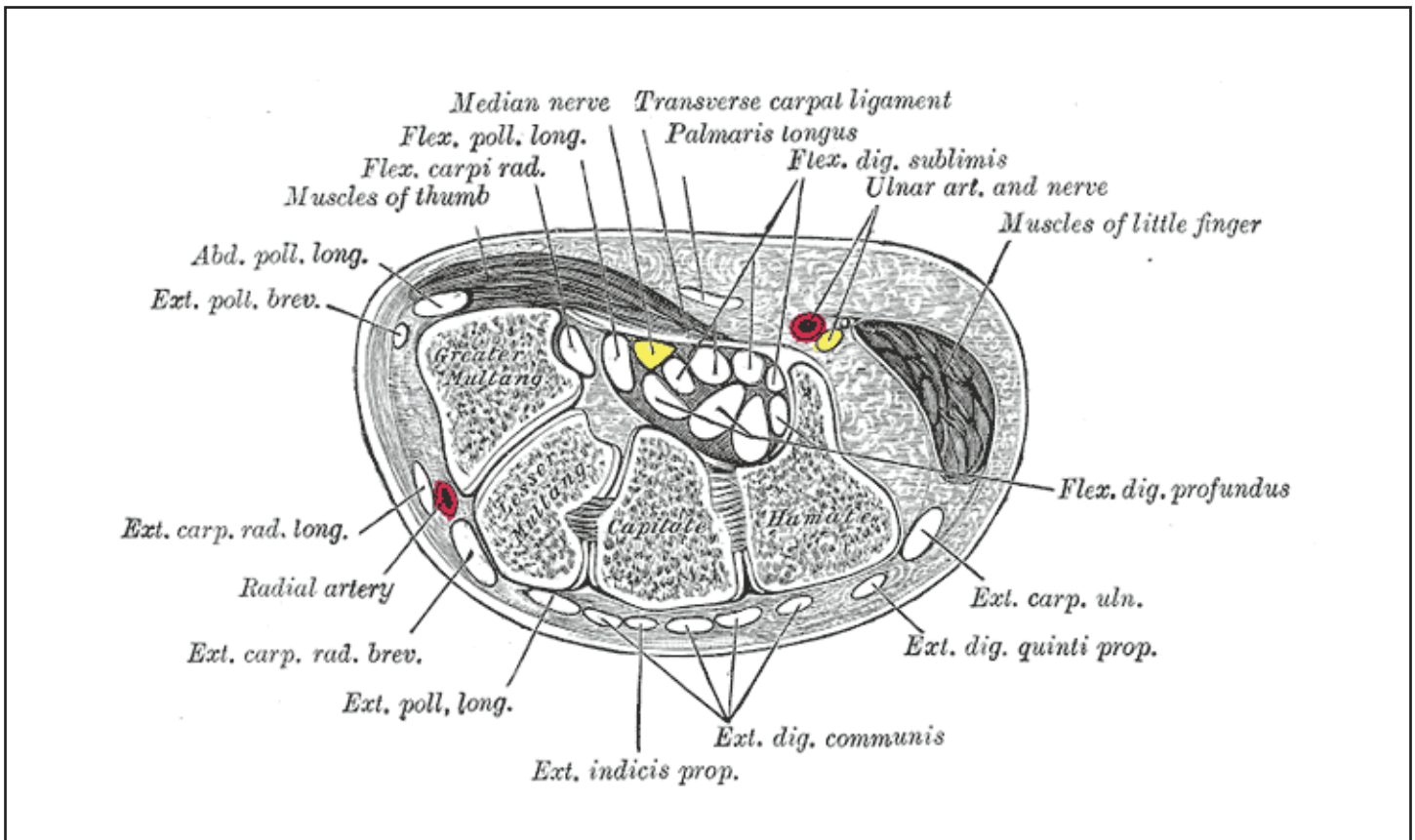


Figure 14 Transverse section across the wrist and digits.

From wikipedia.org (originally from *Gray's Anatomy*, fig. 422).

1. At or around the elbow: Ligament of Struthers, pronator syndrome, and anterior interosseus syndrome.
 - A. Ligament of Struthers: Here a fibrous band attached to a bony spur on the humerus entraps the median nerve. Routine nerve conduction studies (NCSs) from the wrist and elbow may be normal with the pathology consisting of focal slowing and amplitude loss between the the elbow and axilla stimulation. This entity is rare.
 - B. Pronator syndrome: This is caused by the median nerve becoming entrapped between the two heads of the pronator teres muscle. Motor distal latencies and sensory nerve action potentials (SNAPs) are normal. Conduction velocity (CV) is slowed across the proximal forearm. Needle electromyography (EMG) is abnormal in the flexor pollicis longus (FPL) and the flexor digitorum profundus (FDP). The pronator teres is normal. This syndrome is aggravated by pronation of the forearm.
 - C. Anterior interosseous syndrome: This is caused by compression of the anterior interosseus nerve, a motor branch of the median nerve, by fractures, dislocations, trauma, etc. in the forearm. Routine NCSs show normal motor unit action potentials (MUAPs) and SNAPs. There will be a delay in latency when recording motor studies from the pronator quadratus (PQ). Needle EMG abnormalities occur in the PQ, FPL, and FDP to the index and long fingers. Patients will be unable to make the "OK" sign with their thumb and index finger, instead making a "triangle" sign.
 2. In the shoulder region: Fractures, dislocations, and soft tissue involvement may result in median nerve entrapments here. These cases are rare but may be seen more often in a laboratory that has a great amount of access to a trauma unit or emergency room.
 3. In the plexus or root area: Crutch palsy, aneurysms, and carcinomas as well as trauma may contribute to lesions at the root and brachial plexus areas. In the brachial plexus the median nerve pathology may come from trauma to the lateral and/or medial cords of the plexus. NCSs will show median CV slowing due to demyelination and/or amplitude loss if there is axonal involvement if the lesion is in the plexus. Depending on the location of the lesion(s) in the plexus, other nerves may also be affected.
- CTS is one of the most common diagnoses that will be made in an EDX laboratory. At the wrist, the median nerve is surrounded by bones on the sides and thick ligaments on the top. Inside this area, along with the nerve, are tendons which occupy a great deal of space. Any space-occupying lesion, edema, fractures, bleeding, pregnancy, or constant repetitive movement may cause compression to the median nerve in this area.

Table 1 Studies of normal control subjects at Willis-Knighton Medical Center EMG Laboratory

Motor and F wave studies				
Nerve	Distal latency (ms)	Conduction velocity (m/s)	Amplitude (mV)	Distance (cm)
Median	< 4.4	> 49	> 4.2	6.5
F wave	< 31			
Ulnar	< 3.5	> 49	> 5.6	6.5
F wave	< 31			
Sensory studies				
Nerve	Distal latency (ms)	Conduction velocity (m/s)	Amplitude (mV)	Distance (cm)
Median				
Palm	< 2.2		> 40	8.0
2nd digit	< 3.5		> 10	13.0
Ulnar				
Palm	< 2.2		> 20	8.0
5th digit	< 2.9		> 5	13.0

Electrodiagnostic Studies

In CTS, the sensory response is usually the first to become involved. For digital sensory NCSs, a latency of greater than 4.0 ms is used. For motor nerve studies, a distal motor latency of greater than 4.4 ms is considered abnormal. These values may differ depending on the distal distance used. Remember, most CTS occurs bilaterally, so compare both median nerves to the ulnar nerve on the same side to rule out some sort of neuropathy. There are three types of CTS ranging from the mild type where only occasional symptoms are seen to the patients with positive physical examination (i.e., numbness, tingling, pain) and positive electrical findings to finally the severe type where there is atrophy, chronic denervation, absent sensories, and prolonged to absent motor studies. It is in this last type in which needle EMG studies are of the most help. Because sensory studies are usually the first to be affected, the poorer the sensory study, in general, the worse the prognosis.

There are several other NCS techniques that may be used in the diagnosis of CTS. The technique is to perform antidromic median and ulnar sensory studies from the ring (4th) finger. Record from the metacarpal-phalangeal (m-p) joint using the same distal distance (12-14 cm) to the median wrist stimulation site and the ulnar wrist stimulation site. In normal subjects the difference in distal

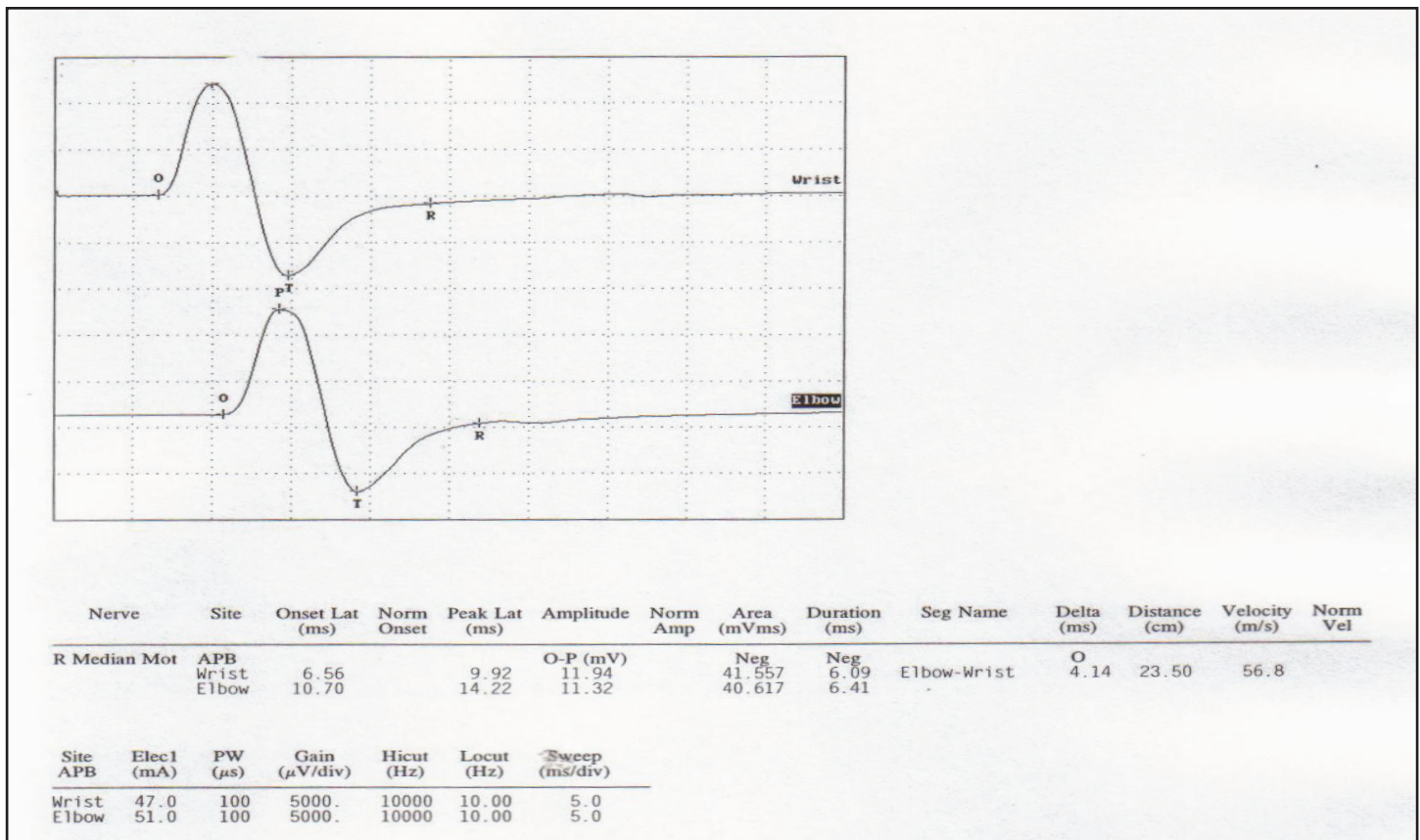


Figure 15 Right median motor nerve study of the abductor pollicis brevis muscle.

ABP = abductor pollicis brevis, Amp = amplitude, ElecI = electrical, Lat = latency, Mot = motor, Norm = normal, PW = pulse width, R = right, Seg = segment, Vel = velocity

Table 2 Median nerve reference sites at Willis-Knighton Medical Center EMG Laboratory

Stimulation	Recording	Reference	Ground
Motor			
Wrist	APB	3 cm distal	Between active and stimulator
Elbow		or proximal to active	
Axilla			
Erb's point			
Sensory			
Thumb	Wrist	Same as above	Same as above
Index finger	Thumb		
Middle finger	Index finger		
Palm	Middle finger		
Wrist			
Elbow			

ABP = abductor pollicis brevis

latencies between the two sites should be < 0.5 ms. This study may also be done orthodromically.

The second technique is to use the second lumbrical and first palmar interosseous as a recording site for median and ulnar antidromic sensory studies. Use the same distal distance (8-10 cm) to the median and ulnar wrist stimulation sites. Again the difference in distal latencies should be < 0.5 ms for normal subjects. This study is also useful for detecting an ulnar neuropathy at Guyon's canal (see Fig. 15).

Treatment for CTS covers a wide range of modalities. At one time, surgical intervention was considered the first method of treatment. Today steroids, wrist splints, and other conservative measures are often tried successfully. Job retraining to decrease repetitive movement has also been highly effective.

BIBLIOGRAPHY

1. Aids to the examination of the peripheral nervous system, 2nd ed. Pendragon House: Medical Research Council of the UK; 1976.
2. Crout B, Flicek C. Nerve conduction studies From A to Z. Kansas City, MO: American Society of Electroneurodiagnostic Technologists; 1997.
3. Dawson DM, Hallet M, Millender LH. Entrapment neuropathies. Little, Brown & Company, 1983.
4. Goodgold J. Anatomical correlates of clinical electromyography. Baltimore: Williams & Wilkins; 1974.
5. Haymaker W, Woodhall B. Peripheral nerve injuries. In: Principles of diagnosis, 2nd ed. Philadelphia: Saunders; 1953.
6. Johnson E, ed. Practical electromyography. Baltimore/London: Williams & Wilkins; 1980.
7. Kimura J. Electrodiagnosis in diseases of nerve and muscle: principles and practice. Philadelphia: Oxford University Press; 2001.
8. Ma DM, Liveson JA. Nerve conduction handbook. Philadelphia: FA Davis; 1983.
9. Practical Electrodiagnosis Seminar. University of Texas Health Science Center at San Antonio, 1990.
10. Preston D, Shapiro B. Electromyography and neuromuscular junction disorders. Philadelphia: Elsevier; 2005.
11. Wikipedia.
12. Woodburne R. Essentials of human anatomy. New York: Oxford University Press, 1978.