

# Normal MR Imaging Anatomy of the Knee

Saifuddin Vohra, DO, George Arnold, MD, Shashin Doshi, MD, David Marcantonio, MD\*

## KEYWORDS

• Anatomy • Knee • MR imaging • Pitfalls

There are several keys to successfully interpreting MR imaging examinations. Initially, constructing a solid foundation consisting of a good understanding of basic MR imaging principles and imaging protocols as well as the appearance of normal imaging anatomy is crucial. This knowledge can be then applied to one's understanding of pathology commonly encountered in the area of interest. Careful attention should be focused on awareness of commonly encountered normal variants and diagnostic pitfalls to improve accuracy and avoid misinterpretation. In this article, MR imaging of a healthy volunteer was performed on a 3-T MR imaging unit (Siemens, Munich, Germany). Normal anatomy is depicted at representative levels throughout the knee, and descriptions of frequently encountered anatomic variants are provided.

## PROTOCOLS

At the authors' institution, a combination of intermediate-weighted proton density (PD) and T2-weighted fast spin echo sequences with and without fat suppression are used to provide excellent anatomic detail and localize pathology. Fat suppression accentuates bone marrow and soft tissue edema on fluid-sensitive sequences, and non-fat-suppressed images increase conspicuity of bone marrow abnormalities on short echo time (TE) sequences. Furthermore, fast spin echo PD sequences employing fat saturation are accurate and sensitive for evaluation of meniscal tears and articular cartilage disruption.

In general, optimal evaluation is achieved when the imaging planes are oriented perpendicular to and parallel to the long axis of the structure in question. The multiplanar capability of MR imaging allows for oblique sagittal image acquisition oriented parallel to the lateral femoral condyle, which optimizes evaluation of the anterior cruciate ligament (ACL), horns of the menisci, femorotibial joint and femoral trochlear articular cartilage, cruciate ligaments, and extensor mechanism. The coronal plane of imaging is preferred for evaluation of the body of the menisci, and medial and lateral stabilizing structures. The axial plane is used to evaluate the patellar articular cartilage, quadriceps tendon, and medial and lateral stabilizing structures.

The routine knee MR imaging protocol at the authors' institution (**Table 1**) consists of axial intermediate PD with fat saturation, PD sagittal oblique without fat saturation, PD coronal without fat saturation, intermediate T2 coronal with fat saturation, and intermediate T2 sagittal oblique with fat saturation sequences. When indicated, intravenous gadolinium contrast may help to further characterize neoplastic, infectious, and inflammatory processes. Prior to gadolinium contrast administration, an axial T1-weighted sequence with fat suppression is obtained as a control sequence. Following intravenous gadolinium contrast administration, T1-weighted fat-suppressed sequences are obtained in the axial plane, and at least one additional orthogonal plane. Indications for intra-articular dilute gadolinium contrast administration include suspected

---

The authors having nothing to disclose.

Division of Musculoskeletal Radiology, Department of Diagnostic Radiology-Imaging Center, William Beaumont Hospital, 3601 West 13 Mile Road, Royal Oak, MI 48073, USA

\* Corresponding author.

E-mail address: David.Marcantonio@beaumont.edu

Magn Reson Imaging Clin N Am 19 (2011) 637–653

doi:10.1016/j.mric.2011.05.012

1064-9689/11/\$ – see front matter © 2011 Elsevier Inc. All rights reserved.

**Table 1**  
Routine MR imaging protocol: knee (volume surface phased array) coil

Sequence	Fat Saturation	FOV (cm)	Matrix	TR (ms)	TE (ms)	Slice Thickness/Gap (mm)
Intermediate PD axial	Y	14	313 × 384	4430	11	3/0.6
Intermediate T2 sagittal oblique	Y	14	200 × 256	2920	56	3/0.6
Intermediate T2 coronal	Y	14	200 × 256	4050	56	3/0.6
PD coronal	N	14	314 × 448	1200	15	3/0.6
PD sagittal oblique	N	14	314 × 448	1200	15	3/0.6

Setup: Feet first, supine, knee minimally flexed, neutral to slightly externally rotated; 3-T MR unit (Siemens, Germany). Post-gadolinium contrast T1-weighted sequences are obtained in at least 2 orthogonal planes with fat suppression.

*Abbreviations:* FOV, field of view; PD, proton density; TE, echo time; TR, repetition time.

meniscal retear after meniscectomy, and evaluation for instability of an osteochondral lesion.

The field strength, coil (volume surface phased array), slice thickness, field of view, matrix size, and other select imaging parameters are optimized with the goal of increasing the signal to noise ratio and decreasing scan time, thereby decreasing motion artifact. Metal artifact reduction can be achieved by orienting the long axis of metallic prosthesis parallel to both magnetic field and frequency encoding axis, employing fast spin echo techniques with increased echo train length, increasing receiver band width, decreasing field of view, and increasing the matrix size in the direction of the frequency encoding gradient.<sup>1</sup>

## IMAGING ANATOMY

The knee, a hinge-type joint, is primarily composed of 3 articulating compartments: patellofemoral, medial femorotibial, and lateral femorotibial. A combination of muscles, tendons, ligaments, and extensions of the joint capsule collectively help to offer multidirectional stability to the knee, while allowing for necessary mobility. Numerous bursae about the knee allow for ease of motion of the stabilizing structures in relation to one another.

The medial femorotibial compartment is formed by the medial femoral condyle and medial tibial plateau articulation, and houses the medial meniscus and articular cartilage. Major medial stabilizers include the deep (coronary ligaments) and superficial portions of the medial collateral ligament (MCL), medial tendons (sartorius, gracilis, semitendinosus, and semimembranosus), and deep crural fascia of vastus medialis, which helps to form the medial patellar retinaculum anteriorly. Posteriorly, the deep portion of the MCL, with contributing fibers from the semimembranosus tendon and synovial sheath, form the posterior

oblique ligament, a major stabilizer of the posteromedial knee. The MCL bursa is located along the middle third of the medial knee joint between the superficial and deep components of the MCL.<sup>2</sup>

The lateral femorotibial compartment is formed by the lateral femoral condyle and lateral tibial plateau articulation, and houses the lateral meniscus and articular cartilage. It can communicate with the proximal tibiofibular joint in a minority of individuals. Lateral joint stabilizers are composed of muscles, tendons, and ligaments. The anterolateral joint is stabilized by the joint capsule and the iliotibial tract, which inserts on Gerdy's tubercle along the anterolateral tibia, and is a fascial extension of the tensor fascia lata. The posterolateral corner is a complex anatomic area providing stabilization, achieved by several structures including the fibular (lateral) collateral ligament (FCL), biceps femoris tendon, popliteus muscle and tendon, popliteal fibular and popliteal meniscal ligaments, oblique popliteal, arcuate, and fabellofibular ligaments, and lateral gastrocnemius muscle. These structures are collectively referred to as the arcuate ligament complex. The major stabilizers of the posterolateral corner are adequately visualized on routine knee MR imaging examinations. The FCL has an oblique course from the lateral femoral condyle, immediately anterior to the origin of the lateral head of the gastrocnemius muscle, to the fibular head. The biceps femoris common tendon, directly posterior to the iliotibial tract at the level of the femoral condyles, joins the FCL to form the conjoint tendon before inserting upon the fibular head. The intra-articular segment of the popliteus tendon originates just below and passes beneath the FCL (through the popliteus hiatus), and then the arcuate ligament. The extra-articular segment of the tendon quickly joins its muscle belly, which in turn attaches to the posteromedial proximal tibial surface.

The menisci are C-shaped structures composed of relatively small anterior and larger posterior horns and a central body. The menisci are divided into an inner avascular or white-white zone (>5 mm from the capsule), middle hypovascular or red-white zone (3–5 mm from the capsule), and outer vascular or red-red zone (<3 mm from the capsule).<sup>3,4</sup>

Several potential diagnostic pitfalls exist involving the menisci, and awareness of anatomic variants related to these structures is essential to avoid misinterpretation. The most common meniscomeniscal ligament is the anterior transverse meniscal ligament, which can be a potential diagnostic pitfall because the junction of the ligament and meniscus can mimic a tear if not properly followed through its entirety.<sup>5,6</sup> The meniscomeniscal ligaments of Humphrey and Wrisberg, located anterior and posterior to the posterior cruciate ligament (PCL), respectively, can similarly be mistaken for pseudotears or meniscal fragments of the posterior horn of the lateral meniscus at their meniscal attachment.<sup>6</sup> A rare variant, the oblique meniscomeniscal ligament, courses obliquely from the posterior horn of either meniscus through the intercondylar notch between the cruciate ligaments to the anterior horn of the opposite meniscus, and can be mistaken for a flipped meniscal fragment.<sup>5</sup> Physiologic small fluid within the popliteus tendon sheath can simulate a lateral meniscal tear at the body-posterior horn junction. Meniscal flocule is an unusual normal variant characterized by a single fold along the inner margin of the meniscus.<sup>3</sup> It more commonly involves the medial meniscus and can be mistaken for a tear, especially on coronal images.

Imaging artifacts generated by patient motion, magic angle, arterial pulsation, susceptibility artifact/field inhomogeneity (eg, chondrocalcinosis), and the concave morphology of the menisci (edge artifact) all can create a diagnostic dilemma, and this can be avoided with improved understanding of MR imaging physics and by paying special attention to imaging technique. Hemosiderin-vacuum phenomenon from fracture or osteoarthritis can mimic a meniscal fragment, and will be more conspicuous on gradient echo sequences.<sup>4</sup>

The cruciate ligaments are situated in the intercondylar notch between the medial and lateral compartments. The ACL courses from the posteromedial aspect of the lateral femoral condyle to insert anterolateral to the anterior tibial spine. The normal ACL has a fan-shaped striated appearance on both T1-weighted and T2-weighted sequences whereas, in contrast, the PCL appears homogeneously hypointense on all sequences. The PCL has a broad origin along the mid aspect

of the medial femoral condyle and tapers as it inserts along the posterior mid tibia approximately 1 cm below the joint line.<sup>7</sup> Both cruciate ligaments have two distinct components, an anterolateral and posteromedial bundle. A normal recess, which can accumulate fluid, is located posterior to the PCL.<sup>8</sup>

The extensor mechanism of the knee is composed of the quadriceps tendon, prepatellar quadriceps continuation, and patellar tendon.<sup>9</sup> The quadriceps tendon is striated in appearance, due to interspersed fat between 4 contributing muscles: vastus lateralis, vastus intermedius (deep), rectus femoris (superficial), and vastus medialis. The patellar tendon is a hypointense band arising from the inferior pole of the patella and attaching to the tibial tuberosity. The prepatellar quadriceps continuation is a thin sliver of hypointense signal comprising superficial fibers from the rectus femoris tendon.

Numerous bursae are present around the knee joint, and allow for smooth motion of various stabilizing structures in relation to one another. Visualization of these potential spaces is commonly due to pathologic fluid accumulation (bursitis). The semimembranosus-gastrocnemius bursa, located within the posteromedial aspect of the knee, communicates with the knee joint in a majority of individuals, and is referred to as a popliteal (Baker's) cyst.<sup>10</sup> The neck of the cyst is formed by the tendon of the medial head of the gastrocnemius muscle laterally and semimembranosus tendon medially. Anteriorly, 4 bursae are commonly visualized and include the suprapatellar, prepatellar, and superficial and deep infrapatellar bursae. The anterior and posterior bursae are best seen on axial or sagittal sequences.

Medially, the pes anserine, tibial collateral ligament, and semimembranosus-tibial collateral ligament bursae are seen. The pes anserine bursa is located between the distal tibial collateral ligament and the pes anserinus, which is composed of the sartorius, gracilis, and semitendinosus tendons at their tibial insertion. The tibial collateral ligament (MCL) bursa is located at the level of the knee joint line between the superficial and deep components of the MCL, and is elongated in a vertical fashion. The semimembranosus-tibial collateral ligament bursa, an inverted U-shaped structure, does not communicate with the joint, and is positioned between the semimembranosus tendon and tibial collateral ligament at the level of the medial tibial plateau.<sup>11</sup> Laterally, the iliotibial band and fibular collateral ligament (FCL)-biceps femoris bursae are found. The iliotibial band bursa is situated between the tibia and distal iliotibial band immediately proximal to its insertion on Gerdy's tubercle.

The FCL-biceps femoris bursa is found lateral to the distal FCL, and insinuates anterior and antero-medial in relation to this ligament. Superiorly, it extends to the level of the crossing of the biceps femoris tendon, and remains superficial to FCL in this location.<sup>10</sup>

Knowledge of normal locations of bursae is important in order to distinguish these from pathologic processes. One example exists within the soft tissues deep to the distal iliotibial tract at the level of the lateral femoral condyle. As a normal bursa does not exist in this location, fluid accumulation is likely pathologic and related to iliotibial band friction syndrome; however, it must be differentiated from joint fluid within the lateral parapatellar recess.<sup>6</sup>

The popliteal fossa is located posterior to the knee and contains several neurovascular structures that course between the thigh and leg. The popliteal artery most commonly bifurcates at the caudal aspect of the popliteus muscle into the posterior and anterior tibial arteries. A rare but important variant branching pattern, termed the aberrant anterior tibial artery, occurs when there is high (early) division of the popliteal artery, and

the anterior tibial artery courses inferiorly along the anterior surface of the popliteal muscle. This vessel is at high risk of injury during orthopedic operations involving posterior knee soft tissue manipulation, drilling through the posterior tibial cortex, and proximal tibial osteotomies.<sup>12</sup>

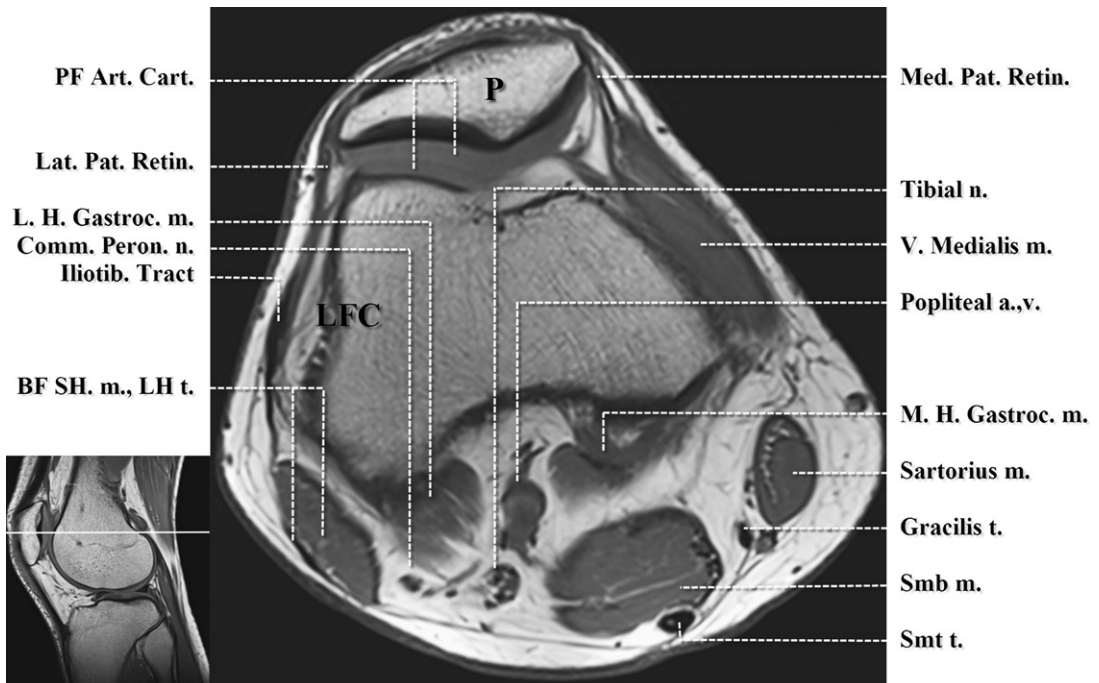
## SUMMARY

It is essential to develop an understanding of basic MR imaging principles and anatomy, as well as musculoskeletal imaging protocols, prior to interpreting MR imaging examinations of the knee. Learning normal MR imaging anatomy, commonly encountered anatomic variants, and imaging pitfalls is crucial for improving radiologists' ability to accurately detect disease. (See Appendix for illustrative figures.)

## ACKNOWLEDGMENTS

We thank Mike Tenzer MD, our healthy imaging volunteer, who provided many of the images used in this article.

## APPENDIX



**Fig. 1.** Axial T1-weighted image. Mid patellofemoral compartment. a., artery; BF SH. m., LH t., biceps femoris short head muscle, long head tendon; Comm. Peron. n., common peroneal nerve; m, muscle; n, nerve; M.H./L.H. Gastroc., medial and lateral heads of gastrocnemius; Iliotib., iliotibial; Med./Lat. Pat. Retin., medial and lateral patellar retinacula; PF Art. Cart., patellofemoral articular cartilage; Smb, semimembranosus; Smt, semitendinosus; t, tendon; v., vein; V., vastus.

## Key Points

- The semimembranosus muscle is the largest of the posteromedial muscles continuing inferiorly to this level. The semitendinosus tendon can be seen immediately posterior to the semimembranosus muscle. The smaller sartorius muscle is seen more medially with the gracilis tendon interposed. The vastus medialis isobliquus muscle is draped over the medial femoral condyle.
- The adductor tubercle (not seen), along the superior medial femoral condyle, is the insertion site of the adductor magnus muscle.
- The medial and lateral heads of gastrocnemius muscles originate from immediately superior to their respective femoral condyles.
- The popliteal artery is anterior to the popliteal vein within the superior aspect of the popliteal fossa.
- The common peroneal nerve follows the course of the biceps femoris musculature.
- The patellar articular cartilage is located slightly superior to the femoral trochlear articular cartilage during knee extension.

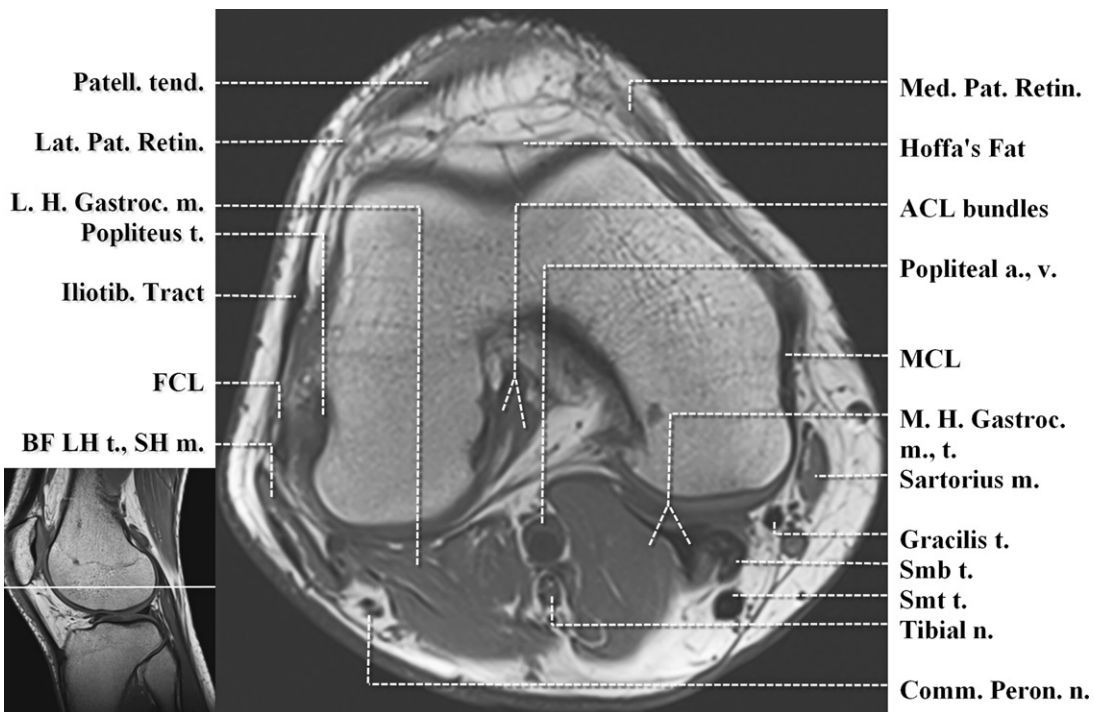


Fig. 2. Axial T1-weighted image. Inferior patellofemoral compartment. a., artery; ACL, anterior cruciate ligament; BF LH. t., SH m., biceps femoris short head muscle, long head tendon; Comm. Peron. n., common peroneal nerve; FCL, fibular collateral ligament; Iliotib., iliotibial; m., muscle; MCL, medial collateral ligament; M.H./L.H. Gastroc., medial and lateral heads of gastrocnemius; Med./Lat. Pat. Retin., medial and lateral patellar retinacula; n., nerve; Patell. tend., patellar tendon; Smb, semimembranosus; Smt, semitendinosus; t., tendon; v., vein.

## Key Points

- The semimembranosus muscle forms a crescentic tendon, and together with the medial head gastrocnemius tendon, creates the neck of the semimembranosus-gastrocnemius bursae (also known as Baker's cyst).
- The femoral attachment of the tibial collateral ligament (MCL) can be seen.
- The patellar retinacula and iliotibial tract (laterally) attach the patella to the collateral ligaments.<sup>13</sup>
- The medial and lateral heads of gastrocnemius muscles border the popliteal artery and vein on either side. The tibial nerve is positioned immediately posterior to the popliteal vessels.
- The femoral attachment of the two bundles of the ACL is seen within the posterolateral superior aspect of the intercondylar notch just above the level of the femoral attachment of the PCL.
- The origin of the popliteus tendon is immediately inferior and posterior to the femoral attachment of the fibular collateral ligament (FCL). The inferior lateral genicular artery courses between the FCL and the popliteus tendon.

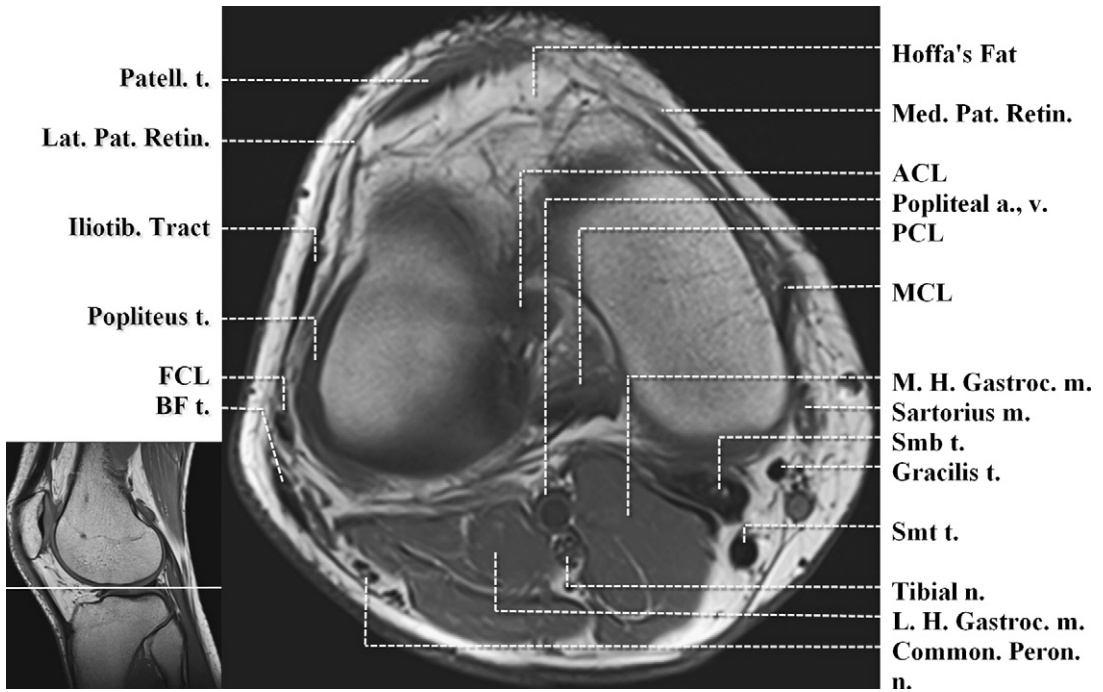


Fig. 3. Axial T1-weighted image. Femorotibial joint space. a., artery; ACL, anterior cruciate ligament; BF LH. t., SH m., biceps femoris short head muscle, long head tendon; Comm. Peron. n., common peroneal nerve; FCL, fibular collateral ligament; Iliotib., iliotibial; m., muscle; MCL, medial collateral ligament; M.H./L.H. Gastroc., medial and lateral heads of gastrocnemius; Med./Lat. Pat. Retin., medial and lateral patellar retinacula; n., nerve; Patell. tend., patellar tendon; Smb, semimembranosus; Smt, semitendinosus; t., tendon; v., vein.

#### Key Points

- The tibial nerve is positioned immediately posterior to the popliteal vessels.
- The proximal ACL is coursing toward the anteromedial aspect of the intercondylar notch. The PCL is posterior and courses toward its posterior tibial attachment 1 cm below the joint line.
- The biceps femoris tendon is seen proximal to forming the conjoint tendon with the fibular collateral ligament.
- The proximal popliteus tendon is intracapsular and closely apposed to the posterolateral knee joint. Magic angle artifact is seen to cause intermediate signal intensity alteration of the visualized proximal popliteus tendon. In general, it affects curving tendons, ligaments, and menisci about the knee when they are oriented 55° relative to the main magnetic field, and is more prominent on low TE sequences; however, it does not commonly hinder diagnostic interpretation in the knee. Artifact is considerably diminished on higher TE sequences (not shown).

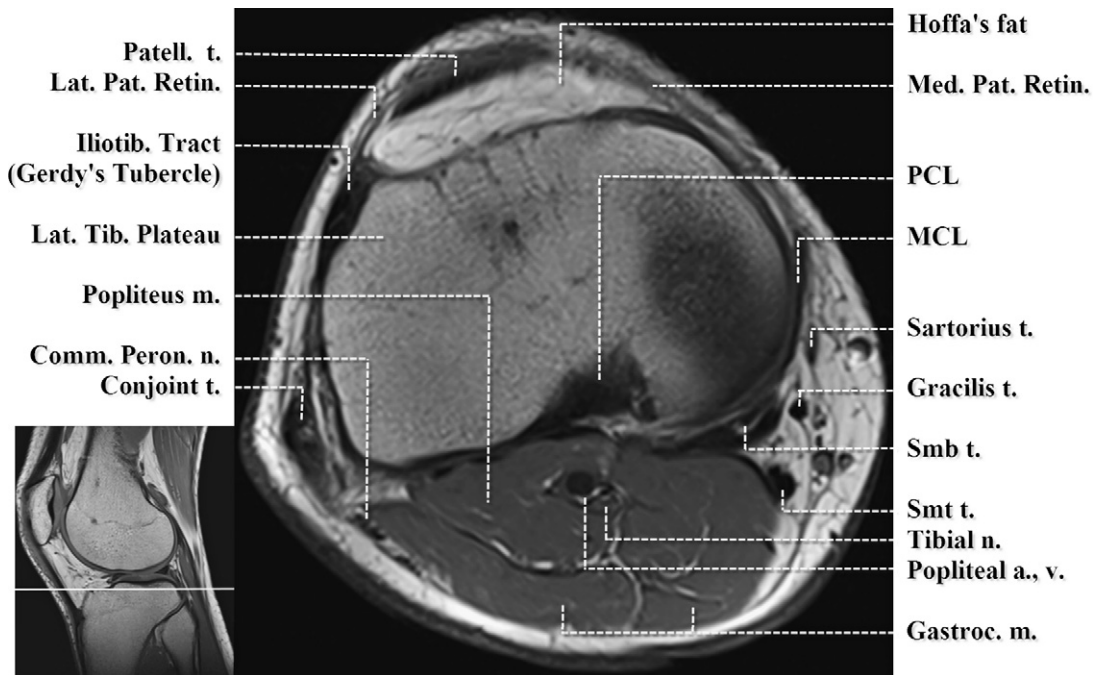


Fig. 4. Axial T1-weighted image. Proximal tibia immediately below femorotibial joint line. a., artery; Comm. Peron. n., common peroneal nerve; Gastroc., gastrocnemius; Iliotib., iliotibial; Lat. Tib., lateral tibia; m., muscle; MCL, medial collateral ligament; Med./Lat. Pat. Retin., medial and lateral patellar retinacula; n, nerve; Patell., patellar; PCL, posterior cruciate ligament; Smb, semimembranosus; Smt, semitendinosus; t., tendon; v., vein.

#### Key Points

- The semimembranosus tendon has multiple arms that insert along the posterior and medial proximal tibia.
- The sartorius, gracilis, and semitendinosus tendons (anterior to posterior) compose the pesanserinus (goose foot complex; not seen) and course inferiorly to insert upon the proximal medial tibia. The tibial attachment of the medial collateral ligament is superior to the pesanserinus attachment.
- The conjoint tendon is formed at this level by the union of the common biceps femoris tendon and FCL, which will attach upon the fibular head. The common peroneal nerve is posteromedial to the conjoint tendon, and has given rise to the lateral sural cutaneous nerve located posteromedial.
- The iliotibial tract inserts upon Gerdy's tubercle along the anterolateral proximal tibia.

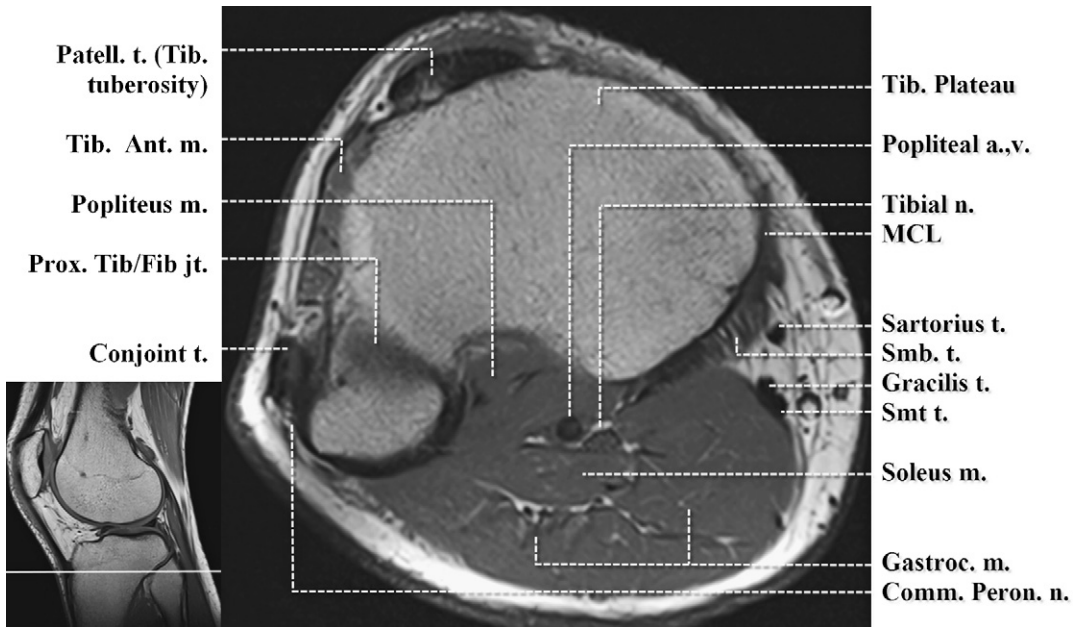


Fig. 5. Axial T1-weighted image. Proximal tibia/fibula. a., artery; Comm. Peron. n., common peroneal nerve; Gastroc., gastrocnemius; Iliotib., iliotibial; m., muscle; MCL, medial collateral ligament; n., nerve; Patell., patellar; Prox. Tib/Fib jt., proximal tibiofibular joint; Smb, semimembranosus; Smt t, semitendinosus; t, tendon; Tib. Ant, tibialis anterior; Tib, tibia; v, vein.

#### Key Points

- The soleus muscle originates from the posterior aspect of the proximal fibula.
- The conjoint tendon is formed at this level by the union of the common biceps femoris tendon and FCL, and inserts upon the fibular head.
- The superiormost muscle fibers of the tibialis anterior muscle originate posterolateral to Gerdy's tubercle (slightly superior to the level shown). The common peroneal nerve is lateral to the fibula at this level.
- The patellar tendon inserts upon the tibial tuberosity lateral to midline.



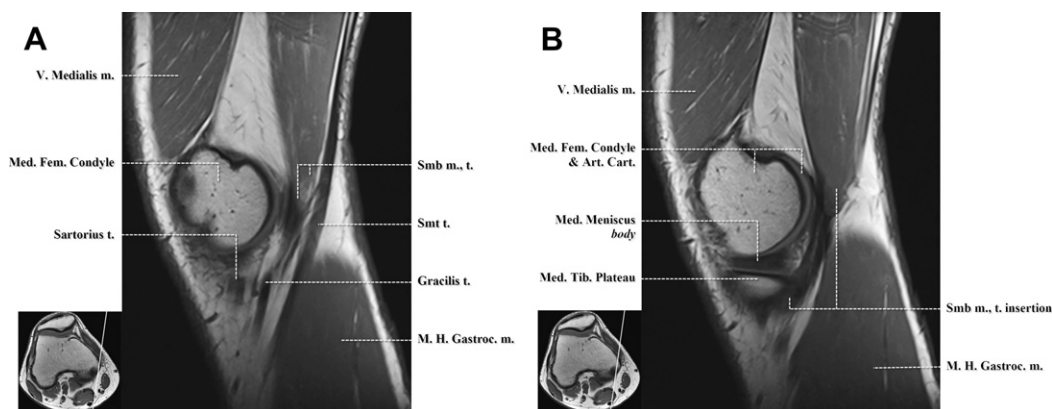


Fig. 6. Sagittal T1-weighted images. Medial aspect of the knee. (A) m., muscle; Med. Fem., medial femoral; M.H. Gastroc., medial head gastrocnemius; Smb, semimembranosus; Smt, semitendinosus; t., tendon; V., vastus. (B) Art. Cart., articular cartilage; m., muscle; Med., medial; Med. Fem., medial femoral; Med. Tib., medial tibial; M.H. Gastroc., medial head gastrocnemius; Smb, semimembranosus; Smt, semitendinosus; t., tendon; V., vastus.

### Key Points

- The sartorius, gracilis, and semitendinosus tendons (anterior to posterior) course inferiorly and anteriorly to form the pesanserinus (goose foot complex). The distal medial collateral ligament (not seen) also sends a small contribution to this complex.
- The semimembranosus muscle and myotendinous junction are subjacent to the pesanserinus complex, and the tendon has a broad insertion upon the posteromedial aspect of the proximal tibia.

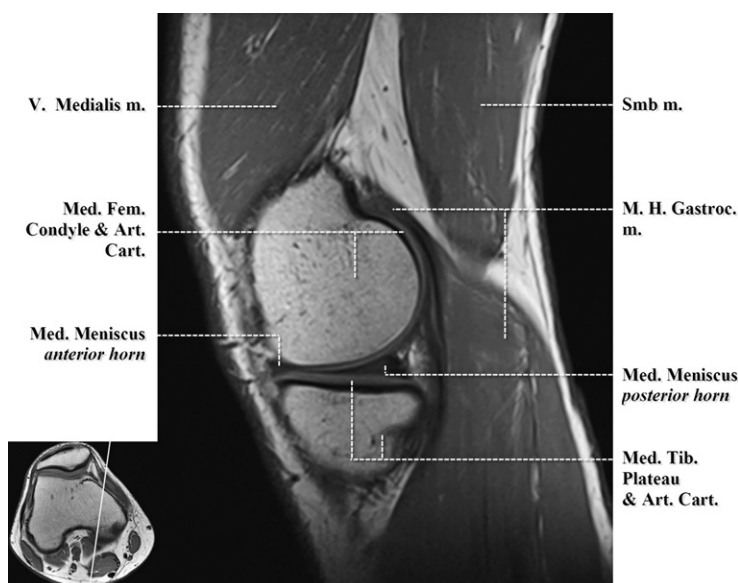


Fig. 7. Sagittal T1-weighted image. Medial aspect of the knee through posterior horn of the medial meniscus. Art. Cart., articular cartilage; m., muscle; Med., medial; Med. Fem., medial femoral; Med. Tib., medial tibial; M.H. Gastroc., medial head gastrocnemius; Smb, semimembranosus; V., vastus.

### Key Points

- The medial tibial plateau has a more wedge-shaped appearance as opposed to a more polygonal-shaped lateral tibial plateau (not seen).
- The adductor magnus inserts upon the adductor tubercle (not seen) immediately posterior to the insertion of the vastus medialis muscle.
- The medial head gastrocnemius muscle originates along the superior aspect of the medial femoral condyle.

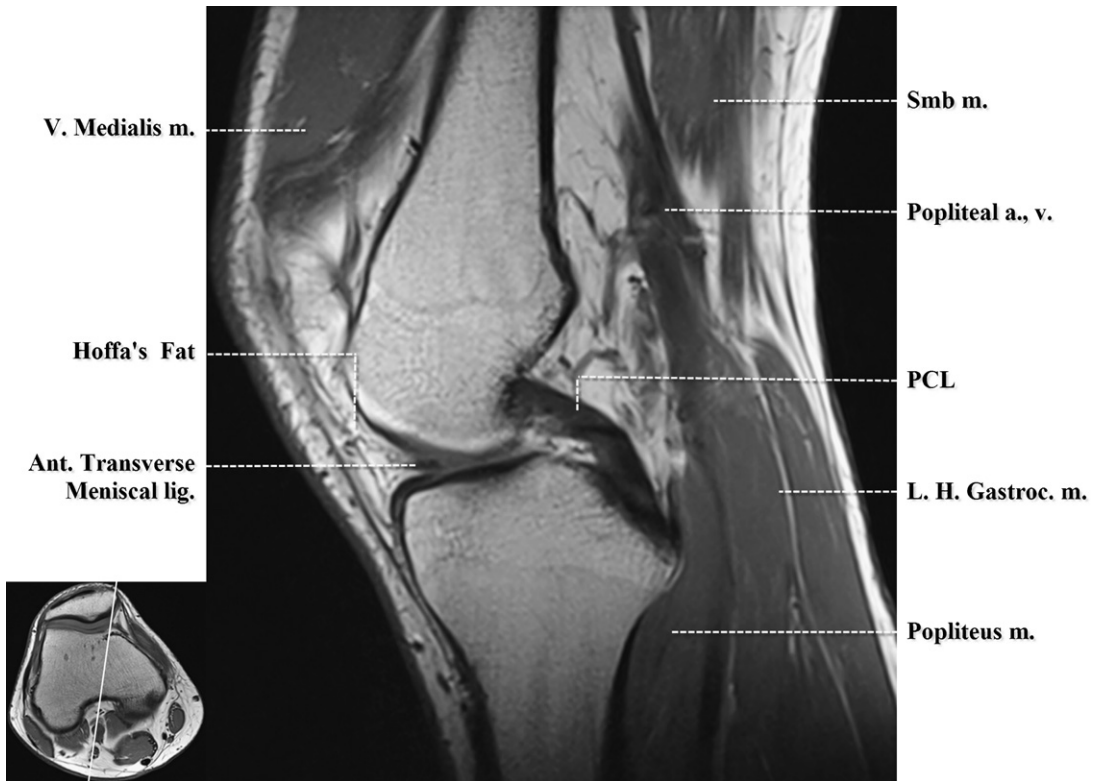


Fig. 8. Sagittal T1-weighted image. Intercondylar notch. a., artery; Ant., anterior; m., muscle; L.H. Gastroc., lateral head gastrocnemius; lig., ligament; PCL, posterior cruciate ligament; Smb, semimembranosus; V., vastus; v., vein.

#### Key Points

- The PCL is curved in appearance during knee extension and becomes taut with knee flexion. The intercondylar eminence is anterior to the tibial attachment of the PCL (1 cm below the joint line) within the posterior intercondylar fossa.
- The lateral menisofemoral ligaments of Humphrey and Wrisberg, variably present, attach the lateral meniscus to the medial femoral condyle. In relation to the PCL, the ligament of Humphrey courses anterior, and the ligament of Wrisberg courses posterior.

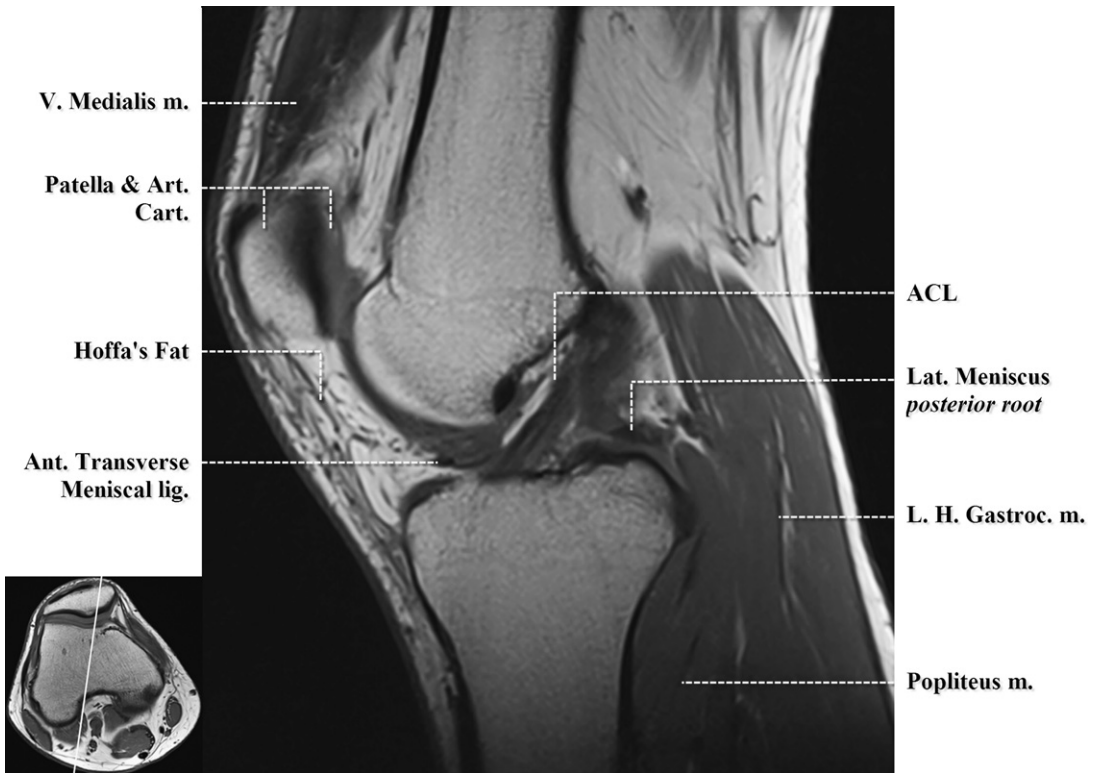
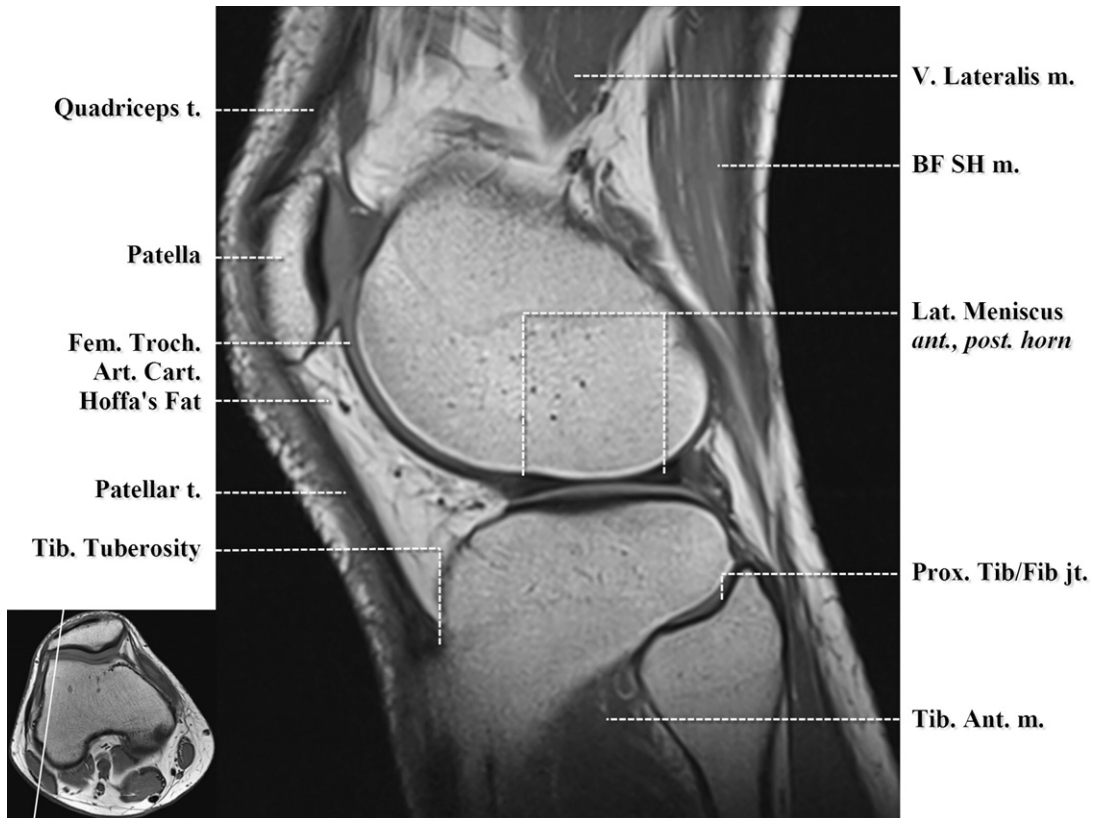


Fig. 9. Sagittal T1-weighted image. Intercondylar notch. a., artery; ACL, anterior cruciate ligament; Art. Cart., articular cartilage; Ant., anterior; m., muscle; L.H. Gastroc., lateral head gastrocnemius; Lat., lateral; lig., ligament; V., vastus.

#### Key Points

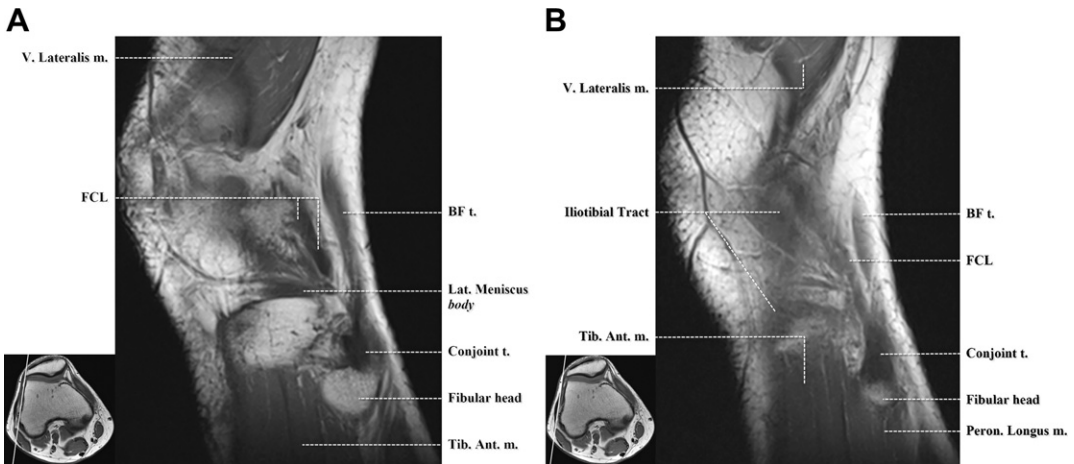
- The ACL has a striated but taut appearance and is oriented slightly more vertical than Blumenstat's line (tangent to the intercondylar roof). The ACL is more heterogeneous in appearance and smaller in diameter than the PCL.
- The anterior transverse meniscal ligament courses through the infrapatellar (Hoffa's) fat pad.
- The patella is the largest true sesamoid bone in the body.



**Fig. 10.** Sagittal T1-weighted image. Lateral femorotibial compartment. ant., anterior; Art. Cart., articular cartilage; BF SH, biceps femoris short head; Fem. Troch., femoral trochlear; m., muscle; Lat., lateral; post., posterior; Prox. Tib/Fib jt., proximal tibiofibular joint; Tib., tibia; Tib. Ant., tibialis anterior; t., tendon; V., vastus.

#### Key Points

- The anterior transverse meniscal ligament has just attached to the anterior horn.
- The intracapsular popliteus tendon is adjacent to the posterior horn.
- The biceps femoris short head muscle and biceps femoris long head tendon (not well seen) course inferiorly to form a common tendon before uniting with the FCL.
- The lateral head of gastrocnemius muscle is partially visualized inferiorly.
- The lateral tibial plateau has a polygonal shape and the medial tibial plateau (not seen) has a more wedge-shaped appearance.
- The quadriceps fat pad is just deep to the quadriceps tendon, superior to the patella, and anterior to the suprapatellar recess.



**Fig. 11.** Sagittal T1-weighted image. Lateralmost aspect of the knee. (A) BF, biceps femoris; FCL, fibular collateral ligament; m., muscle; Lat., lateral; Tib. Ant., tibialis anterior; t., tendon; V., vastus. (B) BF, biceps femoris; FCL, fibular collateral ligament; m., muscle; Peron., peroneus; Tib. Ant., tibialis anterior; t., tendon; V., vastus.

#### Key Points

- The fibular head (faintly seen) serves as the insertion of the conjoint tendon formed by the union of the FCL and the common tendon of the biceps femoris musculature.
- The iliotibial tract will insert along Gerdy's tubercle (faintly visualized).
- The common peroneal nerve (not seen) courses around the fibular neck and then divides into the superficial (lateral compartment) and deep (anterior compartment) peroneal nerves.

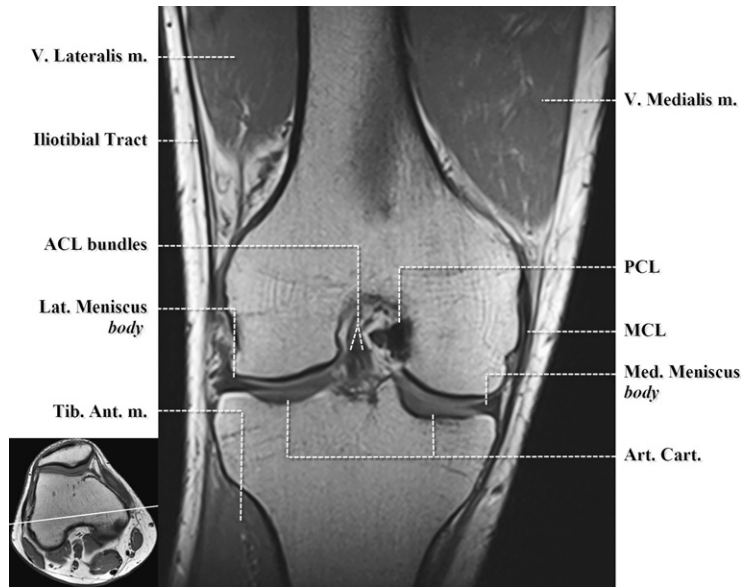


Fig. 12. Coronal T1-weighted image. Mid coronal plane. ACL, anterior cruciate ligament; Art. Cart., articular cartilage; Med., medial; MCL, medial collateral ligament; m., muscle; Lat., lateral; PCL, posterior cruciate ligament; Tib. Ant., tibialis anterior; V., vastus.

#### Key Points

- The PCL is ovoid in shape in the coronal plane, due to the extended knee position, resulting in an almost horizontal orientation.
- The body of medial and lateral menisci are hypointense triangles.
- The medial meniscofemoral (coronary) ligaments comprise the deep component of the MCL. The MCL is closely opposed to the body of the medial meniscus. Distally the pesanserinus tendon crosses over the tibial attachment of the MCL (not seen) and inserts upon the anteromedial proximal tibia.
- The FCL cannot be seen on a single coronal slice normally as it angles posteriorly toward its attachment along the fibular head.
- The iliotibial tract becomes more prominent on more anterior sections.
- The vastus medialis muscle is much larger than the vastus lateralis muscle at this level. The superior genicular vessel branches are located between these muscles and the adjacent femoral cortex.
- The medial femoral condyle and medial tibial plateau are more rounded whereas their lateral counterparts are more flattened in appearance. The medial femoral condyle also extends more inferiorly.

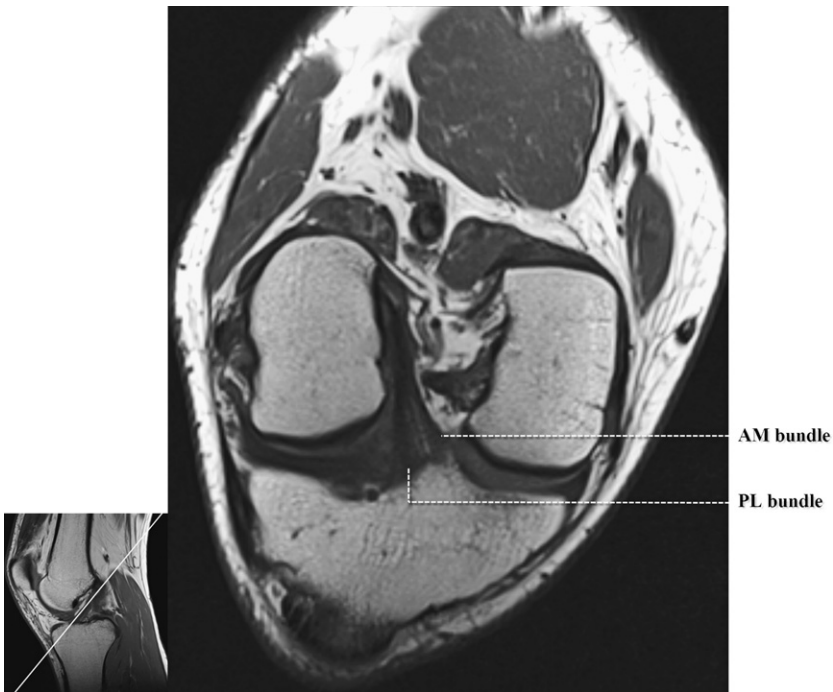
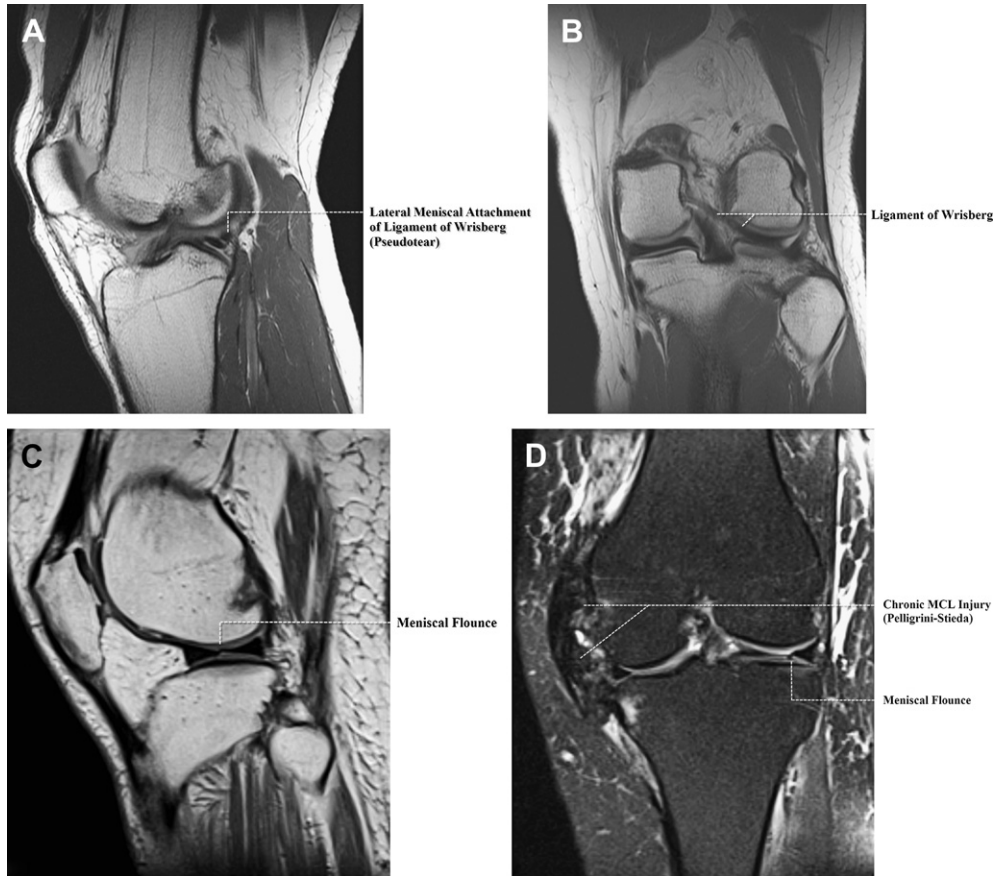


Fig. 13. Double oblique T1-weighted image. Intercondylar notch parallel to Blumenstat's line. AM, anteromedial; PL, posterolateral.

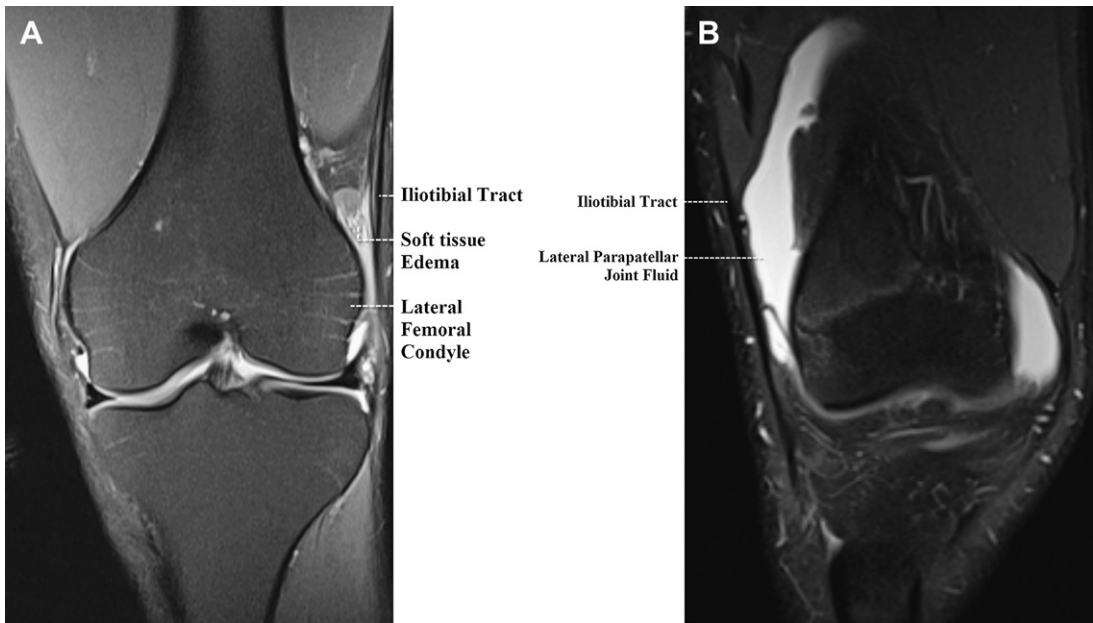
#### Key Point

- The ACL is composed of an anteromedial and posterolateral bundle, and attaches to the posteromedial lateral femoral condyle, within the posterolateral aspect of the intercondylar notch, and to the medial tibial plateau, just anterolateral to the anterior tibial spine.



**Fig. 14.** Normal variants and imaging pitfalls. (A) Sagittal proton density–weighted (PDW) image. Lateral aspect intercondylar notch. “Pseudotear” at lateral meniscal attachment of meniscofemoral ligament of Wrisberg. (B) Coronal PDW image. Immediately posterior to PCL. Meniscofemoral ligament of Wrisberg (in a different patient) extends from the posterior horn of the lateral meniscus to the medial femoral condyle, immediately posterior to the PCL. (C) Sagittal PDW image. Lateral femorotibial compartment. Meniscal flounce, characterized by single symmetric fold along inner margin of the meniscus, more commonly seen in the medial meniscus. (D) Coronal intermediate T2-weighted image with fat suppression. Mid coronal plane. Irregularity and folding (meniscal flounce, in same patient) of inner margin of lateral meniscus can be mistaken for a tear on coronal images. Incidental note is made of severe chronic injury to the MCL (Pelligrini-Stieda).





**Fig. 15.** Differentiating iliotibial band friction syndrome and lateral parapatellar joint fluid. (A) Coronal intermediate T2-weighted image with fat suppression. Mid coronal plane. Edema is seen within the soft tissues between the iliotibial band (tract) and lateral femoral condyle in this patient with iliotibial band friction syndrome. (B) Coronal intermediate T2-weighted image with fat suppression. Mid coronal plane. Fluid is seen within the lateral parapatellar recess in this patient with a moderate joint effusion. Fluid is continuous with the joint effusion in all imaging planes.

## REFERENCES

1. Stoller DW, Lejay H, Holland BA. Technical advances in musculoskeletal imaging. In: Barrett K, editor. *Magnetic resonance imaging in orthopaedics and sports medicine*, vol. 1. 3rd edition. Philadelphia: Lippincott Williams & Wilkins; 2007. p. 1–28.
2. De Maeseneer M, Van Roy F, Lenchik L, et al. Three layers of the medial capsular and supporting structures of the knee: MRI imaging-anatomic correlation. *Radiographics* 2000;20:S83–9.
3. Stoller DW, Li AE, Anderson LJ, et al. The knee. In: Barrett K, editor. *Magnetic resonance imaging in orthopaedics and sports medicine*, vol. 1. 3rd edition. Philadelphia: Lippincott Williams & Wilkins; 2007. p. 305–732.
4. Anderson MW. MR imaging of the meniscus. *Radiol Clin North Am* 2002;40:1081–94.
5. Sanders TG, Linares RC, Lawhorn KW, et al. Oblique meniscomeniscal ligament: another potential pitfall for a meniscal tear- anatomic description and appearance at MR imaging in three cases. *Radiology* 1999;213:213–6.
6. Pfirrmann CW, Zanetti M, Hodler J. Joint magnetic resonance imaging; normal variants and pitfalls related to sports injury. *Radiol Clin North Am* 2002;40:167–80.
7. Manaster BJ, Andrews CL, Petersilge CA, et al. Hip & pelvis: thigh overview. In: McAllister L, editor. *Diagnostic and surgical imaging anatomy musculoskeletal*. 1st edition. Salt Lake City: Amirsys Inc; 2006. p. V190–279.
8. De Abreu MR, Kim HJ, Chung CB, et al. Posterior cruciate ligament recess and normal posterior capsular insertional anatomy: MR imaging of cadaveric knees. *Radiology* 2005;236:968–78.
9. Wangwinyuvirat M, Dirim B, Pastore D, et al. Prepatellar quadriceps continuation: MRI of cadavers with gross anatomic and histologic correlation. *AJR Am J Roentgenol* 2009;192:W111–6.
10. Beaman FD, Peterson JJ. MR imaging of cysts, ganglia, and bursae about the knee. *Radiol Clin North Am* 2007;45:969–82.
11. Hennigan SP, Schneck CD, Mesgarzadeh M, et al. The semimembranosus-tibial collateral ligament bursa. Anatomical study and magnetic resonance imaging. *J Bone Joint Surg Am* 1994;76(9):1322–7.
12. Klecker RJ, Winalski CS, Aliabadi P, et al. The aberrant anterior tibial artery: magnetic resonance appearance, prevalence, and surgical implications. *Am J Sports Med* 2008;36:720–8.
13. El-Khoury GY, Bergman RA, Montgomery WJ. Knee. In: Pope CF, Montgomery WJ, editors. *Sectional anatomy by MRI*. 2nd edition. Philadelphia: Churchill Livingstone Inc; 1995. p. 603–68.