

Nuclear Medicine/PET Clinical Image Atlas

INTRODUCTION	1
GENERAL TIPS AND REMINDERS	2
PLANAR	3
Hepatobiliary	3
Lung Perfusion.....	5
Thyroid/Parathyroid.....	6
Planar (Miscellaneous)	7
Planar - Bone.....	8
Complete Planar Submission	10
SPECT	11
Bone SPECT (special processing xSPECT).....	14
Cardiology (and planar) MUGA.....	16
MUGA Gated SPECT.....	17
CARDIOLOGY	18
Myocardial Perfusion	18
PET: ONCOLOGY AND BRAIN	22
PET: ONCOLOGY	24
PET: CARDIAC.....	28
COMMON ERRORS	29

Revision History for this Article

Date 4/14/2022

Section Myocardial Perfusion p. 21

Description of Revision(s)

Better description of ROI and curve for submission

INTRODUCTION

The links below will direct users to requirements for NM & PET Clinical and Phantom submissions. Please review carefully prior to the uploading of images and submission of the testing packets.

<https://accreditationsupport.acr.org/support/solutions/articles/11000062796-accreditation-testing-overview-nuclear-medicine-and-pet>

<https://accreditationsupport.acr.org/support/solutions/articles/11000062797-clinical-image-testing-nuclear-medicine>

<https://accreditationsupport.acr.org/support/solutions/articles/11000062798-phantom-images-nuclear-medicine>

<https://accreditationsupport.acr.org/support/solutions/articles/11000062799-clinical-image-testing-pet>

<https://accreditationsupport.acr.org/support/solutions/articles/11000062800-phantom-testing-pet>

Testing packages are based on the exams selected in the accreditation application. If you need to make corrections to the testing packet, i.e., remove a module or change exams; please submit a support ticket at the link below BEFORE submitting the testing packet.

<https://accreditationsupport.acr.org>

How can we help you today?

Enter your search term here...

[+ New support ticket](#)
[Check ticket status](#)

Emergency use:

If you are doing a type of scan less than 5 times a month or 25 times a year, **YOU ARE NOT REQUIRED TO APPLY**. This also applies to Tl201, Ga67, & In111.

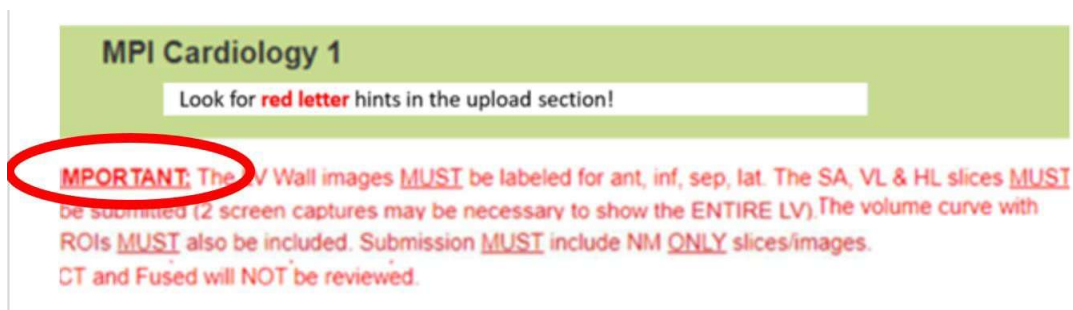
Timeframe	Acceptable Number of 'Emergency Use' Examinations Performed Outside a Unit's Accreditation Status	
	MRI	Nuclear Medicine/PET/Ultrasound
30 days	Fewer than 10	Fewer than 5
12 months	Fewer than 50	Fewer than 25

GENERAL TIPS AND REMINDERS

1. Reports and written procedures **MUST NOT BE PASSWORD PROTECTED.**
2. Incomplete or incorrect uploads (images and/or documentation) will be removed and sites will need to re-upload. This can slow down the review process.
3. Cell phone images, scanned paper or color photos and non-digital images (i.e., scanned documents saved as jpg) are not acceptable as electronic clinical or phantom uploads. The image below on the left shows a paper print scanned and uploaded as jpg. The image on the right is the same image submitted as a “true” digital image.



4. The ACR is requesting examples of a site’s “Best Work”.
5. Look for red-lettering instructions when uploading images in the [ACredit.acr.org](https://www.acredit.org) database.

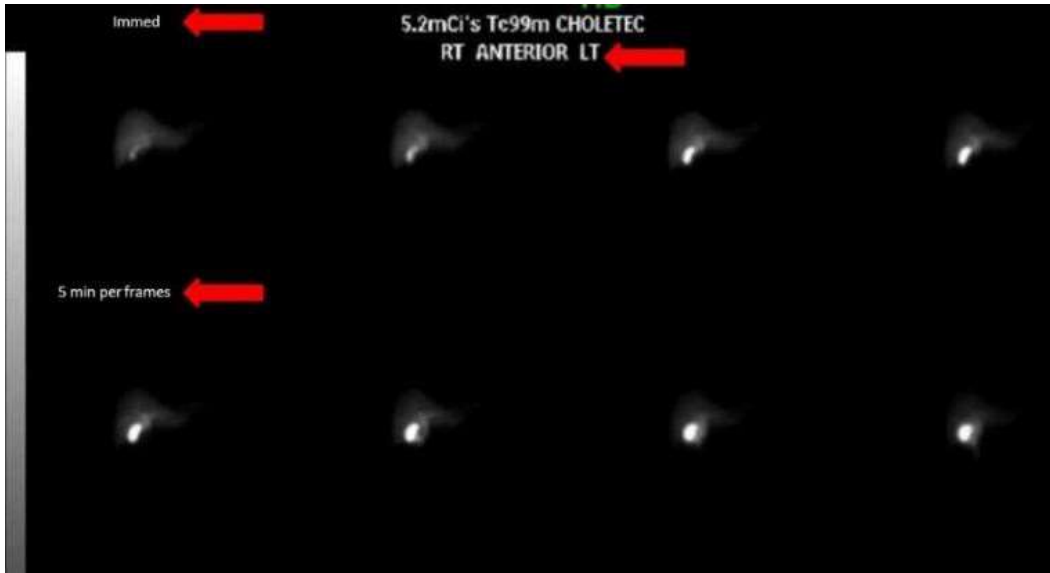


The following pages show image examples only and the images do not include all required annotations or formatting. It is recommended you review the applicable testing requirement articles and ensure all required annotations are available either on the full page or DICOM overlay before submitting for accreditation review. DICOM overlays should NOT obscure the image.

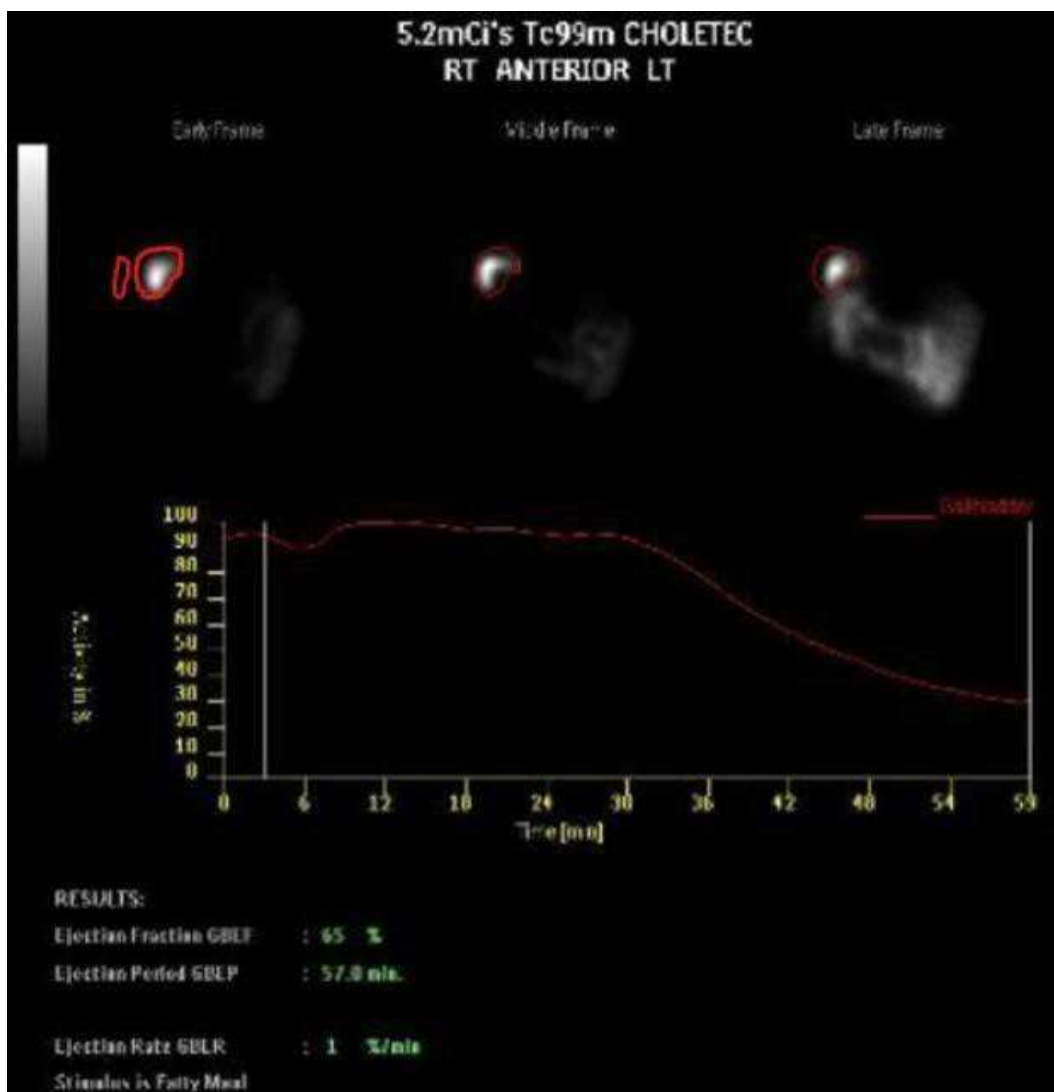
PLANAR

Hepatobiliary


If EF was performed, include the ROI for the gallbladder and background. Ensure at least one image in the series is labeled for laterality.



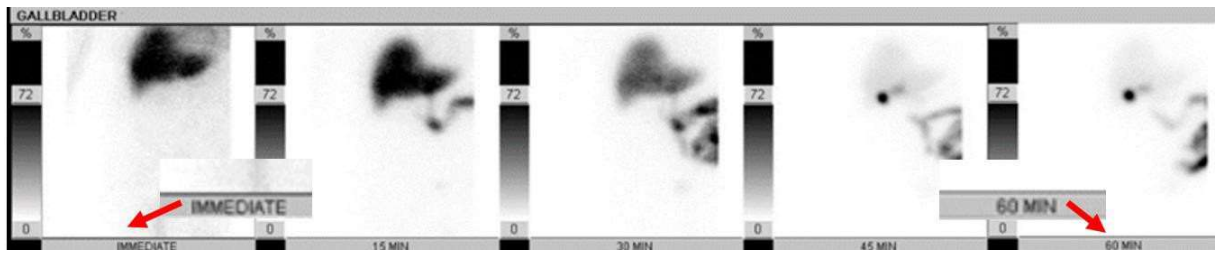
This example shows an early, mid and late frame image.



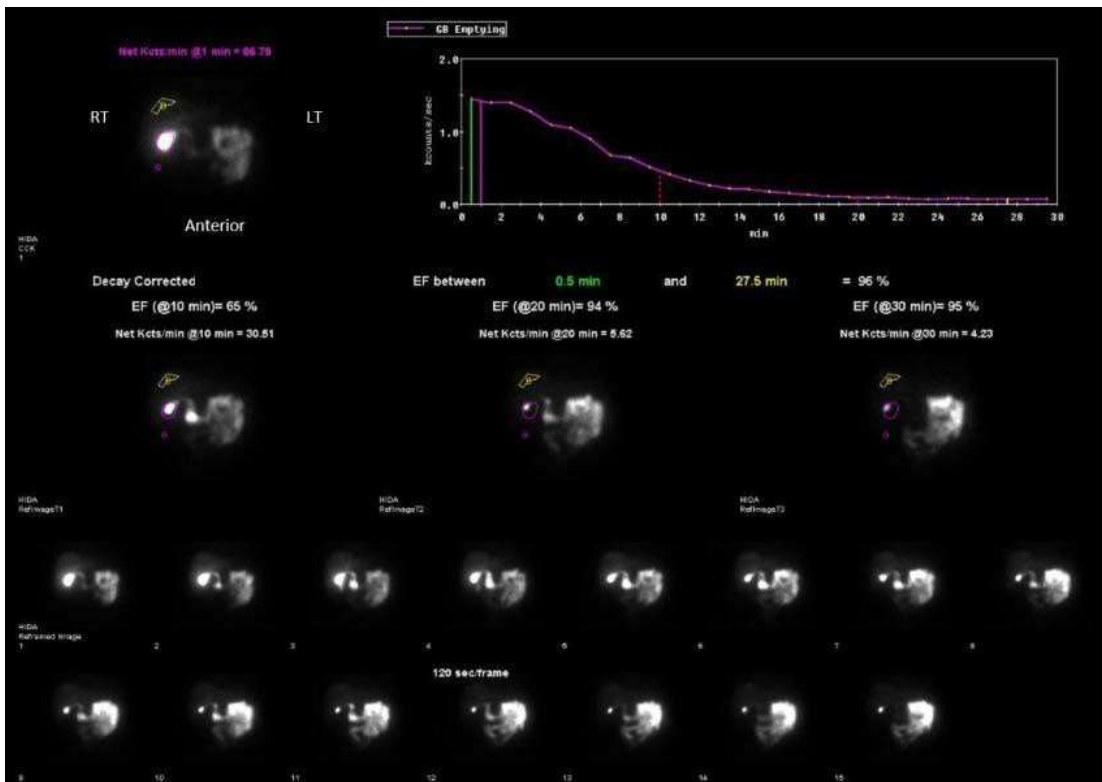
Include all images for pre & post CCK.



Images may be re-framed to show 5, 10, or 15 min frames, etc.

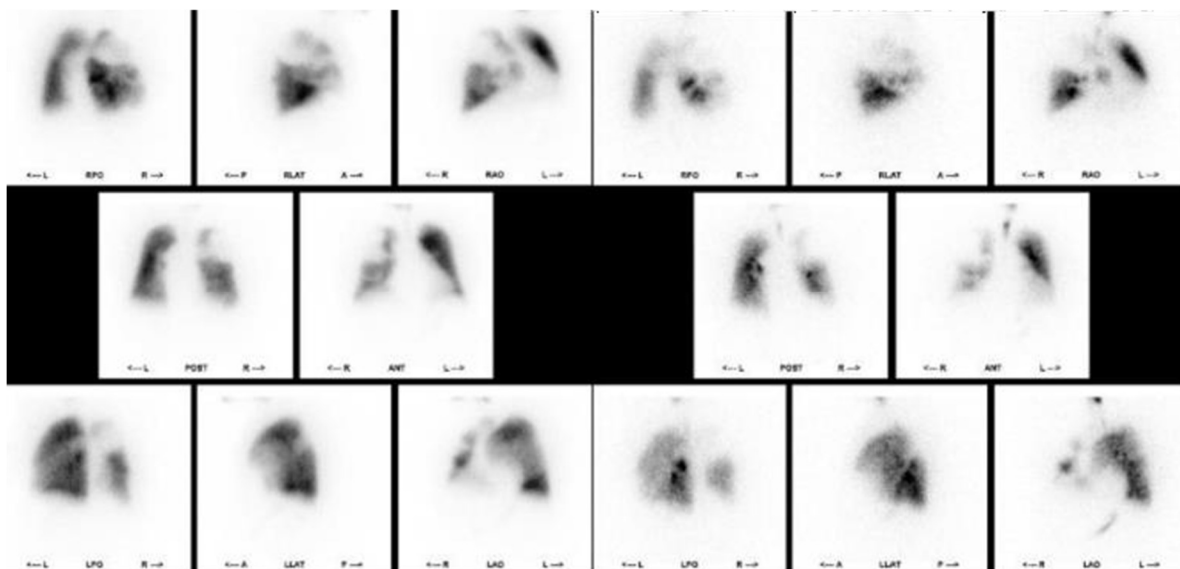


Good CCK set below- includes the complete 30 minutes of the acquisition, includes the EF results and ROIs (GB & ROI), and images are labeled for laterality.

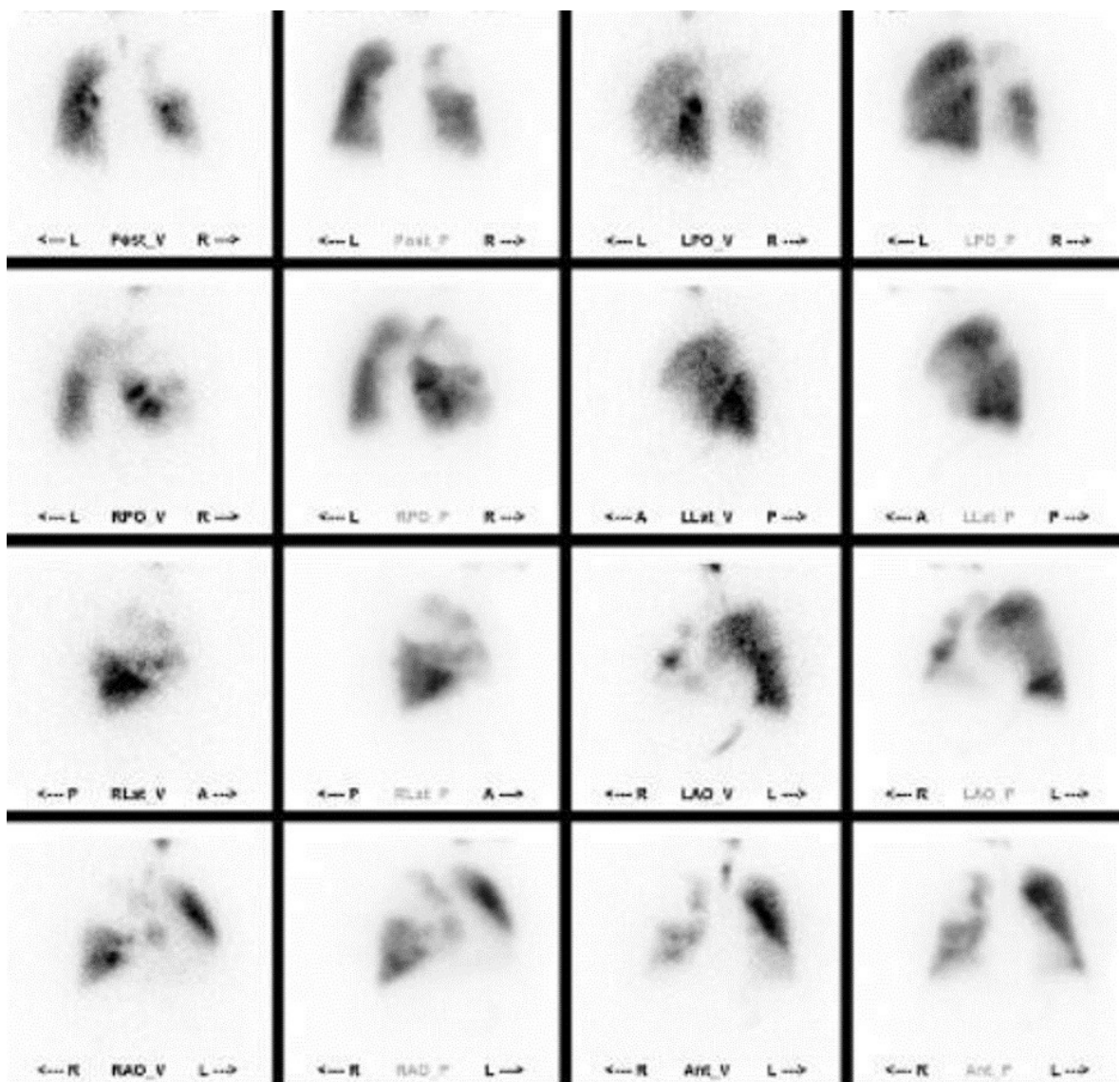


Lung Perfusion

Include all images as noted in the physician's report, i.e., ventilation images must be included if performed.

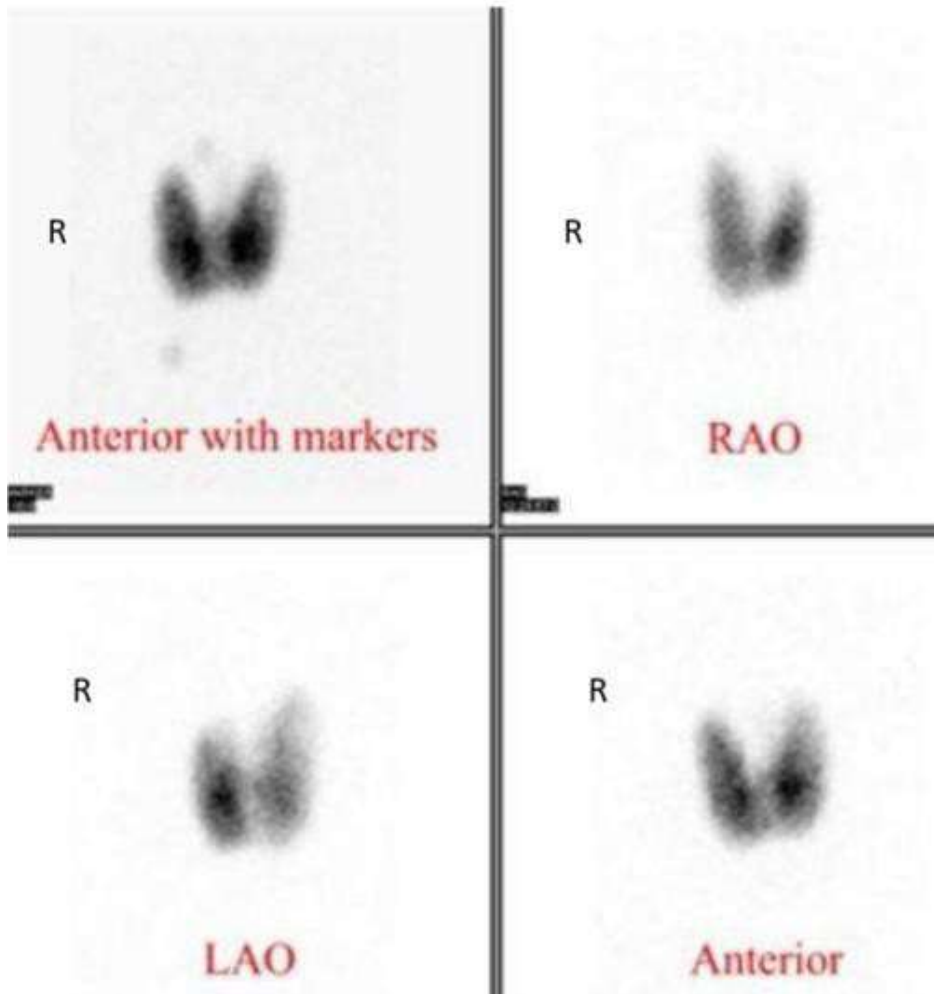


Good example of all images (Ventilation and Perfusion) submitted with appropriate laterality labels. Image set below is also marked with a V and P to distinguish the ventilation and perfusion.

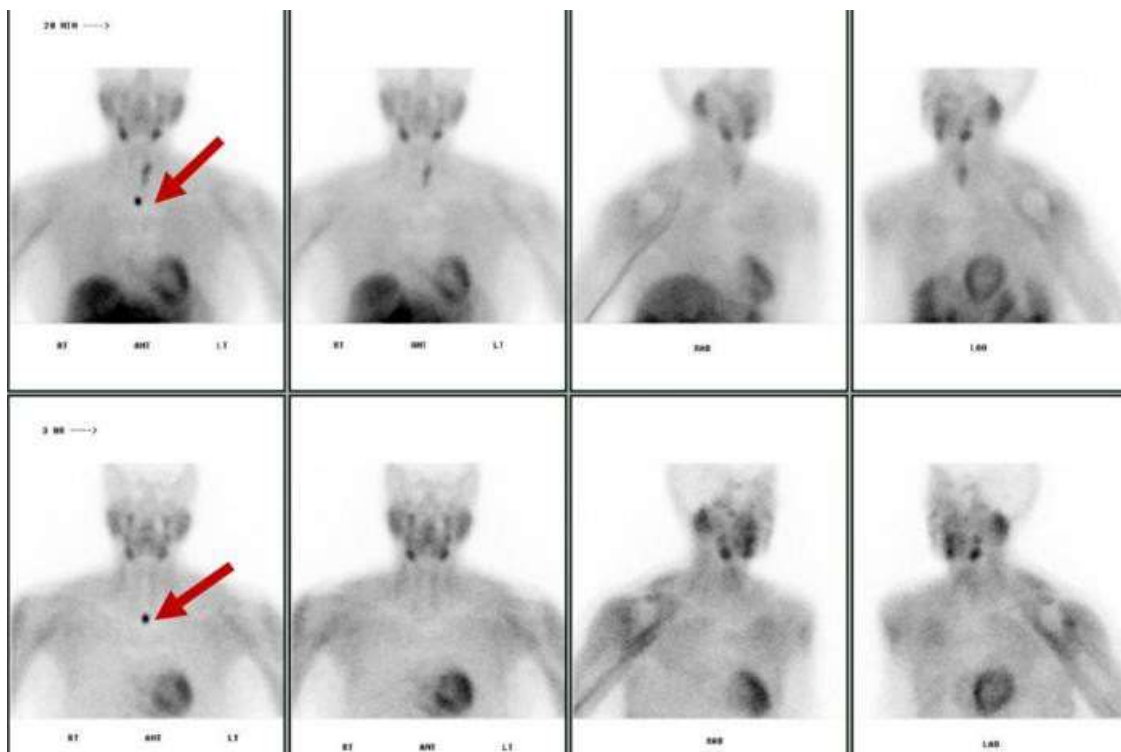


Thyroid/Parathyroid

A common display is a 4-quadrant format. Ensure the images are labeled for laterality and view (i.e., Anterior, LAO, RAO, etc).



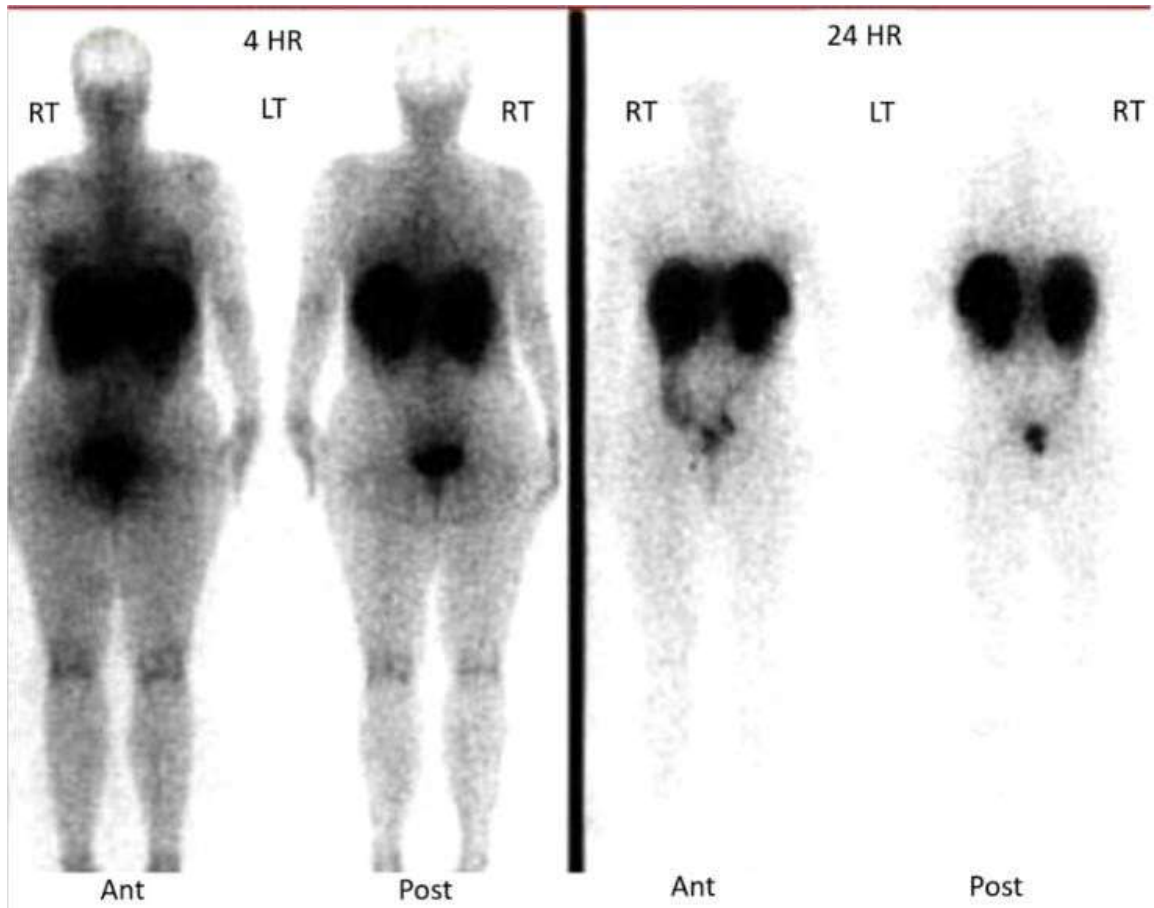
Is the hot spot in the early and delayed images a parathyroid adenoma or sternal notch marker? Images should be marked clearly for “hot” markers. ACR reviewers or outside facilities may incorrectly misinterpret this as an adenoma.



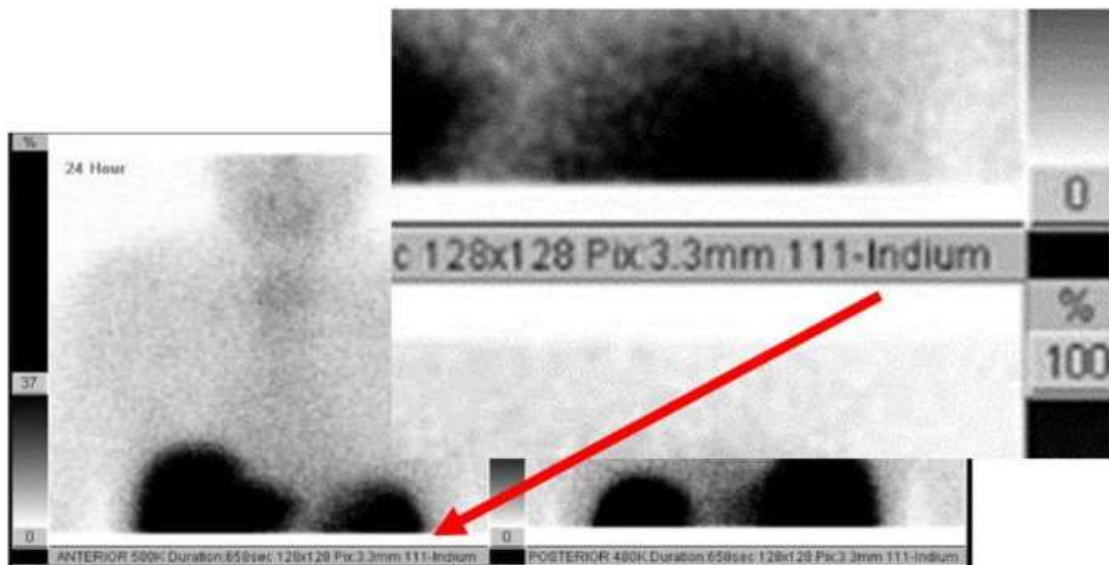
Planar (Miscellaneous)

All other WB and SPOT images (I-131, Ga-67, In-111):

Ensure images are labeled for laterality **AND** delay times (especially for scans performed on multiple days).

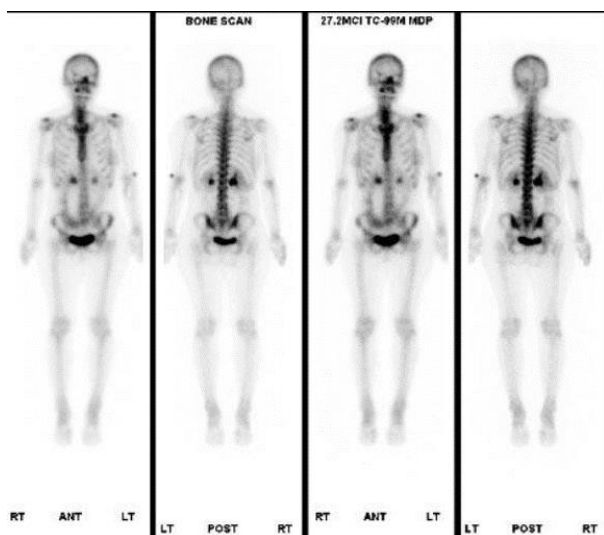


It is also recommended to include isotope or RPH, i.e., Octreoscan, etc.

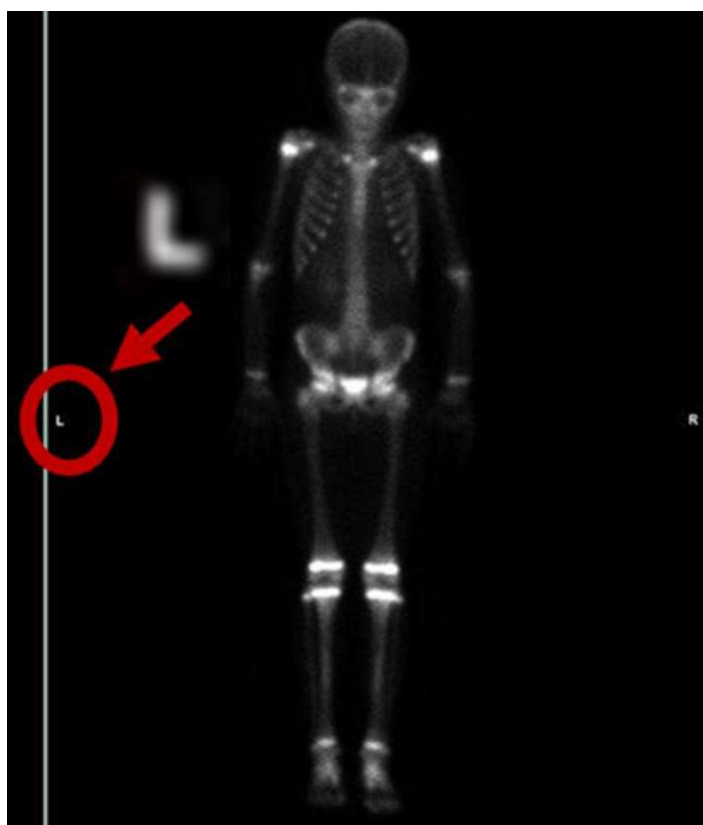
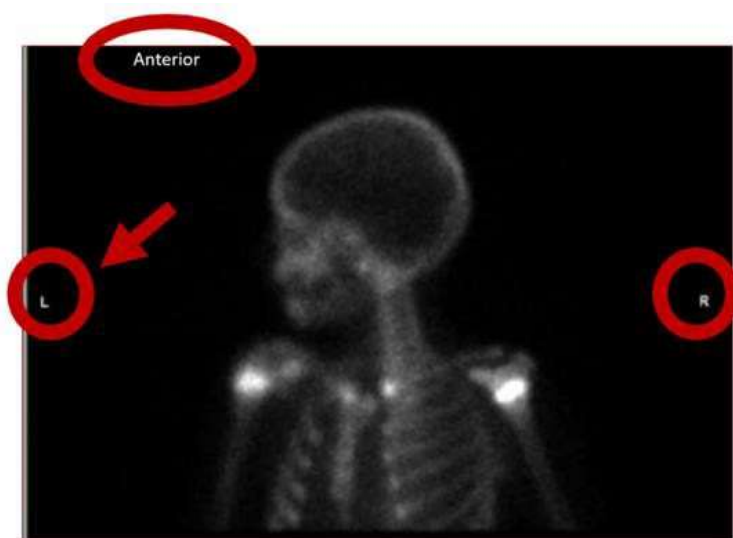

Planar - Bone

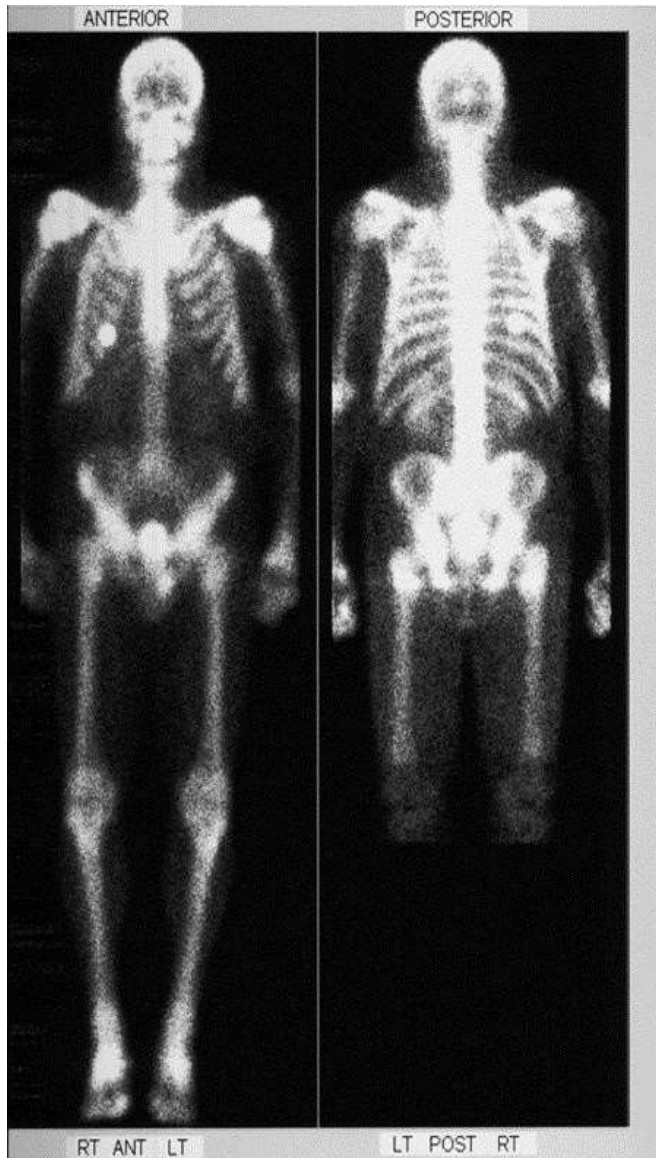
Images must be labeled as to laterality and orientation. Studies will **fail** if images are not properly labeled for laterality.



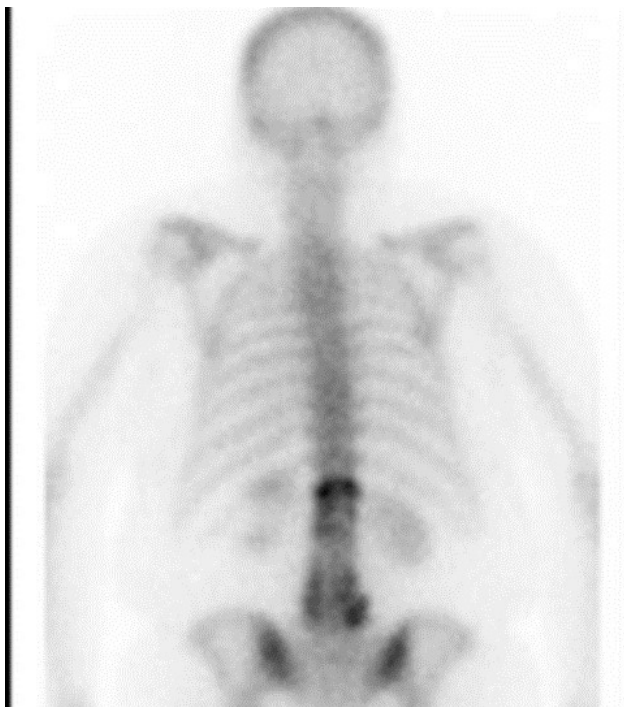Ensure laterality is correct!



If submitting something other than DICOM, i.e., jpg, tif, png, etc., ensure the intensities are adjusted prior to saving the images. These types of files are not able to be windowed by the reviewers and may fail if they are not interpretable.



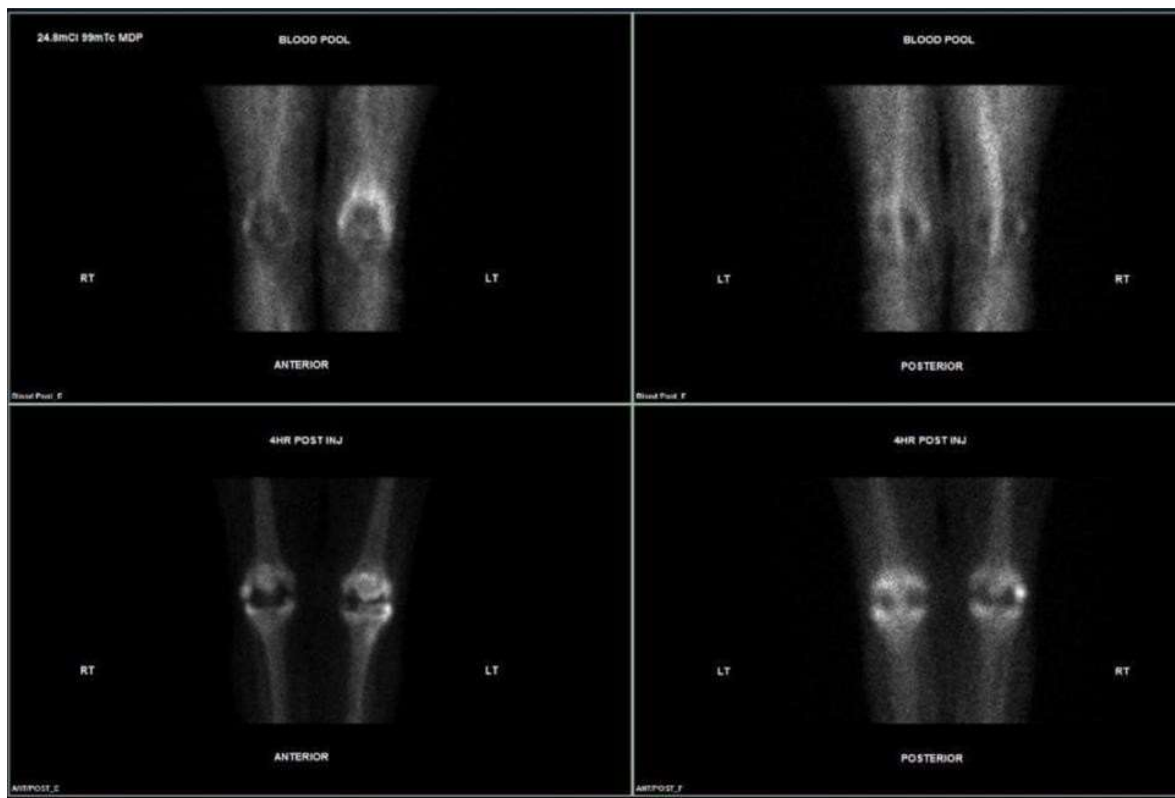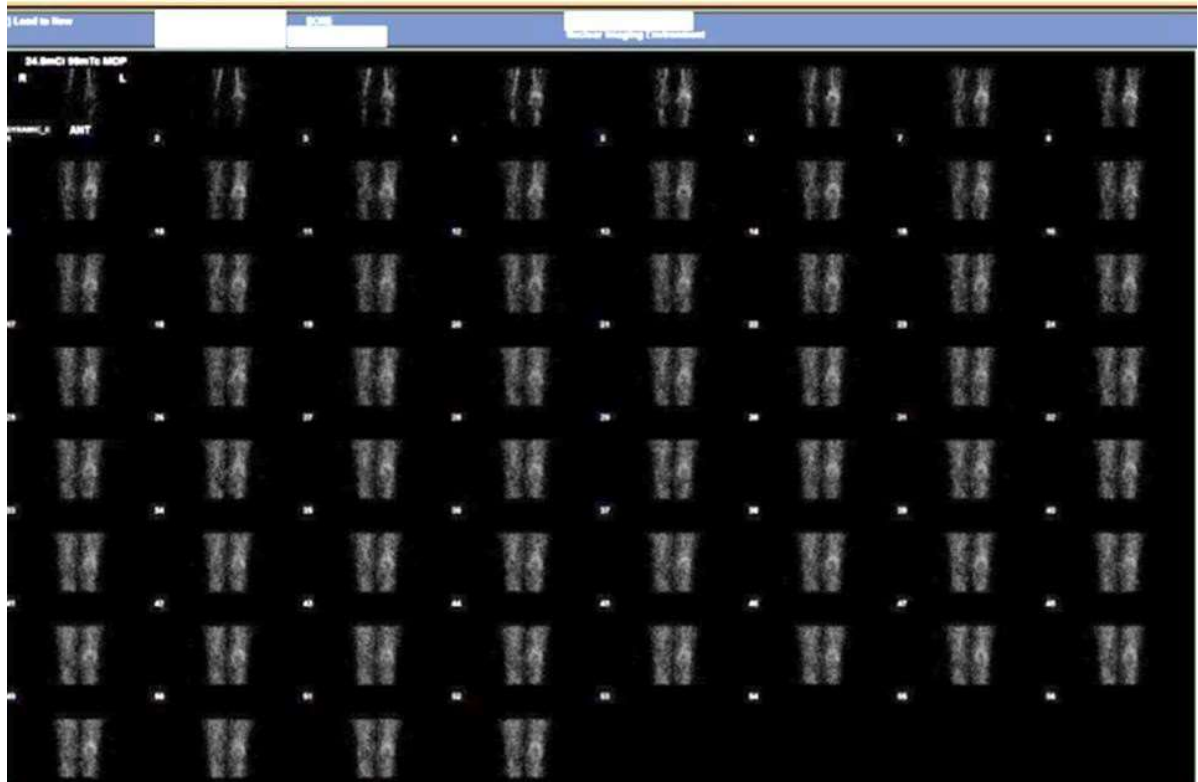
The ACR requests examples of best work. Bone scans should show vertebral bodies.



Complete Planar Submission

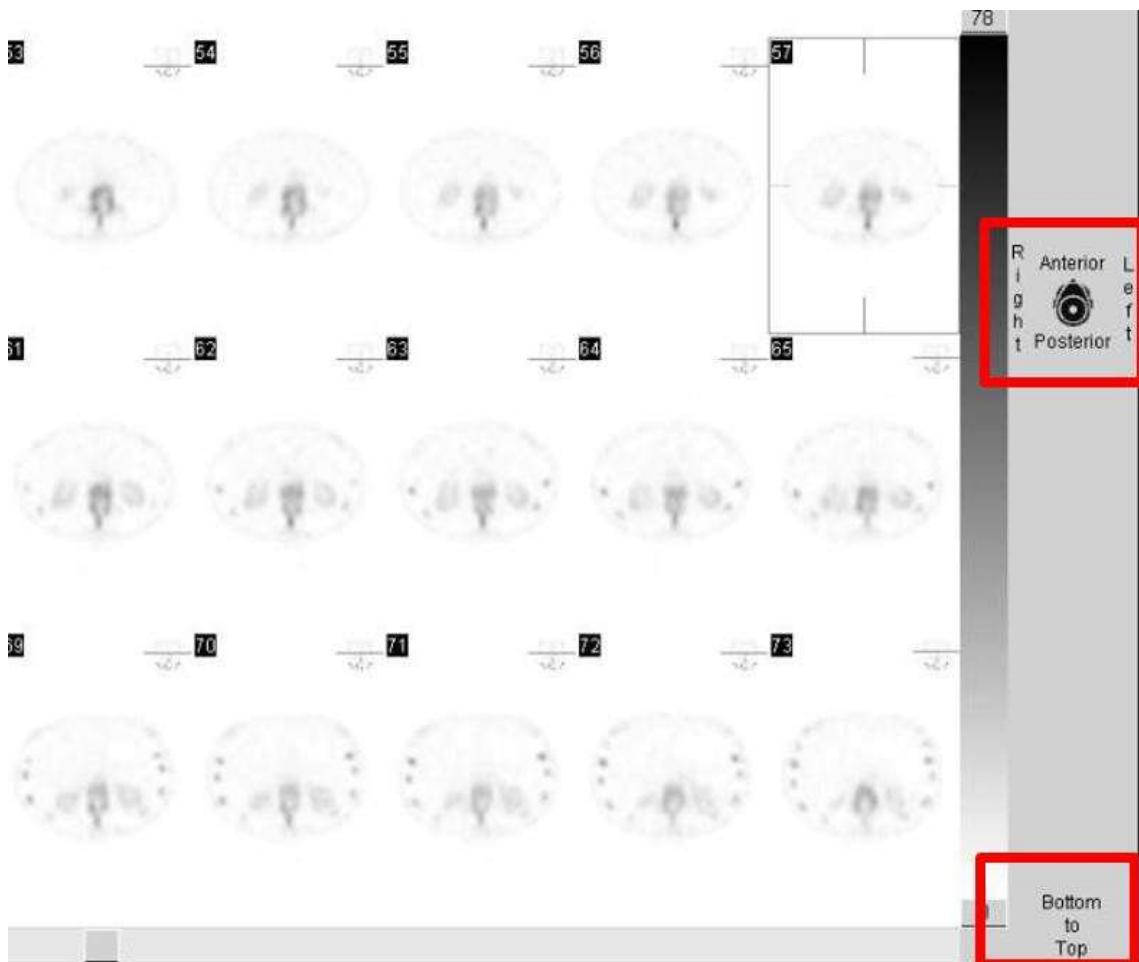
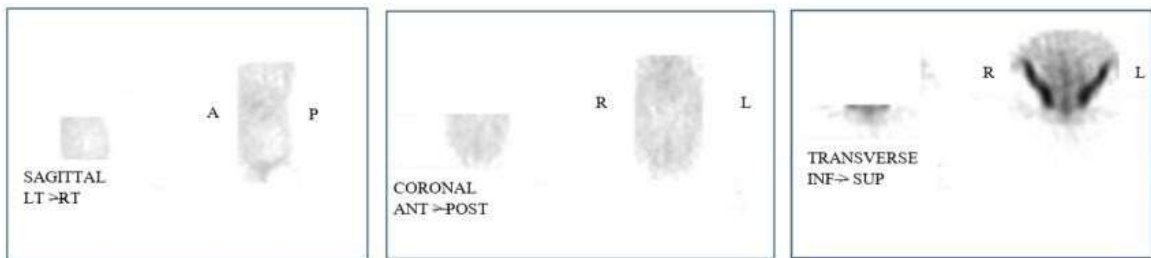
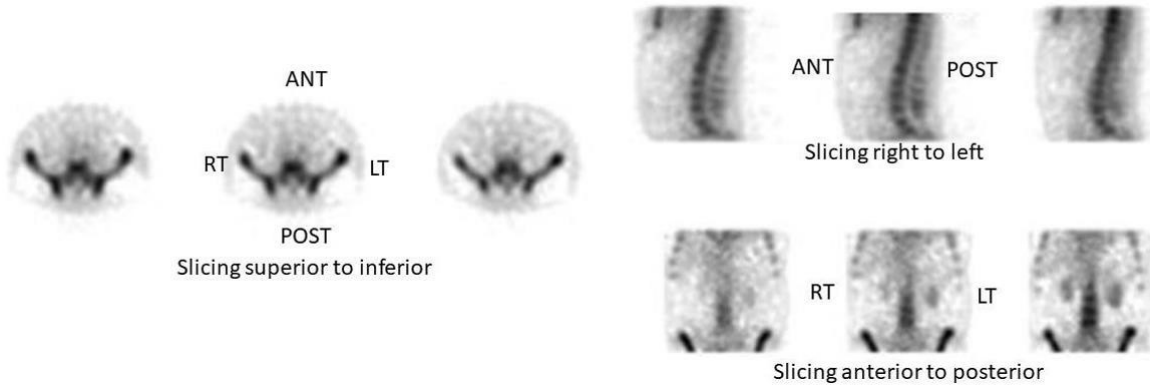
Per testing instructions: Please submit **ALL images** acquired for each exam as described in the physician's report. For example, CCK pictures must be included with hepatobiliary exam, if acquired.

The patient report indicated flow, blood pool, and delays were obtained. The submission correctly included a complete 3-phase Bone scan. Images are correctly labeled for flow, blood pool and 4HR Post Inj.

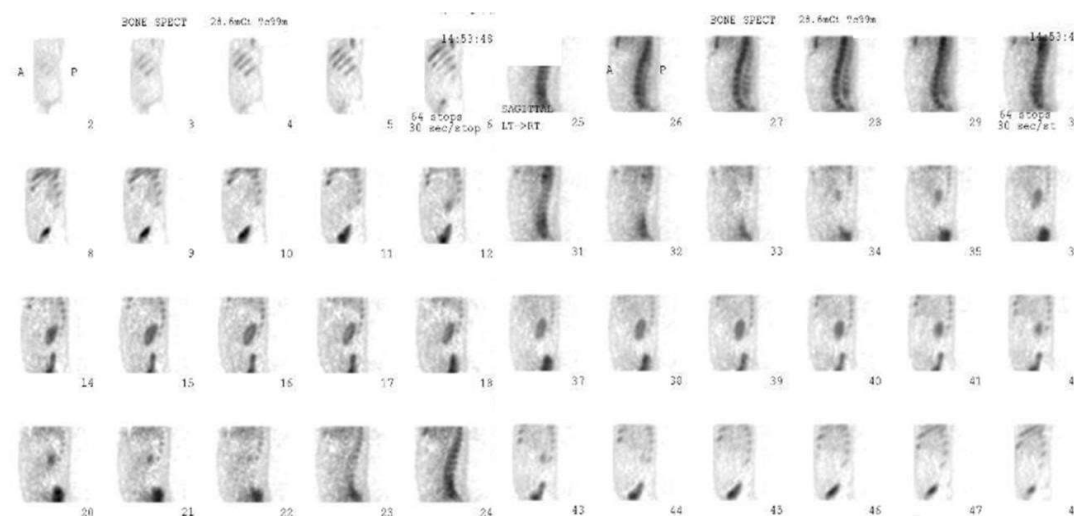
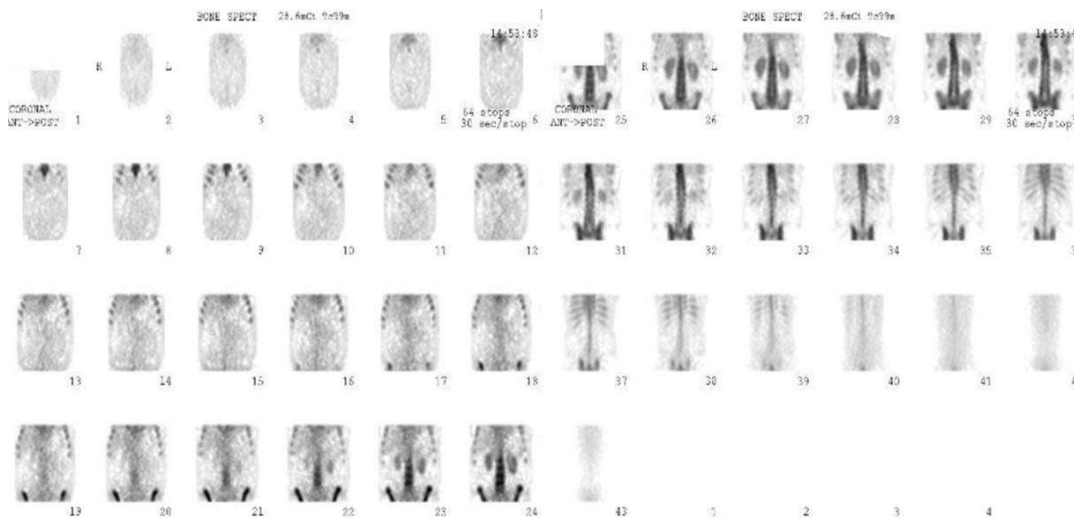
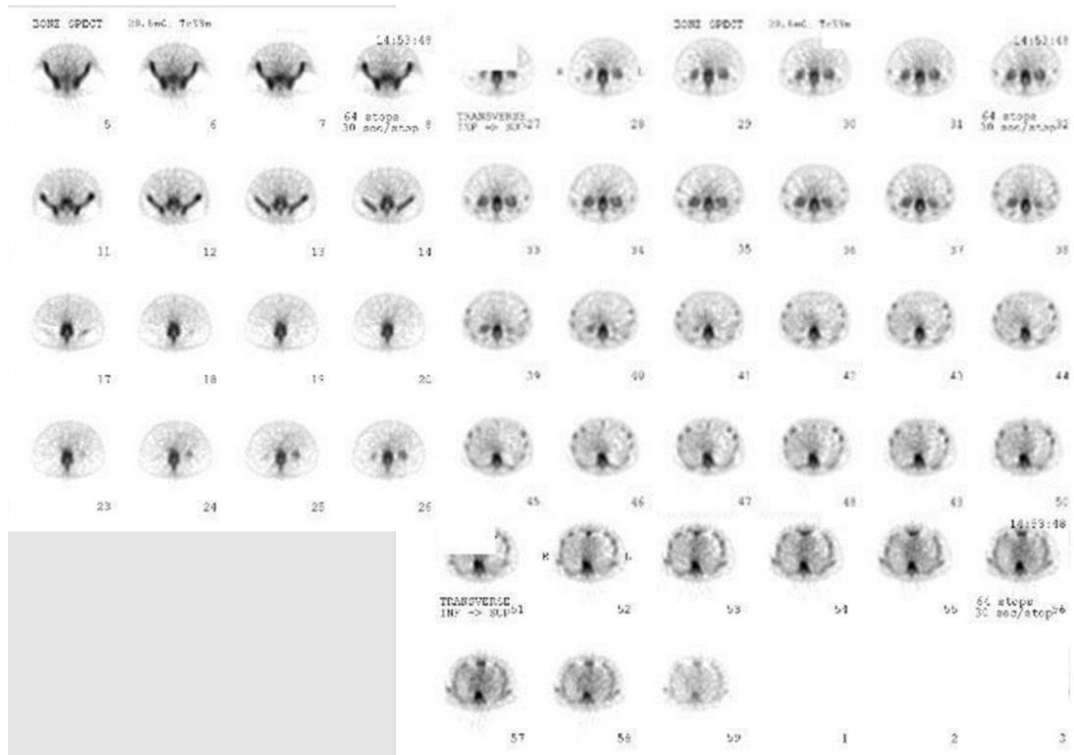


SPECT

Images should show laterality and orientation. SPECT images must include all 3 planes and display the ***entire*** SPECT volume.



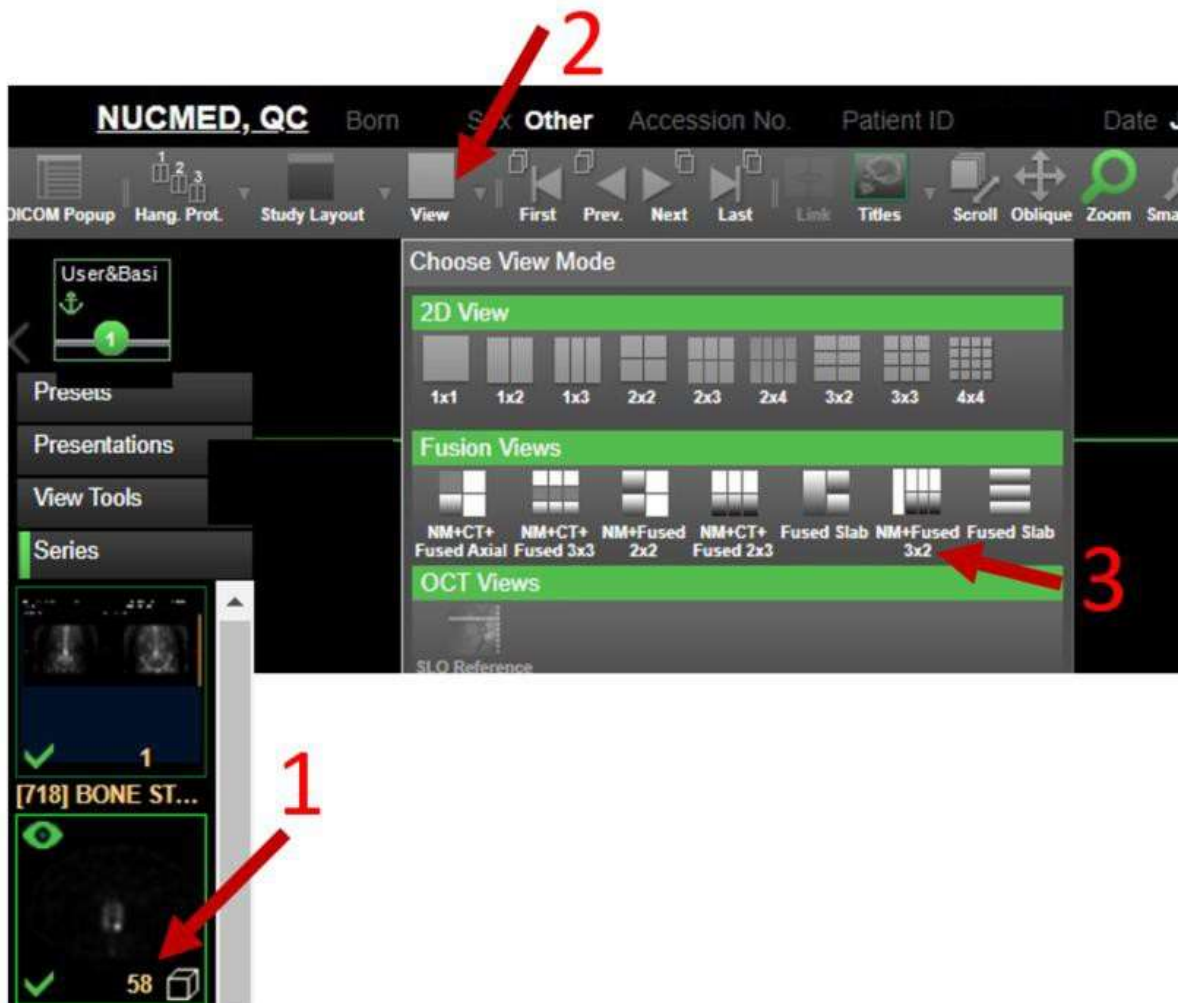
If submitting screen captures (DICOM axial slices recommended, see next page), include the entire SPECT volume, top to bottom, side to side, and front to back.



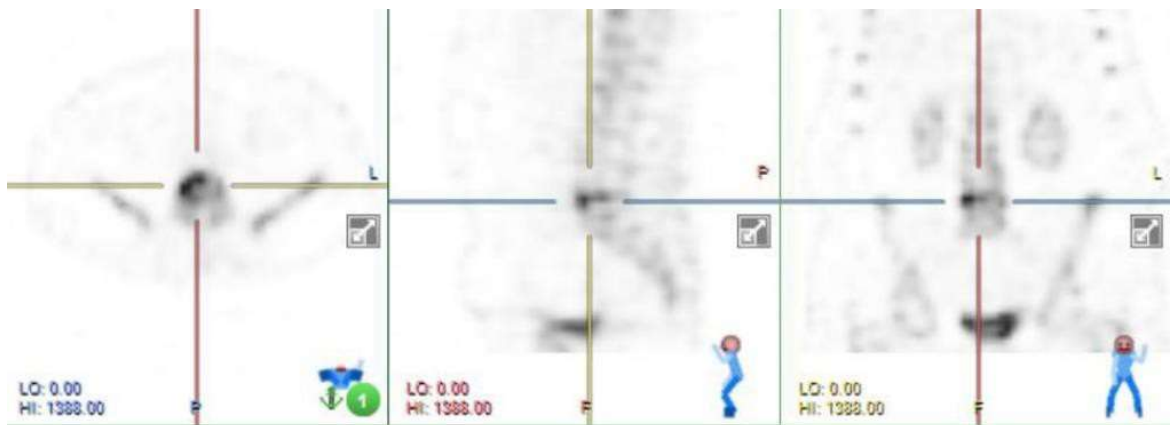
Uploading Axial SPECT Images as DICOM

Sites may now upload **DICOM** axial slices now, in lieu of all three planes.

After uploading the DICOM axial slices, click on the axial dataset (1), View tool (2), and select NM+Fused 3x2 (3)



It will open the file in a 3 view display. This only works with DICOM files. If the images do not display properly, contact the ACR for assistance, or check with your IT/PACs team.



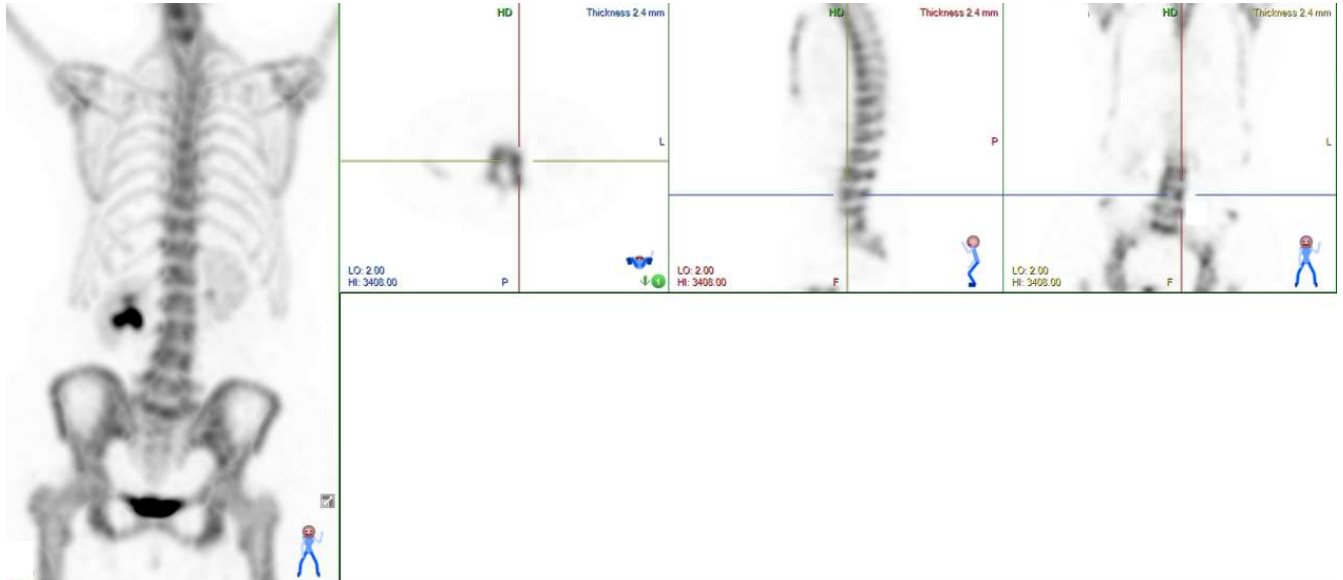
Special Processing Programs

Special programs for processing, i.e. xSPECT may look different.

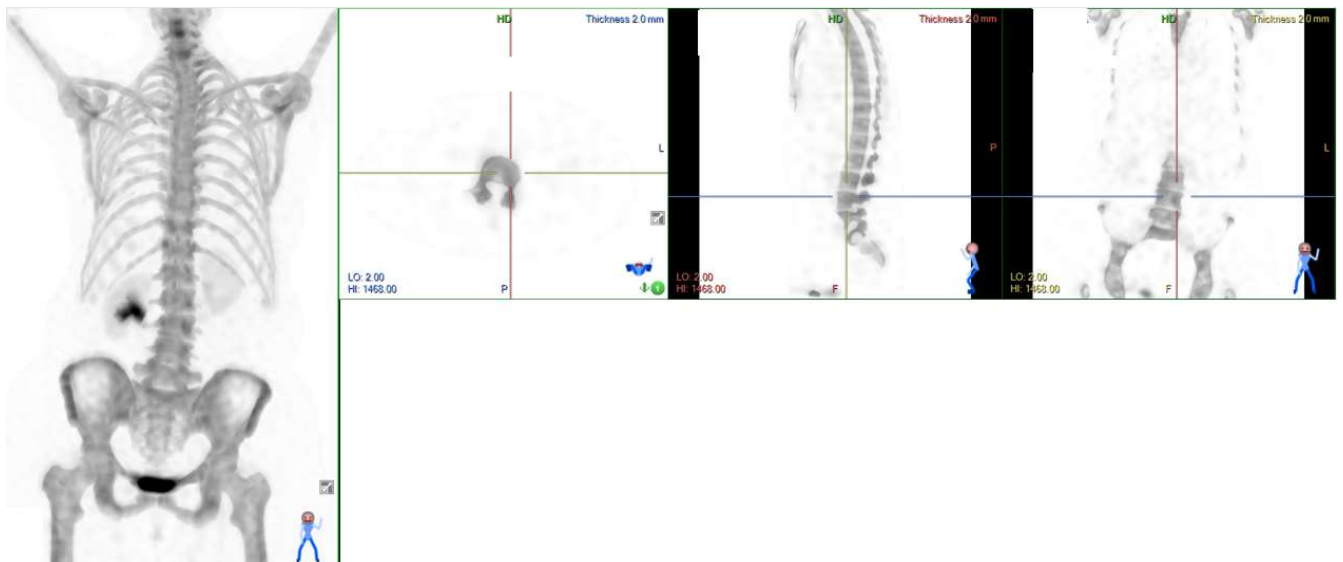
While the ACR understands the images in example #2 is the usual appearance and may be used to read at your site, it is recommended to include the more "usual" appearing NM SPECT slices as shown in example #1.

It is recommended sites upload both sets.

Example 1 - 3D iterative with attenuation correction

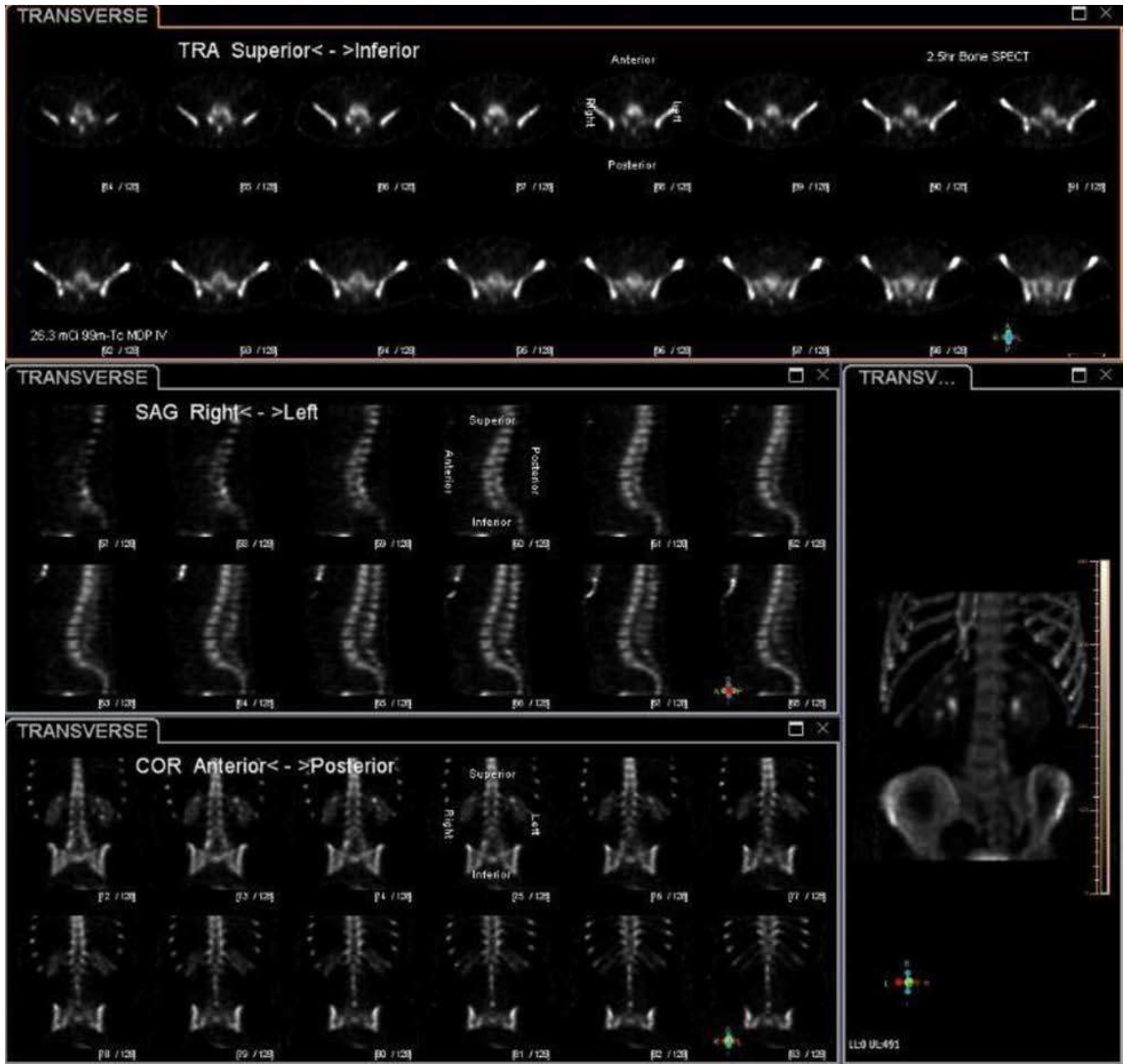


Example 2 - xSPECT processing



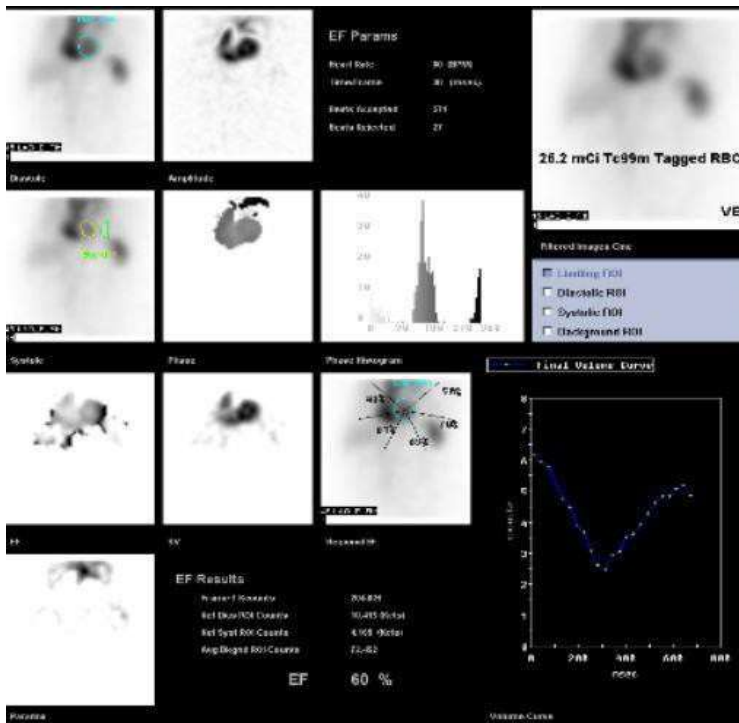
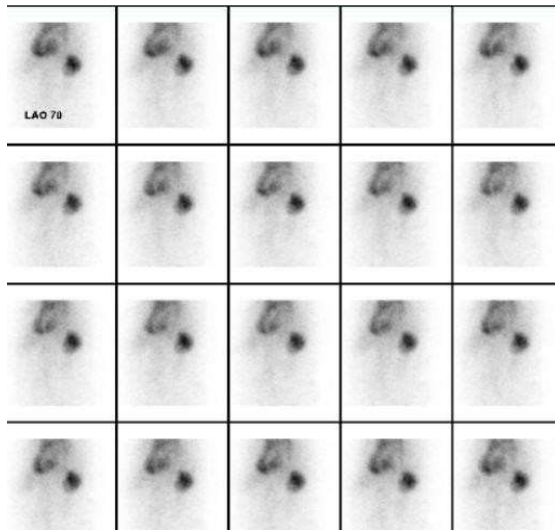
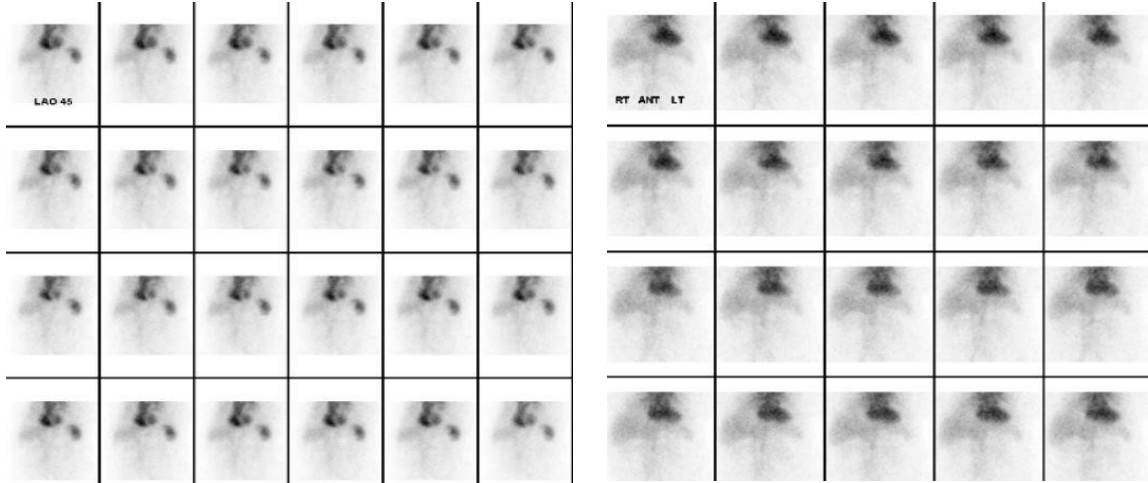
Incomplete SPECT Submission

The entire spine is not seen in the axial, sagittal, or coronal plane.



Cardiology (and planar) MUGA

Images of the entire cardiac cycle for each projection **must** be submitted for the MUGA, **as well as** an image of the ejection fraction curve. Images must be labeled for the view, i.e., Anterior, 45 LAO, LPO, etc. MUGA exams for chemotherapy may submit LAO only. If the patient history indicates cardiac issues, i.e., cardiomyopathy, the exam should include at least one other view. The report should indicate the views acquired, i.e., LAO, Anterior, Lateral, etc.

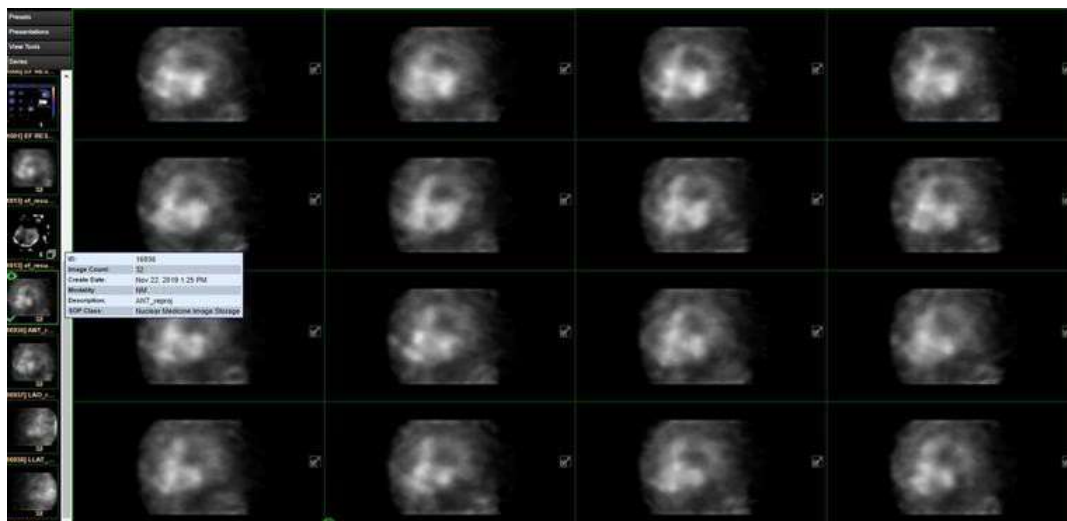
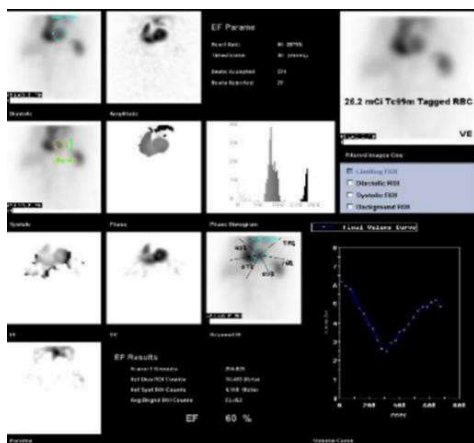
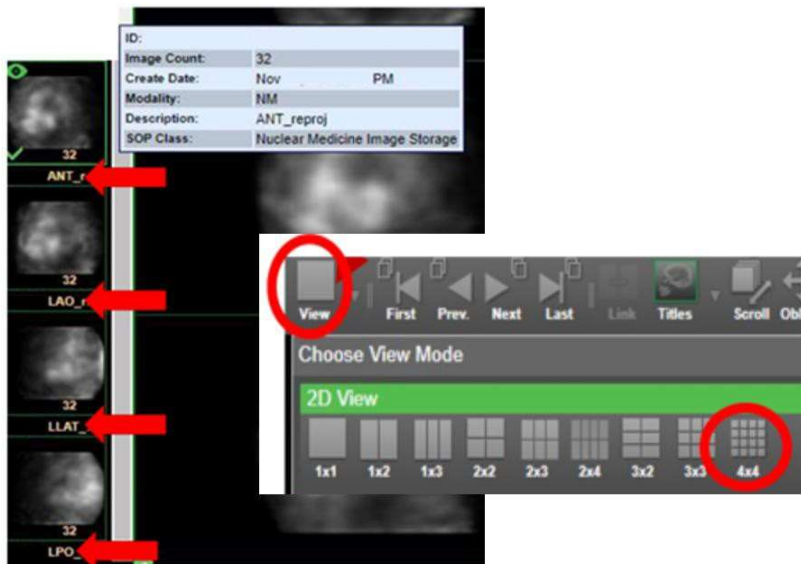


MUGA Gated SPECT

If submitting gated SPECT, you must include the results page that includes the volume curve, ROIs and ejection fraction.

You must also include reconstructed images of the LAO, Anterior and Lateral views. They may be uploaded as screen captures in a splash page using 4x4 or 5x5 formats. Please make sure to label the views as Ant, LAO or LAT.

You may need to contact the vendor applications for assistance with reconstructing in multiple views. If uploading the recon files, select the file on the left, click on "View" And select 4x4.

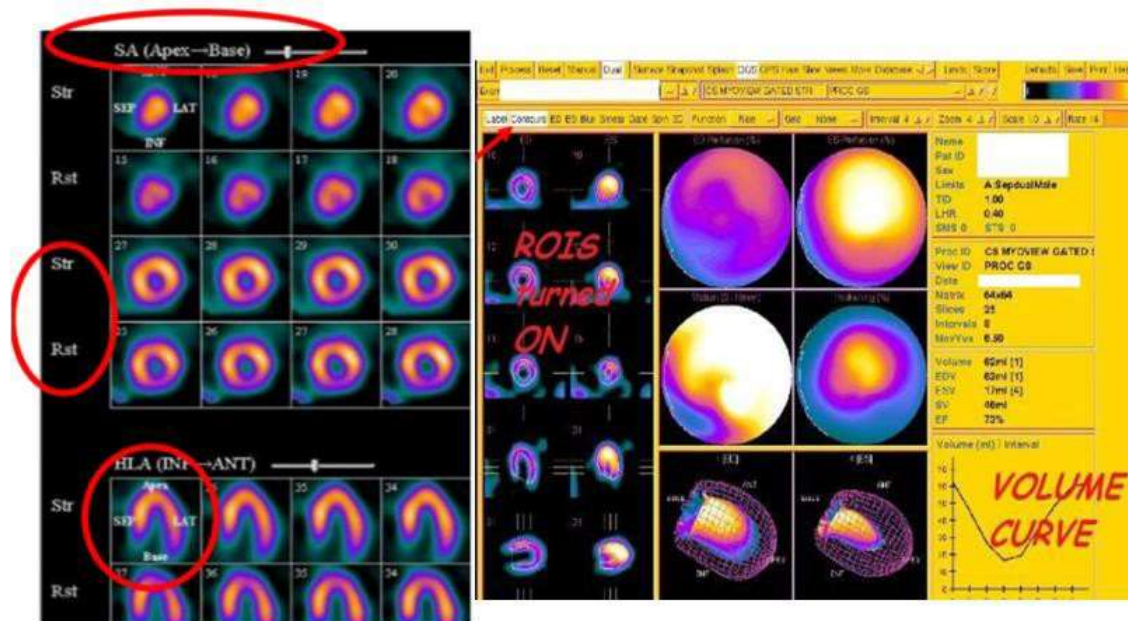


CARDIOLOGY

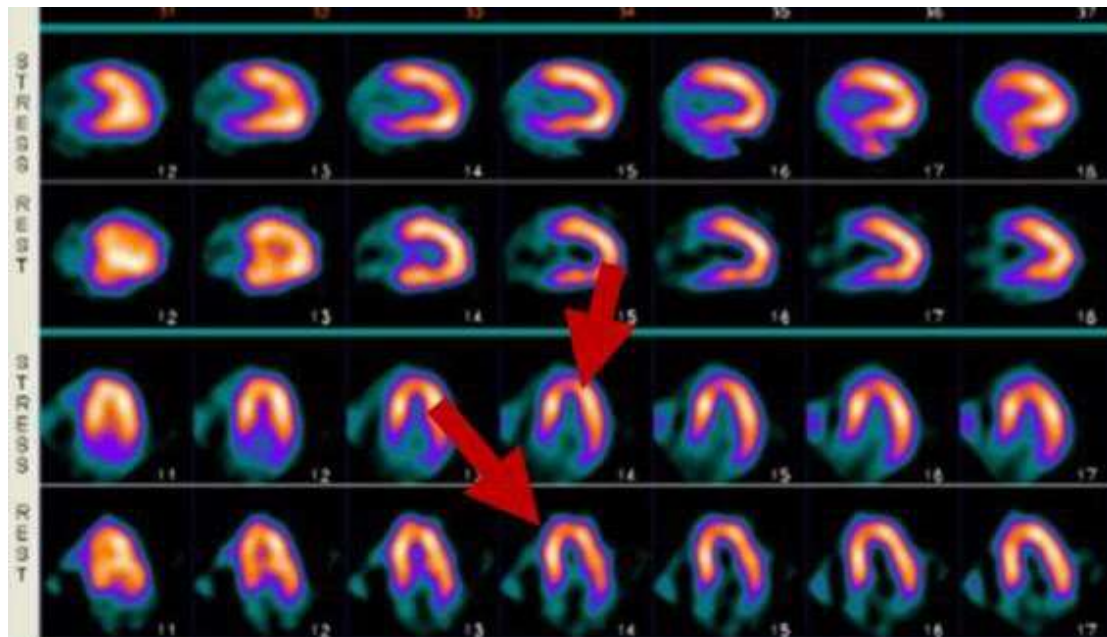
Myocardial Perfusion

SPECT myocardial perfusion images **must** include the stress and rest slices (from apex to base and wall-to-wall). **The walls of the heart must be labeled (i.e. anterior, inferior, septal, & lateral).** In addition, the images depicting the ROIs (end-systole and end-diastole) used to generate the EF as well as an image of time activity or volume curve depicting the EF **must** be submitted. The Image directly below shows correct laterality, orientation, and Stress vs Rest correctly labeled.

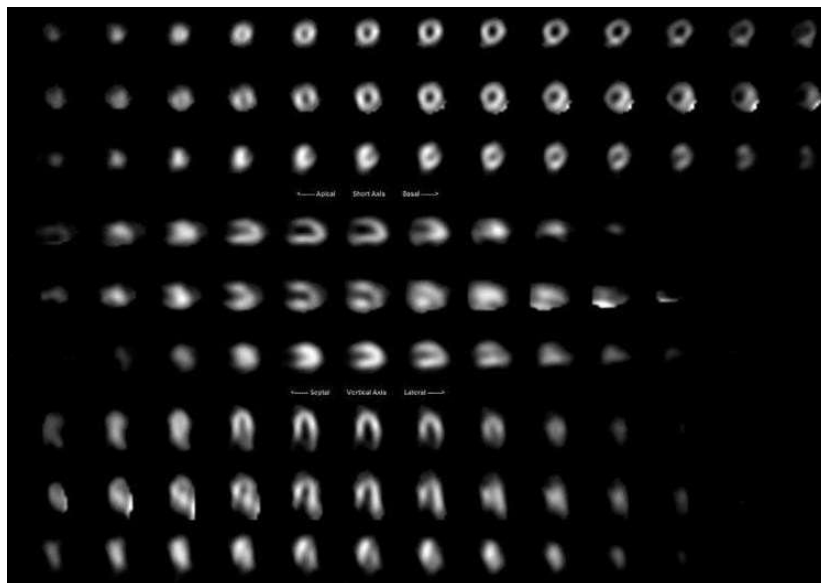
Exams submitted **MUST be Stress and Rest.** Single stress or rest only are not acceptable. Stress with prone but no rest is not acceptable.



Submit "best" work. Image below shows poor processing.

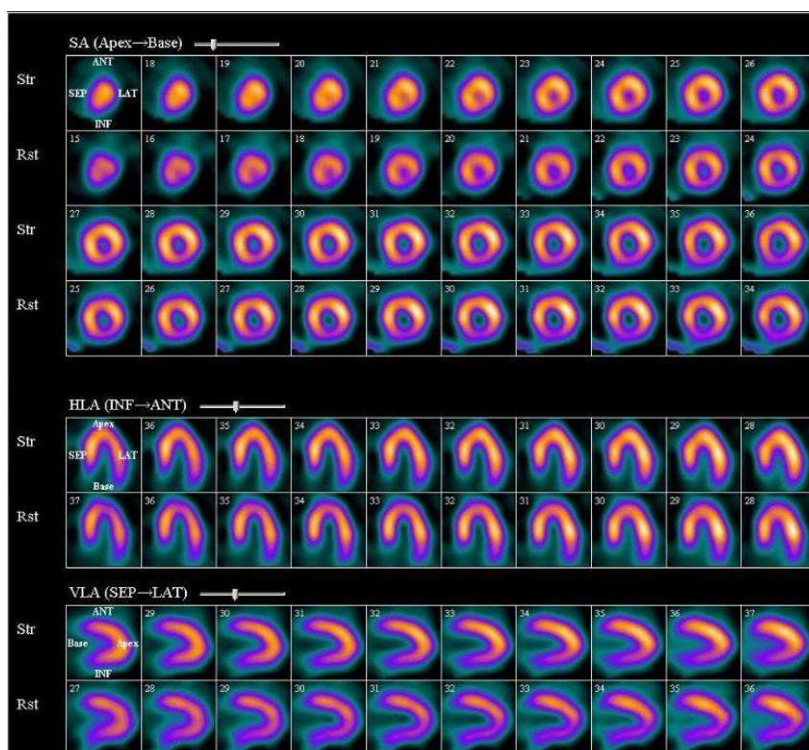


Color images are preferred, but submissions may also be submitted as gray scale images.



The entire LV is not included in the image below. A second page of slices may be necessary to show the entire LV. The gray scale image above correctly shows the entire LV.

The SPECT myocardial perfusion images must include stress and rest slices (from apex to base and wall-to-wall.) The image shown below is an incomplete submission and would require re-upload.

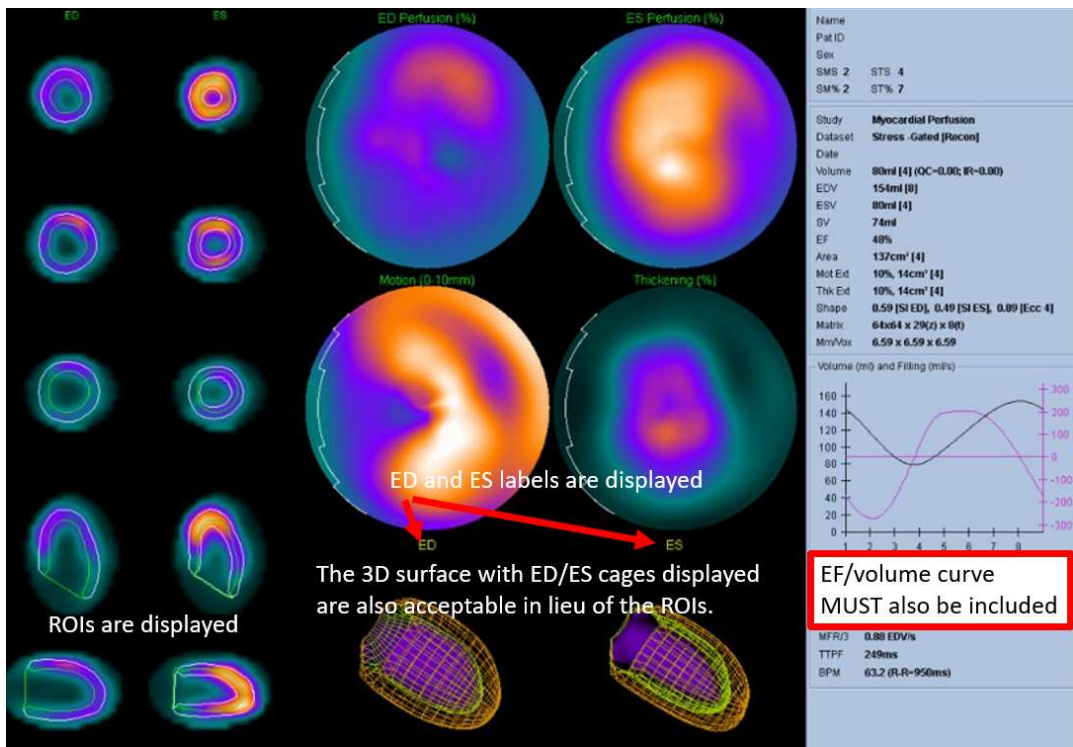
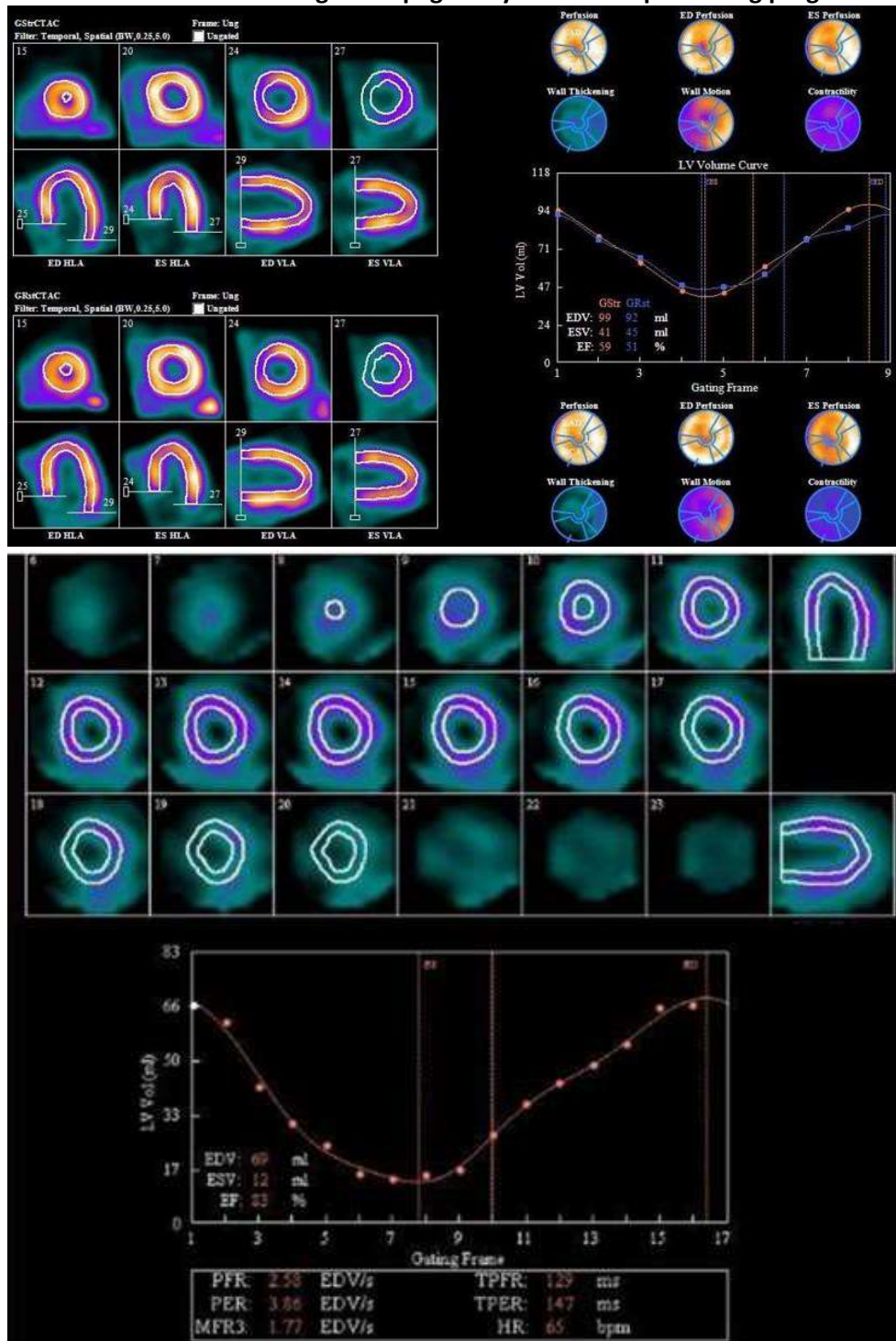


Older software may not allow laterality labels to be included on the slice splash page.

While the 3D surface rendered caged/bullet images may show laterality, they are usually not in the same orientation as the slices.

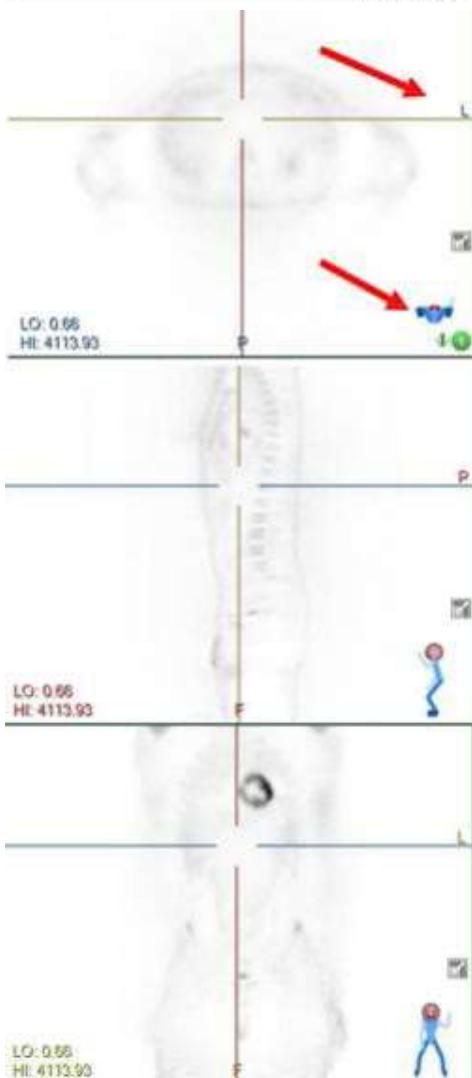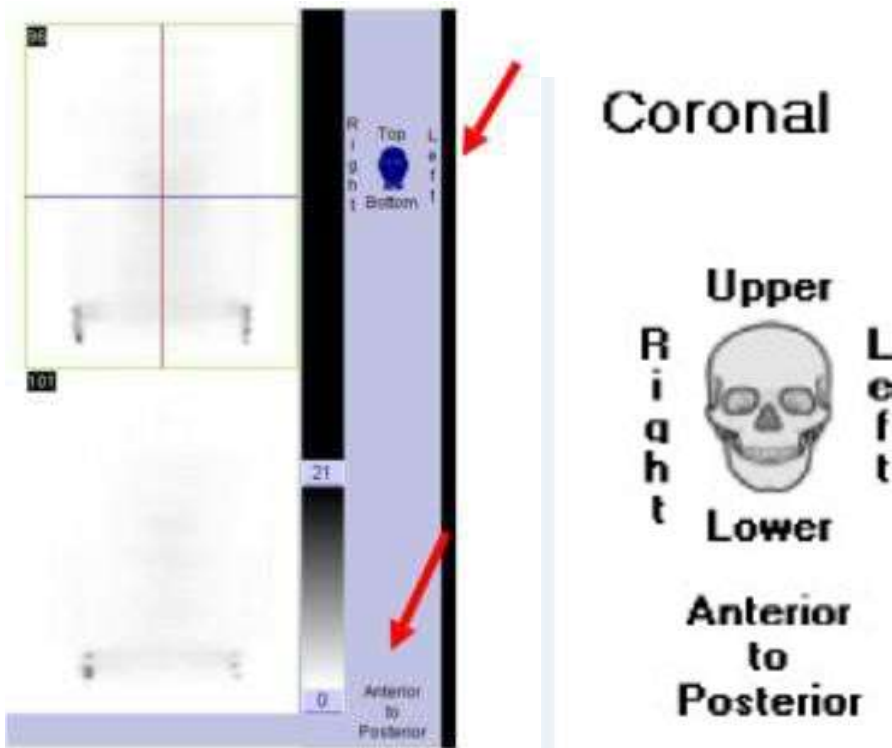
One of two things ***MUST be shown in order for exams to pass***. The 3D surface rendered/caged/bullet images are capable of showing orientation and ***MUST*** be oriented to match the orientation of the slices (usually apex at center, 12 and 3 o'clock) **OR** the slices must show wall laterality, i.e., septum, lateral, inferior, anterior, apex and base.

Below are examples of volume curve and ROI images. **Recommend contacting the vendor for assistance finding these pages in your cardiac processing programs.**

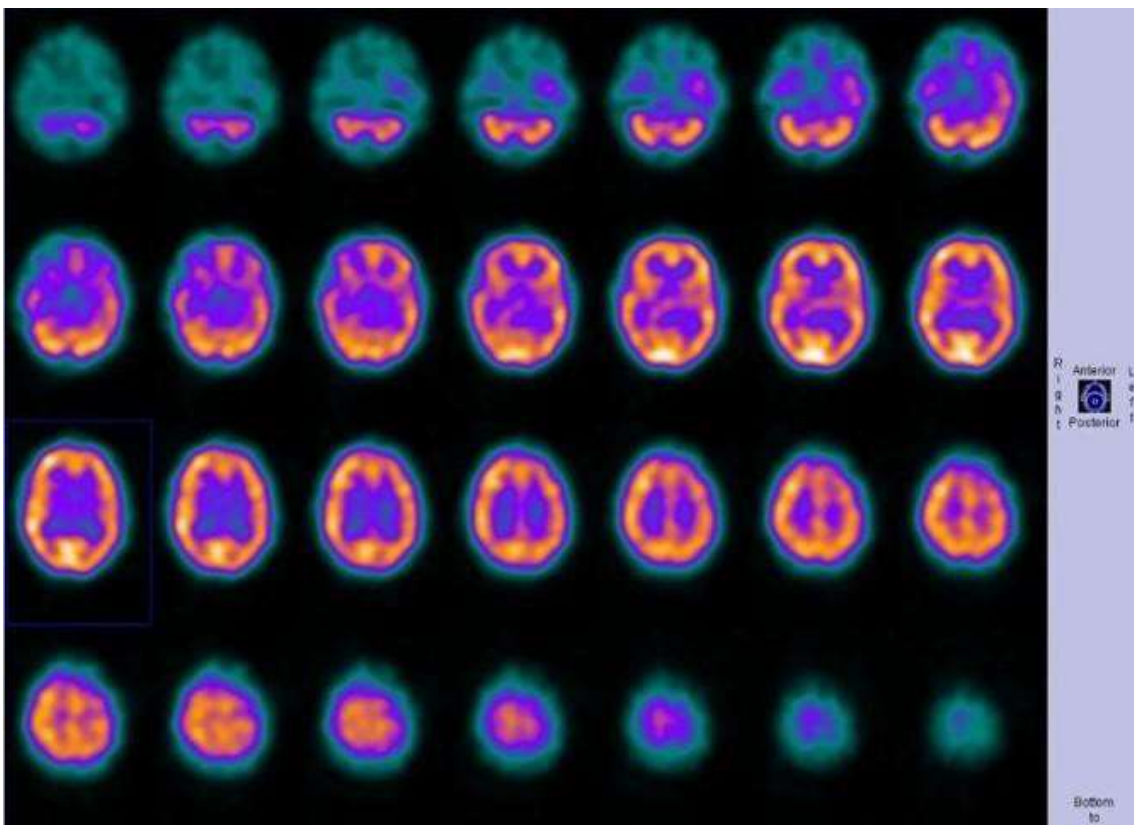
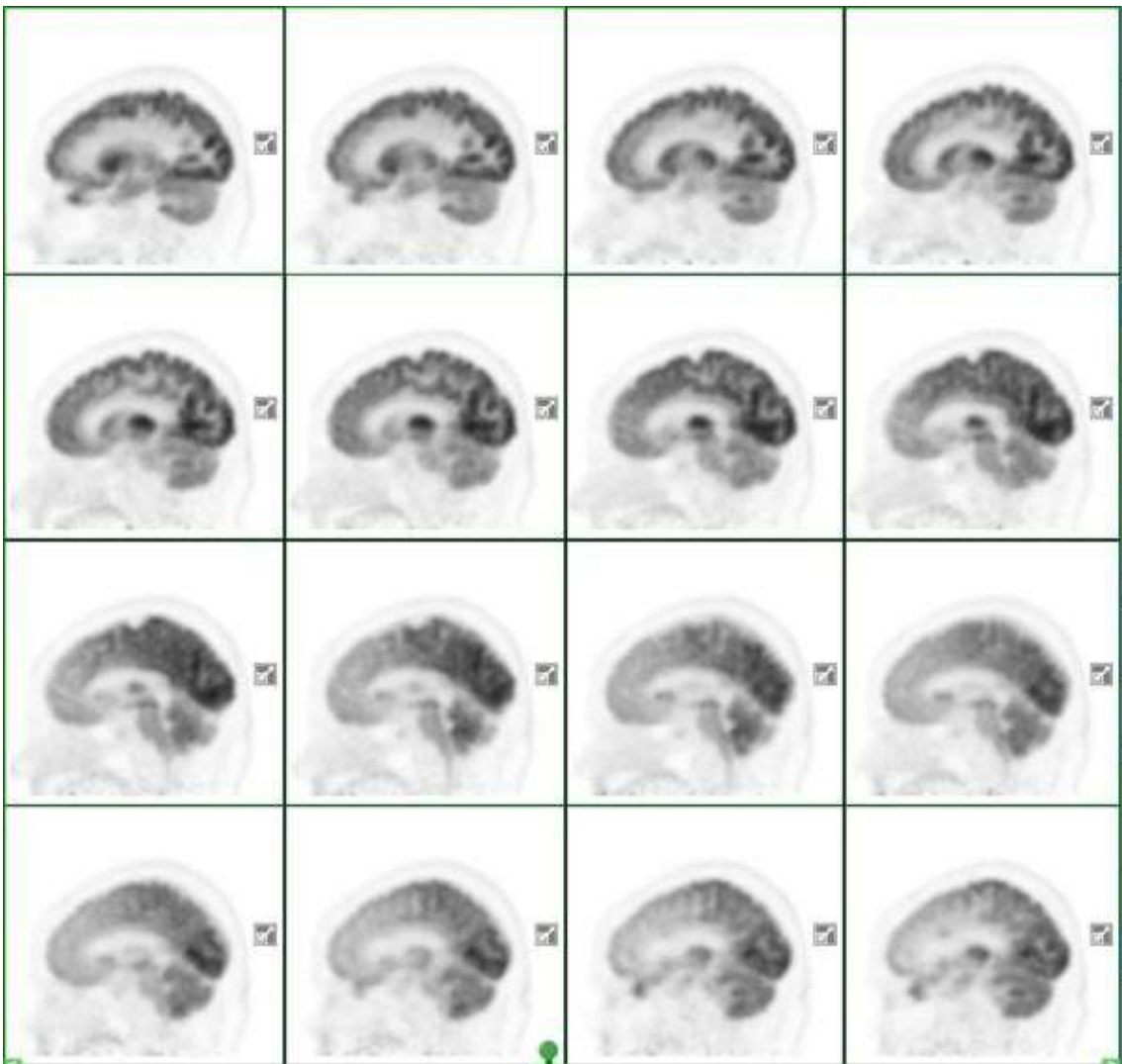


PET: ONCOLOGY AND BRAIN

Images MUST be labeled for laterality and orientation or show ICONS that indicate laterality and orientation (red arrows).



When submitting screen captures (see next page for DICOM upload), the images must show the entire body (AC & NAC eyes to thighs or head to feet) in the coronal plane and brain images must display axial, sagittal, and coronal planes. The sagittal screen capture shown below did not include the entire brain. If submitting screen caps, several pages may be required to show the entire body or brain. The axial image set is complete.

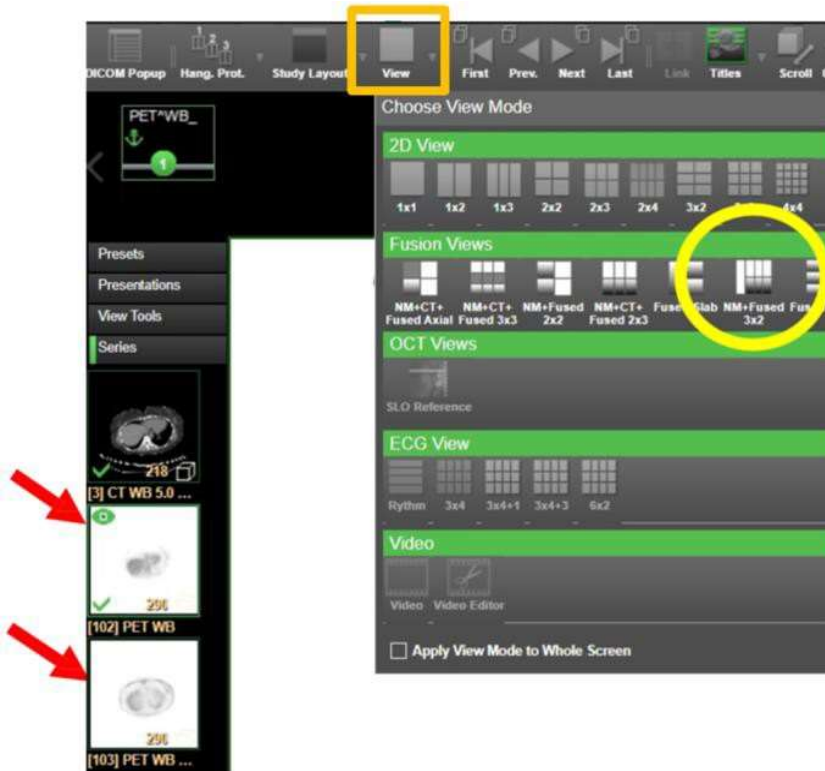

PET: ONCOLOGY

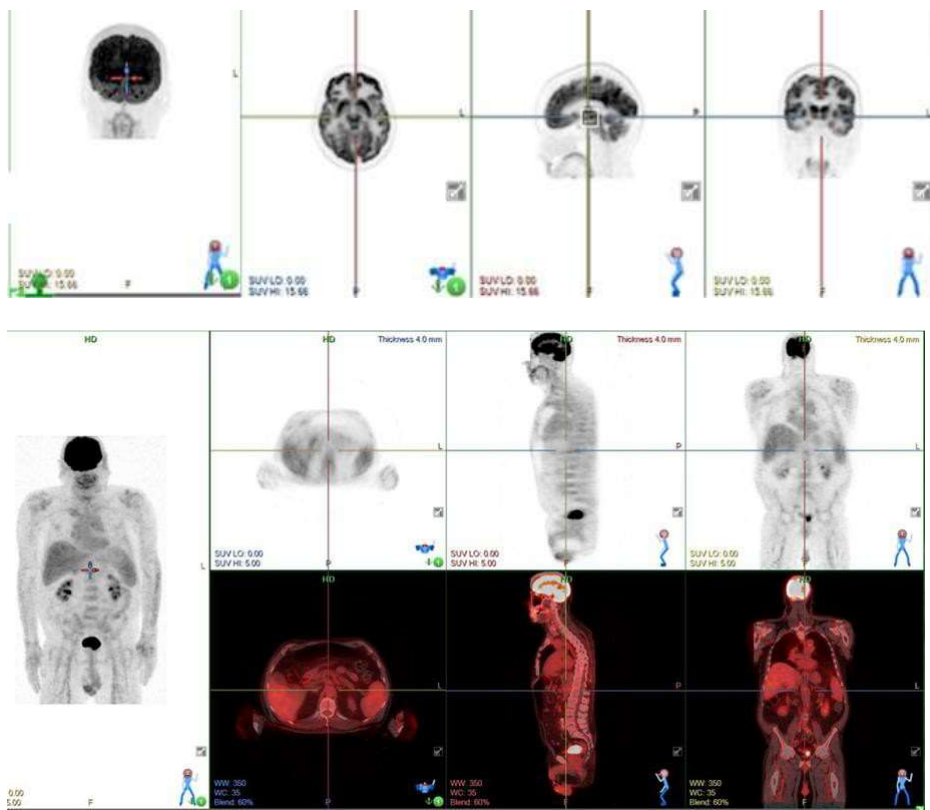
The PET testing instructions states for Oncology, “The whole body coronal images, with and without attenuation correction, must be submitted “and for Brain “Images must be displayed in multiple planes including transverse, coronal and sagittal””

Sites may now upload the axial only AC and NAC (NAC not required for Brain or Cardiac), but they **MUST** display in the coronal plane for Oncology and three planes for Brain using the NIL viewer tool. **This will not work if uploading NON-DICOM images.**

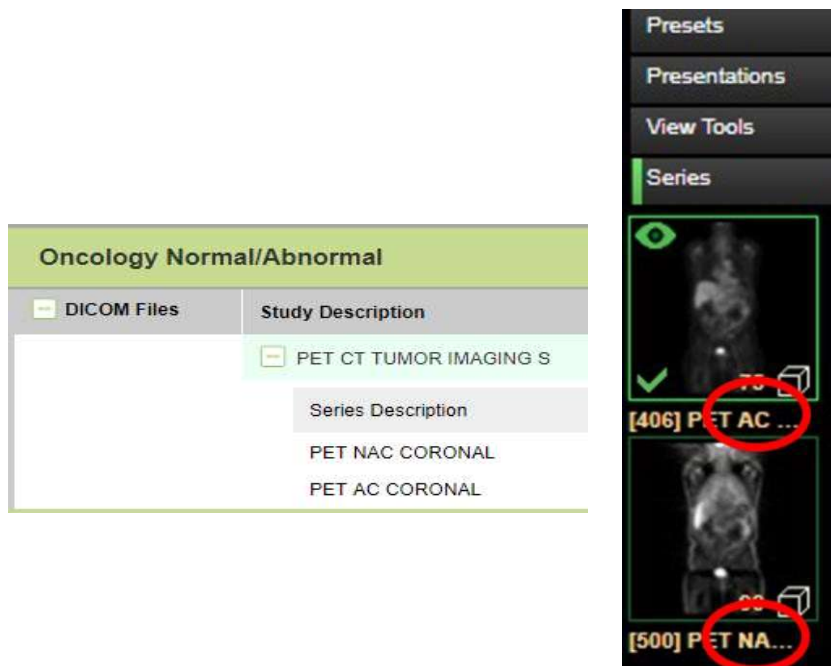
Once images are uploaded, review images and click on the AC or NAC axial image on the left (red arrows), click on the View tool (orange box) and select the NM+Fused 3x2 (yellow circle).



Images will display in all three planes. If CT is included, the images will show PET only and fused images.

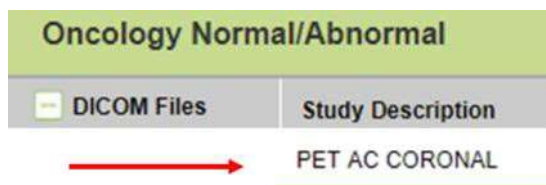


Exams should display as 2 files, usually labeled AC and NAC (image on the left). The NIL viewer will display 2 separate image sets if uploaded correctly (image on the right)



When uploading axial slices, review in the NIL viewer and scroll thru the slices for the attenuation corrected and non-attenuation corrected. **Ensure they are in order.** If they appear out of order or have AC and NAC mixed in the same files (interleaved), or are of varying intensity, **DO NOT SUBMIT.** It is a common occurrence if uploading jpg or NON-DICOM.

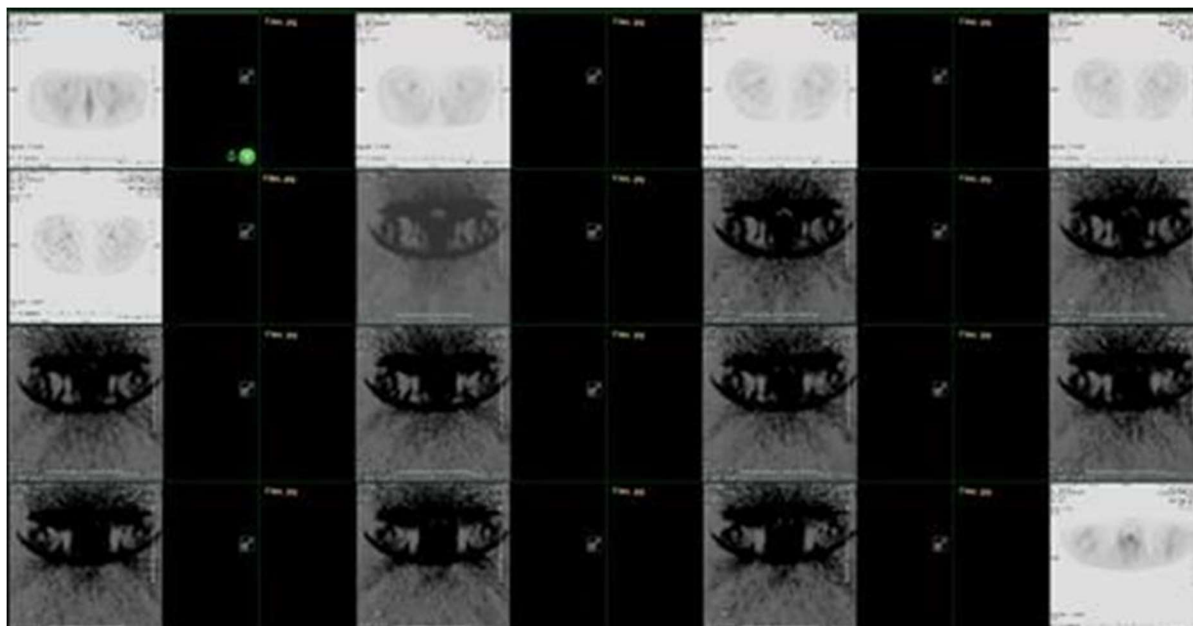
Non-DICMOM: The upload file will usually only show a single PET file, even though the AC and NAC were uploaded separately. Call the ACR for assistance BEFORE submitting the testing packet.



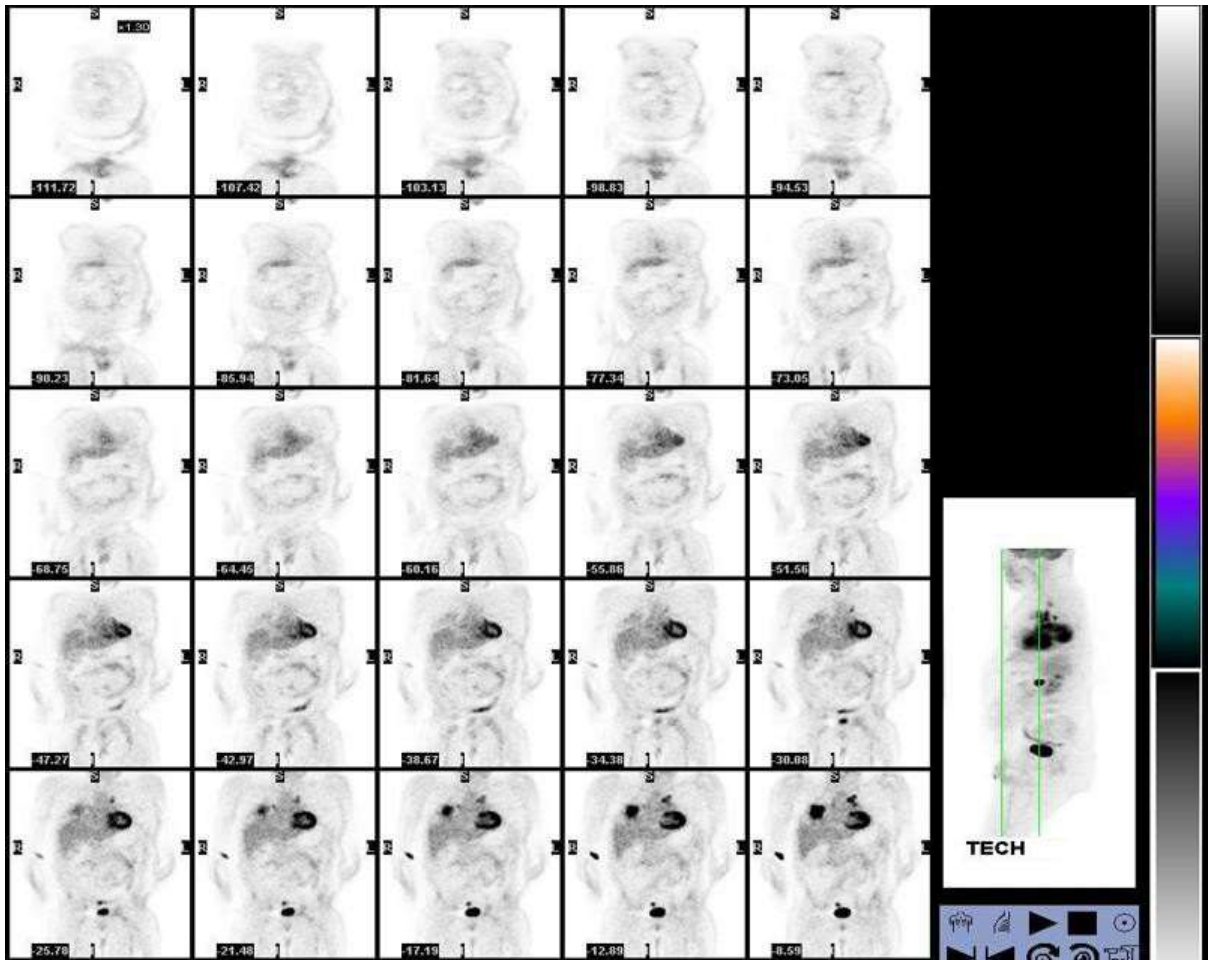
Only a single file is displayed under the exam.

An example of AC and NAC interleaved image set is seen below. Images 1-5 and 16 are AC images, and the rest are NAC. The images show varying intensity.

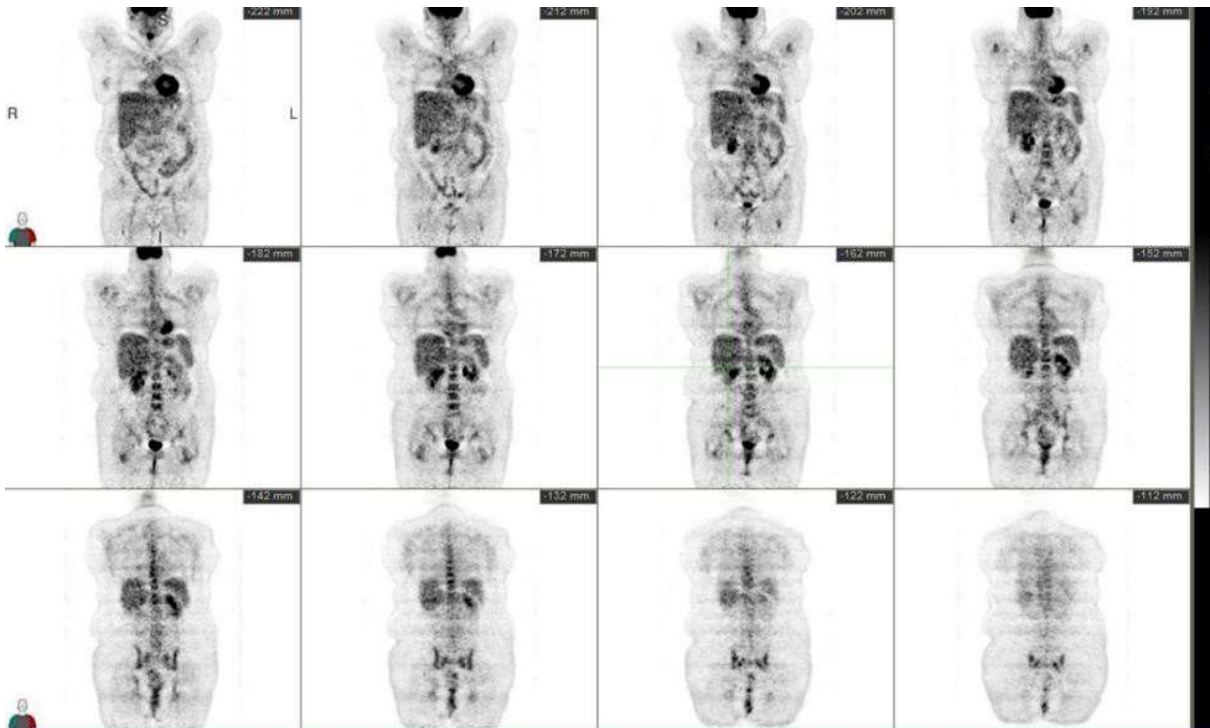
If this happens, call for assistance.



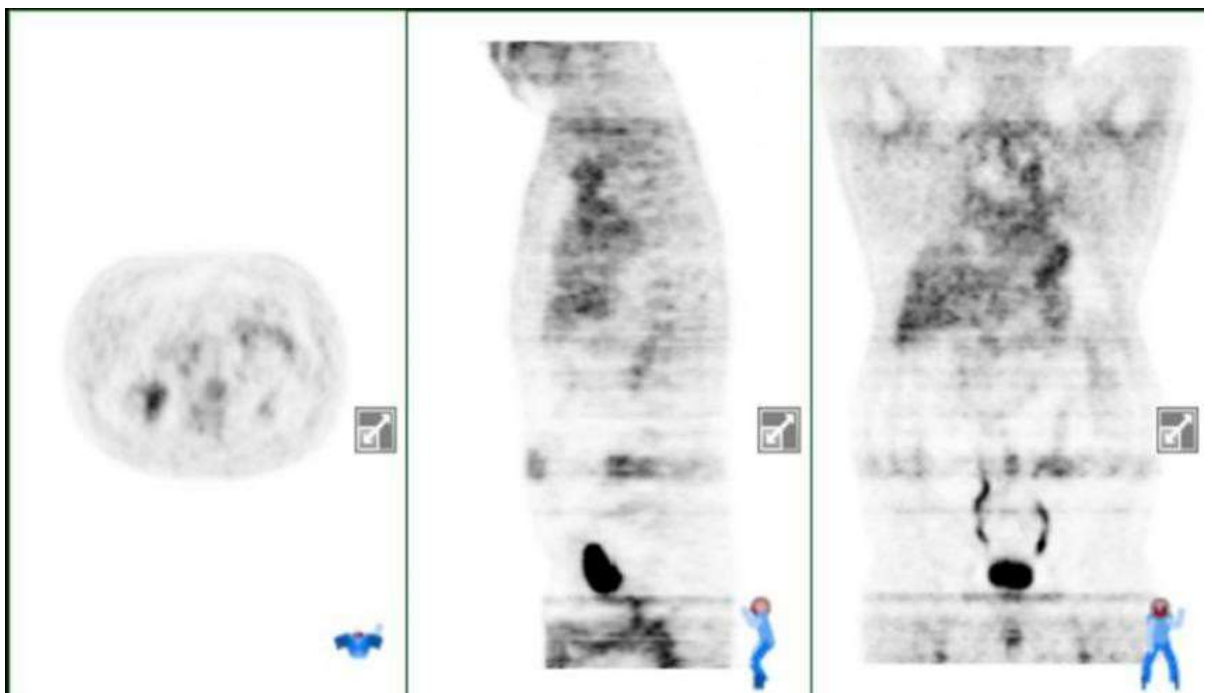
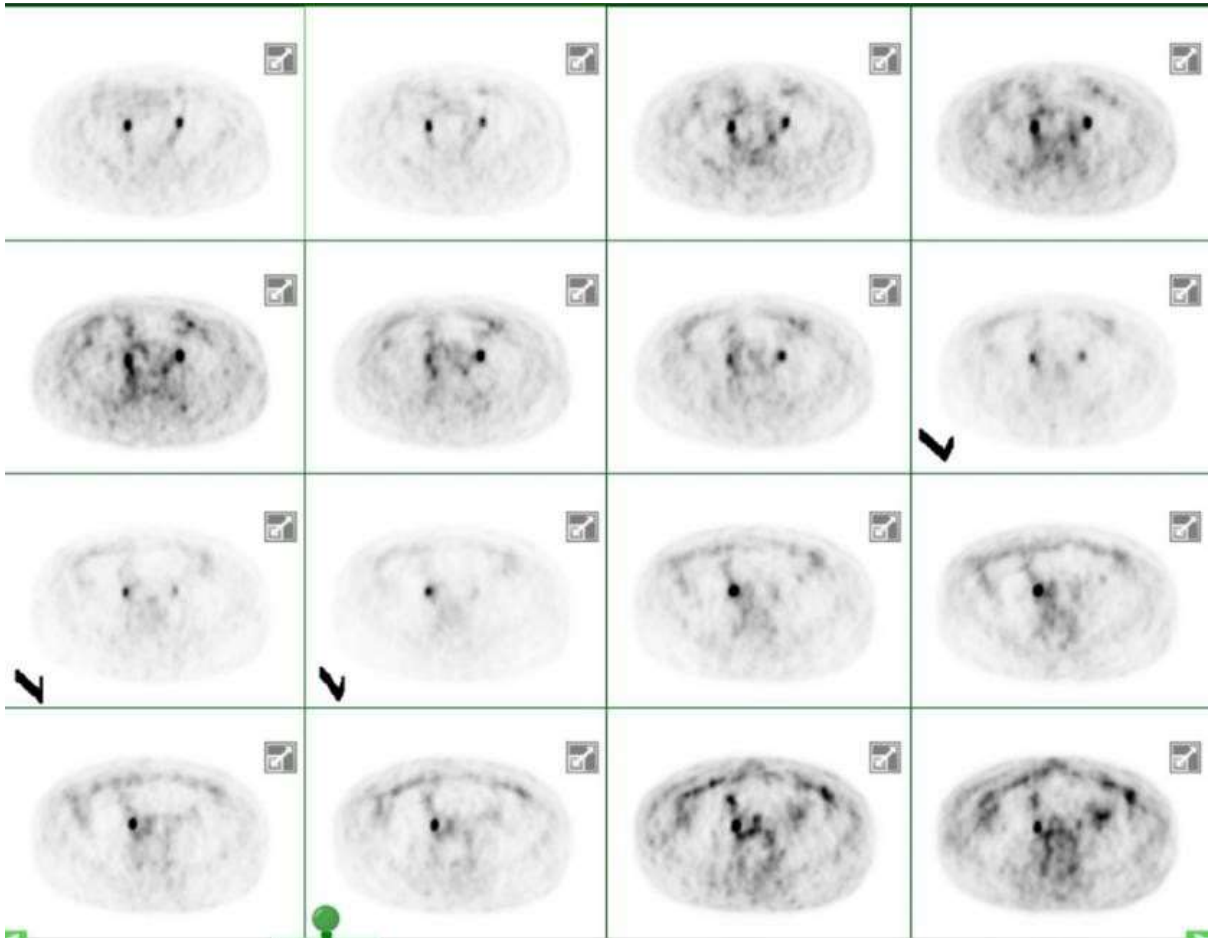
Ensure the entire volume is submitted. The MIP image shows the head was acquired, but not included in the submission. This was a screen capture and images were zoomed prior to saving the image.



Check for artifacts prior to submission. The vertical lines seen may be due to table overlap error.



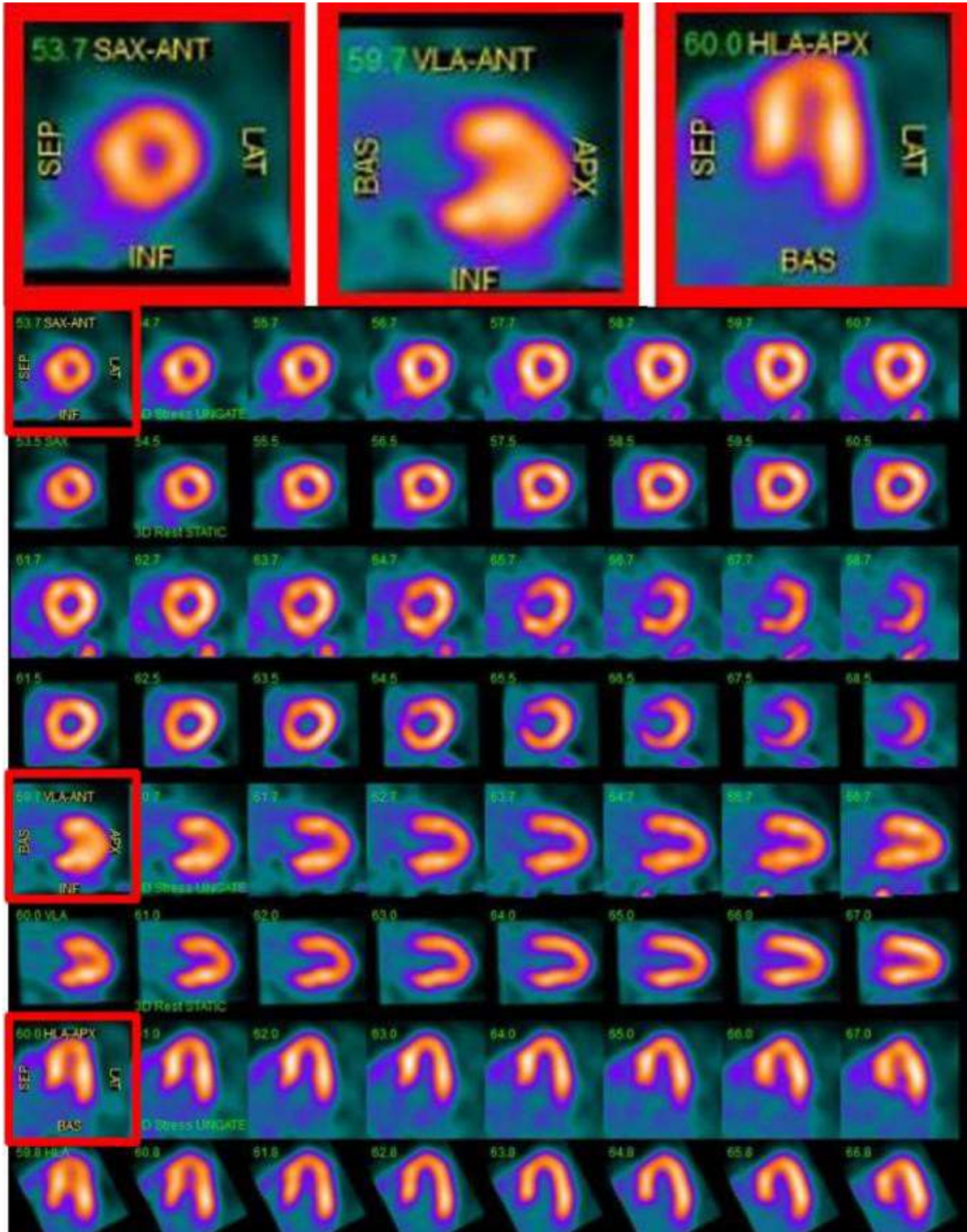
Since sites may now upload the axial only now, when reviewing prior to submission, make sure to use the NM + Fused 3x2 viewer to review the Coronal slices. Changes in intensity may not be obvious scrolling through the axial slices. This appears to be a normalization error and failed. The axial slices show subtle intensity variation which is much more evident in the 3 plane view.



PET: CARDIAC

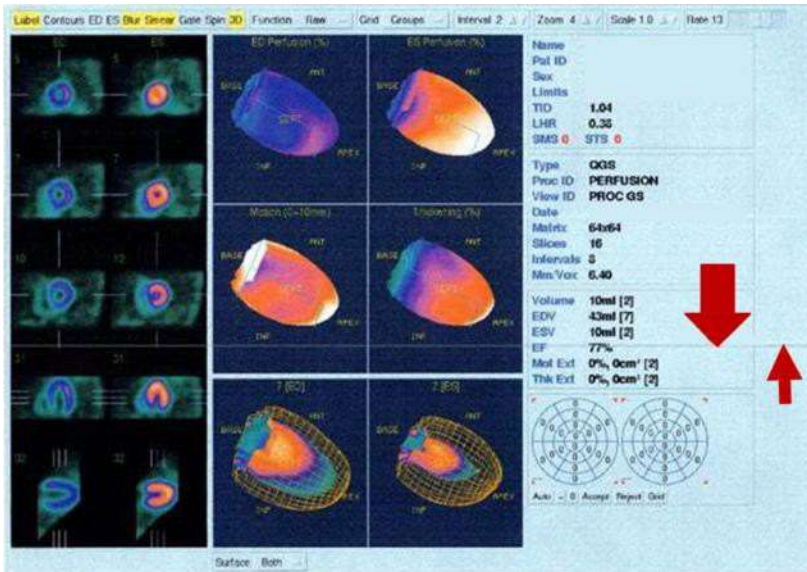
Ensure cardiac images are reoriented similar to NM cardiac images and that the images are labeled for Anterior, Inferior, Septal and Lateral. Please also label Stress and Rest and direction of slicing. ROI and EF volume curve images are not required – but if gated PET was performed, sites may also upload.

This submission was incomplete as the entire LV was not included.



COMMON ERRORS

Poor quality paper print that was scanned and submitted



These Images were displayed in color but saved as B&W. The edges are blurred and not crisp as would be displayed with gray scale images. These will be cleared for site to re-upload.

