

# Nursing Management of Fecal Diversions (Gastrointestinal Ostomies)

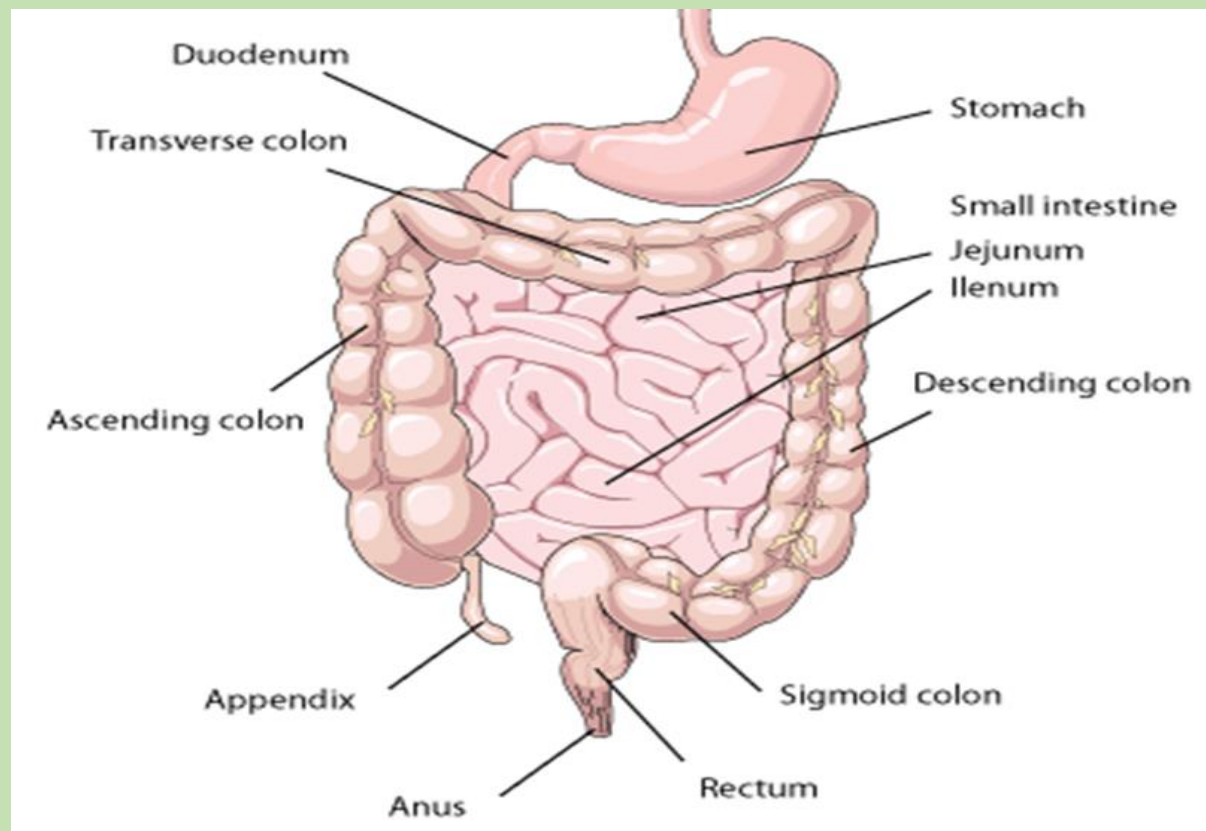
## Understanding different ostomies and management of

*Kechi Iheduru-Anderson DNP, RN, CNE, CWCN*

### Introduction

OSTOMY: A surgically created opening connecting an internal organ (usually the intestines) to the outside of the body, creating a stoma. Ostomies allows the expulsion of gastrointestinal waste from the body. Ostomies may be permanent or temporary depending on the reason for the surgery. Ostomy surgeries of the bowel include; ileostomy, colostomy, ileoanal reservoir, and continent ileostomy.

**Figure 1: The Small and Large intestine**



## Common sites for fecal diversions.

The following section discussed the types, reasons for fecal diversions, location, and type of effluent. Colostomy involve parts of the large intestine while an ileostomy involves part of the small intestine called the ileum.

**Ileostomy:** An ileostomy is a stoma created from a part of the ileum. An ileostomy may be permanent or temporary. An ileostomy is permanent when the surgeon removes or bypasses the entire colon, rectum, and anus.

**Colostomy:** A colostomy is a stoma created from a part of the colon. During this surgery the colon through the abdominal wall and makes a stoma.

**Ileoanal reservoir:** An ileoanal reservoir is an internal pouch made from the ileum. This surgery is a common alternative to an ileostomy and does not have a permanent stoma. Also known as a J-pouch or pelvic pouch, the ileoanal reservoir connects to the anus after a surgeon removes the colon and rectum. Stool collects in the ileoanal reservoir and then exits the body through the anus during a bowel movement. An ileoanal reservoir is an option after removal of the entire large intestine when the anus remains intact and disease-free. A temporary ileostomy is created before or at the time of creating an ileoanal reservoir. Once the ileoanal reservoir heals, the ileum is reconnected to the ileoanal pouch and the temporary ileostomy is closed.

People with an ileoanal reservoir initially have about six to 10 bowel movements a day. The newly formed ileoanal reservoir takes several months to stretch and adjust to its new function. After the adjustment period, bowel movements decrease to as few as four to six a day. People with an ileoanal reservoir may have mild fecal incontinence and may have to get up during periods of sleep to pass stool. A WOC nurse or an enterostomal therapist may recommend pelvic floor exercises to help strengthen the muscles around the anus.

## Type of fecal diversion

### 1. Ascending colostomy

- *Location:* Right abdomen    *Etiology:* Colon cancer, usually right-sided tumors  
Rarely done because ileostomy is preferable
- *Effluent type:* Stool in the ascending colon is liquid. Semiliquid to liquid; contains highly acidic digestive enzymes

Usually permanent, but depends on etiology, the rationale for ostomy creation, and the patient's general condition.

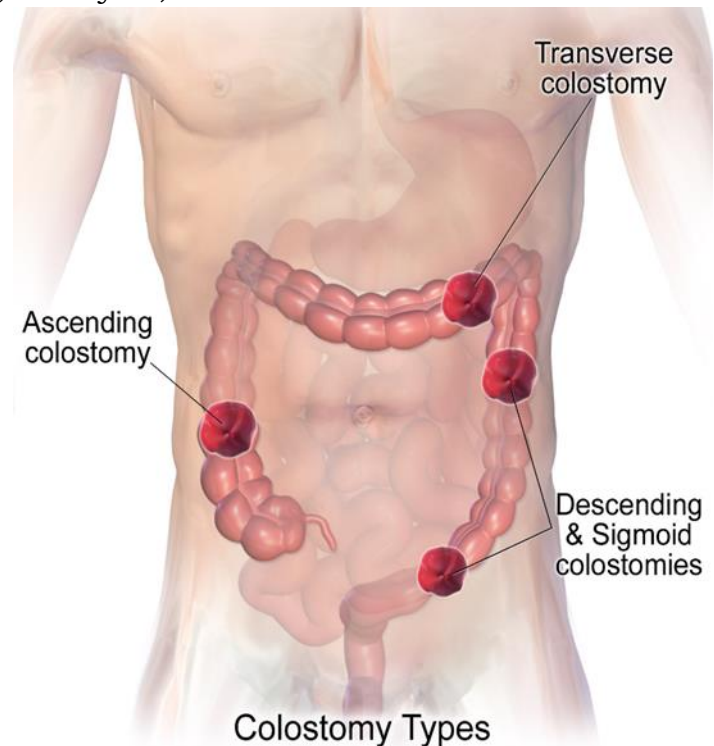
## 2. Transverse colostomy

- *Location:* Upper abdomen, middle or right side
- *Etiology:* Birth defects, Bowel obstruction, Cancer (descending or sigmoid colon), Diverticulitis, Paralysis, Trauma
- *Effluent type:* Semiformed; few digestive enzymes present; unpredictable  
Depends on etiology

## 3. Descending colostomy

- *Location:* Lower left abdomen
- *Etiology:* Cancer of the rectum or sigmoid colon, Bowel obstruction, congenital defects, Diverticulitis, Paralysis, Trauma
- *Effluent type:* Soft, semiformed to formed

Usually permanent but depends on etiology and the patient's clinical condition



## 4. Sigmoid colostomy

- *Location:* Lower left abdomen      Cancer of the rectum or sigmoid colon (most common)
- *Etiology:* Bowel obstruction, congenital defects, Paralysis, Trauma
- *Effluent type:* Soft to firm and formed

Usually permanent, but may be temporary in some cases of abdominal trauma and/or diverticulitis

## 5. Loop colostomy

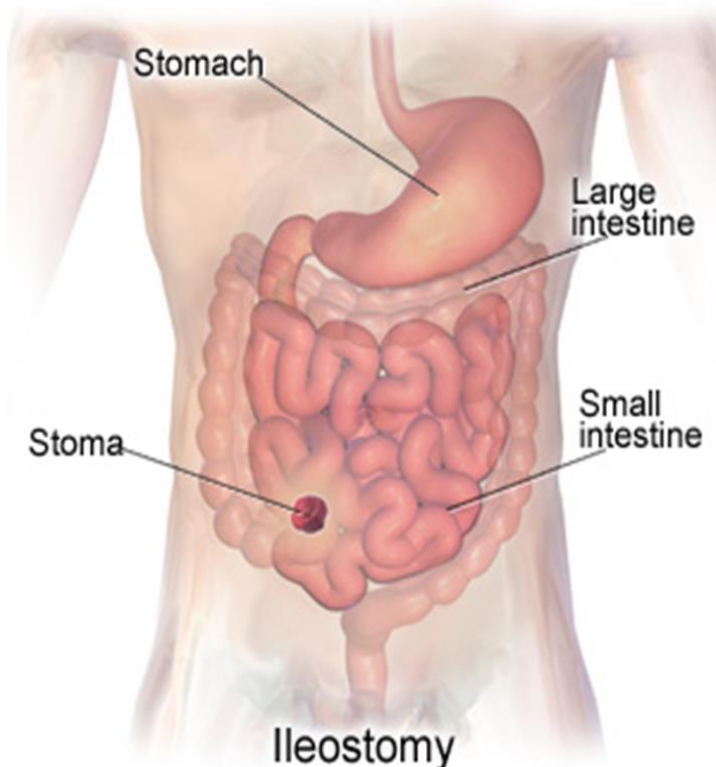
- *Location:* Usually in the transverse colon with proximal (effluent) and distal (mucus) stoma; upper abdomen, middle or right side; patient may pass mucus rectally
- *Etiology:* Trauma; More easily done in emergency situations
- *Effluent type:* Semiformed; few digestive enzymes present; mucus from the second stoma

Usually temporary, but depends on etiology and the patient's general health, clinical condition, and the rationale for stoma creation

## 6. Double-barrel colostomy

- *Location:* Proximal and distal stoma; distal is mucus fistula
- *Etiology:* Cancer of the rectum or sigmoid colon, Bowel obstruction, Diverticulitis, Trauma
- *Effluent type:* Semiformed; few digestive enzymes present; mucus from the second stoma

Usually temporary but depends on etiology, the patient's general health, clinical condition, and the rationale for stoma creation.



## 7. Ileostomy

- *Location:* Lower right abdomen is most common, but may also be placed in the lower left abdomen; dependent on surgical findings, abdominal condition such as scars, and surgeon's preference
- *Etiology:* Ulcerative colitis, Familial polyposis, Crohn disease
- *Effluent type:* Liquid; contains high number of digestive enzymes. May be permanent or temporary depending on etiology; may be used as a fecal diversion; if the patient is

being prepared for an ileoanal anastomosis, the ileostomy is temporary for several weeks before the second surgery to create the internal pouch

## 8. Ileoanal anastomosis (also known as J-pouch, pullthrough, or pelvic pouch)

- *Location:* Usually in the lower right abdomen; the patient must have an intact, disease free anus; the bowel is surgically attached to the anus and the patient doesn't wear an ostomy appliance
- *Etiology:* Ulcerative colitis, Familial polyposis
- *Effluent type:* Liquid to soft stool; high number of digestive enzymes; initially until the pouch is sufficiently stretched, the patient will have 8 to 10 stools/day; after the pouch is stretched, bowel movements may be reduced to 4 to 6/day

Usually permanent

9. **Continent ileostomy** (also known as Kock pouch or Barnett continent ileal reservoir)

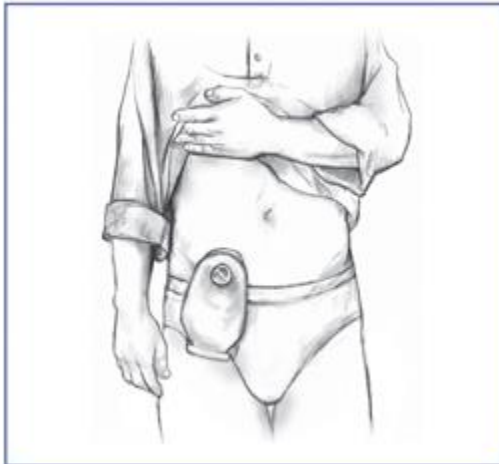- *Location:* An option when there's damage or disease in the rectum and/or anus
- *Etiology:* Bowel diversion surgeries: ileostomy, colostomy, ileoanal reservoir
- *Effluent type:* Liquid to paste-like; contains higher number of digestive enzymes than a colostomy

Usually permanent

**Preoperative care**

Preparation for fecal diversion surgery begins a few days prior to the procedure unless the surgery is being done on an emergency basis, such as for an injury or intestinal bleeding. Most patients have undergone a colonoscopy, sigmoidoscopy, or barium enema to diagnose the disease. The surgery for fecal diversion is usually performed in a hospital under general anesthesia. The surgeon and a wound, ostomy, and continence (WOC) nurse or an enterostomal therapist will work together with the patient to select the best location for the stoma. A removable external collection pouch (an ostomy pouch or ostomy appliance), is attached to the stoma and worn externally to collect intestinal contents or stool.

The preoperative nursing care is similar to that of other client



undergoing abdominal surgery under general anesthesia. The client will also need bowel cleansing prior to fecal diversion surgery. The colon contains bacteria and waste products that can cause infection if they leak into the abdomen during surgery. To reduce the risk of peritonitis oral antibiotics may be prescribed several days before the surgery, and the colon is emptied as much as possible using enema and laxatives. Generally 2 or 3 days prior to

surgery, a soft or semi-liquid diet is ordered. 24 hours before surgery clear liquid diet and nothing may be taken by mouth after midnight.

During bowel cleansing clients may develop severe diarrhea which can cause dehydration. Encourage client to drink plenty of clear liquid diet to prevent dehydration and electrolyte imbalance. IV fluid may be ordered. Blood thinner are usually placed on hold several days before the



surgery. The client must sign an informed consent acknowledging that the patient understands the procedure, the potential risks, and that they will receive certain medications. Therefore the nurse should ensure that the client has received and understood the necessary information prior to the surgery.

### **Post-op care**

Most patient return to the unit with IV and nasogastric tube. The intravenous remains in place until the colon has recovered sufficiently for food and fluid to be taken by mouth, and it is no longer needed to administer medication. The urinary catheter remains until bladder control returns usually within 24 hours following surgery or soon after. (The foley catheter should not be left in place for nurses' convenience.) Pain management via patient controlled analgesia or intermittent IV injections. Pain assessment and management is very critical for client's wellbeing and to prevent complications. Antibiotics may also be given postoperatively.

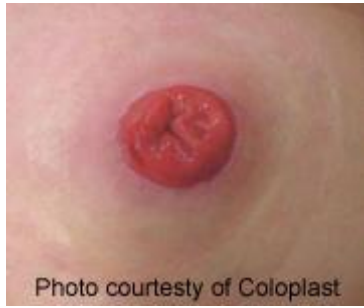Patient remains NPO until it is certain that normal colon function has resumed. This is determined by the return of bowel sounds (the passage of gas), indicating that normal movement inside the colon has returned. The passage of stool is another indication that the colon is healing. In some cases, in order to keep the stomach empty, gastric contents are aspirated through a nasogastric tube. If this is the case the nurse must monitor and record the content of NG tube. Nasogastric tube is removed after colon function returns. Patient is started on clear liquid diet, if clear liquids are tolerated, the diet is slowly advanced until the patient is eating solid foods.

Early ambulation is important soon after recovery from anesthesia. Physical activity stimulates bowel function and helps blood circulation return to normal. Patients who undergo a laparoscopic colon resection generally experience less postoperative pain and leave the hospital sooner than patient with open resection.

### **Healthy Stoma**

After an ostomy procedure, the stoma is shiny, wet, and red. It is usually round or oval, and gradually shrinks in size during the first few months. The color changes to pink similar to the inside of the mouth. The stoma does not have nerve endings; therefore, it does not transmit sensations (e.g., pain). It is rich in blood vessels and may bleed slightly if rubbed or irritated. If bleeding is prolonged, or if the discharge from the stoma contains blood, a physician should be notified. When inspecting a stoma the presence of the following indicates a healthy stoma:

The stoma may be round, oval, or irregular in shape



Stoma should be above the skin level;  
Pink-red in color (pallor (pale) may suggest anemia; dark hue may represent ischemia).

Moist like the inside of your mouth;  
May slightly bleed when rubbed;  
No painful to touch.

No separation between the

mucocutaneous edge and the skin.

No evidence of erythema, rash, ulceration or inflammation in the surrounding skin.

### **Assessment**

During initial assessment after creation of ileostomy, the abdomen should be soft and nontender, with an ileostomy on the lower right side. The stoma is red, and cloudy serosanguineous effluent is near the tail closure. During the early weeks and months after surgery, patients with an ileostomy or a colostomy may have excessive gas. This extra gas will decrease once the bowel has had time to heal and the person resumes a regular diet.

**Colostomy irrigation:** Colostomy irrigation to assist in regulating the effluent. Irrigation is performed by administering an enema through the colostomy using a colostomy irrigation set rather than an enema set.

**When to empty the pouch:** the pouch should be emptied whenever it is one-third to half full. Emptying the pouch helps prevent leaking from the weight of the effluent pulling the barrier away from the skin.

**When to change the pouch:** The best time to change a pouching system is first thing in the morning or 2 to 4 hours after meals, when the bowel is least active. After a few months, most patients can predict the time that's best for them. Leaking requires a complete change of equipment—down to the skin—because a leak can't be patched.

**Selecting a pouching system:** Selecting the appropriate pouching system depends upon the characteristics of the stoma, stoma location, presence of skin folds or defects, the ostomate's abilities, the type of ostomy, preference, and, at times, insurance reimbursement. When selecting a pouching system, choose one that delivers the best adhesive seal and skin protection for that

patient. Other considerations include the consistency of the fecal matter, availability and cost of supplies, amount of time the patient will wear the pouch, any known adhesive allergy, and the personal preferences of the patient. It is important that the pouch system fits correctly, so the stoma must be measured frequently, especially during the recovery period.

**Changing the ileostomy:** Changing the ileostomy appliance every 4 to 6 days and as necessary if leaking occurs. The nurse explains that the effluent is acidic and will cause a chemical burn due to digestive enzymes if it's allowed to remain on the skin. Ileostomy can be high output up to 2 liters per day, so emptying the appliance up to 8 to 10 times/day is critical to keeping his peristomal skin intact. Carefully cleaning and drying the skin with soap that is residue free, every time the pouch system is changed, is the best way to prevent skin irritation. Moisturizing soaps leave a residue that can interfere with the adhesion of the skin barrier of the pouch system. It is important that the pouch system is the correct size and the stoma should be measured every time supplies are purchased and whenever the patient's weight fluctuates.

- When removing the old barrier/wafer, support the skin with one hand while gently pulling off the wafer.
- Wipe away any mucus on the stoma (It is a good idea to moisten the barrier with water or a stoma adhesive remover.)
- clean the skin around the stoma with warm water and a washcloth
- rinse the skin thoroughly
- pat dry the skin completely
- Inspect the stoma for signs of skin irritation and any abnormality such as dramatic changes in stoma size, shape, or color (Contact the HCP if noted.)

**Patient education after ileostomy and colostomy:** Important education includes;

- Drinking enough fluid daily to replace ileostomy losses, chewing all food thoroughly, and eating foods that thicken the effluent such as pasta or potatoes without fat-filled sauces. Medication may be prescribed to thicken effluent.
- Outputs consistently above average levels may put patients at risk for dehydration; a sudden drop in output associated with abdominal pain may indicate constipation or blockage.
- With an ostomy, patient can shower or bathe just as you did before. Soap and water will not flow into the stoma or hurt it in any way. Patient may shower or bathe with the pouch on or off.
- Ostomy pouch is odor proof, so the only time the client will notice an odor is when you empty the pouch.



- Patient can resume activity as tolerated once healing from surgery is complete.
- Foods high in sugar, salt or fat should be avoided, because they can increase ostomy output.
- Good hand washing is very important while caring for the ostomy.
- Patient may hear noise coming from the ileostomy/colostomy during digestion. Usually the noise is barely heard by anyone else. Eating slowly and eating small meals throughout the day may decrease the digestive sounds.
- Instruct client to have extra supplies and possibly a change of clothes in case of a leak.
- Patients must avoid strenuous exertion and heavy lifting for 4 to 6 weeks.

### **Nutrition after fecal diversion surgeries**

Eating well balanced diet is critical to promote healing and wellbeing. Instruct client to

- Start on a low-fiber, low-residue diet and then advance to a regular diet.
- Add new foods one at a time to see the effect they have on ostomy management.
- Chew food thoroughly and eating 3 or more small meals daily may be helpful.
- Limit or avoid gas forming food such as beer, carbonated beverages, broccoli, cabbage, beans, onions, Brussels sprouts, cucumbers. Chewing gum, smoking, drinking from a straw, or sucking on candy can increase gas from swallowing air.
- Foods that can cause an odor: Fish, eggs, garlic, beans, turnips, cheese, cabbage.
- Foods that thicken stool: Pudding, creamy peanut butter, baked apples/applesauce, pasta, rice, cheese, bread, potatoes.
- Foods that can cause blockage if not chewed well: Nuts, celery, coconut, mushrooms, raw crunchy vegetables, dried fruits, popcorn.
- High-fiber foods that can decrease constipation and keep stools soft: Beans (brown, black, kidney, pinto, lentils, lima, soybeans), avocados, fiber-rich cereal, oats, brown rice, turnip greens, wheat pasta, fruit (raspberries, grapefruit, pears, papaya, apples with skin), potatoes with skin, sweet potatoes, yams.

**Table 1: Complications of fecal diversion surgeries**

Local skin irritation from the stoma or from the stoma appliance.	<p>The skin surrounding the stoma (peristomal skin) must be protected from irritating discharge. Discharge that is rich in digestive enzymes, such as from an ileostomy or an ascending colostomy, is particularly irritating to peristomal skin. Skin irritation is the most common complication for people with an ostomy. If the external ostomy pouch does not fit properly, stool or stool contents can leak out around the stoma and under the pouch. This causes itchy, red, and uncomfortable.</p> <ul style="list-style-type: none"> <li>• Ostomy barrier powder on the skin around the stoma to treat skin irritation.</li> <li>• For ileoanal reservoir surgery skin irritation occurs around the anus, a barrier ointment can be used to protect the skin around the anus can help treat and prevent irritation.</li> </ul>
Diarrhea	<p>Diarrhea is the passage of loose stools three or more times a day. This can lead to dehydration, malnutrition, and weight loss. Diarrhea is common and normal in ileostomy and ileoanal reservoir.</p> <ul style="list-style-type: none"> <li>• In most cases the only treatment necessary is replacing lost fluids and electrolytes to prevent dehydration.</li> <li>• Patients should maintain good daily hydration by drinking plenty of water and liquids, such as fruit juices, sports drinks, caffeine-free soft drinks, and broths.</li> <li>• Antidiarrheal meds may be ordered.</li> </ul>
Dehydration and electrolyte imbalance	<p>The main function of the large intestine is to absorb water, nutrients, and electrolytes from partially digested food that enters from the ileum. When the large intestine is removed, absorption of electrolytes does not occur to the same extent, making electrolyte imbalance more likely. Diarrhea, excessive sweating, and vomiting can increase the chance of developing electrolyte imbalance. Symptoms of electrolyte imbalance may include</p> <ul style="list-style-type: none"> <li>• fatigue, or feeling tired</li> <li>• weakness</li> <li>• nausea</li> <li>• muscle problems such as spasms, weakness, uncontrolled twitching, and cramps</li> <li>• dizziness and confusion</li> </ul> <p>Advice clients to report seek medical help and report these symptoms to their HCP.</p>

Intestinal obstruction or bowel blockage	If the stoma has not passed intestinal content or stool for 4 to 6 hours and the client is experiencing cramping or nausea, the ileum or colon may be blocked.
Stoma Problems Stoma problems include the following: <ul style="list-style-type: none"> <li>• Hernia</li> <li>• Stoma prolapse</li> <li>• Narrowing of the stoma (Stomal stricture)</li> </ul>	<ul style="list-style-type: none"> <li>• A stoma hernia, seen as a bulge in the skin around the stoma, is a weakening of the abdominal wall around the stoma site. As with all hernias, a stoma hernia continues to increase in size and may eventually need surgical repair when it becomes too large. May cause bowel obstruction or strangulation requiring surgical repair.</li> <li>• A stoma prolapse occurs when the bowel pushes itself through the stoma. May cause bowel obstruction or strangulation.</li> <li>• Narrowing of the stoma makes it difficult for stool to pass through the stoma. A narrowed stoma may need surgical repair.</li> </ul>
Bleeding	Ostomy surgery may cause internal bleeding. Bleeding may also occur through the stoma or through the anus after surgery. Monitor the client for signs of hemorrhage.
Infection	Intestinal microbes can leak into the abdominal cavity during ostomy surgery. Symptoms of infection may include <ul style="list-style-type: none"> <li>• fever</li> <li>• back pain</li> <li>• poor appetite</li> <li>• nausea and vomiting</li> </ul>
Irritation of the Internal Pouch, or Pouchitis	Pouchitis is an irritation or inflammation of the lining of an ileoanal reservoir or a continent ileostomy pouch. Usually treated with antibiotics. Severe or chronic Pouchitis may be treated with corticosteroids. Symptoms of pouchitis include <ul style="list-style-type: none"> <li>• frequent bowel movements with diarrhea</li> <li>• an urgent need to have a bowel movement</li> <li>• a feeling of pressure in the pouch</li> <li>• abdominal pain</li> <li>• cramping or bleeding</li> <li>• dehydration</li> <li>• low-grade fever</li> <li>• a general unwell feeling</li> </ul>
Vitamin B12 Deficiency	Ostomy surgery of the bowel may affect vitamin B12 absorption from food and result in a gradual drop in vitamin B12 levels in the body leading to anemia.
Phantom Rectum	Phantom rectum is the feeling of needing to have a bowel movement even though the rectum is not present.

	<p>Phantom rectum is relatively common. Symptoms are usually mild and often go away without treatment. However, for some people, phantom rectum may occur for years after a surgeon removes the rectum. Some people with phantom rectum may feel pain. Health care providers treat rectal pain with medications such as pain relievers and sometimes antidepressants. To help control phantom rectum, a health care provider may recommend complementary therapies such as guided imagery and other relaxation techniques.</p>
Short Bowel Syndrome	<p>Short bowel syndrome is a group of problems related to inadequate absorption of nutrients after removal of part of the small intestine. People with short bowel syndrome cannot absorb enough water, vitamins, and other nutrients from food to sustain life. Diarrhea is the main symptom of short bowel syndrome. Other symptoms may include</p> <ul style="list-style-type: none"> <li>• cramping</li> <li>• bloating</li> <li>• heartburn</li> <li>• weakness and fatigue</li> <li>• vomiting</li> <li>• excessive gas</li> <li>• foul-smelling stool</li> </ul> <p>Treatment for short bowel syndrome based on a person's nutritional needs. Treatment may include nutritional support, medications, and surgery.</p>
Rectal Discharge	<p>People with an ileostomy or a colostomy whose lower colon, rectum, and anus are still present may experience a discharge of mucus from their rectum. Instruct patient to use peripad to absorb the mucus. Good perineal hygiene is important.</p>

Advise patient to seek immediate medical care if they experience the following;

- continuous nausea and vomiting
- dramatic change in stoma size, shape, or color
- continuous bleeding at the junction between the stoma and the skin that does not stop by applying pressure
- obstruction, prolapse, or narrowing of the stoma
- a deep cut in the stoma
- no output of intestinal content or stool from the stoma for 4 to 6 hours, with cramping and nausea

- severe diarrhea with risk of dehydration
- excessive bleeding from the stoma opening

### **Ostomy Support**

Because ostomy surgery affects many aspects of life, ostomates may have personal and social concerns. Patients are often unsure about informing casual friends, acquaintances, and co-workers about their surgery. Concerns about intimacy and sexual relationships are also common. Enterostomal therapists and WOC nurses are valuable resources for all concerns following an ostomy. They can often recommend support groups for ostomates.

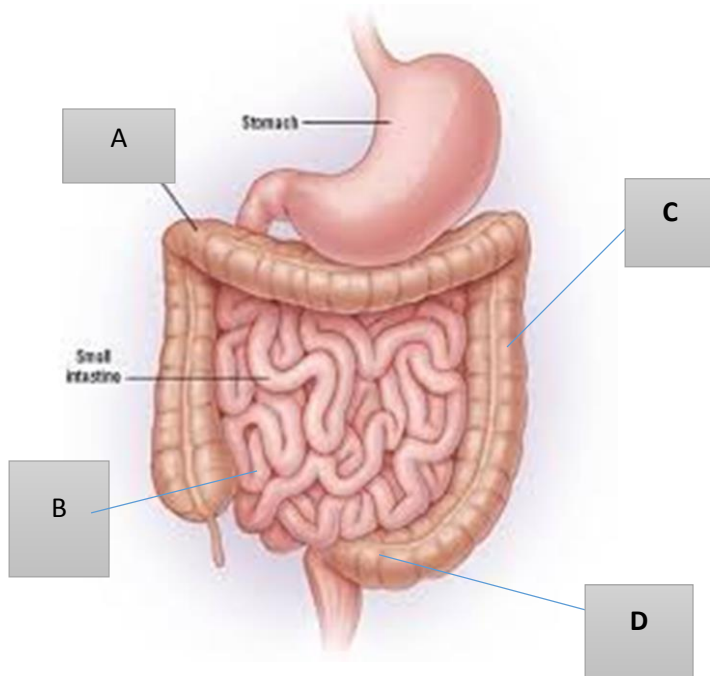
## Selected references

1. National Institute of Diabetes and Digestive and Kidney Diseases (NIDDK). (2014). Ostomy Surgery of the Bowel. Retrieved January 24, 2016 from <http://www.niddk.nih.gov/health-information/health-topics/digestive-diseases/ostomy-surgery-bowel/Pages/ez.aspx>
2. Scemons, D. (2013). The ins and outs of ostomy management. *Nursing made Incredibly Easy*, 11(5), 32–41. doi: 10.1097/01.NME.0000432867.93012.55. Retrieved January 24, 2016 from [http://journals.lww.com/nursingmadeincrediblyeasy/Fulltext/2013/09000/The\\_ins\\_and\\_outs\\_of\\_ostomy\\_management.6.aspx](http://journals.lww.com/nursingmadeincrediblyeasy/Fulltext/2013/09000/The_ins_and_outs_of_ostomy_management.6.aspx)
3. American College of Surgeons. (nd). Home Management and Other Resources. Retrieved January 24, 2016 from <https://www.facs.org/~media/files/education/patient%20ed/home%20management.ashx>
4. Lehrer, J. K. (2014). Ileostomy - changing your pouch. Retrieved January 24, 2016 from <https://www.nlm.nih.gov/medlineplus/ency/patientinstructions/000072.htm>
5. Swierzewski, S. J. (2015). Gastrointestinal Surgery Procedures: Colon Resection Preoperative Procedures. Retrieved January 24, 2016 from <http://www.healthcommunities.com/gastrointestinal-surgery/postoperative-care-colon-colon-resection.shtml>
6. Dorman, C. (2009). Ostomy basics: A nurse's introduction to care, counseling, and equipment. Retrieved January 24, 2016 from <http://www.modernmedicine.com/modern-medicine/news/modernmedicine/modern-medicine-feature-articles/ostomy-basics-nurses-introducti?page=full>



## NCLEX style questions

1. The nurse is teaching the adult child of a client who had a colostomy and is being discharged to the adult child's home. Which of the following statements by the adult child would indicate a correct understanding of the teaching regarding changing colostomy pouch? Select all that apply.
  - a. I should change the pouch right away if she has itching or leakage around the stoma.
  - b. We may need to change the pouch more often if she has been sweating more than usual from hot weather or exercise.
  - c. I can wash the stoma and the skin around it with perfumed soap to decrease odor.
  - d. Leave 2 cm area between the stoma and the pouch opening to prevent pressure on the stoma.
  - e. I can use skin barrier powder or paste around the stoma to help seal it better.
  
2. The nurse completed discharge teaching for a client going home after a new descending colostomy. Which statement by the client regarding when to empty pouch indicates accurate understanding of the instruction?
  - a. "I will empty the pouch when it is totally filled."
  - b. "I will empty the pouch when it is one-third to half full."
  - c. "I will empty the pouch once a day."
  - d. "I will empty the pouch every 3 to 5 days."
  
3. A client has continuous liquid output from his ostomy. Identify the area where the nurse would expect this type of ostomy to be located?

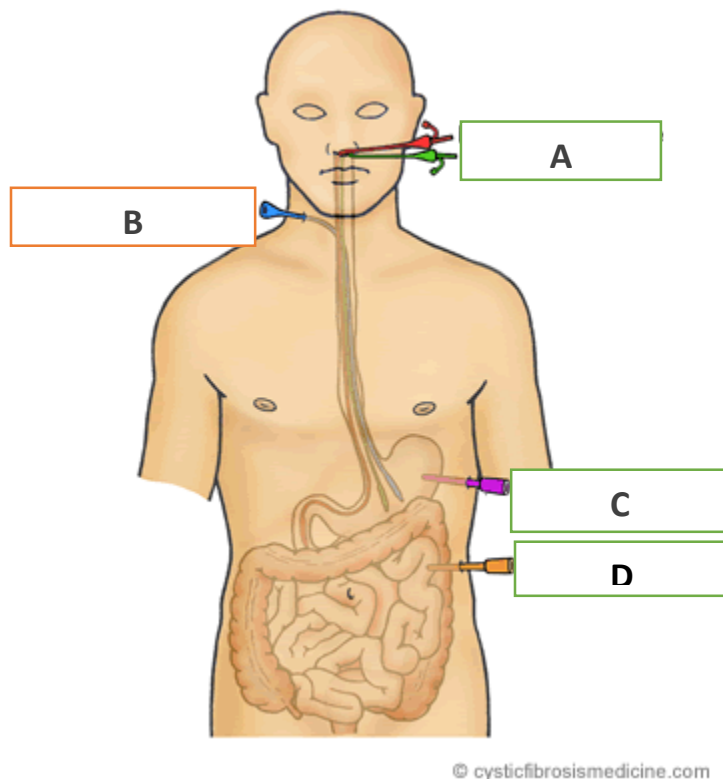


- a. A
- b. B
- c. C
- d. D

4. After a transverse loop colostomy, the nurse inspects the patient's stoma. The stoma appears mostly pink with some dusky discoloration at the lower border. An appropriate action would be to:
  - a. clean the area around the stoma and record the observation in the nurses' notes.
  - b. carefully place a clean pouch over the stoma to prevent any further tissue loss.
  - c. cover the stoma with a petroleum gauze dressing to prevent any further irritation to the stoma.
  - d. clean the area around the stoma, apply a clean pouch, and notify the physician about the discoloration.
  
5. The nurse instruction in surgical unit is discussing fecal diversion surgery with the student nurses. Which statement by one of the students indicate a correct understanding of the teaching?

- a. "Ileostomy is the surgical creation of an opening into the ileum, with a stoma on the abdominal wall."
  - b. "Ileostomy is the surgical creation of an opening into the jejunum, with a stoma on the abdominal wall."
  - c. Ileostomy is a fecal diversion with semiformal liquid stool draining to the outside of the body."
  - d. "An ileostomy is a temporary bowel diversion created from a part of the colon."
6. The nurse is caring for a client scheduled for bowel resection with the plans to create an ileoanal reservoir. Which of these statements by the patient requires further teaching by the nurse?
- a. "I understand I have to eat clear liquid diet the day before surgery."
  - b. "I cannot have anything to eat or drink the night before the surgery."
  - c. "I have to meet with the ostomy nurse to choose the ostomy appliance that will work better for me."
  - d. "I will have to work with the ostomy nurse after surgery to learn how to better control my bowel."
7. Five days after bowel resection and creation of sigmoid colostomy for colon cancer, a client is not passing flatus and has hypoactive bowel sounds. Which interventions should the nurse include in the client's plan of care? Select all that apply.
- a. Administer bisacodyl (Ducolax) suppository as ordered.
  - b. Encourage the client to expel flatus.
  - c. Increase opioid medication to achieve effective pain control.
  - d. Promote frequent ambulation.
  - e. Encourage eating a regular diet.
8. The nurse should include which of the following in a skin care regimen of a client admitted to the long-term care facility with an ileostomy.
- a. Change the pouch every shift to limit odor.

- b. Hold your hand over the pouch and barrier for about 30 seconds after it is placed to help seal it better.
  - c. Use tapes around the pouch if the stoma is at or below the level of the skin, to help seal it better.
  - d. Use lotion soap to cleanse the skin around the stoma to moisturize the skin.
9. The nurse is to initiate tube feeding for a client who has gastrostomy tube. Into which tube on the illustration should the nurse plan to administer the feedings?



- a. A
- b. B
- c. C
- d. D

10. The nurse is assessing a client with transverse colostomy. Which of the following would be consistent with this type of colostomy?

- a. Stoma on the upper right abdomen with semiformal stool.
  - b. Stoma on lower right abdomen with mucous filled stools
  - c. Proximal and distal stoma with Soft to firm stools.
  - d. Stoma on Lower left abdomen with semiliquid to liquid
11. Which of these clients with fecal diversions (Ostomy) might eventually not require wearing an ostomy bag.
- a. Transverse colostomy
  - b. Ascending colostomy
  - c. End ileostomy
  - d. Sigmoid Colostomy
12. A client with permanent descending colostomy reported a feeling of needing to have a bowel movement. The nurse correctly interprets this as:
- a. Phantom rectum
  - b. Short Bowel Syndrome
  - c. A sign of psychological distress.
  - d. Irritation of the Internal Pouch
13. To avoid skin irritation the nurse should instruct the client to do which of the following. Select all that apply.
- a. Keep the skin barrier opening close to the edge of the stoma
  - b. No to wear the skin barrier too long.
  - c. Use skin barrier powder if the skin around the stoma is red and weepy
  - d. Clean the skin around the stoma with alcohol
  - e. Change the pouch if liquid seeps under the barrier
  - f. To apply skin barrier ointment to the skin before apply the pouch.
14. The nurse administered hydromorphone 2mg IV to a client for complaint of incisional pain 9 out of 10. What is the nurses most important nursing action immediately following the administration on the medication?

- a. Assess the patient's level of pain.
  - b. Document administration of the medicine.
  - c. Explain the medication to the client.
  - d. Apply pressure to the site for 3 -5 minutes.
15. A client with an end ileostomy reported to the emergency department with complaints of cramping abdominal pain and nausea. What other sign and symptom will the nurse assess for
- a. Assess client for history of diverticulitis or diverticulosis.
  - b. Assess the clients dietary and exercise pattern.
  - c. Ask the client the last time he emptied the ileostomy pouch.
  - d. Ask the client about nutritional intake of fiber and proteins.
16. The nurse has explained the importance of taking vitamin B supplements to a client with ileostomy. To ensure that learning occurred, the nurse should
- a. Repeat the details of the vitamin B supplement once more.
  - b. Ask the client relative to verify that the client understand the teaching.
  - c. Listen to the client's comments and answer his/her questions.
  - d. Refer the client to the written instructions for more information.
17. A client admitted to the surgical unit for fecal diversion surgery asked the nurse about a procedure with which the nurse is not familiar with. What is the best nursing response?
- a. "The technicians in the radiology department will explain the procedure in detail when you go for the test."
  - b. "It is your doctor's responsibility to explain the procedure to you. Would you like me to call the doctor for you?"
  - c. "I can't explain that now, but I will get back to you later after all the morning medications are given out."
  - d. "I don't know much about that procedure but I find out and bring you information about it."
18. Which of these dietary recommendations should the nurse include in the discharge instructions of a client going home after sigmoid colostomy? Select all that apply.



- a. Add new foods one at a time to see how you tolerate it.
  - b. Limit the intake of whole grains and soybean products.
  - c. Drink only water to prevent excess gas.
  - d. Avoid gas forming foods such as fish and eggs.
19. The nurse is taking care of a client who is 24 hours post-op following bowel resection and ascending colostomy for bowel perforation. The client has Jackson Pratt wound drain in place. Which action will the nurse perform after emptying the device to reestablish suction to the tube?
- a. Close the cap on the device.
  - b. Ensure the tubing has no kink.
  - c. Squeeze the collection chamber.
  - d. Wipe the port with alcohol.
20. A client has order for cefotaxime (Claforan) 1 gram IV every 6 hours following a bowel resection surgery. The reconstituted vial in the client's medication drawer is labelled with a concentration of 95 mg/mL. How many milliliters of solution should be added to the IV bag for the intermittent infusion?

Answer: \_\_\_\_\_ mL.

21. During discharge teaching. The nurse instructed a client with a new ileostomy to chew food thoroughly and avoid high fiber foods for 6 to 8 weeks. What is the rationale for the nurse's instruction?
- a. Foods that are high in fiber are hard to digest and can cause odor and gas
  - b. Foods that are high in fiber may cause blockages in the small intestine.
  - c. Foods that are high in fiber can cause diarrhea and dehydration.
  - d. Foods that are high in fiber increase urine odor by causing fluid imbalance.

22. The nurse instructed a client with a new ileostomy to avoid high fiber foods for 6 to 8 weeks. Which of the following food choices indicate the need for further instruction?

- a. **Celery**
- b. **Popcorn**
- c. Beans
- d. Fish
- e. Whole milk

### **Correct responses to NCLEX questions.**

1. A, B, and E

2. B

3. B

4. D

5. A

6. C

7. A, B, D, and E

8. B

9. C

10. A

11. Rationale: (D.) With a sigmoid colostomy the feces are solid, therefore the client might eventually gain enough control that he wouldn't need to wear a colostomy bag. The other choices the client is not likely to gain control.

12. (A.) Phantom rectum is the feeling of needing to have a bowel movement even though the rectum is not present. Phantom rectum is relatively common. Symptoms are usually mild and often go away without treatment.

13. A, B, C, and E.

14. Rationale: (B.) the nurse should document the administration of the medication immediately after completion. Assess the level of pain ½ hour to an hour after the administration to give the medicine time to take effect. The nurse should explain the medication to the client prior to administering the medication. Option d is wrong.

15. Rationale: (C.) The client is exhibiting signs of intestinal obstruction or bowel blockage. Asking client about the last time he emptied the ileostomy pouch will ascertain this. Diverticulitis is more common in colon and client with end ileostomy usually have the entire large intestine removed. Options B and D are general assessment that are irrelevant to the clients complaints.

16. Rationale: (C.) it is important that the nurse listen to the feedback given by the patient and answer question to clarify information provided to ensure that the message sent was received. Repetition is important in teaching but does not evaluate clients understanding.

17. Rationale: (D) demonstrates honesty and openness between the client and the nurse, it also addresses the client's need for information. The other options puts the client's needs on hold, do not represent honesty with the client, or transfer responsibility to another person.

18. Rationale: Option A is correct client should be instructed to add new foods one at a time to see the effect they have on ostomy management. Whole grain contains dietary fiber which the client need to promote regulation of elimination patterns. Drinking fluids is important but should not be limited to only water. Fish and eggs can cause odor but not gas.

19. Rationale: (C.). the nurse should squeeze the collection chamber to reestablish negative pressure and suction to the device. The nurse then wipes the port with alcohol before closing to prevent infection. Tubing should always be free of kinks to prevent obstruction.

20. Answer: 10.5 mL.

1 gram is equal to 1000 mg. Use the following formula to set up the problem.

$1000 \text{ mg (dose desired)} / 95 \text{ mg (dose available)} = X(\text{unknown}) / 1 \text{ mL (quantity)}$

Cross multiply 95 by X and 1000 by 1 to yield  $95X = 1000$ .

Divide 1000 by 95 to yield 10.52 or 10.5 mL.

21. (B.) Ileostomy patients must chew food thoroughly and avoid high fiber foods for 6 to 8 weeks. Foods that are high in fiber may cause blockages in the small intestine, especially after surgery, and should be added to the diet one at a time.

22. A and B.