

# A Comparative Study between Topical 5% Minoxidil and Topical “Redensyl, Capixyl, and Procapil” Combination in Men with Androgenetic Alopecia

Nezih Karaca<sup>1\*</sup> and Nebahat Demet Akpolat<sup>2</sup>

<sup>1</sup>Sculpture Polyclinics, Sisli, Istanbul, Turkey

<sup>2</sup>Department of Dermatology, Beykoz State Hospital, Beykoz, Istanbul, Turkey

\*Corresponding author: Nezih Karaca, Sculpture Polyclinics, Sisli, Istanbul, Turkey, Tel: +90 212 291 20 91; E-mail: drnezihkaraca@gmail.com

Received date: February 05, 2019; Accepted date: March 07, 2019; Published date: March 14, 2019

Copyright: © 2019 Karaca N, et al. This is an open-access article distributed under the terms of the Creative Commons Attribution License, which permits unrestricted use, distribution, and reproduction in any medium, provided the original author and source are credited.

## Abstract

**Objective:** Androgenetic Alopecia (AGA) is one of the three most common forms of noncicatricial alopecia characterized by hair loss in both men and women. It occurs in 50% of men above in their sixth decade. Currently, two effective treatments for AGA are used in men: topical minoxidil and oral finasteride. However, although clinical studies have shown that minoxidil and finasteride have positive therapeutic outcomes, their use can have certain side-effects. In this study, we aimed to compare the safety and effectiveness of an alternative treatment, Redensyl, Capixyl, and Procapil (RCP), and 5% minoxidil solution in adult male patients suffering from AGA.

**Methods:** This randomized controlled study was conducted on patients who used either RCP or 5% minoxidil for 24 weeks. The patients applied 1 mL of each solution to their head skin twice each day, in the morning and evening.

**Results:** The comparison between RCP and minoxidil groups revealed that patients treated with RCP had a significantly higher researcher score (minoxidil group 25.5% vs. RCP group 64.7%), higher global photographic evaluation score (minoxidil: 60% vs. RCP: 88.9%), and higher self-evaluation score.

**Conclusion:** The RCP group showed a significantly better clinical recovery in terms of hair growth.

**Keywords:** Alopecia; Androgenetic hair loss; Finasteride; Hair growth; Male patients; Minoxidil; Redensyl; Capixyl; Procapil

## Introduction

The three most common types of noncicatricial alopecia are androgenetic alopecia (AGA), alopecia areata, and telogen effluvium. AGA causes hair loss, which starts with bitemporal recession in the frontal hair line and progresses with a substantial thinning on the top of the head [1]. Loss of hair is a general problem related to AGA, which is seen in 50% of men above their 50s [1]. In females, the male-type AGA generally occurs in individuals who suffer from postmenopausal hair loss, although it may also occur in younger individuals. Alopecia is triggered by hair follicle miniaturization in response to stimulation of the conversion of testosterone to Dihydrotestosterone (DHT) by the 5 $\alpha$ -Reductase (5-AR) enzyme and progresses gradually. It has been reported that AGA does not occur in males who are genetically deficient in the 5-AR type 2 enzymes, and therefore AGA is assumed to be the outcome of androgen-dependent hair follicle miniaturization stimulated by the 5-AR type 2 enzymes [2]. Depending on the severity of AGA, different levels of hair loss are seen on the frontotemporal and top areas of the head skin in affected men [1]. A model for AGA pathogenesis has been suggested that explains these clinical aspects based on a variety of factors, including miniaturization of hair follicles, an increase in the telogen/anagen ratio, systemic and local effects of the androgens that trigger the disease, and familial susceptibility. The candidate genes involved in this process are related to androgen production and conversion of androgen into DHT. Although the

pathogenesis of AGA is complex, this clinical condition is believed to occur as a consequence of an autosomal dominant gene showing an altered penetrance, and is also known to have a polygenetic inheritance [3].

Given that AGA is a common problem, particularly among the male population, certain topical and oral treatment strategies or implants have been used to treat this condition. To date, however, only two drugs have been approved by the US Food and Drug Administration (FDA) for the treatment of AGA: minoxidil and oral finasteride. Minoxidil is a biological response regulatory drug that prevents hair loss in AGA and stimulates hair growth with no reported anti-androgenic effects. Although minoxidil was developed as an antihypertensive drug, its effect on hair growth was discovered later. Minoxidil is suggested to stimulate hair growth by inhibiting the decrease in calcium levels in the cells [4,5].

However, topical formulations of finasteride are currently not commercially available, and although minoxidil is generally well tolerated, it has several side effects, including burning/irritation and itching in the eye, irritation in the application area, and the growth of unwanted hair in different parts of the body. Inflammation has also been reported in patients with hair loss/alopecia [6]. The most common minoxidil-dependent side effect is irritant contact dermatitis, which is primarily related to the propylene glycol contained in minoxidil. In some cases, allergic contact dermatitis can also occur, as a small amount of minoxidil passes through the systemic circulation [6].

Finasteride is an inhibitor of 5-AR that causes the inhibition of miniaturization of hair follicles and an increase in the production of DHT. Oral finasteride has, however, been suggested to have certain potential risks such as gynecomastia, feminization, and impotence [3]. It has, nevertheless, been reported that 1 mg oral finasteride and 5% topical minoxidil are safe and effective treatments, with oral finasteride being found to be more effective than minoxidil in patients with moderately severe AGA [7]. Furthermore, a combination of minoxidil and finasteride was shown to result in better outcomes than their individual use [8-10].

As potentially safer/more effective alternatives to these two treatments, the effects of a number of other compounds have been actively investigated. Redensyl is prepared from a combination of botanical ingredients and contains Dihydroquercetin Glucoside (DHQG: 0.005%), Epigallocatechin Gallate glucoside (EGCG2: 0.0009%), glycine (0.005%), zinc chloride (0.002%), metabisulfite (0.015%), and glycerin (50%), among which DHQG and EGCG2 (two stabilized polyphenols) target and stimulate fibroblasts in the outer root sheath stem cells and dermal papilla, and glycine and zinc are required for hair metabolism [11,12]. Glycine is one of the main constituents of specific hair proteins known as Keratin-related Proteins (KAP) [13] and zinc is also an essential element that facilitates the binding of cysteines in keratin [14].

Another compound, Procapil, contains three extremely effective plant-derived substances: oleanolic acid (extracted from olive leaves), which inhibits 5 $\alpha$ 1 and 5 $\alpha$ 2 reductase enzymes [15]; apigenin (a flavonoid extracted from citrus peel) for vasodilation; and glycine-histidine-lysine peptides, which are required for pro-matrix metalloproteinase activity that is necessary for meeting the metabolic needs of hair follicles [16]. Furthermore, biotinyl-GHK (a vitamin-carrying peptide) is formed from biotin (vitamin H), a deficiency of which leads to hair thinning, alopecia, loose skin, and dermatitis [17].

Capixyl is a biomimetic peptide complex that is mixed with red clover extract and has been demonstrated to cause an increase in hair width and density [18].

These three compounds have been mixed and used as a topical spray to prevent hair loss and stimulate the growth of new hair follicles. The combination of Redensyl, Capixyl, and Procapil (RCP) is prepared according to the criteria for cosmetic products to develop a more effective treatment option for patients without side effects and thus the formula is available for long-term use. The present study was performed to evaluate whether this combination is more effective than minoxidil.

## Material and Methods

### Materials

**Redensyl, Capixyl and Procapil:** Redensyl was obtained from Induchem Laboratories (Switzerland and USA), Capixyl was obtained from International Flavors and Fragrances Laboratories (France), and Procapil was obtained from Sederma Laboratories (France).

**Minoxidil:** Topical minoxidil (5%) was procured from a local drug company in Turkey.

### Preparation

Water was added to the boiler. First, the water-soluble powder raw materials are added to the water and mixed until dissolved. Remaining

active raw materials such as Redensyl, Capixyl and Procapil are added to the system and mixed. The topical RCP and were formulated at the Cosmetic Studies Unit R&D Department, Faculty of Pharmacy, Yeditepe University, and all the rights of this RCP combination are reserved by the Turkish Patent Institute under the name Procure. After receiving approval (16/2016, in 31.01.2016) from the Ethics Board of the Istanbul Anatolia-North Region Public Hospitals Trust, this study was conducted according to the Good Clinical Applications guide of the Helsinki Declaration and Central Drugs Standard Control Organization.

### Methods

A total of 120 patients were included in this study. All the patients who desired to participate were evaluated by taking all inclusion and exclusion criteria into account and their suitability was screened before the study. According to the modified Norwood-Hamilton classification [19], all the male patients, 18-55 years of age, who had stages II-V AGA, wanted to preserve the style, length, and color of their hair during the study, and who had signed a written consent, were included in this study.

Those patients having dermatological diseases other than AGA on their head skin and those suffering from serious cardiovascular, kidney, liver, drug hypersensitivity, or lung diseases were excluded from the study. Also excluded were those individuals who used wigs, had a hair loss-related treatment history, or had shaved head skin. All the volunteer patients who satisfied these suitability criteria were registered with a randomization ID. Two of the test compounds were provided to these patients in one visit. These patients attended a training session for instruction on how to topically apply these test compounds to the hairless area. The start date of the study was considered as the first day for all registered patients, and all other time points for the evaluation (e.g., visit days) was planned accordingly. The patients were randomized to take only RCP or minoxidil. These two compounds were applied to hair using an injector in the mornings and evenings, applying 1 mL each time. This amount was labelled on the injector and shown during the training session. At each time point of the evaluation [start of the study, follow-up (after every 4 weeks), and end of the study (after 24 weeks)], the patients were expected to visit the clinic and the condition of their hair, the follow-up plan of their topical serum treatment, and adverse effects, if any, were recorded in the Case Record Form (CRF). In addition, the researcher used a five-point evaluation to assess increases in hair density, the scaling criteria of which are as follows:

**A significant recovery:** Intensive hair growth (the hairless area has an almost similar intensity to the non-hairless area, and the skin is almost covered with hair).

**A moderate recovery:** Average hair growth (the hairless area has less intensity than the non-hairless area and is partially covered with the newly grown hair).

**A slight recovery:** Minimal hair growth (despite hair growth, the hairless area can clearly be seen).

**No change:** No hair growth detectable, using the naked eye.

**Worsening:** A decrease in hair growth.

In addition to the visits at the beginning of the study, the effect of the test compounds on hair growth was evaluated using a self-evaluation form (Table 1). The related scores were recorded in the CRF. Detailed global photographic evaluations [20] were performed at the

beginning of the study and at the end of the 12<sup>th</sup> and 24<sup>th</sup> week visits by the researcher.

Questions	Score
<b>Did your bald area shrink?</b>	
Strongly agree	1
Agree	2
No idea	3
Disagree	4
Strongly disagree	5
<b>What was your opinion of your hair after the treatment?</b>	
Much better	1
Better	2
Same	3
Worse	4
Much worse	5
<b>How do you rate your new hair growth?</b>	
Perfectly increased	1
Moderately increased	2
Not changed	3
Moderately decreased	4
Clearly decreased	5

<b>Are you satisfied with the appearance of your new hair?</b>	
<b>Frontal (frontal area)</b>	
<b>Vertex (top of the hair)</b>	
Very satisfactory	1
Satisfactory	2
Average	3
Not satisfactory	4
Very bad	5

**Table 1:** Patient self-evaluation form.

Changes in the researcher evaluation scores in terms of hair growth and intensity-dependent head skin coverage were used as primary activity criteria. To evaluate secondary activity criteria, changes in the hair condition were assessed using the self-evaluation questionnaire and a seven-point global photographic evaluation. Single-variable SAS was used to test the assumption of normality, and the Shapiro-Wilk test was used for the normality evaluation of both groups.

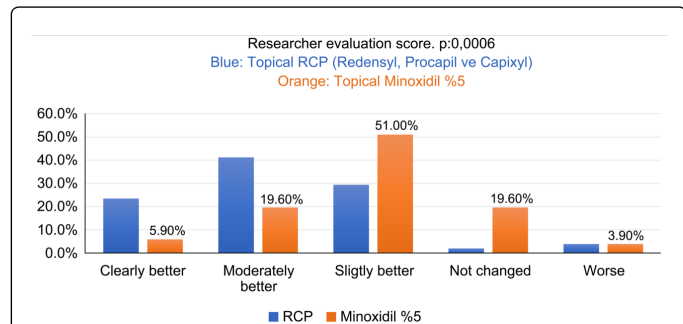
## Results

This randomized, prospective, open-ended clinical study was scaled using the modified Norwood-Hamilton scale between stages II and V (Table 2). It was conducted on adult male patients with AGA. Eligible volunteers were randomized to take either RCP or topical minoxidil. For evaluation of compound activity, the data at the beginning and the end of the treatment were compared within groups and between groups. During the study, any absolute change in the evaluation of the researcher at each time point after the beginning date of the study, patient evaluation, or global photographic evaluation scores were reported.

Type 1	No recession in the frontotemporal hairline region is observed or the recession is minimal
Type 2	A symmetrical and triangle-shaped recession is observed on the frontotemporal region hairline. Although some hair loss or thinning is seen in the middle of the frontal region, it is less than that in the frontotemporal region
Type 3	Hair loss becomes evident. A deep symmetrical frontotemporal recession becomes clearer
Type 4	Severe frontal and frontotemporal hair loss is observed
	A clear thinning is observed in the vertex
	These two regions are divided by a clear hair band structure
Type 5	The hair band in type 4 becomes thinner
	Hair-free regions increase in the vertex and frontotemporal region
Type 6	The hair loss becomes clearer even in the hair band region
	Frontotemporal hair-free regions merge with those in the vertex
Type 7	This is a severe form
	It starts from the front of the ear and extends backward. Only a horseshoe-shaped band of hair that surround the posterior region remains

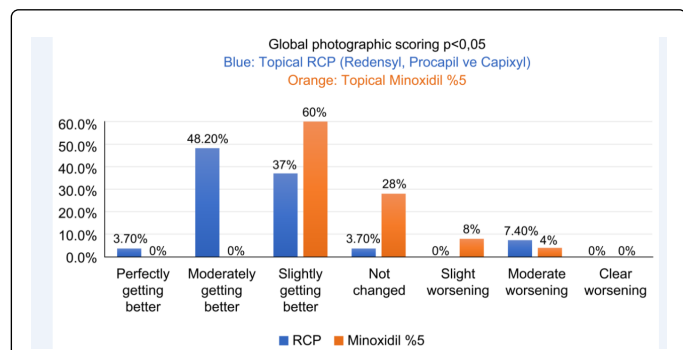
**Table 2:** Norwood-Hamilton classification.

Of the 120 individuals enrolled in the study, 106 completed the study (54 patients in the RCP group and 52 patients in the minoxidil group). The researcher evaluation showed significantly better recovery in the group treated with RCP than in the group that received minoxidil treatment (minoxidil group 25.5% vs. RCP group 64.7%,  $p=0.006$ ) (Figure 1).

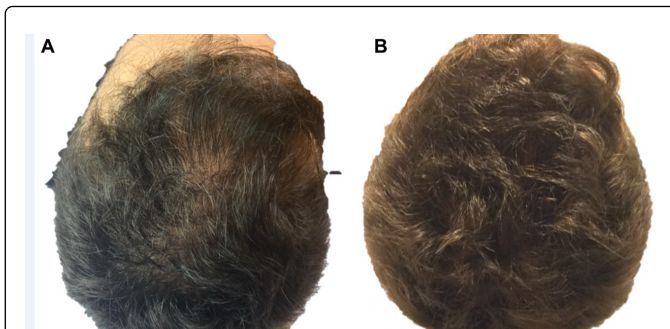


**Figure 1:** Researcher Evaluation Score.  $p: 0.0006$  Blue: Topical RCP (Redensyl, Procapil vs. Capixyl) Orange: Topical Minoxidil.

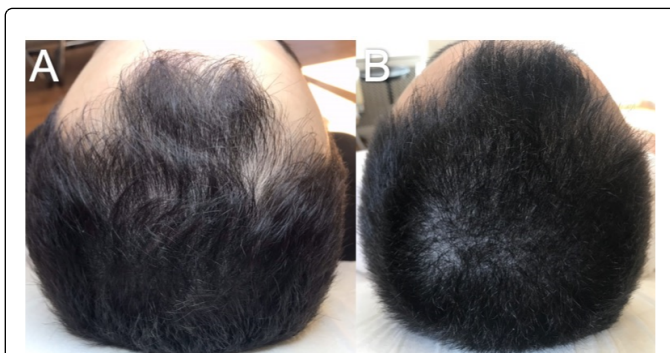
In the patients with AGA, a seven-point global photographic evaluation scale was used to evaluate the head skin before and after the treatment by the photography of the top and superior frontal area. Global photographic evaluation of the 106 patients who completed the study revealed a significantly greater extent of recovery (slight, moderate, and high increase) in the group treated with RCP than in the group treated with topical minoxidil (88.9% in the RCP group vs. 60% in the minoxidil group) (Figure 2). Topical RCP thus provided better recovery compared with 5% minoxidil, and the difference was shown to be statistically significant ( $p<0.05$ ) (Figures 3-7).



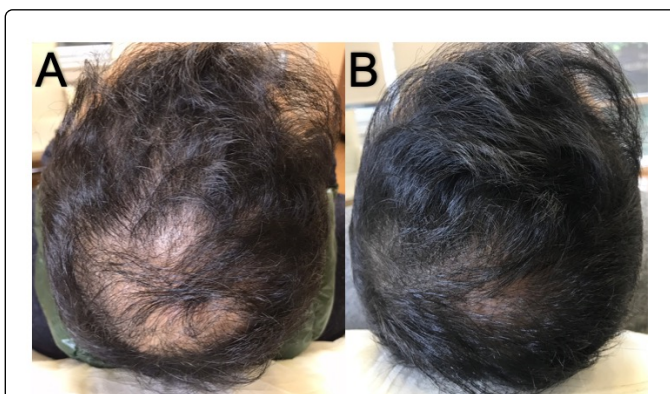
**Figure 2:** Global Photographic Scoring  $p<0.05$  Blue Color: Topical RCP (Redensyl, Procapil vs. Capixyl).



**Figure 3:** (A) View of the alopecic areas before treatment (extending from the frontal area to the vertex); (B) Recovery on the alopecic areas after 24 weeks of RCP treatment.

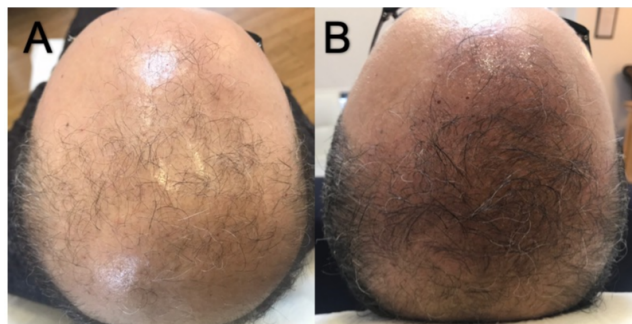


**Figure 4:** (A) Alopecic areas before treatment (extending from the frontal area to the vertex); (B) Recovery after 24 weeks of RCP treatment.

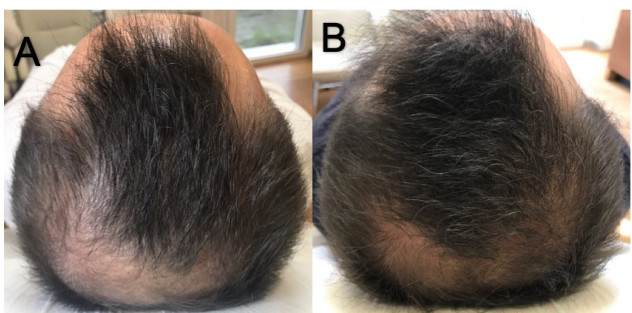


**Figure 5:** (A) Before treatment (extending from the frontal area to the vertex); (B) Recovery on the alopecic areas after 24 weeks of RCP treatment.





**Figure 6:** (A) View of the alopecic areas before treatment (extending from the frontal area to the vertex); (B) Recovery on the alopecic areas after 24 weeks of topical minoxidil treatment.



**Figure 7:** (A) Alopecic areas before treatment (extending from the frontal area to the vertex); (B) Recovery on the alopecic areas after 24 weeks of minoxidil treatment.

Sixty-eight patients (34 in the minoxidil group and 34 in the RCP group) submitted their responses to the self-scoring questionnaire. Evaluation of these forms indicated that 15 patients in the group using 5% minoxidil and 30 in the group using RCP responded to the question "Did your bald area shrink?" by selecting "strongly agree" or "agree," a difference that was found to be statistically significant (Table 3).

Bald area scoring (gradual shrinkage of the bald area)					
Treatment	Strongly agree	Agree	Disagree	No idea	Total
RCP	9	21	2	4	36
Minoxidil	0	15	8	11	34
Total	9	36	10	15	70

**Table 3:** Patient self-evaluation regarding shrinkage of the bald area after treatment with minoxidil or RCP (Redensyl+Capixyl+Procapil) ( $p=0.0008$ ).

Patients treated with RCP showed a better recovery on their hair front line ( $P = 0.023$ ) and general evaluation (0.0004). They also stated that they had better outcomes in terms of hair growth and hair loss. Tables 4 and 5 shows the self-evaluation scores of the patients related to hair growth and hair loss retardation.

Treatment	Hair growth scoring				
	Clearly increased	Moderately increased	Slightly increased	Not changed	Moderately decreased
RCP	10	14	8	3	1
Minoxidil	3	10	13	7	1
Total	13	24	21	10	2

**Table 4:** Self-evaluation scores of the patient after treatment with minoxidil or RCP (Redensyl+Capixyl+Procapil) ( $p=0.0023$ ).

Treatment	Hair loss scoring				
	Very effective	Effective	Partially effective	No effect	Total
RCP	6	17	10	3	36
Minoxidil	3	16	13	2	34
Total	9	33	23	5	70

**Table 5:** Evaluation scores related to the hair loss retardation of the patient after treatment with minoxidil or RCP (Redensyl+Capixyl+Procapil) ( $p=0.0004$ ).

## Discussion

Minoxidil is a biological response regulatory drug that prevents hair loss in individuals with AGA and stimulates hair growth. No anti-androgenic effects of this drug have been reported. Although originally developed as an antihypertensive drug, the effect of Minoxidil on hair growth was discovered later. Minoxidil opens potassium channels and decreases intracellular calcium, the latter of which inhibits epidermal growth factor-stimulated growth of the hair root. Minoxidil has been suggested to stimulate hair growth by inhibiting the decrease in calcium levels in cells [4,5,21]. Moreover, minoxidil has been shown to be a mitogenic drug that prolongs the life of hair follicles [22], and *in vitro* studies have shown that minoxidil stimulates the proliferation of hair follicles [23]. In 1997 and 1998, 2% and 5% minoxidil were respectively approved by the FDA. The dose of minoxidil should be 1 mg twice a day and needs to be used for at least 6 months to evaluate its efficacy [24]. The clinical effectiveness of minoxidil has been demonstrated in several studies. It has been shown to stimulate the conversion of villus-type hair to terminal hair, and thus its efficacy depends on the severity of AGA and the presence of these types of hair [25]. Moreover, minoxidil is not effective when applied topically to the temporal area. Although a previous study has shown that minoxidil could stimulate new hair growth in 90% of the males and also strengthened the hair growth in 60% of the patients [26], it is considered that these results were exaggerated. Another study demonstrated new hair formation in 15% of the males who used minoxidil, with a delay in the hair loss being observed in 50% of the males and continuous hair loss being observed in the remaining 35% of individuals [3]. In a further study that compared the effectiveness of 5% and 2% minoxidil, it was found that the effects of minoxidil were noted earlier in the 5% minoxidil group and that 45% stronger hair growth was observed in this group [27]. Similarly, whereas a 23% improvement was observed in men who used a placebo, a 60% improvement was recorded in the group treated with 5% topical

minoxidil for 48 hrs. Furthermore, 5% minoxidil treatment was found to result in better hair growth compared with 2% minoxidil treatment [5]. However, it has been found that discontinuation of minoxidil treatment results in a loss of the newly grown hair and reversion to the pre-treatment condition [28]. Minoxidil can however, be combined with tretinoin, and it has been reported that this formulation promotes more rapid hair growth [29].

As an alternative to minoxidil, finasteride has been approved for the treatment of AGA. Finasteride inhibits the activity of the 5-AR enzyme, thereby inhibiting the conversion of testosterone to DHT. This drug does not affect androgen receptors or cause any elevations in testosterone levels, and thus does not have any anti-androgenic effects, and can be safely used in males. Its half-life is approximately 8 hrs, and no dose adjustment is required as a precautionary measure against kidney failure. In 1997, the use of this drug for the treatment of AGA was approved by the FDA [30,31]. Using a recommended application of 1 mg finasteride, a 48% increase in hair intensity was reported as at the end of the first year and a 66% increase at the end of the second year of treatment, compared with a 7% increase in the placebo group [24]. In contrast, no significant difference was observed between finasteride and placebo treatments in postmenopausal women with AGA [32]. Accordingly, the use of finasteride for women is not recommended. This drug is generally well tolerated, and no cross-reactions with other drugs have been reported. Although it rarely produces side effects, a decrease in libido (1.8%), erectile dysfunction (1.3%), and reduced ejaculation volume (0.8%) have been reported. Moreover, as it can cause feminization in the fetus, its use by women of reproductive age is contraindicated. Use of finasteride at 1 mg/day has been shown to slow the progression of hair loss and result in an increase in hair growth within 2 years [33]. Hair intensity-independent factors such as increased growth (length) and hair thickness contribute to the beneficial effects of finasteride [33].

In this study, Redensyl<sup>®</sup>, is a mix of four active ingredients: Dihydroquercetin-glucoside (DHQG), Epigallocatechin gallate-glucoside (EGCG2), glycine and zinc. Glycine is essential for the hair shaft structure as it enters directly in the composition of Keratin associated protein [11]. Zinc is added to the composition to reinforce hair shaft structure. Zinc is also essential for cystin incorporation into keratin [14].

*In vitro* studies performed and literature data have shown the multiple properties of Epigallocatechin gallate-glucoside derivatives have anti-inflammatory properties by reduction of IL-8 release by keratinocytes under inflammatory condition, stimulation of proliferation of dermal papilla fibroblasts [34], effects on free radicals [35] and stimulation of human hair follicle growth [34].

Another compound Procapil contains three extremely effective plant-derived substances: oleanolic acid, which inhibits 5 $\alpha$ 1 and 5 $\alpha$ 2 reductase enzymes (extracted from olive leaves); apigenin for the vasodilation (a flavonoid that is extracted from citrus peel); and glycine-histidine-lysine peptides, which are required for pro-matrix metalloproteinase activity to be able to meet the metabolic needs of hair follicles [16]. Also, Biotinyl-GHK (vitamin-carrying peptide) is formed from biotin (vitamin H). The deficiency of this vitamin leads to thin hair, alopecia, loose skin, and dermatitis [17].

Capixyl is a biomimetic peptide complex that is mixed with red clover extract. It has been demonstrated to cause an increase in hair width and density [18]. Biochanin A is the major isoflavone in red

clover. Biochanin A is known to be an effective inhibitor of 5 $\alpha$ -reductase type I & II activity [36].

In the present study, as an alternative to the generally accepted topical minoxidil, which plays an important role in AGA treatment, we evaluated the effectiveness of topical Redensyl, Procapil, and Capixyl (RCP) in an appropriate stoichiometric combination, which we compared with that of 5% minoxidil. The researcher evaluation scores indicated that 64.7% of volunteers in the RCP group and 25.5% in the 5% minoxidil group showed either "significant recovery" or "moderate recovery" ( $p=0.0006$ ). At the end of 24-week treatment period, hair recovery in the RCP group was 2.54 times higher than that in the minoxidil group, a difference that was found to be statistically significant.

The global photographic evaluation revealed significantly greater recovery (slight, moderate, and high increase) in the group treated with RCP than in the group treated with topical minoxidil (88.9% in the RCP group and 60% in the minoxidil group) (Figure 2) and again the difference between the two groups was statistically significant ( $p<0.05$ ). Hence, the RCP group showed 1.5 times greater improvement than the minoxidil group, which is consistent with the results of researcher evaluation scores.

## Conclusion

In conclusion, we can say that there are no previous studies related to Redensyl, Capixyl and Procapil nor RCP combination. Only studies on the sub-contents of the relevant raw materials have been reported. Apart from a slight minoxidil-related irritation, no serious adverse effects were reported in this study. Furthermore, compared with topical application of minoxidil, greater efficacy and patient satisfaction were reported in response to treatment with topical RCP. Given that either topical or systemic treatment of AGA may necessitate prolonged usage to produce noticeable effects, the combinational treatment of "topical RCP" represents a potentially innovative and effective approach for patients who have concerns regarding the side effects of topical minoxidil. In order to further evaluate the effectiveness of RCP treatment, more large-scale, controlled studies need to be conducted to assess the difference between single and combinational usage with minoxidil.

## References

1. Shapiro J, Wiseman M, Lui H (2000) Practical management of hair loss. *Can Fam Physician* 46: 1469-1477.
2. Hoffmann R (2002) Male androgenetic alopecia. *Clin Exp Dermatol* 27: 373-382.
3. Sinclair R (1998) Male pattern androgenetic alopecia. *British Med J* 317: 865-869.
4. Headington JT (1987) Hair follicle biology and topical minoxidil: Possible mechanisms of action. *Dermatologica* 175: 19-22.
5. Bergfeld W, Washenik K, Callender V, Zhang P, Quiza C, et al. (2016) A phase III, multicenter, parallel-design clinical trial to compare the efficacy and safety of 5% minoxidil foam versus vehicle in women with female pattern hair loss. *J Drugs Dermatol* 15: 874-881.
6. Rossi A, Cantisani C, Melis L, Iorio A, Scali E, et al. (2012) Minoxidil use in dermatology, side effects and recent patents. *Recent Pat Inflamm Allergy Drug Discov* 6: 130-136.
7. Arca E, Acikgoz G, Tastan HB, Köse O, Kurumlu Z (2004) An open, randomized, comparative study of oral finasteride and 5% topical minoxidil in male androgenetic alopecia. *Dermatology* 209: 117-125.

8. Khandpur S, Suman M, Reddy BS (2002) Comparative efficacy of various treatment regimens for androgenetic alopecia in men. *J Dermatol* 29: 489-498.
9. Tanglertsampan C (2012) Efficacy and safety of 3% minoxidil versus combined 3% minoxidil / 0.1% finasteride in male pattern hair loss: a randomized, double-blind, comparative study. *J Med Assoc Thai* 95: 1312-1316.
10. Diani AR, Mulholland MJ, Shull KL, Kubicek MF, Johnson GA, et al. (1992) Hair growth effects of oral administration of finasteride, a steroid 5 alpha-reductase inhibitor, alone and in combination with topical minoxidil in the balding stump-tail macaque. *J Clin Endocrinol Metab* 74: 345-350.
11. Rogers GE (2004) Hair follicle differentiation and regulation. *Int J Dev Biol* 48: 163-170.
12. Liu Z, Ma LP, Zhou B, Yang L, Liu ZL (2000) Antioxidative effects of green tea polyphenols on free radical initiated and photosensitized peroxidation of human low density lipoprotein. *Chem Phys Lipids* 106: 53-63.
13. Jenkins BJ, Powell BC (1994) Differential expression of genes encoding a cysteine-rich keratin family in the hair cuticle. *J Invest Dermatol* 103: 310-317.
14. Hsu JM, Anthony WL (1971) Impairment of cystine-35S incorporation into skin protein by zinc-deficient rats. *J Nutr* 101: 445-452.
15. Mas-Chamberlin C, Mondon P, Lamy F, Peschard O, Lintner K, et al. (2019) Reduction of Hair-loss: Matrikines and plant molecules to the rescue. *Sederma France*: 1-12.
16. Maquart FX, Siméon A, Pasco S, Monboisse JC (1999) Regulation of cell activity by the extracellular matrix: The concept of matrikines. *J Soc Biol* 193: 423-428.
17. Trüeb RM (2016) Serum biotin levels in women complaining of hair loss. *Int J Trichology* 8: 73-77.
18. Loing E, Lachance R, Ollier V, Hocquaux M (2013) A new strategy to modulate alopecia using a combination of two specific and unique ingredients. *J Cosmet Sci* 64: 45-58.
19. Norwood OT (1975) Male pattern baldness: Classification and incidence. *South Med J* 68: 1359-1365.
20. Canfield D (1996) Photographic documentation of hair growth in androgenetic alopecia. *Dermatol Clin* 14: 713-721.
21. Buhl AE, Waldon DJ, Conrad SJ, Mulholland MJ, Shull KL, et al. (1992) Potassium channel conductance: A mechanism affecting hair growth both in vitro and in vivo. *J Invest Dermatol* 98: 315-319.
22. Cohen RL, Alves M, Weiss VC, West DP, Chambers DA (1984) Direct effects of minoxidil on epidermal cells in culture. *J Invest Dermatol* 82: 90-93.
23. Buhl AE, Waldon DJ, Kawabe TT, Holland JM (1989) Minoxidil stimulates mouse vibrissae follicles in organ culture. *J Invest Dermatol* 92: 315-320.
24. Aksungur VL, Tüzün Y, Güreler MA, Serdaroglu S, Oğuz O (2008) Androgenetik alopesi. (3rd edn) *Dermatoloji* 1309-1318.
25. Tosti A, Camacho-Martinez F, Dawber R (1999) Management of androgenetic alopecia. *J Eur Acad Dermatol Venereol* 12: 205-214.
26. Savin RC (1987) Use of topical minoxidil in the treatment of male pattern baldness. *J Am Acad Dermatol* 16: 696-704.
27. Olsen EA, Dunlap FE, Funicella T, Koperski JA, Swinehart JM, et al. (2002) A randomized clinical trial of 5% topical minoxidil versus 2% topical minoxidil and placebo in the treatment of androgenetic alopecia in men. *J Am Acad Dermatol* 47: 377-385.
28. Olsen EA, Weiner MS (1987) Topical minoxidil in male pattern baldness: effects of discontinuation of treatment. *J Am Acad Dermatol* 17: 97-101.
29. Serdaroglu S, Dolar N (2002) Androgenetik alopesi tedavisi. *Dermatose* 4: 11-16.
30. Şendur N, Karaman GC (2000) Androgenetik alopesi. *ADÜ Tıp Fakültesi Dergisi* 1: 39-46.
31. McClellan KJ, Markham A (1999) Finasteride: A review of its use in male pattern hair loss. *Drugs* 57: 111-126.
32. Kaufman KD, Olsen EA, Whiting D, Savin R, DeVillez R, et al. (1998) Finasteride in the treatment of men with androgenetic alopecia. Finasteride Male Pattern Hair Loss Study Group. *J Am Acad Dermatol* 39: 578-589.
33. Price VH, Menefee E, Sanchez M, Ruane P, Kaufman KD (2002) Changes in hair weight and hair count in men with androgenetic alopecia after treatment with finasteride, 1 mg, daily. *J Am Acad Dermatol* 46: 517-523.
34. Kwon OS, Han JH, Yoo HG, Chung JH, Cho KH, et al. (2007) Human hair growth enhancement in vitro by green tea epigallocatechin-3-gallate (EGCG). *Phytomedicine* 14: 551-555.
35. Park SY, Jeong YJ, Kim SH, Jung JY, Kim WJ (2013) Epigallocatechin gallate protects against nitric oxide-induced apoptosis via scavenging ROS and modulating the Bcl-2 family in human dental pulp cells. *J Toxicol Sci* 38: 371-378.
36. Evans BA, Griffiths K, Morton MS (1995) Inhibition of 5 alpha-reductase in genital skin fibroblasts and prostate tissue by dietary lignans and isoflavonoids. *J Endocrinol* 147: 295-302.