



# Evaluation of the safety of VASER™ in liposuction surgery to improve body contour

*Avaliação da segurança no emprego do VASER® em cirurgia de lipoaspiração para melhora de contorno corporal*

FELIPE MASSIGNAN <sup>1\*</sup> 

Institution: Centro Hospitalar Santa Mônica,  
Erechim, RS, Brazil.

Article received: April 4, 2019.  
Article accepted: October 20, 2019.

Conflicts of interest: none.

DOI: 10.5935/2177-1235.2019RBCP0225

## ■ ABSTRACT

**Introduction:** Liposuction has been improved continuously since it was first introduced. The third-generation ultrasound technology VASER™ (Vibration Amplification of Sound Energy at Resonance) facilitates liposuction, providing improved safety and satisfactory results, especially in the search for greater definition and superficial liposuction. **Methods:** From 2015 to 2017, 76 patients underwent liposuction to improve their body contour at the Santa Monica Hospital Center in Erechim, Rio Grande do Sul, Brazil. The results, complications, and the safety of VASER™ were evaluated. **Results:** The routine use of VASER™ improves body contour. The emulsification generated by the device, along with liposuction, resulted in greater definition and revelation of the anatomical landmarks. **Conclusion:** Liposuction associated with VASER™ allows plastic surgeons to refine the results better while ensuring patient safety is maintained. **Keywords:** Tissue; Lipodystrophy; Postoperative complications; Subcutaneous fat; Patient safety; Body contour.

<sup>1</sup> Centro Hospitalar Santa Mônica, Centro Hospitalar, Erechim, RS, Brazil.

## ■ RESUMO

**Introdução:** A lipoaspiração tem sido submetida à evolução constante desde a sua consolidação e emprego sistemático. O auxílio de tecnologia ultrassônica de terceira geração, VASER® (*Vibration Amplification of Sound Energy at Resonance*), se destina a facilitar a execução da lipoaspiração e trazer maior segurança e resultados satisfatórios, especialmente na busca por maior definição e lipoaspiração superficial. **Métodos:** No período de 2015 a 2017, 76 pacientes foram submetidas à lipoaspiração para melhora de contorno corporal no Centro Hospitalar Santa Mônica em Erechim. Foram avaliados os resultados obtidos, as possíveis complicações e a segurança do emprego do VASER®. **Resultados:** A utilização rotineira do VASER® gera aperfeiçoamento de resultados em contorno corporal. A emulsificação gerada pelo dispositivo associada à lipoaspiração em diversos níveis permite uma maior definição e evidência dos marcos anatômicos. **Conclusão:** Lipoaspiração associada ao VASER® permite ao cirurgião plástico o refinamento de seus resultados com a preservação da segurança do paciente.

**Descritores:** Tecido adiposo; Lipodistrofia; Complicações pós-operatórias; Gordura subcutânea; Segurança do paciente; Contorno corporal.

## INTRODUCTION

Liposuction is one of the main procedures performed by plastic surgeons. Over time, a number of important innovations have been made to traditional liposuction, which have resulted in greater comfort for the surgeon as well as better results<sup>1</sup>.

Historically, several approaches have been used to remove adipose tissue during liposuction<sup>2</sup>. Over time the procedure has been refined, and improvements were made to improve various aspects of the procedure, such as the surgical technique, the cannulas employed and the use of adjuvant devices.

In a sense, this will be a continuous journey. There are no particular objectives, but only goals. Traditional liposuction remains a somewhat strenuous procedure with limited tactical variations. Therefore, initiatives capable of generating a reduction in the load and mechanical stress or amplifying the handling of the subcutaneous cell tissue variations can help optimize liposuction<sup>3</sup>.

The use of ultrasound in surgical procedures is not new. Zocchi, in 1995<sup>4</sup>, became a pioneer in applying ultrasound to emulsify fat selectively so as to contour the body. The first-generation devices for ultrasonic-assisted liposuction were developed by SMEI, Italy. The

SMEI appliance consisted of solid 4–6 mm probes that emulsified the fat at a frequency of 20 kHz.

Second-generation devices were introduced in the 1990s, such as the Lysonix 2000 (Lysonix Inc. Carpinteria, CA). In this case, emulsification and aspiration occurred simultaneously through a “golf-tee” and “bullet design” cannula at a frequency of 22.5 kHz. During the same period, the Mentor Corporation introduced its body contouring devices, Mentor Contour Genesis Devices, with a hollow 3.0 mm and 5.1 mm cannula at a frequency of 27 kHz. The excessive transfer of energy to the tissues combined with the elimination of the protective layer from the simultaneous extraction resulted in significant complications<sup>5</sup>.

The popularity of ultrasonic-assisted liposuction decreased by the end of the 1990s. In 2001, Sound Surgical Technologies introduced VASER™ (*Vibration Amplification of Sound Energy at Resonance*), a third-generation device that was created to improve safety by reducing the energy transferred to the tissues while maintaining efficacy<sup>6</sup>.

VASER™ has a solid probe that emulsifies fat efficiently at 36 kHz while preserving nearby tissue. The tunable nature of the system allows almost all areas of the body to be treated safely and effectively.

Currently, VASER™ is considered the gold standard in high-definition body contour<sup>7</sup>.

In VASER™, the resonance uses a frequency of 36 kHz, which is close to the resonance of fat. For this reason, a lower energy is transferred to other tissue. Moreover, adipose cells are much larger than other adjacent tissues, such as blood vessels, nerves, and connective tissue and, therefore, are more susceptible to ultrasonic energy<sup>8</sup>.

The appliance uses 2.2–4.5 mm diameter probes with grooves near the tip to increase the energy transmission efficiency and fragmentation of fat. A larger probe results in more ultrasonic energy being dispersed. The device also has a pulsed ultrasonic energy delivery mode. This method uses high vibration frequencies with non-continuous activation, decreasing the total tissue energy applied while maintaining efficacy<sup>9</sup>.

## OBJECTIVE

This study aimed to evaluate the safety of a third-generation ultrasonic device, VASER™, with liposuction surgeries to improve body contour. The data obtained in this study were compared with the existing literature.

## METHODS

The study consisted of a retrospective review of medical records of patients who underwent a liposuction procedure with the aid of VASER™, from January 2015 to June 2017, at the Santa Monica Hospital Center in Erechim, Rio Grande do Sul, Brazil.

The data and the methods used were approved by the Ethics Committee of the Santa Monica Hospital, Erechim/RS, Brazil. Record 002/2018.

## Selection of patients as well as inclusion and exclusion criteria

The patients included in the study were male or female, aged over 18 years, with localized excess subcutaneous fat. The exclusion criteria were:

- Patients with a limiting clinical condition;
- Women in the first year after birth, were pregnant or lactating;
- A body image disorder;
- Inflammatory conditions of the skin in the target area of surgical therapy;
- Obesity (BMI > 30);
- Concomitant abdominoplasty surgery.

We included 76 patients in our study. Females were the most common gender, with 74 patients, accounting for 97.36% of the sample. Two male patients (2.67%) underwent liposuction with VASER™. The average age of the women in the study was 39 years old (21 to 65 years) and 37 years old for men. The mean BMI of the sample was 24.64 kg/m<sup>2</sup> (Table 1).

## Evaluation Criteria

Given that liposuction was performed, we used the routine criteria mentioned in the current literature regarding surgical complications. These can be classified according to the occurrence period.

## Preoperative evaluation

All patients were evaluated before surgery by the anesthesiology team of the Santa Monica Hospital Center. Laboratory and complementary exams were requested in accordance with their age and comorbidities. Patients were under general anesthesia for the procedure (Table 2).

**Table 1.** Procedures performed.

Procedure performed	Number of Patients
Liposuction in the abdominal region, flanks, and dorsum.	31
Liposuction in the abdominal region and dorsum with the placement of breast implants.	20
Liposuction in the abdominal region, flanks, and dorsum with mastopexy.	8
Liposuction in the abdominal region and mastopexy with the placement of implants.	5
Liposuction in the abdominal region, flanks, and dorsum with mastopexy and placement of implants.	3
Liposuction in the abdominal region with the placement of breast implants.	3
Liposuction in the lateral face of the thigh with the placement of breast implants.	2
Liposuction in the abdominal region.	1
Liposuction of the abdominal region, flanks, and dorsum with correction of gynecomastia.	2
Liposuction of the lateral face of the thighs.	1

**Table 2.** Complications.

Perioperative complications (0–48 h)	Postoperative complications in recent (1–7 days)	Complications in the late postoperative period (1 week–3 months)
Skin necrosis	Cellulite	Seroma
<i>Injury due to the cannula, portal or endpoint</i>	Paresthesia, transient or permanent alteration in sensitivity	Prolonged Edema
Anesthetic Complications	Hyperpigmentation	Fibrosis
	Hypopigmentation	

Complications – Ultrasonic-assisted liposuction

**VASER™ Technology**

Ultrasonic technology is based on the conversion of electrical energy in sound vibrating waves through a handpiece. This vibration moves through a titanium probe at a constant frequency of 36 kHz. The interaction of probe designs with tissue sound reverberation regulates the effectiveness of the system<sup>2</sup>.

Subcutaneous tissue, which is in a humid environment, receives the sound energy coming from this probe. There are two operating mechanisms. The first, and less frequent, breaks down the cell membrane by direct impact. The second is called cavitation. The vibratory frequency of the sound wave produces compression and rarefaction forces (cavitation), which are issued by its distal rings, with small air bubbles forming. These bubbles will gradually increase in diameter and simultaneously englobe the adipocytes in their interior until they rupture. The energy released by the rupture of the microbubbles releases the adipocytes from the tissue microarchitecture<sup>8</sup>.

Cavitation and the mechanical rupture of tissue are selective, i.e., the diameter of fat cells are larger than the adjacent tissue microarchitecture (blood vessels, muscle fibers, connective tissues). Therefore, these remain intact<sup>8</sup>.

The appliance has enough power and accuracy to treat different body areas without the need to use loading to overcome areas of tissue resistance<sup>6</sup>.

The VASER™ is composed of an integrated system, formed by a display (ultrasound), handpiece, probes (special atraumatic rods), aspiration tower using the Ventx system (ventilated suction system), integrated irrigation system, and drive pedals. This entire apparatus brings together all the necessary equipment to perform liposuction surgery in an organized manner. This helps to ensure safety, comfort, and practicality in using the device<sup>8</sup> (Figure 1).

**Skin Ports**

Protective parts used in surgical accesses are routinely inserted into the gluteus sulcus, anterior and posterior axillary topographies, pubic region,



**Figure 1.** VASER™ System (Vibration Amplification of Sound Energy at Resonance). Source: The Author (2018)



navel, and inframammary sulcus. They prevent and protect these areas from thermal lesions occurring due to ultrasonic vibrations and trauma of repetitive movements (Figure 2).



Figure 2. Portals with a suitable design for varying the diameters of the ultrasonic probe. Source: The Author (2018)

**Handpiece**

Sound pulse conduction instrument connected directly to the ultrasound with inserts for the probes. They require continuous revision of “wrench” fitting to dissipate the sound wave vertically (Figure 3).

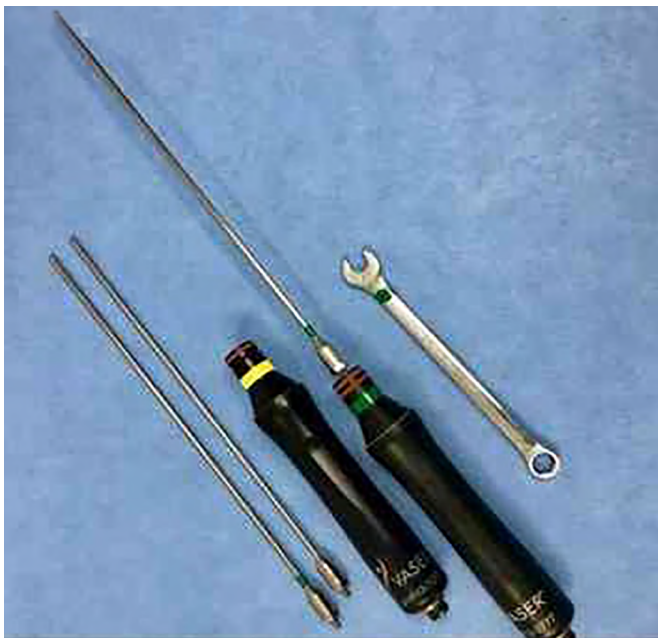

Figure 3. Handpiece with probes and a wrench. Source: The Author (2018)

**Cannulas**

Atraumatic cannula system for collecting emulsified tissues, with amplitudes and configurations for variable anatomical units<sup>6</sup> (Figure 4).

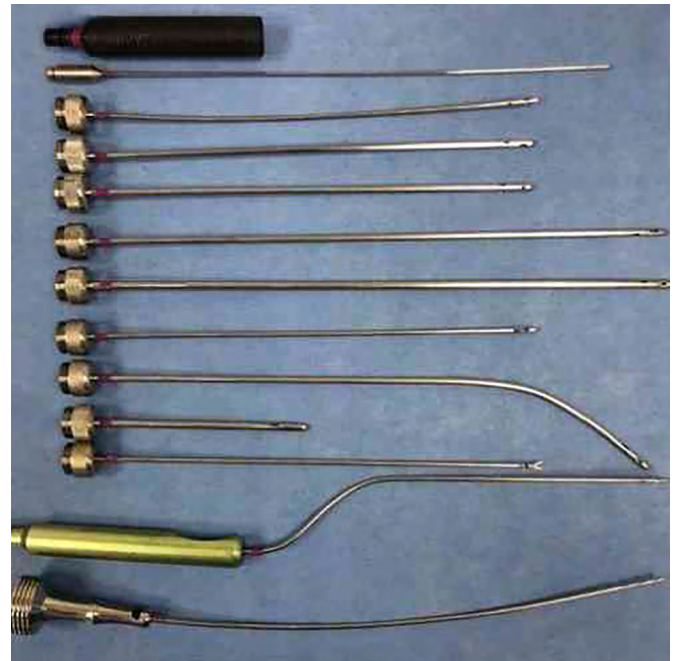


Figure 4. Set of Ventx™ cannulae, from top to bottom: Adaptation handle, 3.0 mm infiltration cannula, 3.0 mm liposuction cannulae, 3.7 mm, 4.6 mm short, 4.6 mm long, 5.0 mm basket cannula, 4.6 mm curved cannula, baby armpit cannula, 3.0 mm Toledo cannula, 3.0 mm lower limbs cannula and 4.0 mm cannula for fat grafting. Source: The Author (2018)

**Probes**

The equipment has probes of different diameters with grooves near the tip to transmit power. The larger the diameter of the probe, the greater the dissipated energy. Formatting for all anatomical units is available<sup>7</sup> (Figure 5).



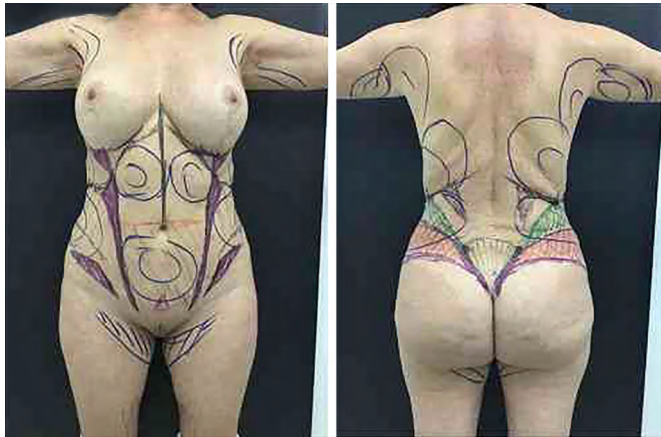
Figure 5. VASER™ ultrasonic probes. From left to right: 4.5 mm probe, 3.7 mm probe/2 rings, 3.7 mm probe/3 rings, arrow probe and 2.9 mm probe/3 rings and Saturn probe. Source: The Author (2018)

**Presurgical marking**

During the physical assessment, an analysis of the distribution of adipose tissue in different parts of the body is established. This includes documenting the thickness of the abdominal and trunk fat, as well as muscle mass.

We use routine VASER™ instead of a body contouring liposuction procedure as the surgical protocol indications are identical, with no exceptions.

We begin with the patient in the orthostatic position, and the first anatomical landmarks delimited are the areas in which the withdrawal of 100% of the lamellar layer of subcutaneous tissue is planned. Then, the rectus abdominis muscles, the anterosuperior iliac crests, and the inguinal ligaments are identified. The topography of the gluteus maximus muscles, the sacral concavity, and the transition between the upper and lower back following the lumbosacral fascia syncope are also delimited (Figure 6).



**Figure 6.** Blue: delimitation of deep extraction. Black: delimitation of strategic anatomical points. Lilac: transitional areas of superficial relief. Green: Region of total extraction of lamellar layer and partial extraction of areolar compartment. Red: alert area to avoid excessive resection. Source: The Author (2018)

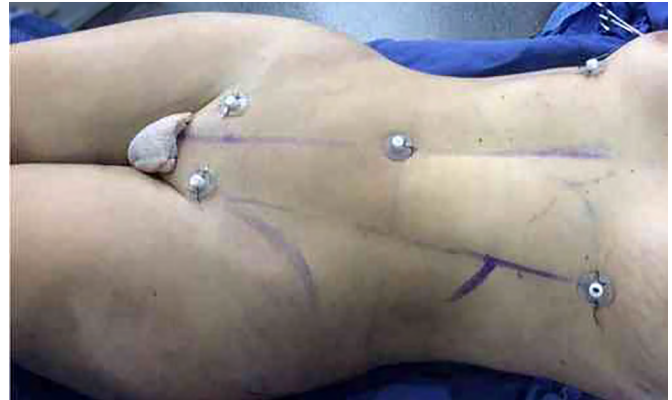### **Surgical technique**

The preparation of the patient in the surgical center begins with anesthesia; we prefer using general anesthesia. After that, a delayed bladder catheter, socks, and intermittent venous compression equipment for the lower limbs and body warming systems are prepared.

The surgery is standardized in three stages: infiltration, emulsification, and aspiration.

### **Positioning**

The patient is positioned in ventral decubitus with ample exposure of anatomical units and, after the end of this step, changed to dorsal decubitus. In both positions, strategic portals are placed in masking areas (back: intergluteal sulcus and in posterior axillary fold topography. Abdomen: in the pubic region, umbilical scar, inframammary topography, and anterior axillary topography). These accesses receive, after infiltration, protectors (skin ports) to slide the probes, avoiding adjacent thermal injuries (Figure 7).



**Figure 7.** Patient in dorsal decubitus with safety portals in the pubic area, the upper edge of navel and inframammary sulcus (prorings). Source: The Author (2018)

### **Infiltration**

The super humid infiltration technique is used for both superficial and deep regions. The routine volume used is 1:1 (infiltrate volume/aspirate volume), with a warm saline solution and epinephrine (1 ampoule for each 1000 mL saline). The solution is inserted through the previously made portals. The adjacent region needs to be kept moist during the surgical stages with a physiological solution to dissipate better the thermal energy generated by the device and friction.

### **Emulsification**

The introduction of the probes follows the working movement practiced in traditional liposuction, that is, back and forth movements, without force, feeling the device cross the tissues. This process begins with the lamellar layer and ends in the areolar compartment.

The recommended duration of VASER™, according to guidelines from the manufacturer, is approximately 1 minute for each 100 mL of infiltrated solution, to generate the feeling of a “loss of resistance”. Areas of higher fat content can be addressed with a larger diameter probe and with the appliance power up to 80% in continuous mode. In less thick areas, such as the waist, smaller probes, 2.9 mm, with 3 rings (greater lateral dispersion of energy) and the appliance power up to 60%, in pulsed mode, is recommended.

The superficial use of the VASER™ is performed with a 2.9 mm probe, 3 rings, and in pulsed mode. This step is responsible for the retraction of the skin, offsetting the areas of myofascial flaccidity, especially the hypogastrium. The duration of the emulsification stage in our routine is approximately 30–45 minutes in each decubitus (Table 3).



**Table 3.** VASER™ system probes.

Density	Volume	Probe	Model	Frequency
Smooth	Medium/Large	3.7 mm (3 grooves)	Continuous	70–80
Smooth	Small	2.9 mm (3 grooves) or 3.7 mm (2 grooves)	Pulsed or continuous	70–80
Slightly fibrous	Medium/Large	3.7 mm (2 grooves)	Continuous	80–90
Slightly fibrous	Small	2.9 mm (3 grooves) or 3.7 mm (1 groove)	Continuous	80–90
Very fibrous	Medium/Large	3.7 mm (2 grooves) or 3.7 mm (1 groove)	Continuous	80–90
Very fibrous	Small	2.9 mm (3 grooves)	Continuous	80–90

Length of probes

## LIPOSUCTION

### Lamellar layer

The aspiration of fat follows the conventional technique of tissue collection, that is, “fan-shaped” and with a “spread hand,” feeling the movement of the cannula. Tissue resistance is minimal, given that the density of the tissue is markedly decreased by emulsification. The cannulae used have a diameter of 3.0 mm, 3.7 mm, and 4.0 mm. The aspiration of the tissue is always initiated by the deep layer, with greater diameter cannulae (3.7 mm and 4.0 mm).

### Areolar layer

The superficial emulsification and liposuction are performed selectively on the edges of the muscle groups (alba line and inguinal ligament). Thinner cannulas are essential.

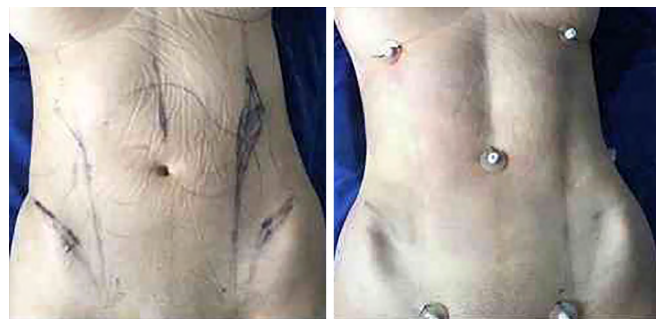
### Transition

This phase is used to ease the transition between the muscle groups and the sharp edges in the superficial liposuction, promoting the withdrawal of excess muscle fat, with an improvement of the definition of the anatomical landmarks superficially. The goal is the demarcation of the lateral edges of the muscle groups, with the maintenance of a pinch test of around 1 cm.

### Superficial subdermal liposuction

This consists of aspirating superficial subdermal fat through thin 3.0 mm and 2.0 mm cannulae. By reducing the fat just below the skin, it is possible to obtain effective skin retraction. The Ventrax system enables continuous negative pressure in the liposuction cannula. Consequently, the aggression of

the cannula when sliding through tissue, in particular to the subdermal plexus, does not damage it (Figure 8).



**Figure 8.** Example of liposuction with approaches of the various levels of lamellar fat anatomical relief, joint thinning of the subcutaneous cellular tissue in areas of tendon encounters and the adjacent anatomical transitions

After the end of the liposuction step, we introduce a continuous aspiration drain (PortoVac) in the lumbosacral and suprapubic regions.

### Postoperative management

Patients use a compressive modeling mesh and venous return pump throughout their hospital stay. On the second postoperative day, patients begin daily postoperative lymphatic drainage for at least 10 days.

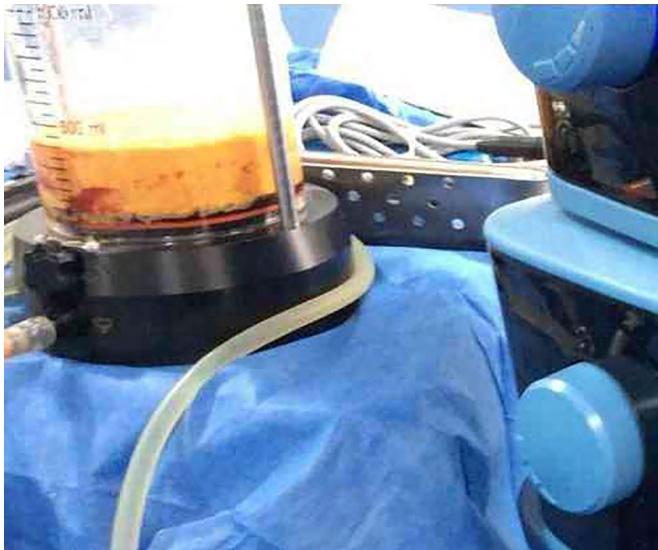
## RESULTS

In this retrospective study, we performed an analysis of the medical records of patients that underwent liposuction using the VASER™ system to assess the surgical complications found. We then compared our findings with the existing literature.

Our main goal was to evaluate the safety of the VASER™ device. Other data such as the volume infiltrated and aspirated solution, the mode of energy used (pulsed or continuous), and application time

were also collected. Some results will be mentioned in general terms.

The maximum volume did not exceed 4,000 mL in any patient. In all cases, the supernatant fat exceeded 80% of the total of the aspirate volume (Figure 9). In some cases, this index was above 93%.



**Figure 9.** Emulsified fat. In our sample, the supernatant fat exceeded 80% of the total lipoaspirated volume. Source: The Author (2018).

Among the patients analyzed in this study, 71 (93.42%) presented no complications related to postsurgical liposuction with the aid of the VASER™. Five cases (6.57%) presented complications (Table 4).

**Tabela 4.** Complications.

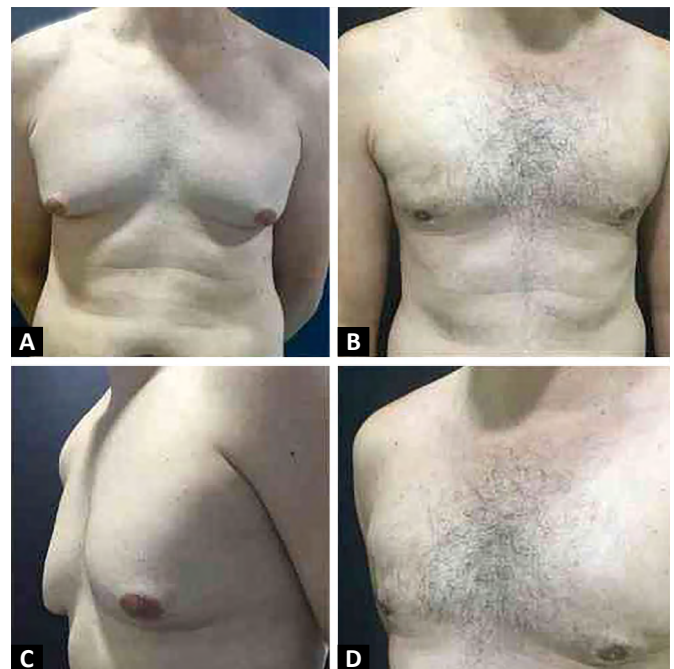
Complications	Number of patients	%
Prolonged edema	1	1.31
Thermal injury in insertion portal	1	1.31
Hyperpigmentation	2	2.67
Epidermal lesion	1	1.31
Cellulite	0	0.00
Anesthetic complications	0	0.00
Fibrosis	0	0.00
Changes in sensitivity	0	0.00
Seroma	0	0.00
Total	5	6.57

The hyperpigmentation and thermal injury events in the insertion portal occurred in the same patient. The remainder of the complications presented in different patients. The transmission of ultrasonic energy to the tissue can cause a lesion at the insertion portal site or terminal damage, according to the

excessive static maintenance of the probes<sup>9</sup>, or a wear to the skin port, as in our sample. Excision and suturing were performed.

The epidermal lesion also occurred in one flank after use of the VASER™. The patient presented progressive improvement with intensive care of the affected area. Dyschromia and hypo- or hyperpigmentation of the skin from using ultrasonic devices has been reported in the literature<sup>9,10</sup>. Hyperpigmentation may occur due to the release of hemosiderin and its deposit, causing alteration in color, or the use of modulators that improperly compress tissues, possibly associated with the pathophysiology of this complication<sup>11</sup>. The two patients affected recovered after compression relief.

There was no formation of seroma in our study. Only one case of prolonged edema (1.31%) occurred, which was resolved with intensive conservative therapy. We believe that the low rates found in our sample are due to the standardization of lymphatic drains and the systematic use of vacuum drains (Figure 10).



**Figure 10.** A and C. Preoperative photographs of a 38-year-old male with gynecomastia. B and D. Postoperative photographs 8 weeks after surgical treatment with VASER™ assisted ultrasonic liposuction. Infiltration of 300 mL of saline solution per side, with a 2.9 mm probe for 3 minutes and 7 seconds on the right and 3 minutes and 20 seconds on the left. 70% power was used in pulsed mode. Total volume aspirated of 520 mL (90% of emulsified fat tissue)

## DISCUSSION

In this study, 76 patients were submitted to ultrasonic liposuction assisted with VASER™ for the treatment of lipodystrophies. The results indicate that



the emulsification of subcutaneous tissue through the continuous and pulsed ultrasound mode was efficient and safe. The aspirated material contained more than 80% fat supernatant, reaching 93% in some cases. Blood losses were not relevant, considering that the characteristics of infranatant liquids aspirated were insignificant and, by association, no clinical management by depletion was performed. These findings are in agreement with the comparative study conducted by Garcia Junior and Nathan, in 2008<sup>12</sup>, which concluded that the use of third-generation ultrasonic devices leads to 20% less blood loss than other techniques<sup>12</sup>.

Jewell, Fodor, Pinto, and Al Shammari, in 2002<sup>8</sup>, reviewed the literature with a statistical analysis of the surgical complications related to liposuction. Ninety-three articles were selected, of which 14 were statistically evaluated. An average of 13.5% of unwanted events was observed in the studied literature. In our sample, we obtained 6.57% of postoperative complications, thus assuring the safety of this technology.

In 1998<sup>9</sup>, Rohrich et al. sought to evaluate the experience of using an ultrasonic liposuction device in with 114 consecutive patients. In their sample, five complications were observed: one case of dysesthesia, which the author believed to have been due to an excessively prolonged use of the device, three cases of abdominal seroma (with need for aspiration and compression) and one case of thermal lesions in the insertion portal of the cannula, likely due to an improper driving technique. The author emphasizes the need for maintenance of a damp environment and constant movement of the cannula. These are positive results when compared to traditional liposuction. The author relates the complications with the learning curve.

Dixit and Wagh, in 2013<sup>11</sup>, conducted a literary review on postoperative problems in liposuction, reporting a rate of 18.7% cutaneous hyperpigmentation in manipulated areas. They state that the leading cause of this is the inadequate approach of the areolar layer with consequent lesion of the subdermal plexus. In our study, we found 2.67% events of this nature. The low incidence of this complication is significant because, in at least 92.1% of the cases, the areolar layer was affected in one anatomical unit with fat emulsification and subsequent liposuction. The small amount of adverse events in superficial liposuction is the most important finding in terms of safety<sup>10</sup>. Since the technical foundations underlying conventional liposuction is the deep manipulation of fat tissue in a humid environment, a thickness of approximately 1 cm of

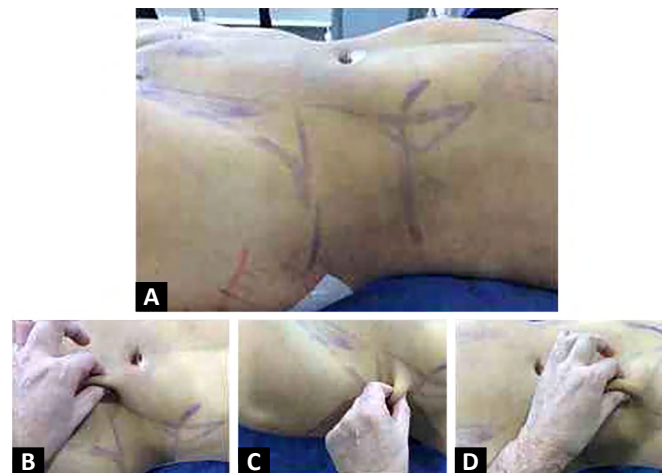
tissue is left to prevent contour irregularities and/or superficial devitalization<sup>3</sup>.

Nagy and Vanek Junior, in 2012<sup>13</sup>, performed a multicenter randomized study comparing traditional liposuction and the ultrasonic method on contralateral anatomical regions of the same patients, with female patients aged between 20 and 48 years old.

Increased tissue retraction occurred in 53% per cc aspirated when the VASER<sup>TM</sup> was used, which was statistically significant and clinically relevant<sup>14</sup>.

Based on these assumptions of higher skin retraction and manipulation of the areolar layer without tissue devitalization, it is possible to obtain greater muscle definition in patients with favorable physical characteristics<sup>6</sup>.

We agree with this premise despite having subjective contextualization. When performing techniques that aim for greater definition of compartments, ensuring safety using appropriate probes, selecting the correct pulsed or intermittent energy dispersion, and providing super humid superficial conditions, deep infiltration, and lamellar aspiration with subsequent areolar collection are essential<sup>6</sup> (Figure 11).



**Figure 11.** A. Photographs in the immediate postoperative period of a 32-year-old woman, after VASER<sup>TM</sup> assisted liposuction in the abdominal region, flanks, and dorsum with a deep approach to the entire circumference and superficial and deep manipulation in the muscle intersection areas. B, C, and D. Pinch test with different thicknesses according to the surgical plan

Hoyos and Millard, in 2007<sup>2</sup>, stated that VASER<sup>TM</sup> technology enables surgeons to perform superficial lipoplasty techniques efficaciously. The first- and second-generation ultrasonic devices were associated with severe burns and necroses when they dispersed their energy on the surface. These issues are not prevalent in the third-generation technology<sup>15,16,17,18</sup>, which can be seen in our study.

## CONCLUSION

The existing literature, as well as our analysis, shows that VASER™ liposuction procedures can improve body contour safely, with low complication rates.

The potential complications from ultrasonic devices, such as tissue ischemia or necrosis, can be mostly attributed to the device being used inappropriately. It is of fundamental importance to standardize care concerning the insertion portals and to ensure an adequate amount of infiltrating solution is used as well as that the device is applied for the appropriate amount of time and areas.

Therefore VASER™ is a potential tool that is safe for surgeons to use in body contouring procedures.

\*Felipe Massignan and the other authors did not receive any financial compensation or benefits from the company responsible for the device mentioned in this article.

## COLLABORATIONS

**FM** Analysis and/or data interpretation, Conception and design study, Conceptualization, Data Curation, Formal Analysis, Investigation, Methodology, Project Administration, Realization of operations and/or trials, Resources, Supervision, Validation, Visualization, Writing - Original Draft Preparation, Writing - Review & Editing

## REFERENCES

- Fodor PB, Cimino WW, Watson JP, Tahernia A. Suction-assisted lipoplasty: physics, optimization, and clinical verification. *Aesthetic Surg J*. 2005 May;25(3):234-246.
- Hoyos AE, Millard JA. VASER-assisted high-definition liposculpture. *Aesthetic Surg J*. 2007 Nov/Dec;27(6):594-604.
- Markman B, Barton Junior FE. Anatomy of the subcutaneous tissue of the trunk and lower extremity. *Plast Reconstr Surg*. 1987 Aug;80(2):248-254.
- Zocchi ML. Ultrasound-assisted lipoplasty. *Adv Plast Reconstr Surg*. 1995;11:197-221.
- Scuderi N, Paolini G, Grippaudo FR, Tenna S. Comparative evaluation of traditional, ultrasonic, and pneumatic assisted lipoplasty: analysis of local and systemic effects, efficacy, and costs of the methods. *Aesthetic Plast Surg*. 2000 Nov/Dec;24(6):395-400.
- Hoyos AE. High definition liposculpture. Presented in the XIII International Course of Plastic Surgery. Bucaramanga, Colombia; 2003.
- Cimino WW. Ultrasonic surgery: power quantification and efficiency optimization. *Aesthetic Surg J*. 2001 May;21(3):233-41.
- Jewell ML, Fodor PB, Pinto EBS, Al Shammari MA. Clinical application of VASER-assisted lipoplasty: a pilot clinical study. *Aesthetic Surg J*. 2002 Mar;22(2):131-46.
- Rohrich RJ, Beran SJ, Kenkel JM, Adams Junior WP Jr, DiSpaltro F. Extending the role of liposuction in body contouring with ultrasound-assisted liposuction. *Plast Reconstr Surg*. 1998 Apr;101(4):1090-102;discussion:1117-9.
- Rocha RP, Rocha ELP, Pinto EBS, Sementilli A, Nakanishi CP. Cutis marmorata resemblance after liposuction. *Aesthetic Plast Surg*. 2005 Jul/Aug;29(4):310-2.
- Dixit VV, Wagh MS. Unfavorable outcomes of liposuction and their management. *Indian J Plastic Surg*. 2013 May/Aug;46(2):377-92.
- Garcia Junior O, Nathan N. Comparative analysis of blood loss in suction-assisted lipoplasty and third-generation internal ultrasound-assisted lipoplasty. *Aesthetic Surg J*. 2008 Jul/Aug;28(4):430-5.
- Nagy MW, Vanek Junior PF. A multicenter, prospective, randomized, single-blind, controlled clinical trial comparing VASER-assisted Lipoplasty and suction-assisted Lipoplasty. *Plast Reconstr Surg*. 2012 Apr;129(4):681-9e.
- Rocha RP, Pinto EBS, Cardoso RA, Nardino EP, Rodrigues L, Tonetti RL. Morphological aspects of dorsum and sacrum skin as related to liposuction. *Aesthetic Surg J*. 2000 May/Jun;24(3):171-8.
- Zucowski ML, Ash K. Ultrasound-assisted lipoplasty learning curve. *Aesthetic Surg J*. 1998 Mar;18(2):104-10.
- Troilius C. Ultrasound-assisted lipoplasty: is it really safe?. *Aesthetic Plast Surg*. 1999;23:307-311.
- Schefflan M, Tazi H. Ultrasonically assisted body contouring. *Aesthetic Surg J*. 1996 Jun;16(2):117-122.
- Grolleau JL, Rougé D, Chavoin JP, Costagliola M. Severe cutaneous necrosis after ultrasound lipolysis. Medicolegal aspects and review. *Ann Chir Plast Esthet*. 1997;42(1):31-36. 29. Hoyos AE. High Definition liposculpture. Presented in the XIII International Course of Plastic Surgery, Bucaramanga, Colombia, 2003. – é igual a ref. n. 6
- Hoyos AE. High Definition liposculpture. Presented in the XIII International Course of Plastic Surgery, Bucaramanga, Colombia, 2003. – é igual a ref. n. 6
- Hoyos AE, Millard JA. VASER-Assisted High-Definition Liposculpture. *Aesthetic Surg J*. 2007;27:594-604. – é igual a ref. n. 2
- Zucowski ML, Ash K. Ultrasound-assisted lipoplasty learning curve. *Aesthetic Surg J*. 1998 Mar;18(2):104-10.
- Troilius C. Ultrasound-assisted lipoplasty: is it really safe?. *Aesthetic Plast Surg*. 1999;23:307-311.
- Schefflan M, Tazi H. Ultrasonically assisted body contouring. *Aesthetic Surg J*. 1996 Jun;16(2):117-122.
- Grolleau JL, Rougé D, Chavoin JP, Costagliola M. Severe cutaneous necrosis after ultrasound lipolysis. Medicolegal aspects and review. *Ann Chir Plast Esthet*. 1997;42(1):31-36.

\*Corresponding author:

**Felipe Massignan**

Rua Itália, 878, Sala 105, Espírito Santo, Erechim, RS, Brazil.

Zip code: 99711-010

E-mail: felipemassignan@me.com