

EARLY-AGE ORTHODONTIC TREATMENT

Aliakbar Bahreman, DDS, MS

Clinical Professor
Orthodontic and Pediatric Dentistry Programs
Eastman Institute for Oral Health
University of Rochester
Rochester, New York



Quintessence Publishing Co, Inc

Chicago, Berlin, Tokyo, London, Paris, Milan, Barcelona, Beijing,
Istanbul, Moscow, New Delhi, Prague, São Paulo, Seoul, Singapore,
and Warsaw

Contents

Foreword by <i>J. Daniel Subtelny</i>	<i>vii</i>
Preface and Acknowledgments	<i>viii–ix</i>
Introduction	<i>x</i>

Part I Clinical and Biologic Principles of Early-Age Orthodontic Treatment 1

- 1** Rationale for Early-Age Orthodontic Treatment 3
- 2** Development of the Dentition and Dental Occlusion 15
- 3** Examination, Early Detection, and Treatment Planning 41

Part II Early-Age Orthodontic Treatment of Nonskeletal Problems 71

- 4** Space Management in the Transitional Dentition 73
- 5** Management of Incisor Crowding 105
- 6** Management of Deleterious Oral Habits 131
- 7** Orthodontic Management of Hypodontia 157
- 8** Orthodontic Management of Supernumerary Teeth 189
- 9** Diagnosis and Management of Abnormal Frenum Attachments 205
- 10** Early Detection and Treatment of Eruption Problems 225

Part III Early-Age Orthodontic Treatment of Dentoskeletal Problems 291

- 11** Management of Sagittal Problems
(Class II and Class III Malocclusions) 293
- 12** Management of Transverse Problems
(Posterior Crossbites) 355
- 13** Management of Vertical Problems
(Open Bites and Deep Bites) 377

Index 417

Foreword

This book is a compendium of significant and pertinent information related to early-age orthodontic treatment, a subject that seems to have evolved into one of considerable controversy, with as many orthodontists expressing a negative reaction as a positive reaction to its benefits. Dr Bahreman is a believer in early-age orthodontic treatment, and he expresses some cogent arguments founded in years of experience in practice and teaching to back up his beliefs. In developing his treatise, Dr Bahreman outlines the development of the occlusion and/or malocclusion from the embryonic stages, when the foundation of the jaws and thereby the position of the dentition is first established.

Early-age orthodontics is not about the time it takes to orthodontically treat a problem; it is a story of growth, of variation in anatomy, and of muscle function and influences, a realization that it is the jaws that contain the teeth and that where the jaws go, the teeth will have to go, and

both undergo varying influences as well as grow in varying directions. Early-age orthodontics necessitates recognition of this process and aims to alter and redirect it whenever feasible and possible. Dr Bahreman has undertaken a monumental effort in directing efforts along this path. An extensive exploration of the literature is an added bonus, as the mechanical approaches are based on this literature. In fact, the extensive review of the literature and its application to diagnosis and varying forms of therapy are worth a veritable fortune.

You may or may not agree with the basic premises, but you will have access to important information that will widen your scope of vision and thereby widen your treatment horizons. To my mind, an ounce of prevention, if possible, is worth a pound of cure. The reality of prevention can exist at the earliest stages of development.



J. Daniel Subtelny, DDS, MS, DDS(Hon)

Professor Emeritus
Interim Chair and Director of Orthodontic Program
Eastman Institute for Oral Health
University of Rochester
Rochester, New York

Preface

After obtaining a master's degree in orthodontics in 1967, I began my career at a newly founded dental school in Tehran. My responsibilities included teaching and administrative duties at the university and maintenance of a very busy private practice. In addition, I established both the orthodontic and pediatric dentistry departments at the university.

Many patients were being referred to the orthodontic department, and there were no qualified faculty members to help me provide care. To rectify the situation, I designed an advanced level, comprehensive curriculum in orthodontics for undergraduate students, including classroom instruction, laboratory research, and clinical demonstrations. Once the students completed the course, they could work in the clinic, thus temporarily solving the issue of the heavy patient load in the orthodontic clinic. With additional staff now available, I could select patients, mostly children in the primary or mixed dentition, for some interceptive treatment.

Despite my difficulties in performing all of the aforementioned duties, this situation had a fortunate outcome. It helped me to understand and discover the advantages of early-age orthodontic treatment, which was not common in those years. During my more than 40 years of practice and teaching, especially in early orthodontic treatment, I have accumulated a considerable amount of educational data for teaching purposes. I would like to share this experience and information with readers.

The public's growing awareness of and desire for dental services, especially at an early age, have encouraged our profession to treat children earlier. Despite the recommendation by the American Association of Orthodontists that orthodontic screening begin by the time a child is 7 years old, many orthodontists still do not treat children prior to the complete eruption of the permanent teeth. I believe that this inconsistency is due to the educational background of orthodontists as well as a lack of familiarity with recent technical advancements and the various treatment options that are available for young patients.

The therapeutic devices available for this endeavor are not complex, but deciding which ones to use and when to employ them are important steps. As we make these decisions, we should also remember not to treat the symptom but rather to treat the cause. My goal is to present the basic information necessary to understand the problems, to differentiate among various conditions, and to review different treatment options. Case reports are examined to facilitate clinical application of the theory in a rational way.

To understand the morphogenesis of nonskeletal and skeletal occlusal problems, to detect problems early, and to intervene properly, we must look at all areas of occlusal development, including prenatal, neonatal, and postnatal changes of the dentoskeletal system, and explore all genetic and environmental factors that can affect occlusion at different stages of development. In other words, we must have a profound understanding of the fundamental basis and morphogenesis of each problem and then apply this knowledge to clinical practice. Thus, the goals of this book are:

- To provide a comprehensive overview of all areas of dental development, from tooth formation to permanent occlusion, to refresh the reader's memory of the fundamentals necessary for diagnosis and treatment planning.
- To emphasize all the important points of the developmental stages that must be recognized during examination of the patient to facilitate differential diagnosis. Each tooth can become anomalous in a number of ways and to different degrees. Occlusion and maxillomandibular relationships can vary in the sagittal, transverse, and vertical directions.
- To discuss the application of basic knowledge to practice by presenting several cases with different problems and different treatment options.
- To demonstrate the benefits of early-age orthodontic treatment, achieved by intervention in developing malocclusion and guidance of eruption.

Materials are presented in three parts: In Part I, "Clinical and Biologic Principles of Early-Age Orthodontic Treatment," three chapters introduce and explain the concept of early-age treatment, describe its necessity and advantages, and discuss the controversies surrounding this topic; discuss the basic foundation of occlusal development, empowering the practitioner to detect anomalies and intervene as necessary; and illustrate the procedures, tools, and techniques available for diagnosis, emphasizing differential diagnosis and treatment planning for early-age treatment.

Part II, "Early-Age Orthodontic Treatment of Nonskeletal Problems," consists of seven chapters describing the nonskeletal problems that might develop during the primary and mixed dentitions. The chapters explain the ontogeny, diagnosis, and early detection of, and intervention for, these problems. Topics include space management, crowding, abnormal oral habits, abnormal frenum attachment, hypodontia, supernumerary teeth, and abnormal eruption problems.

Part III, “Early-Age Orthodontic Treatment of Dentoskeletal Problems,” consists of three chapters on early intervention for the dentoskeletal problems that might arise during the primary and mixed dentitions in the three dimensions: sagittal problems (anterior crossbite and Class II and Class III malocclusions); transverse problems (posterior crossbites); and vertical problems (open bites and deep bites).

This book will provide the reader with a firm foundation of the basic science and case examples with various treatment options. It is my hope that the information provided will promote a better understanding of abnormalities and their causes and enable readers to recognize the clues for early detection and intervention.

Acknowledgments

First and foremost, I would like to gratefully acknowledge the valuable opportunity that was afforded me as a student in Dr Daniel Subtelny’s orthodontic program. Between 1964 and 1967, I completed both my orthodontic specialty and master degree programs with Dr Subtelny as my mentor. As chairman and program director, researcher, and mentor, Dr Subtelny has dedicated over 57 years of his life to teaching, personally influencing the lives of over 350 students from around the world, myself included. In 1999, after over 32 years of teaching, practicing, and administrating in Tehran, I was fortunate enough to return to the Eastman Institute for Oral Health to work alongside Dr Subtelny as a faculty member in the Orthodontic and Pediatric Dentistry Programs.

In addition to Dr Subtelny, there are several individuals to whom I would like to express my deep gratitude for their help and encouragement in preparation of this book: the late Dr Estepan Alexanian, head of the Department of Histology at the Shahid Beheshti University Dental School in

Tehran, whose dedication as an educator and preparation of superb histologic slides is remarkable and who allowed me to use his slides in my publication; Mr Aryan Salimi for scanning some of the slides and radiographs in this book; and Ms Elizabeth Kettle, Program Chair of the Dental Section of the Medical Library Association, head of Eastman’s library, for her sincere help in editing this publication.

Finally, I wish to acknowledge the constant support of my family: Malahat, Nasreen, Saeid, Alireza, Tannaz, and Peymann Motevalei. Especially high gratitude goes to my wife, Malahat, for her tolerance, support, and encouragements. I also want to thank my son Alireza for his technical help and guidance in computer skills and my granddaughter Tannaz Motevalei for drawing some of the illustrations.

This publication is the product of 17 years spent organizing materials derived from my 45 years of practice and teaching as well as reviewing hundreds of articles and books. I herewith dedicate this book to the teachers, practitioners, residents, and students who are dedicated to treating malocclusion earlier in children, before it becomes more complicated and costly.

Introduction

Occlusal development is a long process starting around the sixth week of intrauterine life and concluding around the age of 20 years. This long developmental process is a sequence of events that occur in an orderly and timely fashion under the control of genetic and environmental factors. Dental occlusion is an integral part of craniofacial structure and coordination of skeletal growth changes. Occlusal development is essential for establishing a normal and harmonious arrangement of the occlusal system.

As we learn about craniofacial growth changes, the potential influences of function on the developing dentition, and the relationships of basal jawbones and head structure, we acquire a better understanding of when and how to intervene in the treatment guidance for each patient. It is more effective to intervene during the primary or mixed dentition period to reduce or, in some instances, avoid the need for multibanded mechanotherapy at a later age.

Untreated malocclusions can result in a variety of problems, including susceptibility to dental caries, periodontal disease, bone loss, temporomandibular disorders, and undesirable craniofacial growth changes. Moreover, the child's appearance may be harmed, which can be a social handicap. The benefits of improving a child's appearance at an early age should not be undervalued. The goals of many clinicians who provide early treatment are not only to reduce the time and complexity of comprehensive fixed appliance therapy but also to eliminate or reduce the damage to the dentition and supporting structures that can result from tooth irregularity at a later age. In short, early intervention of skeletal and dental malocclusions during the primary and mixed dentition stages can enable the greatest possible control over growth changes and occlusal development, improving the function, esthetics, and psychologic well-being of children.

For many decades, orthodontists have debated about the best age for children to start orthodontic treatment. While we agree on the results of high-quality orthodontic treatment, we often differ in our opinions as to how and when to treat the patient. Some practitioners contend that starting treatment in the primary dentition is the most effective means of orthodontic care. Others prefer to begin the treatment in the mixed dentition. There is also controversy about whether the early, middle, or late mixed dentition is preferable.

Despite the fact that the American Association of Orthodontists recommends that orthodontic screening be started by the age of 7 years, many orthodontists do not treat children prior to the eruption of permanent teeth, and some postpone the treatment until the full permanent dentition

has erupted, at approximately 12 years. The controversy surrounding early versus late treatment is often confusing to the dental community; therefore, clinicians must decide on a case-by-case basis when to provide orthodontic treatment. Indeed, there are occasions when delaying treatment until a later age may be advisable.

The long-term benefits of early treatment are also controversial. The majority of debates seem to revolve around early or late treatment of Class II malocclusions. There is less controversy regarding many other services that can be performed for the benefit of young patients during the primary or mixed dentition, such as treatment of anterior and posterior crossbite, habit control, elimination of crowding, space management, and management of eruption problems.

Practitioners who are in favor of early treatment of Class II problems contend that early intervention is the best choice for growth modification when the problem is skeletal and especially when it results from mandibular retrusion. On the other hand, opponents believe that there is no difference in the final result and that a single-phase treatment approach is preferable because of the advantages that accompany the reduced treatment time.

Unfortunately, some practitioners, without a profound evaluation of the indications for early treatment, conclude that late treatment is always preferable. However, broad conclusions drawn from narrowly focused research can be misleading. One cannot conclude that no birds can fly by considering the flight characteristics of the ostrich.

To evaluate and demonstrate the benefits of early treatment, I aim to discuss and clarify available treatments and services and discuss cases with different problems and different treatment options. An understanding of all aspects of early treatment requires a thorough knowledge of the basics of embryology, physiology, and growth and development. This includes development of the dentition, tooth formation, eruption, exfoliation, and all transitional changes. Therefore, my other goal is to integrate the basic science and the clinical, in order to refresh the reader's memory on important points about the bases of nonskeletal and skeletal problems that can arise during the transitional stages of occlusion.

Each patient who enters our practice represents a new chapter and a new lesson that we can learn from. A thorough knowledge of the basis for early-age orthodontic treatment, an understanding of the proper treatment techniques, and a willingness to consider their appropriateness for each individual patient will allow us to intervene in ways that will provide the maximum benefit for a young and growing child.



PART

I

CLINICAL AND
BIOLOGIC PRINCIPLES
OF EARLY-AGE
ORTHODONTIC
TREATMENT

1

Rationale for Early-Age Orthodontic Treatment

In the past, orthodontic treatment has been focused mainly on juvenile and adult treatment. Treatment options for patients in these age groups often are limited by complex dental and orthodontic problems and the lack of sufficient future cranio-facial growth.

During the later part of the 18th century, orthodontic treatment of Class II malocclusion was limited primarily to retraction of the maxillary anterior teeth to decrease excessive overjet. In 1880, Norman Kingsley¹ published a description of techniques for addressing protrusion. He was among the first to use extraoral force to retract the maxillary anterior teeth after extraction of the maxillary first premolars; the extraoral force was applied with headgear. Later, Case² continued to refine these methods.

Angle's classification³ of malocclusion, published in the 1890s, provided a simple definition of normal occlusion and was an important step in the development of orthodontic treatment. Angle opposed the extraction of teeth and favored the preservation of the full dentition. His position against tooth extraction led him to depend on extraoral force for the expansion of crowded dental arches and retraction of the anterior segment. Later he discontinued the use of extraoral force and advocated the use of intraoral elastics to treat sagittal jaw discrepancies.

Because of Angle's dominating belief that treatment with Class II elastics was just as effective as extraoral force, the use of headgear was abandoned by the 1920s. Then, in 1936, Oppenheim⁴ reintroduced the concept of extraoral anchorage, employing extraoral traction to treat maxillary protrusion. Accepting the position of the mandible in Class II malocclusions, Oppenheim attempted to move the maxillary dentition distally by employing a combination of occipital anchorage and an E-arch, allowing the mandible to continue its growth. This resulted in an improved relationship with the opposing jaw. In 1947, Silas Kloehn⁵ reintroduced extraoral force, in the form of cervical headgear, for the treatment of skeletal Class II relationships.

In 1944, another student of Angle's, Charles Tweed,⁶ was discouraged by the prevalence of relapse in many of his patients treated without extraction, so he decided to oppose the conventional wisdom of nonextraction.

In the early part of the 20th century, there was optimism about the influence of orthopedic force on skeletal growth. An almost universal belief was that orthodontic forces, if applied to the growing face, could alter the morphologic outcome. In the United States, headgear was the principal appliance used for facial orthopedic treatment, whereas in Europe the functional appliance was predominantly used.

In 1941, Alan Brodie,⁷ one of Angle's students, concluded that the growing face could not be significantly altered from its genetically predetermined form and that the only option for the orthodontist in cases of skeletal malocclusion would be dental camouflage, or the movement of teeth within their jaws. This idea led to tooth extraction.

Panoramic radiographs

The panoramic radiograph is a common diagnostic tool in today's dental practice. It is a kind of radiograph that provides a full picture of the dentition and the complete maxilla and mandible.

Panoramic radiographs do not show the fine detail captured on intraoral radiographs and are not as specific as other intraoral radiographs, but in a single radiograph it provides a useful general view of all dentition, the maxilla and mandible, the sinuses, and both TMJs. This type of radiograph is very useful, especially during the mixed dentition, for early detection and prevention of all problems disturbing the normal development of occlusion.

Especially during the mixed dentition as a diagnostic tool for early-age orthodontic treatment, the following are important aspects that should be carefully evaluated on a panoramic radiograph before any orthodontic treatment:

- Position and pattern of fully emerged as well as emerging permanent teeth
- Sequence of permanent tooth eruption
- Asymmetric eruption
- Comparison of crown height levels on the left and right sides
- Obstacles preventing eruption
- Abnormal tooth malformations (gemination, fusion, dens in dente, or dilaceration)
- Exfoliation and pattern of primary teeth root resorption
- Tooth number and supernumerary teeth or congenitally missing teeth
- Eruption problems, such as impaction, ectopic, transposition, or ankylosis
- Bone density and trabeculation
- Cysts, odontomas, tumors, and other bone defects or pathologic lesions
- Third and second molar positions, inclinations, and relationships to the first molars and ramus edge
- Shape of the condylar head and ramus height
- Comparison of the left and right condylar heads and rami

The characteristics and management of these problems are discussed in their related chapters in part 2 of this book. Chapter 10 introduces a simple and practical technique for application of panoramic radiographs to assess canine impaction.

Longitudinal Panoramic Radiograph Monitoring

Over many years of teaching and practice, in both pediatric dentistry and orthodontic departments, the author became interested in conducting a retrospective evaluation of patients who were referred for some type of orthodontic problem and who had previous panoramic radiographs available. This retrospective evaluation led to the conclusion that the longitudinal monitoring of panoramic radiographs during the mixed dentition is a very valuable, easy technique that enables detection of developmental anomalies during the transitional dentition. Today the author strongly recommends this easy and very useful technique to all practitioners, especially pediatric dentists and orthodontists.

The transitional dentition is one of the most critical stages of the dentition, and many eruption problems, whether hereditary or environmental, emerge during this stage. Longitudinal panoramic radiograph monitoring is a careful serial monitoring technique that any practitioner can perform for young patients during transitional dentition to watch for developmental anomalies that may arise at these ages.

The technique the author recommends is to take one panoramic radiograph when the patient is around the age of 6 years (during the eruption of the permanent first molar) and then two more panoramic radiographs at 8 and 10 years of age. Careful comparison of two or three consecutive radiographs of a patient at this stage of the dentition can easily reveal any abnormal developmental processes emerging between radiographs and therefore can enable early detection and intervention. The following three cases illustrate the advantages of longitudinal monitoring of panoramic radiographs and proper intervention.

Case 3-1

This case confirms the importance of longitudinal radiographic evaluation, indicating how early intervention could have helped this little girl. Figures 3-23a to 3-23c are three consecutive radiographs found in her record. A periapical radiograph reveals the first sign of a problem, that is, asymmetric eruption of the central incisors at age 7 years. A panoramic radiograph taken about 15 months later shows the eruption of both central incisors and the asymmetric position of the lateral incisors. A third radiograph, a panoramic radiograph taken about 7 months later, reveals that the left lateral incisor had erupted while the right lateral incisor remained unerupted.

The important, detectable abnormal sign in this radiograph is the abnormal position of the maxillary permanent right canine in relation to the unerupted lateral incisor; unfortunately, no intervention was performed at this point, and the patient did not return until 3 years later. Figures 3-23d and 3-23e present the last panoramic and occlusal views, showing the complete resorption of the permanent lateral incisor root.

Possible intervention:

Assessment of the available serial radiographs indicates that the best treatment option was early intervention and extraction of the maxillary primary right canine when the first (see Fig 3-23b), or even the second (see Fig 3-23c), panoramic radiograph was taken. Extraction of the maxillary primary right canine would have facilitated and accelerated eruption of the permanent lateral incisor, moving this tooth away from the canine forces and preventing root resorption (see Figs 3-23d and 3-23e).

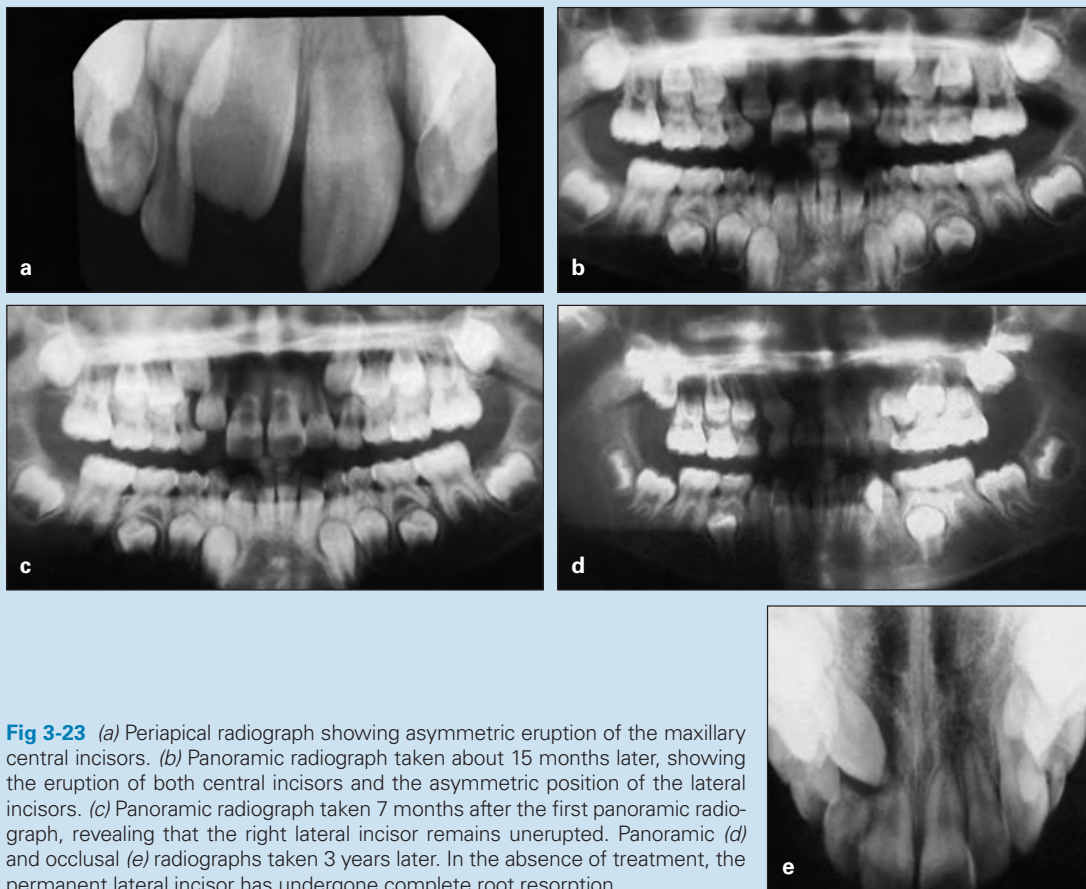

Fig 3-23 (a) Periapical radiograph showing asymmetric eruption of the maxillary central incisors. (b) Panoramic radiograph taken about 15 months later, showing the eruption of both central incisors and the asymmetric position of the lateral incisors. (c) Panoramic radiograph taken 7 months after the first panoramic radiograph, revealing that the right lateral incisor remains unerupted. Panoramic (d) and occlusal (e) radiographs taken 3 years later. In the absence of treatment, the permanent lateral incisor has undergone complete root resorption.



Fig 4-17 Fixed unilateral sliding loop space regainer.

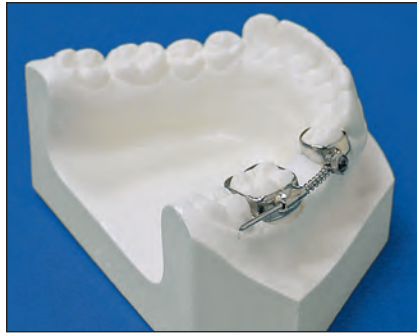

Fig 4-18 Gurin lock space regainer.

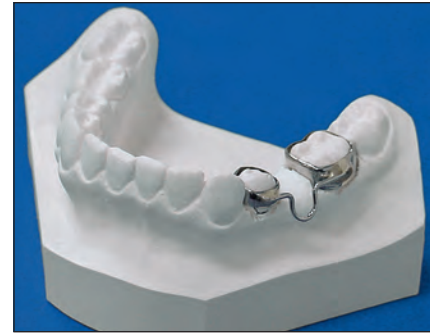

Fig 4-19 Band and U-loop space regainer. (Courtesy of Great Lakes Orthodontics.)

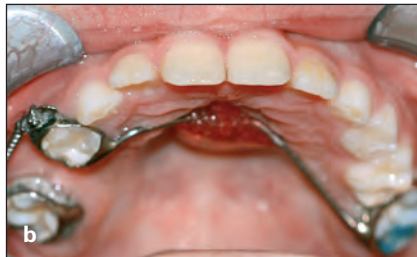
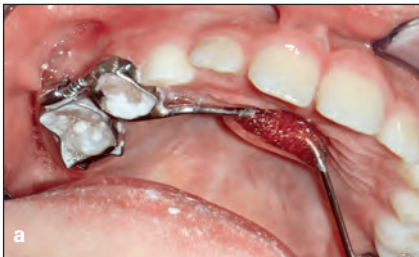
Fig 4-20 Molar distalizer with Nance anchorage. (a) Space loss at the time of appliance placement. (b) Space regained at the end of treatment.

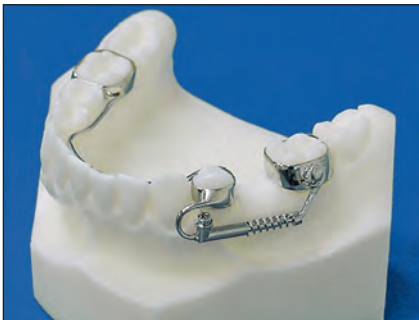

Fig 4-21 Mandibular molar distalizer. (Courtesy of Great Lakes Orthodontics.)




Fig 4-22 Pendulum distalizer with spring activation on the right molar. The distalizer in this image also includes a screw for expansion.

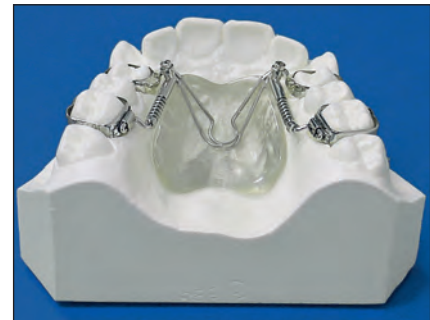

Fig 4-23 Distal jet appliance for molar distalization. (Courtesy of Great Lakes Orthodontics.)

This type of unilateral regainer is recommended in cases where the force is to be directed only to the molar in the maxillary dentition.

Sliding loop and lingual arch. This appliance is designed similarly to the sliding loop regainer, but it includes a lingual holding arch connected to the opposite molar band to provide anchorage and prevent adverse effects on the anterior component (Fig 4-21).

Pendulum appliance (molar distalizer). The pendulum appliance is a fixed bilateral or unilateral molar distalizer. It is designed with two bands cemented to the primary first molars or the premolars and an acrylic resin button touching the palate to provide good anchorage. One end of a β -titanium spring is embedded in acrylic and the other end

is inserted in the palatal tube, making the spring removable (Fig 4-22). The appliance can be activated at each appointment. This type of distalizer is indicated for the permanent dentition, in cases of space loss or Class II molar correction.

Distal jet appliance. The distal jet appliance is also a fixed unilateral or bilateral distalizer with an acrylic resin button for anchorage. Bands are cemented to the anterior abutment, and two bars with open coil spring slide to embedded tubes for activation. The bars connected to the molar palatal tube can be removed, and the push coil can be reactivated (Fig 4-23).

2 × 4 bonding. Molar distalization and space regaining can be achieved as a part of 2 × 4 bonding in patients who need

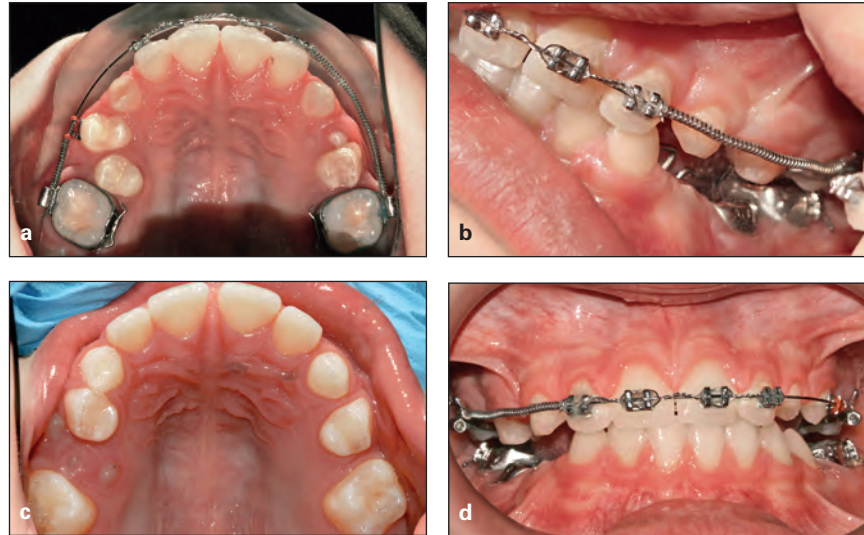


Fig 4-24 (a to d) Push coil and 2 × 4 bonding to regain space for the maxillary second premolars.

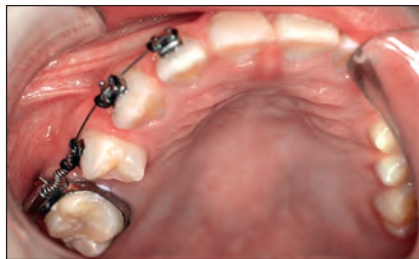

Fig 4-25 Sectional bracketing to open space for the maxillary right premolar.

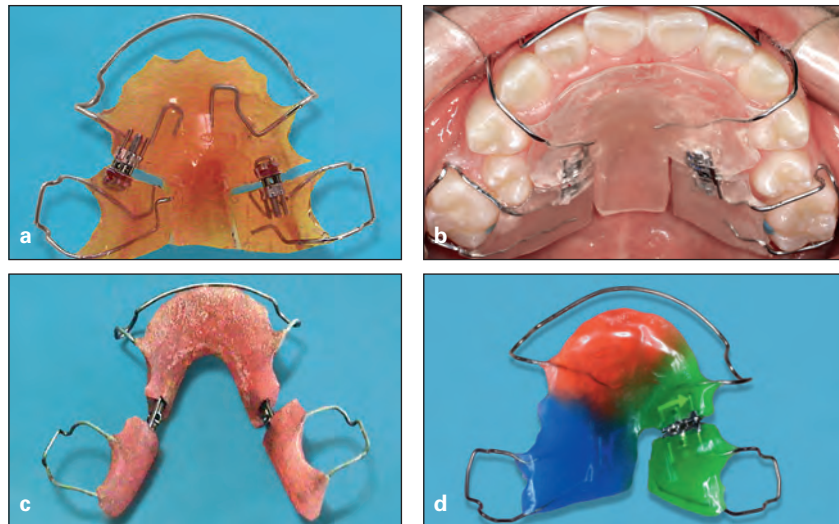


Fig 4-26 Hawley removable space retainers with jackscrews. (a and b) Bilateral removable retainers for the maxilla. (c) Bilateral removable retainer for the mandible. (d) Unilateral removable retainer for the maxilla.

incisor alignment (such as space closure, crossbite correction, or midline shift) during the early or middle mixed dentition. A light force can be applied to molars by a push coil inserted between lased incisors and the permanent molar tube (Fig 4-24).

Sectional bracketing. In patients with normal occlusion and space loss in one quadrant, minor tooth movement and space regaining can be achieved by sectional bracketing. Figure 4-25 shows a patient with a good Class I mandibular and maxillary left dentition. The problem is space loss at the maxillary right second premolar site that has resulted from mesial tipping of the molar and distal tipping of the first pre-

molar. Sectional bracketing of this segment, leveling with a sectional archwire, and placement of a push coil between the tipped molar and premolar can open space and upright the adjacent teeth.

Removable space retainers

Removable appliances can also be used for space regaining as well as space maintenance. This can be accomplished by incorporating different springs or screws in the appliance, either unilaterally or bilaterally. A Hawley appliance with different modifications is a simple, effective appliance that can be used for all of these purposes (Fig 4-26).

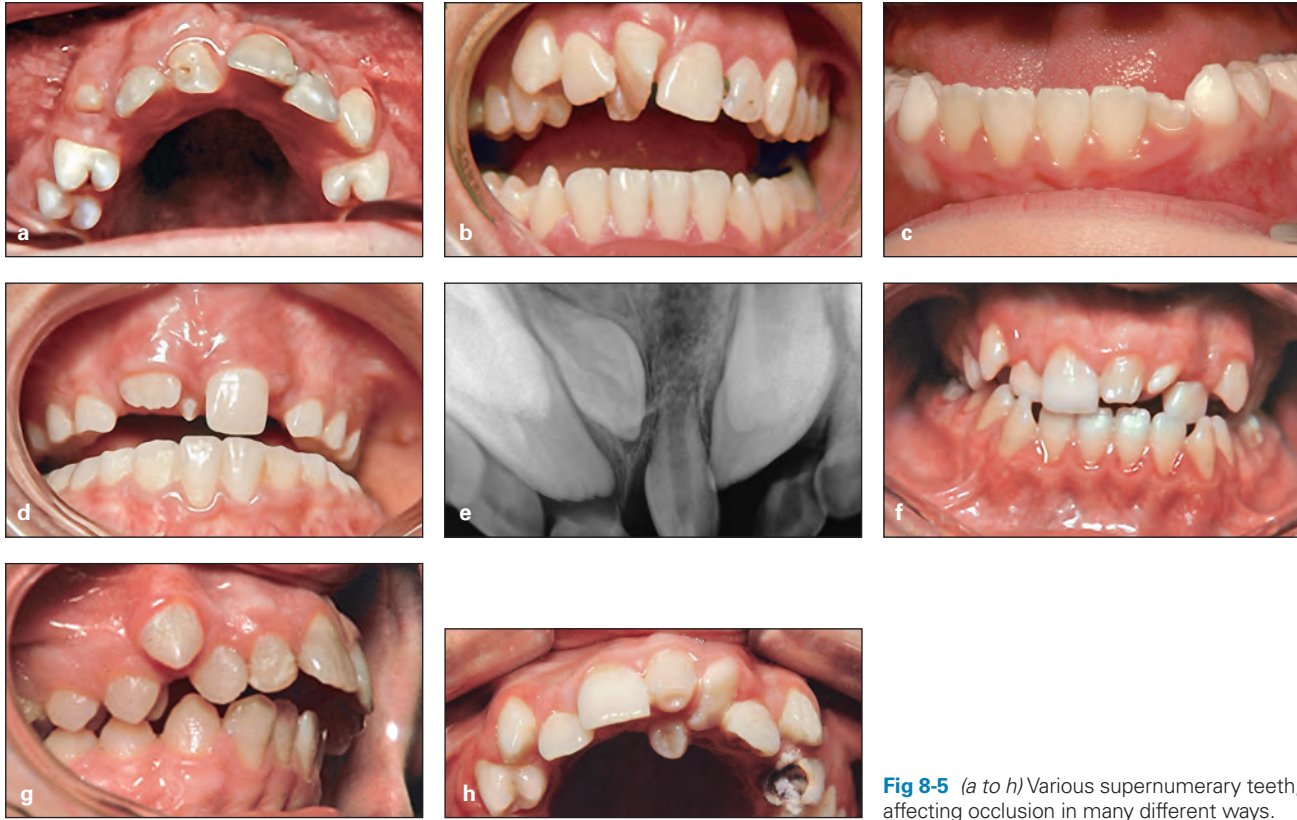

Fig 8-5 (a to h) Various supernumerary teeth, affecting occlusion in many different ways.

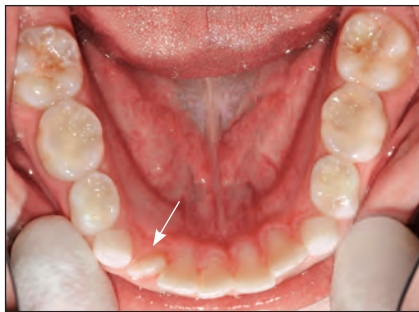


Fig 8-6 Supplemental mandibular supernumerary tooth (arrow) causing crowding, midline shift, and arch asymmetry.

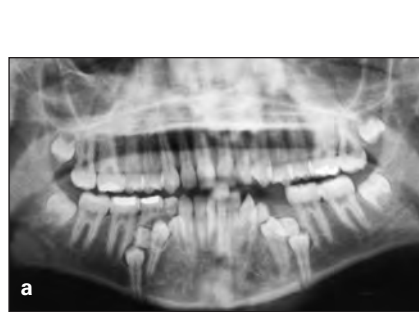

Fig 8-7 (a) Parapremolar supernumerary teeth preventing eruption of mandibular premolars. (b) Paramolar supernumerary teeth damaging the permanent first molar roots.

Early Recognition and Clinical Signs of Hyperdontia

Development of supernumerary teeth can occur any time during the primary dentition, mixed dentition, and the permanent dentition. They are almost always harmful to adjacent teeth and to the occlusion. Most cases of supernumerary teeth are asymptomatic and are usually found during routine clinical or radiologic investigations. Therefore, early recognition of and treatment planning for supernumerary teeth are important components of the preliminary assessment of a child's occlusal status and oral health, which is based on careful clinical and paraclinical examinations.

Clinical examination

Clinical examination of children during the primary or mixed dentition is discussed in detail in chapter 3. When assessing supernumerary teeth in the developing occlusion of a child, the clinician must consider the number, size, and form of teeth, the eruption time, the sequence of eruption, the position of each tooth, and local and general factors that can affect occlusion during transitional changes. The following are clinical signs of the presence of supernumerary teeth:

- Abnormal pattern and abnormal sequence of eruption
- Delayed eruption
- Absence of eruption

Case 9-2

A 10-year, 8-month-old girl exhibited a Class II division 1 malocclusion and maxillary and mandibular incisor protrusion. In addition, an invasive frenum attachment caused severe maxillary incisor crowding, displacement, and cystic formation (Figs 9-19a to 9-19e).

Treatment:

The treatment plan included removal of the frenum, the cyst, and all abnormal soft tissue attachment and extraction of the four first premolars, carried out as a serial step-by-step extraction.

After the surgical procedure and tissue healing, a removable maxillary Hawley appliance was inserted to achieve slow, minor incisor alignment, and use of a lower holding arch for about 1 year was followed by step 1 of the extraction series: removal of the maxillary primary canines, both maxillary primary first molars, and both mandibular primary first molars. Figure 9-19f shows alignment of the maxillary incisors and the canine bulges before serial extraction.

Step 2 was extraction of all four first premolars. Maxillary anchorage was prepared with a Nance appliance, and the lower holding arch was removed as reciprocal anchorage.

Step 3 of the extraction sequence was removal of the remaining primary second molars. This was followed by maxillary and mandibular bonding to start maxillary canine retraction. Then mandibular and later anterior retraction and space closure were accomplished. Some mesial movement of the mandibular molars was allowed, in order to achieve a Class I molar relationship (Figs 9-19g to 9-19k).

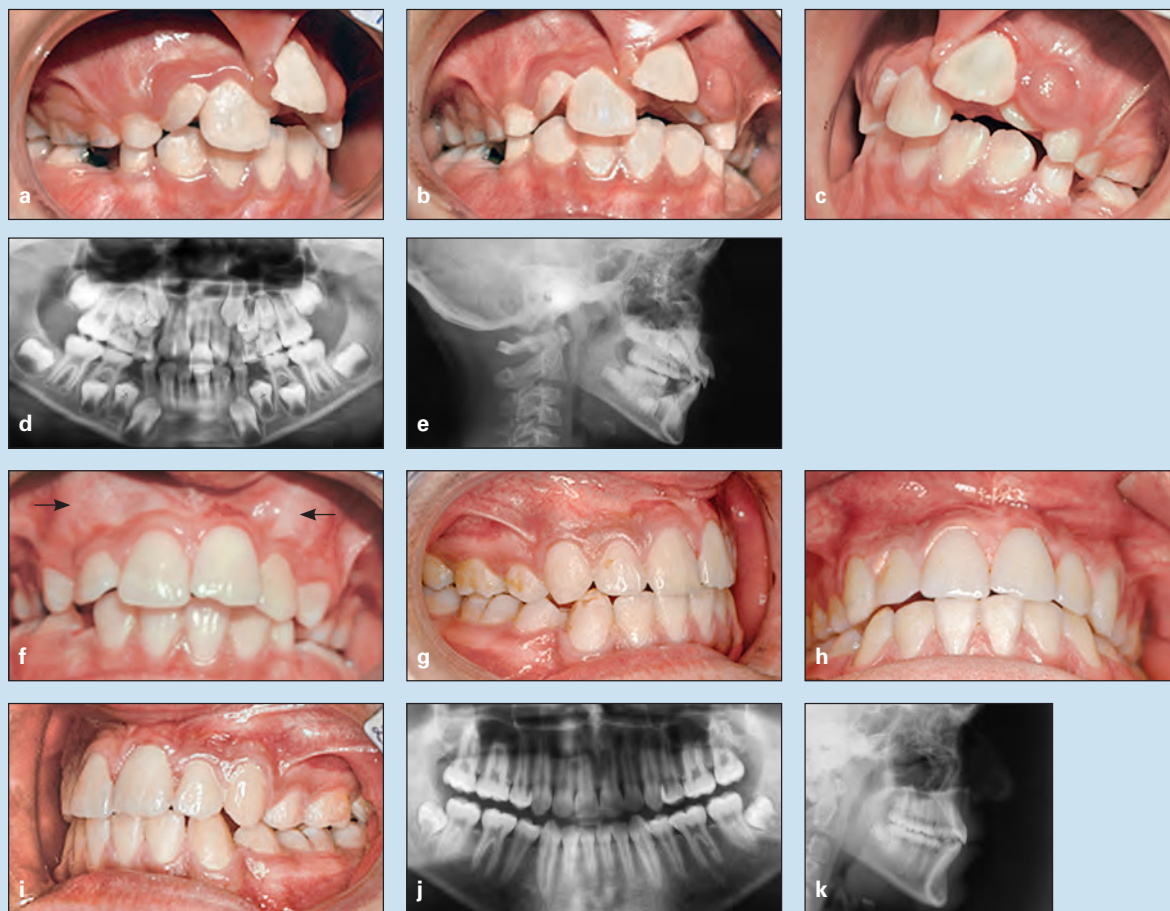

Fig 9-19 Treatment of a 10-year, 8-month-old girl with a Class II division 1 malocclusion and maxillary and mandibular protrusion. An invasive frenum attachment has caused tooth displacement, maxillary incisor crowding, and formation of a cyst. (*a to c*) Pretreatment occlusion. (*d*) Pretreatment panoramic radiograph. (*e*) Pretreatment cephalometric radiograph. (*f*) Tissue healing and some incisor alignment. The *arrows* show canine bulge. (*g to i*) Posttreatment occlusion. (*j*) Posttreatment panoramic radiograph. (*k*) Posttreatment cephalometric radiograph.

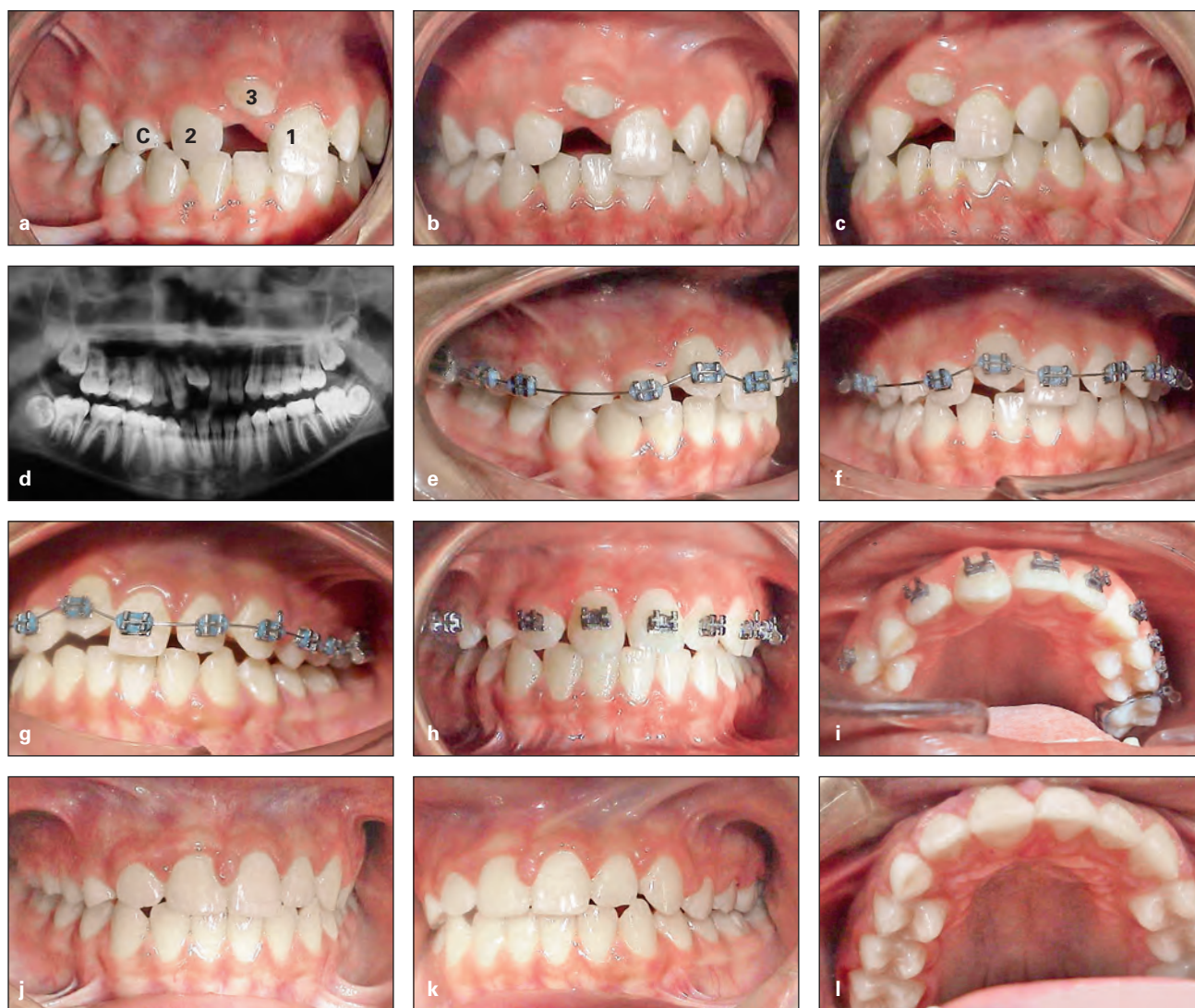

Fig 10-18 Management of an ectopic maxillary canine that has caused resorption of the permanent central incisor root and subsequent exfoliation. (*a to c*) Pretreatment occlusion. (*d*) Pretreatment panoramic radiograph. (*e to h*) Occlusion during active treatment and leveling. The canine bracket has a higher K distance to achieve elongation. (*i to l*) Posttreatment occlusion, after end of active treatment and reshaping of the canine to mimic the central incisor. 1—permanent central incisor; 2—permanent lateral incisor; 3—permanent canine; C—primary canine.

Tooth Transposition

Another kind of eruption disturbance is tooth transposition, or positional interchange of two adjacent teeth, especially their roots. Tooth transposition is a rare but clinically difficult developmental anomaly. Depending on the transposed teeth and their position, normal eruption of adjacent teeth can be affected, root anatomy can be damaged, and eruption of the affected teeth can be delayed. This eruption disturbance was first defined in 1849 by Harris,⁵⁰ who described tooth transposition as an “aberration in the position of the teeth.”

Transposed teeth are classified into two types of tooth displacement: complete transposition and incomplete

transposition (Fig 10-19). In complete transposition, both the crowns and the entire root structures of the involved teeth are displaced to abnormal positions. In incomplete transposition, only the crown of the involved tooth is transposed, and the root apices remain in place.

Transposition is sometimes accompanied by other dental anomalies, such as peg-shaped lateral incisors, congenitally missing teeth, crowding, overretained primary teeth, dilacerations, and rotation of adjacent teeth.

Displacement of one tooth from one quadrant across the midline to the other side of the arch has very rarely been reported, but according to Shapira and Kuflinec⁵¹ these types of anomalies should be considered ectopically erupted teeth, not transposed teeth.

Case 11-9: Anterior dental crossbite

A 10-year-old girl in the middle mixed dentition presented with a Class III molar relationship on the right side because of space loss, 0- to 1-mm overbite and overjet, and three maxillary incisors in crossbite. Treatment had been delayed, causing severe crowding of the mandibular incisors and ectopic eruption of the mandibular right lateral incisor (Figs 11-18a to 11-18f).

Treatment:

Because of the severe crowding and displacement of incisors, the treatment plan incorporated fixed appliances with maxillary and mandibular 2 × 6 bonding. The first step in treatment was 2 × 4 maxillary bonding, mandibular first molar occlusal bonding to disocclude the anterior segment, and placement of 0.016-inch nickel-titanium maxillary arches (cinched back) for leveling and release of abnormal anterior contact. The second step was placement of 0.016-inch stainless steel maxillary arches with an open U-loop mesial to the molar tube (extended arch length) to procline the maxillary incisors out of crossbite. The third step was mandibular 2 × 4 bonding: first with 0.014-inch nickel-titanium archwire because of severe crowding and later with 0.016-inch nickel-titanium archwire for further leveling.

The fourth step was use of an open U-loop to place an extended-length stainless steel archwire against the mandibular molar tube to achieve minor mandibular incisor proclination in order to gain space and align the mandibular incisors. The final step was bonding the permanent canines after eruption for final anterior alignment. Figures 11-18g to 11-18k show the treatment outcome.

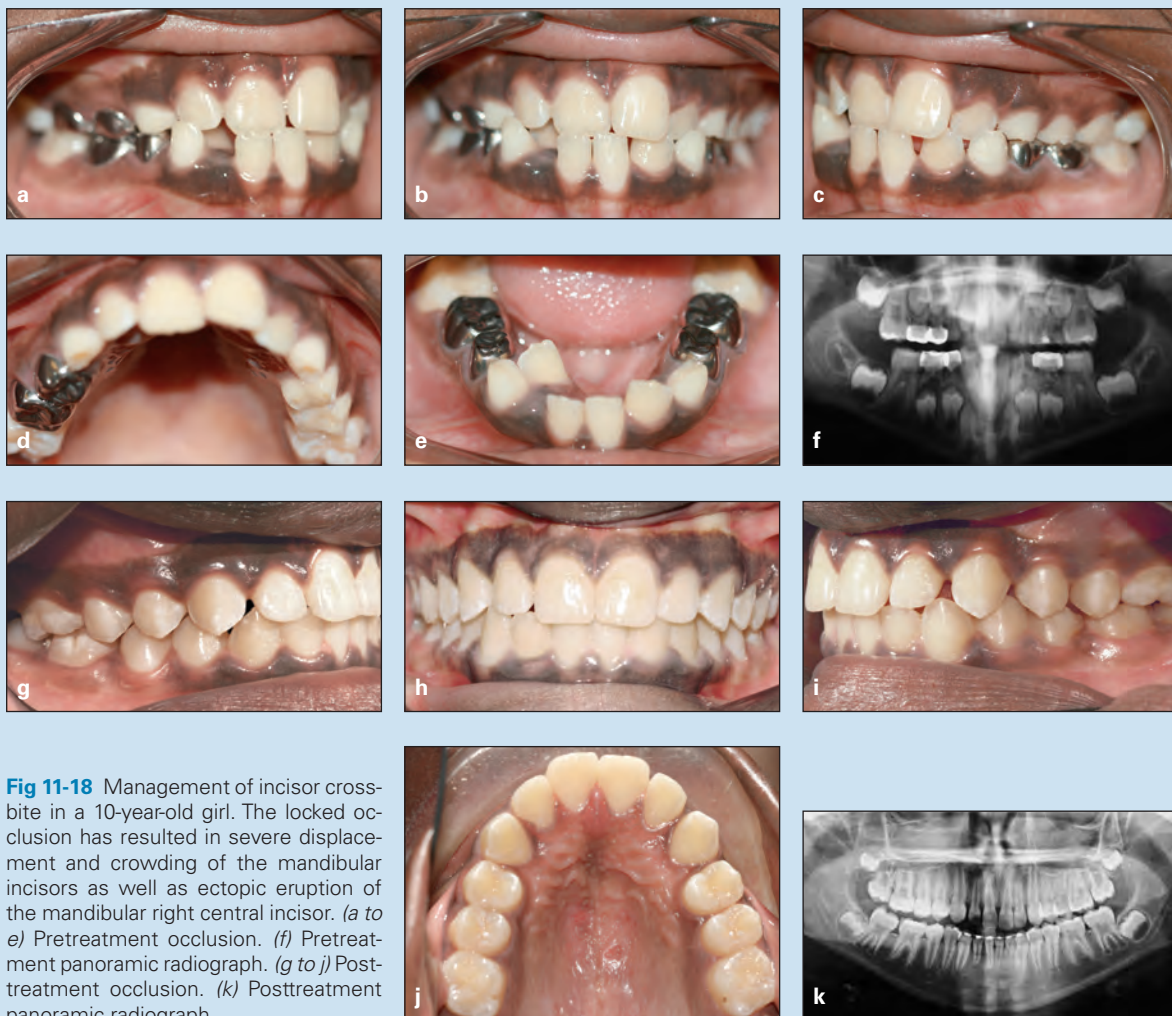


Fig 11-18 Management of incisor crossbite in a 10-year-old girl. The locked occlusion has resulted in severe displacement and crowding of the mandibular incisors as well as ectopic eruption of the mandibular right central incisor. (a to e) Pretreatment occlusion. (f) Pretreatment panoramic radiograph. (g to j) Posttreatment occlusion. (k) Posttreatment panoramic radiograph.

Index

Page numbers with “t” denote tables; those with “f” denote figures; those with “b” denote boxes

A

Acellular cementum, 23
Achondrodysplasia, 230
Acrodynia, 236
Active holding arch, 82, 83f
Active lingual arch, 92
Adenoid facial type, 146
Age of patient
 midline diastema and, 210
 for orthodontic screening, 7
 serial extraction considerations, 117
 space loss affected by, 76
Agranulocytosis, 236
Alginate, 51
Alkaline phosphatase, 20, 235
Allergies
 hypodontia and, 162
 mouth breathing and, 147
Alveolar bone, 24
Alveolar process
 development of, 225
 function of, 26
 growth of, 26
 maxilla and mandible relationship to, 37
Alveolar ridge, 233
Ameloblasts, 18, 19f, 20
Amelogenesis, 20
Amelogenesis imperfecta, 19
Amelogenin, 21
Anchored space regainers, 87–89, 88f
Angle's classification of malocclusion, 3, 150
Ankyloglossia, 215f, 215–216
Ankylosis
 case studies of, 285f–286f
 definition of, 281
 dentition effects of, 282, 282f–283f
 diagnosis of, 283
 etiology of, 281–282
 lateral tongue thrust and, 141
 management of, 283–284
 permanent teeth, 31
 prevalence of, 281
 primary teeth, 31, 165, 281
 treatment of, 283–284
Anodontia, 158

Anterior Bolton discrepancy, 209
Anterior crossbite
 case studies of, 320f–322f
 cephalometric evaluation of, 316
 Class III malocclusion and, 316
 clinical examination of, 316
 differential diagnosis of, 316
 Hawley appliance for, 319
 illustration of, 49f, 257f
 incisor, 317, 318f, 321f
 maxillary canine impaction and, 257f
 in mixed dentition, 321f
 simple
 definition of, 316
 etiology of, 317, 318f
 incidence of, 316
 signs of, 317
 single-incisor, 320f
 treatment of, 319, 347f–351f
Anterior open bite
 anterior tongue thrust and, 142
 illustration of, 49f
 lisping caused by, 50
 thumb sucking as cause of, 133, 134f
Anterior provisional partial denture, 84–85, 85f
Anterior teeth
 early loss of, 84
 protrusion of, 90
Anterior tongue thrust, 141, 141f
Apposition, 21
Arch
 collapse of, 6, 6f, 339, 344f
 crowding in, 52
 dental cast evaluation of, 52
 development of, 28
 form of, 52
 length of
 definition of, 53
 incisor proclination for increasing, 91
 loss of, 282
 palatal canine impaction and, 255
 primary dentition's role in, 30
 reduction of, during transitional dentition, 115

 tooth size and, discrepancy between, 106–107
 transitional dentition changes in, 38
 physiologic changes in, 29
 required space in, 53
 symmetry of, 52, 53f
Arnold expander, 363, 363f
Asymmetric tooth eruption, 240–241
Atavism theory, 192
Autotransplantation
 canine impaction treated with, 265
 disadvantages of, 171
 lateral incisor hypodontia treated with, 171
 mandibular second premolar hypodontia treated with, 174

B

Band and loop space maintainer, 82, 83f
Band and occlusal bar, 84, 84f
Band and pontic, 84, 84f
Band and U-loop space regainer, 87, 88f
Behavioral evaluation, 43
Behavioral modification, for non-nutritive sucking, 135
Bipupillary plane, 56
Bite guards, 152
Bite plate, 403–404, 404f
Bitewing radiographs, 58
Blanching test, 211, 211f
Bluegrass appliance, 136, 137f
Bolton analysis, 54, 78, 79f
Bolton discrepancy, 115, 127, 128f, 209
Bone morphogenetic protein 2, 23
Bone remodeling, 228
Brachycephalic head shape, 45
Brodie syndrome, 360f, 360–361, 372f–373f
Bruxism, 151–152
Buccal canine impaction, 254, 257f, 263–264
Buccal crossbite, 360, 372f–374f
Bud stage, 17f–18f, 17–18

C

- Calcospherites, 21
 Camouflage treatment
 for Class II malocclusion, 297
 for open bite, 380
 Canines
 crescent moon-shaped root
 resorption of, 118, 119f
 eruption of
 ectopic, 165, 243, 244f
 before premolar eruption,
 239–240
 mandibular. *See* Mandibular
 canines.
 maxillary. *See* Maxillary canines.
 permanent
 ectopic eruption of, 165, 243, 244f
 eruption of, 37, 38b
 primary
 early loss of, 403
 extraction of, 261–262
 overretained, 246
 premature exfoliation of, 118
 serial extraction of, 120
 transposition of, 245–246, 255
 unerupted, bulging of, 118
 Cap stage, 18, 18f
 Cartilage calcification, 21
 Casts, dental, 51–54
 Cellular cementum, 23
 Cementoblasts, 22f, 23
 Cementogenesis, 23
 Cementum
 acellular, 23
 cellular, 23
 formation of, 23
 Central diastema, 36
 Central incisors
 eruption of, before maxillary
 lateral incisor eruption, 240
 maxillary
 anterior crossbite caused by, 317,
 318f
 diastema between, 205
 overretained, 317
 supernumerary, 199f–200f
 Cephalometric radiographs, 66–67,
 68b, 101f, 116–117, 258, 296
 Cervical headgear, 3
 Cervical loop, 22, 22f
 Chemotherapy, 162–163
 Chin cap with spurs, 332, 332f
 Clark's rule, 258
 Class I malocclusions, serial
 extraction in, 119–122, 121f,
 124f–126f
 Class II malocclusion
 case studies of, 302f–315f
 cephalometric analysis of, 296
 characteristics of, 294
 diagnosis of, 295–296
 division 1, 301–302, 407f
 division 2, 302, 410f
 early treatment of, 9, 294
 facial height effects on, 294
 growth patterns, 294
 historical background of, 3
 jaw characteristics in, 295b
 morphologic characteristics of,
 295, 295b
 panoramic radiograph of, 62f
 prevalence of, 294
 serial extraction in, 122–123
 transverse dimension
 considerations, 294
 treatment of
 camouflage, 297
 early, 294
 extraoral traction, 298–299
 functional appliances, 298
 growth modification and occlusal
 guidance, 297–299
 headgear, 298–300
 HLH technique, 299–302,
 308f–309f, 314f
 lip bumper, 300–301, 301f
 modified Hawley appliance, 300,
 300f
 one-phase, 302, 310f–315f
 orthognathic surgery, 297
 two-phase, 301–302, 302f–309f
 variations of, 295f
 Class III malocclusion
 anterior crossbite and, 316
 case studies of, 333f–351f
 causes of, 329
 classification of, 331
 crossbite and, comparisons
 between, 331b
 dentofacial characteristics of, 329
 hereditary, 334f, 342f–343f
 mandibular prognathism with,
 330, 341f, 346f
 pretreatment evaluation of, 329
 prevalence of, 329–330
 pseudo-
 case studies of, 325f–329f
 definition of, 323
 delayed treatment of, 324, 330
 multiple incisor involvement in,
 323
 removable appliances for, 324,
 324f
 signs of, 323
 treatment of, 323–324, 324f
 serial extraction in, 123
 skeletal, 329–330
 treatment of
 after incisor eruption, 338,
 338f–346f
 chin cap with spurs, 332, 332f
 in early mixed dentition, 333
 early strategies for, 331–332
 face mask–chin cap combination,
 332, 332f
 factors that affect, 331b
 interceptive, 335f–336f
 in late mixed dentition, 344f
 in primary dentition, 333, 334f
 Cleft lip and palate, 163
 Cleidocranial dysostosis, 231
 Clinical examination
 ankylosed primary molars, 283
 anterior crossbite, 316
 delayed tooth eruption, 232
 description of, 44
 differential diagnosis of, 142–143
 hyperdontia, 196–197
 posterior crossbite, 361
 before serial extraction, 116
 tongue thrust, 142–143
 Closing the drawbridge, 383, 383f
 Computed tomography scans, 59,
 59f, 258–259
 Concave profile, 47, 47f
 Concomitant hypodontia and
 hyperdontia, 165
 Condylar hypertrophy, 361, 361f
 Condylar hypotrophy, 361
 Congenital hypothyroidism, 230
 Convex facial profile, 47f, 117
 Coronoid process, 26
 Corrective orthodontic treatment, 4
 Craniofacial growth
 dentition development and, 15,
 25–27
 description of, 5, 116
 genetic influences on, 5
 mouth breathing effects on, 148
 occlusion affected by, 116
 Crossbite
 anterior. *See* Anterior crossbite.
 central incisor, 179f
 functional. *See* Pseudo–Class III
 malocclusion.
 posterior. *See* Posterior crossbite.
 skeletal Class III malocclusion and,
 comparisons between, 331b
 thumb sucking as cause of, 133,
 134f
 unilateral, 6, 7f
 Crowding
 arch, 52
 degree of
 space analysis and, 79
 space loss affected by, 76
 of incisors. *See* Incisor(s),
 crowding of.
 of mandibular incisors, 38–39
 of molars, 91f
 Crown
 epithelial coverage of, 24
 permanent, primary root
 resorption and, 32
 Crown and bar, 84, 84f
 Crown and pontic, 84, 84f
 Curve of Spee, 53–54, 79, 404
 Curve of Wilson, 361
 Cuspal height, 400
 Cusps, enamel knot's role in
 formation of, 20
 Cyst formation, 18

D

- Deep bite
 case studies of, 405f–413f
 cuspal height effects on, 400
 definition of, 397
 degree of, 397
 dental, 397–398, 402–403
 development of, 397
 differential diagnosis of, 399–400
 etiology of, 397–399
 factors that affect, 400
 impinging, 6, 6f, 202f, 206, 209,
 310f, 314f, 405f
 mandibular forward growth and,
 397
 morphologic characteristics of, 399
 periodontal disease and, 401
 relapse of, 399
 reverse, 336f
 skeletal, 398–399, 403–404
 treatment of
 appliances for, 404–405
 delayed, 400
 early, 401
 in mixed dentition, 403–404, 412f
 in permanent dentition, 401–402
 in primary dentition, 403
 strategies for, 402–405
 Deep overbite, 303f
 Deglutition, 139–140
 De-impactor spring, 242, 243f

- Delayed exfoliation, of primary dentition, 31
- Dental caries, 31
- Dental casts
- arch form and symmetry evaluations using, 52
 - description of, 51–52
 - occlusion evaluations using, 52
 - before serial extraction, 116
- Dental follicle
- anatomy of, 22–23
 - fibroblasts of, 24
 - permanent, congenital absence of, 31
 - tooth eruption affected by, 227
- Dental history, 43–44
- Dental lamina
- development of, 16f, 16–17
 - magnification of, 16f
- Dental occlusion. *See* Occlusion.
- Dental retrusion, 56
- Dentigerous cyst, 193, 194f
- Dentin
- apposition of, 21
 - formation of, 20
 - hypoplasia of, 21
 - interglobular, 21
 - mineralization of, 20–21, 23
- Dentin fluorosis, 21
- Dentin matrix protein-2, 23
- Dentinogenesis, 20
- Dentinogenesis imperfecta, 19
- Dentition
- ankylosis effects on, 282, 282f–283f
 - bruxism effects on, 152
 - intraoral examination of, 48–49, 49f
 - monitoring of, during early-age orthodontic treatment, 9
- Dentition development
- craniofacial growth and, 15, 25–27
 - description of, 15
 - neonatal, 27f, 27–28
 - permanent, 19
 - postnatal, 28
 - primary. *See also* Primary dentition.
 - bud stage of, 17f–18f, 17–18
 - calcification stage of, 20–21
 - cap stage of, 18f, 18f
 - crown stage of, 21, 21f
 - early bell stage of, 18f, 18–19
 - initiation stage of, 16f–17f, 16–17
 - late bell stage of, 19f–20f, 19–20
 - molecular level of, 22–23
 - morphodifferentiation stage of, 19f–20f, 19–21
 - root formation, 22, 22f
 - studies of, 22–23
 - retarded, 238–239
- Dentogingival junction
- development of, 24
 - tissues of, 24
- Desmosomes, 18
- Developmental spaces, 28–29
- Diagnostic database, 42
- Diagnostic process
- description of, 51
 - goal of, 41
 - interview, 42–44
 - questionnaire, 42–44
 - schematic diagram of, 42, 42f
 - steps involved in, 42
- Diastema, 36, 94, 179f
- central, 94, 179f
 - midline. *See* Midline diastema.
- Dichotomy theory, 192
- Digit sucking, 132–136, 134f
- Digital imaging, 59
- Distal drift, 76–77
- Distal jet appliance, 88, 88f
- Distal shoe, 82
- Distal step terminal plane, 29f, 29–30, 33f
- Distraction osteogenesis, 360
- Divergence of the face, 47
- Dolichocephalic head shape, 45, 146f
- Down syndrome, 163, 231, 245
- Drift, 26, 76–77
- “Dual bite,” 51
- Dwarfism, 230
- E**
- E space, 110, 110f
- Early exfoliation, of primary dentition, 31
- Early-age orthodontic treatment
- advantages of, 66
 - benefits of, 11–12
 - clinical evidence about, 10
 - controversy associated with, 9–11
 - costs of, 11
 - current interest in, 6–7
 - definition of, 4
 - dentition monitoring during, 9
 - goals of, 8
 - growth patterns and, 10–11
 - lack of training in, 12
 - misconceptions about, 10–11
 - modern views on, 41
 - objectives of, 4
 - one-phase, 8
 - patient benefits, 11
 - phases of, 8–9
 - practitioner benefits, 12
 - professional encouragement of, 12
 - rationale for, 7
 - reasons for, 4–7
 - results with, 11–12
 - single phase of, 8, 10
 - strategy of, 4, 8
 - timing of, 7–8, 298
 - two-phase, 9–10
- Ectoderm, 22
- Ectodermal dysplasia, 163
- Ectomesenchymal cells, 19–20, 23–24
- Ectomesenchyme, 16–17
- Ectopic eruption
- definition of, 241
 - permanent canines, 243, 244f
 - permanent first molars, 241–242, 242f
 - prevalence of, 241
- Ectopic impacted canines, 260
- Ellis lingual arch, 82, 83f
- Embryonic period, 15
- Enamel
- apposition of, 21
 - formation of, 20
 - mineralization of, 20–21
 - tetracycline discoloration of, 21
- Enamel hypoplasia, 21
- Enamel knot
- in cusp formation, 20
 - definition of, 17
 - illustration of, 18f
- Enamel matrix, 20–21
- Enamel organ, 18, 18f
- Epithelial cuff, 24
- Epithelial thickening, 16, 16f
- Examination(s)
- clinical. *See* Clinical examination.
 - extraoral. *See* Extraoral examination.
 - photographic evaluation. *See* Photographic evaluation.
 - radiographic. *See* Radiographs.
- Exfoliation, of primary dentition
- description of, 30–32, 229
 - early, 235–236
- External enamel epithelium, 18
- Extraction. *See also* Serial extraction.
- early-age orthodontic treatment effects on need for, 11–12
 - space creation through, 90
- Extraoral anchorage, 3
- Extraoral examination
- elements of, 44–45
 - frontal facial evaluation, 45–46, 46f
 - lateral facial evaluation, 46–47
- Extraoral photography
- facial esthetics, 55–56, 57f
 - frontal view, 54–57, 55f
 - lateral view, 55–56
 - oblique view, 55
- Extraoral radiographs, 58–59
- Extraoral traction, for Class II malocclusion, 298–299
- F**
- Face
- description of, 131
 - embryologic development of, 15
 - vertical growth of, 380
- Face mask–chin cap combination, 332, 332f
- Facial asymmetry, 56, 57f, 361f
- Facial esthetics
- composition of, 45
 - early-age orthodontic treatment benefits for, 11
 - evaluation of, 44
 - malocclusion effects on, 9
 - photographic evaluation of, 55–56, 57f
 - primary dentition’s role in, 30
- Facial evaluation
- frontal, 45–46, 46f
 - lateral, 46–47
- Facial form, 44
- Facial height, 294
- Facial profiles, 47, 47f
- Facial proportion
- evaluation of, 46, 46f
 - frontal, 56, 57f
 - head posture and, 148
 - lateral, 56, 57f
- Facial symmetry, 45–46, 46f
- Facial trauma, 162
- Facial typing, 45
- Family medical history, 43–44
- Fiber-reinforced composite resin
- fixed partial denture, 170
- Fibroblast growth factors, 23
- Fibroblasts, 228
- Finger sucking, 132–136, 134b, 134f, 378, 378f, 381–382

- First molars
 distalization of, 91, 91f
 ectopic eruption of, 241–242, 242f
 mandibular
 maxillary first molar and, 37
 mesial shift of, 38
 permanent, 32
 maxillary
 ectopic eruption of, 119, 119f, 243f
 mandibular first molar and, 37
 vertical palisading of, 119, 119f, 124
- Fixed expanders, 93–94, 94f, 362–364, 363f–364f
- Fixed orthodontic appliances, 136, 137f
- Fluorosis, dentin, 21
- Flush terminal plane, 29f, 29–30, 33, 33f
- Fourth germ layer, 22
- Frenectomy, 214, 215f, 217f
- Frenotomy, 216
- Frenum
 maxillary labial, 207
 morphogenesis of, 206–207
 structure of, 206–207
- Frenum attachment abnormalities
 ankyloglossia, 215–216
 case studies of, 216f–222f
 differential diagnosis of, 210–211
 in infants, 214
 management of
 in adults, 211–212
 delayed, 212
 frenectomy, 214, 215f, 217f
 in infants, 214
 in mixed dentition, 212–213, 213f
 in primary dentition, 213–214
 results of, 213f
 two-phase, 213
 midline diastema. *See* Midline diastema.
 occlusion affected by, 210
 radiographs of, 211, 211f
 signs of, 211, 211f
- Frontal cephalometric radiographs, 67
- Frontal view, 54–55, 55f
- Functional crossbite, 359–360.
See also Pseudo–Class III malocclusion.
- Functional matrix, 6, 131
- G**
- Genetic theory, of maxillary canine impaction, 255–256
- Gingival groove, 27
- Glossectomy, 49
- Glycosaminoglycans, 18
- Proper fixed anterior prosthesis, 85
- Growth modification techniques
 Class II malocclusion treated with, 297–299
 open bite treated with, 382–383, 383f
- Growth patterns
 Class II malocclusion, 294
 early-age orthodontic treatment and, 10–11
 incisor position and crowding affected by, 111
 mixed dentition space analysis, 53
 sagittal expansion and, 90–91
 serial extraction considerations, 117–118
 space analysis and, 79
- Growth status evaluation, 43
- Gubernaculum dentis, 227
- Guidance theory, of maxillary canine impaction, 254–255
- Gum pads, 27, 27f, 140
- Gurin lock regainer, 87, 88f
- H**
- Haas expander, 93, 94f, 363, 363f
- Halterman appliance, 242, 243f
- Hand-wrist radiographs, 59
- Hard tissues. *See* Dentin; Enamel.
- Hawley appliance
 anterior crossbite treated with, 319
 bruxism treated with, 152
 Class II malocclusion treated with, 299–300
 as habit breaker, 136, 137f
 modified, 300, 300f, 324f, 406f
 as removable distalizer, 92
 space maintenance using, 86, 86f
 space regaining using, 89, 89f
 tongue thrust treated with, 145f
- Headgear
 Class II malocclusion treated with, 298–300
 high-pull, 299
 historical background of, 3
 J-hook, 299
 patient's cooperation in using, 299
 sagittal expansion using, 92
- Hemifacial microsomia, 163
- Hereditary crowding, of incisors, 118–119, 119f
- Hertwig's epithelial root sheath, 22, 22f, 24
- Histodifferentiation
 description of, 18, 19f
 developing abnormalities during, 19
- Holoprosencephaly, 207
- Homeobox genes, 22, 161
- Hyperactivity theory, 192
- Hyperdontia. *See also* Supernumerary teeth.
 case studies of, 198f–202f
 clinical examination of, 196–197
 definition of, 17
 hypodontia and, 165–166, 192
 management of, 197–198
 occlusion affected by, 196, 197f
 prevalence of, 189–190, 190t–191t
 radiographic examination of, 197
- Hypodontia
 autotransplantation for, 171, 174
 case studies of, 174f–185f
 central incisors, 180f–181f
 clefts associated with, 163
 clinical signs of, 167
 definition of, 17, 158
 dental anomalies associated with, 164–165
 dentoskeletal patterns affected by, 166
 description of, 157
 distribution of, 160t
 in Down syndrome, 163
 early recognition of, 167
 environmental factors, 161–163
 ethnicity and, 159t–160t
 etiology of, 160–163
 sex and, 159t–160t
 genetic factors, 160–161
 in hemifacial microsomia, 163
 hyperdontia and, 165–166, 192
- lateral incisors
 autotransplantation for, 171
 canine substitution for space closure, 168–169
 case studies of, 176f–178f, 184f–185f
 impaction caused by, 274
 management of, 168–171
 maxillary, 208f
 midline diastema caused by, 208, 208f
 prosthesis for, 169–171, 171f
 management of, 167–168
 mandibular second premolars, 172–174, 180f–181f
 microdontia and, 164
 occlusion affected by, 157, 166
 partial, 163
 prevalence of, 158, 159t, 162
 soft tissue affected by, 166
 space closure, 168–169, 173
 syndromes associated with, 163–164
 systemic diseases associated with, 162
 treatment of, 167–168
- Hypophosphatasia, 235–236
- Hypopituitarism, 230
- Hypoplasia
 dentin, 21
 enamel. *See* Enamel hypoplasia.
- Hypothyroidism, 230
- Hyrax expander, 93–94, 94f, 363, 363f
- I**
- Image shift principle, 258
- Impinging deep bite, 6, 6f, 202f, 206, 209, 310f, 314f, 405f
- Implant-supported restorations, 173–174
- Incisor(s)
 anterior crossbite, 317, 318f, 321f
 crowding of
 acquired, 118
 Bolton discrepancy, 115, 127, 128f
 causes of, 106–107
 characteristics of, 107–108
 in Class I malocclusions, 119–122, 121f, 124f–126f
 in Class II malocclusions, 122–123
 in Class III malocclusions, 123
 classification of, 107–108
 description of, 95, 105
 environmental, 118
 hereditary, 118–119, 119f
 intervention for, 107
 measurement of, 117
 minor, 108
 in mixed dentition, 95, 105–106
 moderate, 108–114, 109f–114f
 prediction of, 106
 prevention of, 107
 serial extraction for. *See* Serial extraction.
 severe, 115, 117, 120, 121f, 264
 tooth size–arch length discrepancy as cause of, 106–107, 123
 in transitional dentition, 110
 transverse expansion for, 93
- eruption of
 asymmetric, 36
 central diastema persistence during, 36

- Class III malocclusion treatment
 after, 338, 338f–346f
 mandibular central incisors, 34, 34f
 mandibular lateral incisors, 34, 34f
 maxillary central incisors, 35, 35f
 maxillary lateral incisors, 35–36, 36f
 permanent, 34f–36f, 34–36
 problems during, 36, 36b
 impaction of
 case studies of, 275f–280f
 early detection and diagnosis of, 273
 etiology of, 273
 interceptive treatment of, 274
 odontoma as cause of, 273
 supernumerary teeth as cause of, 273, 274f, 279f
 trauma as cause of, 273
 inclination of, 53, 56, 79, 91, 117
 intrusion of, 402
 labial movement of, 91
 lateral
 mandibular, 34, 34f
 maxillary, 35–36, 36f
 splaying of, 118, 119f
 lip position and, 53
 mandibular
 crowding of
 Bolton discrepancy as cause of, 127, 128f
 description of, 38–39, 91, 105, 107, 114f, 207, 406f
 eruption of, 34, 34f
 gingival recession at, 118
 maxillary
 eruption of, 35–36, 36f
 space closure with, 94
 overretained, 32f
 periodontal condition of, 91
 primary
 early loss of, 81f, 85
 overretained, 274, 317, 318f
 roots, delayed resorption of, 109f
 sequential stripping of, 109
 spaces between, 28
 proclination of, 34f, 91–92
 root resorption of
 delayed, 34f, 109f
 description of, 256
 splaying of, 118, 119f
 Incisor liability, 33–34, 36
 Inconstant swallowing, 142
 Infantile swallowing, 140, 142
 Initiation stage, 16f–17f, 16–17
 Inter canine arch width, 34
 Interceptive treatment
 definition of, 4
 of incisor impaction, 275
 of maxillary canine impaction, 260–262
 patient expectations about, 43
 Interdental fibers, 207
 Interdental spacing, 79
 Interglobular dentin, 21
 Interincisal angle, 400
 Intermolar width, 92
 Interproximal wedging technique, 242, 242f
 Intertransitional periods, 28
 Interview, 42–44
 Intraoral examination
 components of, 116
 dentition, 48–49, 49f
 description of, 47, 116
 paraclinical evaluation, 51
 soft tissues, 49–51
 temporomandibular joint function, 51
 tongue, 49–51, 50f
 Intraoral photography, 58
 Intraoral radiographs, 58
 Irradiation, 162–163
- J**
 Jaw
 fracture of, 246
 ontogenesis of, 25, 25f
 Jaw muscles, 26
 J-hook headgear, 299
 Jumping the bite, 298
 Juvenile hypothyroidism, 230
 Juvenile rheumatoid arthritis, 26
- L**
 Lasers, 214
 Lateral cephalometric radiographs, 4, 258
 Lateral expansion, 93
 Lateral facial evaluation, 46–47
 Lateral facial proportion, 56, 57f
 Lateral incisors
 hypodontia of
 autotransplantation for, 171
 canine substitution for space closure, 168–169
 case studies of, 176f–178f
 management of, 168–171
 palatally displaced maxillary canines associated with, 255
 prosthesis for, 169–171, 171f
 mandibular
 eruption of, 34, 34f
 transposition of, 245, 249f
 maxillary
 eruption of, 35–36, 36f, 240
 microdontia of, 208, 208f
 supernumerary, 194f
 transposition of, 250f
 microdontia of, 208, 208f
 peg-shaped, 274
 proclination of, 36, 36f
 supernumerary, 198f
 transposition of, 245, 249f–250f, 252f–253f
 Lateral jaw radiographs, 58–59
 Lateral tongue thrust, 141f, 141–142
 Lateral view, 55–56
 Leeway space, 78, 80, 95, 276f
 Ligand for receptor activator for nuclear factor κ B, 30
 Lingual crossbite, 360, 360f
 Lip bumper, 91–92, 92f, 299, 300–301, 301f
 Lip dysfunction, 209, 209f, 398
 Lip line, 169
 Lip position, 56, 57f
 Lip proportion, 56, 57f
 Lip seal, 382
 Lip strain, 55f
 Lipping, 50
 Locked occlusions, 6f, 6–7, 113f
 Longitudinal panoramic radiographs, 60, 61f–65f, 116
 Lower holding arch, 82, 83f, 109f
 Lower lip dysfunction, 403
- M**
 Macroglossia
 description of, 49, 49f
 tongue thrust associated with, 141, 141f
 Malocclusions
 Angle's classification of, 3, 150
 Class I, 119–122, 121f, 124f–126f
 Class II. *See* Class II malocclusion.
 Class III. *See* Class III malocclusion.
 environmental factors associated with, 293
 etiology of, 42
 facial esthetics affected by, 9
 speech problems and, 50, 150–151
 thumb/finger sucking as cause of, 133, 134f, 137f
 treatment of, 115
 untreated, problems secondary to, 9
 Mandible
 anatomy of, 25, 25f
 anterior shift of, 325f–326f
 displacement of, 247
 masticatory muscle attachment to, 26
 normal closure pattern of, 400
 positions of, 297
 retrusion of, 412f
 Mandibular arch, 49f
 Mandibular canines
 eruption of, 37
 impaction of, 265
 permanent, eruption of, 37
 primary
 early extraction of, 36
 premature loss of, 35, 98f, 102f
 Mandibular condyle
 ankylosis of, 26
 growth of, 26–27
 Mandibular first molars
 extraction of, 247f
 maxillary first molar and, 37
 mesial shift of, 38
 permanent, 32
 Mandibular first premolar eruption before canine eruption, 239–240
 description of, 37
 Mandibular growth
 asymmetric, 7f, 25, 46f
 direction of, 26
 impinging deep bite effects on, 6
 insufficient, 19
 malocclusions caused by problems with, 25
 at mandibular condyle, 26
 occlusion affected by, 106
 temporomandibular joint-related factors that affect, 26
 Mandibular incisors. *See also* Incisor(s).
 central, 34, 34f
 crowding of
 Bolton discrepancy as cause of, 127, 128f
 description of, 38–39, 49, 91, 105, 107, 114f, 207
 inclination of, 79
 lateral, 34, 34f
 proclination of, 350f
 relative position of, 397
 Mandibular molar distalizer, 88, 88f
 Mandibular plane–occlusal plane angle, 400

Mandibular prognathism, 330, 341f, 346f

Mandibular second molars
eruption of, maxillary second molar eruption before, 240
impaction of, 119, 119f
terminal plane, 32, 33f

Mandibular second premolars, 172–174, 180f–181f

Mastication, 30

Masticatory muscles, 26

Maternal rubella, 162

Maxillary arch
collapse of, 6, 6f, 339, 344f
constriction of, 355, 357, 359

Maxillary bone, 25

Maxillary canines. *See also* Canines.
displacement of, 266f–267f
eruption before premolars, 239
impaction of
autotransplantation of, 265
buccal, 254, 257f, 263–264
case studies of, 266f–272f
clinical examination of, 257–258
consequences of, 256–257
early detection of, 257–260
ectopic, 260, 262f, 268f
etiology of, 254–256
interceptive treatment of, 260–262
labial, 256
odontoma as cause of, 269f–271f
orthodontic procedures for, 264
palatal, 254–256, 263
panoramic radiographs of, 259f, 259–260
position of, 262
prevalence of, 254
proximity of, to adjacent teeth, 259
radiographic evaluation of, 258f–259f, 258–260
signs of, 258
space deficiency as cause of, 266f–267f
step-by-step management of, 264b
surgical exposure of, 262–264, 263f
treatment of, 260–265

Maxillary first molars
ectopic eruption of, 119, 119f, 243f
mandibular first molar and, 37
vertical palisading of, 119, 119f, 124

Maxillary incisors. *See also* Incisor(s).
central, 35, 35f
delayed treatment of midline diastema until complete eruption of, 212
flaring of, 133
labial migration of, 401
lateral
description of, 35–36, 36f
eruption of, 35–36, 36f, 240
microdontia of, 208, 208f
supernumerary, 194f
liability, 36
permanent, 319
protrusion of, 36f
secondary spacing, 36, 36f

Maxillary intercanine distance, 29

Maxillary second molars
eruption of, before mandibular second molar eruption, 240
terminal plane, 32, 33f

Mechanotherapy
incisor impaction treated with, 277f
with selective extraction, for open bite, 383
tongue thrust treated with, 143, 143f

Meckel's cartilage, 25

Medical history, 43–44

Mentolabial sulcus, 56, 57f

Merrifield analysis, of space, 78

Mesial drift, 26, 76–77

Mesial occlusion. *See* Class III malocclusion, skeletal.

Mesial shift, 38, 347f

Mesial step terminal plane, 29f, 29–30, 33, 33f

Mesiodens, 194, 208, 208f

Mesocephalic head shape, 45

Microdontia
hypodontia and, 164
illustration of, 163f
lateral incisors, 208, 208f

Midline diastema
case studies of, 216f–222f
causes of, 207–210
anterior Bolton discrepancy, 209
impinging deep bite, 209
lateral incisor hypodontia, 208, 208f
lip dysfunction, 209, 209f
mesiodens, 208, 208f
odontoma, 208
overview of, 207–208
pathologic tooth migration, 210, 210f
definition of, 205
differential diagnosis of, 210–211
etiology of, 206–210
sex and, 206
management of
in adults, 211–212
delayed, 212
in infants, 214
in mixed dentition, 212–213, 213f
in primary dentition, 213–214
results of, 213f
two-phase, 213
occlusion affected by, 210
prevalence of, 206
radiographs of, 211, 211f
shape of, 211, 211f

Mineralization, of hard tissues, 20–21, 23

Mixed dentition
anterior crossbite in, 317, 318f, 321f
deep bite in, 403–404, 412f
early, Class III malocclusion
treatment in, 333
frenum attachment abnormalities in, 212–213, 213f
incisor crowding in
description of, 95, 105–106
serial extraction for, 115. *See also* Serial extraction.
Moyers analysis of, 78
open bite management in, 382
posterior crossbite in, 367f
space analysis of, 52–54, 78
transverse expansion during, 93

Modified Hawley appliance, 406f

Molar(s)
distalization of, 91
first. *See* First molars.
mesially tipped, 91

permanent, 53
primary
ankylosis of, 165, 281, 282f, 285f
extraction of, 74, 120–121, 121f, 173
long-term retention of, 172
submerged, 285f
second. *See* Second molars.

Molar distalizer
with Nance anchorage, 87–88, 88f
pendulum appliance as, 92, 92f

Morphodifferentiation stage, 19f–20f, 19–21

Mouth breathing
adenoid tissue location
evaluations, 150
clinical examination of, 149–150
dentofacial characteristics of, 146, 146f, 148–149
etiology of, 147
evaluation of, 149–150
general body growth associated with, 147–148
lip incompetence associated with, 150
maxillofacial complex affected by, 146–147
occlusion effects of, 146–147
open bite caused by, 378
orthodontic management of, 150
posterior crossbite secondary to, 356–357
postural changes associated with, 146–148
problems associated with, 149, 149f
signs of, 146f, 147–149
treatment of, 150

Moyers mixed dentition analysis, 78

MSX1, 23

MSX2, 23

MSX genes, 161

Multirooted teeth, 22

Muscular dystrophy, 26

N

Nance analysis, of space, 54, 77–78

Nance holding arch, 83, 84f

Nasal obstruction, 147, 149

Nasolabial angle, 56, 57f

Nasomaxillary complex, 27, 146

Natal teeth, 27–28

Neonatal dentition
development of, 27f, 27–28
gum pads, 27, 27f, 140
natal teeth, 27–28

Neural crest cells, 15, 22

Non-nutritive sucking
case studies of, 137f–138f
clinical examination of, 134
definitions of, 132
etiology of, 132–133
finger, 132–136, 134b, 134f
midline diastema caused by, 209, 209f
occlusion effects, 133
open bite caused by, 378, 378f, 381–382, 384f
pacifiers, 136, 139
posterior crossbite caused by, 356
prevalence of, 133
thumb, 132–136, 134b, 134f
treatment of
age of intervention, 135
behavioral modification

- techniques, 135
description of, 135–138, 137f–138f
orthodontic appliances, 138, 139f
- O**
- Obstructive sleep apnea syndrome, 148
- Occlusal bite plate, 152
- Occlusal development
craniofacial growth effects on, 116
environmental factors, 5–6
factors that affect, 37
form and function in, 6, 24–25
genetic factors, 5
hypodontia effects on, 157
locked occlusions effect on, 6f, 6–7
long process of, 5
mechanisms that affect, 5–6
prenatal stage of, 16–27
tongue's role in, 27
- Occlusal interferences, 6, 6f–7f
- Occlusal radiographs, 58, 258, 258f
- Occlusal system, 47
- Occlusion
Class I, 47
dental cast evaluation of, 52
frenum attachment abnormalities
effect on, 210
hyperdontia effects on, 196, 197f
hypodontia effects on, 166
importance of, 25
locked, 6f, 6–7, 113f
mandibular growth effects on, 106
midline diastema effects on, 210
mouth breathing effects on,
146–147
normal, 397
pacifier sucking effects on, 139
preparation of, for prosthetics, 174
sagittal evaluation of, 52
serial extraction and, 117
space loss and, 76
thumb sucking effects on, 133, 134f
type of, 52
vertical dimension of, 293
- Odontoblastic process, 20
- Odontoblasts, 18–20, 19f, 30
- Odontoma
canine impaction caused by,
269f–271f
description of, 18, 192–193, 193f,
200f–201f, 208, 255
incisor impaction caused by, 273
midline diastema caused by, 208
- Oligodontia
case study of, 182f–183f
computed tomography of, 59, 59f
definition of, 158
management of, 167
microdontia and, 163f
- One-phase orthodontic treatment,
5, 8
- Open bite
anterior
anterior tongue thrust and, 142
illustration of, 49f
lispings caused by, 50
thumb sucking as cause of, 133,
134f
case studies of, 384f–396f
cephalometric evaluation of, 380f
classification of, 381
dental, 379
differential diagnosis of, 379–380
- etiology of, 378–380
finger sucking as cause of, 378,
378f, 381–382, 384f
genetic factors, 378–379
morphologic characteristics of, 379
mouth breathing as cause of, 378
non-nutritive sucking as cause of,
378, 378f, 381–382, 384f
overview of, 377–378
serial extraction in patients with, 123
skeletal, 379
tongue force abnormality as cause
of, 378, 379f
tongue guards for, 143, 143f
tongue thrust and, 140, 141f, 142,
379, 381, 387f. *See also* Tongue
thrust.
treatment of
camouflage, 380
closing the drawbridge, 383, 383f
early, 380–383
growth modification, 382–383, 383f
lip seal, 382
mechanotherapy with selective
extraction, 383
in mixed dentition, 382
orthognathic surgery, 380
posterior facial height–anterior
facial height ratio increase,
383, 383f
strategies for, 380
type I, 381, 384f–386f
type II, 381, 387f
type III, 381, 388f–396f
vertical growth pattern associated
with, 390f
- Oral cavity, 48
- Oral drive theory, 132
- Oral habits, abnormal
arch collapse affected by, 77
bruxism, 151–152
early-age orthodontic treatment
effects on control of, 12
midline diastema caused by, 209,
209f
mouth breathing. *See* Mouth
breathing.
non-nutritive sucking. *See* Non-
nutritive sucking.
overview of, 131
time of appearance, 132
tongue thrust. *See* Tongue thrust.
- Oral infections, 236
- Orofacial structure, 47
- Oronasal complex, 24
- Oronasal functional matrix, 27
- Orthodontic appliances, for non-
nutritive sucking, 138, 139f
- Orthodontic forces, 3
- Orthodontic screening, 7
- Orthodontic treatment
canine impaction, 264
early-age. *See* Early-age
orthodontic treatment.
historical background of, 3
one-phase, 5
scientific evidence regarding, 6
two-phase, 5, 9–10
- Osteoblasts, 24
- Osteoclastogenesis, 228, 230
- Osteogenesis, 228
- Osteoprotegerin, 30
- Outer enamel epithelium, 18
- Overjet, 303f, 310f, 391f
- P**
- Pacifiers, 136, 139
- Palatal appliance, 136, 137f
- Palatal crossbite, 360
- Palatal expansion, orthopedic, 93
- Palatal plane–occlusal plane, 400
- Panoramic radiographs, 60, 61f–65f,
116, 259f, 259–260
- Paraclinical evaluation, 51, 116–117
- Parathyroid hormone receptor 1, 230
- Parathyroid hormone-related protein,
230
- Patient chief complaint of, 43
compliance of, 11–12
early-age orthodontic treatment
benefits for, 11
medical history of, 44
- Peak height velocity, 59
- Pedo temporary bridge, 85
- Pendulum appliance, 88, 88f, 92, 92f
- Periapical abscesses, 31, 31f
- Periapical radiographs, 58, 211, 211f,
258
- Periodontal disease, 49, 401
- Periodontal ligament
collagen fibers of, 24, 25f
description of, 22
development of, 24, 25f
formation of, 23
remodeling of, 228
tooth eruption affected by, 227–228
- Periodontitis, 236
- Permanent dentition
ankylosis of, 31
eruption of, 30
formation of, 19
nonsyndromic agenesis of, 160
premature eruption of, 235–236
transposition of, 164
- Photographic evaluation
applications of, 54
extraoral. *See* Extraoral
photography.
intraoral, 58
before serial extraction, 116
- Physical growth evaluation, 43
- Pierre Robin syndrome, 49–50
- Porter appliance, 93, 94f, 362, 363f
- Posterior crossbite
Brodie syndrome, 360–361,
372f–373f
buccal, 360, 372f–374f
case studies of, 364f–374f
clinical examination of, 361
definition of, 355
delayed treatment of, 357, 358f
differential diagnosis of, 361–362
early treatment of, 359, 362–366
etiology of, 356–357
functional shift as cause of, 359f
illustration of, 49f
lateral mandibular shift caused
by, 51
lingual, 360, 360f
mandibular shift and, 365f–366f,
369f–371f
maxillary arch constriction
associated with, 355, 357, 359
in mixed dentition, 367f
morphologic characteristics of, 355
mouth breathing as cause of,
356–357
palatal, 360
paraclinical evaluations, 362

- prevalence of, 355, 357
 in primary dentition, 368f
 scissors bite, 360
 thumb sucking as cause of, 133, 134f
 treatment of
 appliances, 362–364, 363f–364f
 Arnold expander, 363, 363f
 bonded expander, 364, 364f
 delayed, 357
 early, 359, 362–366
 fixed expanders, 362–364, 363f–364f
 Haas expander, 363, 363f
 Hyrax expander, 363, 363f
 quad helix, 362–363, 363f
 rapid expander with occlusal coverage, 364, 364f
 removable expanders, 364, 364f
 variations of, 358–361, 359f
 W-arch for correction of, 93
 Posterior facial height–anterior facial height ratio, 383, 383f
 Posterior teeth
 extrusion of, 402
 mesial migration of, 402
 Postnatal development of dentition, 28
 Preameloblasts, 20
 Premolars
 eruption of
 description of, 37–38, 38b
 E space preservation for, 110, 110f
 maxillary canine eruption before, 239
 second molars eruption before, 239
 mandibular, 238f
 second
 ankylosis of, 165, 165f
 hypodontia of, 172–174, 180f–181f
 transposition of, 247f, 282, 283f
 supernumerary, 195
 transposition of, 245
 Preventive orthodontic treatment, 4
 Primary dentition
 ankylosis of, 31
 bud stage of, 17f–18f, 17–18
 calcification stage of, 20–21
 canines
 early loss of, 403
 extraction of, 261–262
 overretained, 246
 premature exfoliation of, 118
 serial extraction of, 120
 cap stage of, 18, 18f
 Class III malocclusion treatment in, 333, 334f
 classification of, 28
 crown stage of, 21, 21f
 deep bite in, 403
 delayed exfoliation of, 31
 dental lamina, 16f, 16–17
 early bell stage of, 18f, 18–19
 early exfoliation of, 31
 eruption of
 delayed, 233b
 description of, 28
 evaluation of, 48
 exfoliation of, 30–32, 229, 235–236
 frenum attachment abnormality management in, 213–214
 hypodontia of, 172
 importance of, 30
 initiation stage of, 16f–17f, 16–17
 late bell stage of, 19f–20f, 19–20
 life history stages of, 16
 loss of
 premature, 74
 space lost after, 75
 molecular level of, 22–23
 morphodifferentiation stage of, 19f–20f, 19–21
 overretained, 172
 posterior crossbite in, 368f
 premature loss of, 74
 root formation, 22, 22f
 root resorption of, 32, 282
 sequential stripping of, 109
 spacing in, 28, 29f
 studies of, 22–23
 terminal plane of, 29f, 29–30
 Primary epithelial band, 16
 Primary failure of tooth eruption, 236–238, 237f
 Primary molars
 ankylosis of, 37, 165
 extraction of, 241
 Primate spaces, 28, 29f
 Profile
 lateral, 55
 photographic evaluation of, 55
 space analysis and, 79
 types of, 47, 47f, 53
 Prosthesis
 fiber-reinforced composite resin
 fixed partial denture, 170
 lateral incisor hypodontia
 managed with, 169–171
 removable partial denture, 170
 Pseudo-Class III malocclusion
 case studies of, 325f–329f
 definition of, 323
 delayed treatment of, 324, 330
 multiple incisor involvement in, 323
 removable appliances for, 324, 324f
 signs of, 323
 treatment of, 323–324, 324f
 Psychologic problems, 11
 Puberty, 59
- Q**
 Quad helix, 93, 94f, 136, 137f, 362–363, 363f
 Questionnaire, 42–44
- R**
 Radiation therapy, 236
 Radiographs
 ankylosis, 283
 bitewing, 58
 canine impaction, 258f–259f, 258–260
 cephalometric, 66–67, 68b, 101f, 116–117
 delayed tooth eruption, 234, 234f
 digital, 59
 extraoral, 58–59
 hand-wrist, 59
 intraoral, 58
 lateral jaw, 58–59
 longitudinal, 60, 61f–65f
 occlusal, 58
 panoramic, 60, 61f–65f, 116
 periapical, 58, 211, 211f
 before serial extraction, 116
 supernumerary teeth, 197, 197f
 RANK. *See* Receptor activator for nuclear factor κ B.
 RANKL. *See* Ligand for receptor activator for nuclear factor κ B.
 Rapid palatal expander, 364, 364f
 Receptor activator for nuclear factor κ B, 30
 Reciprocal induction, 20
 Reduced dental epithelium, 24
 Reminder therapy, for non-nutritive sucking, 135
 Removable bite plate appliance, 403
 Removable expanders, 94
 Removable orthodontic appliances, 136, 137f, 243, 298, 324, 324f
 Removable partial denture, for lateral incisor hypodontia, 170
 Removable space maintainers, 85f–86f, 85–86
 Removable space regainers, 89f, 89–90
 Retained infantile swallow, 140
 Reward therapy, for non-nutritive sucking, 135
 Ricketts' esthetic line, 56
 Root development, 117
 Root formation
 illustration of, 22, 22f
 tooth eruption and, 227
 Root resorption
 crescent moon-shaped, 118, 119f
 primary tooth, 32
 regulation of, 30
 Rule of fifths, 46, 56, 57f
- S**
 Sagittal expansion, 90–92, 91f–92f, 99f
 Schwartz removable slow expander, 94f
 Scissors bite, 360
 Second molars
 eruption of, before premolars, 239
 mandibular
 impaction of, 119, 119f
 terminal plane, 32, 33f
 maxillary, 32, 33f
 Second premolars
 hypodontia of, 172–174, 180f–181f
 transposition of, 247f, 282, 283f
 Secondary spaces, 28–29
 Secondary spacing, 36, 36f
 Sectional bracketing, 89, 89f
 Sequential selective enamel stripping, 90
 Sequential stripping of primary teeth, 109
 Serial extraction
 in Class I malocclusions, 119–122, 121f, 124f–126f
 in Class II malocclusions, 122–123
 in Class III malocclusions, 123
 clinical examination before, 116
 crowding measurements before, 117
 definition of, 115
 description of, 9
 diagnostic procedures before, 116–117
 historical background of, 115

- mandible, 122–123
maxilla, 122–123
occlusal considerations, 117
in open bite, 123
paraclinical examinations before, 116–117
planning for, 117–119
sequence of, 120–122
skeletal pattern and, 117–118
timing of, 120
 Single-tooth implant, for lateral incisor hypodontia, 169–170, 171f
- Skeletal deep bite, 398–399
Skeletal maturation assessment, 59
Skeletal maturity, 59
Sleep disorders, 148
Sliding loop regainer, 87–88, 88f
Social evaluation, 43
Soft tissue
 evaluation of, 49–51, 66
 hypodontia effects on, 166
Soft tissue profile, 91, 117, 312f
Somatic swallowing, 142
Space analysis
 Bolton, 54, 78, 79f
 considerations in, 79–80
 definition of, 77
 Merrifield, 78
 methods of, 54
 mixed dentition, 52–54
 Moyers, 78
 Nance, 54, 77–78
 Staley and Kerber, 78
 study casts for, 52–54
 Tanaka and Johnston, 78
 types of, 77–78
Space closure
 canine substitution for, 168–169
 description of, 74–75, 94
 frenectomy before, 215f
 mandibular second premolar hypodontia, 173
Space creation
 case studies of, 96
 definition of, 90
 maxillary canine impaction treated with, 261
 moderate incisor crowding treated with, 110
 sagittal expansion for, 90–92, 91f–92f, 99f
 sequential selective enamel stripping, 90, 109
 tooth extraction for, 90
 transverse expansion for, 92–94, 94f, 99f
Space maintainers
 functional fixed, 84f, 84–85
 nonfunctional fixed
 bilateral, 82, 83f
 unilateral, 82
 qualities of, 81
 removable, 85f–86f, 85–86
Space maintenance
 contraindications for, 80–81
 definition of, 80
 indications for, 80
 space closure as, 74–75, 94
 space maintainers for. *See* Space maintainers.
Space management
 case studies of, 96–102
 diagnostic procedures used in, 77–80
 fundamentals of, 73–77
 planning for, 77–80
 treatment options for, 80–95
Space regainers, 87–90, 88f–89f
Space regaining, 86–90, 88f–89f, 97f, 102f
Space supervision
 case study of, 100f–101f
 combination approach, 110–111
 definition of, 95
 E space preservation, 110, 110f
 methods of, 109–111
 sequential stripping of primary teeth, 109
Speech
 development of, 30
 physiology of, 150
Speech problems
 early incisor loss and, 85
 malocclusion and, 50, 150–151
 soft tissue causes of, 151
 tongue thrust as cause of, 142
Staley and Kerber analysis, of space, 78
Stellate reticulum, 18, 19f, 30
Step-type anterior arch, 383, 383f
Stomion plane, 56
Stomodeum, 16f, 16
Straight facial profile, 47f
Stratum intermedium, 18, 19f
Subnasale line, 56
Sucking, non-nutritive. *See* Non-nutritive sucking.
Sudden infant death syndrome, 139, 148
“Sunday bite,” 51
Supernumerary teeth. *See also* Hyperdontia.
 case studies of, 198f–202f
 classification of, 194, 194b
 definition of, 189
 early recognition of, 197
 ectopic eruption of, 194–195
 ethnicity and, 190, 191t
 etiology of, 192
 sex and, 190, 191t
 genetic syndromes associated with, 192
 incisor impaction caused by, 273, 274f, 279f
 late development of, 195, 202
 location of, 190, 191t
 management of, 197–198
 maxillary canine impaction and, 255
 multiple, 190
 orthodontic considerations after removal of, 198
 prevalence of, 189–191, 190t–191t
 radiographic examination of, 197, 197f
Swallowing
 physiology of, 50, 139–140, 381
 types of, 142
- T**
Tanaka and Johnston analysis, of space, 78
Taurodontism, 162, 164–165
Temporomandibular disorders, 152
Temporomandibular joint
 function assessments, 51
 malfunction of, 401
Terminal plane, 29f, 29–30, 32, 33f
Tetracycline-related enamel discoloration, 21
Three-phase treatment plan, 8
Thumb sucking, 132–136, 134b, 134f, 209, 209f, 384f
Tongue
 clinical examination of, 142
 dysfunction of, 142
 force abnormality of, open bite caused by, 378, 379f
 functions of, 49–51, 50f
 occlusal development affected by, 27
 posture of, 50, 50f
 size of, 49–50, 142
 tonsil effects on, 50f
Tongue crib–transpalatal arch appliance, 136, 137f, 382, 383f
Tongue guard, 143, 143f
Tongue thrust
 anterior, 141, 141f
 bilateral, 141–142
 case studies of, 138f, 144f–145f
 classification of, 140
 clinical examination of, 142–143
 complex, 140
 definition of, 139
 development of, 140
 etiology of, 140–141
 lateral, 141f, 141–142
 macroglossia associated with, 141, 141f
 mechanotherapy for, 143, 143f
 myofunctional therapy for, 143
 open bite caused by, 140, 141f, 142, 379, 381, 387f
 oral habit training for, 143
 problems associated with, 142
 retained infantile, 140
 simple, 140
 speech problems secondary to, 142
 treatment of, 143, 143f–145f
 types of, 141–142
Tongue-tie. *See* Ankyloglossia.
Tooth agenesis. *See* Hypodontia.
Tooth buds, 17, 17f, 19, 25, 28, 225, 246
Tooth development. *See* Dentition development.
Tooth emergence, 75–76, 229. *See also* Tooth eruption.
Tooth eruption
 abnormal sequence of, 239–241
 ankylosis. *See* Ankylosis.
 asymmetric, 48, 240–241
 bone remodeling effects on, 228
 cellular bases of, 228
 characteristics of, 229
 definition of, 28, 225
 delayed, 48, 232–235, 233b, 233f
 dental follicle effects on, 227
 description of, 24
 disturbances of, 229–231, 231b
 ectopic
 definition of, 241
 permanent canines, 243, 244f
 permanent first molars, 241–242, 242f
 prevalence of, 241

- eruptive phase of, 226
 factors that disturb
 achondrodysplasia, 230
 cleidocranial dysostosis, 231
 Down syndrome, 231
 genetic, 230–231
 hypothyroidism, 230
 local, 231
 overview of, 229–230
 systemic, 230
 factors that influence, 76
 failure of, 236–238, 237f
 general pattern of, 80
 guidance of, 95
 hydrostatic pressure and, 227
 mechanisms of, 226–228
 molecular bases of, 228
 periodontal ligament effects on, 227–228
 phases of, 226
 posteruptive phase of, 226
 prediction of, 75–76
 pre-eruptive phase of, 226
 primary dentition, 28
 retarded, 238–239
 root formation and, 227
 sequence of, 37
 stages of, 229
 timing of, 76
 tooth transposition. *See* Tooth transposition.
- Tooth germs, 28, 226
 Tooth grinding. *See* Bruxism.
 Tooth impaction
 definition of, 254
 ectopic, 260, 262f, 268f
 incisors. *See* Incisor(s), impaction of.
 mandibular canines, 265
 maxillary canines. *See* Maxillary canines, impaction of.
- Tooth migration, 26, 210, 210f, 247
 Tooth movement
 bone support in edentulous areas
 achieved through, 171
 early-age orthodontic treatment
 effects on need for, 12
 Tooth size–arch length discrepancy
 description of, 106–107
 space deficiency caused by, 123
 Tooth transposition
 case studies of, 249f–253f
 in children, 246f
 complete, 244, 250f
 definition of, 244
 dental anomalies associated with, 244
 description of, 164
 diagnosis of, 248
 etiology of, 246–247
 incidence of, 245
 incomplete, 244, 248
 treatment of, 248
 Tooth-supported restorations
 lateral incisor hypodontia
 managed with, 169–170
 mandibular second premolar
 hypodontia managed with, 173–174
 Tooth-supporting tissues, 22f, 23–24
 Transcription factors, 23
 Transitional dentition
 definition of, 32
 dimensional arch changes during, 38
 eruption problems, 60
 incisor crowding during, 110
 panoramic radiographs of, 116
 phase I, 32–34, 33f–34f
 phase II, 34f–36f, 34–36
 phase III, 37
- Transpalatal arch, 82, 83f
 Transposition. *See* Tooth transposition.
 Transverse expansion
 indications for, 93
 space creation through, 92–94, 94f, 99f
 Trauma
 ankylosis caused by, 282
 facial, 162
 incisor impaction caused by, 273
 Treatment planning
 cephalometric radiography for, 67
 description of, 41–42
 serial extraction, 117–119
 Trisomy 21. *See* Down syndrome.
 2 x 4 bonding, 88–89, 89f, 97, 122, 319, 324
 Two-phase orthodontic treatment, 5, 9–10
- U**
 “Ugly duckling” stage, 35f, 35–36, 205, 257, 258f
 Upper lip–lower lip height ratio, 46, 47f
 Utility arch, 404
- V**
 Vertical dimension of occlusion, 293
 Vertical drift, 26
 Vestibular lamina, 17, 17f
 Visceral swallowing, 142
- W**
 W-arch, 93, 94f, 362, 363f
 Warford analysis, 260, 261f
 Wax bite, 51
 Weinberger appliance, 242, 243f
 Wiskott-Aldrich syndrome, 236
 Wnt signaling pathway, 161