



Review Article

Laparoscopic Ovarian Transposition Before Pelvic Cancer Treatment: Ovarian Function and Fertility Preservation

Nash S. Moawad, MD, MS, FACOG*, Estefania Santamaria, BS, Alice Rhoton-Vlasak, MD, and Judith L. Lightsey, MD

From the Section of Minimally Invasive Gynecologic Surgery, Department of Obstetrics and Gynecology (Dr. Moawad), Division of Reproductive Endocrinology & Infertility, Department of Obstetrics and Gynecology (Dr. Rhoton-Vlasak), Department of Radiation Oncology (Dr. Lightsey), and University of Florida College of Medicine (Ms. Santamaria), Gainesville, Florida.

ABSTRACT Survivors of pelvic cancer treatment live with the ramifications of pelvic radiation for many years after their cure. Several options are available to preserve ovarian function and fertility in reproductive age women undergoing pelvic radiation. Laparoscopic ovarian transposition is an under-utilized, yet fairly simple surgical procedure to relocate the ovaries away from the radiation field. Although randomized-controlled trials on the outcomes of ovarian transposition are scarce, there is a growing body of evidence on the risks and benefits of this procedure, in terms of prevention of premature ovarian failure, and potentially preserving fertility. In this review, we summarize the available data on the indications, patient selection and outcomes of ovarian transposition, as well as illustrate the technique of the procedure. *Journal of Minimally Invasive Gynecology* (2017) 24, 28–35 Published by Elsevier Inc. on behalf of AAGL.

Keywords: Laparoscopy; Oophorectomy; Ovarian transposition; Ovariectomy; Pelvic malignancy

The American Cancer Society estimates that more than 15.5 million Americans with a history of cancer are living in the United States, and this number is expected to exceed 20 million over the next decade [1]. Two of the most prevalent cancers in women are uterine (757 000) and colorectal (727 000) cancers [1]. Increasing numbers of cancer survivors are confronted with morbidity secondary to exposure to chemotherapy and radiation treatments. For reproductive-aged women, the reserve of primordial follicles in the ovary is fixed and declines with age at a fairly predictable rate (Fig. 1) [2]. Thus, any injury to the ovaries reduces this pool and accelerates a woman's reproductive aging.

The American Society of Clinical Oncology and the National Comprehensive Cancer Network recommend offering ovarian transposition as an option for optimizing fertility preservation in patients with cancer [3,4].

The authors declare that they have no conflict of interest.

Corresponding author: Nash S. Moawad, MD, MS, FACOG, Associate Professor, Minimally Invasive Gynecologic Surgery, Department of Obstetrics and Gynecology, University of Florida College of Medicine, P.O. Box 100294, Gainesville, FL 32610.
E-mail: nmoawad@ufl.edu

Submitted July 1, 2016. Accepted for publication August 27, 2016.
Available at www.sciencedirect.com and www.jmig.org

1553-4650/\$ - see front matter Published by Elsevier Inc. on behalf of AAGL.
<http://dx.doi.org/10.1016/j.jmig.2016.08.831>

Preserving ovarian function by sparing the ovaries from the direct deleterious effects of radiation can be accomplished with this procedure, which repositions the ovaries out of the field of radiation. The procedure is indicated for women of reproductive age who are undergoing pelvic or lower abdominal radiation therapy [5]. Recently, less invasive laparoscopic and robotic approaches to ovarian transposition have been successfully performed and described.

Methods

Sources

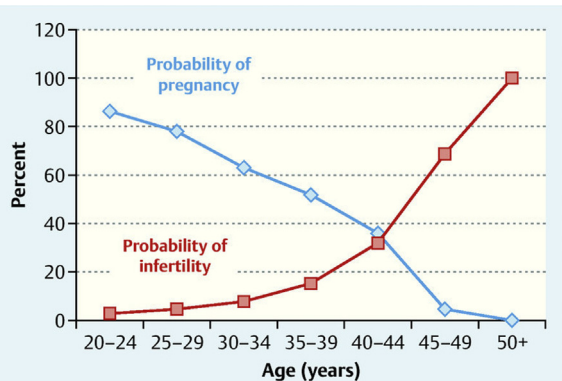
We conducted an electronic search of all research articles published in English without time restriction, using PubMed and Cochrane databases for studies of ovarian transposition. The text words used in the search included “ovarian transposition,” “ovariectomy,” and “oophorectomy.” References from articles were reviewed, and pertinent articles and reviews were used for the discussion.

Study Selection

The authors identified the appropriate articles for review. Of the 79 studies initially identified, 55 were selected after

Fig. 1

The reserve of primordial follicles in the ovary is fixed and declines with age at a fairly predictable rate. Graph obtained from Reference [2]; permission from Thieme.



limiting the review to clinical trials and case reports focusing on ovarian transposition in the context of cancer; 24 articles focusing on endometriosis and adnexal torsion were excluded. Given the rarity of ovarian transposition and the scarcity of data available from large, prospective, randomized trials, selection of studies was not limited by the design or the number of patients in the studies. We report the available data and describe the indications for ovarian transposition, the most commonly reported surgical techniques, the potential complications associated with this procedure, and prognoses and outcomes in the context of ovarian function and fertility preservation for patients who have the procedure done before undergoing pelvic radiation and chemotherapy.

Results

Indications for Ovarian Transposition

Female patients with gynecologic cancers, including cervical cancer, vaginal cancer, uterine cancer, and ovarian dysgerminomas, are candidates for ovarian transposition [6]. Ovarian transposition has also been used in nongynecologic cancers of the pelvis, including osteosarcoma, rhabdomyosarcoma, Hodgkin's lymphoma, anorectal carcinomas, and medulloblastoma before radiation therapy [7–13]. Cases of patients ranging from ages 11 to 40 have been reported in the literature. Women older than 40 years already have decreased ovarian reserve and are at higher risk for ovarian failure even with ovarian transposition [14]. Menopausal women and women at risk of developing ovarian metastases are inappropriate candidates for ovarian transposition. Additionally, women who will be receiving chemotherapeutic agents with a low probability of gonadotoxicity are candidates for the procedure. At gonadotoxic levels, systemic chemotherapy is deleterious to the ovaries, regardless of the anatomic location.

Surgical Techniques

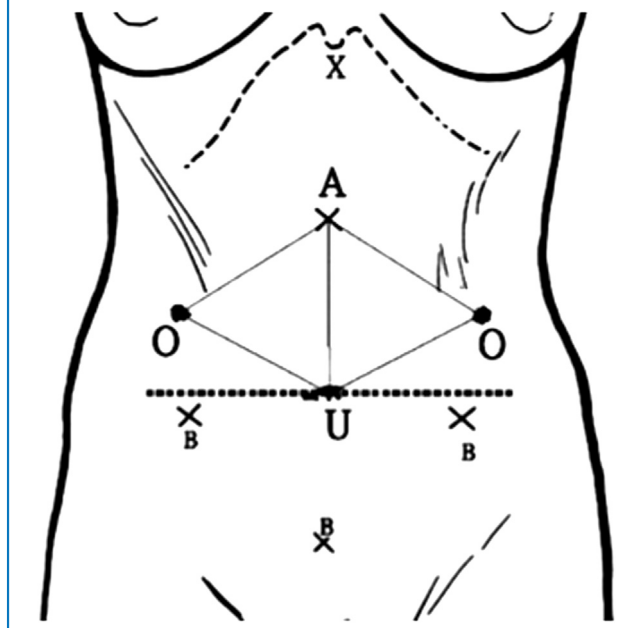
Two surgical techniques for laparoscopic ovarian transposition have been described in the literature: lateral and medial approaches. The uterus can be used as a shield from radiation in certain cancers like Hodgkin's lymphoma. For these patients, medial ovarian transposition has been described [15–18]. However, in a study comparing medial and lateral ovarian transposition in patients receiving pelvic irradiation for Hodgkin's disease, lateral ovarian transposition resulted in better outcomes [19]. Seventeen patients of childbearing age received total lymphoid irradiation, including pelvic and inguinal nodes. Fifteen of 17 patients underwent prophylactic bilateral oophorectomy during staging laparotomy: 10 underwent lateral transposition and 5 had midline fixation. Patients were followed for reproductive and ovarian function by menstrual history and serum hormonal assays for a minimum of 3 years. In 13 patients who remained in complete remission, normal cyclic ovarian activity was found in 7 of 9 patients after lateral transposition (including 1 pregnancy) but only in 1 of 4 cases after medial transposition. The authors concluded that lateral transposition should be preferred if ovarian protection is required before pelvic radiation [19].

Descriptions of the laparoscopic technique and variations using the lateral approach have been reported in the literature [20–22]. A video depicting the technique is also available for viewing [23]. The procedure is performed under general anesthesia with the patient in the Trendelenburg position. Because of the final destination of the transposed ovaries outside of the pelvic cavity, consideration should be given to higher trocar placement that commonly used in pelvic laparoscopy. The location of the midline incision for the optical trocar varies in the literature, with some articles reporting the incision 5 cm above the umbilicus and others reporting the Lee-Huang point, located 3 to 4 cm above the umbilical line at the midpoint between the umbilicus and the xyphoid process (Fig. 2) [21]. A Veress needle is then inserted at the umbilicus for insufflation with carbon dioxide to achieve adequate pneumoperitoneum, and the primary trocar is then inserted at the umbilicus, followed by the optical trocar at a more cephalad location.

Alternatively, open (Hasson) entry at the umbilicus can be performed, followed by the subxiphoid trocar insertion under laparoscopic guidance. The endoscopic camera is introduced through the subxiphoid port. A secondary trocar is placed in the midline at the umbilicus, in lieu of a suprapubic trocar, because of the higher region for operating outside of the pelvis, and 2 secondary trocars are placed in the paramedian lines at the same level of the umbilicus, which is higher than the typical lower quadrant trocar insertion for other gynecologic procedures. If a midline approach is chosen as described above, the surgeon and the assistant will be facing the pelvis during the procedure, with a monitor at the foot of the operating table. Alternatively, 2 ipsilateral ports can be used instead

Fig. 2

Trocar placement strategy. O: Final destination of the ovaries; A: Sub-xiphoid optical trocar site (Lee-Huang point); U: Umbilicus; B: Accessory trocar sites. Graph reprinted from Reference [24], with permission from Elsevier.

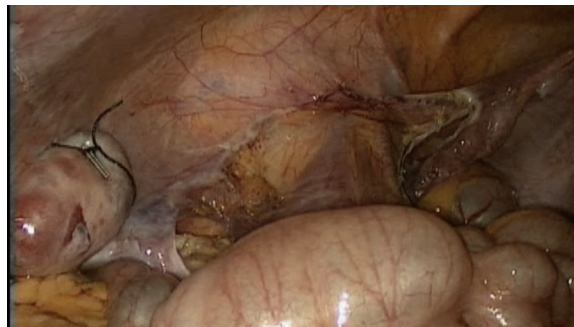

of the midline approach, with the surgeon looking at a monitor across the operating table. The authors prefer the use of minilaparoscopic instruments and trocars (3 mm) to facilitate healing.

After inspecting the abdominal and pelvic anatomy, each utero-ovarian ligament is coagulated and transected to provide mobility to the ovary. The use of a vessel-sealing cutting device may facilitate the procedure. The mesosalpinx and mesovarium are dissected (Fig. 3). Each ovary is then mobilized with its corresponding blood supply in the infundibulopelvic ligament attached and transposed to the anterolateral abdominal wall. Care is taken to incise the peritoneum outside of the mesosalpingeal vessels to avoid compromising the blood supply to the transposed ovaries. The peritoneum is incised alongside the infundibulopelvic ligament, with careful attention to the ureter medially, to allow for complete mobilization of the ovary. The fallopian tubes can be left intact in an attempt to allow for future spontaneous conception [25,26]. Other reports describe either removing the fallopian tubes during the procedure or transecting them and leaving them attached to the transposed ovaries [21,25–27]. Care is taken to adequately skeletonize the ovarian vessels to avoid kinking when the ovaries are pulled cephalad. The ovaries are then sutured securely at 2 to 3 points, using permanent sutures, to the transversalis fascia of the abdominal wall or the lower paracolic gutters (Fig. 4). Surgical clips are placed at the border of each ovary for identification during radiation therapy planning and administration (Figs. 5 and 6) [23].

Fig. 3

The mesosalpinx and mesovarium are dissected and the ovary is mobilized to the anterolateral abdominal wall.



Transposition of the ovaries greater than 1.5 cm above the iliac crest is associated with a higher chance of preservation of ovarian function after pelvic radiotherapy [28]. Mobilizing the large bowel medially may provide more space for higher transposition when needed in cases requiring iliac lymph node irradiation.

A few case reports detailing the medial approach technique have also been published. In this procedure, the utero-ovarian ligaments are coagulated and transected, as is done with the lateral approach. The ovaries are then fixed to their respective uterosacral ligaments behind the uterus and—as with the lateral approach—surgical clips are placed to mark the ovaries for identification during radiation treatment [15,16].

Variations to the described techniques have been reported in the literature. These include a surgical glove-single port technique and robotic-assisted ovarian transposition [29–31]. Yet another technique uses a percutaneous needle to transpose the ovaries; this procedure can be performed in the outpatient setting. A prospective study using percutaneous needle fixation demonstrated normal ovarian function in 11 of 12 patients diagnosed with

Fig. 4

Once an adequate length of the infundibulopelvic ligament is skeletonized, the ovary is sutured to the transversalis fascia using permanent sutures at 2–3 points to prevent ovarian torsion. Vascular clips are applied to the sutures as markers for radiation simulation.

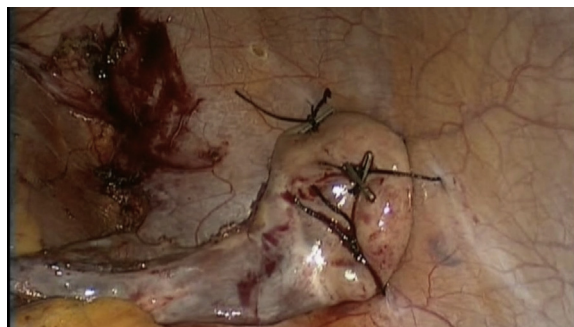
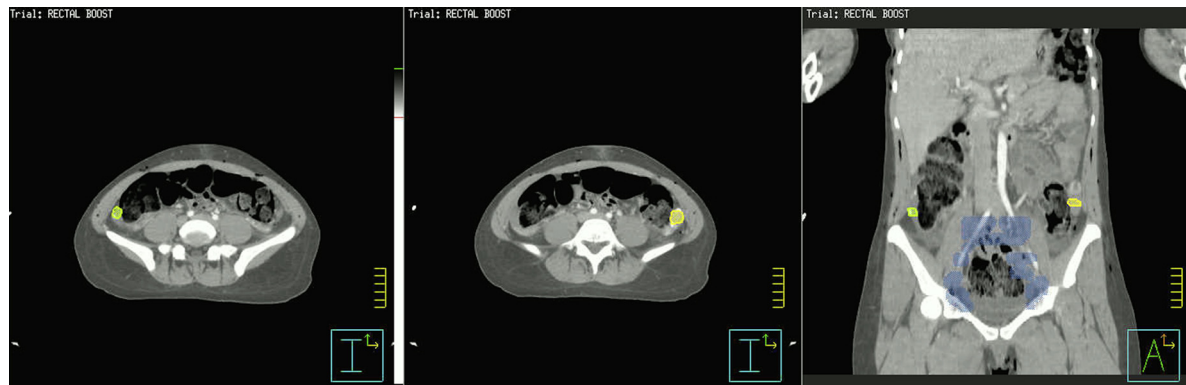

Fig. 5

The transpositioned ovaries (yellow) at their final location of L3–L4 upon radiation simulation.



either rectal cancer or Hodgkin’s lymphoma [32]. The study, however, did not report the exact time of follow-up when ovarian function was assessed.

Various reports describe different strategies to manage the fallopian tubes at the time of ovarian transposition. Bilateral salpingectomy has been performed at the time of ovarian transposition in several reports to evaluate for fallopian tube metastasis [21,27]. Sicam et al [27] reported completing ovarian transposition and bilateral salpingectomy on a 40-year-old woman diagnosed with stage IIB cervical carcinoma who was found to have fallopian tube metastasis on histologic evaluation. The surgeons’ rationale for performing bilateral salpingectomy was to detect possible occult metastases within the fallopian tubes and to reduce the risk of

hydrosalpinx secondary to postoperative adhesions. In their retrospective study, Huang et al [21] also performed bilateral salpingectomies on 14 patients for the latter reason.

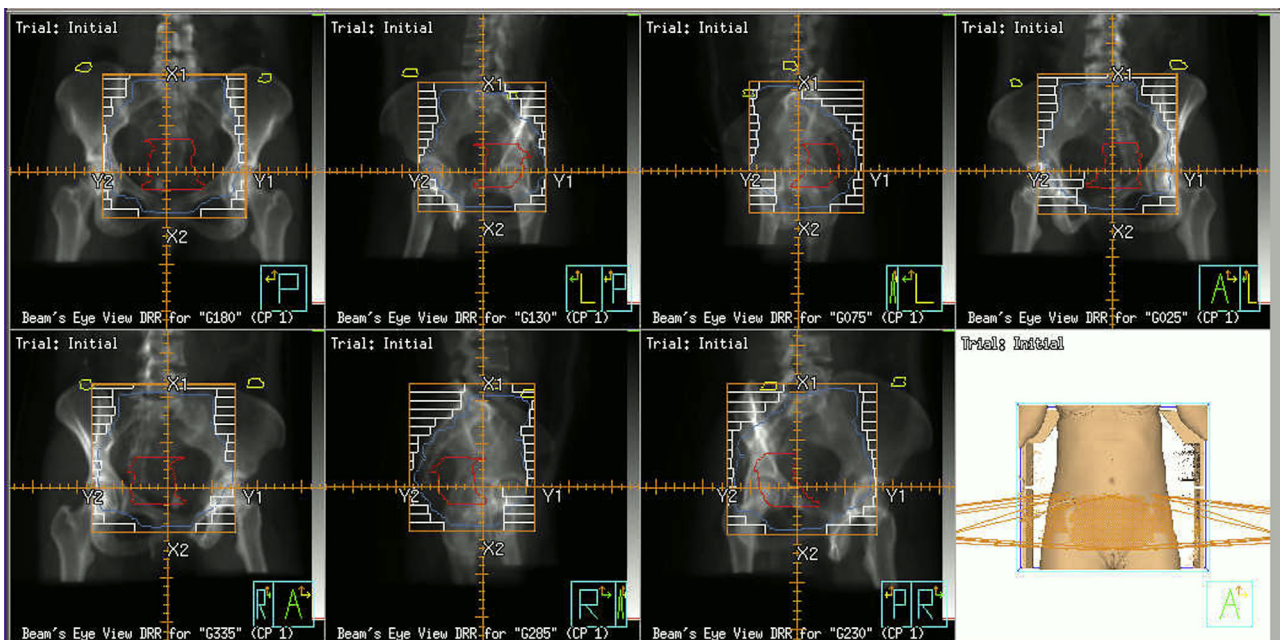
In cases where the fallopian tubes have been left intact during ovarian transposition, reports of spontaneous intrauterine pregnancies have been described [25,26]. No data are available regarding the risk of ectopic pregnancy after the preserved fallopian tubes have been exposed to radiation.

Ovarian Function After Ovarian Transposition

Multiple small studies have reported successful ovarian function preservation after ovarian transposition and chemoradiotherapy. In a study by Huang et al [21], only 1 of 7

Fig. 6

Radiation simulation showing the transpositioned ovaries (yellow) and their optimal location in relationship to the planned radiation field.



patients younger than 39 years developed ovarian failure as evidenced by elevated follicle-stimulating hormone levels, with a mean follow-up period of 72 months after receiving concurrent chemoradiation. Moreover, 1 meta-analysis calculated that ovarian transposition was associated with preservation of ovarian function in 90% of patients [6]. This was based on a number of subjective and objective data reported in the studies, including clinical symptoms and follicle-stimulating hormone, luteinizing hormone, and progesterone levels.

The rates of ovarian function preservation differ based on the type of cancer treatment the patient receives. In a prospective study of 107 patients with cervical cancer, 104 patients underwent bilateral ovarian transposition before surgery, vaginal brachytherapy, and/or external radiation therapy. The rates of ovarian function preservation differed depending on the type of radiotherapy; 90% of patients who underwent vaginal brachytherapy and 60% of patients who underwent external radiation therapy with vaginal brachytherapy had preserved ovarian function [24].

Fertility Preservation After Ovarian Transposition

Reproductive success after ovarian transposition has been reported in the literature [33]. A study reported 14 pregnancies (11 births and 3 miscarriages) after ovarian transposition in 11 women treated for Hodgkin's lymphoma during a median follow-up period of 14 years [26].

In patients with preserved ovarian function after ovarian transposition, ovulation induction and oocyte retrieval have been successfully performed transabdominally from the transposed ovaries [34,35]. Successful surrogate pregnancies have been reported using oocytes retrieved from patients after ovarian transposition and cancer treatment with radiation and/or chemotherapy [36–39].

Two case reports described a combined approach using cryopreservation and ovarian transposition to ensure reproductive success in the future [10,40]. The main advantage of embryo and oocyte cryopreservation is the proven ability to preserve fertility in the future if the patient becomes infertile or sterile. Both may remain frozen indefinitely. The disadvantages include the cost (not commonly covered by insurance), the 2- to 3-week delay to begin cancer therapy, high estradiol levels during stimulation that theoretically could affect prognosis, and need for an egg retrieval procedure. It is important to note that ovarian tissue cryopreservation remains experimental at this time, and its availability and cost vary widely depending on the institution.

Complications of Ovarian Transposition

Few complications of ovarian transposition have been reported. Gomez-Hidalgo et al [41] reported 2 cases of ovarian torsion after laparoscopic ovarian transposition. Absorbable sutures were used in these 2 cases. Ovarian contamination by

cancer cells is possible, especially when the primary cancer is likely to extend into gonadal tissue [42,43]. Picone et al [44] reported abdominal wall metastasis at the trocar site after ovarian transposition. A prospective study reported the development of benign ovarian cysts requiring oophorectomy in 2 patients who underwent ovarian transposition and pelvic radiation for cervical cancer [45]. Furthermore, Morice et al [46] reported 2 cases of ovarian metastasis 3 years after the end of treatment for stage IB squamous cell cervical carcinoma.

In addition to these reported complications and outcomes, there is also the risk of chronic pelvic or abdominal pain and Mittelschmerz pain and a risk of injury to the ovarian vessels during the procedure, which can compromise ovarian function. Torsion of the vascular pedicle can also compromise blood supply, but the risk is decreased if the ovary is fixed firmly in its final extrapelvic position in at least 2 to 3 points [47]. It is important to consider and counsel the patient appropriately regarding the general complications associated with surgery, such as the risk of anesthesia, bleeding, transfusion, injury to the bowel or the ureters, infection, venous thromboembolism, and the risk of reoperation.

Discussion

Radiation and chemotherapy can both reduce ovarian function, leading to infertility and premature ovarian failure. Premature menopause with long-term estrogen deprivation can lead to osteopenia and osteoporosis. Certain chemotherapy drugs increase the loss of primordial follicles, thus accelerating the process of normal reproductive aging. The effect of chemotherapeutic drugs on ovarian function depends on the type and dose of agents used and the number of treatment cycles. Additionally, the incidence of acute ovarian failure, infertility, and early menopause from chemotherapy correlates with the woman's age [48]. Cyclophosphamide and other alkylating agents such as busulfan, chlorambucil, procarbazine, and ifosfamide; some nonclassic alkylators such as dacarbazine and temozolomide; and heavy metals such as carboplatin and cisplatin are the most toxic to the ovaries [49,50]. When exposed to these chemotherapeutic medications, ovarian insufficiency can be transient or permanent. In children, ovarian insufficiency can lead to pubertal delay. The incidence of premature menopause in survivors of childhood cancers can reach up to 30% [51]. In older women, this can lead to low estradiol levels, oligomenorrhea, amenorrhea, impaired fertility, or, ultimately, premature ovarian failure. Women not receiving sterilizing doses of radiation therapy or chemotherapy may be able to conceive post-treatment but may be at increased risk of suffering complications during pregnancy [52].

Radiation therapy is an integral component in the management of several pelvic malignancies, including cancers of the cervix, endometrium, rectum, and bladder as well as lymphomas that involve the pelvic region. Doses required for the management of these various malignancies can range

from a minimum of 30 Gray (Gy) in divided doses for lymphoma to as high as 60 Gy or greater for locally advanced cervical carcinomas. The ovaries are exquisitely radiosensitive, and doses as low as 10 Gy can be associated with a high risk of ovarian failure.

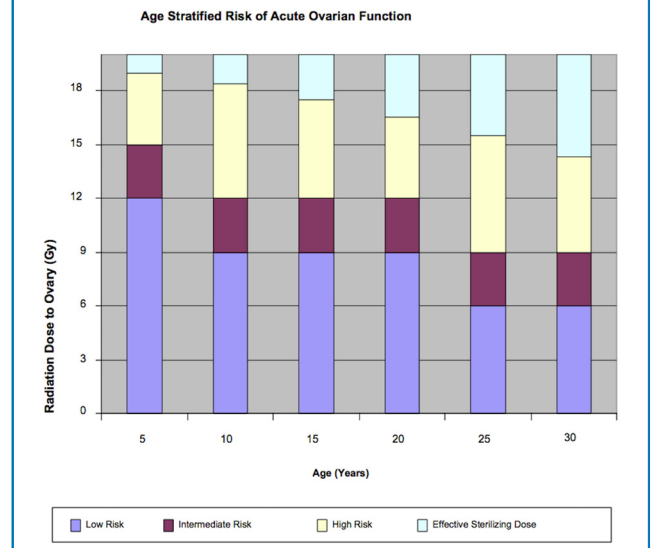
Natural atresia of ovarian primordial follicles begins at birth in a predictable manner (Fig. 1). Ionizing radiation can hasten this decline through direct DNA damage to ovarian follicles, leading to follicular atrophy and decreased ovarian follicular reserve. The amount of damage to the ovaries depends on the type of agent, the doses of radiation to which the patient is exposed, the age of the patient at the time of radiation exposure, and the extent of the radiation treatment field [53,54]. Mathematical models have been devised to estimate the dose required to induce ovarian failure. Wallace et al [53] extended that model to account for age at onset of radiation treatment (Fig. 7). Their model uses the effective sterilizing dose, defined as the dose of fractionated radiotherapy at which ovarian failure occurs in 97.5% of patients [53,55]. The effective sterilizing dose decreases with increasing age at treatment: at birth, effective sterilizing dose is 20.3 Gy; at 10 years, 18.4 Gy; at 20 years, 16.5 Gy; and at 30 years, 14.3 Gy. Figure 7 graphically depicts the risk of developing acute ovarian failure, defined as failure within 5 years of diagnosis, stratified by age and radiation dose to the ovary.

The combined effects of radiation therapy to the pelvis along with systemic chemotherapy are more damaging to the ovaries than 1 or the other alone. In a retrospective study of 162 premenopausal women with colon or rectal cancer who underwent adjuvant chemotherapy and chemoradiotherapy, more than 90% of patients with rectal cancer experienced long-term amenorrhea [56]. By itself, pelvic irradiation results in follicular loss, impaired follicular maturation, and cortical and capsular damage [57]. Abdominopelvic irradiation can lead to high rates of premature ovarian failure, with even less than 2 Gy, causing the loss of 50% of primordial follicles. Pelvic irradiation may also impair the uterus, leading to poor pregnancy outcomes. The pathophysiology seems to involve vascular, endometrial, and myometrial damage [58,59]. In some cases the only option to achieve a successful pregnancy may be with the use of a gestational surrogate, donor eggs, or both.

The decision to undergo ovarian transposition for fertility preservation depends on each patient's clinical scenario and personal preferences. The American Society of Clinical Oncology, American Society of Reproductive Medicine, and American Academy of Pediatrics have guidelines regarding the options and recommendations for fertility preservation for women [4,60,61]. The options include embryo/oocyte cryopreservation, ovarian transposition, ovarian tissue freezing with retransplantation (experimental), and the use of gonadotropin-releasing hormone agonists [62]. The woman's current state of health should be considered, because some women with severely debilitating cancers may be too ill to undergo any fertility preservation procedure [54].

Fig. 7

The risk of developing AOF increases with increasing radiation doses to the ovaries. Graph obtained from Reference [55]; permission from Elsevier.



Research indicates that many patients with a cancer diagnosis do not receive adequate information regarding fertility preservation. Less than half of cancer patients are referred to a reproductive specialist [63–65]. Despite the American Society of Clinical Oncology, American Academy of Pediatrics, and American Society of Reproductive Medicine guidelines and recommendations, a study reported that only 18% of oncologists had any patient resources on fertility preservation available and only 50% reported moderate to high confidence in knowledge regarding the subject [66]. Many barriers have been identified, including a lack of physician knowledge about fertility preservation options and resources, time constraints associated with assisted reproductive technologies and delaying the initiation of cancer therapy, and cost concerns and patient prognosis, especially with advanced disease. Women with cancer are interested in discussing fertility preservation, and their cancer care providers should address the possibility of infertility as soon as possible before the initiation of treatment [67]. The discussion will reduce stress and can improve patient satisfaction and the woman's quality of life in the long run [68]. Collaborative care between the oncology team, infertility specialists, psychologists, the patient, and her family can help ensure these women have access to such information and services. It is imperative to remember that for adult survivors, their cancer treatment is a distant memory, but the issue of infertility remains a present problem that limits their social lives and curtails their hope of a biologic family [69].

The lack of well-designed clinical trials limits the quality of available data on the outcomes of ovarian transposition. Other limitations in reviewing the outcomes of ovarian transposition are the lack of comparative data regarding the different types of radiotherapy, the different

chemotherapeutic agents used in the literature, and the heterogeneity of the patient populations and the techniques used. With an understanding of these limitations, the authors endeavored to review the available literature and to synthesize this concise summary for the gynecologic surgeon to adequately counsel affected patients, to maximize the utilization of fertility preservation options including ovarian transposition, to minimize the long-term impact of cancer on the patient's future, and to improve quality of life.

In conclusion, laparoscopic ovarian transposition is a feasible, safe procedure and is recommended by American Society of Clinical Oncology and National Comprehensive Cancer Network as an option for optimizing fertility preservation. The procedure increases the odds of maintaining ovarian function and, as such, should be offered to women of reproductive age along with the other options available for fertility preservation. The under-utilization and the limited studies on laparoscopic ovarian transposition mandate the need for prospective randomized trials to better inform cancer treatment so that maintaining ovarian function after cancer cure is optimized.

References

- Miller KD, Siegel RL, Lin CC, et al. Cancer treatment and survivorship statistics, 2016. *CA Cancer J Clin*. 2016;66:271–289.
- Findeklee S, Lotz L, Heusinger K, Hoffmann I, Dittrich R, Beckmann MW. Fertility Protection in female oncology patients: how should patients be counseled? *Geburtsh Frauenh*. 2015;75:1243–1249.
- NCCN Clinical Practice Guidelines in Oncology: Cervical Cancer. National Comprehensive Cancer Network; 2016. Available from: <https://www.tri-kobe.org/nccn/guideline/gynecological/english/cervical.pdf>. Accessed September 21, 2016.
- Loren AW, Mangu PB, Beck LN, et al. Fertility preservation for patients with cancer: American Society of Clinical Oncology clinical practice guideline update. *J Clin Oncol*. 2013;31:2500–2510.
- Ray GR, Trueblood HW, Enright LP, Kaplan HS, Nelsen TS. Oophorectomy: a means of preserving ovarian function following pelvic megavoltage radiotherapy for Hodgkin's disease. *Radiology*. 1970;96:175–180.
- Gubbala K, Laios A, Gallos I, Pathiraja P, Haldar K, Ind T. Outcomes of ovarian transposition in gynaecological cancers; a systematic review and meta-analysis. *J Ovar Res*. 2014;7:69.
- Al-Asari S, Abduljabbar A. Laparoscopic ovarian transposition before pelvic radiation in rectal cancer patient: safety and feasibility. *Ann Surg Innov Res*. 2012;6:9.
- Elizur SE, Tulandi T, Meterissian S, Huang JY, Levin D, Tan SL. Fertility preservation for young women with rectal cancer—a combined approach from one referral center. *J Gastrointest Surg*. 2009;13:1111–1115.
- Shou H, Chen Y, Chen Z, Zhu T, Ni J. Laparoscopic ovarian transposition in young women with cervical squamous cell carcinoma treated by primary pelvic irradiation. *Eur J Gynaecol Oncol*. 2015;36:25–29.
- Gavrilova-Jordan L, Rowe MS, Ballenger CA, Mersereau JE, Hayslip CC. Emergent oocyte cryopreservation with a novel ovarian transposition technique in a colorectal cancer patient: a combined approach for fertility preservation. a case report. *J Reprod Med*. 2015;60:354–358.
- Salakos N, Bakalianou K, Iavazzo C, et al. The role of ovarian transposition in patients with early stage cervical cancer—two case reports. *Eur J Gynaecol Oncol*. 2008;29:280–281.
- Farber LA, Ames JW, Rush S, Gal D. Laparoscopic ovarian transposition to preserve ovarian function before pelvic radiation and chemotherapy in a young patient with rectal cancer. *Medsc Gen Med*. 2005;7:66.
- Mitchell JD, Hitchen C, Vlachaki MT. Role of ovarian transposition based on the dosimetric effects of craniospinal irradiation on the ovaries: a case report. *Med Dosimetry*. 2007;32:204–210.
- Barahmeh S, Al Masri M, Badran O, et al. Ovarian transposition before pelvic irradiation: indications and functional outcome. *J Obstet Gynaecol Res*. 2013;39:1533–1537.
- Sola V, Ricci P, Baeza MR, Lema R, Pardo J. Preservation of ovarian function in young woman with Hodgkin disease by laparoscopic medial transposition before abdominal irradiation. *Surg Laparosc Endosc Percutan Techn*. 2008;18:423–425.
- Scott SM, Schlaff W. Laparoscopic medial oophorectomy prior to radiation therapy in an adolescent with Hodgkin's disease. *J Pediatr Adolesc Gynecol*. 2005;18:355–357.
- Williams RS, Littell RD, Mendenhall NP. Laparoscopic oophorectomy and ovarian function in the treatment of Hodgkin disease. *Cancer*. 1999;86:2138–2142.
- Lester-Coll NH, Morse CB, Zhai HA, et al. Preserving fertility in adolescent girls and young women requiring craniospinal irradiation: a case report and discussion of options to be considered prior to treatment. *J Adolesc Young Adult Oncol*. 2014;3:96–99.
- Grabenbauer GG, Girke P, Wildt L, Muller RG, Herbst M, Sauer R. [Ovariopexy and the treatment of Hodgkin's disease]. *Strahlenther Onkol*. 1991;167:273–276.
- Eitan R, Krissi H, Beller U, et al. Laparoscopic adnexal transposition: novel surgical technique. *Int J Gynecol Cancer*. 2011;21:1704–1707.
- Huang KG, Lee CL, Tsai CS, Han CM, Hwang LL. A new approach for laparoscopic ovarian transposition before pelvic irradiation. *Gynecol Oncol*. 2007;105:234–237.
- Visvanathan DK, Cutner AS, Cassoni AM, Gaze M, Davies MC. A new technique of laparoscopic ovariopexy before irradiation. *Fertil Steril*. 2003;79:1204–1206.
- Moawad N, Santamaria, E. Ovarian transposition. YouTube: Green Journal, 2016. Available from: https://youtu.be/q-DAYY_gsBQ. Accessed September 21, 2016.
- Morice P, Juncker L, Rey A, El-Hassan J, Haie-Meder C, Castaigne D. Ovarian transposition for patients with cervical carcinoma treated by radiosurgical combination. *Fertil Steril*. 2000;74:743–748.
- Kurt M, Uncu G, Cetintas SK, Kucuk N, Guler S, Ozkan L. Successful spontaneous pregnancy in a patient with rectal carcinoma treated with pelvic radiotherapy and concurrent chemotherapy: the unique role of laparoscopic lateral ovary transposition. *Eur J Gynaecol Oncol*. 2007;28:408–410.
- Terenziani M, Piva L, Meazza C, Gandola L, Cefalo G, Merola M. Oophorectomy: a relevant role in preservation of ovarian function after pelvic irradiation. *Fertil Steril*. 2009;91:935.
- Sicam RV, Huang KG, Lee CL, Chen CY, Ueng SH. Treatment of fallopian tube metastasis in cervical cancer after laparoscopic ovarian transposition. *J Minim Invasive Gynecol*. 2012;19:262–265.
- Hwang JH, Yoo HJ, Park SH, et al. Association between the location of transposed ovary and ovarian function in patients with uterine cervical cancer treated with (postoperative or primary) pelvic radiotherapy. *Fertil Steril*. 2012;97:1387–1393.
- Molpus KL, Wedergren JS, Carlson MA. Robotically assisted endoscopic ovarian transposition. *JSLs*. 2003;7:59–62.
- Al-Badawi I, Al-Aker M, Tulandi T. Robotic-assisted ovarian transposition before radiation. *Surg Technol Int*. 2010;19:141–143.
- Ben Dhaou M, Zouari M, Jallouli M, Mhiri R. Single-port laparoscopic ovarian transposition in an 11-year-old girl. *Arch Pediatr*. 2015;22:533–535.
- Gareer W, Gad Z, Gareer H. Needle oophorectomy: a new simple technique for ovarian transposition prior to pelvic irradiation. *Surg Endosc*. 2011;25:2241–2246.
- Ferrari S, Persico P, Di Puppo F, Giardina P, Ferrari A. Laparoscopic lateral ovarian transposition: a fertility sparing procedure. *Min Ginecol*. 2009;61:465–468.

34. Roberts J, Ronn R, Tallon N, Holzer H. Fertility preservation in reproductive-age women facing gonadotoxic treatments. *Curr Oncol*. 2015;22:294–304.
35. Steigrad S, Hacker NF, Kolb B. In vitro fertilization surrogate pregnancy in a patient who underwent radical hysterectomy followed by ovarian transposition, lower abdominal wall radiotherapy, and chemotherapy. *Fertil Steril*. 2005;83:1547–1549.
36. Giacalone PL, Laffargue F, Benos P, Dechaud H, Hedon B. Successful in vitro fertilization-surrogate pregnancy in a patient with ovarian transposition who had undergone chemotherapy and pelvic irradiation. *Fertil Steril*. 2001;76:388–389.
37. Agorastos T, Zafrakas M, Mastrominas M. Long-term follow-up after cervical cancer treatment and subsequent successful surrogate pregnancy. *Reprod Biomed Online*. 2009;19:250–251.
38. Zinger M, Liu JH, Husseinzadeh N, Thomas MA. Successful surrogate pregnancy after ovarian transposition, pelvic irradiation and hysterectomy. *J Reprod Med*. 2004;49:573–574.
39. Azem F, Yovel I, Wagman I, Kapostiansky R, Lessing JB, Amit A. Surrogate pregnancy in a patient who underwent radical hysterectomy and bilateral transposition of ovaries. *Fertil Steril*. 2003;79:1229–1230.
40. Martin JR, Kodaman P, Oktay K, Taylor HS. Ovarian cryopreservation with transposition of a contralateral ovary: a combined approach for fertility preservation in women receiving pelvic radiation. *Fertil Steril*. 2007;87:189.
41. Gomez-Hidalgo NR, Darin MC, Dalton H, et al. Ovarian torsion after laparoscopic ovarian transposition in patients with gynecologic cancer: a report of two cases. *J Minim Invasive Gynecol*. 2015;22:687–690.
42. Irtan S, Orbach D, Helfre S, Sarnacki S. Ovarian transposition in prepubescent and adolescent girls with cancer. *Lancet Oncol*. 2013;14:e601–e608.
43. Nguyen L, Brewer CA, DiSaia PJ. Ovarian metastasis of stage IB1 squamous cell cancer of the cervix after radical parametrectomy and oophorectomy. *Gynecol Oncol*. 1998;68:198–200.
44. Picone O, Aucouturier JS, Louboutin A, Coscas Y, Camus E. Abdominal wall metastasis of a cervical adenocarcinoma at the laparoscopic trocar insertion site after ovarian transposition: case report and review of the literature. *Gynecol Oncol*. 2003;90:446–449.
45. Pahisa J, Martinez-Roman S, Martinez-Zamora MA, et al. Laparoscopic ovarian transposition in patients with early cervical cancer. *Int J Gynecol Cancer*. 2008;18:584–589.
46. Morice P, Haie-Meder C, Pautier P, Lhomme C, Castaigne D. Ovarian metastasis on transposed ovary in patients treated for squamous cell carcinoma of the uterine cervix: report of two cases and surgical implications. *Gynecol Oncol*. 2001;83:605–607.
47. Hodel K, Rich WM, Austin P, DiSaia PJ. The role of ovarian transposition in conservation of ovarian function in radical hysterectomy followed by pelvic radiation. *Gynecol Oncol*. 1982;13:195–202.
48. Letourneau JM, Ebbel EE, Katz PP, et al. Acute ovarian failure underestimates age-specific reproductive impairment for young women undergoing chemotherapy for cancer. *Cancer*. 2012;118:1933–1939.
49. Committee opinion no. 607: Gynecologic concerns in children and adolescents with cancer. *Obstet Gynecol*. 2014;124(2 Pt 1):403–408.
50. Group CsO. Female health issues after treatment for childhood cancer. Female Health Issues. 2008 ed;2008. p. 6. Available from: <http://www.survivorshipguidelines.org/pdf/FemaleHealthIssues.pdf>. Accessed September 21, 2016.
51. Sklar CA, Mertens AC, Mitby P, et al. Premature menopause in survivors of childhood cancer: a report from the childhood cancer survivor study. *J Natl Cancer Inst*. 2006;98:890–896.
52. Sanders JE, Hawley J, Levy W, et al. Pregnancies following high-dose cyclophosphamide with or without high-dose busulfan or total-body irradiation and bone marrow transplantation. *Blood*. 1996;87:3045–3052.
53. Wallace WH, Thomson AB, Saran F, Kelsey TW. Predicting age of ovarian failure after radiation to a field that includes the ovaries. *Int J Radiat Oncol Biol Phys*. 2005;62:738–744.
54. Practice Committee of American Society for Reproductive Medicine. Fertility preservation in patients undergoing gonadotoxic therapy or gonadectomy: a committee opinion. *Fertil Steril*. 2013;100:1214–1223.
55. Wo JY, Viswanathan AN. Impact of radiotherapy on fertility, pregnancy, and neonatal outcomes in female cancer patients. *Int J Radiat Oncol Biol Phys*. 2009;73:1304–1312.
56. Wan J, Gai Y, Li G, Tao Z, Zhang Z. Incidence of chemotherapy- and chemoradiotherapy-induced amenorrhea in premenopausal women with stage II/III colorectal cancer. *Clin Colorect Cancer*. 2015;14:31–34.
57. Schwartz CL. *Survivors of Childhood and Adolescent Cancer: A Multidisciplinary Approach*. 2nd ed. Berlin: Springer; 2005.
58. Reulen RC, Zeegers MP, Wallace WH, et al. Pregnancy outcomes among adult survivors of childhood cancer in the British Childhood Cancer Survivor Study. *Cancer Epidemiol Biomark Prevent*. 2009;18:2239–2247.
59. Signorello LB, Cohen SS, Bosetti C, et al. Female survivors of childhood cancer: preterm birth and low birth weight among their children. *J Natl Cancer Inst*. 2006;98:1453–1461.
60. Fallat ME, Hutter J, American Academy of Pediatrics Committee on Bioethics, American Academy of Pediatrics Section on Hematology/Oncology, American Academy of Pediatrics Section on Surgery. Preservation of fertility in pediatric and adolescent patients with cancer. *Pediatrics*. 2008;121:e1461–e1469.
61. Practice Committees of American Society for Reproductive Medicine, Society for Assisted Reproductive Technology. Mature oocyte cryopreservation: a guideline. *Fertil Steril*. 2013;99:37–43.
62. Chen H, Li J, Cui T, Hu L. Adjuvant gonadotropin-releasing hormone analogues for the prevention of chemotherapy induced premature ovarian failure in premenopausal women. *Cochrane Datab System Rev*. 2011;CD008018.
63. Forman EJ, Anders CK, Behera MA. Pilot survey of oncologists regarding treatment-related infertility and fertility preservation in female cancer patients. *J Reprod Med*. 2009;54:203–207.
64. Peddie VL, Porter MA, Barbour R, et al. Factors affecting decision making about fertility preservation after cancer diagnosis: a qualitative study. *Br J Obstet Gynaecol*. 2012;119:1049–1057.
65. Woodruff TK. Oncofertility: a grand collaboration between reproductive medicine and oncology. *Reproduction*. 2015;150:S1–S10.
66. Duffy C, Allen SM, Dube C, Dickersin K. Oncologists' confidence in knowledge of fertility issues for young women with cancer. *J Cancer Educ*. 2012;27:369–376.
67. Penrose R, Beatty L, Mattiske J, Koczwara B. Fertility and cancer—a qualitative study of Australian cancer survivors. *Support Care Cancer*. 2012;20:1259–1265.
68. Kelvin JF, Thom B, Benedict C, et al. Cancer and fertility program improves patient satisfaction with information received. *J Clin Oncol*. 2016;34:1780–1786.
69. Morice P, Castaigne D, Haie-Meder C, et al. Laparoscopic ovarian transposition for pelvic malignancies: indications and functional outcomes. *Fertil Steril*. 1998;70:956–960.