

Patellofemoral Pain Syndrome

Introduction

Patellofemoral pain syndrome (PFPS) is a common musculoskeletal complaint that has been estimated to affect up to 25% of the general population, including physically inactive individuals, and nearly 40% of physically active individuals.¹ PFPS is the most common cause of knee pain and the second most common complaint presenting to outpatient physical therapy after low back pain.^{1,2} The term PFPS is often used to refer broadly to anterior knee pain, however, it specifically denotes retro- or peri-patellar pain behind or around the patella.^{3,4} Because PFPS and anterior knee pain are often *incorrectly* used interchangeably coupled with the reality that some patients may not seek healthcare services for this type of complaint, estimates for both prevalence and incidence vary greatly among publications.

Anatomy

The patellofemoral joint itself is comprised of the patella and the distal femur and surrounded by soft tissue structures. The patella, the largest sesamoid bone in the body, is embedded into the quadriceps muscle group tendon superiorly at its base and inserts into the patellar tendon inferiorly at its apex.⁵ Only the superior two-thirds of the posterior patella articulates with the trochlear groove of the distal femur, which is formed between the medial and lateral condyles, as the inferior pole of the patella narrows to form a tendinous insertion site.⁵ The patella's posterior surface is convex with medial and lateral facets separated by a longitudinal central ridge, all of which are covered by articular cartilage.⁵ The patella's anterior surface is also convex and generally considered in terms of its medial and lateral facets separated by a longitudinal median ridge.⁵ The lateral aspect of the patella is generally longer than the medial aspect to match the anatomy of the longer lateral femoral condyle.⁵ Similarly, the

orientation of the patella is also largely dependent on the bony anatomy of the distal femur. In addition to being longer superiorly to inferiorly, the lateral femoral condyle is also generally larger and extends further anteriorly to posteriorly than the medial condyle.⁵ The depth of the trochlear groove, measured as the sulcus angle, and how the patella is positioned within this groove varies based on these anatomical features of the femoral condyles.⁵

Bony anatomy of both the patella and femur varies affecting joint congruency and resultant stability. For this reason, surrounding soft tissue structures play a critical role in active and passive patellofemoral joint stability. The quadriceps muscle group, comprised of the rectus femoris, vastus medialis, vastus lateralis, and vastus intermedius, inserts into the patella as described above. This group of knee extensors, innervated by the femoral nerve, is the primary active stabilizer with a gross posterosuperior pull on the patella when engaged.⁵ Passive stabilizers include the medial and lateral patellofemoral ligaments (MPFL and LPFL), patellar retinaculum, and the iliotibial (IT) band.⁵ On the medial aspect of the joint, the vastus medialis, particularly the obliquus portion (VMO), and the MPFL act as active and passive primary restraints respectively against lateral translation of the patella during motion.⁵ Laterally, the retinaculum acts as a passive secondary restraint against lateral translation during motion.⁵

The bony anatomy and surrounding soft tissue structures described above combined with the tibial tubercle, where the patellar tendon inserts, form the extensor mechanism.^{5,6} Biomechanically, the patella acts as a pulley to increase the moment arm of the quadriceps muscle group and redirect their pull, which enhances biomechanical advantage by ultimately requiring less force from this muscle group when engaged.^{5,6} The patella is also crucial for achieving the last 30° of knee extension.⁶ During normal knee extension, the patella glides superiorly within the trochlear groove as a result of the pull at the quadriceps tendon.⁷ Movement

of the patella, termed patellar tracking, normally occurs in a C-shaped pattern wherein the patella moves slightly medially then slightly laterally back to neutral or in a straight line.⁷ The articular cartilage on the posterior surface of the patella, if healthy, aids smooth gliding by reducing friction during motion.⁵ As the knee approaches terminal extension, patellofemoral joint contact area decreases due decreased posteriorly-directed compressive forces from the quadriceps muscle group and its tendon actively and decreased patellar tendon tension passively.⁵ During normal knee flexion, the patella glides inferiorly in a reversed C-shaped pattern.⁷ Patellofemoral joint contact area increases as the knee approaches full flexion due to increased posteriorly-directed compressive forces actively and passively that engage the patella within the trochlear groove.⁵ In theory, however, the increased compressive forces are distributed across an increased contact area and should balance out to keep compressive stresses relatively low. Atypical bony anatomy or imbalanced soft tissue structures can affect normal patellar tracking, in addition to patellofemoral joint trauma, leading to maltracking and increased compressive stresses which both tend to affect the lateral aspect of the patellofemoral joint.⁵⁻⁷

Etiology

Much like the definition of PFPS, its aetiology can be nondescript and vary greatly among individuals but is generally considered to be multifactorial.⁴ Factors associated with PFPS can be anatomic, neuromuscular and anthropometric in origin, creating static malalignments and/or dynamic maltracking with subsequent increased compressive stresses and/or subluxation or dislocation. Related pathoanatomy and pathomechanics can be either causal or compounding.⁴ In pooled analysis, the following static malalignments have been significantly associated with PFPS: increased quadriceps angle (Q-angle), sulcus angle, and patellar tilt.⁴ The Q-angle (*Figure 1*) is formed in the frontal plane between intersecting lines from the midpoint of the patella to the

anterior superior iliac spine (ASIS) and to the tibial tubercle ipsilaterally.^{7,8} A normal Q-angle is considered roughly 15-18° for women and 12° for men with the greater width of the female pelvis explaining the difference between the sexes and likely why women are at a greater risk of developing PFPS than men.^{5,8,9} Increased Q-angle predisposes individuals to greater lateral translation of the patella during tracking, due to more lateralized bony and muscular anatomy, and potentially subluxation or dislocation.^{5,8,10} Abnormalities that cause increased knee valgus, such as hip abductor weakness or foot pronation, result in increased Q-angle.^{5,7} Next, the sulcus angle (*Figure 2*) is formed in the transverse plane between intersecting lines from the trochlear groove to the medial and lateral femoral condyles.^{5,11} The sulcus angle is considered a measure of both trochlear groove depth and patellofemoral joint congruency.^{5,11} A sulcus angle of roughly 135-140° is considered normal, and an increased sulcus angle indicates a shallower trochlear groove and decreased joint congruency.^{5,11} Finally, patellar tilt (*Figure 3*) can occur in both the transverse and sagittal planes but this terminology usually refers to mediolateral tilt in the transverse plane unless otherwise specified.⁶ Disagreement exists as to whether the patella should lie completely flat in the transverse plane or whether some degree of lateral tilt should be considered normal.¹ All three of these static malalignments are problematic, causing increased compressive stresses along the lateral aspect of the patellofemoral joint with additional concerns about instability (subluxation and dislocation) due to reduced joint congruency.⁶

In individual studies, additional static malalignments significantly associated with PFPS include: increased foot pronation and knee hyperextension, and decreased articular cartilage contact area.⁴ Foot pronation, namely subtalar joint pronation, drives internal rotation of the entire lower extremity segment. This positions the patella more lateral than normal relative to an internally rotated femur, which reduces total patellofemoral joint contact area and increases

contact pressure laterally.⁶ These compressive stresses are magnified when coupled with tight soft tissue structures laterally such as the IT band or retinaculum. Decreased articular cartilage contact area has a decreased ability to attenuate contact forces and results in increased contact pressure and potentially even damage to the subchondral bone.¹² Finally, knee hyperextension causes the patella to rest more proximal to the trochlear groove than normal and contributes to decreased patellofemoral joint congruency and increased instability.⁶

In pooled analysis, the following contributors to dynamic maltracking have been significantly associated with PFPS: decreased hip abduction and external rotation strength (as a percentage of body weight), and peak knee extension torque.⁴ Hip abductor and external rotator muscle weakness lead to excessive hip adduction and internal rotation and therefore increased knee valgus, thus increasing the Q-angle. Dynamic valgus magnifies lateral translation of the patella, especially if lateral soft tissues structures are tight, and the risk of subluxation or dislocation.^{5,6,10} Similarly, decreased peak knee extension torque suggests weakness of the quadriceps muscle group, which is responsible for stabilization of the patella during gliding, and can lead to maltracking in and of itself.⁶ In individual studies, hip weakness manifests as increased hip adduction and internal rotation angles and excursion, and therefore increased knee valgus and Q-angle, during dynamic activities such as single leg squats and jumps and running.⁴ Other factors include mediolateral muscle strength imbalances and reduced lower extremity flexibility of the quadriceps and hamstring muscle groups and the gastrocnemius complex.⁴ All of these can contribute to dynamic maltracking of the patella observed as the J-sign wherein the patella tracks laterally in a J-shape from a medial position out of the trochlear groove and remains.⁸

Notably, these pathoanatomy and pathomechanics can implicate structures beyond the immediate patellofemoral joint described initially and highlight the importance of a thorough lower extremity evaluation during the physical therapy examination. The subjective portion of the examination is no different than that for any other orthopedic complaint. Physical therapists must ascertain the “symptoms’ onset, mechanism of injury (MOI), location, character or description, severity under different conditions, and any aggravating or alleviating factors.”⁷ Physical therapists must also rule out red and yellow flags concurrent with systemic disease or infection that warrant immediate or eventual medical attention in order to determine that complaints are orthopedic in origin.^{7,10} For example, redness and swelling may be indicative of systemic disease/infection coupled with other symptoms like fever and chills rather than musculoskeletal pathology.

Diagnosis

Beyond ruling out red and yellow flags, PFPS can be difficult to recognize and diagnosis due to the varied presentation of anterior knee pain and associated complaints based on the pathoanatomy and pathomechanics involved.⁷ Complaints of dull aching or throbbing often suggest increased patellofemoral joint compressive stresses and worsen as the knee is positioned in flexion for extended periods of time such as prolonged sitting (“movie goers sign”).^{7,13} Similarly, individuals may be aggravated by activities requiring greater amounts of knee flexion such as deep squats and ascending or descending stairs.⁷ Notably, descending stairs is usually more problematic than ascending in severe or chronic cases of PFPS because of the eccentric quadriceps muscle group contraction required and resultant increased patellar loading.⁷ In comparison, patellar instability generally explains feelings of slipping, giving way or giving out.⁷ Even clinically small amounts of instability can cause these feelings since the extensor

mechanism has a decreased ability under this condition to provide active stabilization of the femur on the tibia during closed kinetic chain motion.⁷ Finally, lower extremity malalignments present with host of complaints that are usually generalized and vague.⁷ In addition to complaints related to compressive stresses, instability and malalignments, individuals often describe non-painful crepitus during motion, stiffness or tightness that improves with activity, and catching sensations not related to meniscal injury and/or swelling.¹³ Overuse injuries sustained from repetitive and/or intense training may present as acute exacerbations of chronic PFPS and, for this reason, are often considered a separate causal mechanism.^{7,13} Depending on the pathoanatomy and pathomechanics, individuals with overuse injuries may describe any combination of these complaints.^{7,13}

The recognition and diagnosis of PFPS is further complicated by the reality that anterior knee pain and associated complaints often explain other knee pathology both atraumatic and traumatic. Like the type of complaint can be suggestive of patellofemoral joint pathoanatomy and pathomechanics, the location of pain relative to the joint has been proposed as a schema for differential diagnosis.⁷ Pain proximal to the joint can suggest quadriceps tendonitis/tenodesis while pain distal to the joint may be the result of patellar tendonitis/tenodesis, impingement of Hoffa's fat pad (Hoffa's Syndrome), Osgood-Schlatter's Disease or Sinding-Larsen-Johansen's Syndrome, the latter which differ based on physeal involvement.⁷ Medial or lateral pain can result from retinacular neuromas on the respective aspects of the retinaculum or reflect abnormalities of soft tissue structures.⁷ For example, plica syndrome is responsible for pain medially while a tight IT band can cause irritation laterally.⁷ Finally, retropatellar pain can indicate damage to patellofemoral joint articular cartilage and subchondral bone like in the case of chondromalacia patellae and osteochondritis dissecans (OCD) respectively.⁷ Other conditions

for consideration in the differential diagnosis of PFPS include meniscal injuries and ligamentous instability, synovitis, bursitis and recurrent subluxation or dislocation of the patella irrespective of PFPS.^{7,13s}

Examination

The objective portion of the examination should complement the subjective portion to confirm musculoskeletal pathology, rule out differential diagnoses, and ascertain the correct diagnosis of PFPS. For the purpose of continuity, the physical examination can be organized into standing, seated and supine, side-lying and prone components followed by a functional examination. Within each component, sequencing includes observation, palpation, measurement and special testing as appropriate. Physical therapists should observe the patient in each position for any lower extremity abnormalities related to potential injury such as muscle atrophy, joint edema and effusion, bruising, scarring, etc.^{7,10} For example, atrophy of the VMO is common, however, not isolated in the quadriceps muscle group.^{10,14,15} Depending on the position or activity, physical therapists may also observe static malalignments or dynamic maltracking. Palpation and measurement for bony and soft tissue abnormalities aids observation. Palpation should also consider warmth, edema and effusion, skin and tissue quality, and abnormal protrubences.^{7,10} Given the multifactorial nature of PFPS aetiology, a battery of special testing is often indicated although tests vary greatly in terms of diagnostic accuracy.¹⁶

In standing, key lower extremity evaluation assessments for PFPS can be performed according to the three cardinal planes. In the frontal and saggital planes, postural assessment, including foot pronation, is vital. Foot pronation can be assessed both qualitatively and quantitatively according to the Navicular Drop Test, rearfoot to leg angle, medial longitudinal arch angle and the presence or absence of medial talonavicular bulge.^{7,17} A positive Navicular

Drop Test, the presence of medial bulge or increased rearfoot to leg and longitudinal arch angles indicate a pronated foot.^{18,19} Pronation noted statically on these assessments is most often exacerbated during dynamic activities, which is especially concerning.¹⁹ Additional considerations in the frontal plane include the Q-angle and the sagittal plane include knee hyperextension or flexion contractures. The effects of hyperextension have been described above and can be the result of quadriceps muscle group weakness or ligamentous laxity. Patella alta (*Figure 4*) is similar in that it causes the patella to rest more proximal to the trochlear groove than normal.⁶ With the knee in slight flexion, the most inferior portion of the patella should rest either at or slightly above the joint line.⁶ If this rests more than 20 millimeters above the joint line, the patella is considered a “patella alta,” while below the joint line is termed “patella baja/infera.”^{6,20} Patella alta is objectively worse than patella baja (*Figure 4*) as it requires greater knee flexion for the patella to reach the stability of the trochlear groove and, for this reason, predisposes individuals subluxation or dislocation.⁶ Patella baja, on the other hand, has been associated with wear and tear of articular cartilage like chondromalacia patella due to near-constant frictional abrasion.¹⁰ Knee flexion contractures, like the effects of patella baja, cause increased compressive stresses as a result of overuse of the quadriceps muscle group in attempts to generate knee extension.⁶ Finally, transverse plane assessments should include those for patellar forward orientation, like inward (“squinting”) or outward facing, pelvic symmetry and limb length equality.^{7,17} Although neither pelvic asymmetries nor limb length inequalities have been significantly associated with PFPS in individual studies, both cause disturbances up and down the kinetic chain and resultant compensations for either can mirror known PFPS factors such as foot pronation for equalization.⁴

Some clinicians enter directly into the functional examination following the standing portion of the physical examination, however, others prefer to save this for last to ascertain the severity of patient complaints before subjecting them to functional activity for the purpose of safety. In short sitting, some exam components may be repeated like assessment of patellar forward orientation and height. Additional components include assessment for patellar tracking, range of motion, and strength via traditional manual muscle testing. With the patient sitting back into the tripod position to relieve passive hamstring muscle group tension, the clinician should passively extend and flex the patient's knee looking for any abnormalities with patellar tracking like the J-sign or and range of motion limitations.⁷ This is followed by active knee extension and flexion looking for similar problems. Finally, manual muscles tests typically performed in short sitting include hip flexion and internal/external rotation and knee extension.⁷

In supine, goniometric measurement is introduced to assess passive and active range of motion as well as passive flexibility of the hamstring muscle group during the 90-90 Test.^{7,10} Other flexibility tests performed in this position include the Thomas Test for the hip flexors and passive ankle dorsiflexion with the knee extended and flexed for the gastrocnemius and soleus respectively.⁷ Here, patellar orientation and passive mobility assessment for the four potential primary abnormalities (gliding, rotation, horizontal tilt, and vertical tilt) is perhaps one of the most essential elements of PFPS evaluation.^{10,21} Finally, ligament testing may be indicated to rule out ligamentous instability from PFPS-related instability.⁷ In side-lying manual muscle testing continues for the abductors and adductors plus flexibility testing for the IT band with Ober's Test.^{7,10} Finally, the prone examination for PFPS concludes with manual muscle testing for hip extension and knee flexion and Ely's Test to assess flexibility of the rectus femoris.^{7,10} Other

considerations while in prone are femoral and tibial torsion and forefoot and rearfoot mobility and alignment.¹⁷

Patellar orientation, passive mobility and tracking assessment are all considered special tests but their diagnostic accuracy is generally poor and varies greatly among publications.¹⁶ The diagnostic accuracy, namely specificity, of apprehension and grind (Clarke Sign) testing are far superior.¹⁶ Apprehension testing (*Figure 5*) requires the patient be positioned in long-sitting or supine with the knee in 20-30° of flexion where the patella is passively glided medially and laterally.¹⁰ Apprehension during this activity, especially for lateral glides as most subluxation or dislocation stems from translation in this direction, is considered a positive test for both apprehension and instability.¹⁹ In the same position, grind testing (*Figure 6*) requires physical therapists apply pressure in an anterior-posterior direction just superior to the proximal pole of the patella then have the patient actively contract the quadriceps muscle group.¹⁰ Retropatellar pain or inability to maintain a muscle contraction is considered a positive grind test.¹⁰ Other common but less accurate special tests include the McConnell isometric and compression tests, which involve active quadriceps muscle group contraction with compression of the patellofemoral joint and while facilitating medial translation of the patella respectively.^{10,21}

Finally, the functional examination includes assessment of dynamic motion such as gait, step-ups, step-downs and squatting, which may explain dysfunction both observed and not observed statically.^{7,10} Step-ups and step-downs provide opportunities for qualitative assessment of neuromusculoskeletal strength and control. Individuals with PFPS often struggle with dynamic valgus affecting the entire lower extremity segment and may rely heavily on trunk or upper extremity compensations.⁷ Single- and double-leg squatting are similar in terms of abnormalities but compensations are more readily apparent during single-leg activities. Other

qualitative considerations during functional activities like these include quality of movement such as depth, smoothness and speed.⁷ Static malalignments and dynamic maltracking may be exploited to a lesser degree during gait than other functional activities, however, kinematic abnormalities generally include increased dynamic valgus and foot pronation and decreased velocity during normal walking, and ramp and stair negotiation among others depending on the involved pathoanatomy and pathomechanics.²²

Intervention

Anterior knee pain is a common complaint in general and sports medicine clinics that is most often referred for conservative treatment consisting of physical therapy and associated interventions.¹ Once physical therapists diagnosis this pain as PFPS, treatment generally focuses on addressing lower extremity static malalignments and dynamic maltracking of the patella. Like the aetiology of PFPS is multifactorial so is its treatment with combinations of exercise therapy, modalities, taping and orthotics, and by modifying activities as appropriate.²² Exercise therapy is considered neuromusculoskeletal strength and endurance training and stretching.²² In pooled analysis, exercise therapy is favored over no therapy for significant short-term (less than 12 weeks) pain reductions.²² Unfortunately, these results are not sustained at long-term (greater than 26 weeks) follow-up without continued exercise.²² The short-term and long-term effects on patient-reported measures of activity limitations and participation restrictions mirror those for pain reductions, favoring exercise therapy over no therapy at least in the short-term.²² This highlights the importance of helping patients develop maintenance exercise programs for the lower extremity beyond the episode of care to manage chronic PFPS complaints.

While there is no difference in terms of pain or limitation and participation between open and closed chain kinetic exercises, both knee and hip strengthening exercises are important for

patients with PFPS.^{22,23} Quadriceps strengthening provides increased stabilization of the patella in the femoral groove during gliding.²² VMO strengthening is especially important if muscle imbalances between the vastus lateralis and medialis result in lateral translation of the patella and resultant compressive stresses, subluxation or dislocation.²² Examples of quadriceps muscle group strengthening progression include isometric, seated and standing knee extension and terminal knee extension exercises, double- and single-legged squats, lunges, and step ups and downs.²²⁻²⁴ Hip strengthening, namely of the abductors and external rotators, limits adduction and internal rotation of the lower extremity segment preventing similar issues associated with valgus statically and dynamically.²²⁻²⁴ Strengthening exercises include abduction, external rotation and extension exercises done in side-lying, prone and standing and may overlap with some closed chain knee extension exercises.²²⁻²⁴ Stretching tight soft tissue structures is usually indicated for tissues proximal or lateral to the joint which may cause abnormally high compressive stresses and contribute to maltracking.^{22,24} In terms of additive therapies, there appears to be no additional benefits for pain, activity limitation or participation using electromyography (EMG) for biofeedback during exercise, however, taping and orthotics are associated with significant improvements in these domains.²² Based on limited, low-quality evidence, recommended modalities vary depending on the type of PFPS complaints as does their effectiveness like EMG.²⁵ For pain control, cryotherapy is recommended for acute exacerbations while thermotherapy (ultrasound, moist hot packs and warm whirlpool) is recommended for chronic syndromes plus phonophoresis, iontophoresis, transcutaneous electrical nerve stimulation (TENS) and neuromuscular electrical stimulation (NMES).²⁵ These modalities are also generally recommended to reduce edema and inflammation by manipulating modality parameters.²⁵ NMES and EMG are additionally recommended for muscle strengthening.²⁵

While exercise therapy and modalities address intrinsic factors related to PFPS, taping and orthotics provide external support for improved patellofemoral alignment and tracking. Two popular taping techniques include McConnell taping and kinesiotaping. McConnell taping (*Figure 7*) involves providing inferomedial translation of the patella to improve joint alignment and facilitate the VMO with rigid, highly adhesive tape.^{21,26} Kinesiotaping (*Figure 8*) involves the use of more compliant tape that can strain to nearly 140% of its static length to allow full knee joint range of motion.²⁶ Both taping techniques have been shown to improve pain and provide neuromuscular proprioception but kinesiotaping is thought to additionally stimulate vascular and lymphatic flow for tissue healing.^{21,26} Taping coupled with exercise appears to be more beneficial than taping or exercise alone.²⁷ Additionally, given the known effects of pronation on adduction and internal rotation of the lower extremity segment and resultant increased the Q-angle, foot orthoses are considered a relatively affordable option to combat excessive pronation.²⁸ Foot orthoses reduce pain associated with PFPS if excessive pronation is the culprit but are otherwise ineffective for individuals with malalignments stemming from other anatomical locations.²⁸ Further, foot orthoses prove more effective as the amount of eversion, a component of pronation, increases.²⁸ Both prefabricated and custom orthoses have additive benefits when combined with exercise therapy.²⁹ Notably, modification of activity can be relevant for physically inactive and active individuals although PFPS especially seems to affect athletes like runners. Modification of activity alone is unsubstantiated without the other interventions described above. Modifications may be as simple as reducing duration, frequency and intensity of the offending activity or avoiding it altogether until PFPS improves, such as using the elevator rather than attempting stair negotiation. Dramatic modifications include those

such as barefoot running under controlled environmental conditions, which has been shown to significantly decrease patellofemoral joint stresses by up to 12%.³⁰

Conservative treatment is almost always the first line of treatment for PFPS and generally yields satisfactory results for more than 75% of patients.¹³ When conservative management proves unsuccessful, surgery remains an option although its effectiveness is questionable depending on the pathoanatomy and pathomechanics and related surgical technique. Knee arthroscopy is no more effective than exercise therapy for improvements in pain and function.²⁹ The Elmslie-Trilla procedure, or lateral tibial tubercle transfer with medial soft tissue tightening, yields similar results unless the patient's primary complaint is patellofemoral instability.²⁹ This procedure results in a decreased Q-angle with less lateral translation of the patella and a decreased risk of subluxation or dislocation.²⁹ Trochleaplasty with similar medial soft tissue tightening, on the other hand, is promising for improving patellar instability and joint congruency by increasing the depth of the trochlear groove and sulcus angle.³¹ Finally, lateral soft tissue release with subsequent strengthening of medial lower extremity muscles has demonstrated effects on decreasing compressive stresses and improving patellar tracking.²⁹

Conclusion

All in all, PFPS can be a debilitating disorder if left untreated or treated improperly, affecting daily activities and limiting participation. There is demonstrated value of physical therapy intervention for decreasing pain and fostering return to activity and participation. While anterior knee pain is a defining characteristic of PFPS, it can be incredibly non-specific and describe multiple knee pathologies, which can complicate the recognition and correct diagnosis of PFPS. Much like the multifactorial aetiology, which can potentially implicate a range of pathoanatomy and pathomechanics, successful physical therapy interventions are also generally

multifactorial. The benefits of exercise therapy are enhanced by modalities, taping and orthotics and modification of activity. Return to activity and participation following physical therapy is expected for the majority of patients with PFPS but is reliant on competent clinicians to identify contributory pathoanatomy and pathomechanics then provide evidence-based, multimodal treatment.

Appendix

Figure 1: Q-angle (image retrieved from Dynamic Chiropractic³²)

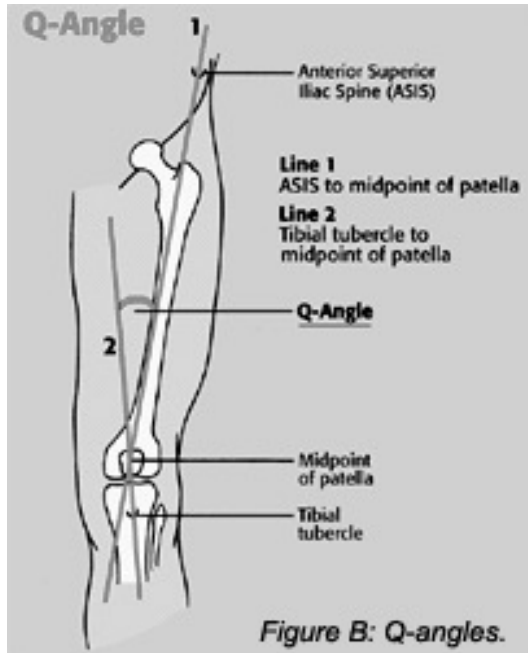


Figure 2: Sulcus angle (image retrieved from Hunter et al.³³)

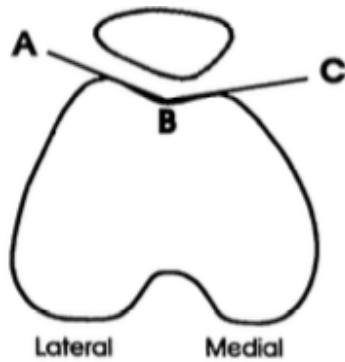


Figure 3: Patellar tilt (image retrieved from Hunter et al.³³)

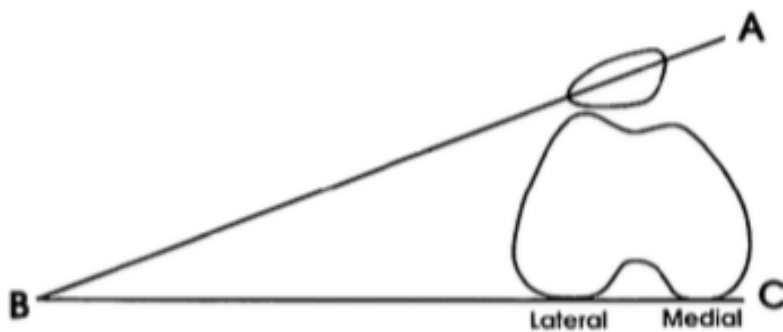


Figure 4: Patellar height (image retrieved from Morthopedics³⁴)

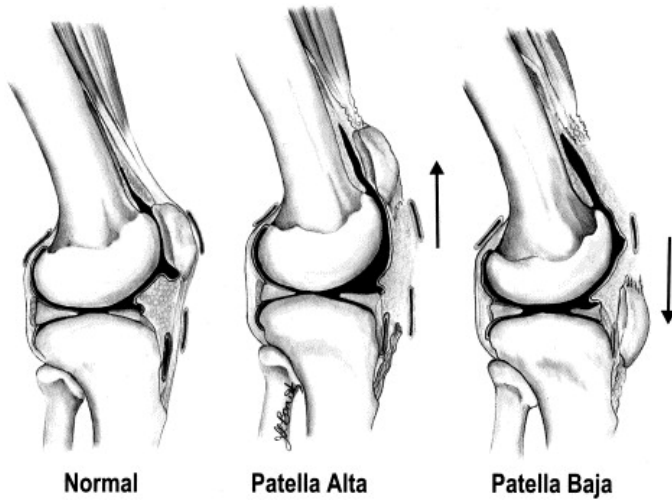


Figure 5: Apprehension testing (image retrieved from Morthopedics³⁵)

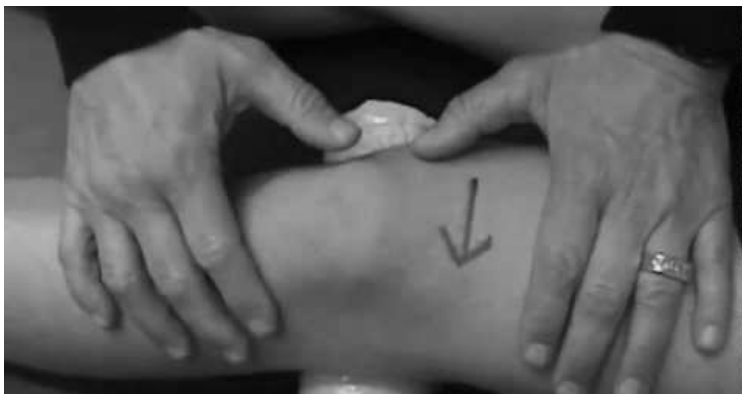

Figure 6: Grind testing (Clarke's sing) (image retrieved from Medview Projects in Medicine³⁶)

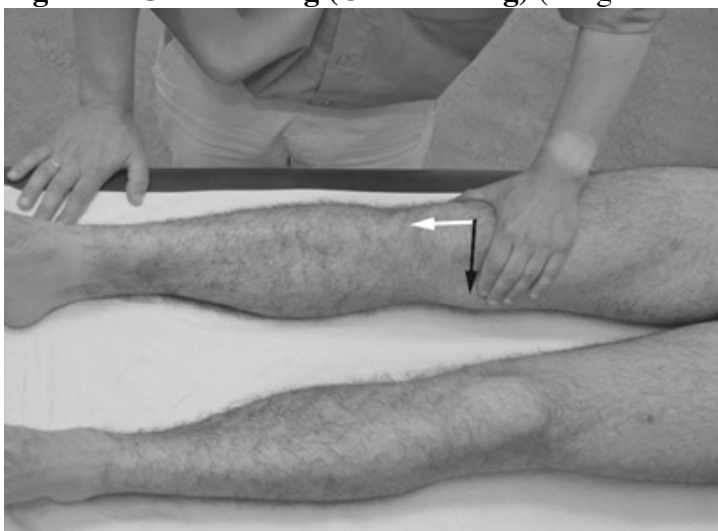

Figure 7: McConnell taping technique (image retrieved from Campolo et al.²⁶)

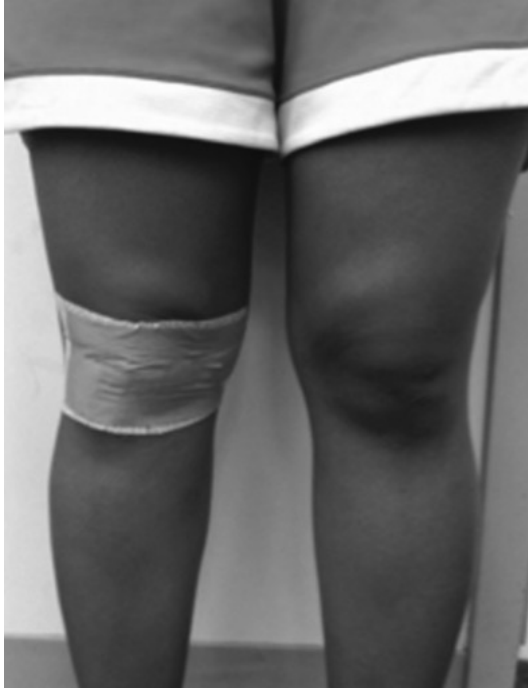
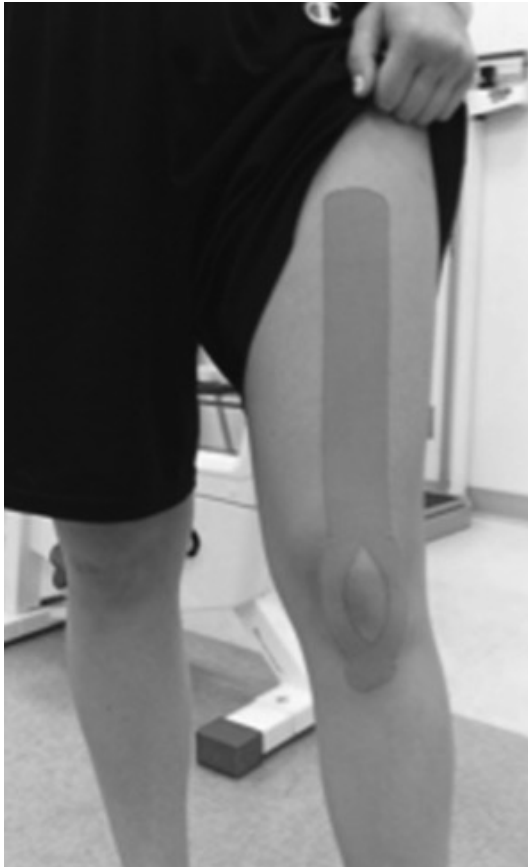

Figure 8: Kinesiotaping technique (image retrieved from Campolo et al.²⁶)



References

1. Wilson T. The measurement of patellar alignment in patellofemoral pain syndrome: are we confusing assumptions with evidence? *J Orthop Sports Phys Ther* 2007;37(6):330-341. doi:10.2519/jospt.2007.2281.
2. Crossley KM, van Middelkoop M, Callaghan MJ, Collins NJ, Rathleff MS, Barton CJ. 2016 Patellofemoral pain consensus statement from the 4th International Patellofemoral Pain Research Retreat, Manchester. Part 2: recommended physical interventions (exercise, taping, bracing, foot orthoses and combined interventions). *Br J Sports Med* 2016;50(14):844-852. doi:10.1136/bjsports-2016-096268.
3. Glaviano NR, Kew M, Hart JM, Saliba S. Demographic and epidemiological trends in patellofemoral pain. *International journal of sports physical therapy* 2015;10(3):281-290.
4. Lankhorst NE, Bierma-Zeinstra SMA, van Middelkoop M. Factors associated with patellofemoral pain syndrome: a systematic review. *Br J Sports Med* 2013;47(4):193-206. doi:10.1136/bjsports-2011-090369.
5. Sherman SL, Plackis AC, Nuelle CW. Patellofemoral anatomy and biomechanics. *Clin Sports Med* 2014;33(3):389-401. doi:10.1016/j.csm.2014.03.008.
6. Loudon JK. Biomechanics and pathomechanics of the patellofemoral joint. *International journal of sports physical therapy* 2016;11(6):820-830.
7. Manske RC, Davies GJ. Examination of the patellofemoral joint. *International journal of sports physical therapy* 2016;11(6):831-853.
8. Sheehan FT, Derasari A, Fine KM, Brindle TJ, Alter KE. Q-angle and J-sign: indicative of maltracking subgroups in patellofemoral pain. *Clin Orthop Relat Res* 2010;468(1):266-275. doi:10.1007/s11999-009-0880-0.
9. Boling M, Padua D, Marshall S, Guskiewicz K, Pyne S, Beutler A. Gender differences in the incidence and prevalence of patellofemoral pain syndrome. *Scand J Med Sci Sports* 2010;20(5):725-730. doi:10.1111/j.1600-0838.2009.00996.x.
10. Lester JD, Watson JN, Hutchinson MR. Physical examination of the patellofemoral joint. *Clin Sports Med* 2014;33(3):403-412. doi:10.1016/j.csm.2014.03.002.
11. Tanamas SK, Teichtahl AJ, Wluka AE, et al. The associations between indices of patellofemoral geometry and knee pain and patella cartilage volume: a cross-sectional study. *BMC Musculoskelet Disord* 2010;11:87. doi:10.1186/1471-2474-11-87.
12. Gross, MT. Articular Cartilage: Composition, Structure, Function, Mechanical Properties, and Healing. Available at: <https://unc.voicethread.com/myvoice/thread/166475/>
13. Malek MM, Mangine RE. Patellofemoral pain syndromes: Comprehensive and conservative approach. *J Orthop Sports Phys Ther* 1981;2(3):108-116.
14. Petersen W, Ellermann A, Gösele-Koppenburg A, et al. Patellofemoral pain syndrome. *Knee Surg Sports Traumatol Arthrosc* 2014;22(10):2264-2274. doi:10.1007/s00167-013-2759-6.
15. Giles LS, Webster KE, McClelland JA, Cook J. Does quadriceps atrophy exist in individuals with patellofemoral pain? A systematic literature review with meta-analysis. *J Orthop Sports Phys Ther* 2013;43(11):766-776. doi:10.2519/jospt.2013.4833.
16. Cook C, Mabry L, Reiman MP, Hegedus EJ. Best tests/clinical findings for screening and diagnosis of patellofemoral pain syndrome: a systematic review. *Physiotherapy* 2012;98(2):93-100. doi:10.1016/j.physio.2011.09.001.
17. Gross, MT. Lower Quarter Screening Examination for Structural Alignment. Available

- at: https://sakai.unc.edu/access/content/group/df72f84a-d2c5-40f1-8795-b4da36906313/Foot_Ankle/LowerQuarterScreen.pdf
18. Jonson SR, Gross MT. Intraexaminer reliability, interexaminer reliability, and mean values for nine lower extremity skeletal measures in healthy naval midshipmen. *J Orthop Sports Phys Ther* 1997;25(4):253-263.
 19. Rathleff MS, Nielsen RG, Kersting UG. Navicula drop test ad modum Brody: does it show how the foot moves under dynamic conditions? *J Am Podiatr Med Assoc* 2012;102(1):34-38.
 20. Carson WG, James SL, Larson RL, Singer KM, Winternitz WW. Patellofemoral disorders: physical and radiographic evaluation. Part II: Radiographic examination. *Clin Orthop Relat Res* 1984;(185):178-186.
 21. Derasari A, Brindle TJ, Alter KE, Sheehan FT. McConnell taping shifts the patella inferiorly in patients with patellofemoral pain: a dynamic magnetic resonance imaging study. *Phys Ther* 2010;90(3):411-419. doi:10.2522/ptj.20080365. Barton CJ, Levinger P, Menz HB, Webster KE. Kinematic gait characteristics associated with patellofemoral pain syndrome: a systematic review. *Gait Posture* 2009;30(4):405-416. doi:10.1016/j.gaitpost.2009.07.109.
 22. Clijsen R, Fuchs J, Taeymans J. Effectiveness of exercise therapy in treatment of patients with patellofemoral pain syndrome: systematic review and meta-analysis. *Phys Ther* 2014;94(12):1697-1708. doi:10.2522/ptj.20130310.
 23. Lack S, Barton C, Sohan O, Crossley K, Morrissey D. Proximal muscle rehabilitation is effective for patellofemoral pain: a systematic review with meta-analysis. *Br J Sports Med* 2015;49(21):1365-1376. doi:10.1136/bjsports-2015-094723.
 24. Ferber R, Bolgla L, Earl-Boehm JE, Emery C, Hamstra-Wright K. Strengthening of the hip and core versus knee muscles for the treatment of patellofemoral pain: a multicenter randomized controlled trial. *J Athl Train* 2015;50(4):366-377. doi:10.4085/1062-6050-49.3.70.
 25. Lake DA, Wofford NH. Effect of therapeutic modalities on patients with patellofemoral pain syndrome: a systematic review. *Sports Health* 2011;3(2):182-189. doi:10.1177/19417381111398583.
 26. Campolo M, Babu J, Dmochowska K, Scariah S, Varughese J. A comparison of two taping techniques (kinesio and mcconnell) and their effect on anterior knee pain during functional activities. *International journal of sports physical therapy* 2013;8(2):105-110.
 27. Logan CA, Bhashyam AR, Tisosky AJ, et al. Systematic review of the effect of taping techniques on patellofemoral pain syndrome. *Sports Health* 2017;9(5):456-461. doi:10.1177/1941738117710938.
 28. Barton CJ, Menz HB, Levinger P, Webster KE, Crossley KM. Greater peak rearfoot eversion predicts foot orthoses efficacy in individuals with patellofemoral pain syndrome. *Br J Sports Med* 2011;45(9):697-701. doi:10.1136/bjism.2010.077644.
 29. Rixe JA, Glick JE, Brady J, Olympia RP. A review of the management of patellofemoral pain syndrome. *Phys Sportsmed* 2013;41(3):19-28. doi:10.3810/psm.2013.09.2023.
 30. Bonacci J, Vicenzino B, Spratford W, Collins P. Take your shoes off to reduce patellofemoral joint stress during running. *Br J Sports Med* 2014;48(6):425-428. doi:10.1136/bjsports-2013-092160.
 31. Neumann MV, Stalder M, Schuster AJ. Reconstructive surgery for patellofemoral joint incongruency. *Knee Surg Sports Traumatol Arthrosc* 2016;24(3):873-878.

doi:10.1007/s00167-014-3397-3.

32. Dynamic Chiropractic website. Available at:
http://www.dynamicchiropractic.com/content/images/austin2_1_4943.gif. Accessed December 8, 2017.
33. Hunter
34. Morthopedics website. Available at: <http://ars.els-cdn.com/content/image/1-s2.0-S0736467902007199-gr3.jpg>. Accessed December 8, 2017.
35. Patella apprehension test. Available at:
<https://i.pinimg.com/originals/43/91/96/43919672788681df333579f71ae27287.jpg>.
Accessed December 8, 2017.
36. Medview Projects in Medicine website. Available at:
<http://simbrazil.mediviewprojects.org/images/stories/LowerExtrem/le-fig-77.jpg>.
Accessed December 8, 2017.