

PAINWEEK[®]

Patient-Centered Approach to Back Pain: Differential Diagnosis

David M Glick, DC, DAAPM, CPE, FASPE

Disclosure

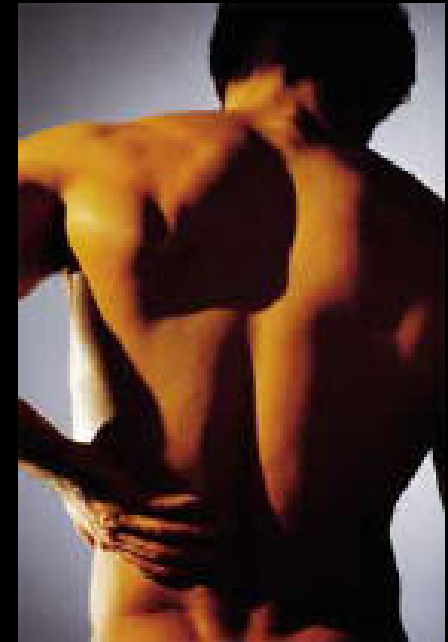- Nothing to Disclose

Course Objectives

- Identify primary and secondary pain generators that contribute to back pain
- Describe how routine examinations may be deficient in providing adequate differential diagnosis of back pain
- Explain how a problem focused examination can differentially diagnose specific pain generators

Misconceptions of Back Pain

- Back pain is Symptom not a pathology.
- All pain is not caused by disc herniations or “pinched nerves.”
- There is no single treatment to address back pain.
- Chronic back pain often occurs from failure to adequately diagnose and treat.



What about the Clinician?



- Highly skilled, well rounded, just not familiar with the particular problem.
- Not every clinician can treat every problem

Most Important Tools for Differential Diagnosis...

- History
- Clinical Examination
- Experience of Clinician

Adverse Factors Affecting Physical Diagnosis

■ Limitations of Time

- *Volume of patients may limit face-to-face time with clinician.*
- *Reimbursements tend to devalue clinical component.*

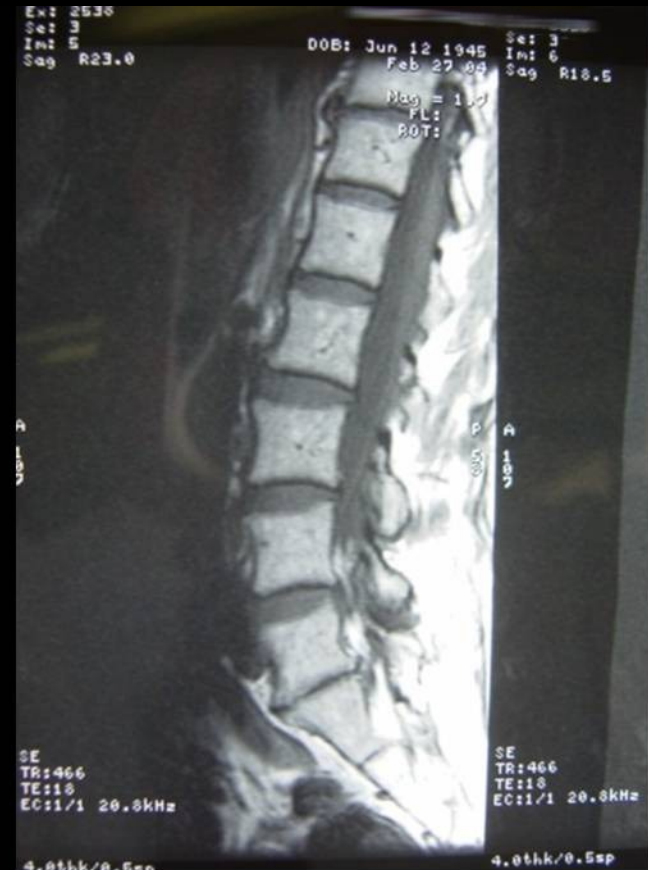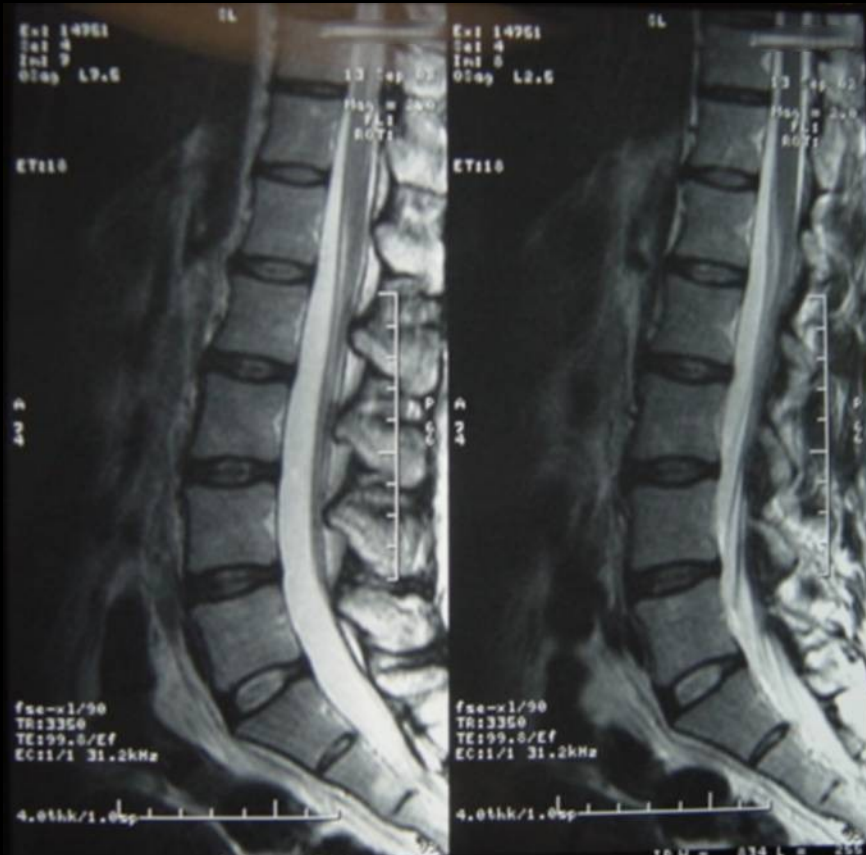■ Reliance Upon Technology

- *MRI shows disc herniations so that must be the cause of the patient's neck pain.*

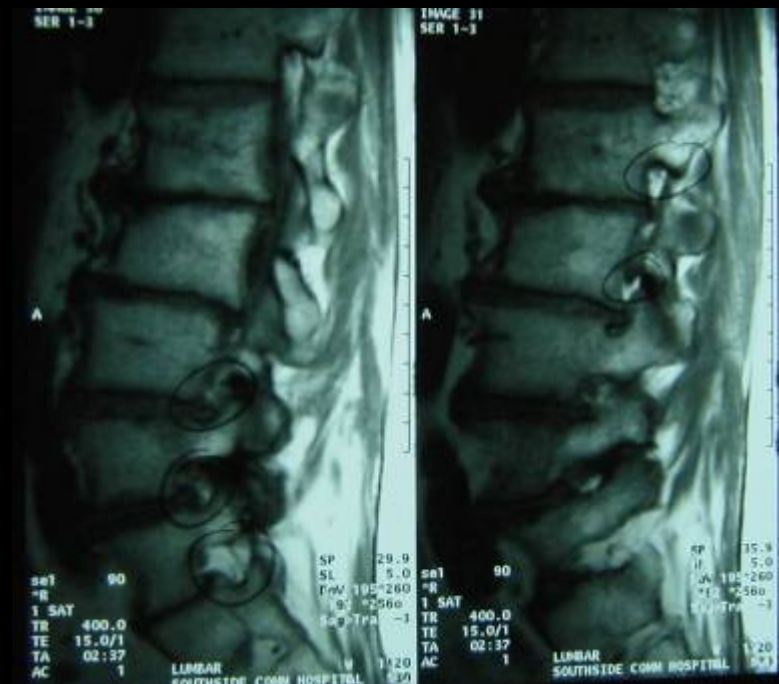
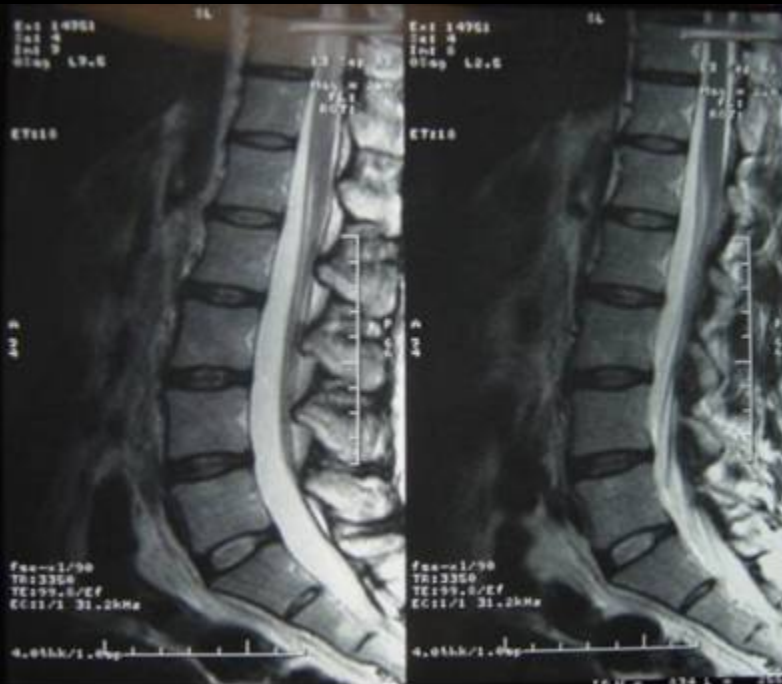■ Clinical Experience

- *Has the clinician evaluated patients with similar symptoms before*

Which patient is suffering from severe chronic low back pain?

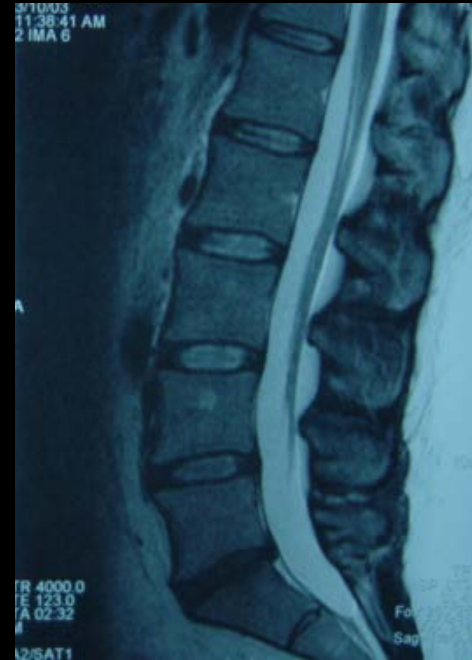
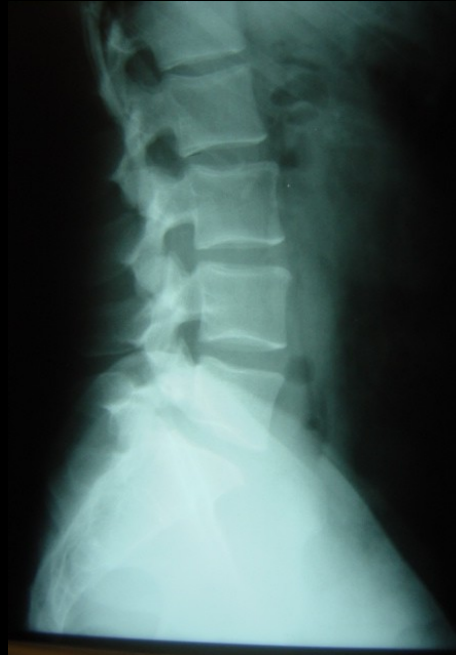
Which patient is suffering from severe chronic low back pain?



Inflammation of a nerve root is quite painful and does not show up on an MRI or other imaging studies

Imaging Studies



- While providing valuable structural, they do not necessarily reflect whether a pathology is clinically relevant

On MRI examination of the lumbar spine, many people without back pain have disc bulges or protrusions but not extrusions. Given the high prevalence of these findings and of back pain, the discovery by MRI of bulges or protrusions in people with low back pain may frequently be coincidental.

.... 36% of the 98 asymptomatic subjects had normal discs at all levels. With the results of the two readings averaged, 52% of the subjects had a bulge at least one level, 27% had a protrusion, and 1% had an extrusion. 38% had an abnormality of more than one intervertebral disc.

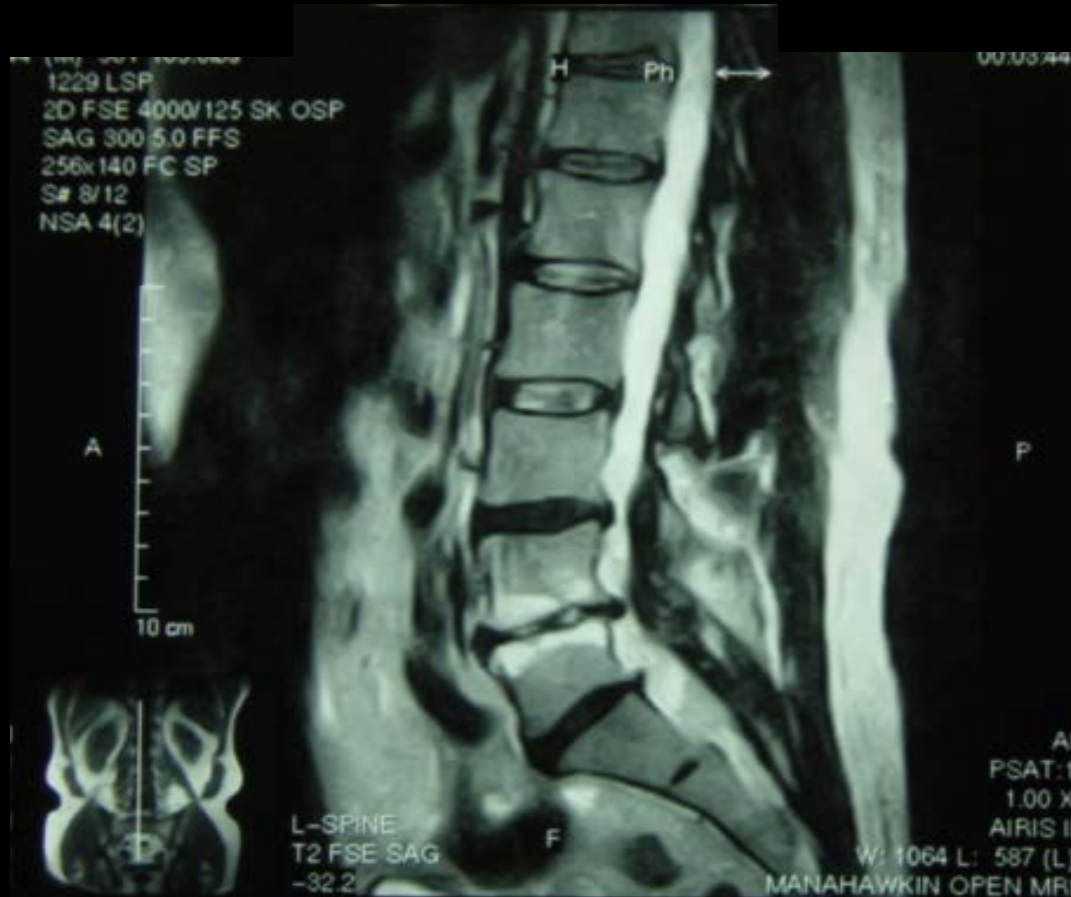- Jensen MC, Brant-Zawadzki MN, Obuchowski N, Modic MT, et. al., Magnetic resonance imaging of the lumbar spine in people without back pain. N Engl J Med. 1994 Jul 14;331(2):69-73. (PMID: 8208267)

“MRIs were not predictive of the development or duration of low-back pain. Individuals with the longest duration of low-back pain did not have the greatest degree of anatomical abnormality on prior scans. Clinical correlation is essential to determine the importance of abnormalities on magnetic resonance images.”

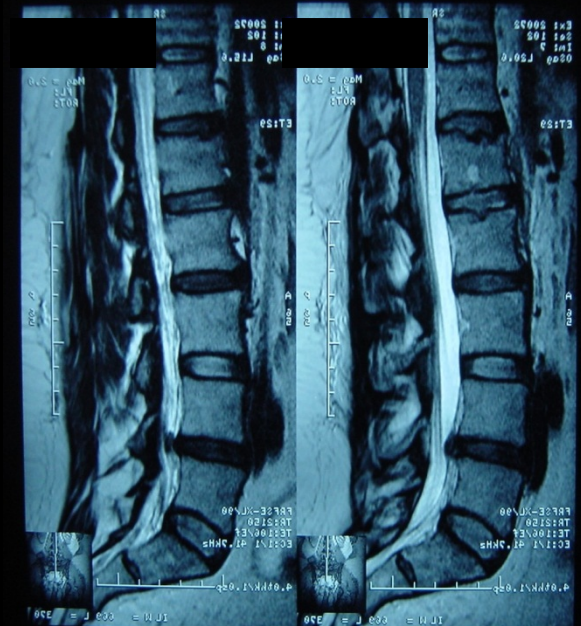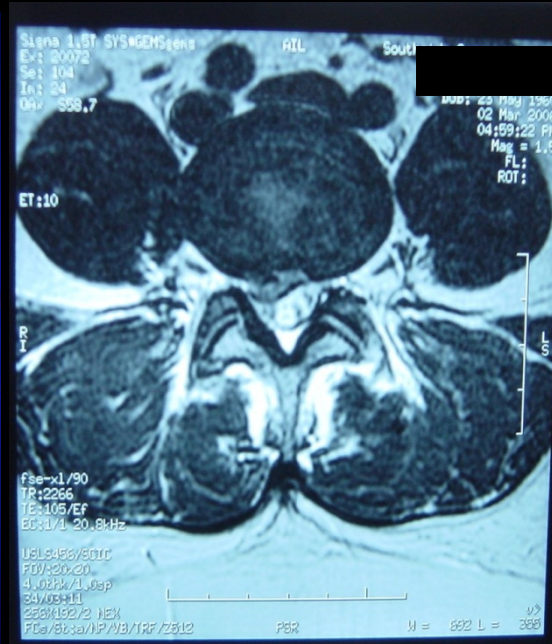
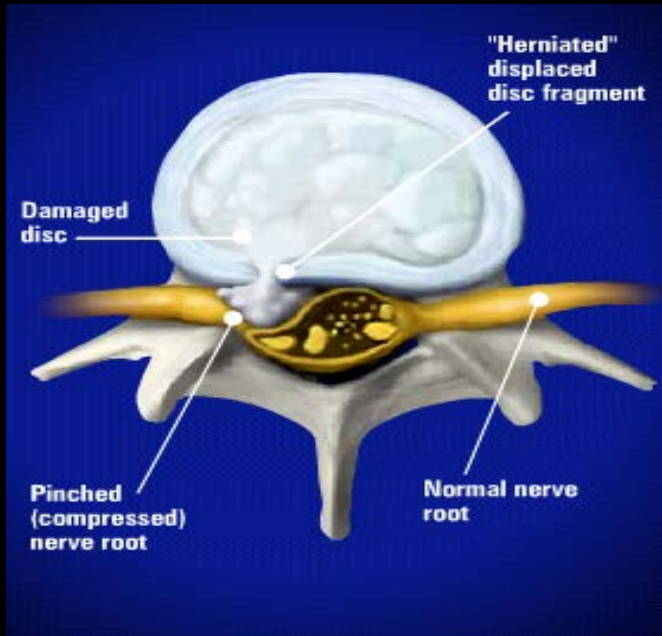
.... 77 asymptomatic individuals with no history of back pain underwent magnetic resonance imaging of the lumbar spine. 21 subjects (31%) had an identifiable abnormality of a disc or of the spinal canal. In the current study, we investigated whether the findings on the scans of the lumbar spine that had been made in 1989 predicted the development of low-back pain in these asymptomatic subjects.

- Borenstein DG, O'Mara JW Jr, Boden SD, Lauerman WC, et. al., The value of magnetic resonance imaging of the lumbar spine to predict low-back pain in asymptomatic subjects: a seven-year follow-up study. J Bone Joint Surg Am. 2001 Sep;83-A(9):1306-11. (PMID: 11568190)

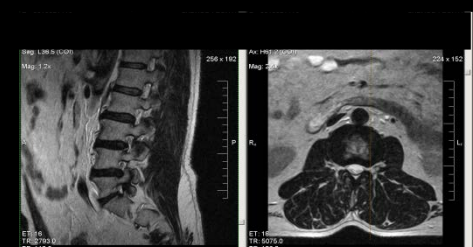
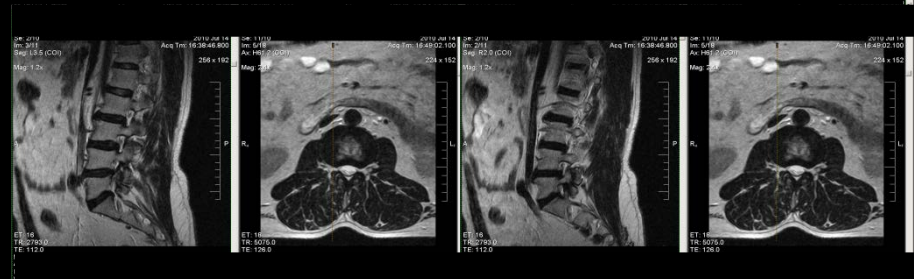
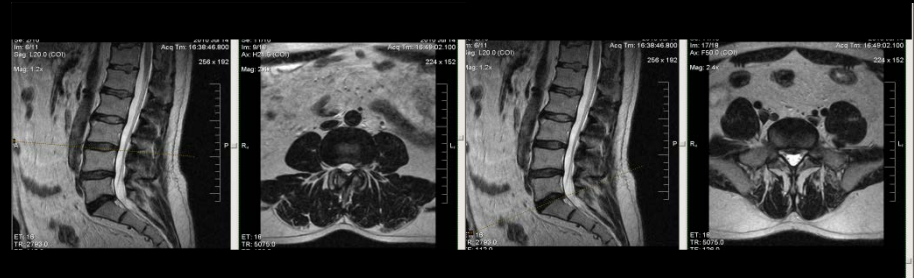
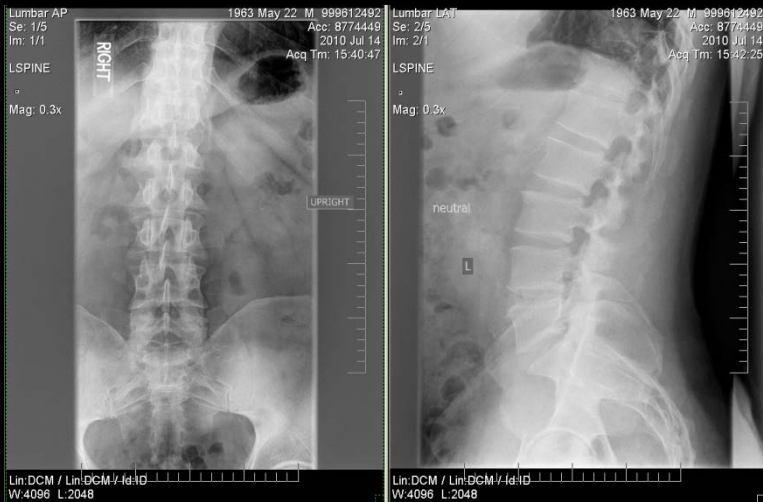How do the imaging study results correlate with the onset of symptoms?



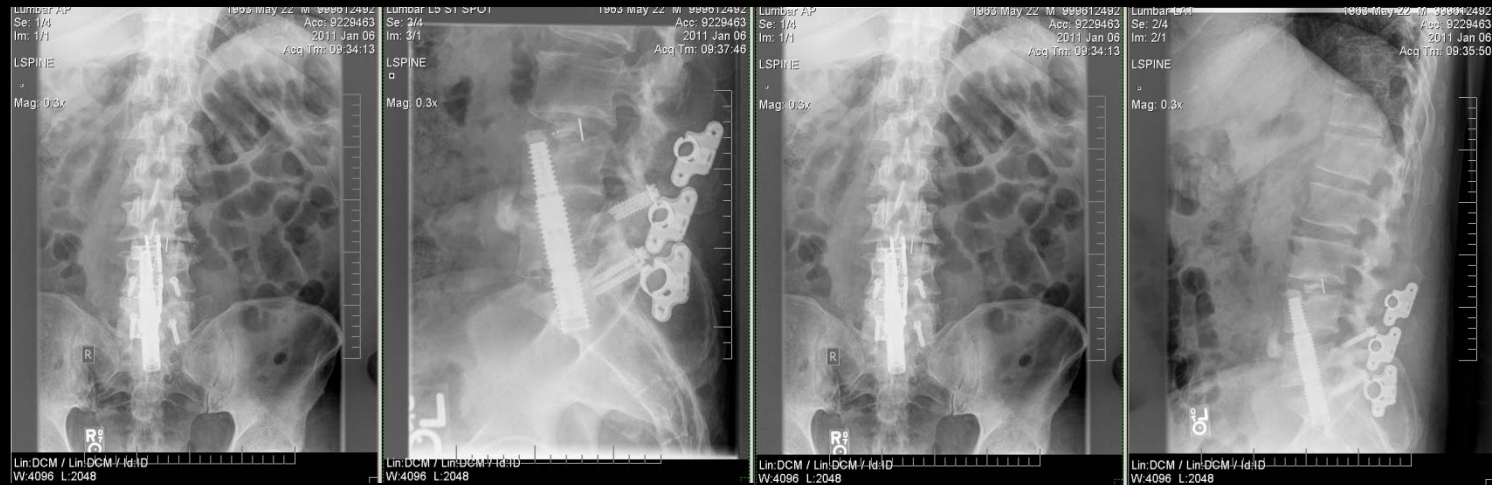
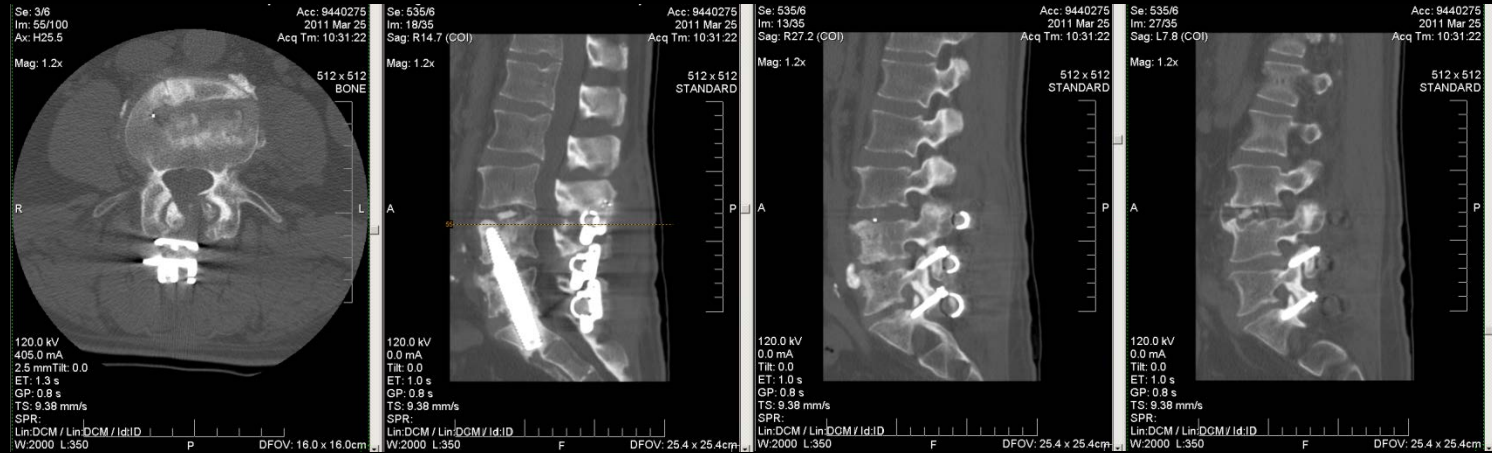Disc Herniation w/ Nerve Root Compression



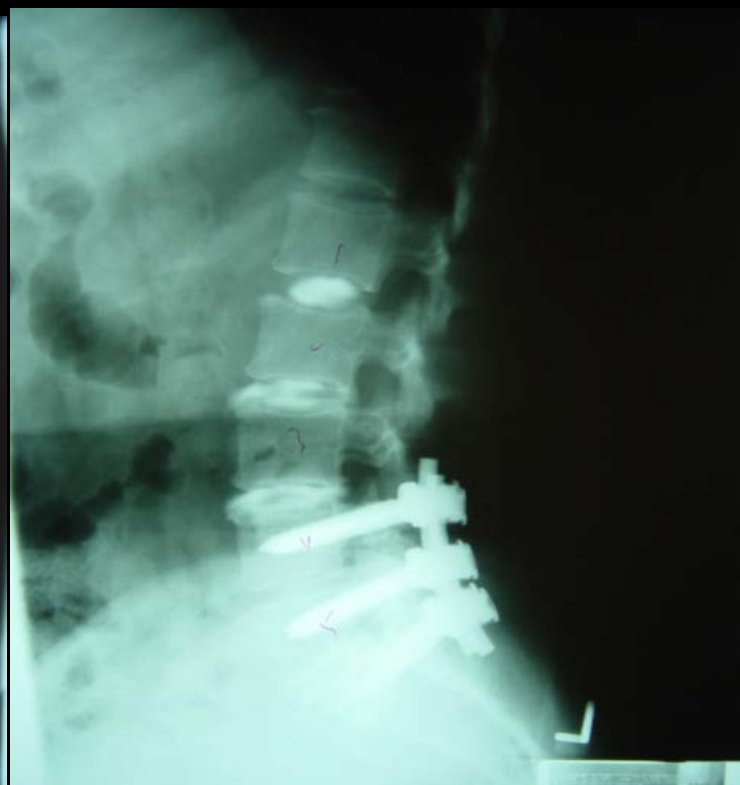
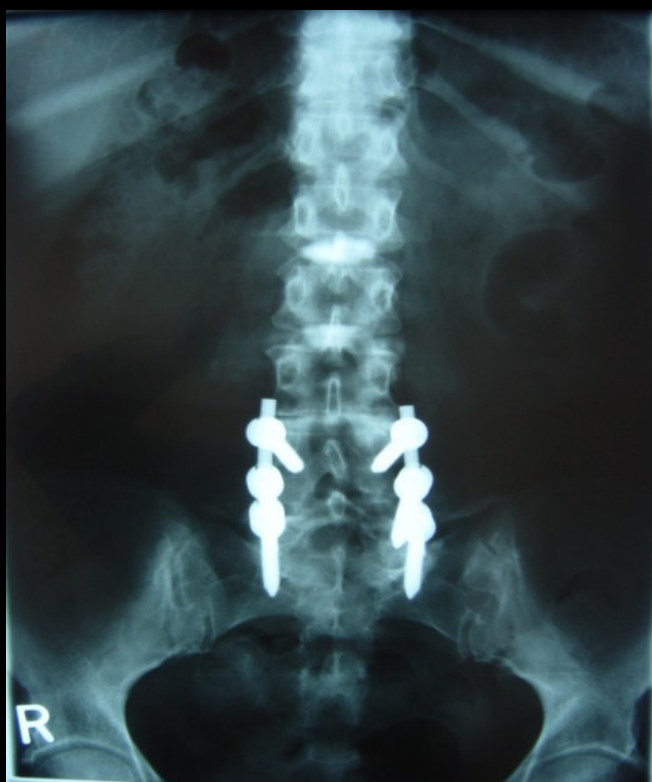Pre Surgery Case Study



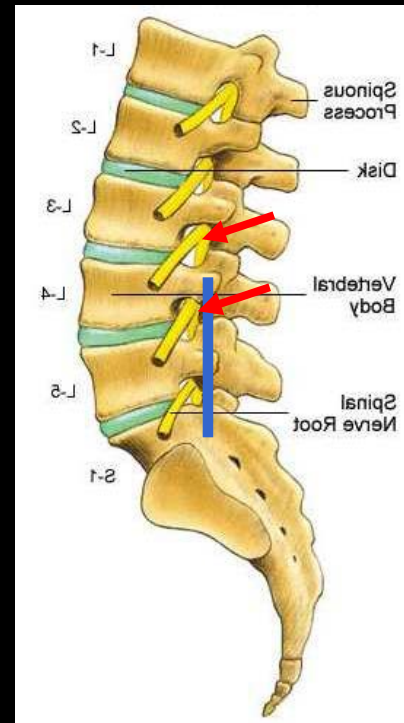
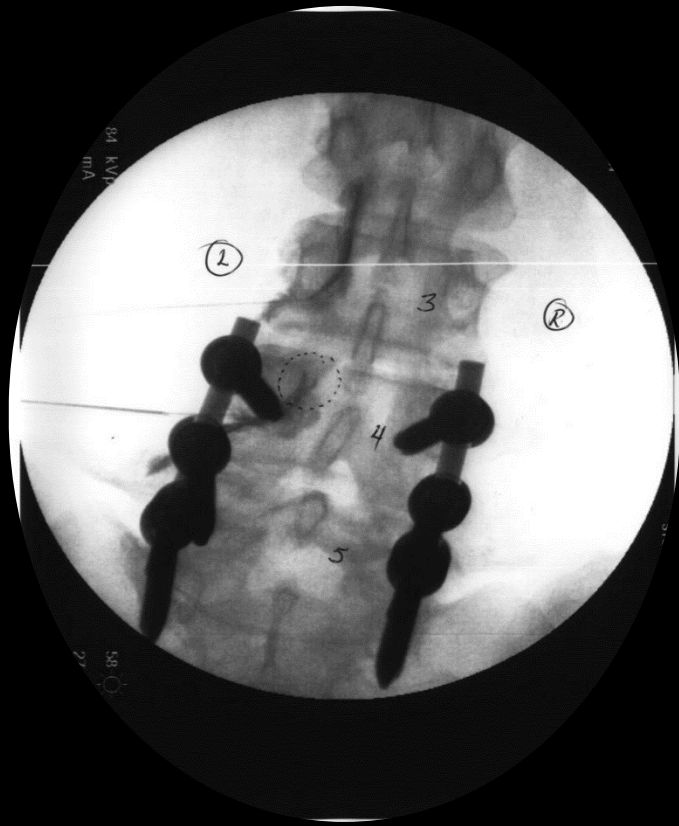Post Surgery



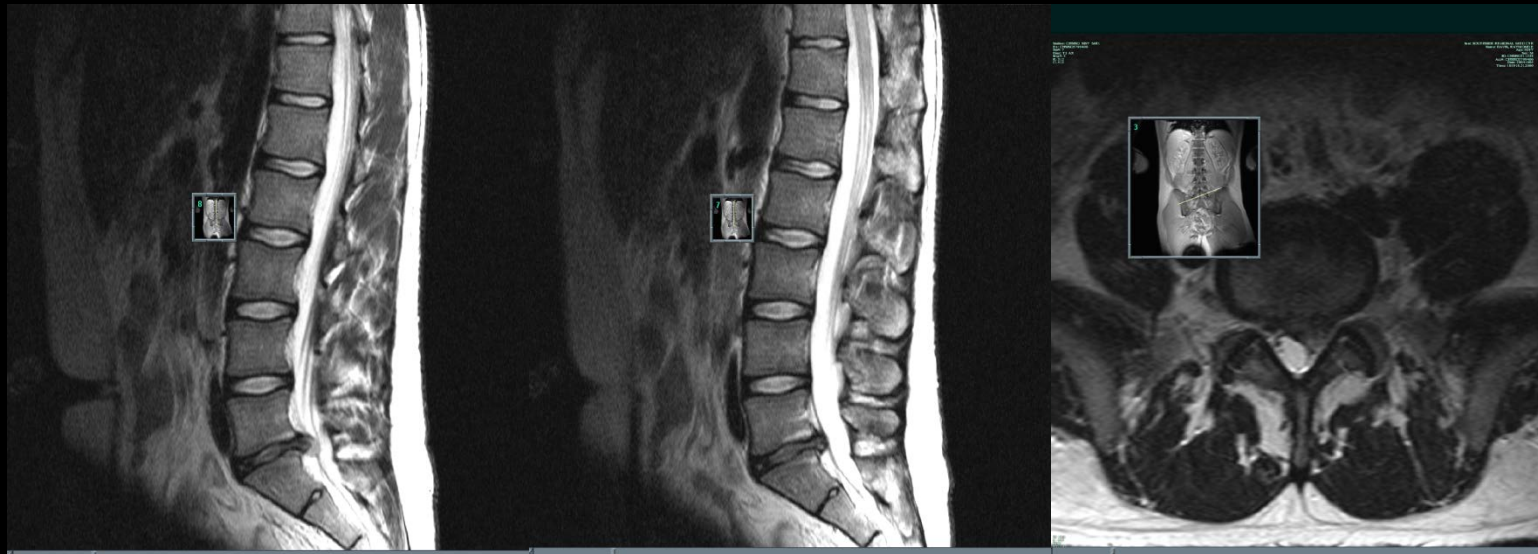Post Surgery – Multi level Posterior fusion



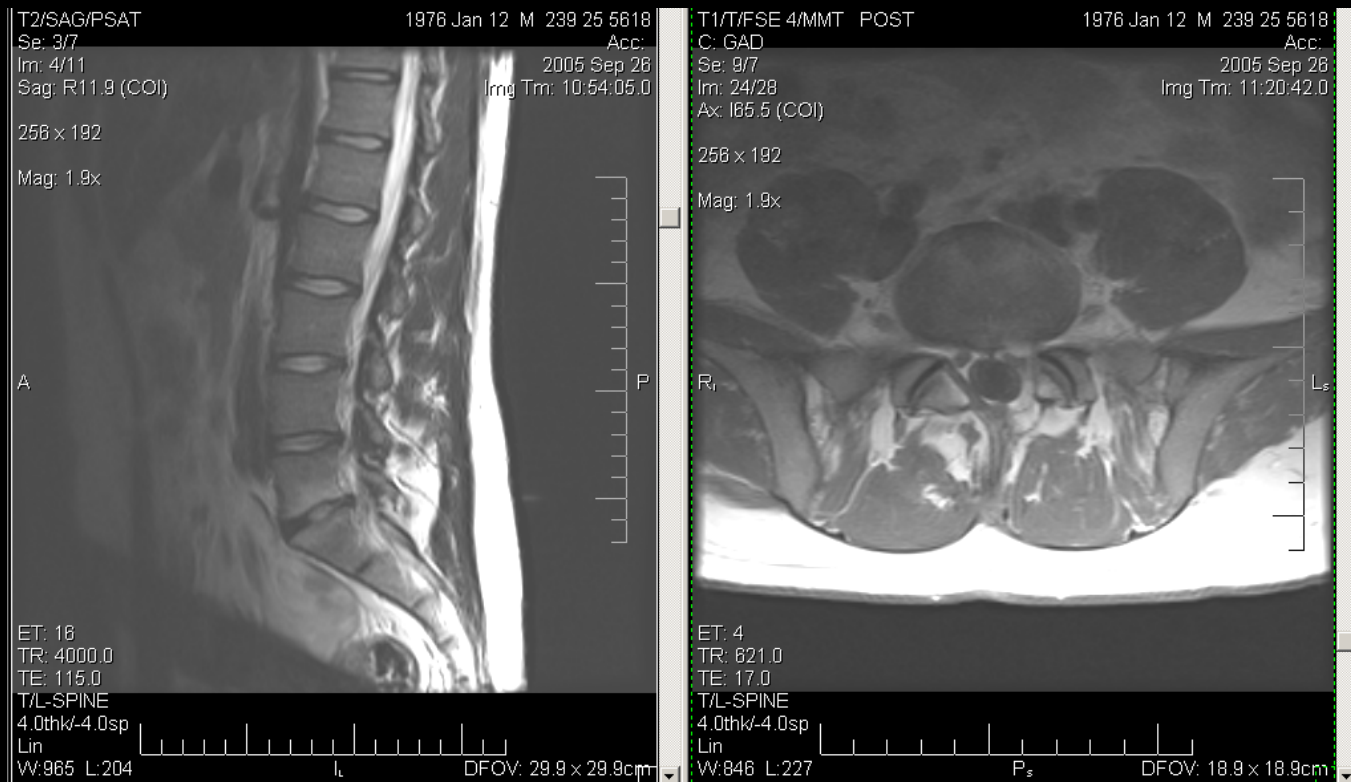Post Surgery – Multi level Posterior fusion



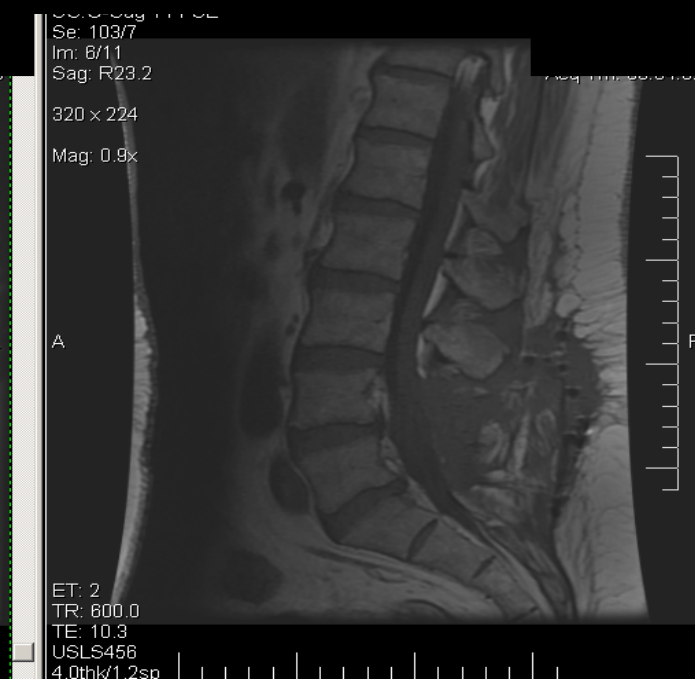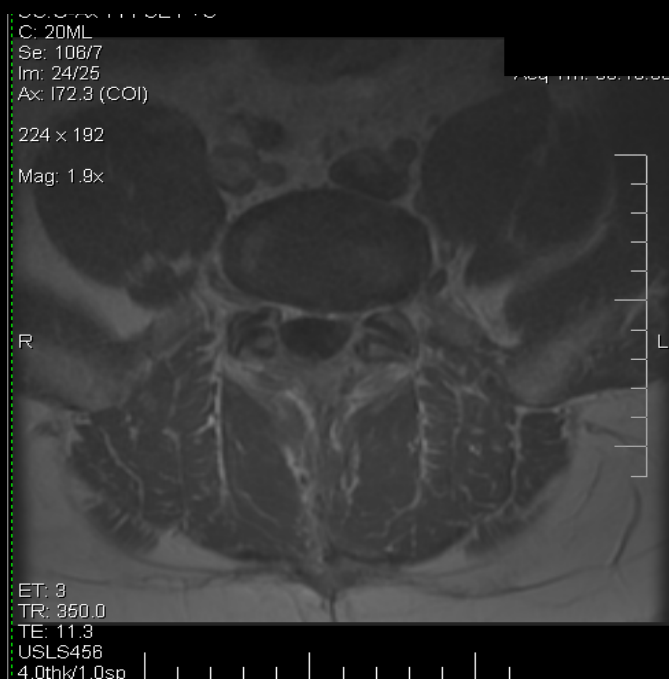Post Surgery – Left L5 Discectomy



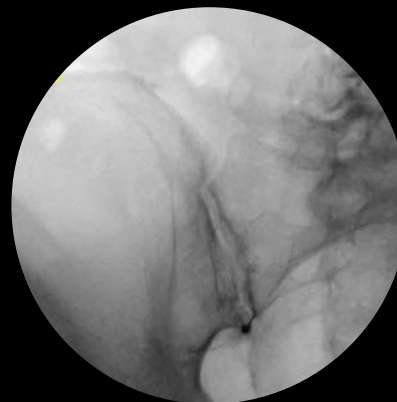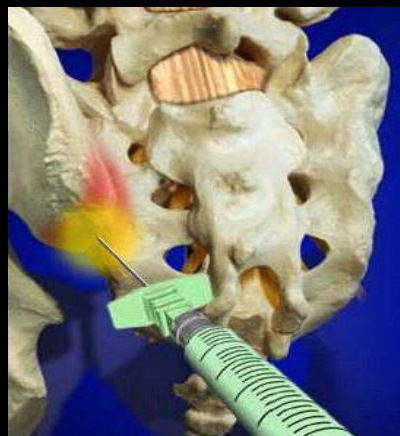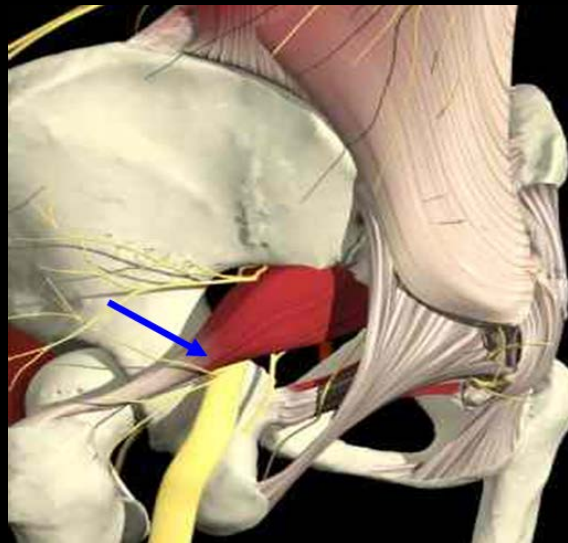
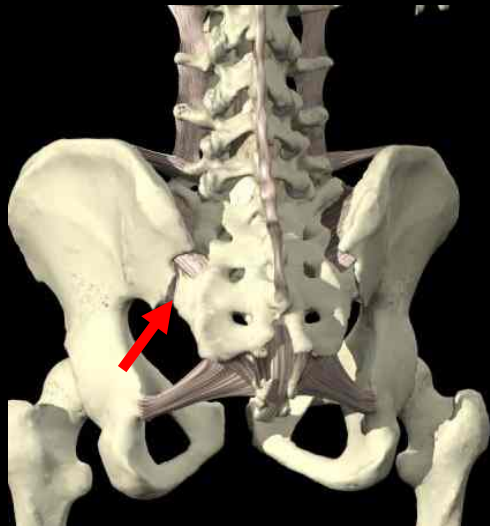
Post Surgery – Left L5 Discectomy



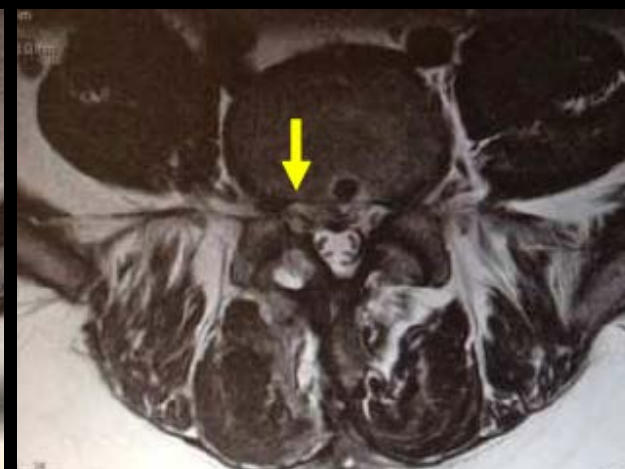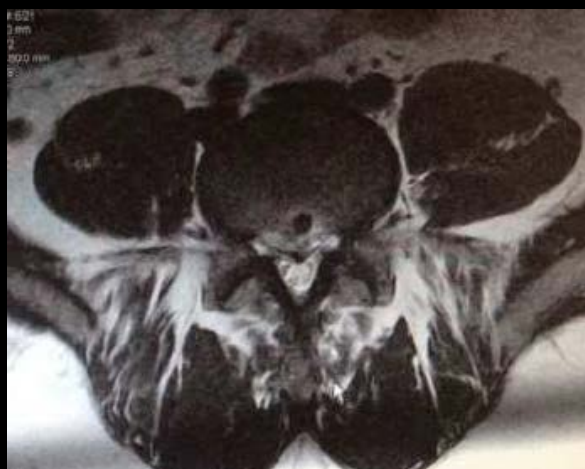Post Surgery – L4-S1 Discectomies/Laminectomies



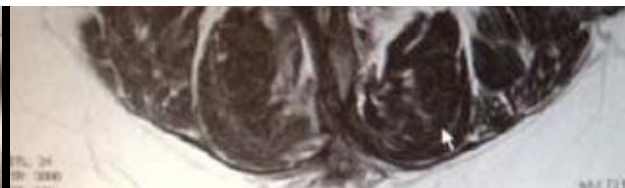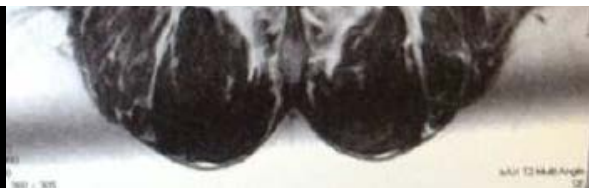Post Surgery – L4-S1 Discectomies/Laminectomies



L4/L5 Disc Osteophyte complex with L5 Root Compromise



Despite the fact that the patient has undergone a successful lumbar microdiscectomy, with marked improvement in his neurologic complaints and findings, and an essentially normal postoperative MRI scan of the lumbar spine, he tells me that he is unable to work at all anymore because of low back pain. He has apparently failed all aggressive nonoperative treatments for low back pain, for which there is no operative treatment, and no good objectively measure.



Back Pain Causes

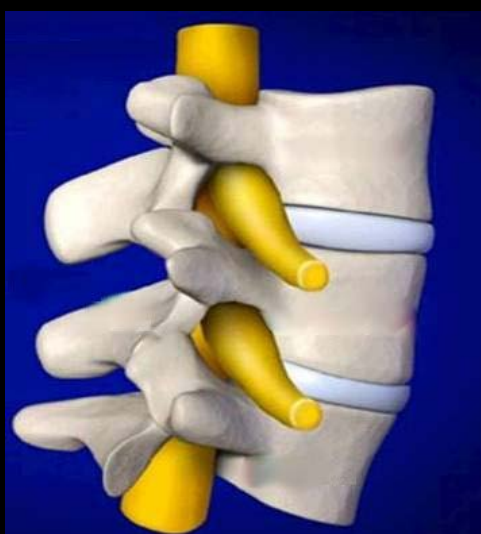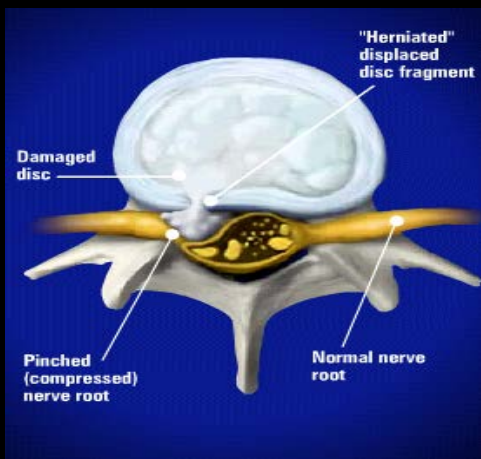
- **Mechanical/Musculoskeletal** - *discogenic, ligamentous, muscular, stenotic, facet mediated, degenerative, osteogenic*
- **Inflammatory** - *arthritic, spondylitic*
- **Infectious** - *osteomyelitis, epidural abscess, discitis*
- **Metabolic** - *osteoporosis, Padgett's*
- **Neoplastic** - *multiple myeloma, cord-canal tumors*
- **Referred** – *abdominal aortic aneurysm, cancer (pancreatic, genitourinary)*

Adapted from Kirkaldy-Willis W. Managing Low Back Pain, Churchill Livingstone, New York 1999; 4rd Ed.

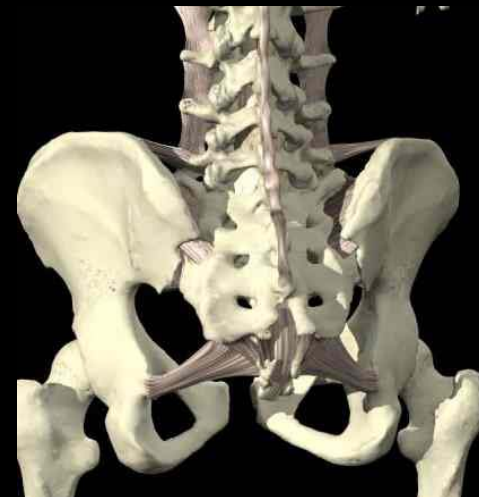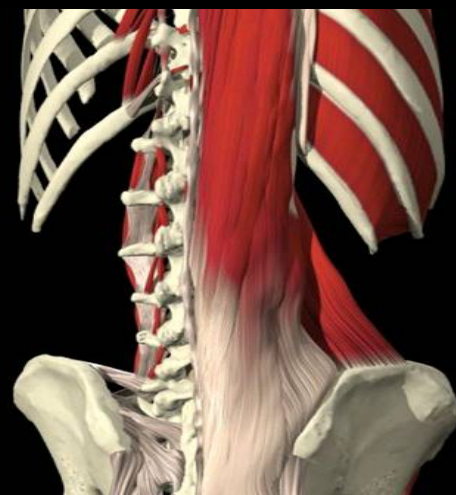Eliminate Red Flags

- **Neoplasm or Infection:** unexplained weight loss, fever, increased nocturnal pain, history of Cancer
- **Cauda Equina Syndrome:** recent onset of bladder dysfunction, saddle anesthesia, progressive neurological deficit including motor weakness (e.g. foot drop)

Mechanical/Musculoskeletal Causes of Back Pain

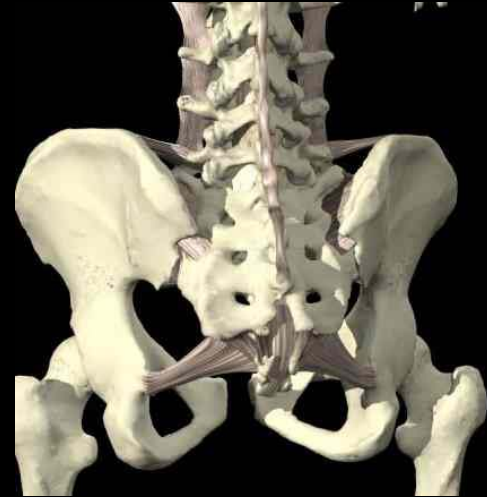
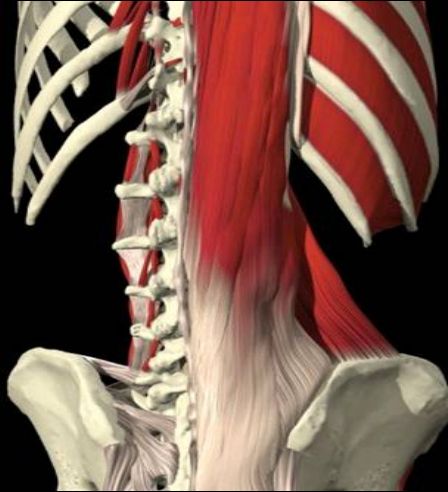
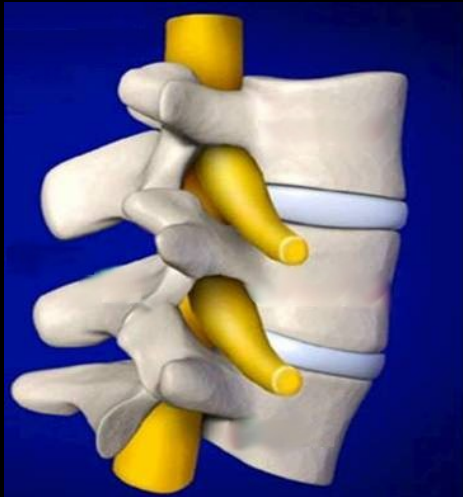- Disc
- Facet
- Ligamentous
- Muscular
- Neurogenic
- Joint related



Clinical Pearl & Teaching Tip

- What are the chances that a patient has a single pain generator?



Importance of Clinical History

- Onset (injury/insidious/unknown)
- Was there an Injury
- Temporal Factors
- Prior History, including Surgery
- Frequency
- Duration
- Exacerbating or Improving Factors

Are there Temporal Factors?

- no relief with bed rest or worse at night may raise the flag for cancer or profound root compression
- morning stiffness suggests an inflammatory problem such as a facet syndrome

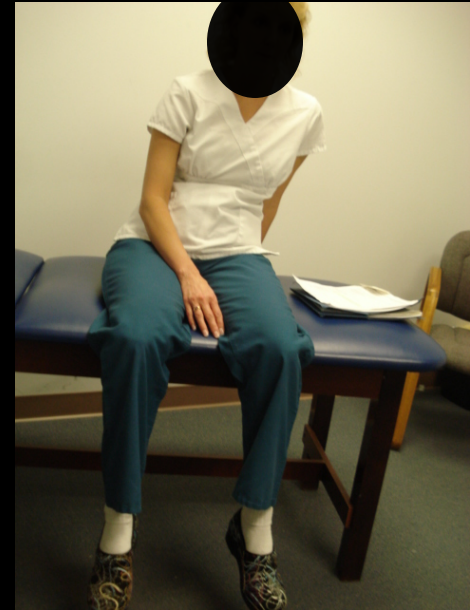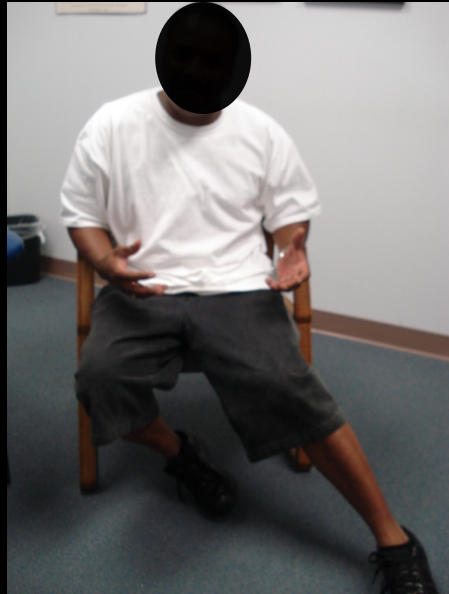Exacerbating or Improving Factors

- May provide insight as to the origin of the pain
 - forward flexion relieving the pain may indicate spinal stenosis or disc herniation as etiology of the pain
 - coughing, sneezing, or Valsalva maneuvers eliciting the pain may indicate a herniated disc as the problem
 - Increased pain on flexion may indicate facet or sacroiliac
 - Increased pain on extension is common with nerve root compression as well as facet pathologies

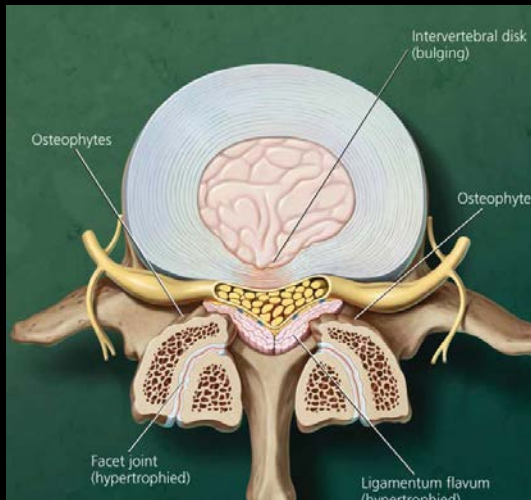
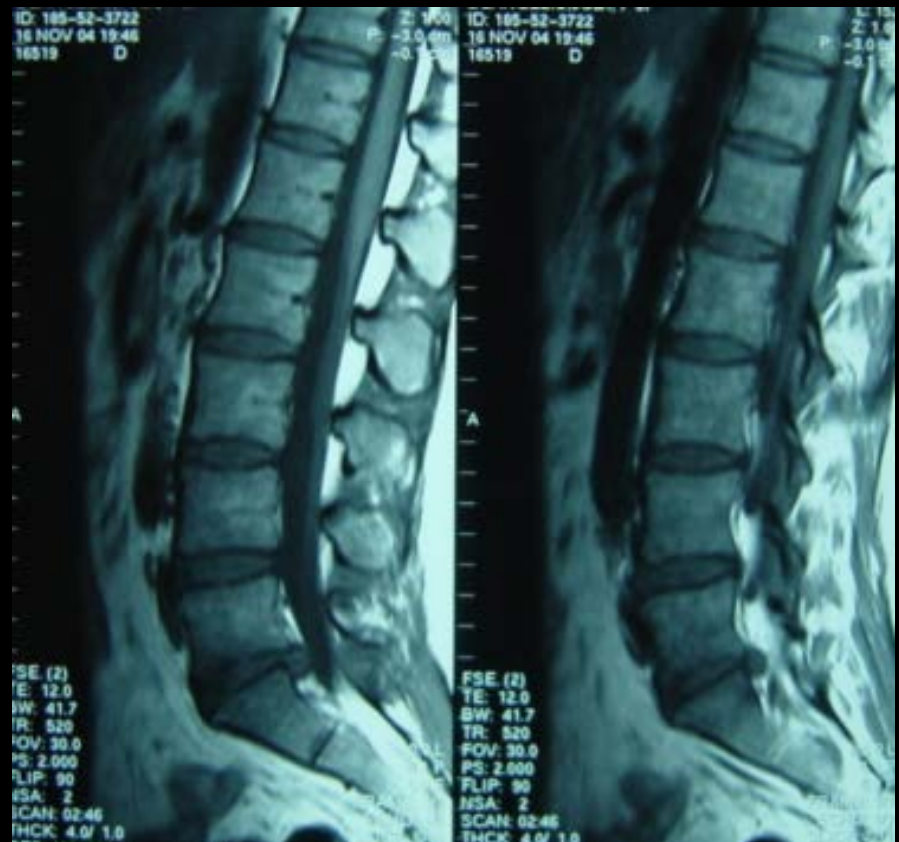
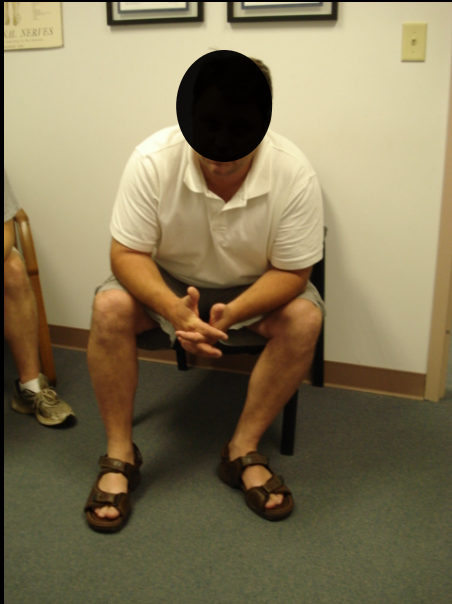Considerations in Performing an Efficient Effective Examination

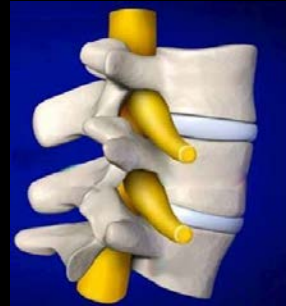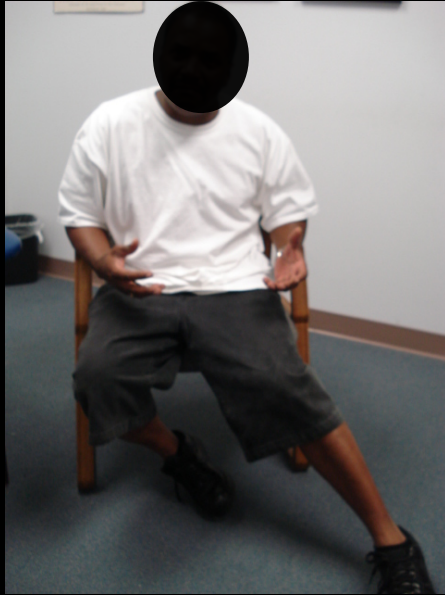- There is no single way to perform a complete physical.
 - *Develop a method or routine that works for you.*
- Structure the examination so that you have a reasonable chance of identifying or defining a problem.
 - *Problem oriented or problem focused.*
- Be consistent performing the examination.
 - *Helps maintain repeatability, and reduce inadvertent omissions.*
- Be efficient.
 - *economy of movement patient and clinician*

Name the Pathology....

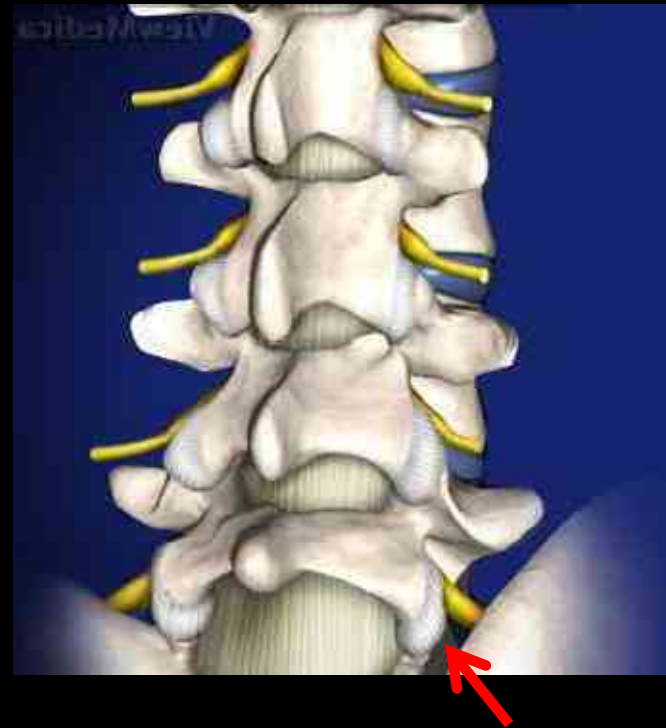

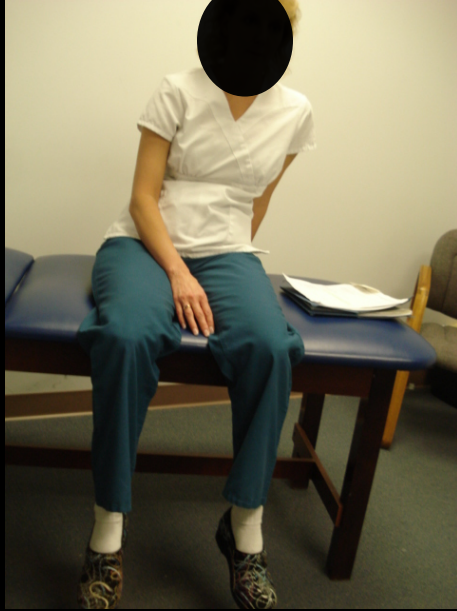Nerve Root Compression or Spinal Stenosis



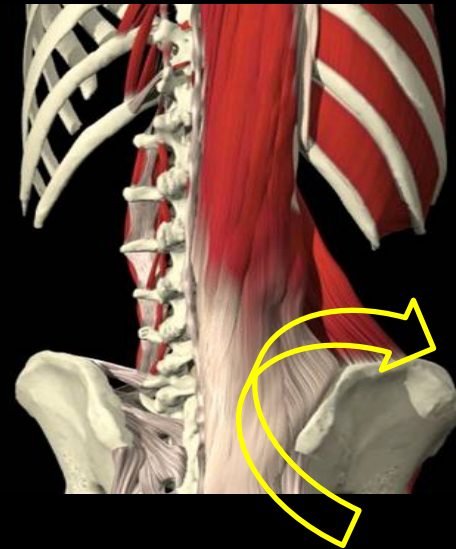
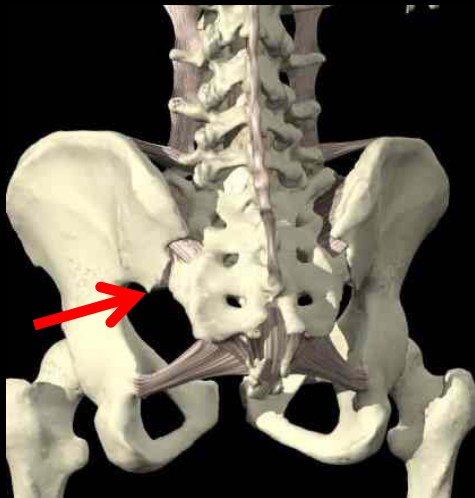


Facet Inflammation

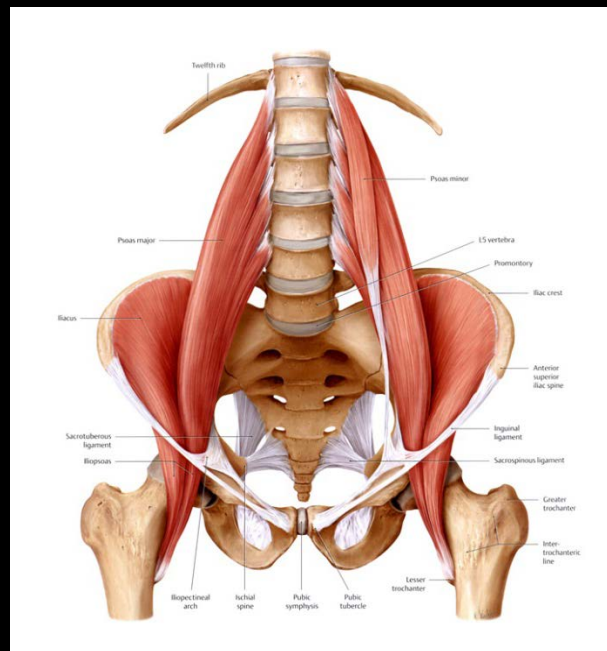




Sacroiliitis or Thoracolumbar Junction Syndrome

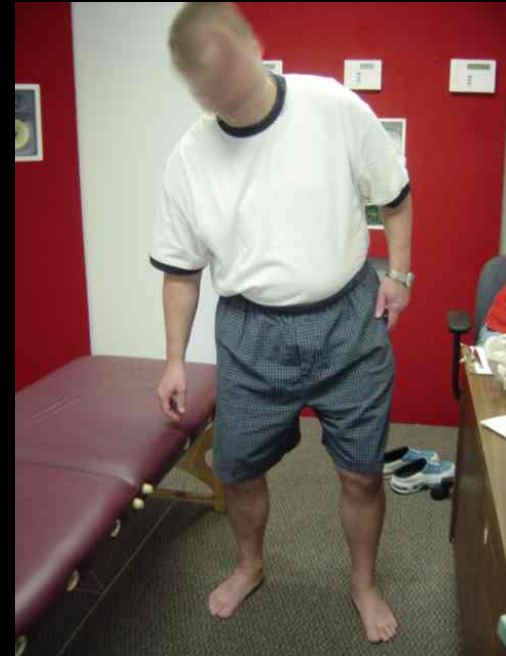

Psoas Muscle Contracture

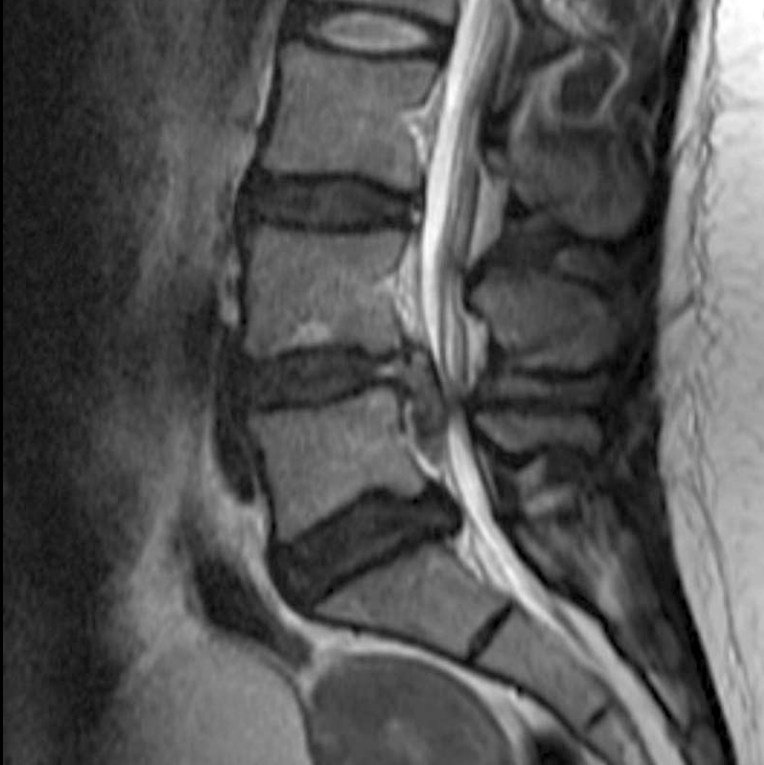

Observation

- Gate
- Physical Stance (Antalgia)
- Alteration of Position
- General Behavior



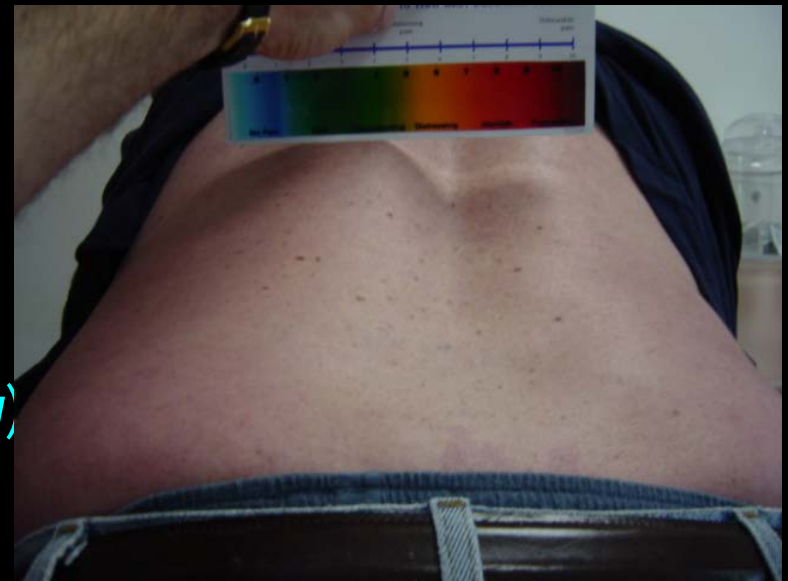
Putting Knowledge to the Test



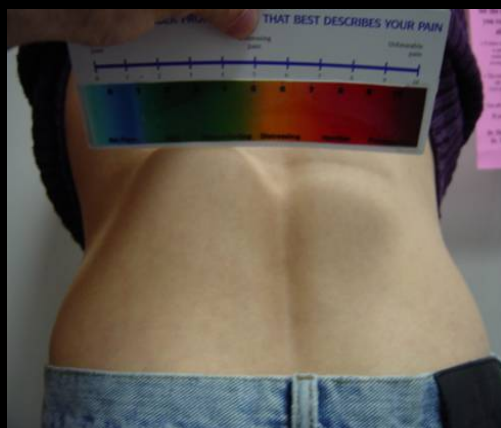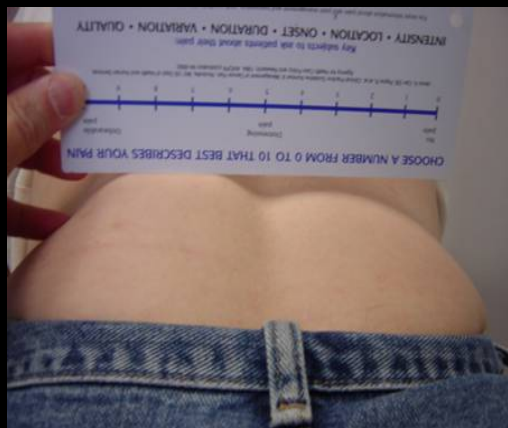
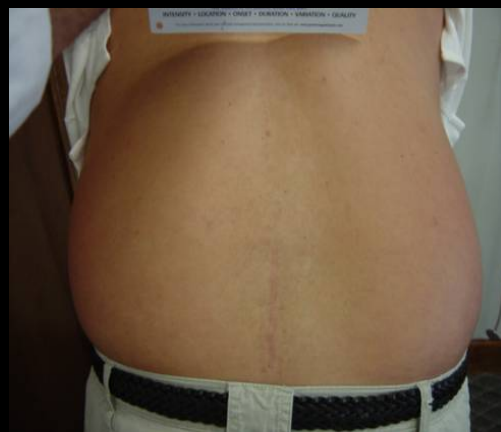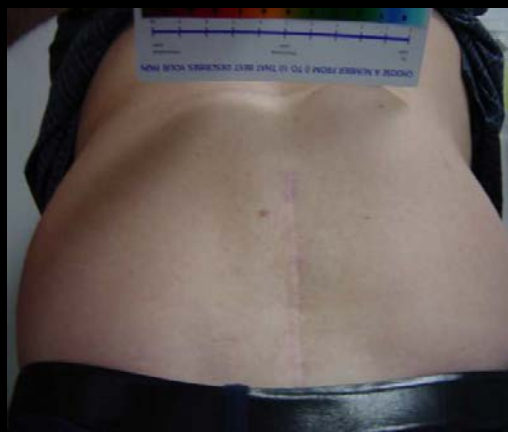
- What would be the predicted antalgic behavior?

Visual Examination

- Presence of Scars
- Lumps (abscess or tumor)
- General Symmetry
- Kyphosis/Lordosis/Gibbus
- Presence of Muscle Spasms (non-voluntary)

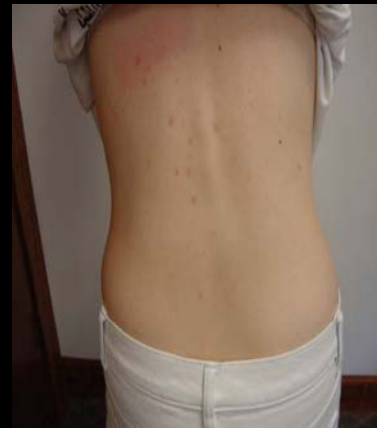
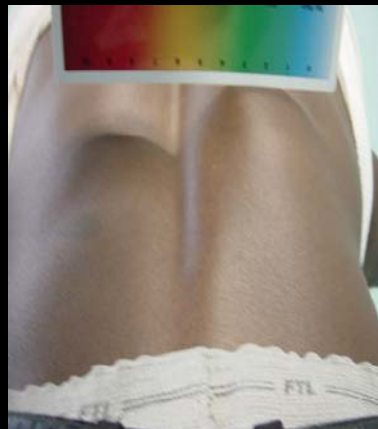
Photographs of the back as a means of objectively documenting back pain is offered as a result of clinical observations by the presenter.



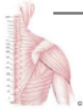Clinical Pearl

- *“A picture is worth a thousand words.”*
 - The presence of non-voluntary muscle spasm helps support the veracity of patient complaints, and is the first indicator of a problem.
 - May be very important to help demonstrate the need for certain medications, especially in the presence of normal imaging studies.



...they also help demonstrate the treatment

effectiveness of



Neural Pain Assessment, PC

David M. Glick, DC
DIPLOMATE AMERICAN ACADEMY OF PAIN MANAGEMENT
Specializing in complex neck and back pain

7329 Boulders View Lane
Richmond VA 23226
804-327-0084
Fax: 866-602-1146
www.painrx.net
npa@painrx.net

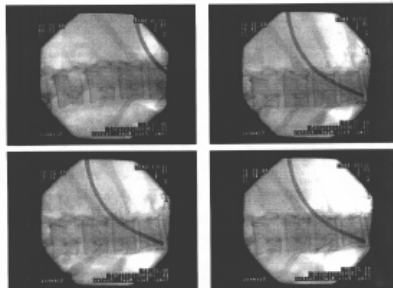
September 3, 2009

PATIENT: R***** G*****
DOB: **/**/1978

Consultation Record

History of Present Complaints: R***** presented today for a follow-up examination after last being seen on August 25th, at that time to undergo manipulation assisted by the use of local regional anesthetic in the form of a medial branch block. From what I understand, she apparently had done pretty well until several days later when she was mowing her lawn, when she started experiencing a more mild exacerbation of her pain, which had her concerned. Then apparently last night she was sitting down on the floor and sneezed and experienced an immediate onset and return of her back, buttock, and leg pain, reportedly to the same intensity of her original complaints. She did note that the numbness and tingling she had been experiencing into the left lower extremity and the giving out of the left leg had improved and not returned. The balance of the medical history remains unchanged.

She was seen by Dr. Nazmi this morning, who based on the recurrence of her symptoms thought it appropriate to repeat the medial branch block for a confirmatory diagnosis prior to considering a facet ablation. The medial branch block included fluoroscopic guided injections to address the facet joints associated with T10/T11, T11/T12, and L1/L2 infiltrated with 2 cc of 1% Lidocaine initially followed by 0.5% bupivacaine and 2.5 mg of dexamethasone at each level.

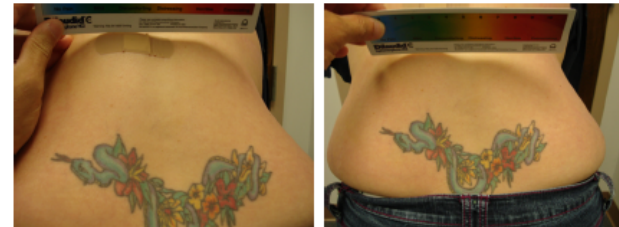

Medications: Ibuprofen and Percocet in addition to the Singular and Advair.

Clinical Evaluation: On clinical examination today, R***** was alert and oriented though ambulating somewhat slowly, which she attributed to the soreness from the injection. Her vital signs at the time of the consultation were BP 109/88 and pulse 60. She was afebrile. Visual and palpatory examination demonstrated spasms of the erector spinae muscles on the left including longissimus, iliocostalis thoracis, and iliocostalis lumborum as well as the quadratus lumborum muscles, which are pictured for the record. There was an anterior tilt to the right ilium

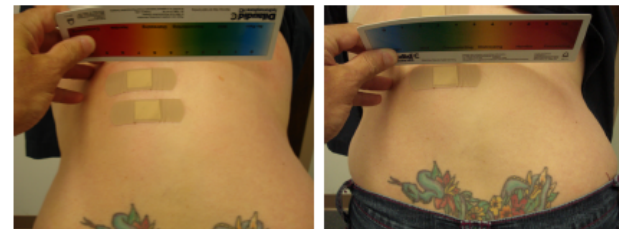G***** 09/03/09 Page 1 of 3

associated with the quadratus lumborum with focal areas of tenderness noted over the T10/T11, T11/T12, and T12/L1 facet joints though not sharp pain. Photographs of the persistent spasms are included for the record.



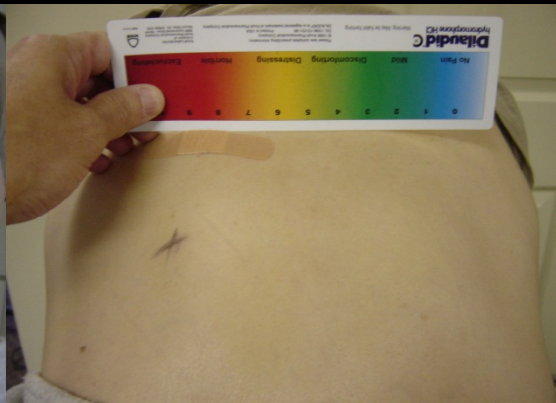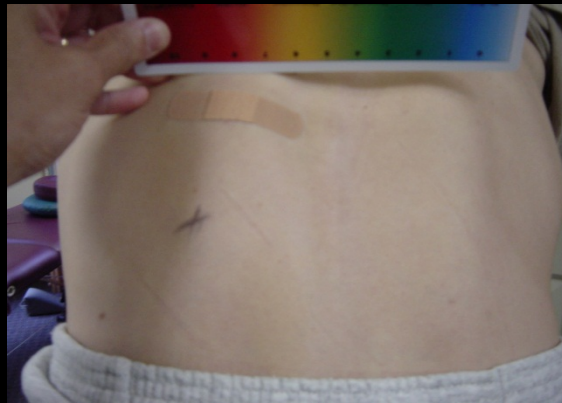
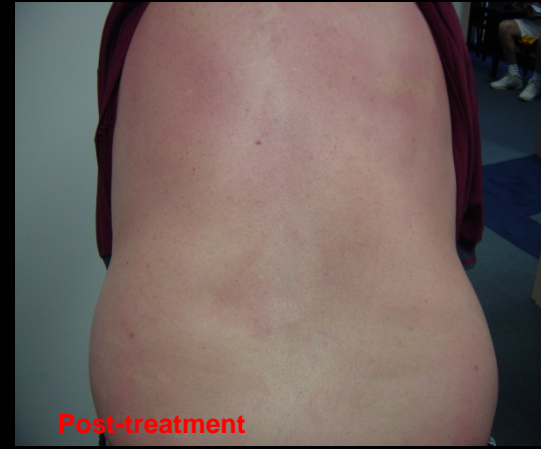
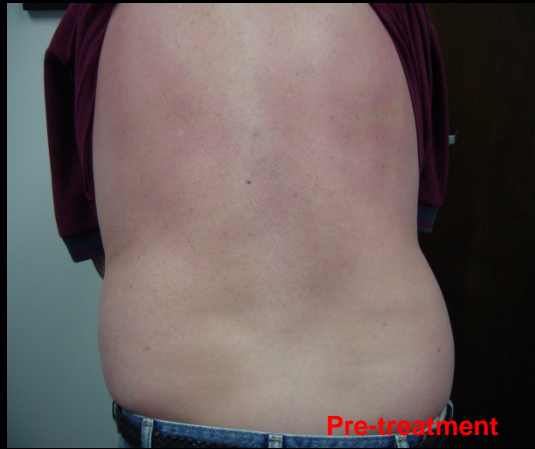
Assessment & Treatment: Since she had responded well to the manipulation upon the medial branch block on the prior occasion it was repeated on this, initially with manipulation in a seated position to address T12/L1 and L1/L2 and then lying supine to address T9/T10, T10/T11, and T11/T12. Upon doing so, the longissimus, iliocostalis, as well as quadratus lumborum spasms abated though there was a detectable spasm of the spinalis muscle persisting as well as a focal area of pain at T4/T5, which was then addressed with gentle manipulation with focus to T4/T5 with her lying supine, again without complication. Since there was still decreased translational movement in the left SI joint, manipulation of the left SI joint was provided as well with her lying on her side to correct for the anterior tilt.

On post treatment assessment, the spasms of the erector spinae muscles completely abated including the quadratus lumborum. Photographs of the back were now included for comparison. Normal translational movement was restored to the left SI joint.



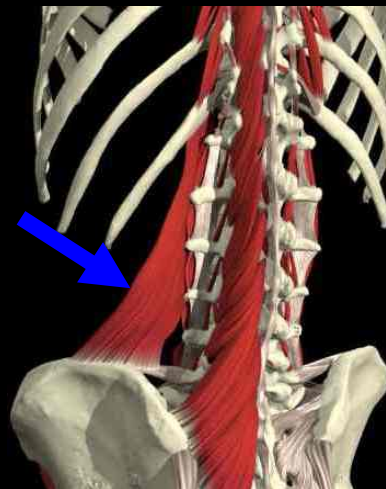
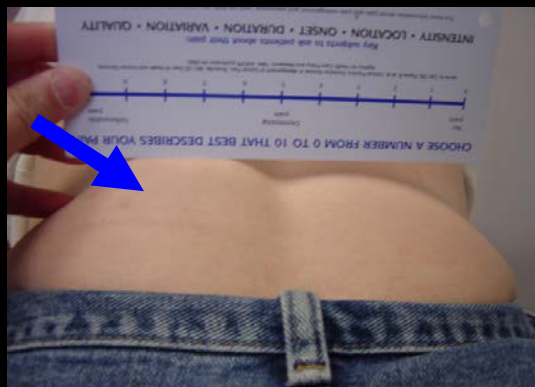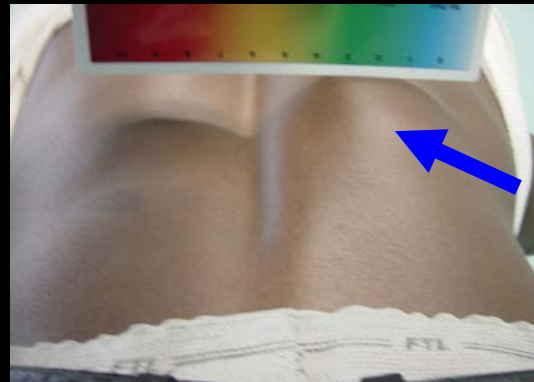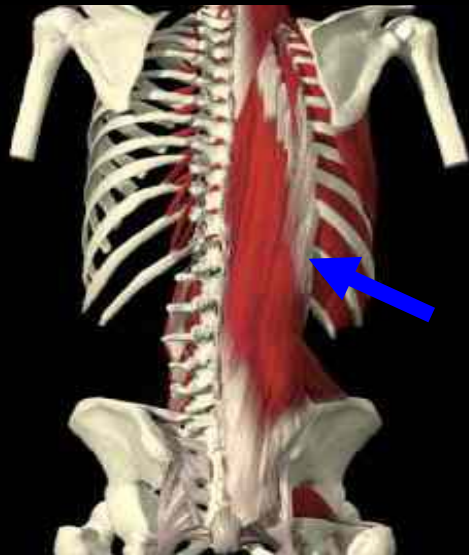
Obviously there was still persistent tenderness over the corresponding facet joints but less bigger than it had been and even deep firm pressure into the piniformis did not elicit breakaway of lower extremity nor radiation of pain. After observing R***** for a period of time to ensure that she did not experience an adverse reaction to the treatment and that the response to the treatment persisted, she was discharged though this time given very specific instructions to do whatever

G***** 09/03/09 Page 2 of 3

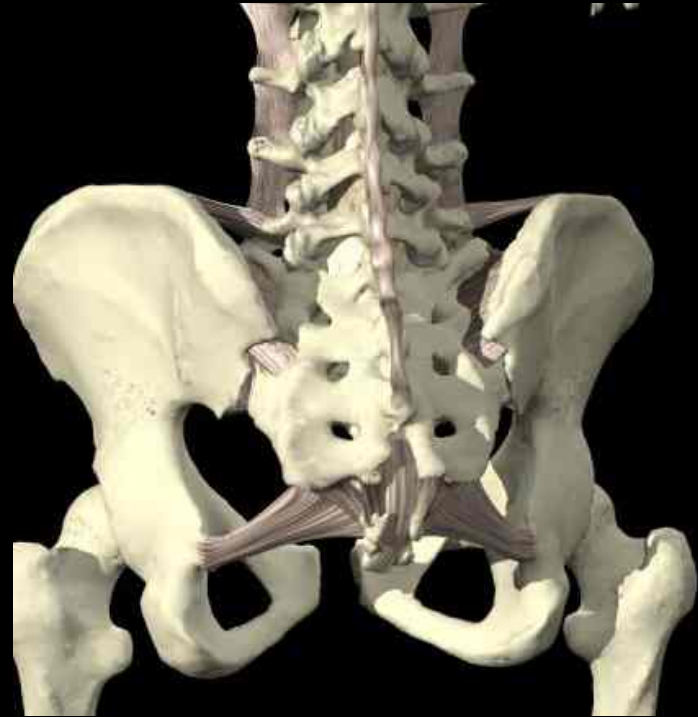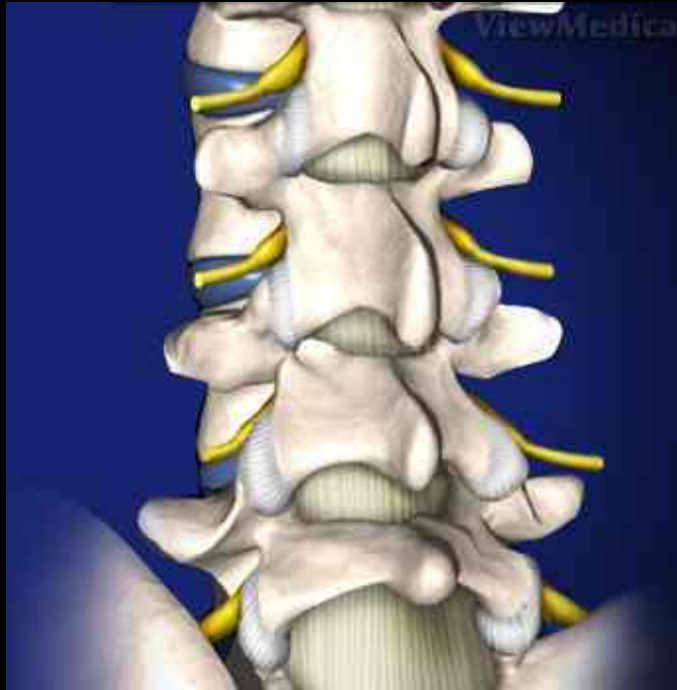


Photographs are offered as a means of documenting changes post treatment based upon the clinical observations by this presenter.

Correlate palpatory findings with underlying structures



Palpation Bony Structures



Visual & Palpatory Examination

Flexion/Weight Bearing

- Muscle Spasms
- Bony Structures (facets, spinous processes, PISIS, Ilium)
- Ligaments, Tendons
- Paravertebral & Extraspinal
- Localize Pain Generators

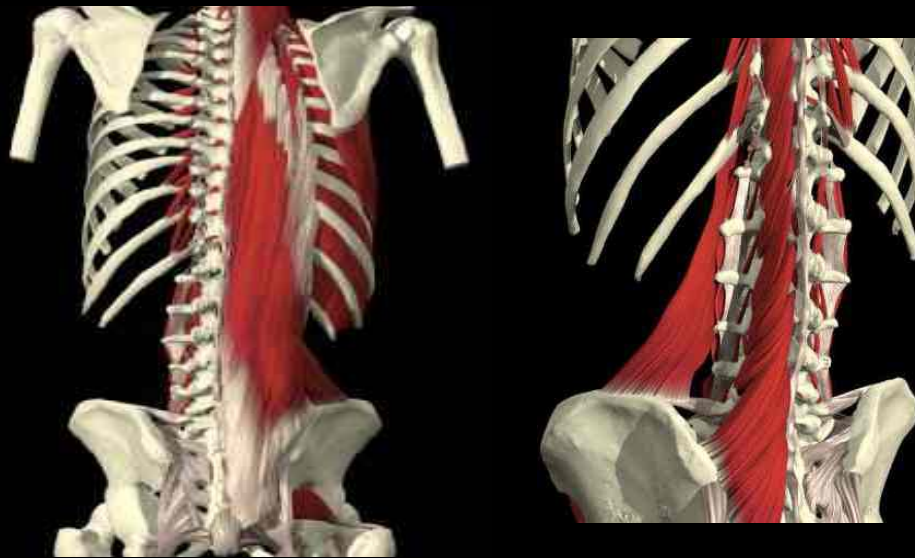
Visual & Palpatory Examination

Lying Prone

- Muscle Spasms
- Bony Structures (facets, spinous processes, PISIS, Ilium)
- Ligaments, Tendons
- Paravertebral & Extraspinal
- Localize Pain Generators

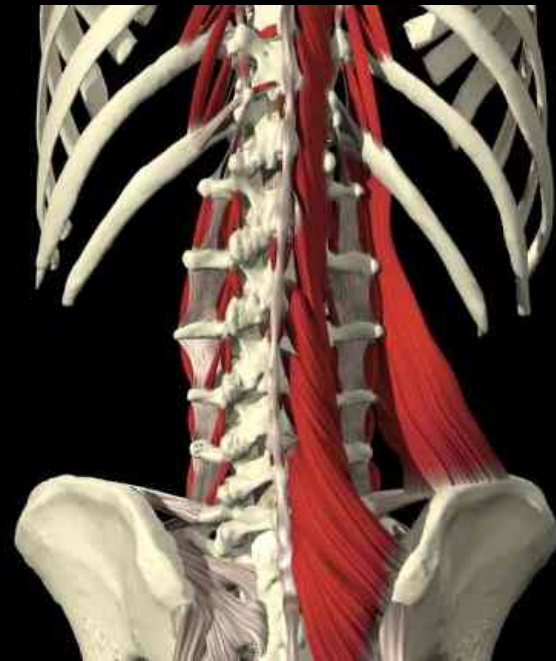Change in finding can be very helpful in evaluating the problem

Primary vs Secondary Muscle Spasms

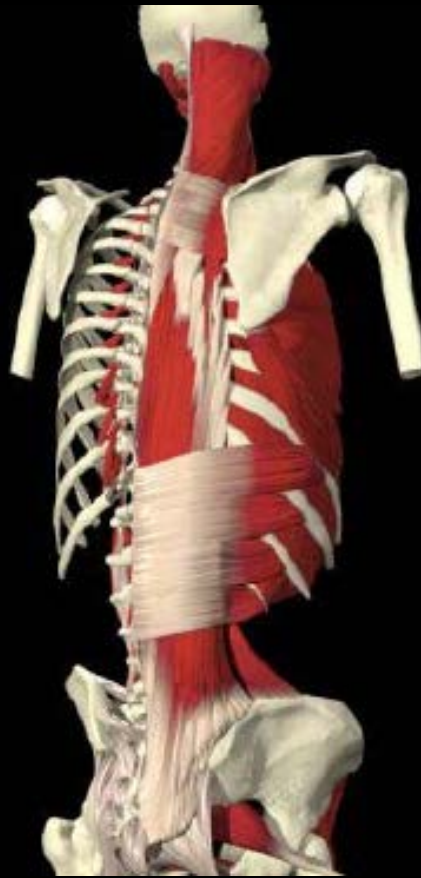

Clinical Pearl

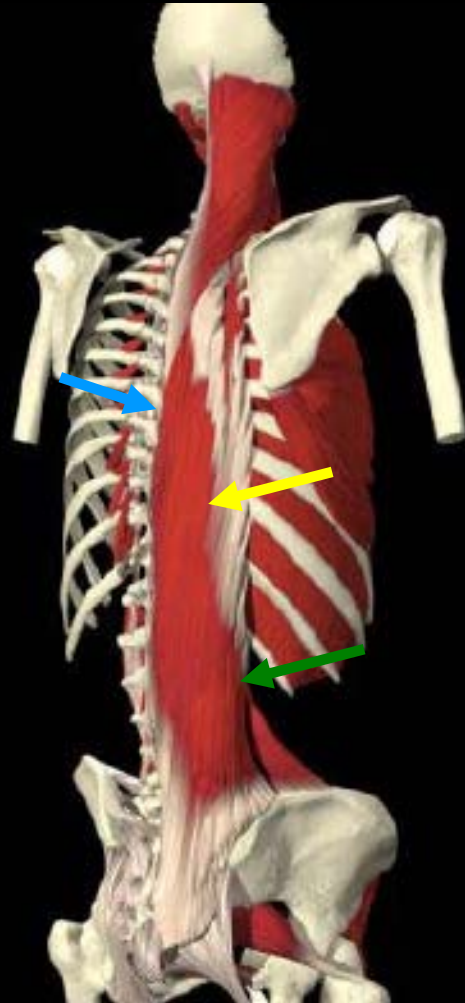
Remember to visualize the underlying structures while palpating



Lumbar Anatomy



Visual & Palpatory Examination



- Erector Spinae Muscles

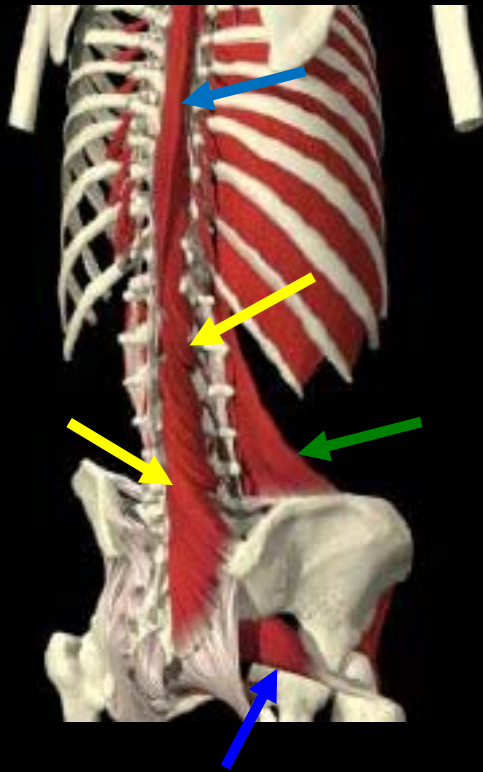
Spinalis

Longissimus

Iliocostalis

(Thoracis & Lumborum_

Visual & Palpatory Examination



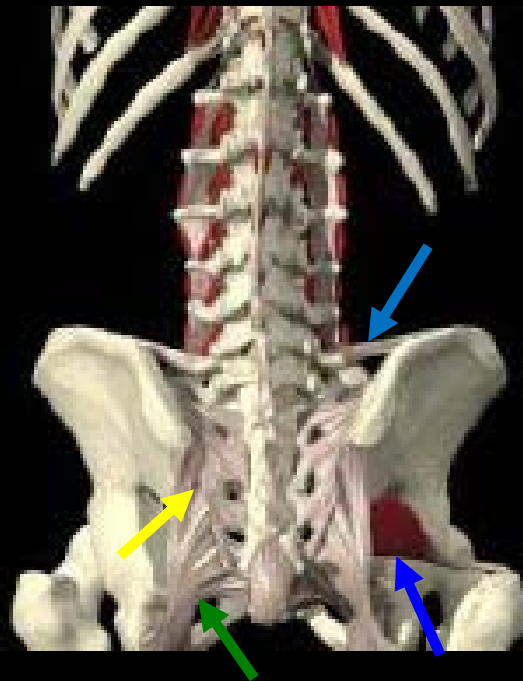
Spinalis

Multifidus

Quadratus Lumborum

Piriformis

Visual & Palpatory Examination



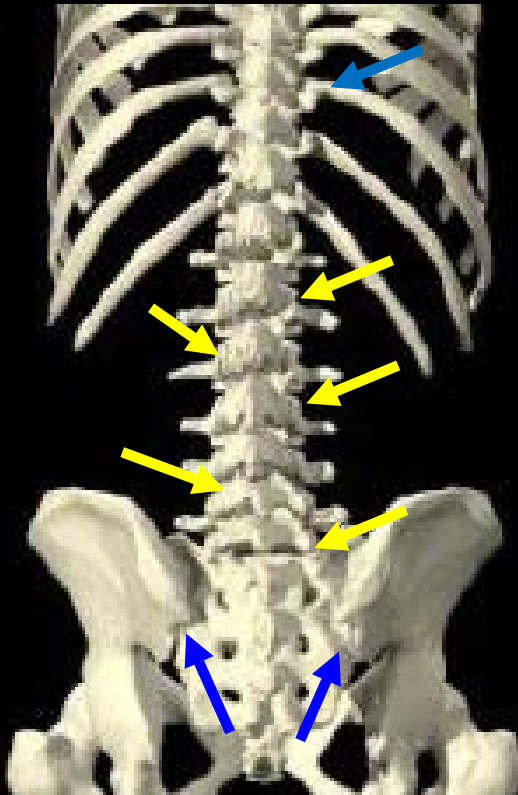
SI Joint ligaments

Iliolumbar ligament

Piriformis

sacrotuberous ligament

Visual & Palpatory Examination



Facet Joints

left/right

each spinal level

Costovertebral joints*

each level

SI Joints

Range of Motion

- Degree of motion in each plain
- Assess behavior during active ROM
- Presence of pain
- Characteristics of pain
 - *(pulling, catching, sharp, dull . . .)*

Routine Physical Assessment

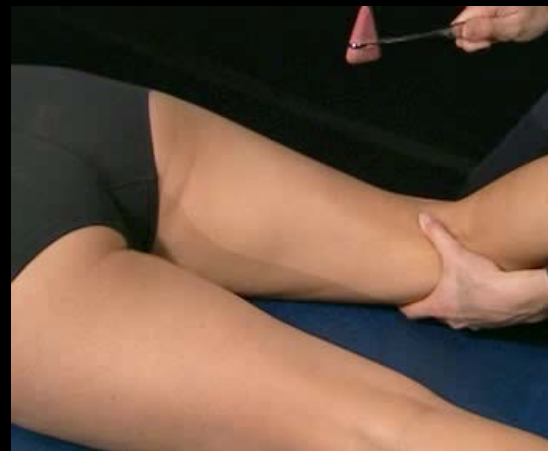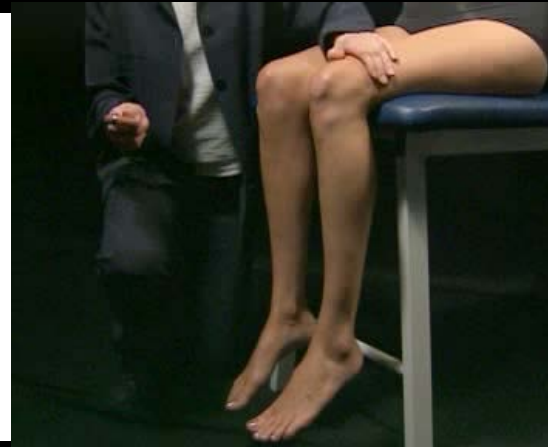- Deep Tendon Reflexes
- Sensory Examination
- Motor Function

Hoppenfeld S, Hutton R, Physical Examination of the Spine and Extremities
Prentice Hall, June 1999 (ISBN-13: 9780838578537)

Hoppenfeld S, Orthopaedic Neurology: A Diagnostic Guide to Neurologic Levels, Lippincott
Williams & Wilkins, June 1977. (ISBN-13: 9780397503681)

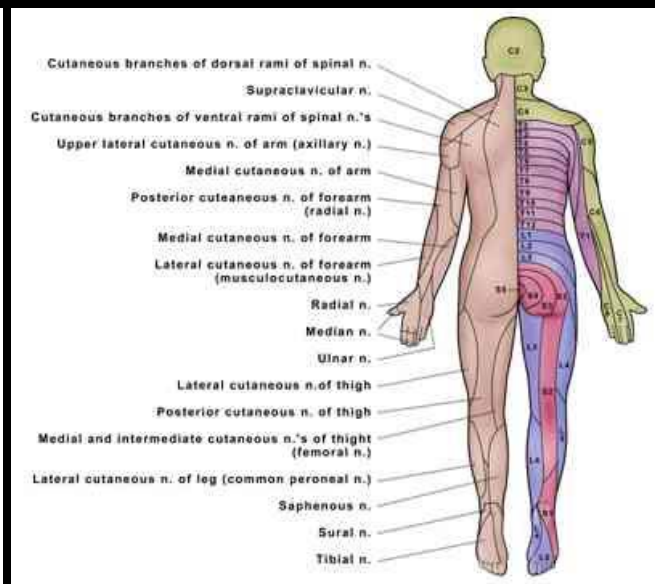
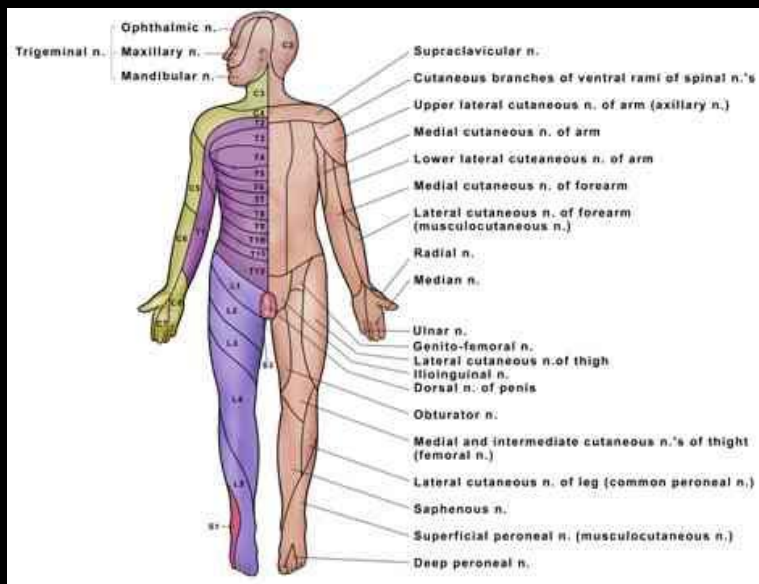
Deep Tendon Reflexes

Deep Tendon Reflexes	
Reflex	Main Spinal Nerve Roots Involved
Biceps	C5, C6
Brachioradialis	C6
Triceps	C7
Patellar	L4
Achilles Tendon	S1



Sensory Examination

Dermatomes & Myotomes



Muscle Strength

Rate each muscle or muscle group according to the following five point grading scale

Score	Muscle Response
0	No Movement
1	Muscle belly moves but the joint does not move
2	Joint moves with gravity eliminated
3	Joint moves against gravity
4	Joint moves against gravity and some resistance
5	Full strength

Common Lower Extremity Muscles Tested

Iliopsoas	L2-L4	Flex hip
Quadriceps		Extend knee
Hamstrings	L5-S2	Flex knee
Gluteus maximus		Extend hip
Tibialis anterior	L4-L5	Dorsiflex foot
Tibialis posterior		invert foot
Peronei	L5-S1	Evert foot
Extensor hallucis longus		Extend (dorsiflex) great toe
Gastrocnemius	S1-S2	Plantar flex foot

Provocative Examination

- Minor's
- Bechterewe's
- FABER Patrick
- Piriformis Stretch
- SLR (aka Lasegue's)
- Goldwaith's, Braggard's, Sicard's, Bowstring
- Leg Lowering, Milgram's
- Double SLR (Bilateral LR)

Provocative Examination *(cont)*

- Hibb's
- Nachlas
- Yeoman's
- Belt Test
 - (aka Supported Adams)
- Glick's Test
- SI Range of Motion

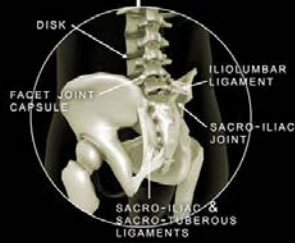Suggested References

- Illustrated manual of part I, neurological reflexes/signs/tests, part II, orthopedic signs/tests/maneuvers for office procedure , J.M. Mazion; 2nd ed edition, 1980.
- Photographic Manual of Regional Orthopaedic and Neurological Tests, Cipriano, Jahn & White, Lippincott Williams & Wilkins; 3rd edition, 1997.
- Physical Diagnosis of Pain, Waldman, Elsevier Saunders, 2006.

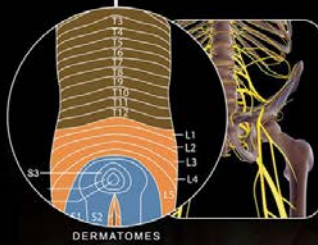
LOWER BACK PAIN

STRUCTURES INVOLVED

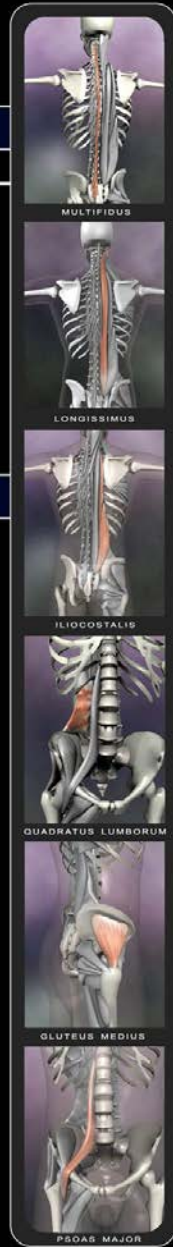CONNECTIVE TISSUE



NERVE



MUSCLE



STATISTICS

50% OF AMERICANS ADMIT TO HAVING BACK PAIN SYMPTOMS EACH YEAR.
 80% OF THE POPULATION WILL EXPERIENCE A BACK PROBLEM AT SOME TIME IN OUR LIVES.
 AMERICANS SPEND AT LEAST \$50 BILLION EACH YEAR ON BACK PAIN.
 MOST CASES OF BACK PAIN ARE MECHANICAL OR NON-ORGANIC,
 MEANING THEY ARE NOT CAUSED BY SERIOUS CONDITIONS.

CAUSES

OVERUSE/ INJURY

SPRAINS STRAINS INFLAMMATION

WEAKNESS

SEDENTARY LIFESTYLE
 CHRONICALLY STRETCHED
 NERVE IMPINGEMENT

DEGENERATION

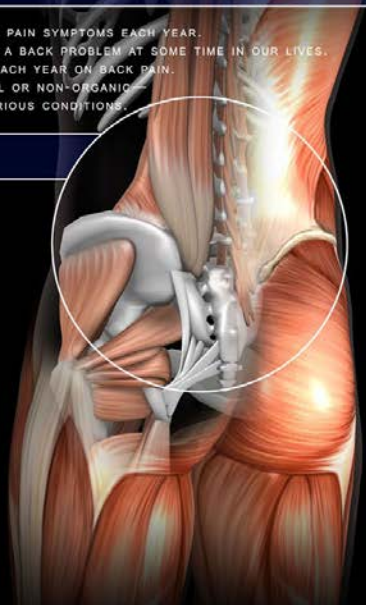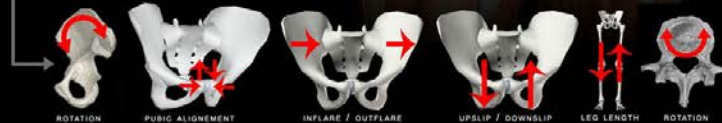OSTEOPOROSIS
 DISK COMPRESSION

NERVE IMPINGEMENT

ABNORMAL BONE GROWTH

OSTEOARTHRITIS
 SPONDYLOLISTHESIS
 CANCER

POSTURAL MIS-ALIGNMENT

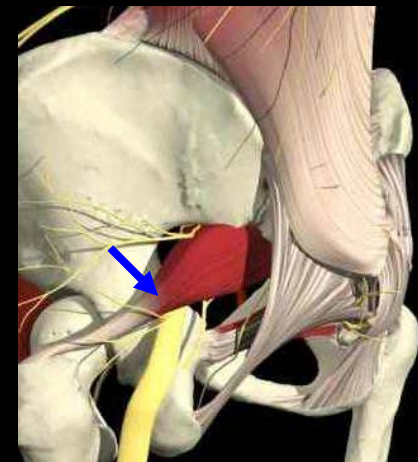
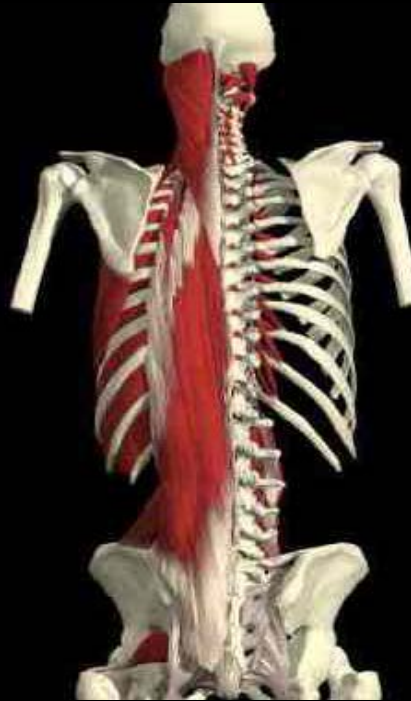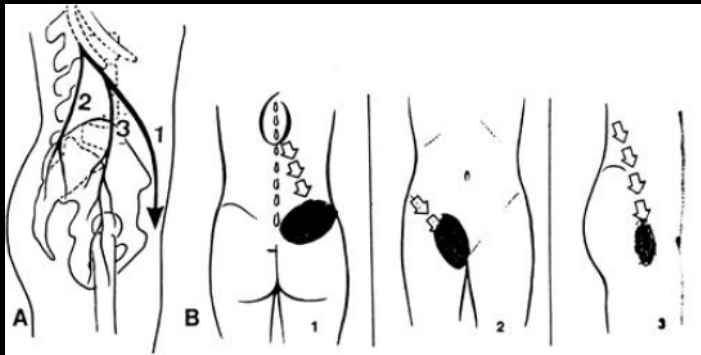


Other common causes of low back ... *pain when the low back is not involved*

- **Thoracolumbar Junction Syndrome**
 - Several variations w/ and w/t nerve involvement
- **Piriformis syndrome**
 - Entrapment vs. anomaly
 - Primary vs. secondary
- **Sacroiliac joint problems**
 - Inflamed (sacroiliitis) vs, arthropathy
- **Hip pathologies**

Thoracolumbar Junction Syndrome

- Mainge R, Semilogie des derangements interveretbraux mineurs. Ann Med Phys 1972 277-289



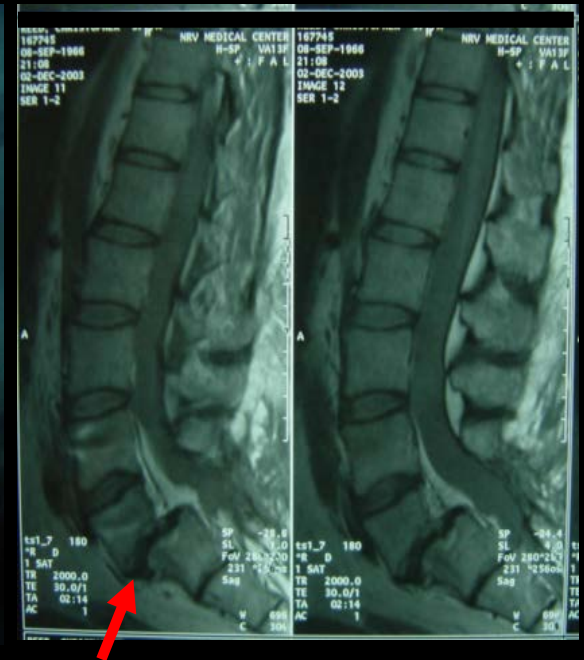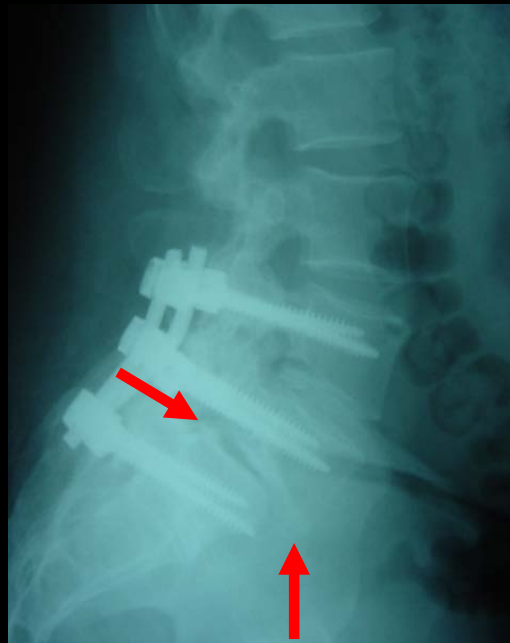
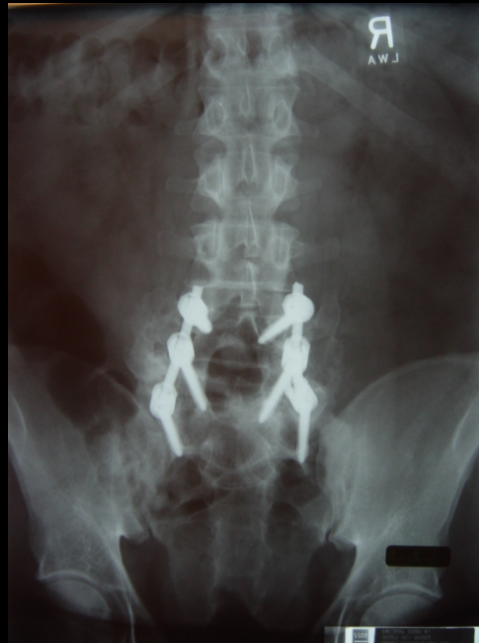Formulating Clinical Impression

- Does this particular clinical situation seem familiar, on the basis of the HISTORY?
- Is there a single answer which explains even a multitude of complaints/symptoms?
 - (remember Occam's Razor --simplest possible explanation.)
- *What are the other explanations?*
 - *Remember common things occur most commonly. Therefore considerations are considered from most likely to least.*
 - *Do pay attention to conditions that can result in increased morbidity/mortality if not identified promptly.*

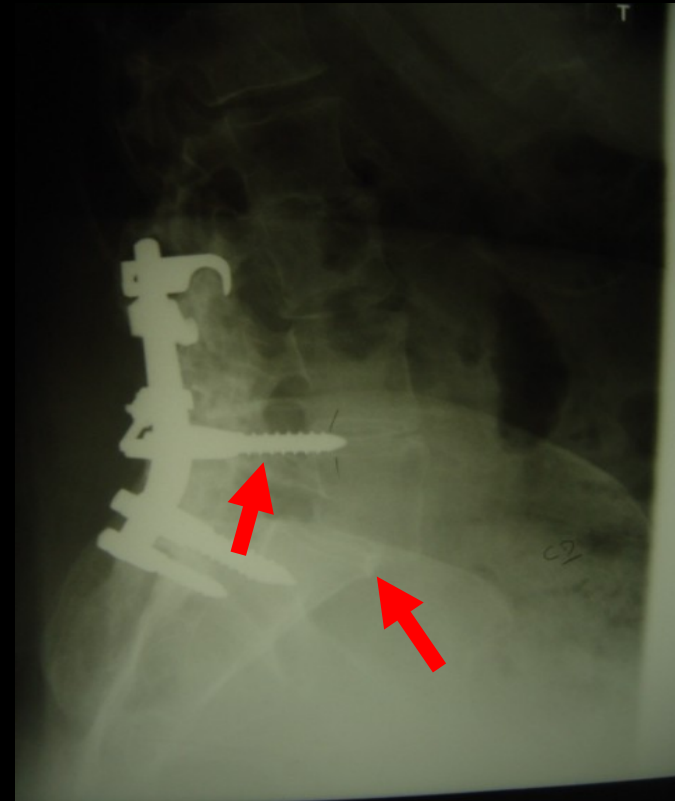
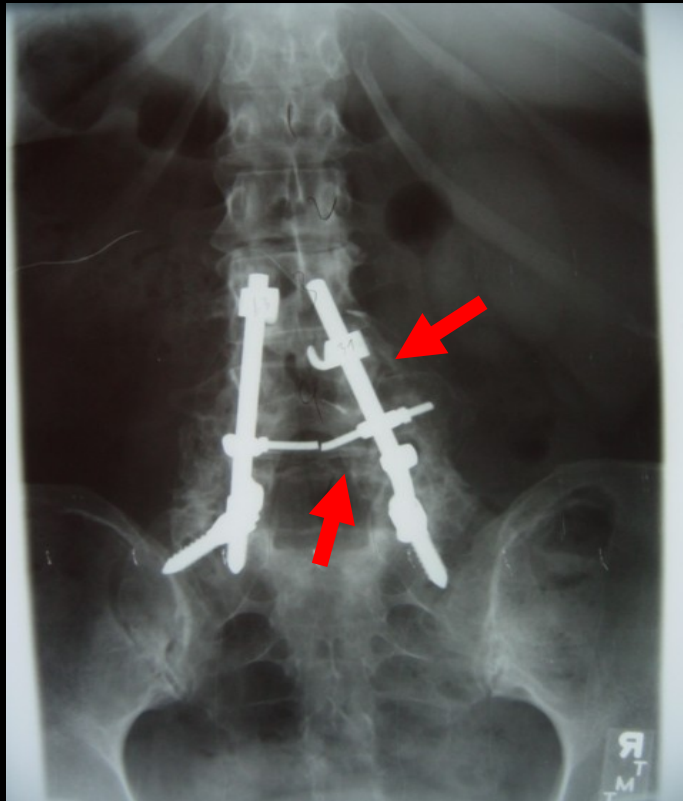
Formulating an Impression *(cont)*

- Does distribution of pain correlate with clinical impression?
- Do the imaging and other test results account for the clinical findings?
- Is the overall clinical picture explained?
- If questions exist, it may be necessary to revisit parts of the clinical examination.
- Review findings with patient

There are occasions when then examination may be almost a moot point



There are occasions when then examination may be almost a moot point



Further Clinical Assessment

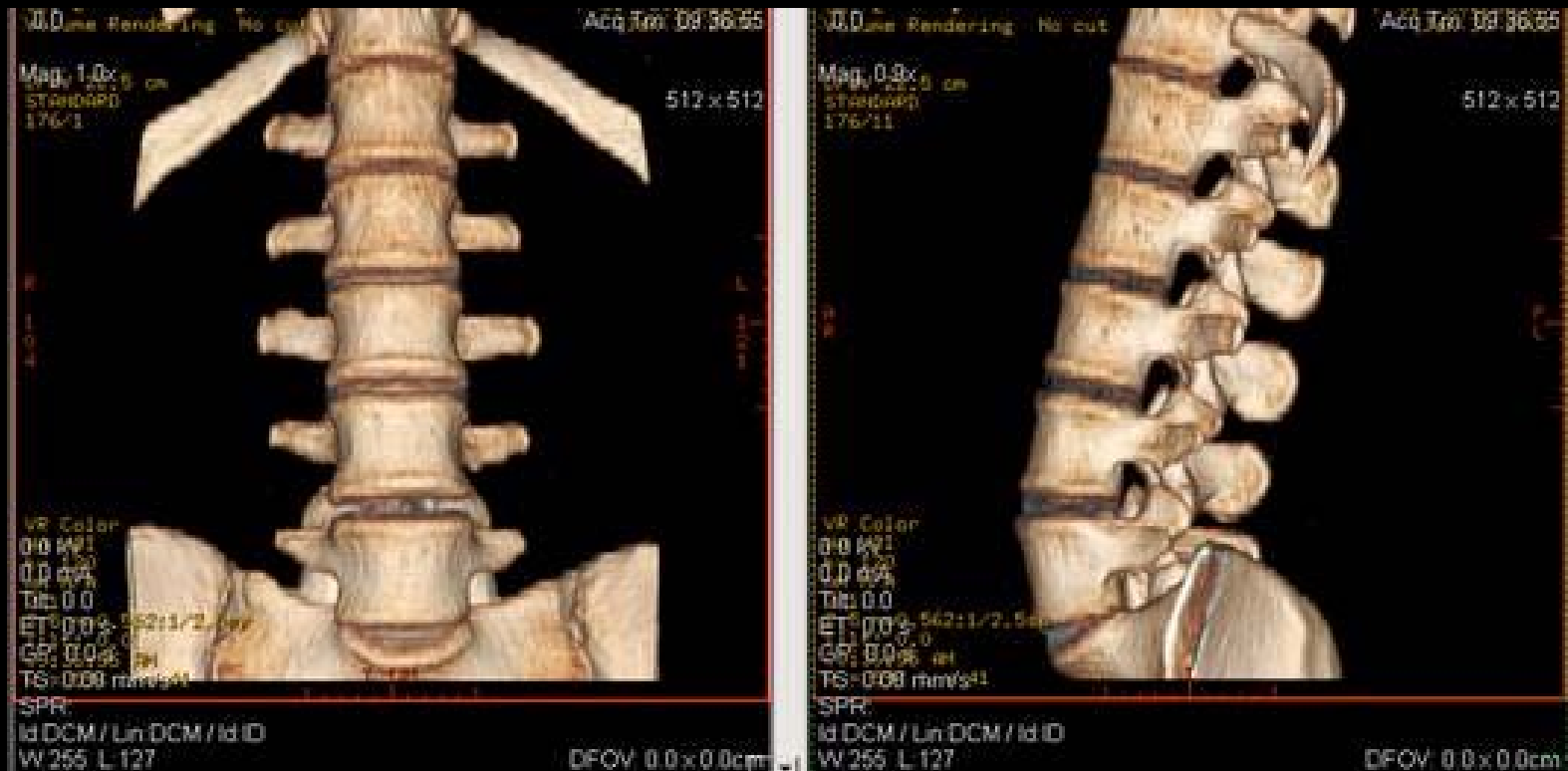■ Structural

- ▶ X-ray
- ▶ MRI
- ▶ CT
- ▶ Bone Scan
- ▶ Discography
- ▶ 3D CT

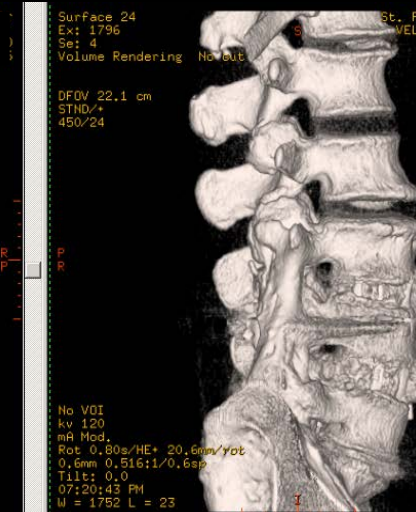
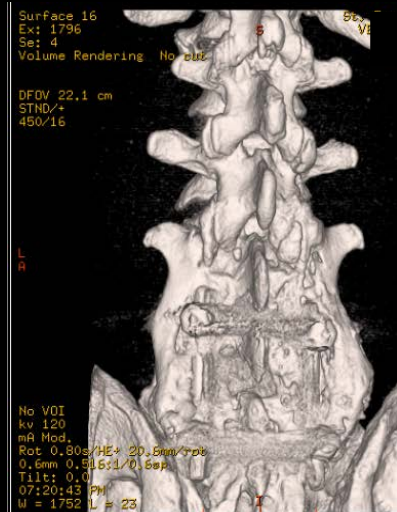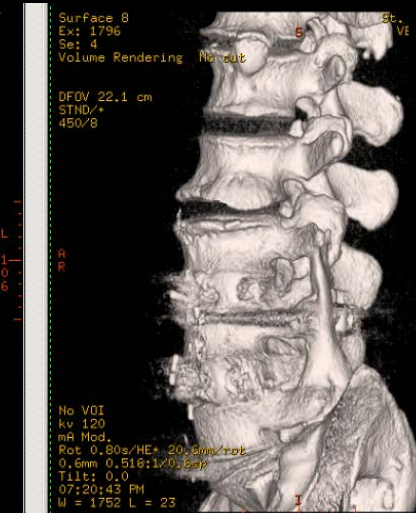
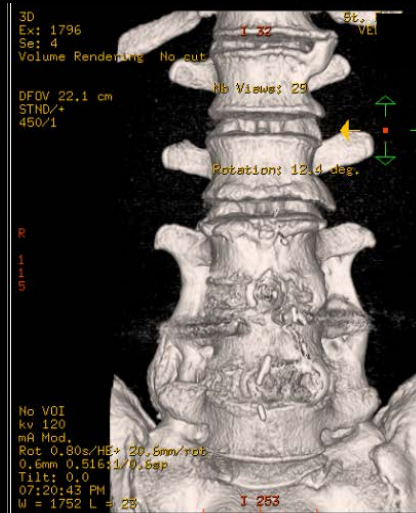
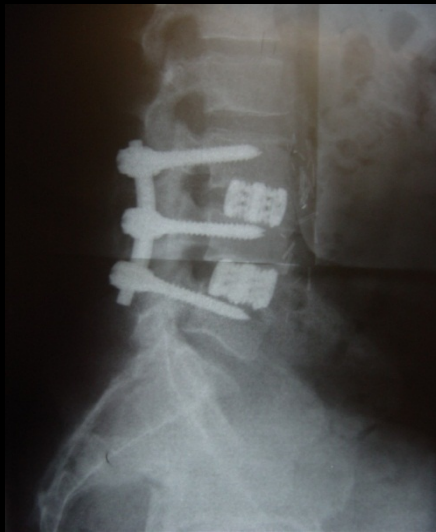■ Functional

Electromyography
(EMG/NCV)
SEP

CT with 3D Reconstruction



X-ray vs. 3D CT



Surface 24
Ex: 1796
Se: 4
Volume Rendering No cut

St.
VE

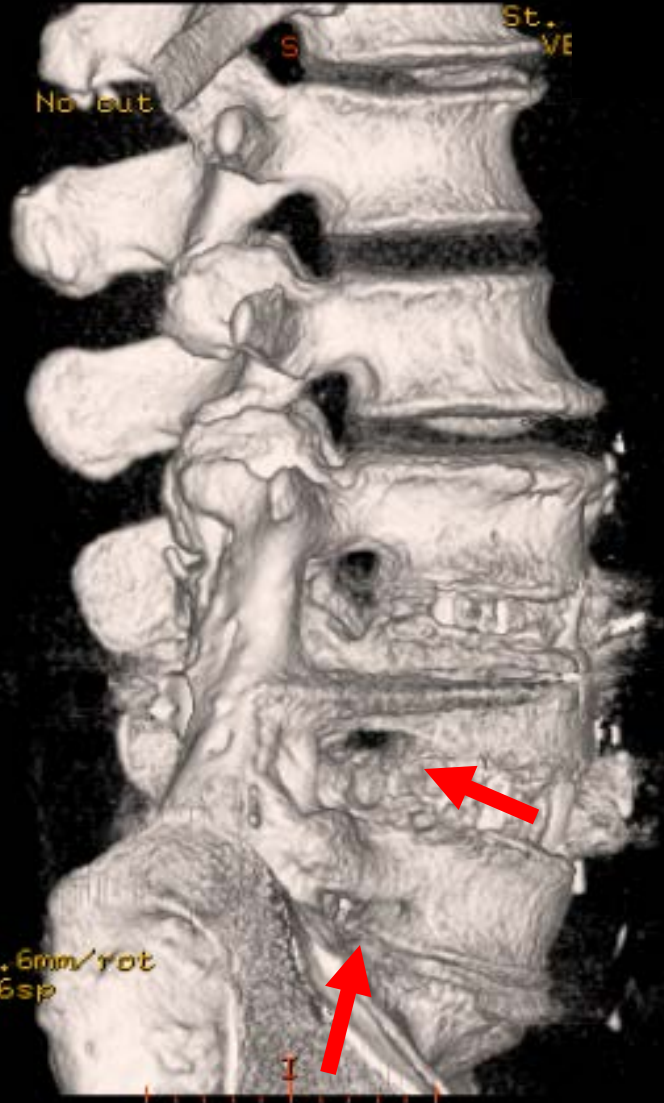
Jan 16 2006

DFOV 22.1 cm
STND/+
450/24

P
R

L
R

No VOI
kv 120
mA Mod.
Rot 0.80s/HE+ 20.6mm/rot
0.6mm 0.516:1/0.6sp
Tilt: 0.0
07:20:43 PM
W = 1752 L = 23



I

Thinking outside the box

- *There is nothing in writing that dictates that each therapy be attempted separately.*
 - ▶ For example- if an SI joint seem frozen and inflamed on clinical examination why not inject with anesthetic and anti-inflammatory medication, then manipulate immediately following?

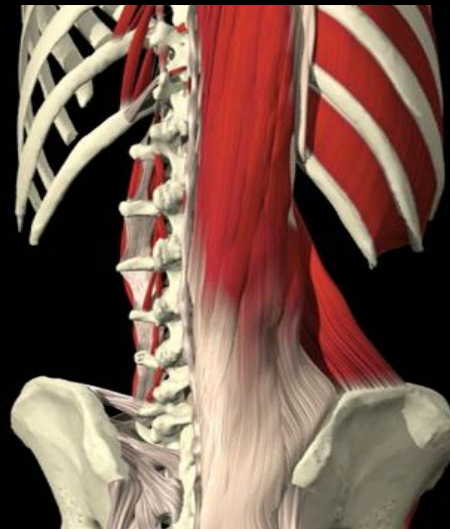
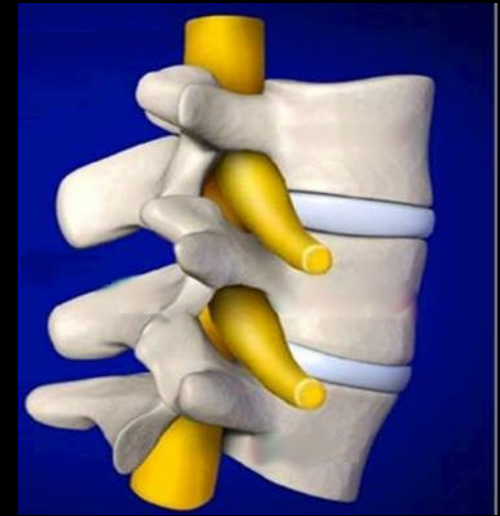Key considerations

- Back pain is Symptom not a pathology.
- All pain is not caused by disc herniations or “pinched nerves.”
- There is no single treatment to address back pain.
- Chronic back pain often occurs from failure to adequately diagnose and treat.



Mechanical/Musculoskeletal Causes of Back Pain

- Disc
- Facet
- Ligamentous
- Muscular (including Tendons)
- Neurogenic
- Joint related



Tips to Remember

- A picture is worth a 1000 words.
- The best tools for the treatment of back pain are the history and clinical examination.
- Limited examinations can ultimately be more costly.
- The symptoms are often associated with multiple pain generators that can be unraveled.

