

Peripheral Nerve Injury in the Athlete: Upper and Lower Limb Entrapment Neuropathies

Greg Moore, MD
Sports and Spine Rehabilitation
NeuroSpine Institute

Outline

- Review common nerve entrapment and injury syndromes, particularly related to sports
- Review pertinent anatomy to each nerve
- Review typical symptoms
- Discuss pathophysiology
- Discuss pertinent diagnostic tests and treatment options

Neuropathy

Mononeuropathies

- Median
 - Pronator Teres
 - Anterior Interosseous Nerve
 - Carpal Tunnel
- Ulnar
 - Cubital Tunnel
 - Guyon's Canal
- Radial
 - Axilla
 - Spiral Groove
 - Posterior Interosseous Nerve
- Femoral
 - Intrapelvic
 - Inguinal Ligament
- Sciatic
 - Piriformis
- Peroneal
 - Fibular Head
- Tibial
 - Tarsal Tunnel

Sports Medicine Pearls

- Utilize your athletic trainers
- Individualize your diagnostic and treatment approach based on multiple factors
 - Age
 - Sport
 - Level of Sport (HS, college, professional)
 - Position

Sports Medicine Pearls

- Time in the season
- Degree of pain/disability
- Desire of the patient/parents
- Coach's desires/level of concern
- Cost (rarely discuss with the coach)
- Danger of a delay in diagnosis
- Impact to the team

Obtaining the History

- Pain questions- location, duration, type, etc.
- Presence and location of numbness and paresthesias
- Exertional fatigue and/or weakness
- Subjective muscle atrophy
- Symptom onset- insidious or post-traumatic
- Exacerbating activities

History (continued)

- Changes in exercise duration, intensity or frequency
- New techniques or equipment
- Past medical history and review of systems
 - Diabetes
 - Hypercoaguable state
 - Depression/anxiety
 - Nutritional deficiencies
 - Thyroid disease

Physical Exam

- Spinal ROM, tenderness and provocative tests
 - Spurling's, Hoffman's, etc.
- Extremity ROM, tenderness, swelling, temperature changes, discoloration, sensation, pain with resisted movements, sensation deficits
- Muscle weakness and atrophy

Exam (continued)

- Anatomic malalignments
- Biomechanical abnormalities
- Provocative testing
 - Tinel's (reproduction of symptoms by tapping over the nerve; compared to unaffected side)
 - Diagnosis specific (i.e., carpal tunnel tests)
- Post-exercise testing

Diagnostic Testing

- Plain radiographs
- MRI, CT or bone scan
 - Of all imaging, MRI most likely to be diagnostic
 - Others often more “exclusionary”
 - Vascular studies- ABI, MRA, angiography
- Labs- glucose, HgbA1C, thyroid, sed rate, CRP, CPK, B12/folate, rheumatologic studies, etc.

Electromyography and Nerve Conduction Studies

- May be helpful but not always diagnostic even if a neuropathy present
- Testing at rest could produce a false negative
- Often 3 weeks of pathology required before EMG/NCS abnormalities can be detected
- An unrelated neuropathy may be detected
- Choose your specialist wisely- someone familiar with athletically-related neuropathies and someone who performs these on a frequent basis

Electrodiagnosis

- Clarify etiology of symptoms
 - Radiculopathy vs. Plexopathy vs. Neuropathy
 - Clarify the type of neuropathy
 - Identify a potential source of pain
- Localize a PNS lesion
- Assist in decision making
- Predict neurological prognosis
- Exclude other disorders

Electrodiagnosis

General Diagnostic Options

- Normal
- Radiculopathy
- Plexopathy
- Neuropathy
- Myopathy
- Widespread Denervation (MND)
- Disorders of neuromuscular transmission

Electrodiagnosis

Specific Diagnostic Options

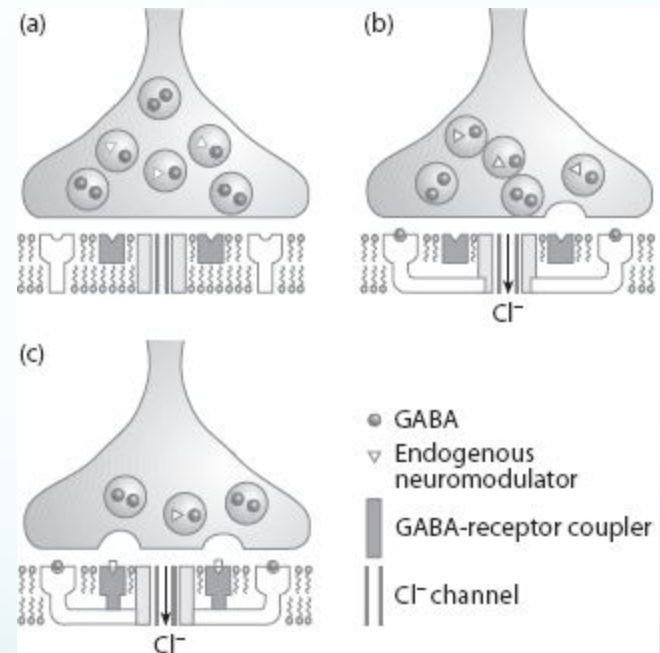
- Acute vs. Chronic vs. Acute & Chronic
- Mild vs. Moderate vs. Severe
- Anatomic Location
 - Root
 - Plexus
 - Nerve
 - Neuromuscular junction
 - Muscle
- Distribution
 - Polyradiculopathy
 - Trunk, Cord
 - Mono vs. Multiplex vs. Distal Symmetric

Treatment

- Highly variable depending on the specific pathology, etiology, degree of pain and disability and proven methods of correction
- 3 **R's**- rest, rehab and/or referral
- NSAIDS, corticosteroids (oral or injectable)
- Improvements in muscle strength, flexibility, posture
- Correction of biomechanical abnormalities and/or errors in technique

Meds

- Types of substances
 - Antidepressants
 - Anti-convulsant meds
 - NSAIDs
- Mechanism of action
 - Nerve transmission modulation
- Examples
 - Amitriptyline
 - Cymbalta
 - Gabapentin (Neurontin)
 - Pregabalin (Lyrica)
 - Gralise

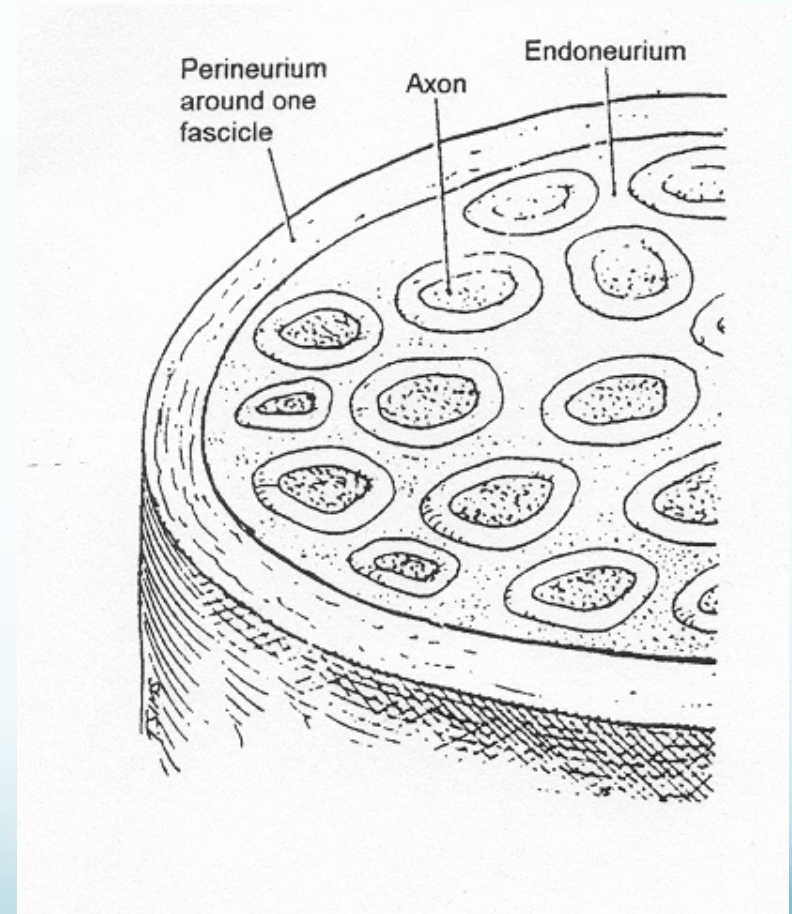


Surgical Treatment

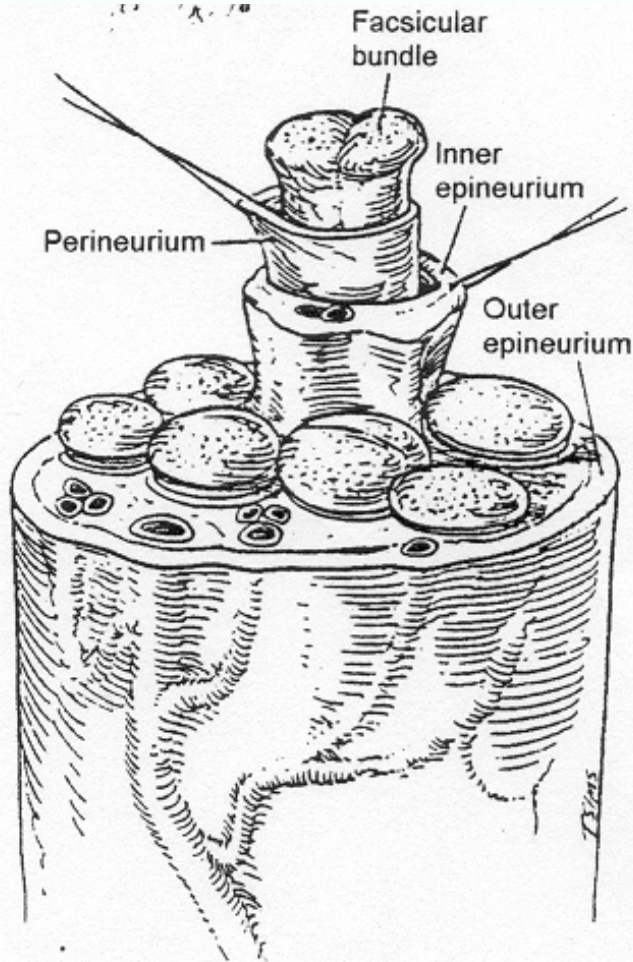
- Nerve decompression
- Neurolysis
- Neuroma excision
- Nerve resection
- Nerve repair
- Nerve or muscle transfer

Basic Nerve Facts

- Anatomy
 - Endoneurium
 - Surrounds axons of peripheral nerves
 - Fascicles
 - Groups of axons
 - Perineurium
 - Surrounds individual fascicles
 - Epineurium
 - Intraneural
 - Outer circumferential



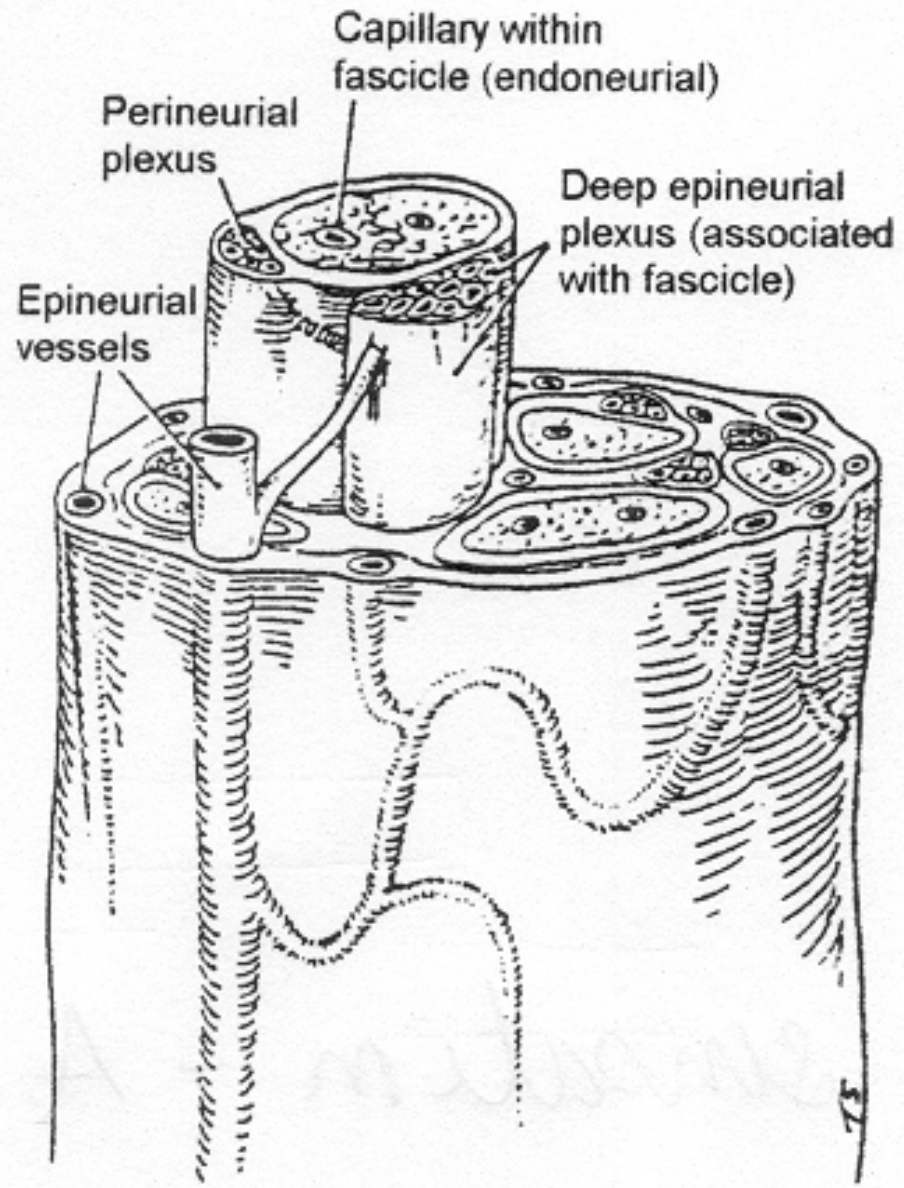
Basic Nerve Facts



- Anatomy
 - Epineurial repair
 - Outer epineurium sutured
 - Fascicular bundle and perineurial repair
 - Inner epineurium repaired
 - Fascicular repair
 - Perineurium sutured

Basic Nerve Facts

- Anatomy
 - Vascular supply
 - Arteriae nervorum
 - Enter nerve segmentally
 - Divide into longitudinal superficial and interfascicular arterioles
 - Longitudinal epineurial and perineurial vessels
 - ALLOW FOR INTRANEURAL DISSECTION FOR FASCICULAR REPAIR
 - Internal neural anatomy
 - Discrete bundles and branches



Basic Nerve Facts

- Physiology
 - Peripheral nerve signaling
 - Localized potentials
 - Short distances
 - Decrease over distance
 - Key for intercellular junctions and sensory nerve endings
 - Action potentials
 - Conducted impulses that DO NOT decrease over distance

Basic Nerve Facts

- Physiology
 - Peripheral nerve signaling
 - Action potentials
 - Unmyelinated fibers
 - Rate of conduction directly proportional to cross section of axon
 - Myelinated fibers
 - Impulse jumps from each site of interrupted myelin sheath (Node of Ranvier)
 - SALTATORY CONDUCTION

Basic Nerve Facts

- Physiology
 - Peripheral nerve transport mechanism
 - Nutrient production
 - Axoplasmic transport systems
 - Breakdown products
 - retrograde axoplasmic transport
 - Disruption of transport systems

Basic Nerve Facts

- Nerve injury
 - Two classification systems
 - Seddon
 - Neuropraxia, axonotomesis, neurotmesis
 - Based on clinical evaluation and judgment of injury
 - Preoperative assessment
 - Sunderland
 - 1st to 5th degree
 - Histology
 - Applicable after nerve exploration

Two Classification Systems of Nerve Injuries

Seddon	Sunderland	Disrupted	Prognosis
Neurapraxia	1 st degree	axon (min)	complete recovery in days/months
Axonotmesis	2 nd degree	axon (total) (wallerian degen.)	complete return in months
Neurotmesis	3 rd degree	axon, endoneurium	mild/mod. reduction in function
Neurotmesis	4 th degree	axon, endoneurium, perineurium	mod. reduction in function
Neurotmesis	5 th degree	all structures	marked reduction in functional return

Basic Nerve Facts

- Nerve repair
 - Timing
 - Functional results of primary and early secondary nerve repair similar
 - Primary best:
 - Proximal injuries
 - Identifiable nerve ends
 - Minimal contamination
 - Without associated injuries
 - Healthy patient
 - Trained surgeon
 - Delayed primary repair within 7 days

Basic Nerve Facts

- Nerve repair
 - Timing
 - Secondary repair
 - After 7 days
 - Nerve stumps approximated and tagged
 - Repair within 6 months
 - Better result than after 6 months
 - Optimal timing of repair
 - Controversial
 - Immediate
 - 3 weeks - fibrosis ideal for repair?

Basic Nerve Facts

- Nerve repair
 - Patient age
 - Younger patient
 - Better functional outcome
 - Optimal recovery in less than 20 years of age
 - Motor/sensory nerve
 - Digital nerve repairs
 - Good results up to 50 years of age
 - Condition of the wound
 - Increased intraneural damage with extensive injuries

Basic Nerve Facts

- Nerve repair
 - Level of Injury
 - More proximal injury
 - Worse functional return
 - Tension of repair
 - Elasticity of neural tissues
 - Elongation by 20%
 - After this point nerve conductivity diminishes
 - Gap size
 - Worse results with gap > 2.5 cm
 - Bridge with grafting, neurotization

Basic Nerve Facts

- Nerve repair
 - Technique
 - Alignment
 - Precise match of motor and sensory fascicles
 - No significant difference in outcome by type of repair
 - Epineurial
 - Perineurial
 - Group Fascicular

Basic Nerve Facts

- Nerve repair
 - Technique
 - Epineurial
 - Conventional technique
 - Aligned with two or three sutures
 - Advantages:
 - Short execution time
 - Technical ease
 - Minimal magnification
 - Intraneural contents undisrupted
 - Disadvantages
 - Imprecise alignment
 - Performance by poorly trained personnel

Basic Nerve Facts

- Nerve repair
 - Technique
 - Perineurial (Fascicular or Funicular)
 - Technique of choice in nerve grafting
 - Best in nerves with fewer than 5 fascicles
 - Advantages:
 - Better fascicular alignment
 - More axons entering endoneurial tubes
 - Disadvantages:
 - Longer operative time
 - Increased fibrosis at suture site
 - Vascular compromise of fasciculi
 - Trauma to nerve

Basic Nerve Facts

- Nerve repair
 - Technique
 - Group fascicular repair
 - Possible when nerve transection at level of distinct functional groupings
 - Motor-motor, sensory-sensory

Basic Nerve Facts

- Nerve repair
 - Nerve grafting
 - Recommended for gaps > 2 cm
 - Interfascicular technique
 - Best recovery if grafting performed between 6-12 months postinjury
 - Sural nerve most common donor
 - Multiple other described techniques:
 - Vascularized nerve
 - Various donors

Pathophysiology of Entrapment

- Etiologies
 - Isolated contusion
 - Repetitive compression
 - Stretch
 - Surgical injury
- Patterns of injury
 - Demyelination → neurapraxia
 - Axonal loss → axonotmesis
 - Transsection → neurotmesis

Nerve Entrapment

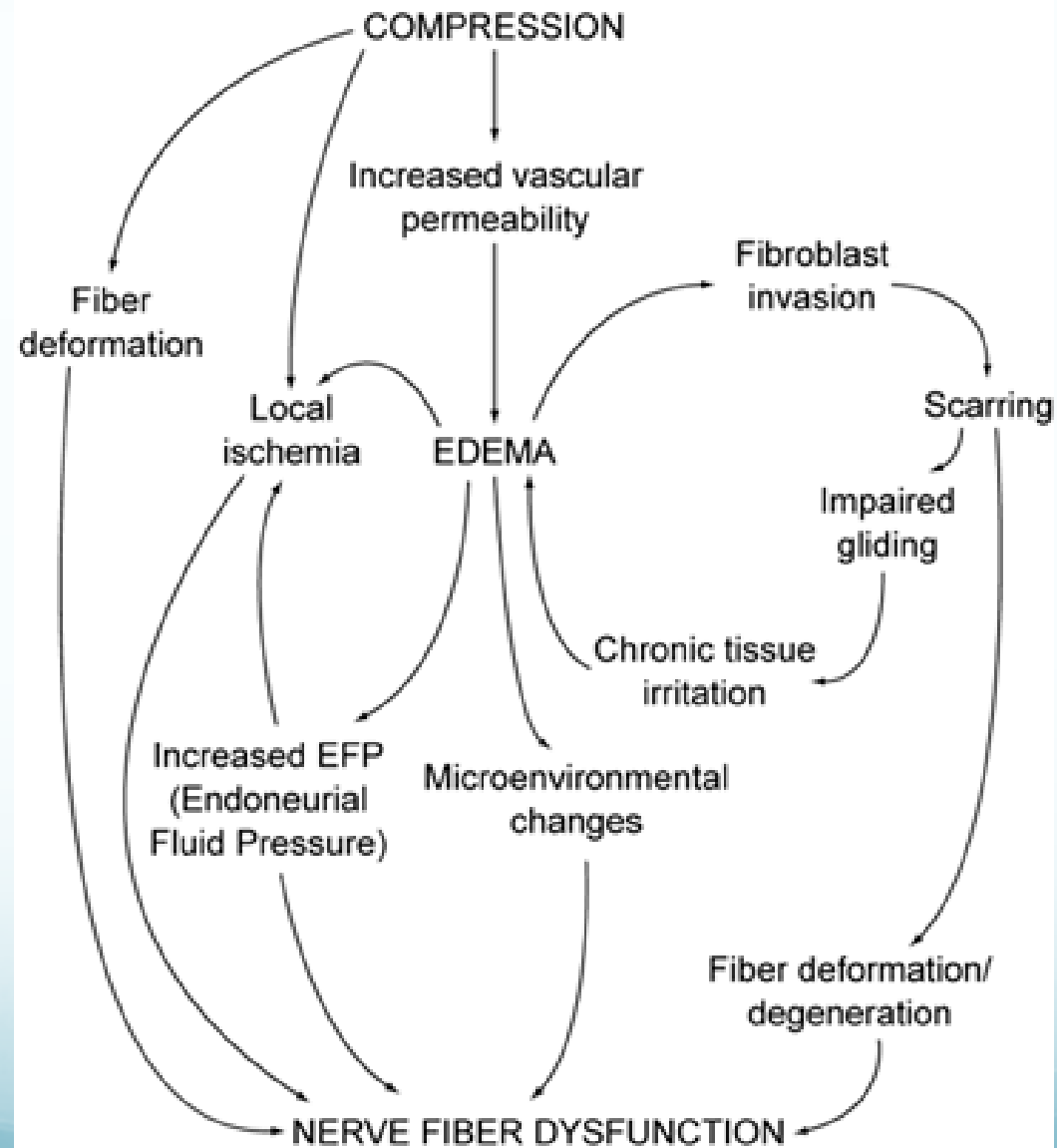
- Pathophysiology
 - Systemic conditions
 - Diabetes
 - Alcoholism
 - Hypothyroidism
 - Exposure to industrial solvents
 - Aging
 - Depression of nerve function
 - Lowers threshold for manifestation of compression neuropathy

Nerve Entrapment

- Pathophysiology
 - Ischemia/Mechanical Factors
 - Earliest manifestation
 - Reduced epineurial blood flow
 - 20-30 mmHg compression
 - Interference in venular flow
 - 40-50 mmHg
 - Impairment of arteriolar and interfascicular capillary flow
 - 60-80 mmHg
 - Complete blockage of nerve perfusion

ACUTE EFFECTS

CHRONIC EFFECTS



Nerve Entrapment

- Pathophysiology
 - Double crush phenomenon
 - Axoplasmic transport systems disrupted
 - Mechanical
 - Diabetes etc...
 - “A nerve with a conduction disorder at one level is more vulnerable to a conduction disorder at a second level”

Radiculopathy

- Usually related to disc herniation in the athlete
- Congenital or acquired spinal stenosis must be considered
- Scapular or interscapular pain must raise your index of suspicion in the neck, buttock, or hip pain in the low back.

Radiculopathy

- MRI most useful imaging choice
- Beware of MRI abnormalities that don't correlate clinically (treat the patient, not the MRI)
- Most younger (<35) will do well with a trial of conservative management (time, meds, rehab/modalities)
- Symptomatic disc herniation is a contraindication to participation in contact sports
- Recommendations less clear on asymptomatic disc herniations (not just mild bulging)

Radiculopathy

Etiology

- Compressive
 - Central spinal canal stenosis
 - Neuro-foraminal stenosis
- Non-compressive
 - Toxic/Metabolic
 - Auto-immune
 - Ischemic
 - Infectious

Radiculopathy

Compressive

- Degenerative
 - Disk herniation
 - Facet joint hypertrophy
 - Ligamentum flavum hypertrophy
 - Post-surgical fibrosis
- Tumors
 - Epidural
 - Intradural
 - Leptomeningeal disease
 - Intramedullary
- Subdural bleed
- Infection
 - Epidural abscess

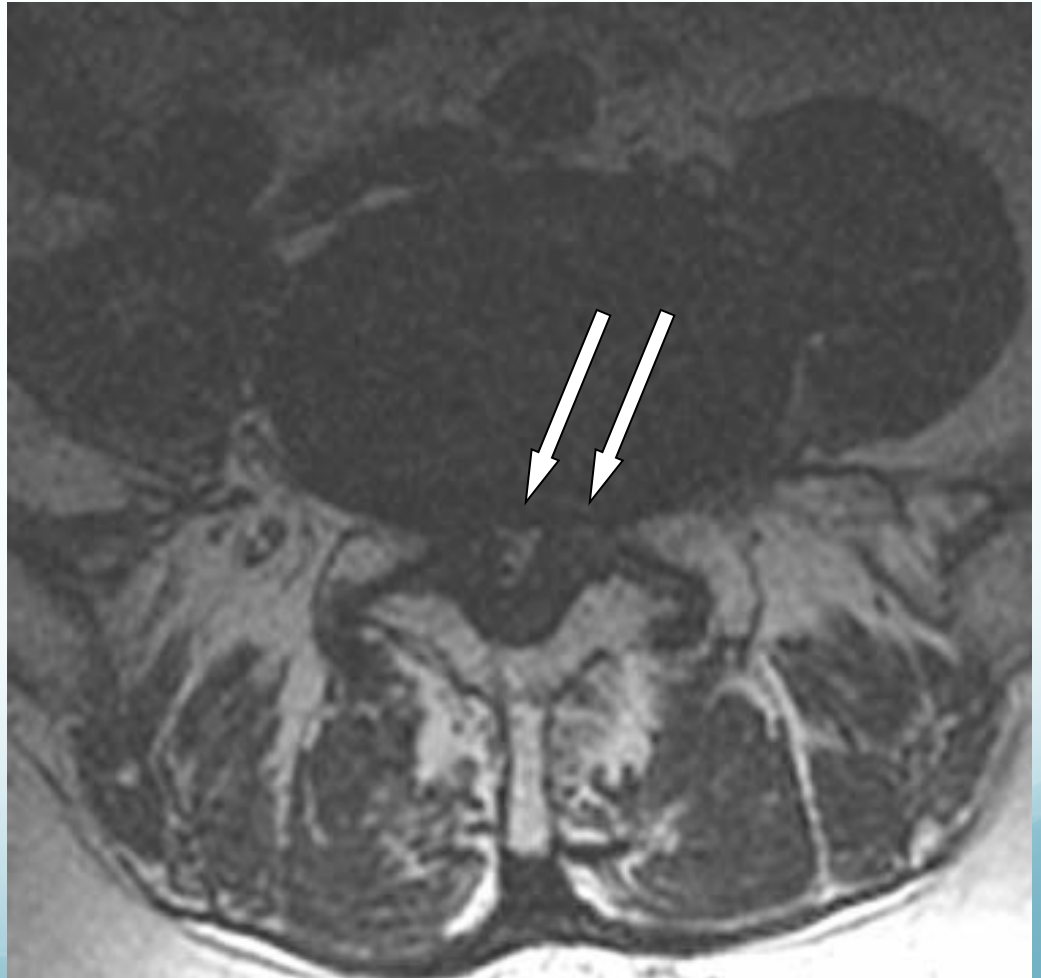
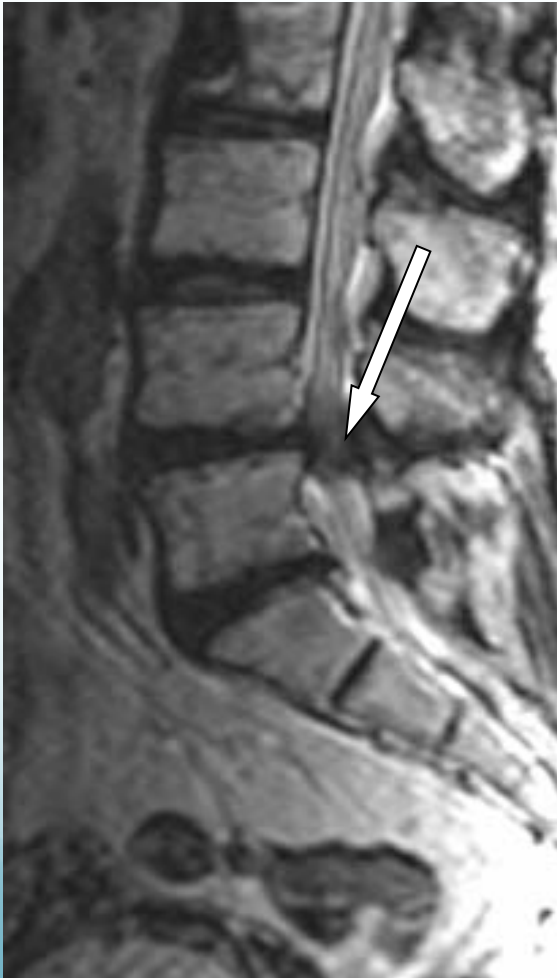Radiculopathy

Non-compressive

- Toxic/Metabolic
 - Diabetes
 - Diabetic amyotrophy
 - Arachnoiditis
 - Contrast agents
 - Bloody spinal tap
 - Anesthetics & Corticosteroids
 - Spinal Surgery
 - Chemotherapy
- Auto-immune
 - Guillain-Barré Syndrome
 - AIDP
 - AMAN/AMSAN
 - CIDP
- Infectious
 - *Mycobacterium tuberculosis*
 - *Cryptococcus neoformans*
 - Lyme disease
 - Syphilis
 - HIV
- Ischemic
 - Leptomenigeal Disease
 - Sarcoidosis

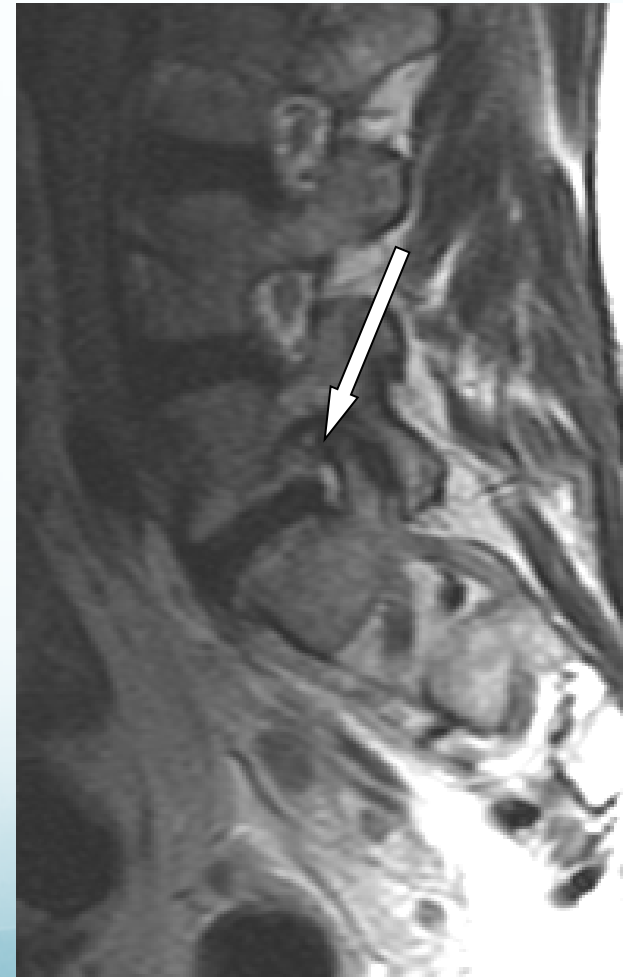
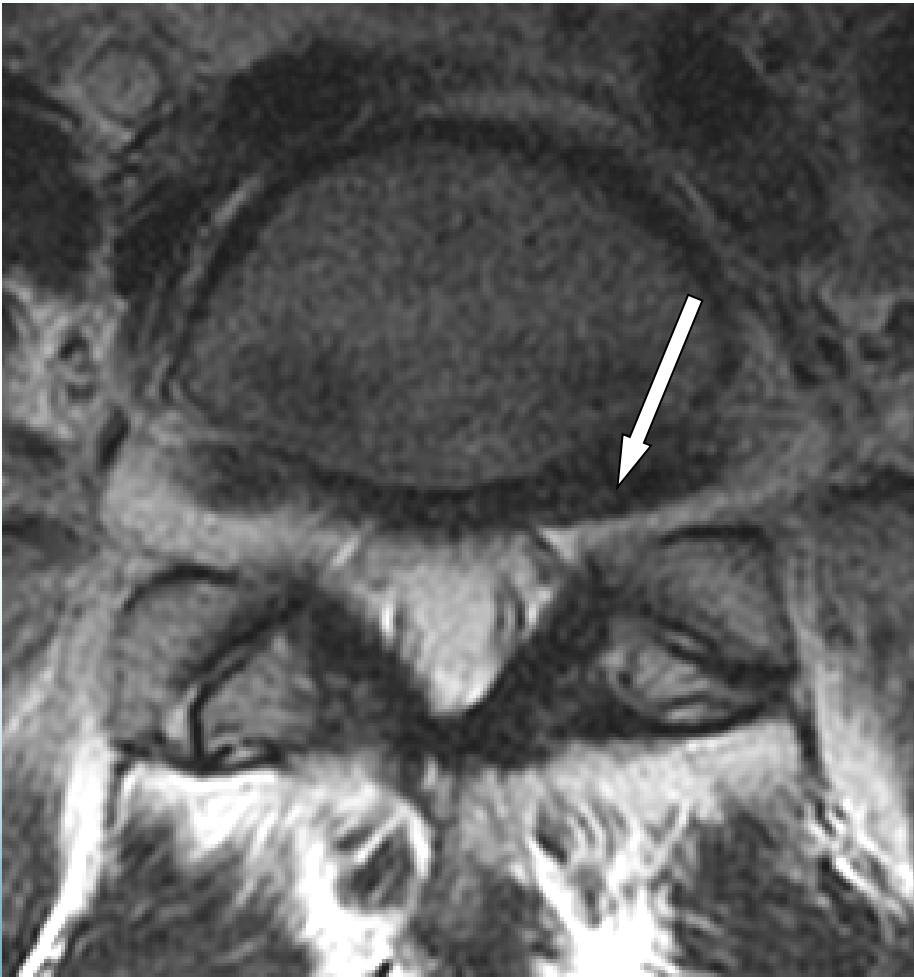Radiculopathy

Central Canal & Neuro-foraminal Stenosis
from Degenerative Changes



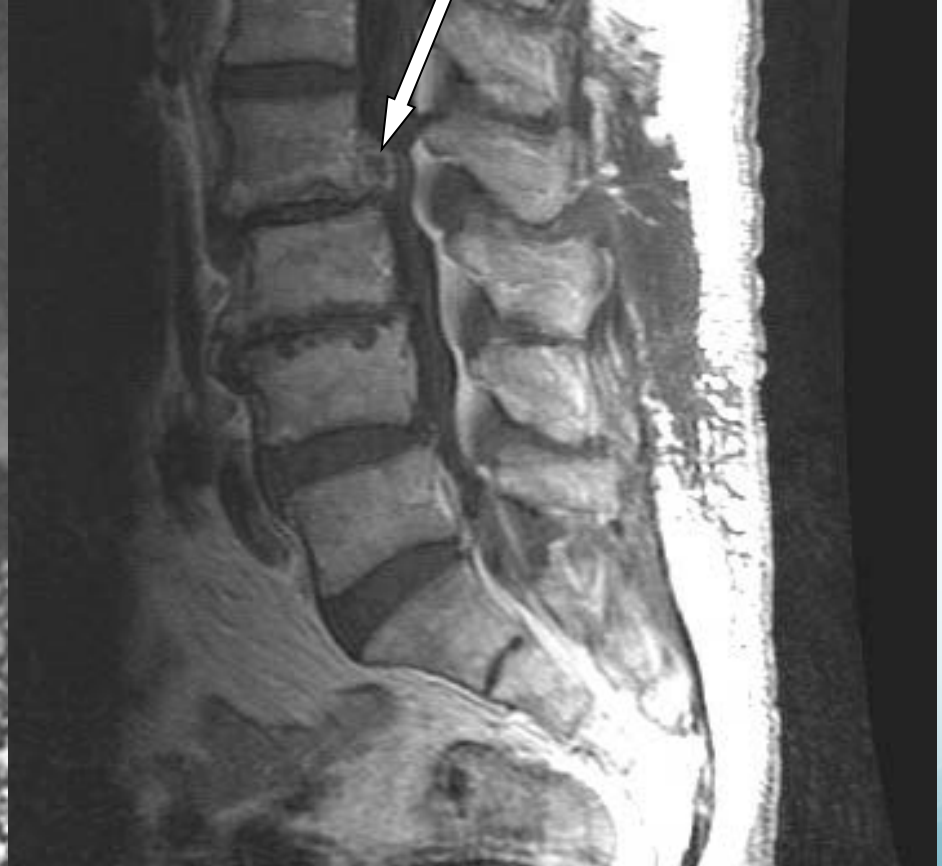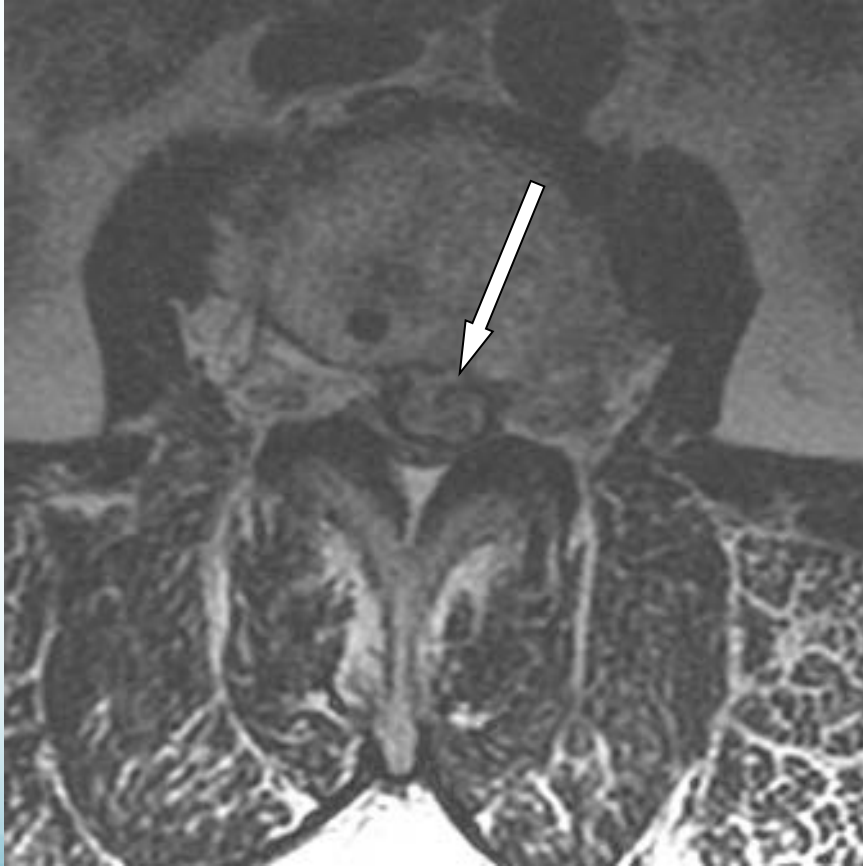
Radiculopathy

Neuro-foraminal Stenosis from L-5 Disc Herniation



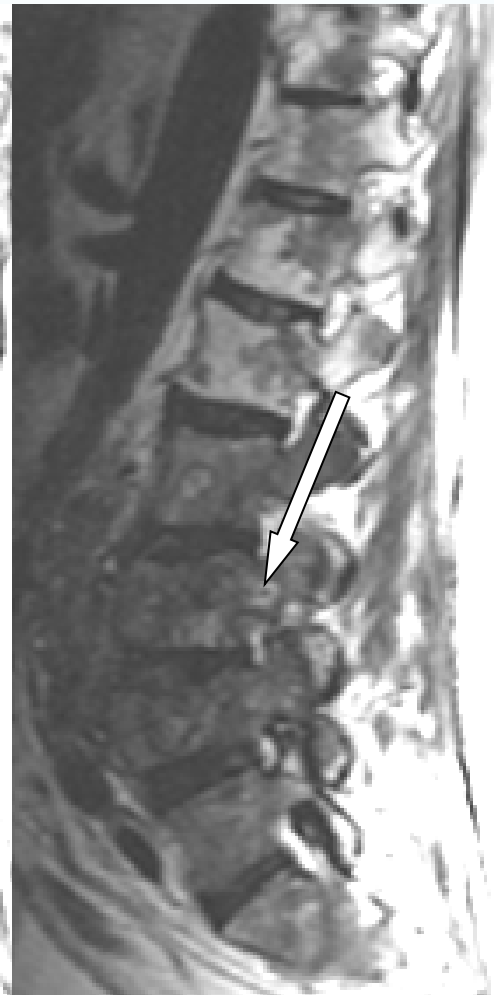
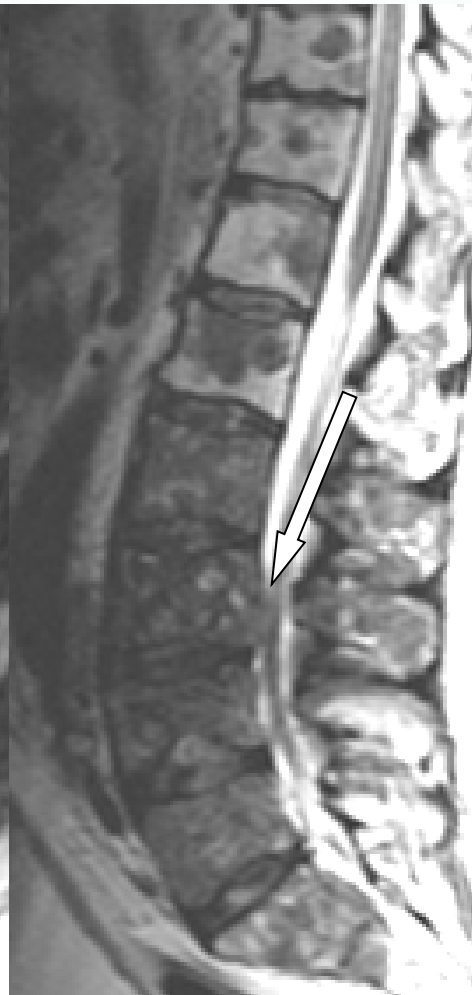
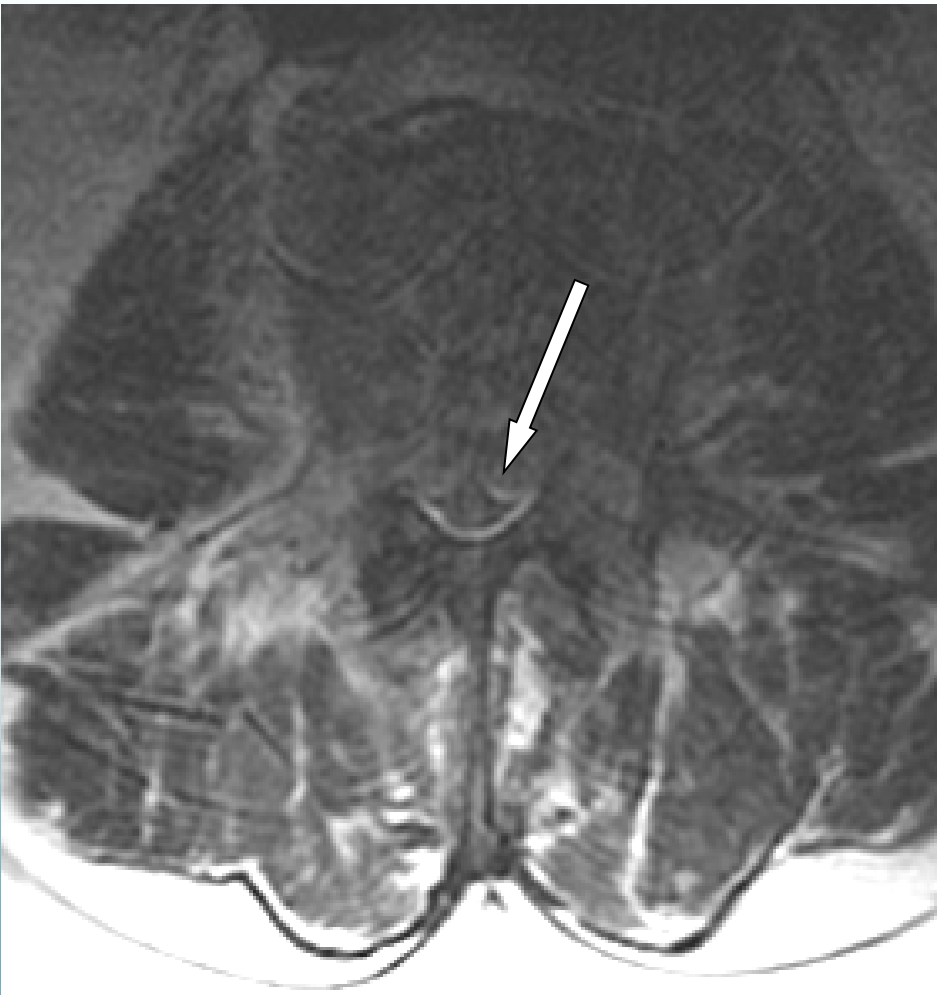Radiculopathy

Sequestered Disk Fragment



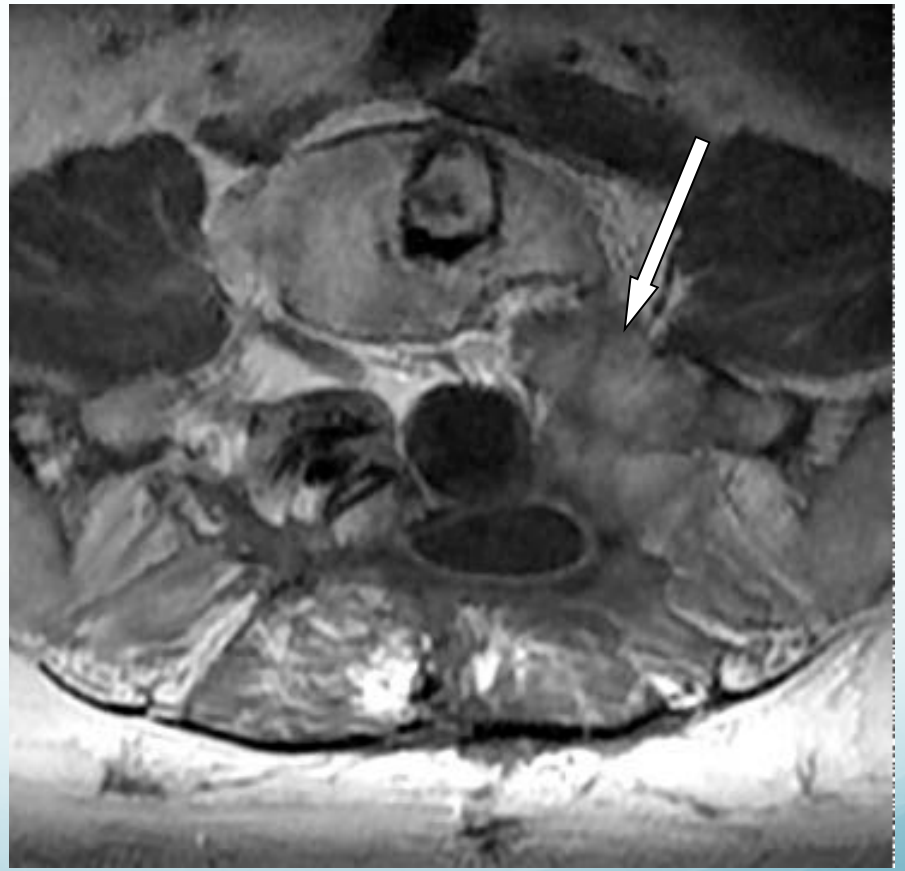
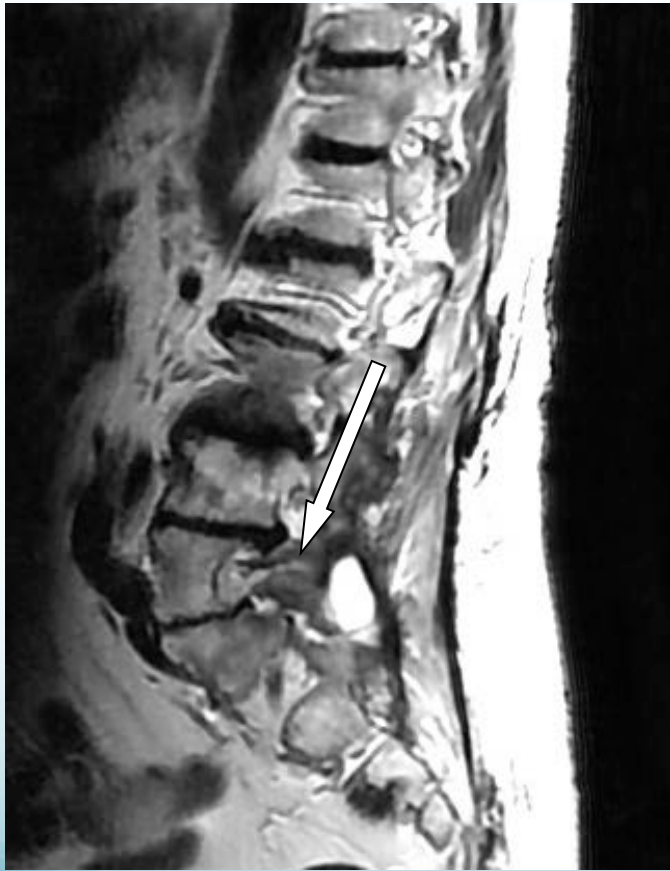Radiculopathy

Epidural Disease with Cauda Equina &
L-3 Nerve Root Compression From Prostate Cancer



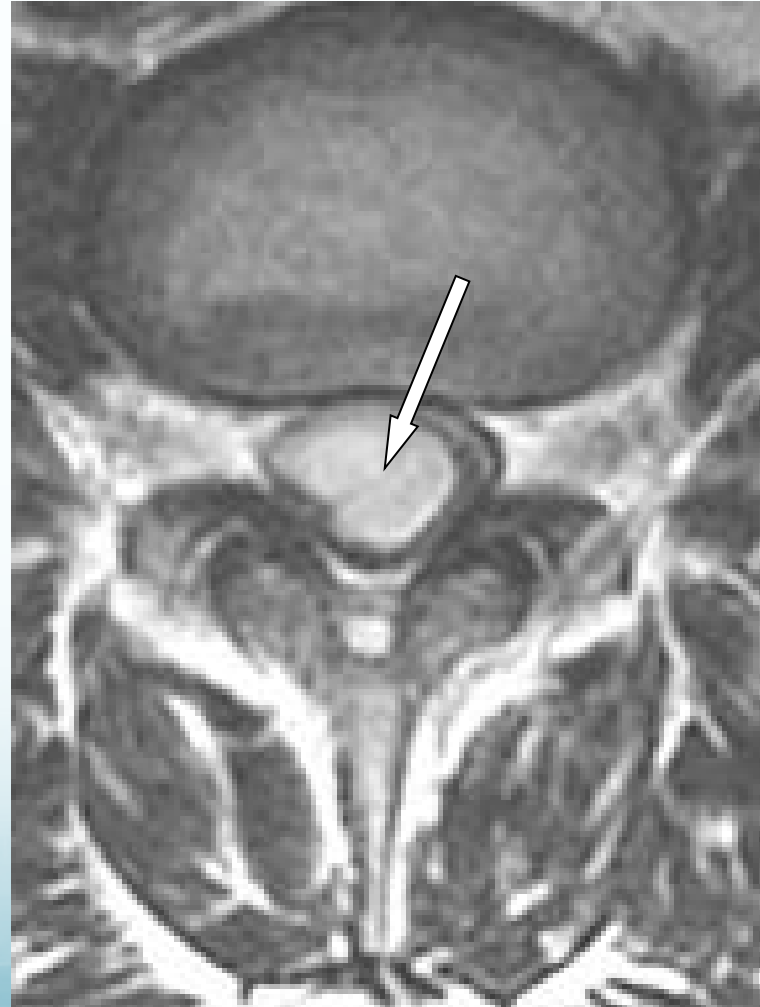
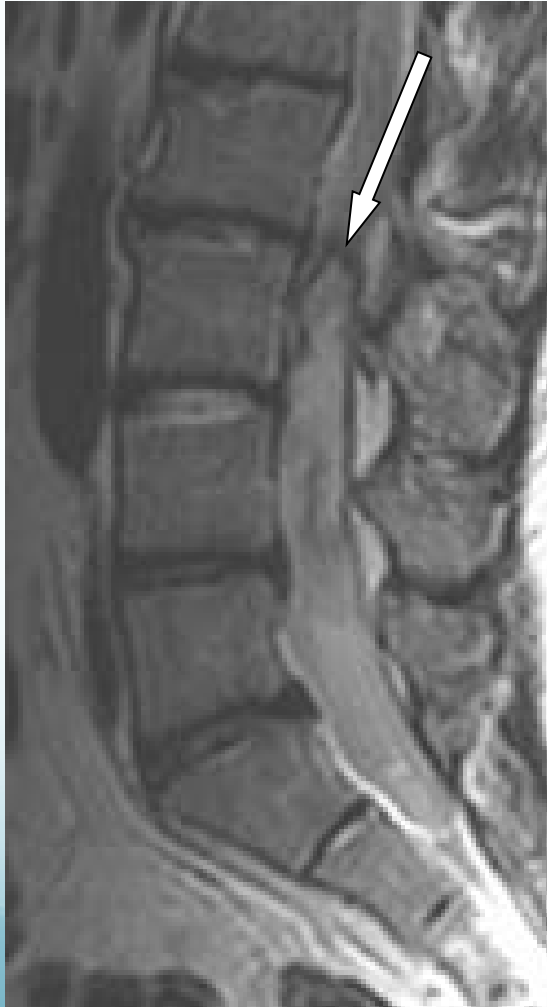Radiculopathy

Recurrent Schwannoma with L-5 Compression



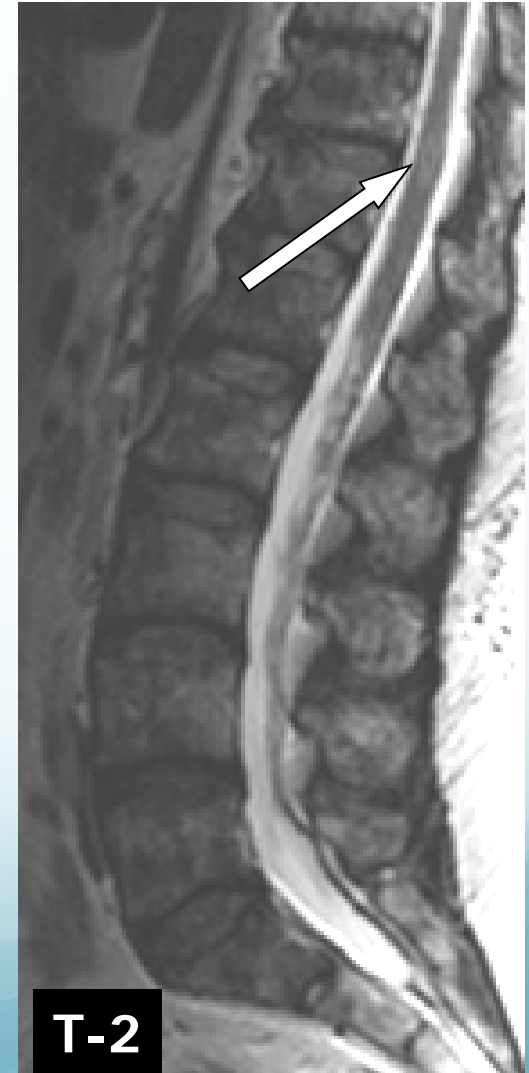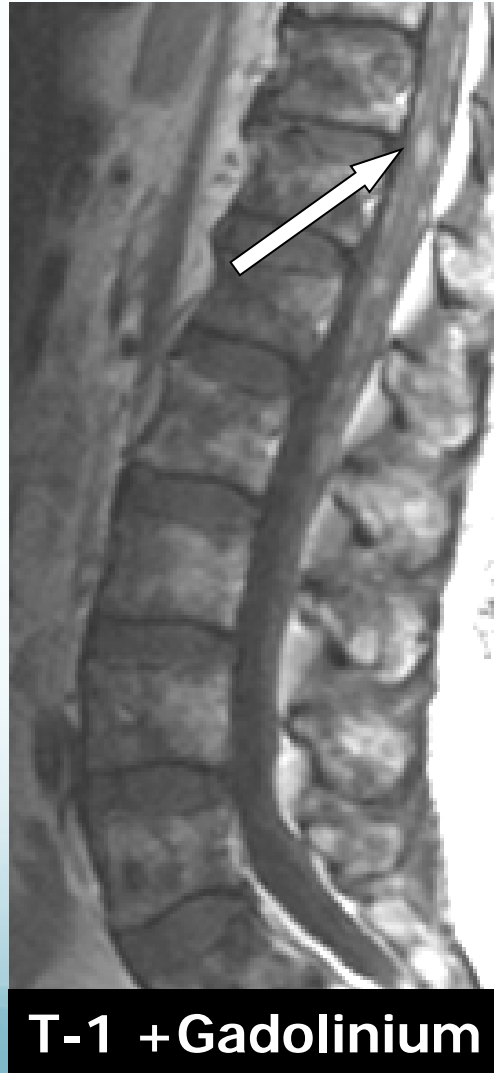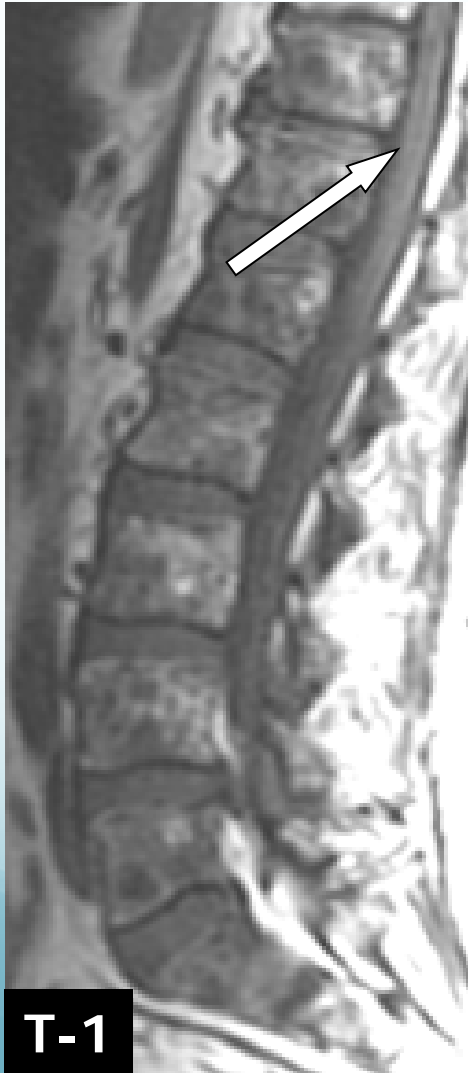Radiculopathy

Subdural Hemorrhage from a Lumbar Puncture



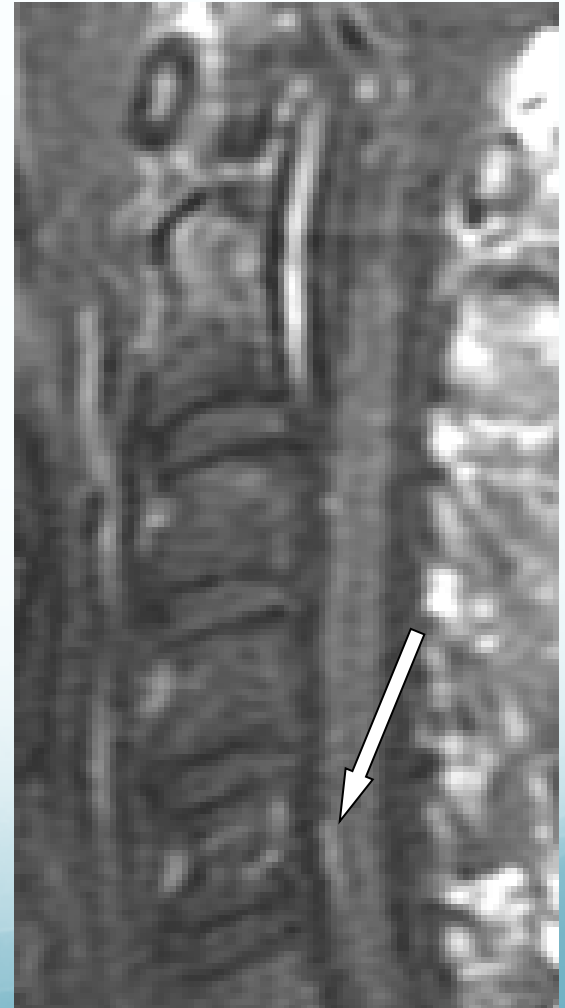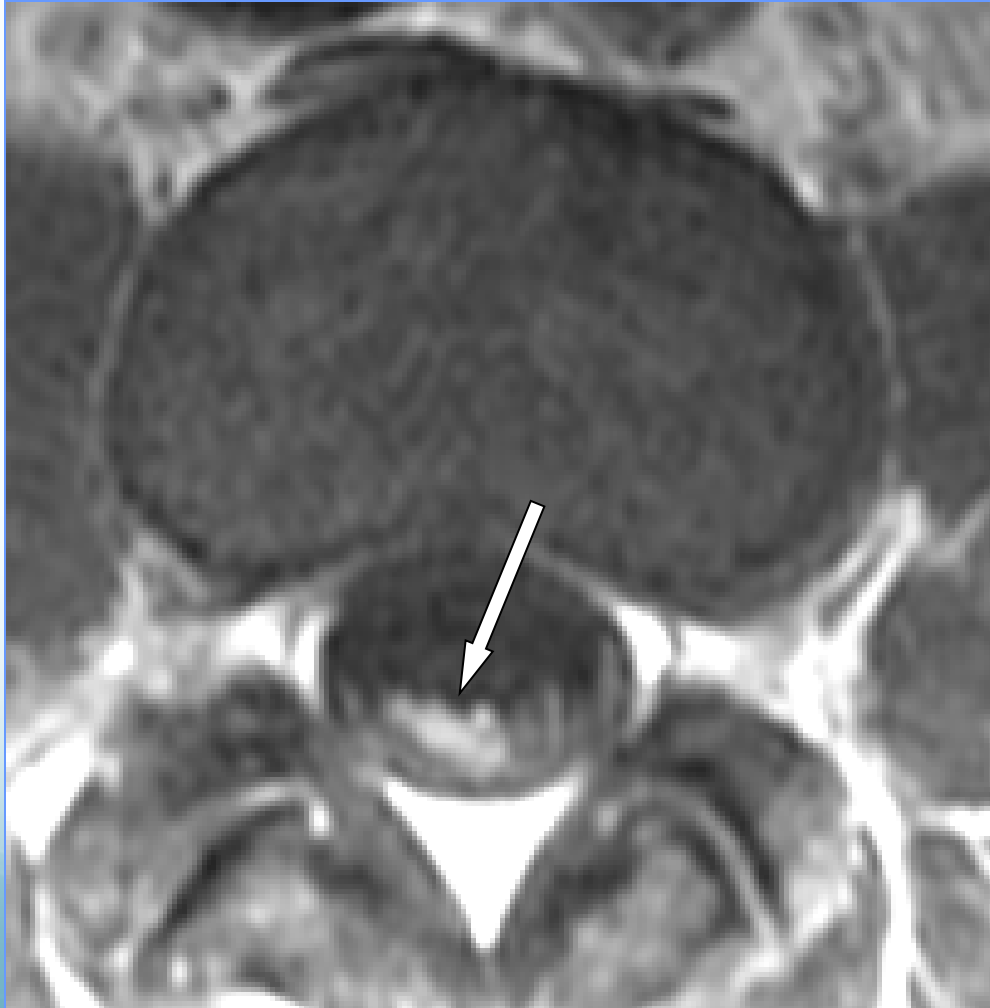Radiculopathy

Leptomeningeal disease in metastatic breast cancer



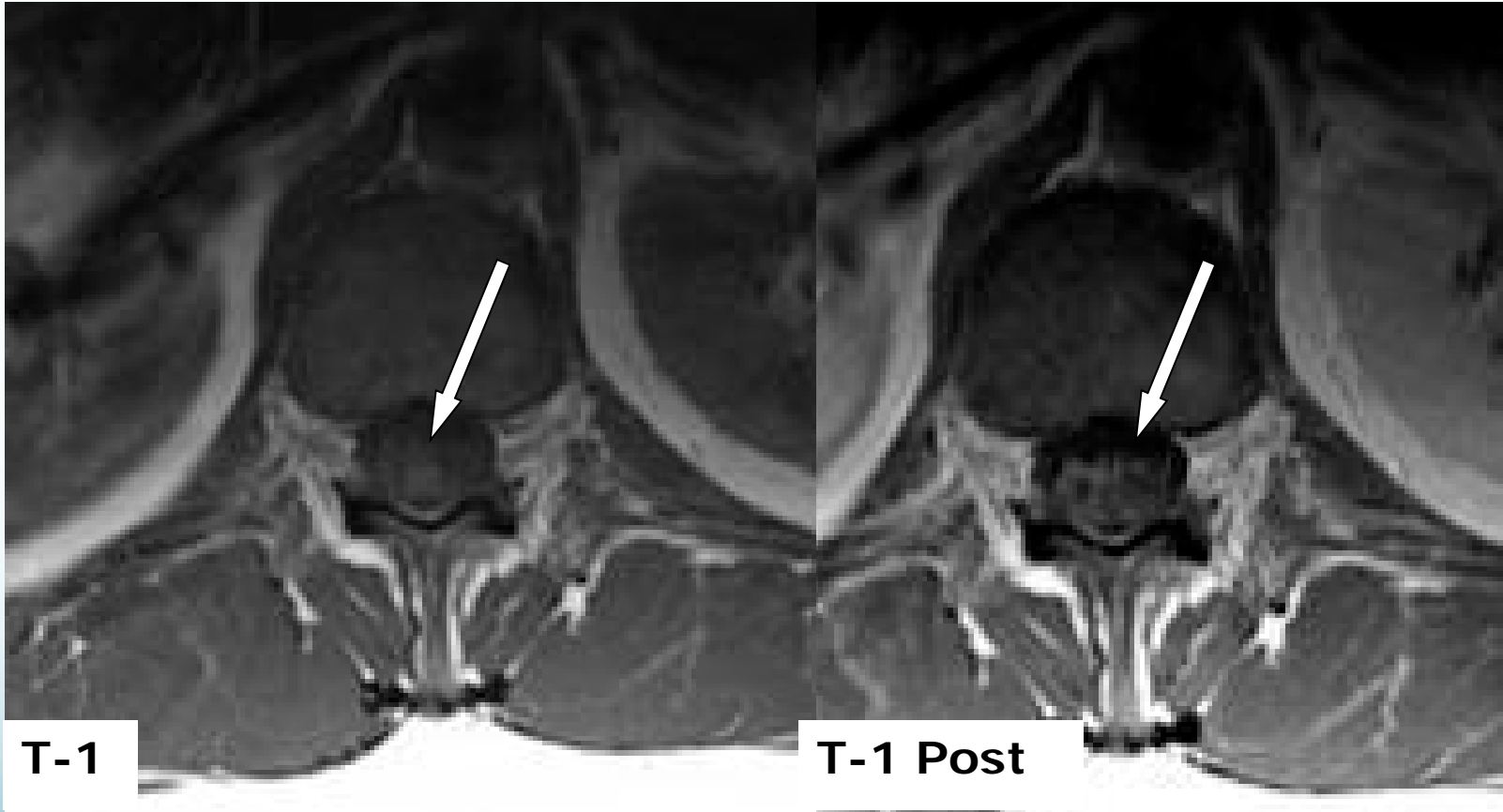
Radiculopathy

Sarcoidosis



Radiculopathy

CIDP



Nerve Entrapment in the Upper Extremity

- Thoracic Outlet Syndrome
- Scapular Winging
 - Long Thoracic Nerve
 - Dorsal Scapular
- Suprascapular Nerve
- Axillary Nerve
- Musculocutaneous
- Radial Tunnel
 - Posterior Interosseus n.
 - Supinator
- Ulnar neuropathy
 - Wrist
 - Elbow (Cubital tunnel synd.)
- Carpal tunnel syndrome
 - Pronator syndrome
 - Anterior Interosseus n.

Thoracic Outlet Syndrome

- Usually overhead athletes
- Compression usually of brachial plexus, subclavian artery or vein
- Pain, paresthesias, early fatigue, weakness, swelling or discoloration
- Compression often at one of three levels
 - Interscalene triangle
 - Costoclavicular space
 - Pectoralis minor insertion on coracoid process

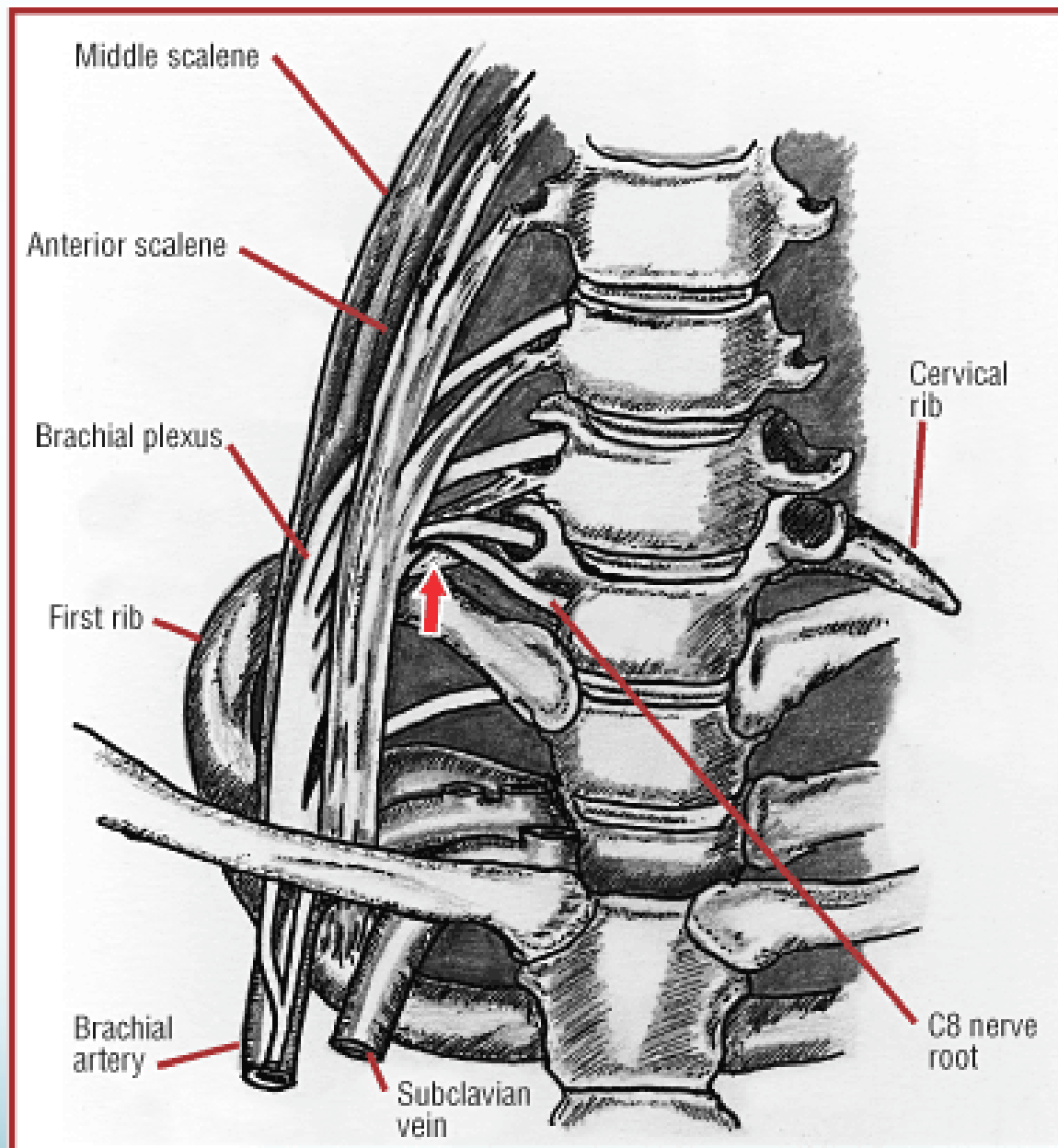


FIGURE 7. Anterior view of the upper chest and neck shows thoracic outlet syndrome caused by an aberrant cervical rib. Note the stretching of the C8 nerve root (arrow) over the cervical rib.

TOS Physical Exam Testing

- Adson's- neck extended and rotated to affected side while deeply inspiring and holding the breath
- Wright's- head turned toward unaffected side and affected arm abducted and externally rotated while taking a deep breath
- Roos'- Shoulder abducted above the head, externally rotated and repetitive gripping with both hands for 30-60 seconds
- Tests considered positive if they reproduce symptoms and/or a decrease in upper extremity pulses is detected with Adson's or Wright's

TOS Diagnostic Testing

- Plain films may reveal a cervical rib or exuberant callus from a clavicle/upper rib fx
- MRI and MRA can reveal brachial plexus anatomy, subclavian vein anatomy or vascular occlusion/compression
- MRA with the arm in abduction can demonstrate subclavian vein obstruction in baseball pitchers

TOS Treatment

- Nonoperative treatment focuses on rest, stretching of the nearby soft tissue structures and posture mechanics; gradual improvement
- Surgical treatments
 - Rib resection
 - Brachial plexus neurolysis and sympathectomy
 - Effort thrombosis also treated with clot lysis with urokinase or heparin

Scapular Winging Evaluation

Nerve Muscle	Long Thoracic Serratus Anterior	Spinal Accessory Trapezius	Dorsal Scapular Rhomboids
Scapula at rest	Winging Medial translocation Inferior angle medially rotated Apparent shoulder droop	Less winging Lateral translocation Inferior angle medially rotated True shoulder droop, prominent levator	Inferior angle winging Lateral translocation Inferior angle laterally rotated
Accentuated Decreased	Forward flexion Abduction	Abduction Forward flexion to 90 ⁰	Overhead elevation

Long Thoracic Nerve

- Less commonly entrapped
- Trauma
 - Iatrogenic
 - Surgical procedures
 - Chiropractic (Muscle and Nerve, 1995)
 - Direct
 - Acceleration/Deceleration
 - Football
 - Wrestling



Long Thoracic Nerve Palsy

- **Caveat-** most with mild scapular winging do not have LTN palsy
- Seen primarily in throwers and wt. lifters
- LTN innervates the serratus anterior
- Stretching or traction of the nerve usually with ipsilateral arm overhead and neck turned to contralateral side

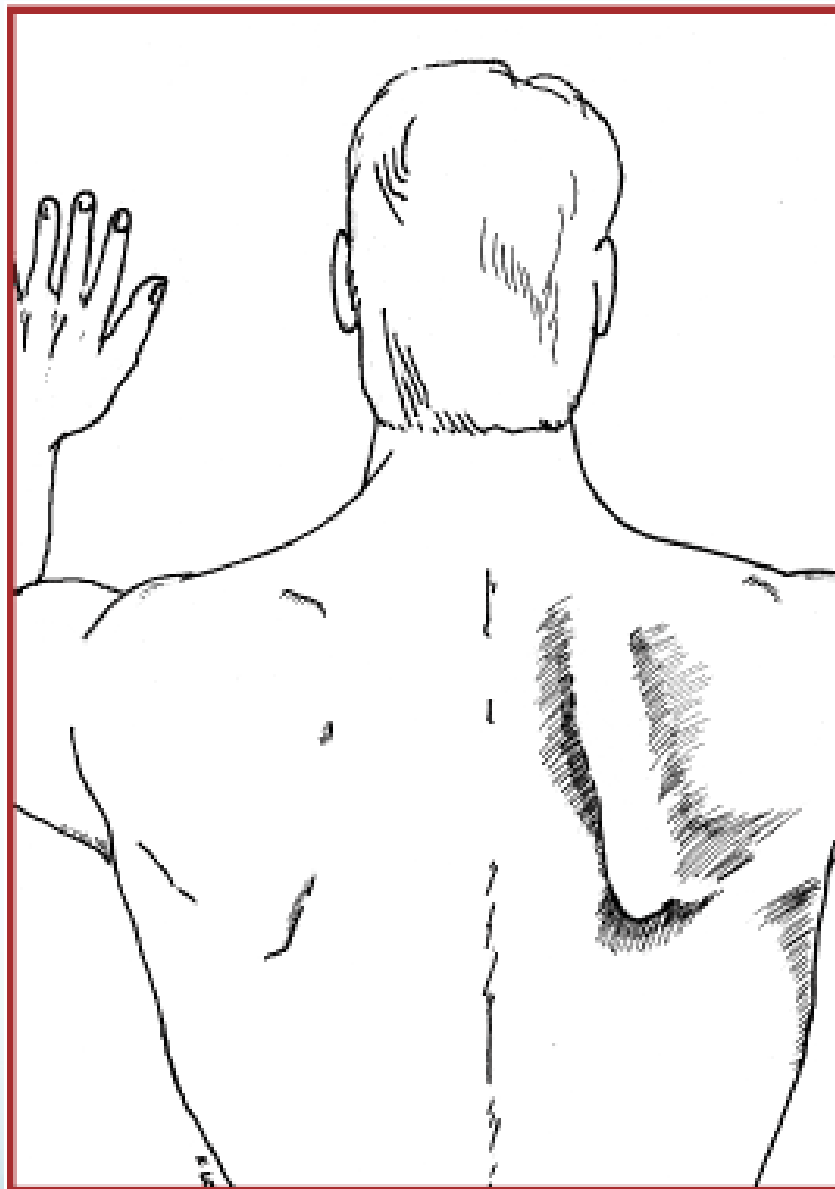


FIGURE 6. Scapular winging caused by long thoracic nerve injury. Scapular abduction, such as pushing against a wall, accentuates the protuberance of the medial scapular edge.

LTN Evaluation

- Symptoms- rotator cuff/impingement-like, shoulder girdle fatigue, difficulty with overhead activities
- “Wall-pushups” usually reveal the winging
- Rest from offending activity, particularly overhead activities
- Non-offending rehab
- Many resolve in 18-24 months
- Tendon or nerve transfers in nonresponders

Dorsal Scapular Nerve

- Proximal branch off brachial plexus
- Innervates rhomboids, a “pure” C5 muscle
- Weightlifting
 - Muscle and Nerve, 1995
- Dislocations
- Scalene medius muscle entrapment
 - Kopell, 1963

Suprascapular Neuropathy

- Throwers, other overhead athletes and weight-lifters
- Arises from superior trunk of brachial plexus
- Innervates supraspinatus and infraspinatus
- Compression most commonly suprascapular or spinoglenoid notch

Suprascapular Nerve Injury

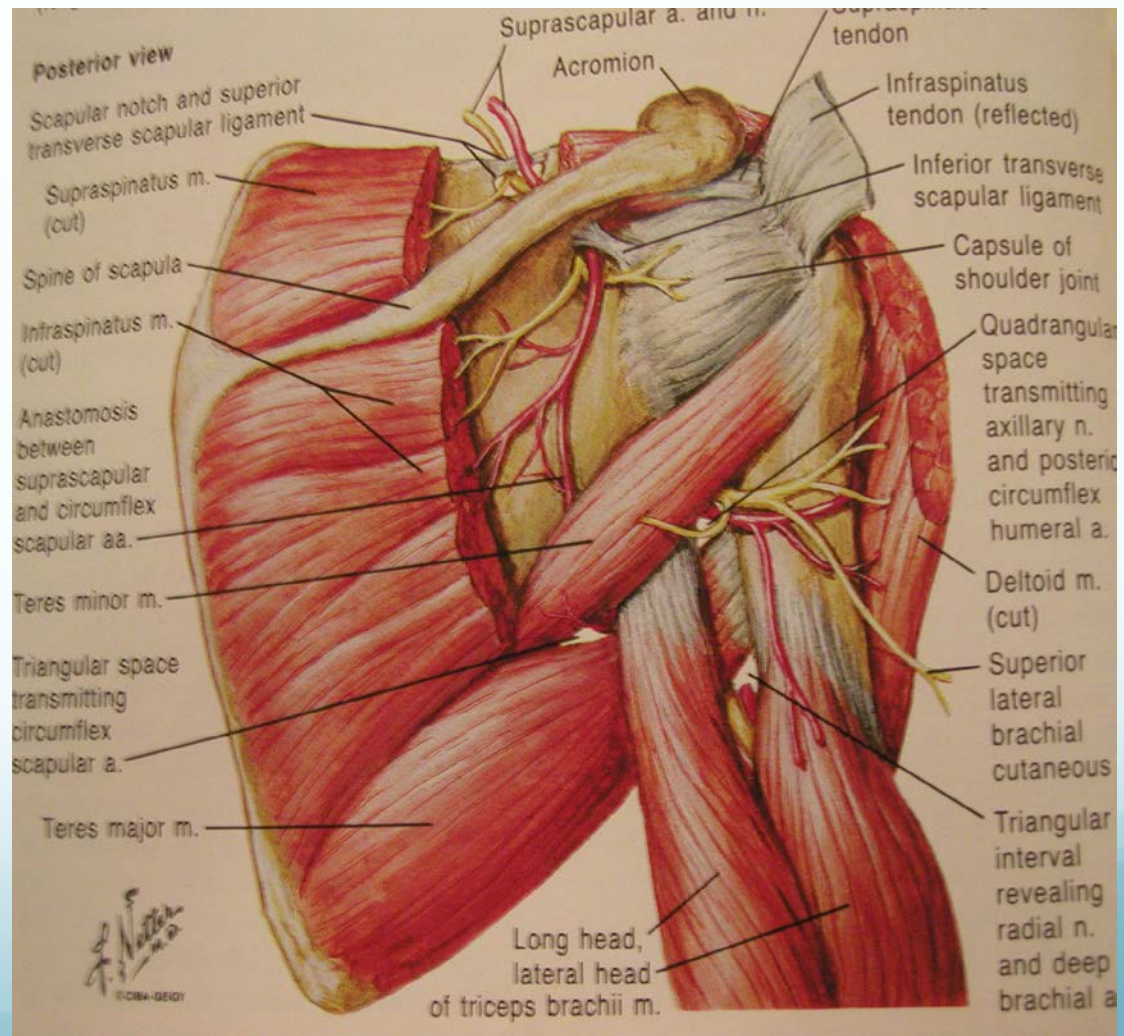


- Volleyball
 - 8% of all nerve injuries in athletes (Krivickas and Wilbourn, 1998)
- Throwers
- Weightlifters
- Swimmers

Suprascapular Nerve

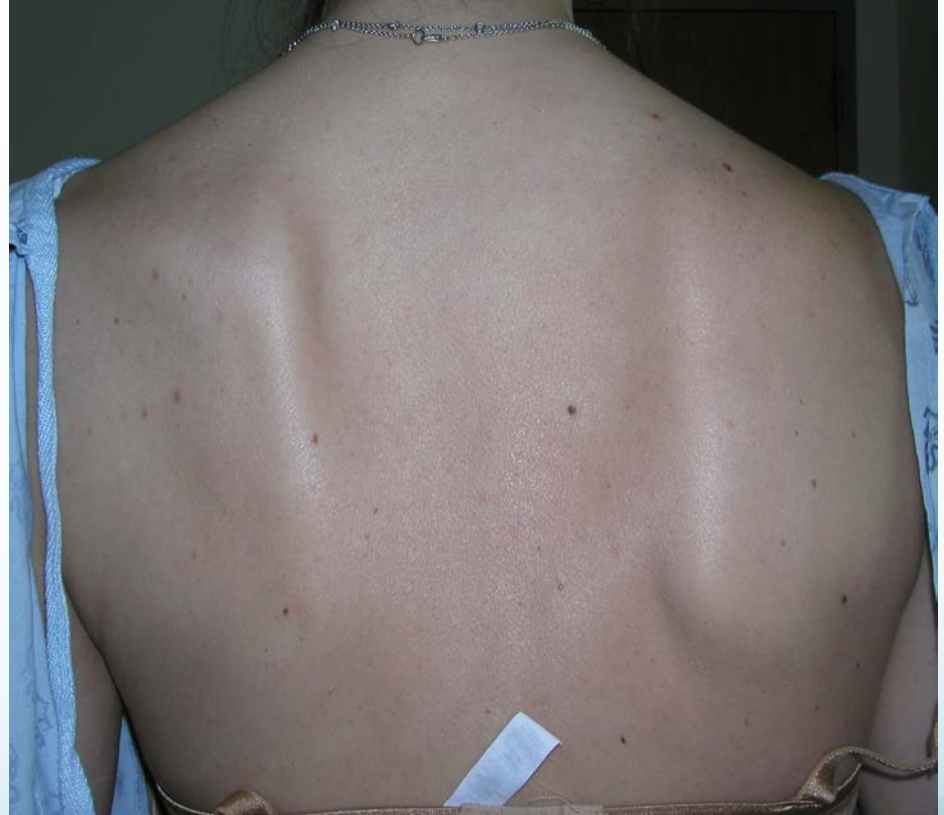Entrapment sites

- suprascapular notch
 - Superior transverse scapular ligament
- spinoglenoid notch
 - Inferior transverse scapular ligament
 - Spinoglenoid ligament



Suprascapular Nerve

- Atrophy in suprascapular & infrascapular fossa or only infrascapular fossa
- Shoulder pain (but not always)
- Impingement from secondary cuff weakness
- Weakness in shoulder (maybe silent), negative lidocaine challenge test
- Can simulate a rotator cuff tear
- Cutaneous sensory changes unusual



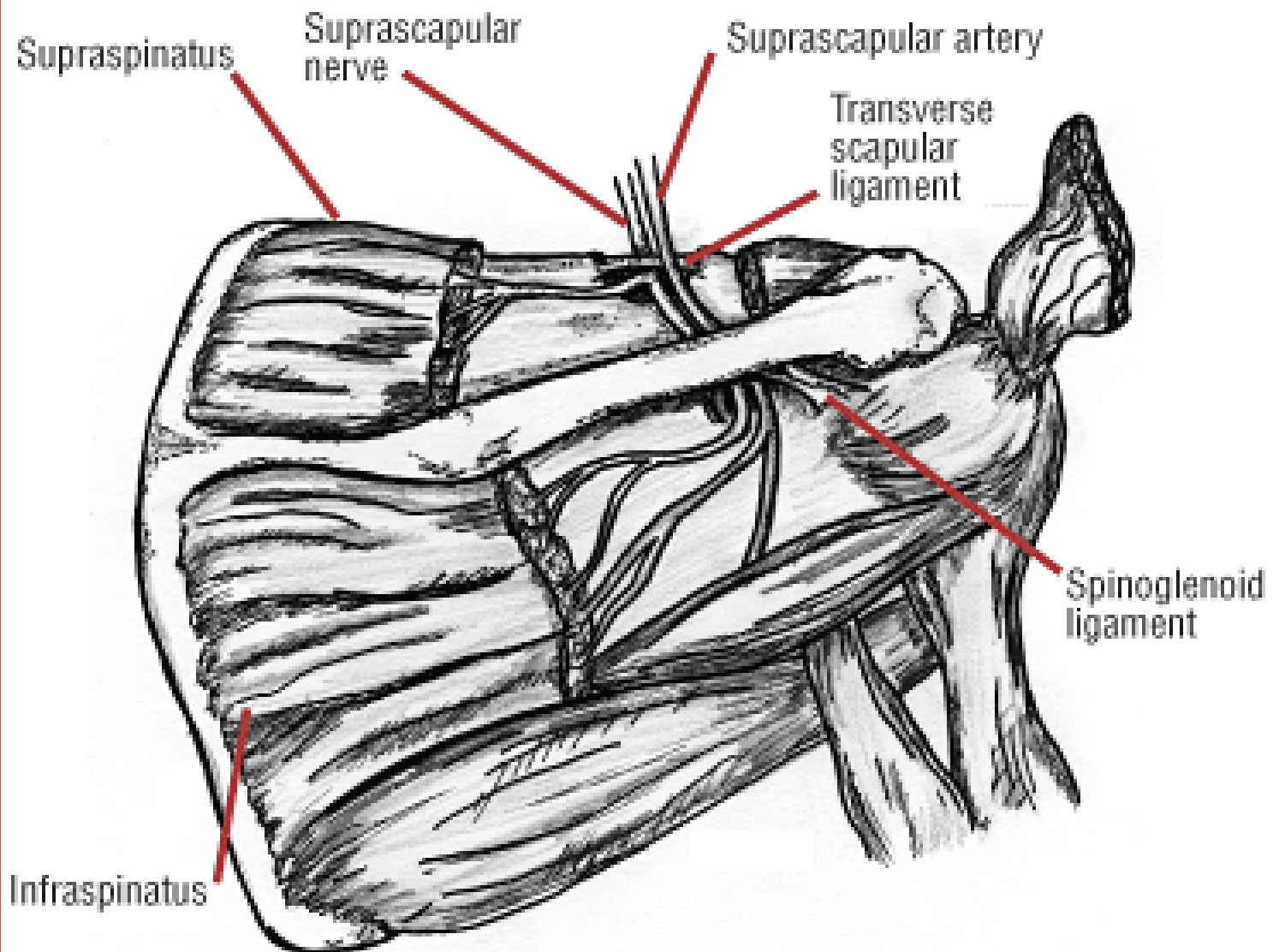


FIGURE 4. The suprascapular nerve enters the suprascapular notch to innervate the supraspinatus muscle, then courses through the spinoglenoid notch to innervate the infraspinatus muscle.

Etiologies of Suprascapular Neuropathy

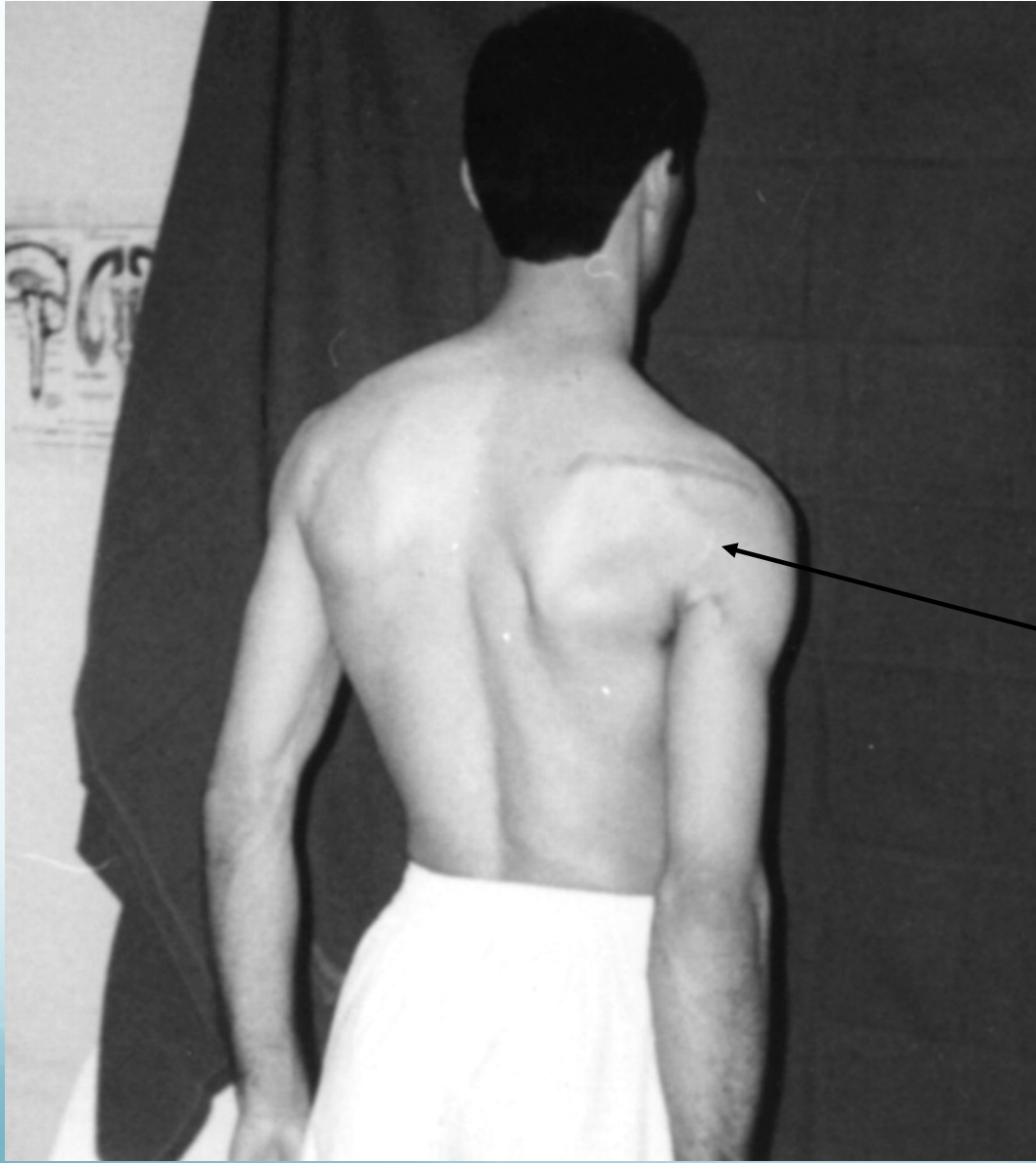- Notch narrowing
- Ganglion cyst from intraarticular defect
 - Often indicative of a labral (SLAP) tear
- Nerve kinking or traction from excessive infraspinatus motion
- Superior or inferior (spinoglenoid) transverse scapular ligament hypertrophy causing compression

Etiologies

- Dislocation
- Repetitive overhead use / microinstability
Relative fixed nerve position
- Direct Trauma
- Fracture
Direct trauma vs. callous formation
- Glenoid cyst
Labral tear
Preferential involvement of infraspinatus
- Neuralgic amyotrophy

Diagnosis of Suprascapular Neuropathy

- Vague posterior shoulder pain, weakness and fatigability
 - Weakness/atrophy without pain often suggests compression at spinoglenoid notch (nerve purely motor beyond this)
- Symptoms may mimic rotator cuff pathology or instability
- Exam reveals rotator cuff weakness and possibly supra- and/or infraspinatus atrophy



Infraspinatus Atrophy

Diagnosis of Suprascapular Neuropathy

- MRI may exclude rotator cuff tears, demonstrate atrophy and/or reveal a ganglion cyst or space-occupying lesion
- MR Neurography
- Electrodiagnostic studies
 - Neuralgic amyotrophy
 - Radiculopathy
 - Plexopathy
 - Determine which branches involved

Suprascapular Neuropathy Treatment

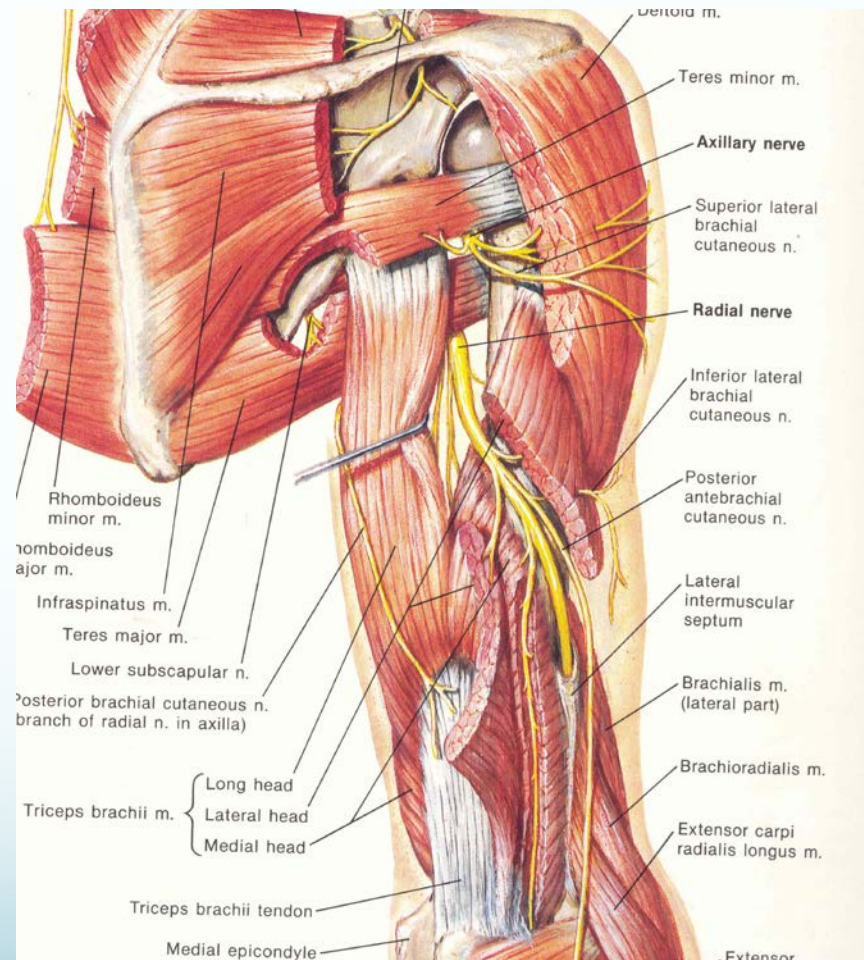
- Treatment
 - Depends on etiology: cyst → surgery
 - microinstability → address scapular mechanics
- Typically begin with nonoperative mgmt.
- Rest and/or rehab., depending on the suspected etiology
- Rest from repetitive hyperabduction
- NSAIDs and corticosteroid injections considered

Suprascapular Neuropathy Treatment

- Symptoms often resolve, allowing full return to athletics, but atrophy may persist
- Nonresponders may benefit from a spinoglenoid notchplasty, transverse scapular ligament release, nerve decompression or surgical exploration


Axillary Nerve

- Shoulder dislocation
- Humeral neck fracture
- Direct trauma
 - Football
 - Hockey
 - Volleyball
- Fibrous bands in quadrilateral space




Diagnosis

- Physical exam
 - Deltoid atrophy
 - Weak abduction
 - Weak external rotation (teres minor)
 - Cutaneous innervation may be spared
 - Dumitru, 2002
- Electrodiagnostic tests



Musculocutaneous Nerve

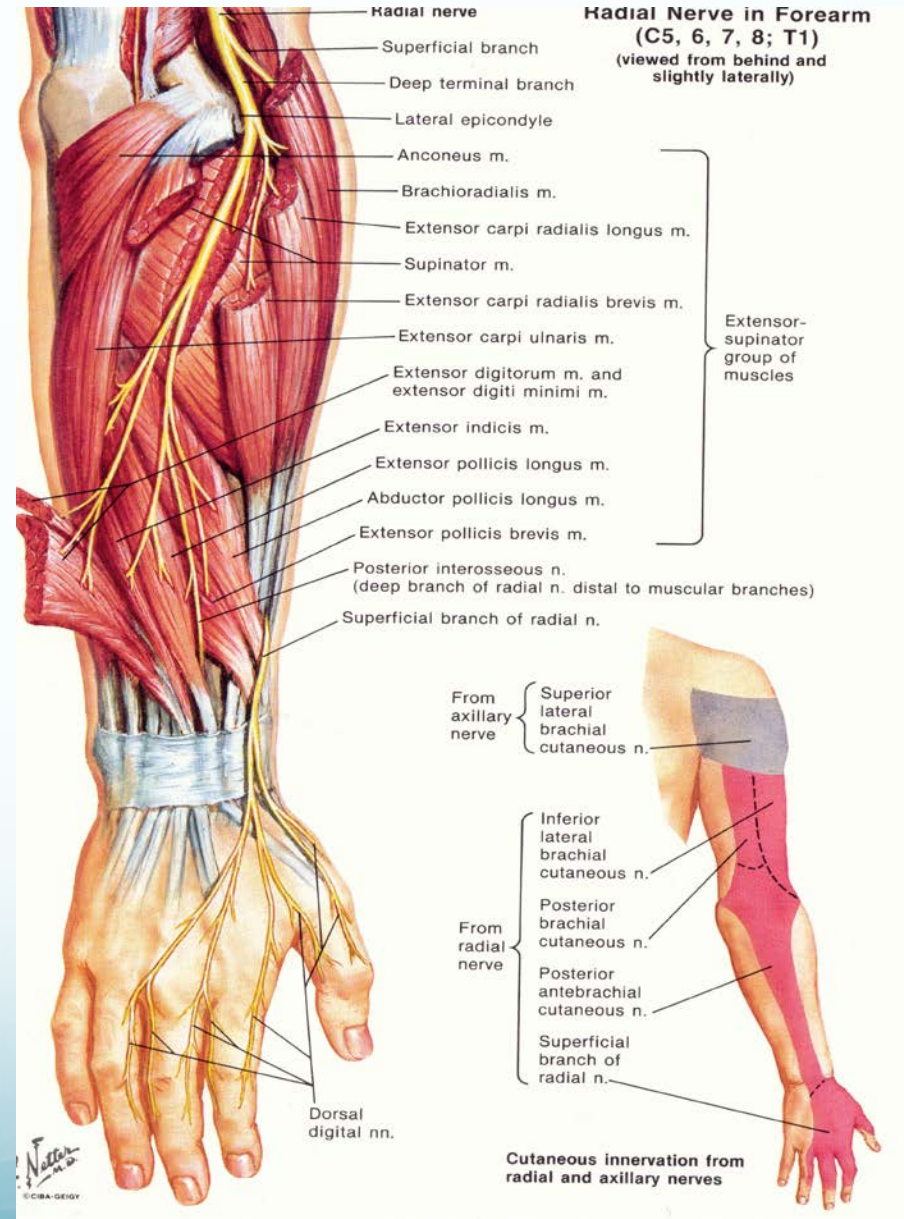
Thoracodorsal Nerve



- Rarely injured in isolation
- Anterior shoulder dislocation
 - Also axillary nerve
- Reported in weightlifting
 - Braddom, 1978
 - Simonetti, 1999
 - Mondelli, 1998

Radial Nerve

- Proximal injury
 - Trauma
 - Fracture
 - Crutch palsy
- Monteggia fracture
 - Proximal ulna fracture with radial head dislocation
 - Tardy radial palsy



Radial Tunnel Syndrome

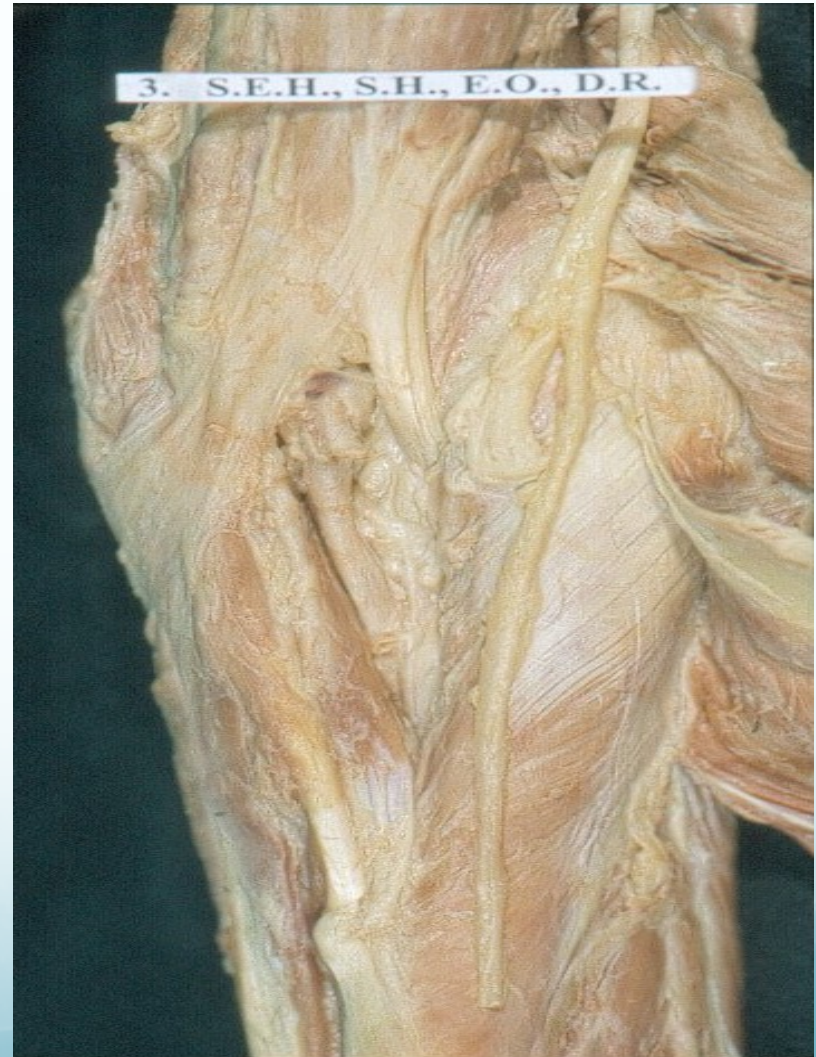- Controversial
- Distinguish from lateral epicondylitis
- Radial tunnel from lateral intermuscular septum to capitulum to supinator muscle
- Multiple potential sites of entrapment
 - Fibrous band at radius connecting biceps → brachioradialis
 - Vascular “leash of Henry”
 - Tendinous edge of ECRB
 - Arcade of Frohse
 - Variety of fibrous bands in supinator

Radial Tunnel Syndrome Hand Clinics, 1996

	Radial Tunnel	Lateral Epicondylitis
Max pain	mobile wad or can't localize	lateral epicondyle
Character	dull, aching	sharp
Reproduction	active extension supination greater	passive flexion
Tenderness	mobile wad	lateral epicondyle
3 rd extension	++	+
Supination	++	+/-
Passive flexion	+/-	++
EMG	-	-
Injection LE	-	+
Injection RT	+	-

Radial Tunnel Syndrome

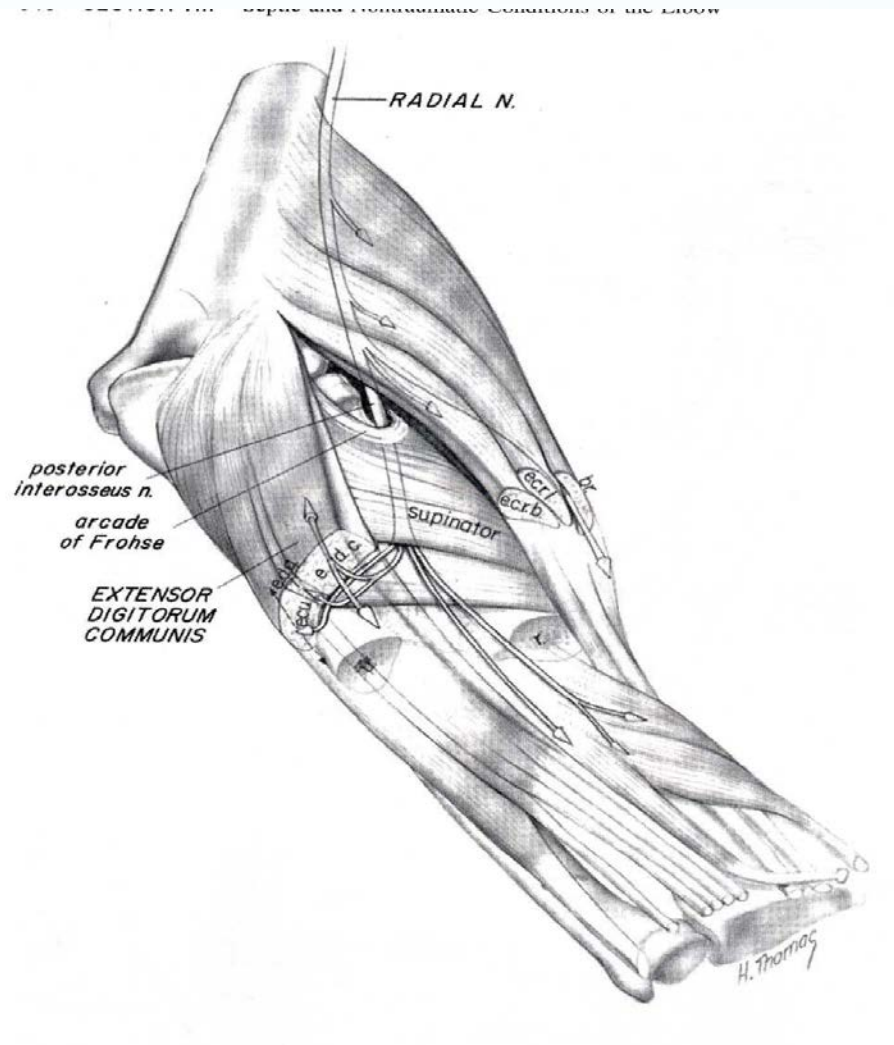
- Variable surgical success
- Surgery for LE may treat RTS
- Compressive lesion affecting sensory nerves in a predominantly motor nerve
- Pain syndrome with little objective findings
- Clinical or Electrophysiologic



Disputed Radial Tunnel Syndrome

Rosenbaum, 1999

- Tender points
- Local injection
- Nerve dysfunction
- Impaired nerve conduction
- NCS inaccurate
- Surgery
- Anatomic structures
- Analogy to carpal tunnel syndrome is flawed



Radial Tunnel Syndrome

- Radial nerve entrapment at one of 5 sites
- Anatomy- posterior cord to emerge between long and lateral heads of triceps, spiral groove of humerus proceeding medially to laterally to emerge between brachialis and brachioradialis on lateral elbow
- Racquet sports, rowing and wt. lifting

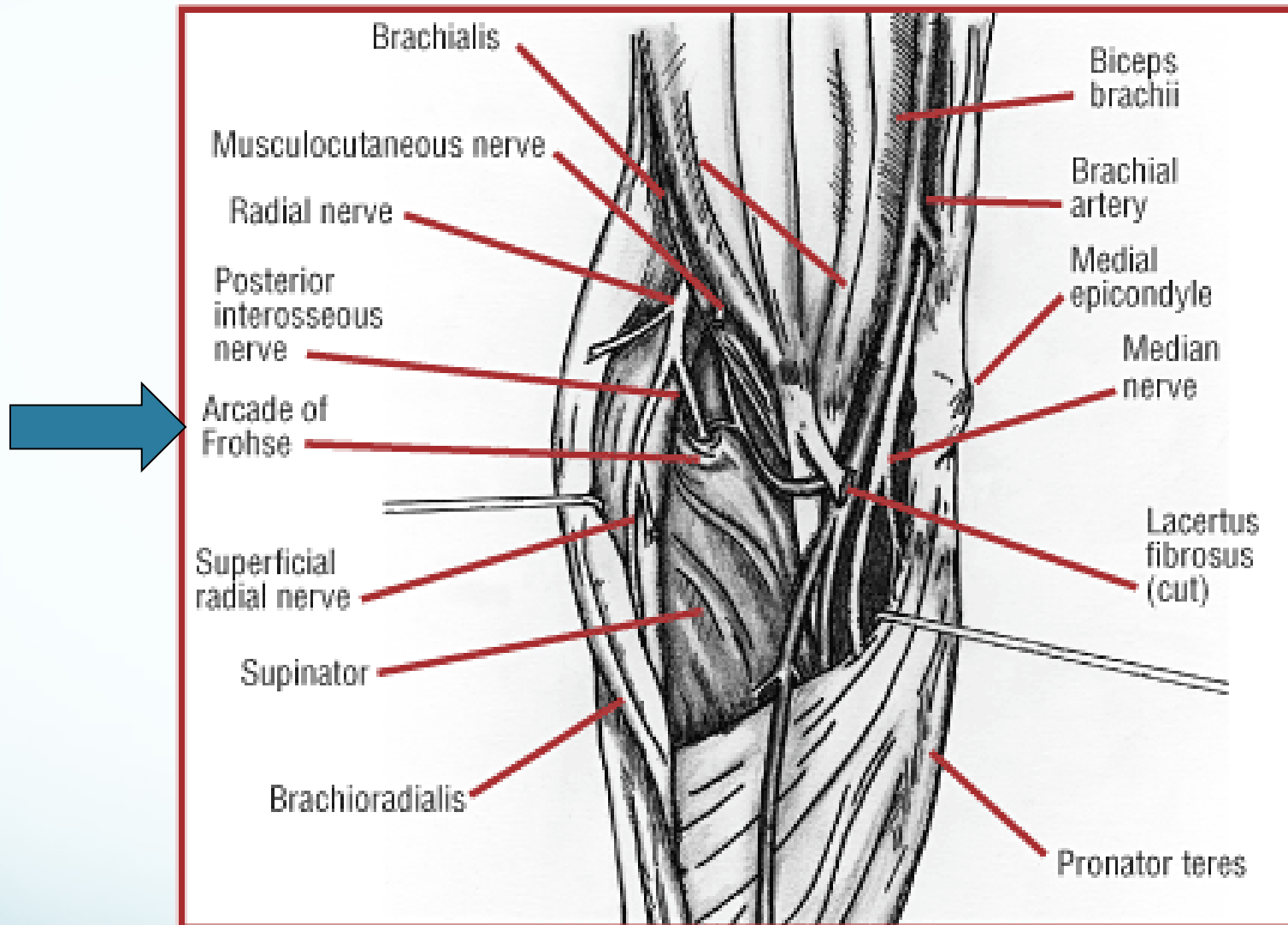


FIGURE 2. Antecubital region, with the pronator teres and brachioradialis reflected. The sites of distal radial nerve impingement within the arcade of Frohse (radial tunnel syndrome) and proximal median nerve impingement at the pronator teres (pronator syndrome) can be seen. Note also the cutaneous branch of the musculocutaneous nerve arising between the brachialis and biceps muscles.

Radial Tunnel Syndrome

- Sensory and motor complaints, although typically less weakness than with PIN
- Dull, deep lateral elbow pain, increased with elbow flexion and extension, forearm supination and wrist extension
- Tenderness over extensor muscle group
- Pain reproduced with resisted forearm supination with elbow flexed

Radial Tunnel Syndrome

- May mimic or coexist with lateral epicondylitis
- Rest, wrist or elbow splinting, corticosteroid injection at arcade of Frohse, neural mobilization techniques or NSAIDs
- Surgery for persistent symptoms usually involves releasing the entrapped location

Posterior Interosseous Nerve Syndrome

- PIN is a branch of the radial nerve, originating in the lateral intermuscular septum
- Purely motor function
- Innervates the supinator and later branches
- Multiple areas of potential compression
- Most common in racquet sports, but also bowlers, rowers, discus throwers, golfers, swimmers
- All involve repetitive supination and pronation

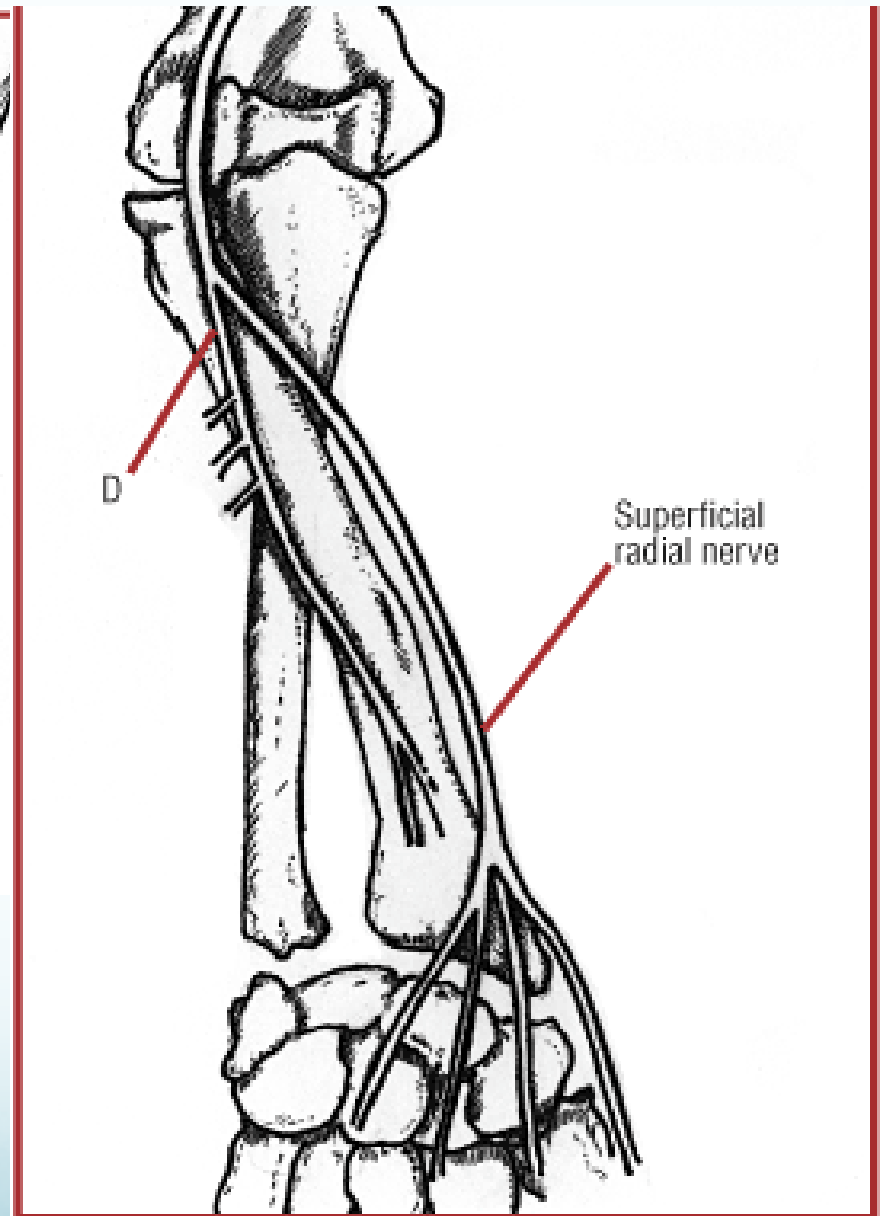
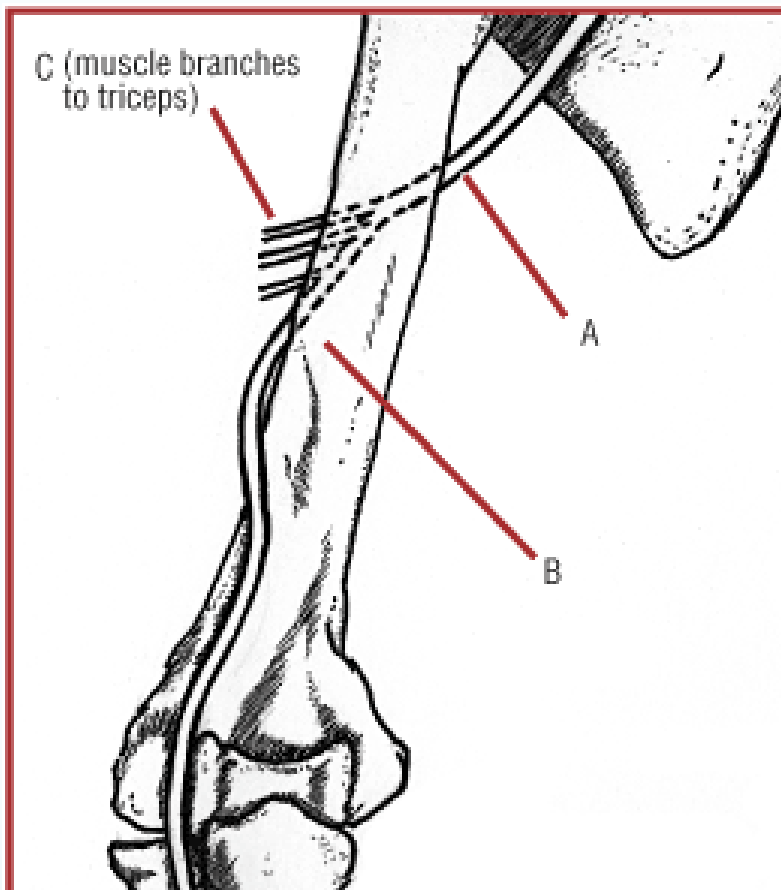


FIGURE 5. Sites of injury to the radial nerve reported with weight training: (A) high radial injury proximal to the triceps branches; (B) high radial injury distal to triceps branches with sparing of elbow extension; (C) isolated injury to the radial nerve triceps branches causing isolated triceps weakness without sensory loss; (D) posterior interosseous nerve compression at the supinator causing distal radial weakness with preservation of superficial radial nerve sensation.

PIN Syndrome

- Very similar symptoms and physical exam to RTS, except no sensory findings and more pronounced motor weakness
- Specifically, pain with resisted supination; weakness with resisted wrist extension in radial deviation, finger and thumb extension and thumb abduction
- EMG/NCS may be helpful to differentiate between lateral epicondylitis and PIN

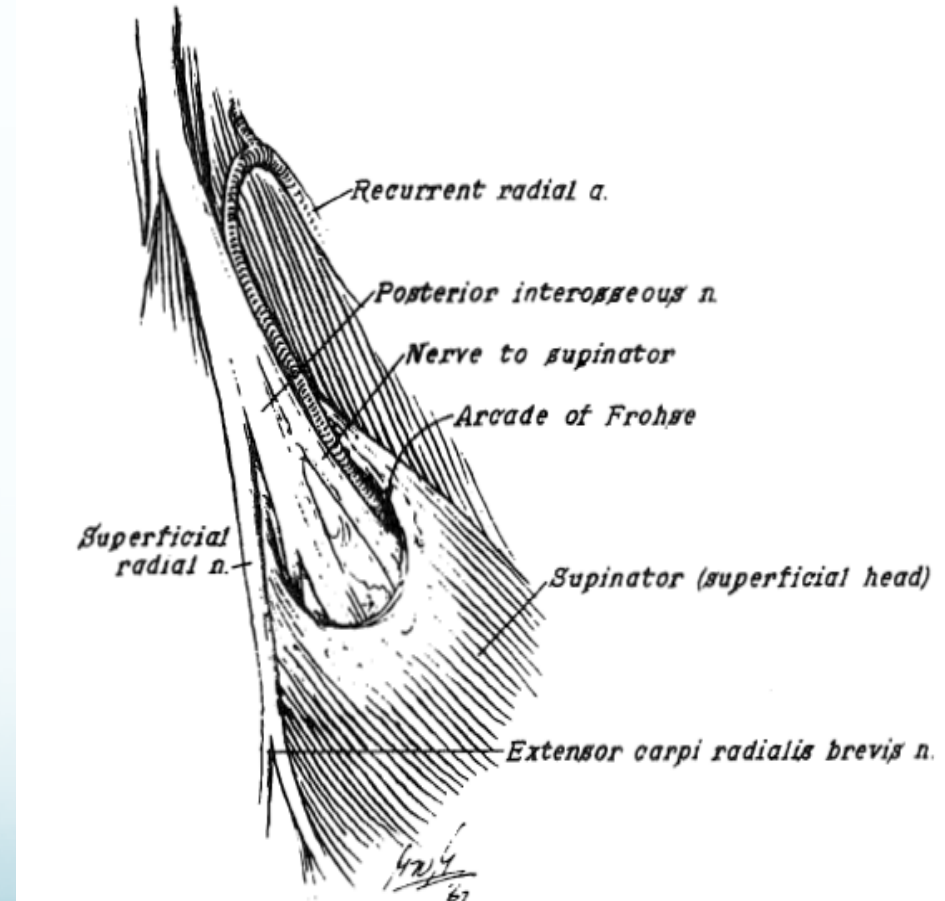
Treatment of PIN Syndrome

- Same as lateral epicondylitis and RTS
- Minimize supination during rehab

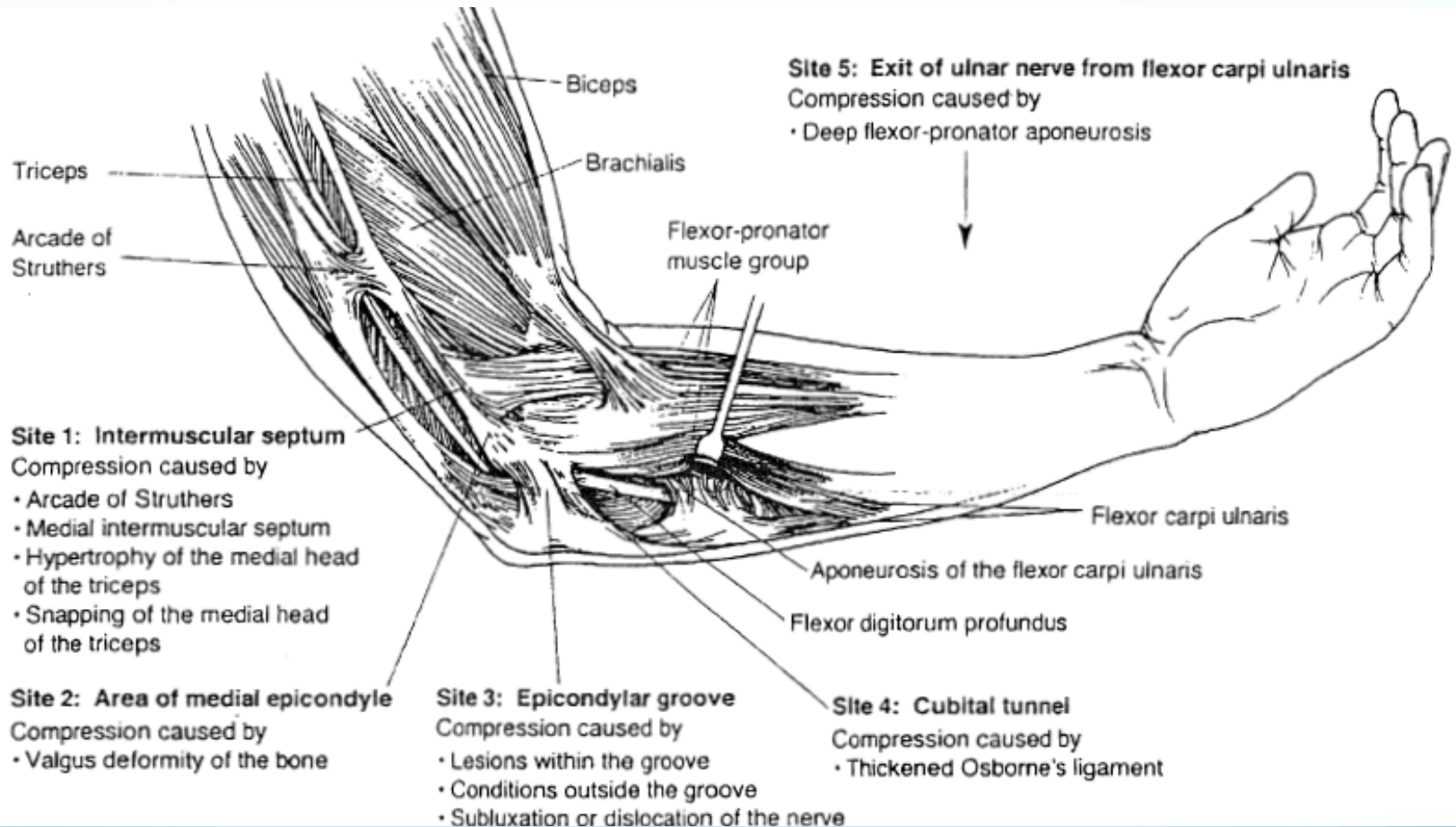


Supinator Syndrome

- Posterior interosseous nerve
- After innervation of ECRB
- Arcade of Frohse
 - Fibrous band at edge of supinator muscle
- Designation based of supinator findings on NEE flawed

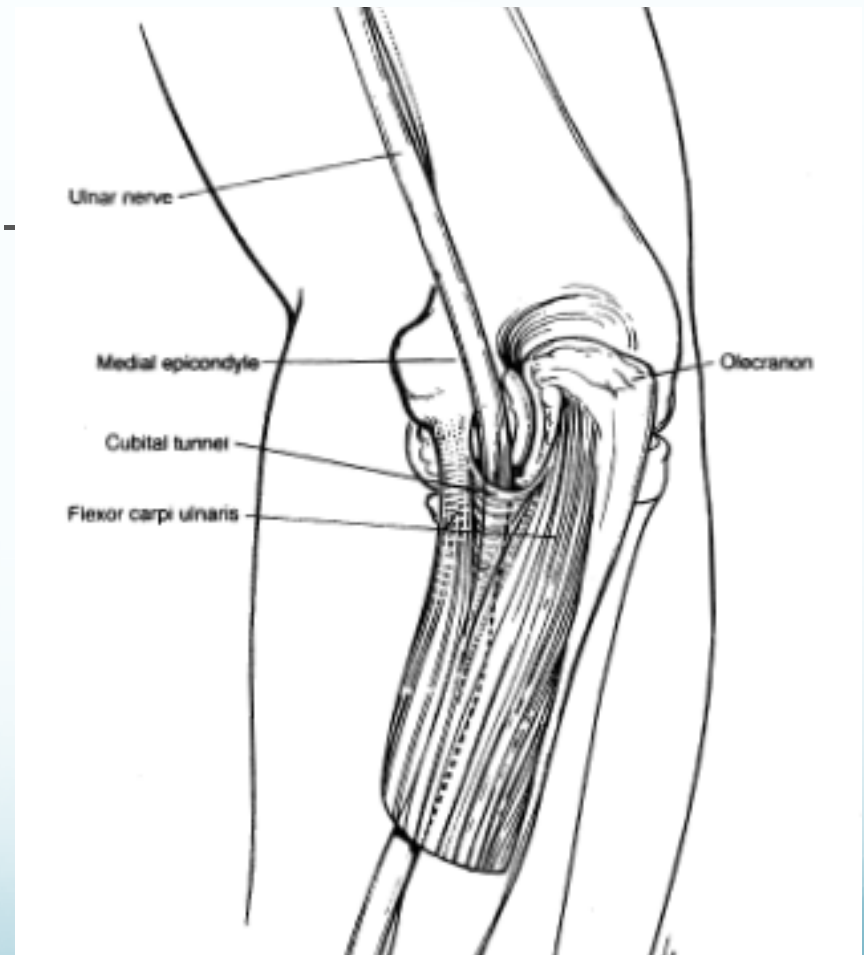


Ulnar Neuropathy at the Elbow



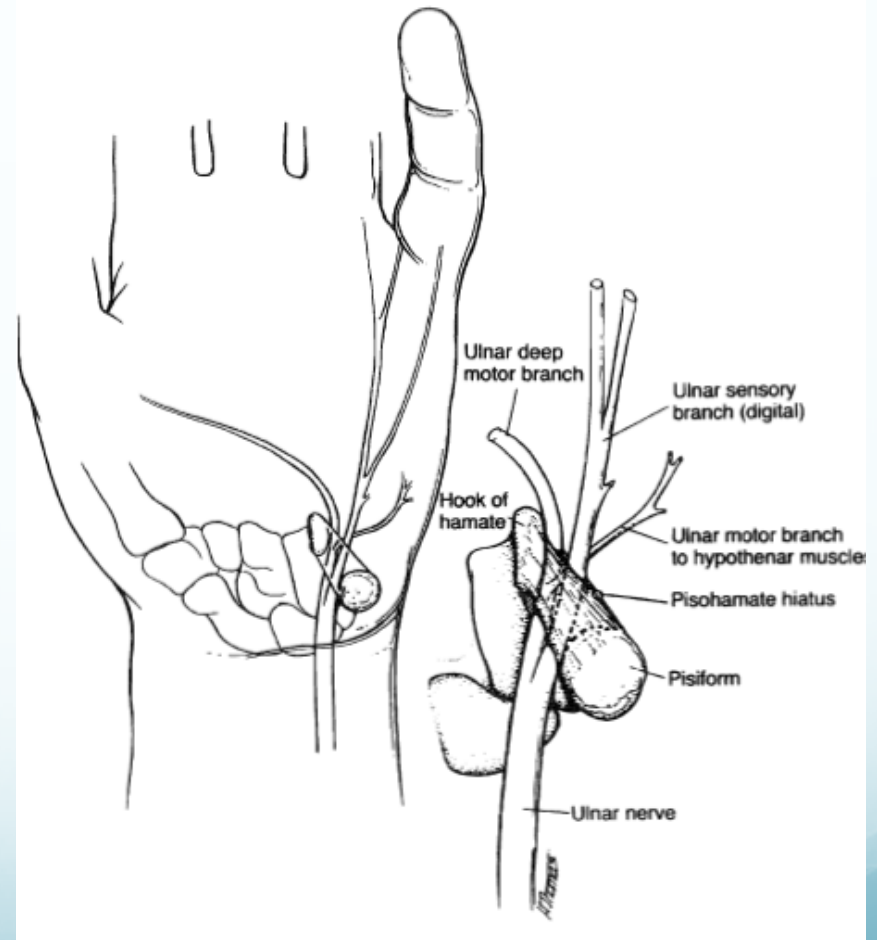
Ulnar Neuropathy at the Elbow

- 2nd most common
- Increased incidence in:
 - Overhead throwing sports, cross-country skiing, weight lifting, racket sport
- Presentation
 - Medial epicondyle pain prior to sensory complaints in ulnar innervated portion of hand
- Treatment:
 - Avoid aggravating factors
 - Conservative treatment
 - Surgical exploration for nerve pathology



Ulnar Neuropathy at Wrist


- Guyon's canal
 - Cyclists, wheelchair athletes, racket sports, club sports
 - Fracture of hook of the hamate
- Symptoms
 - Weakness of intrinsic except lumbricals of index and long fingers, adductor pollicis, deep head of FPB
 - Proximal
 - Spares DUC
 - Within
 - May spare deep motor branch
 - Distal
 - Spares all but sensory to 5th digit and ulnar side of 4th digit



Cyclist Palsy

Akuthota, et al, AJSM 2005

- 28 hands, RAGBRAI
- Prolonged latency of deep ulnar branch: ADM - FDI
- Worsening of NCS in 3 subjects with median neuropathy
- Symptoms in 50%, could not necessarily correlate with NCS
- Physiologic changes in deep ulnar branch, exacerbate CTS



Cubital Tunnel Syndrome

- Entrapment of ulnar nerve at the elbow
- Throwing athletes, weight-lifting, gymnastics, stick-handling sports
- May be entrapped as passing through fibro-osseous cubital tunnel formed by medial trochlea, medial epicondylar groove, posterior UCL and arcuate ligament

Cubital Tunnel Syndrome

- Potential ulnar nerve compression by multiple structures, including medial triceps, FCU, anconeus
- Ulnar nerve traction injury with UCL insufficiency, spurs, scar/adhesions or with nerve subluxation

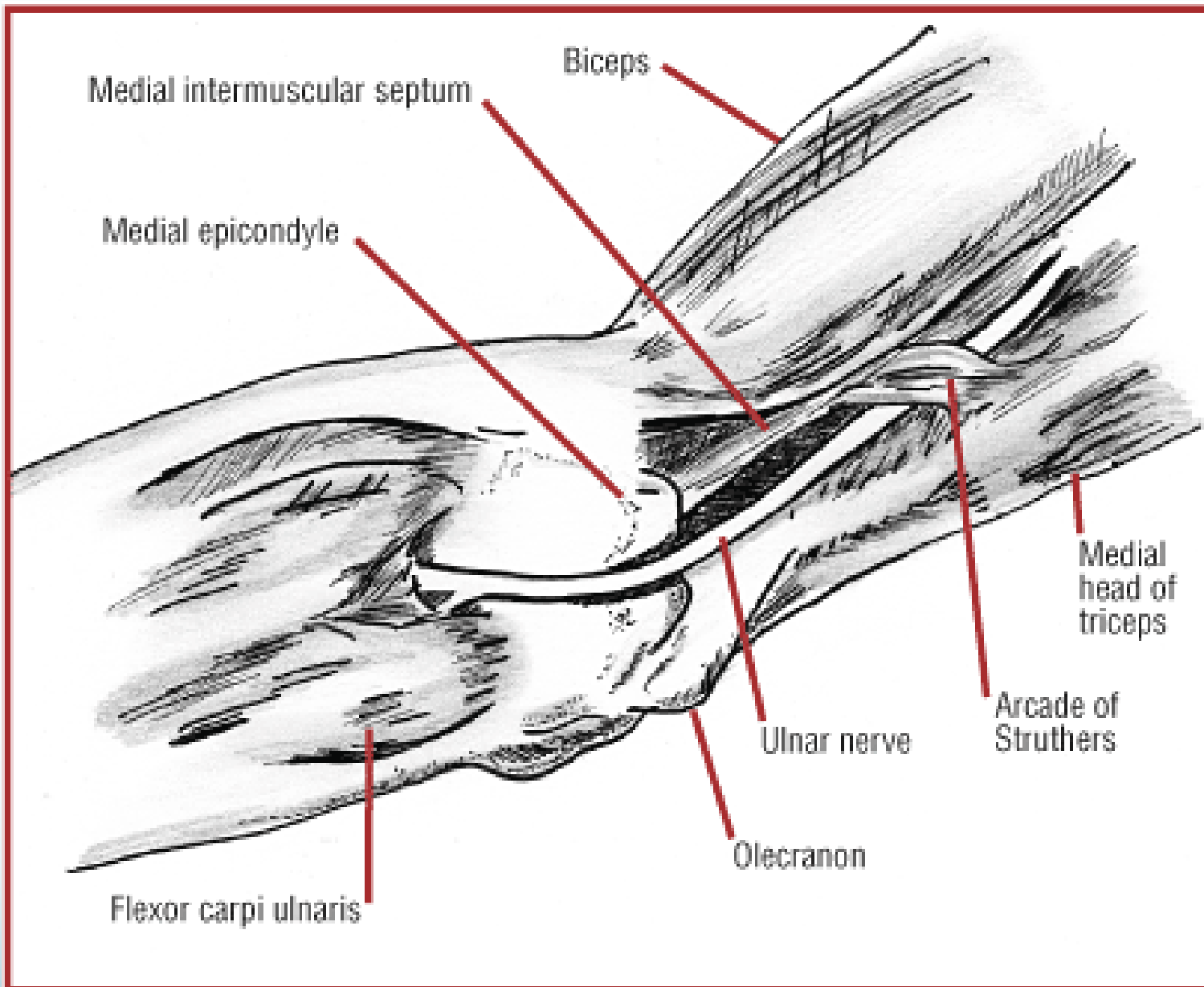


FIGURE 3. Ulnar nerve at the elbow. Common sites of ulnar nerve compression caused by medial triceps hypertrophy in weight-trained individuals are at the flexor carpi ulnaris (cubital tunnel syndrome) and near the arcade of Struthers.

Cubital Tunnel Evaluation

- Symptoms- medial elbow pain, increased with overhead activities; paresthesias in 4th-5th fingers
- Positive (asymmetric) Tinel's sign
- Possible intrinsic hand weakness and atrophy
- Provocative testing with elbows fully flexed and wrist extended for 3 minutes

Cubital Tunnel Evaluation

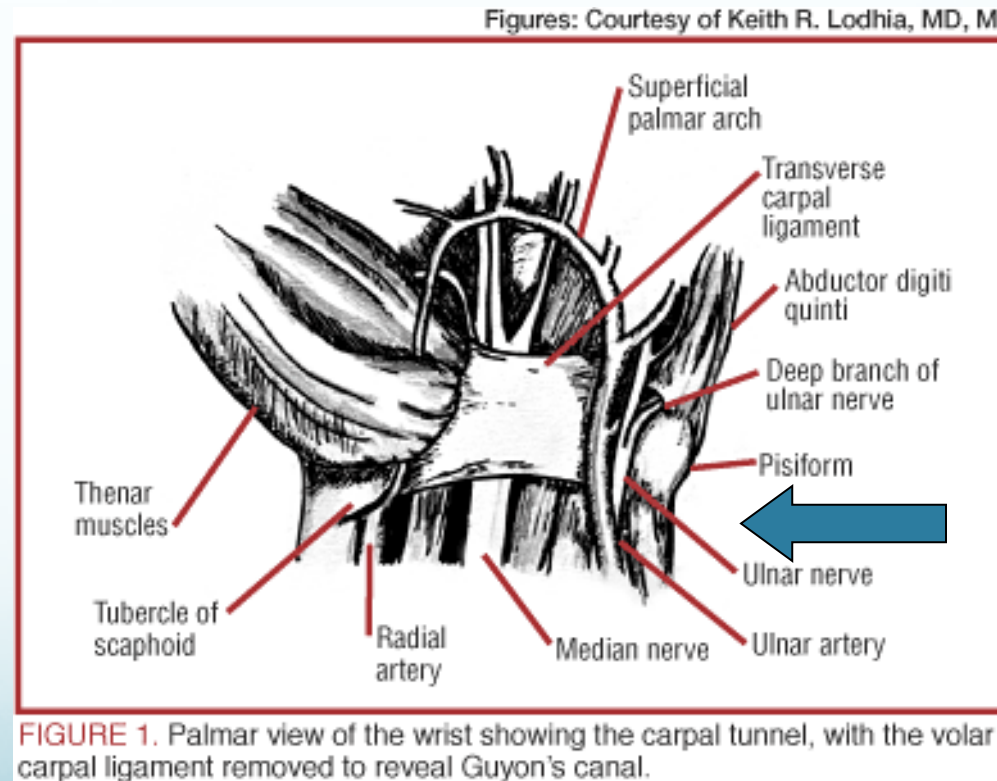
- Plain xrays to exclude a bony compression or evidence of UCL instability
- MRI may assist in a similar but more detailed fashion, but not typically necessary initially
- EMG/NCS to confirm diagnosis and determine severity

Cubital Tunnel Treatment

- Treat the underlying etiology
- Relative rest, night splints to decrease full flexion, NSAIDs or oral steroids
- Corticosteroid injection controversial
- Alteration of biomechanics
- Surgical treatment indicated if
 - Refractory to conservative management
 - Significant atrophy already present
 - Structural abnormality (spur, etc.) as the cause
 - Potential UCL pathology must be addressed

Ulnar Tunnel Syndrome

- Compression of ulnar nerve at Guyon's canal
- Typically in cycling
- Seen also in hook of hamate and pisiform fx
- Symptoms may be motor or sensory
- Similar symptoms and exam to cubital tunnel

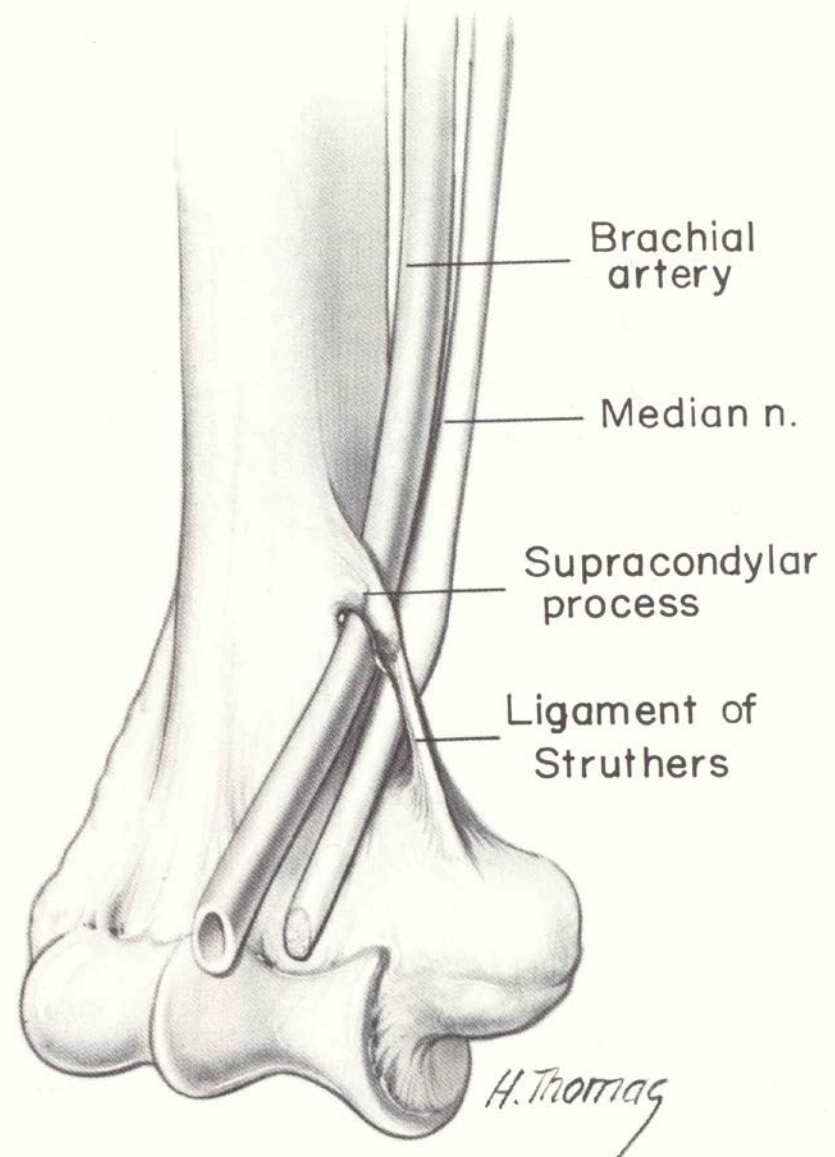


Ulnar Tunnel Syndrome Treatment

- Proper bicycle fitting, handlebar adjustments, frequent change in hand position, handle bar and glove padding
- Wrist splints
- Surgical decompression from failed non-op mgmt., especially with structural lesions such as hook of hamate fracture

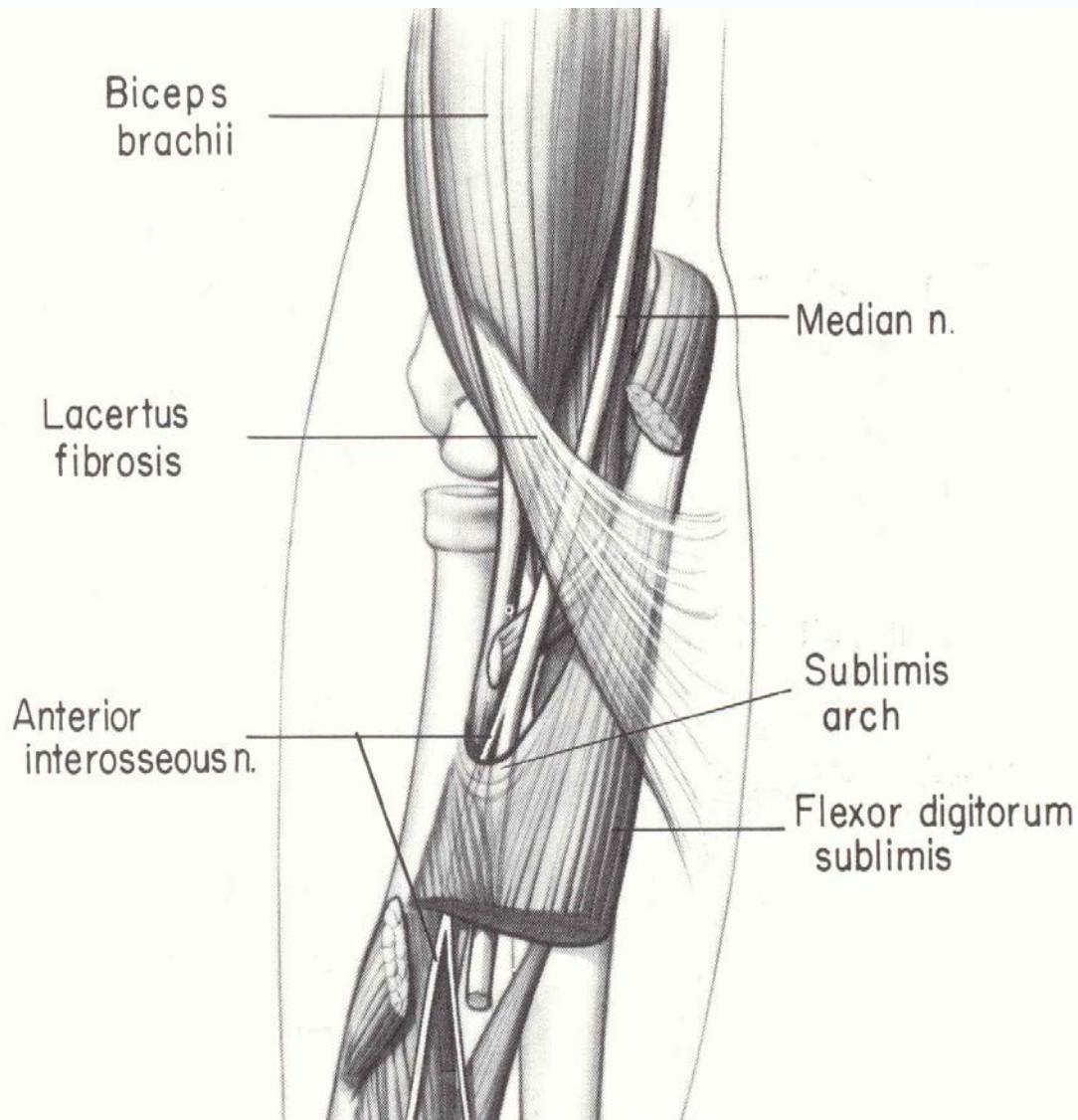
Median Nerve

- High median neuropathy
 - Trauma, fracture
 - Relatively uncommon
 - Protected nerve
- Ligament of Struthers
 - Fibro-osseous ligament
 - 0.7-2.7% of population
 - Most involve pronator teres



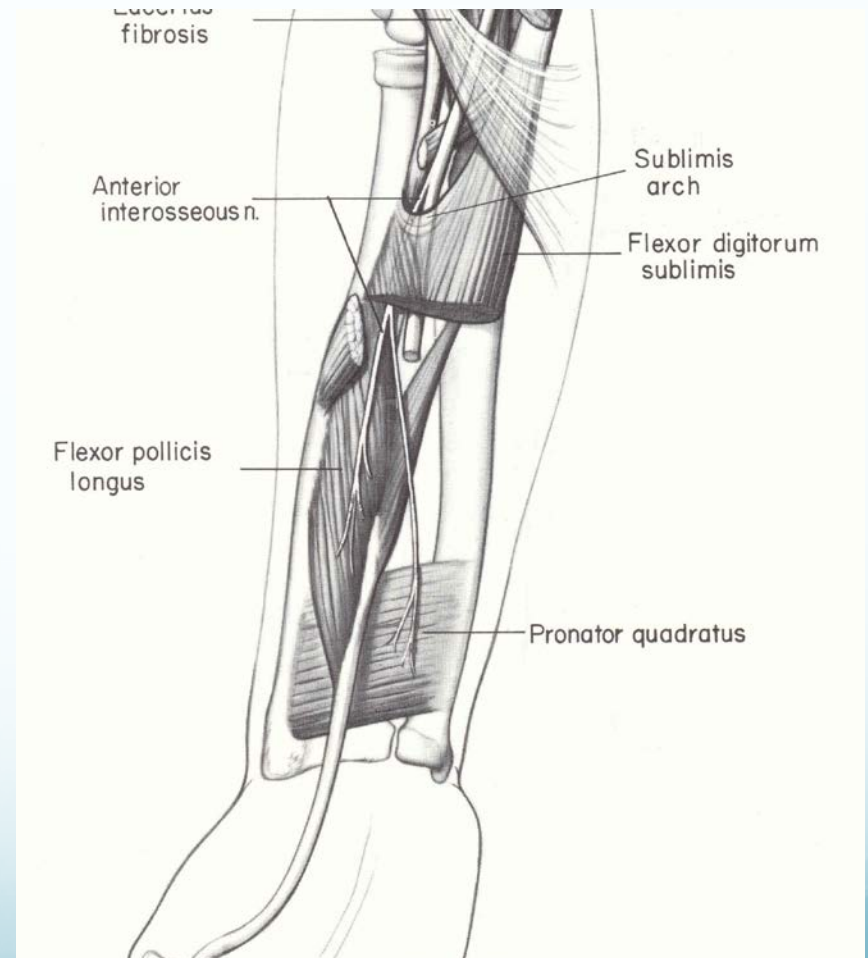
Median Nerve

- Lacertus Fibrosis
 - Bicipital aponeurosis
 - Thickened fascia
 - Variably present
 - Rare compression site
 - Similar EDx findings
- Pronator syndrome
 - 83-95% between heads
 - Sublimis arch
 - Weightlifting
 - Grocery bag neuropathy
- Explore all 3 areas
 - Aiken, 1987



Anterior Interosseous Nerve

- Isolated weakness
 - FPL, PQ, FDP
 - OK sign
- Fracture, forearm exertion, arthroscopy, anomalous fibrous band
- MRI reveals atrophy of above muscles
 - Grainger et al, 1998
- EDx: normal SNAP, abnormal NEE
 - Martin-Gruber anastomosis confuses picture



Pronator Syndrome

- Entrapment of median nerve at the elbow
- Repetitive elbow flexion, forearm pronation and gripping
- Tennis players, pitchers, wt. lifters, rowers
- Multiple areas of compression, most common being at pronator teres, near the anteromedial elbow

Pronator Syndrome

Evaluation

- Symptoms- vague pain volar elbow and forearm, associated with pronation and grasping
- Paresthesias in a median nerve distribution, but nocturnal symptoms are rare
- Pronator tenderness, pain with resisted pronation and a positive Tinel's
- Typical non-op. mgmt. usually effective

Carpal Tunnel Syndrome

- Compression of median nerve deep to the transverse retinacular ligament in volar wrist
- Sports with repetitive gripping, throwing, wrist flexion and extension
- Baseball, racquet sports, gymnastics, rowing, stick sports, wt. lifting, etc.

Figures: Courtesy of Keith R. Lodhia, MD, MS

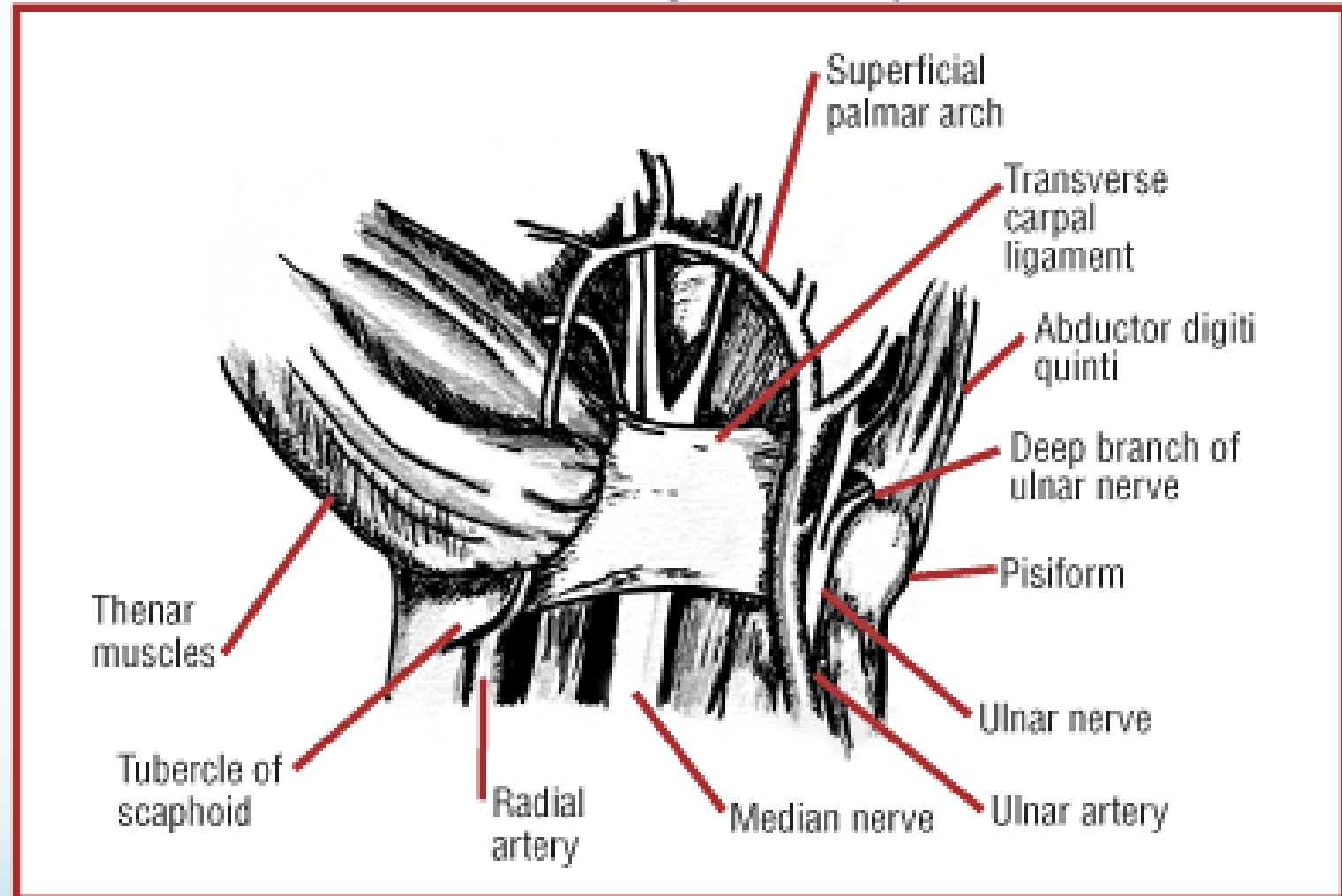


FIGURE 1. Palmar view of the wrist showing the carpal tunnel, with the volar carpal ligament removed to reveal Guyon's canal.

Carpal Tunnel Evaluation


- Symptoms- forearm, wrist and hand pain; paresthesias involving 1st-4th fingers, often worse at night
- Thumb weakness, possibly worse post-exercise
- Thenar eminence atrophy is a late sign
- Phalen's, Tinel's and median nerve compression signs
- Imaging to exclude structural causes
- NCS/EMG for confirmation, potential determination of severity

Carpal Tunnel Treatment

- Activity modification, splinting (esp. at night), tendon gliding rehab
- Corticosteroid injection- 30-45 angle, proximal to distal, ulnar to palmaris longus, lined up with 4th metacarpal, between proximal and distal volar wrist creases, 25 or 27 gauge needle; ~50% have good or excellent response
- Surgery indicated for refractory cases

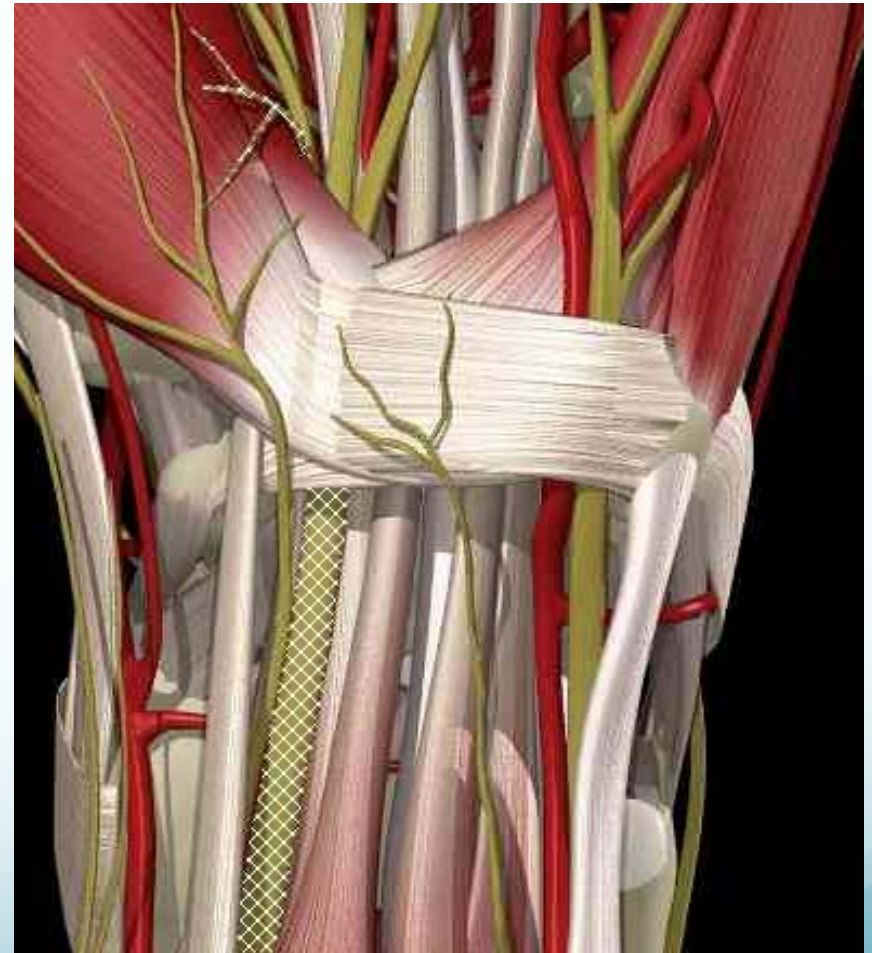
Carpal Tunnel Syndrome

- Most common compression neuropathy
- High Incidence in:
 - Cycling
 - Racket sports
 - Overhead throwing sports
 - Gymnastics
 - Those requiring prolonged gripping (climbing)



Carpal Tunnel Syndrome

- 9 tendons/1 nerve
 - 4 FDP, 4 FDS, FPL
 - Median nerve
 - FCR goes through a separate fibro-osseous tunnel
- Roof
 - Transverse carpal ligament
- Posterior fascicles are most easily injured by adjacent flexor tendons



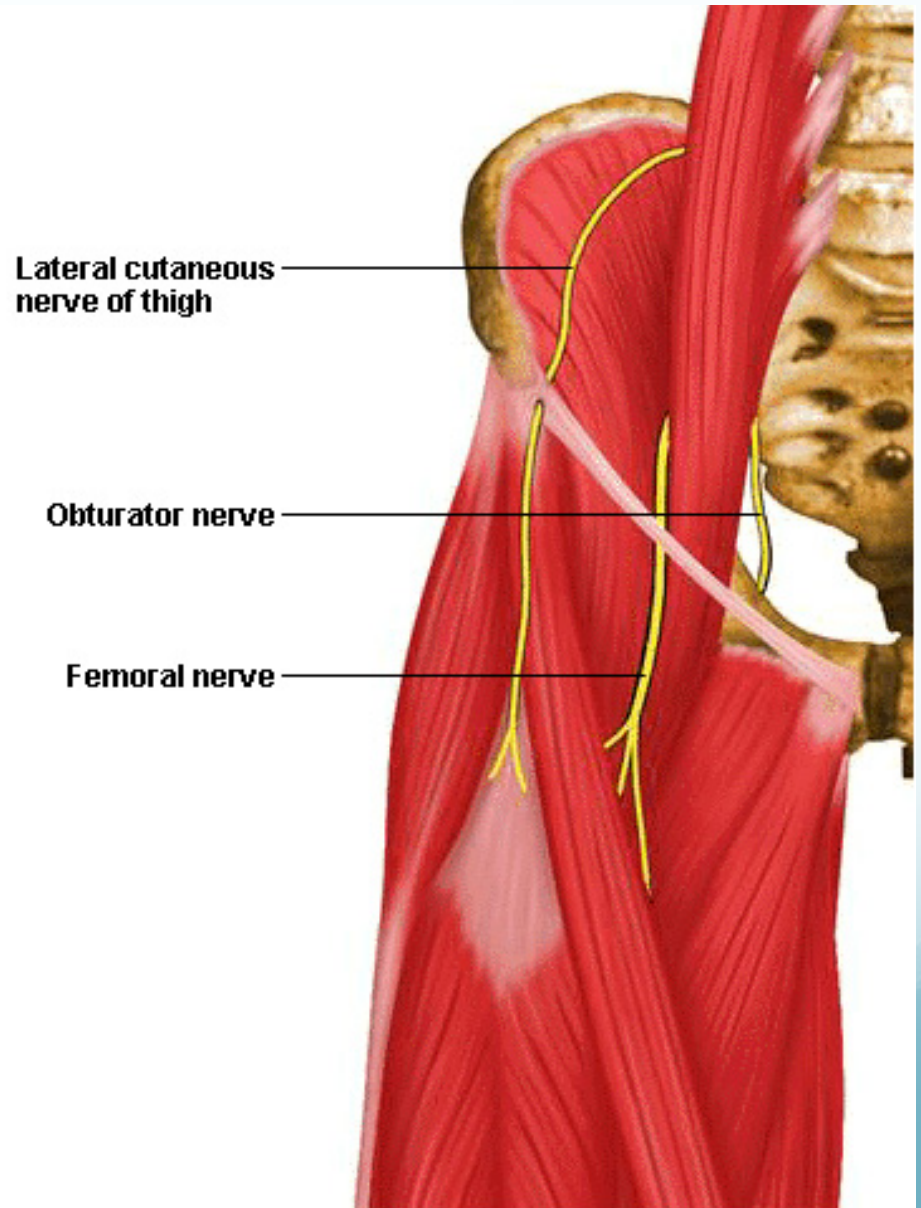
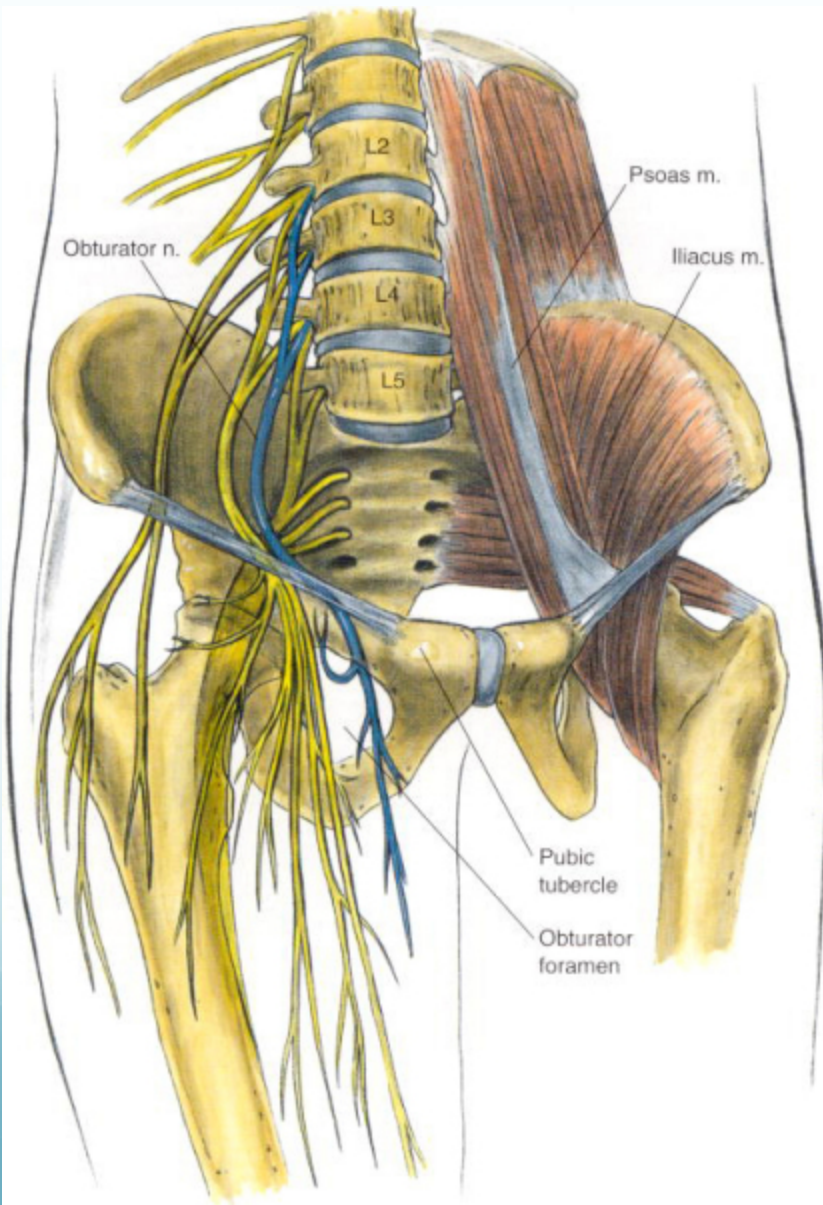
Carpal Tunnel Syndrome

- Evaluation
 - Clinical
 - EDX
 - Characterization
 - Motor, sensory, mixed, denervation
 - CSI high specificity (100%), sensitivity (82%)
 - Establish baseline
 - Ultrasound
- Treatment
 - Wrist splints
 - Full time wear more effective than night-time only
 - Injection
 - Recent studies suggest efficacy
 - Surgery

Nerve Entrapments in Lower Extremity

- Lateral Femoral Cutaneous Nerve
- Obturator Nerve
- First branch of Lateral Plantar Nerve
- Medial plantar nerve
- Tibial nerve
- Peroneal nerve
 - Superficial
 - Deep
- Sural nerve
- Saphenous nerve

Nerve Anatomy of Pelvis



Root Innervation of Lower Extremity Muscles

Femoral Nerve

L2 L3 L4 L5 S1 S2

	L2	L3	L4	L5	S1	S2
Iliacus						
Rectus Femoris						
Vastus Lateralis						
Vastus Medialis						

Obturator Nerve

L2 L3 L4 L5 S1 S2

	L2	L3	L4	L5	S1	S2
Adductor Longus						
Adductor Magnus (Also has Sciatic Nerve Innervation)						

Superior Gluteal Nerve

L2 L3 L4 L5 S1 S2

	L2	L3	L4	L5	S1	S2
Gluteus Medius						
Tensor Fascia Lata						

Inferior Gluteal Nerve

L2 L3 L4 L5 S1 S2

	L2	L3	L4	L5	S1	S2
Gluteus Maximus						

Sciatic Nerve

L2 L3 L4 L5 S1 S2

	L2	L3	L4	L5	S1	S2
Semitendinosus (Tibial Nerve Division)						
Semimembranosus (Tibial Nerve Division)						
Biceps Femoris, Long Head (Tibial Nerve Division)						
Biceps Femoris, Short Head (Peroneal Nerve Division)						

Peroneal Nerve

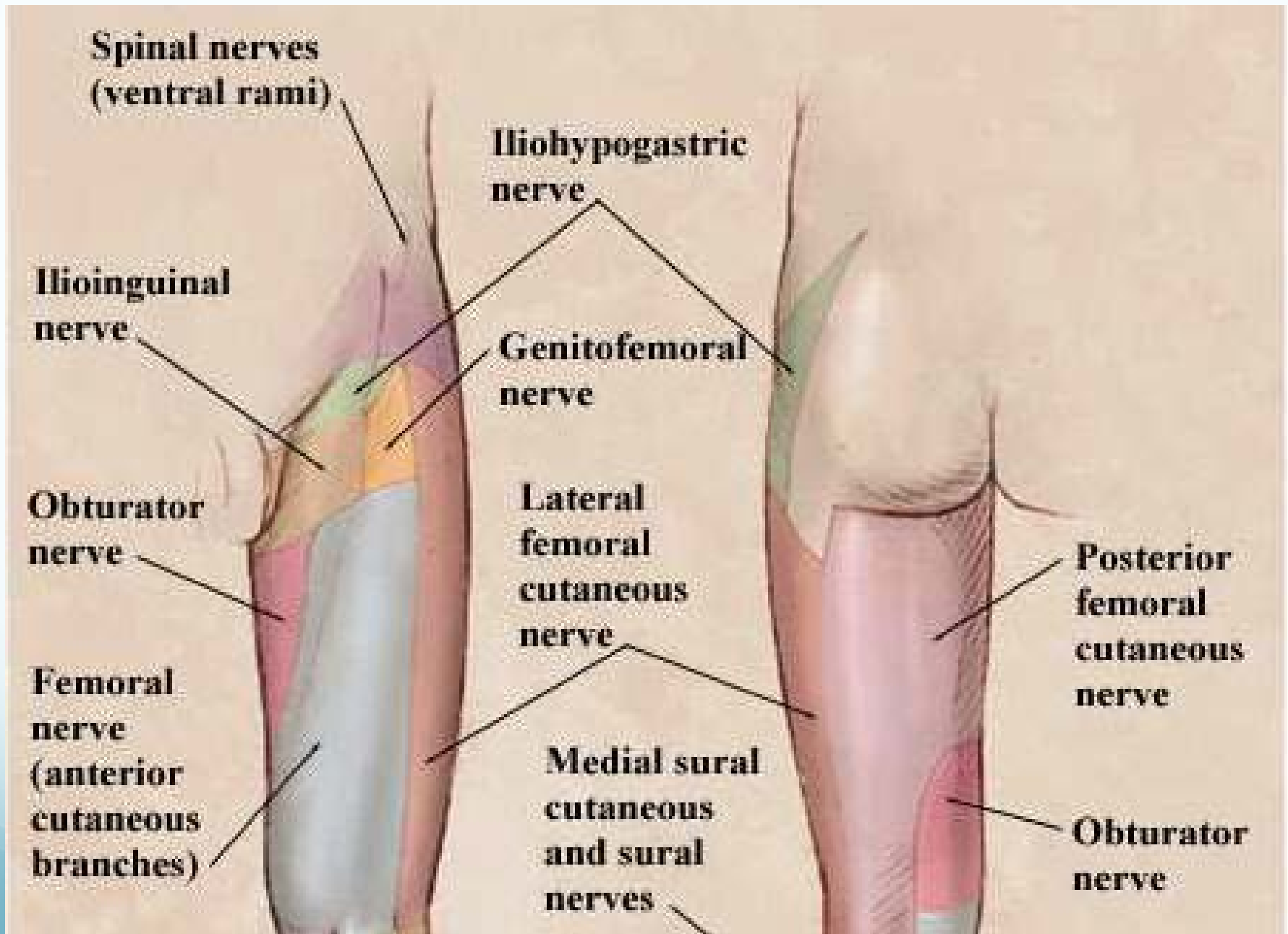
L2 L3 L4 L5 S1 S2

	L2	L3	L4	L5	S1	S2
Tibialis Anterior (Deep Peroneal Nerve)						
Extensor Digitorum Longus (Deep Peroneal Nerve)						
Extensor Hallucis Longus (Deep Peroneal Nerve)						
Peroneus Longus (Superficial Peroneal Nerve)						
Peroneus Brevis (Superficial Peroneal Nerve)						
Extensor Digitorum Brevis (Deep Peroneal Nerve)						

Tibial Nerve

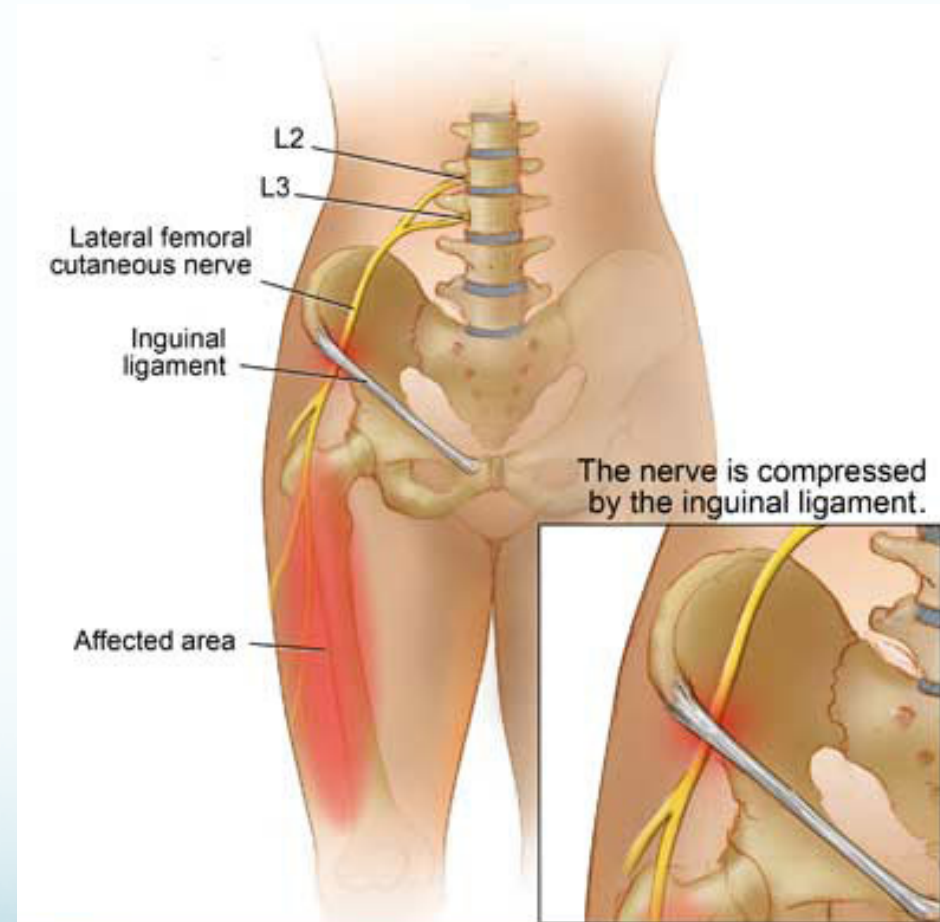
L2 L3 L4 L5 S1 S2

	L2	L3	L4	L5	S1	S2
Tibialis Posterior						
Flexor Digitorum Longus						
Gastrocnemius (lateral head)						
Gastrocnemius (medial head)						
Soleus						
Abductor Hallucis						
Abductor Digiti Quinti Pedis						



Lateral Femoral Cutaneous Nerve Entrapment “Meralgia Paresthetica”

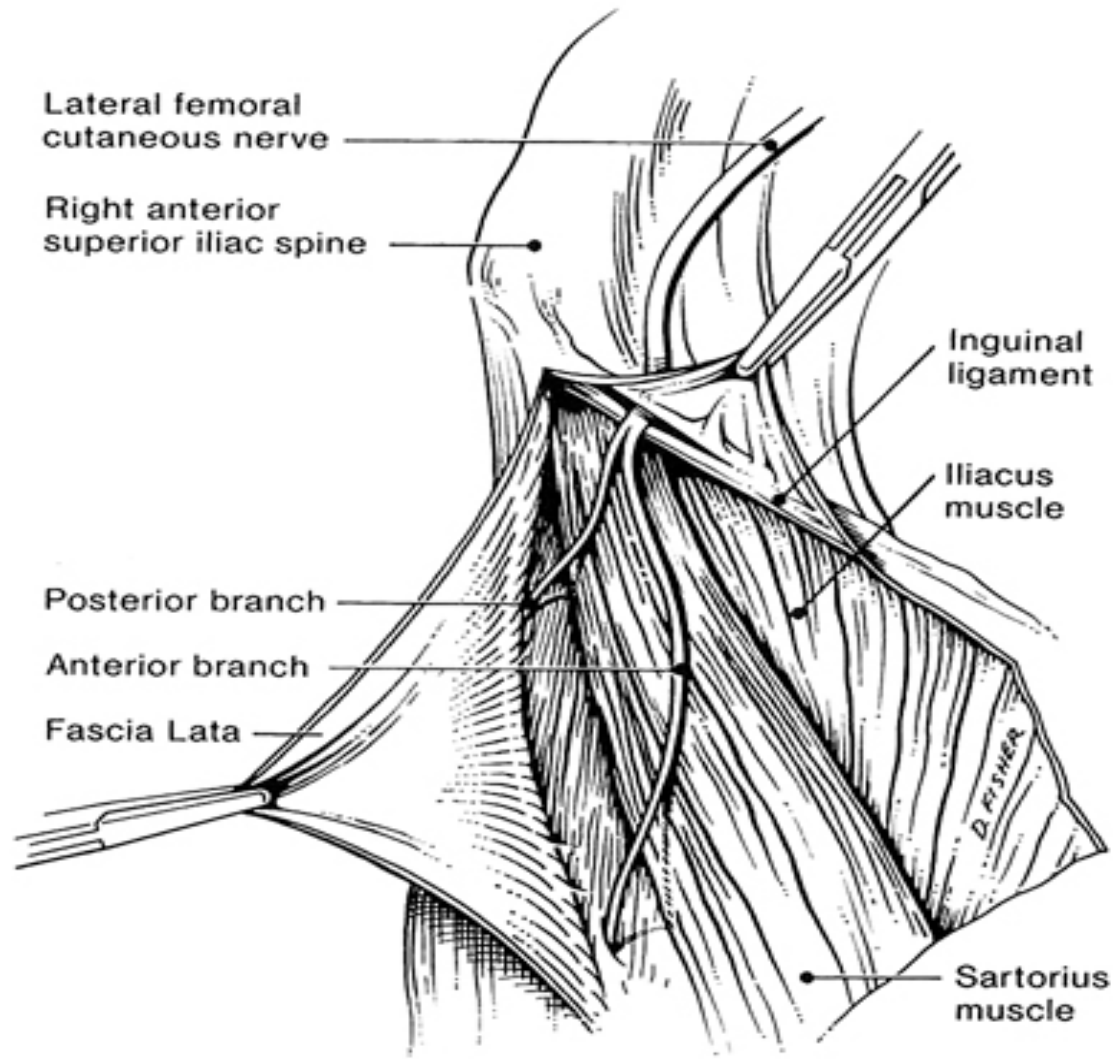
- LFCN arises from L2-L3
- Exits pelvis medial to ASIS thru slit in inguinal ligament
- Injury usually at inguinal ligament
 - Repetitive hip flex/ext
 - Compression
- Etiologies
 - Tight clothing/belts
 - Rapid weight gain
 - “Dunlop’s Disease”
 - Thyroid dz or diabetes



Lateral Femoral Cutaneous Neuropathy

- Pure sensory nerve formed from posterior portions of the ventral rami of L2 and L3 nerve roots.
- Passes medial and inferior to the anterior superior iliac spine (ASIS), inferior to the inguinal ligament and superior to the sartorius muscle.
- A Hip Pointer is a contusion to the ASIS injuring LFCN.
- Neurapraxic lesion seen in football, hockey, soccer and basketball

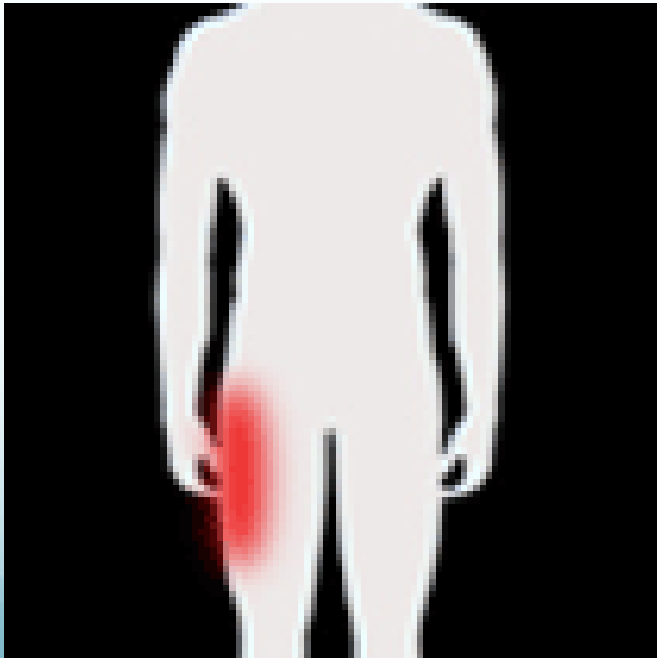
Lateral Femoral Cutaneous Neuropathy



Lateral Femoral Cutaneous Nerve Entrapment

SYMPTOMS

- Neuropathic pain over anterolateral thigh



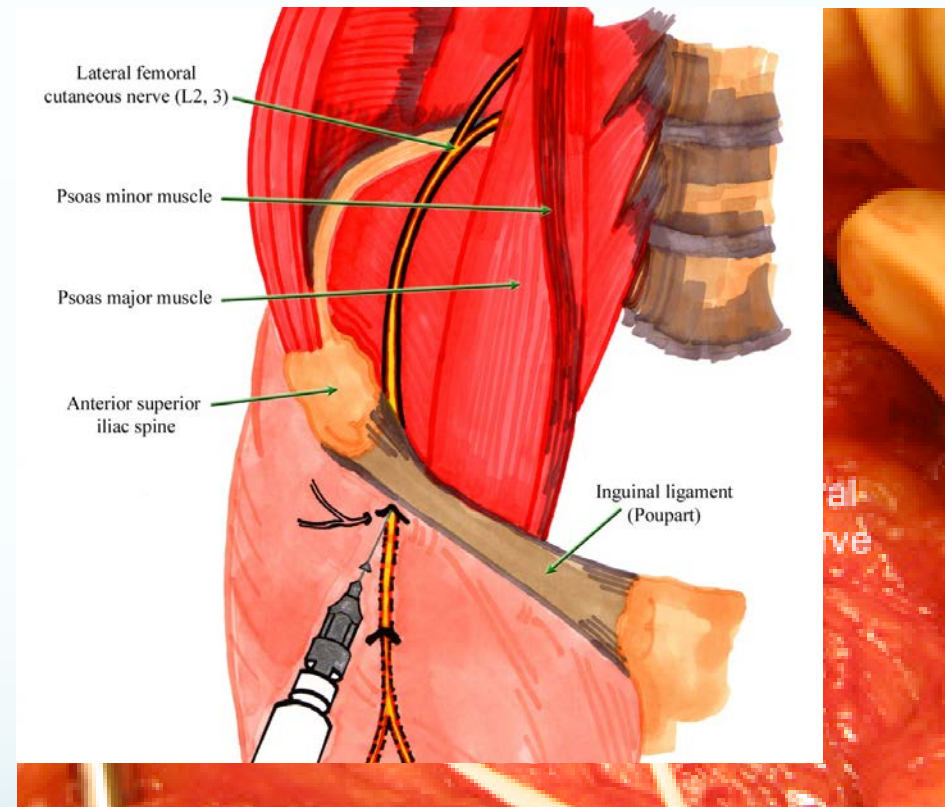
EXAM & TEST FINDINGS

- Exam often normal
- Tinel's 1 cm antero-inferior to ASIS
- Sensory deficit
- Injection can be diagnostic

Lateral Femoral Cutaneous Nerve Entrapment

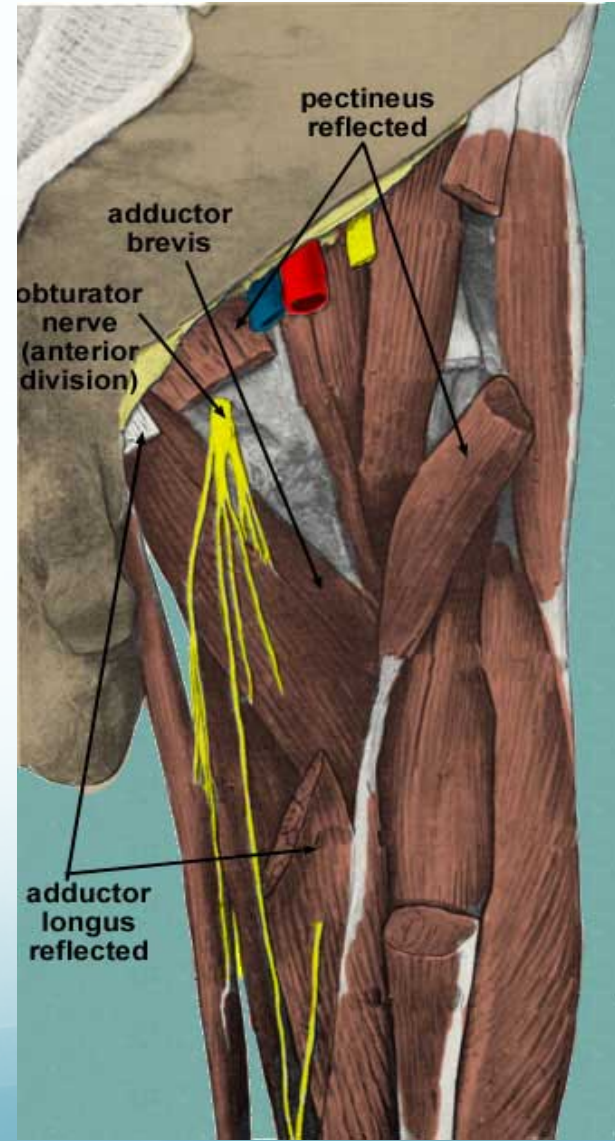
TREATMENT

- “deal with it”
- Remove external pressure source
 - Weight loss
 - Clothing changes
- Injection
- Surgical decompression
- Meds



Obturator Nerve Entrapment

- Exits pelvis in fibro-osseous tunnel (Obturator Canal)
- Innervates most adductors
- Sensation to $\frac{1}{2}$ to $\frac{1}{3}$ of distal medial thigh
- Entrapment commonly at exit of obturator canal



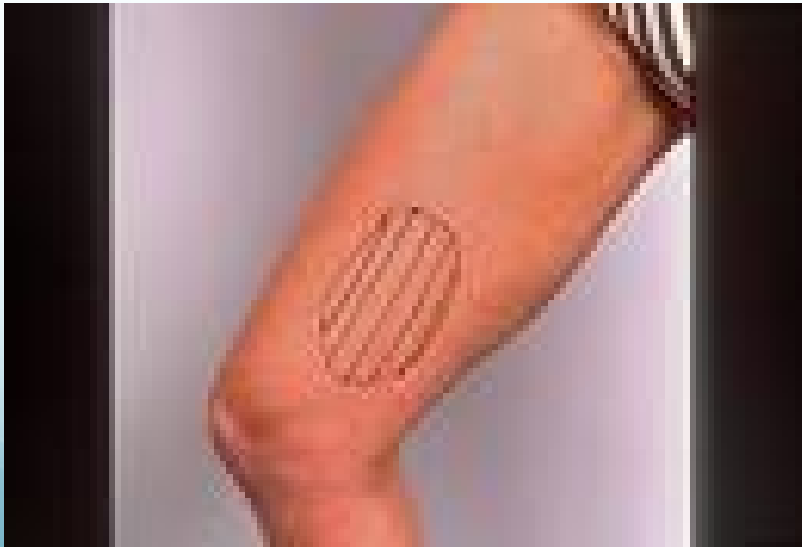Obturator Nerve Entrapment

Symptoms

- Groin pain—deep, achy
- Rare radiation, tingling, numbness

Exam & Test Findings

- Exam often unremarkable
- Diagnosis difficult
- EDT: occasional fibrillation in adductor muscles
- Diagnostic injection useful

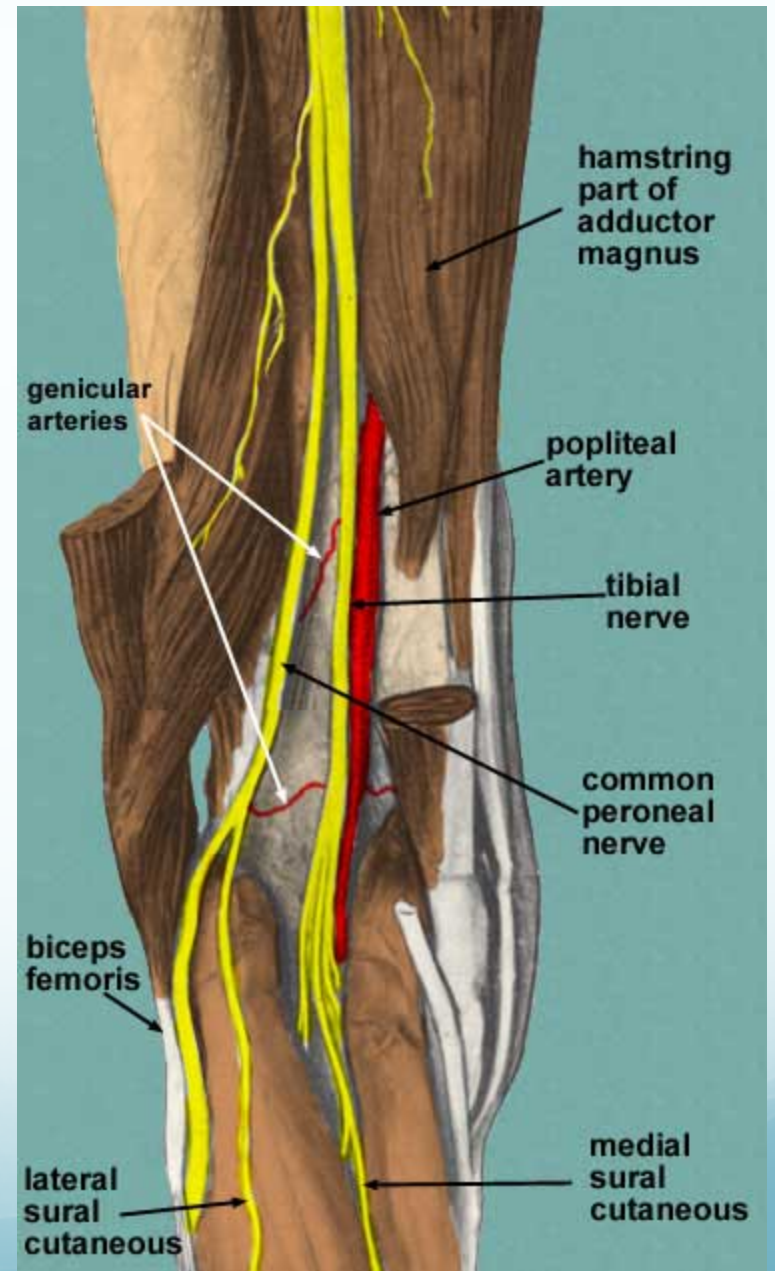
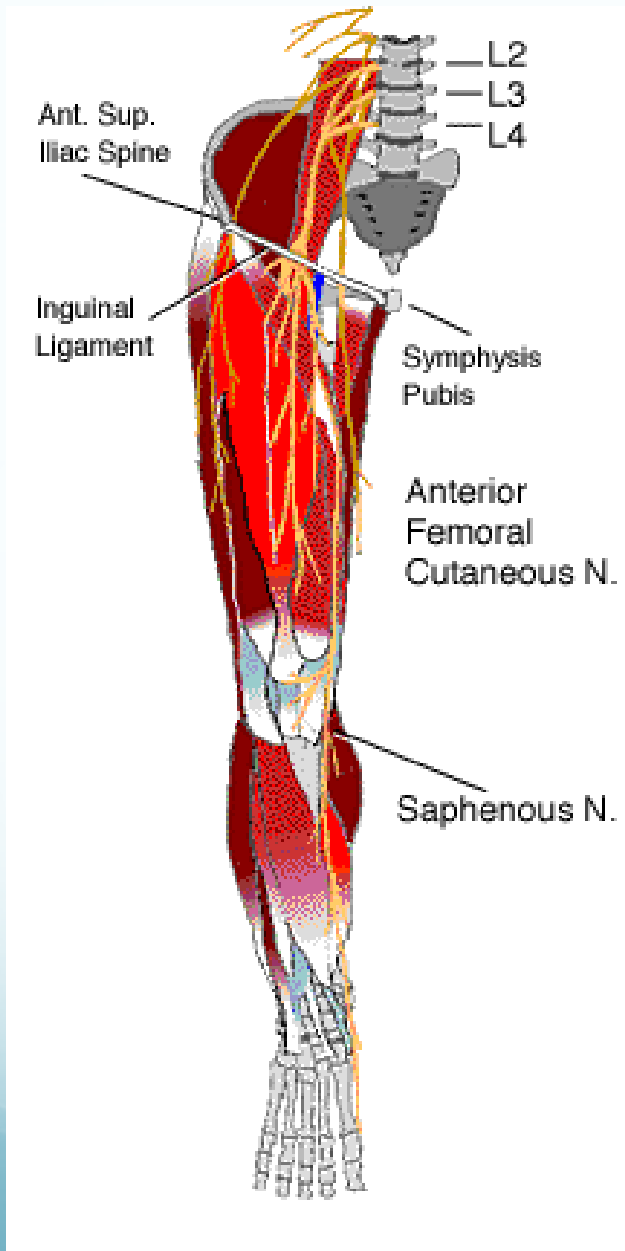


Obturator Nerve Entrapment

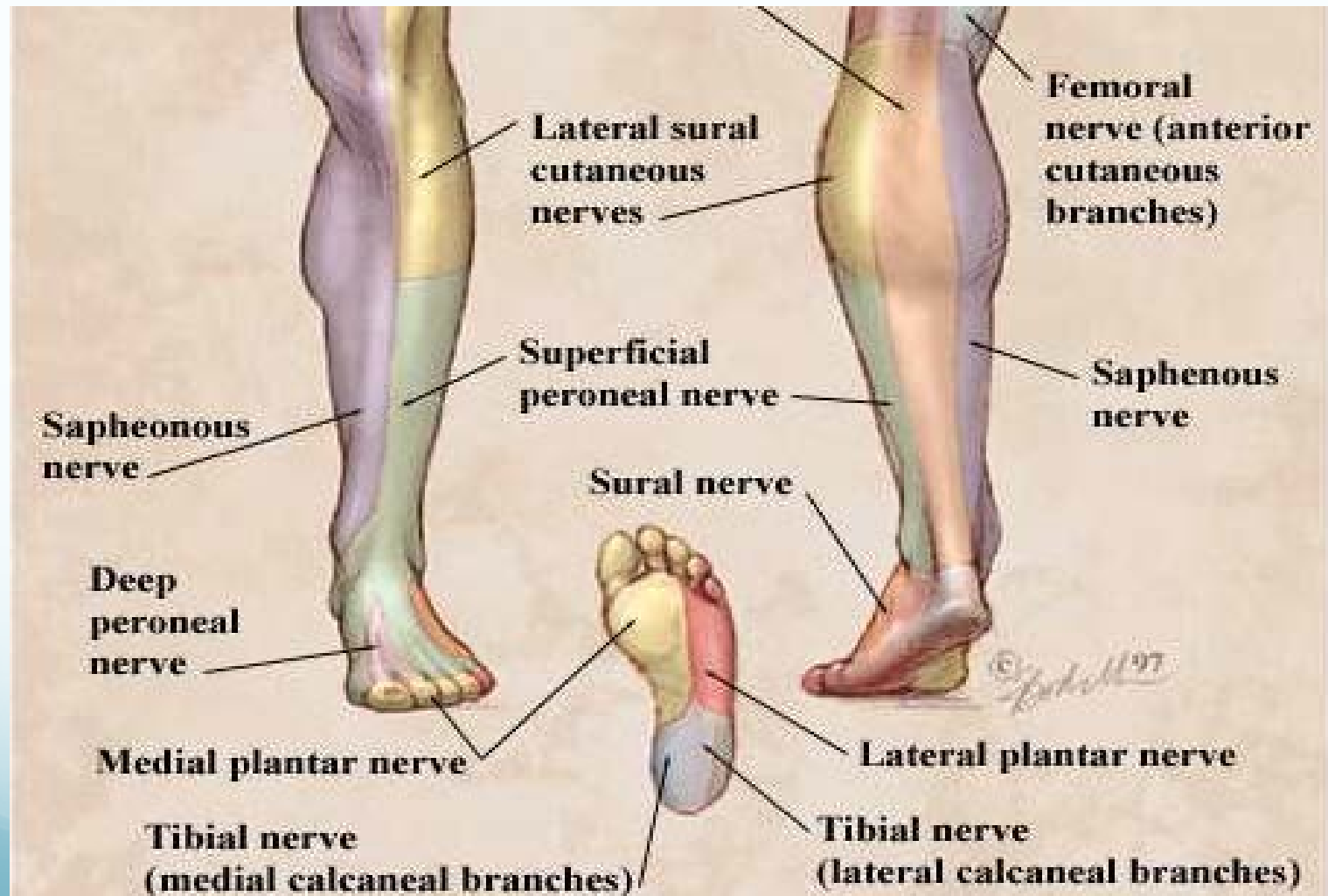TREATMENT

- Guided injection
- Physical therapy to optimize hip ROM and strength
- Surgical ligation if refractory

Nerve anatomy of thigh

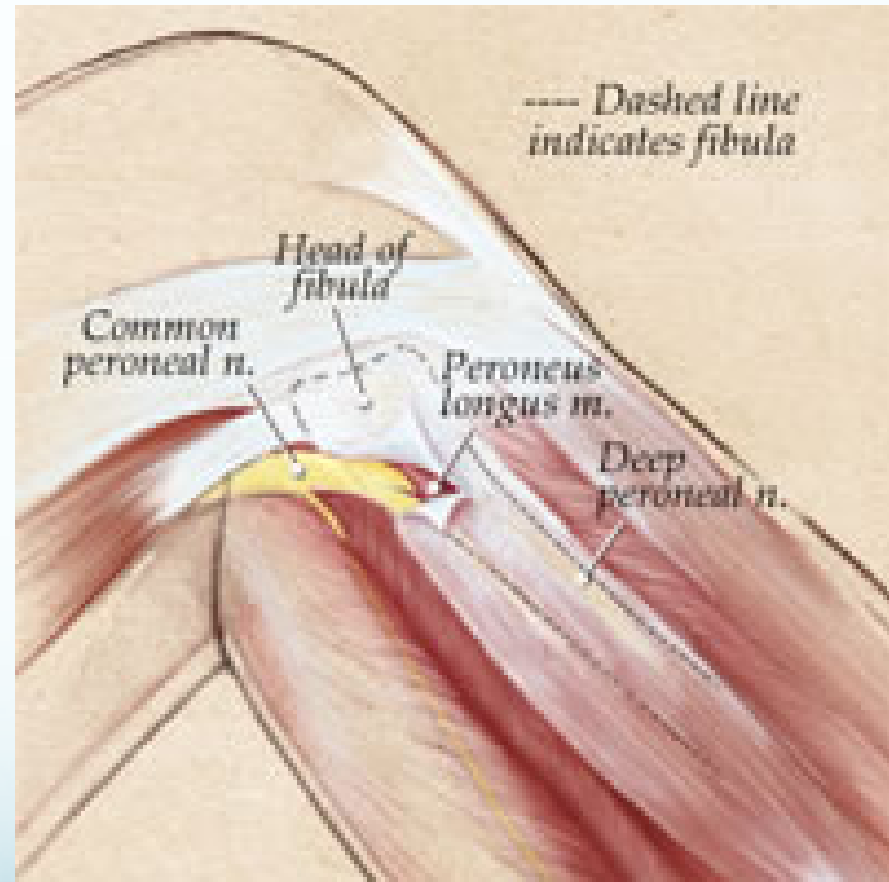


Nerve anatomy of lower leg



Common Peroneal Nerve Entrapment

- Usually at fibular head
- Etiologies
 - Compression: Leg crossing, casts, orthoses
 - Contusions
 - Fibular head dislocation
 - Tumors
 - Tib-fib joint ganglion
 - Baker's cyst
 - Genu varum, recurvatum
 - Compartment syndrome

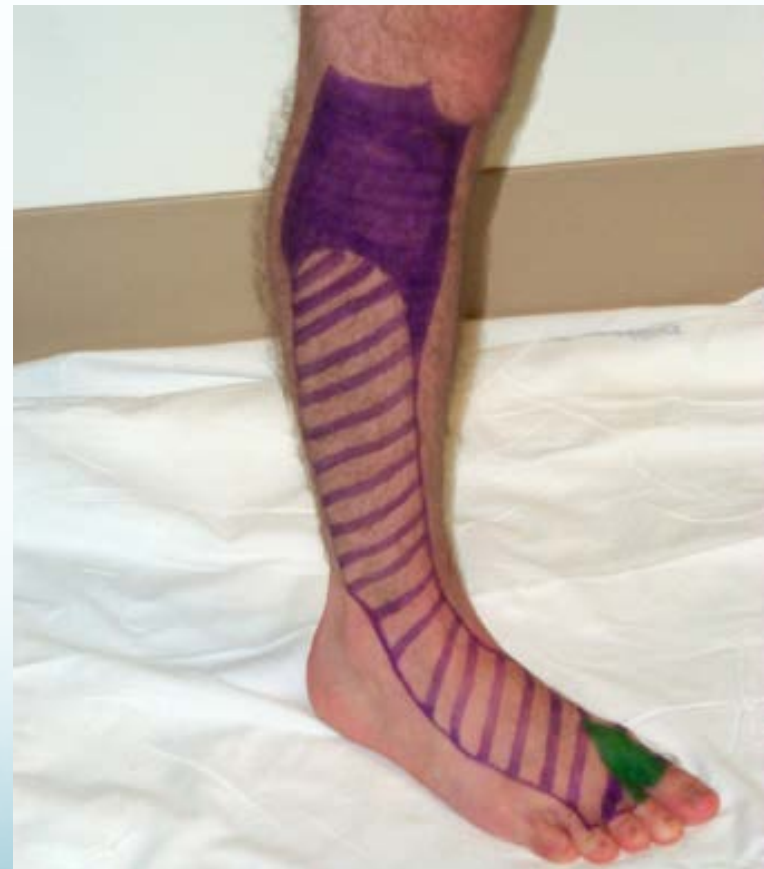

Common Peroneal Nerve Entrapment

SYMPTOMS

- Neuropathic pain in anterolateral leg, extending into dorsal foot and toe web spaces
- Weakness:
 - steppage gait
 - foot slap
 - Recurrent ankle sprains

EXAM & TEST FINDINGS

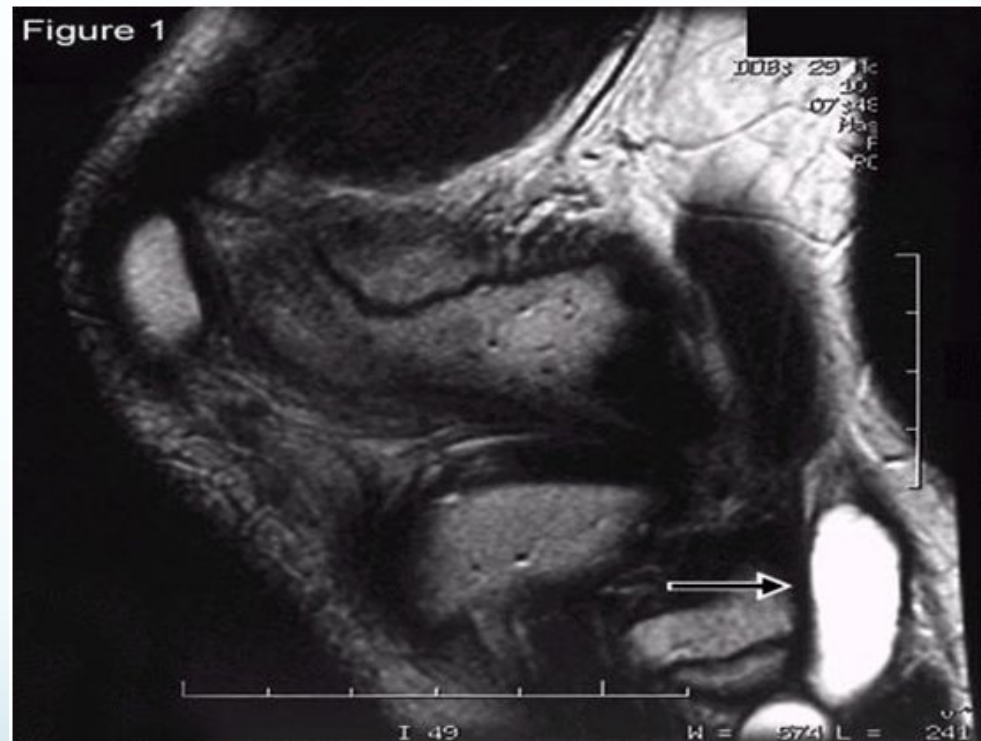


Common Peroneal Nerve Entrapment

TREATMENT

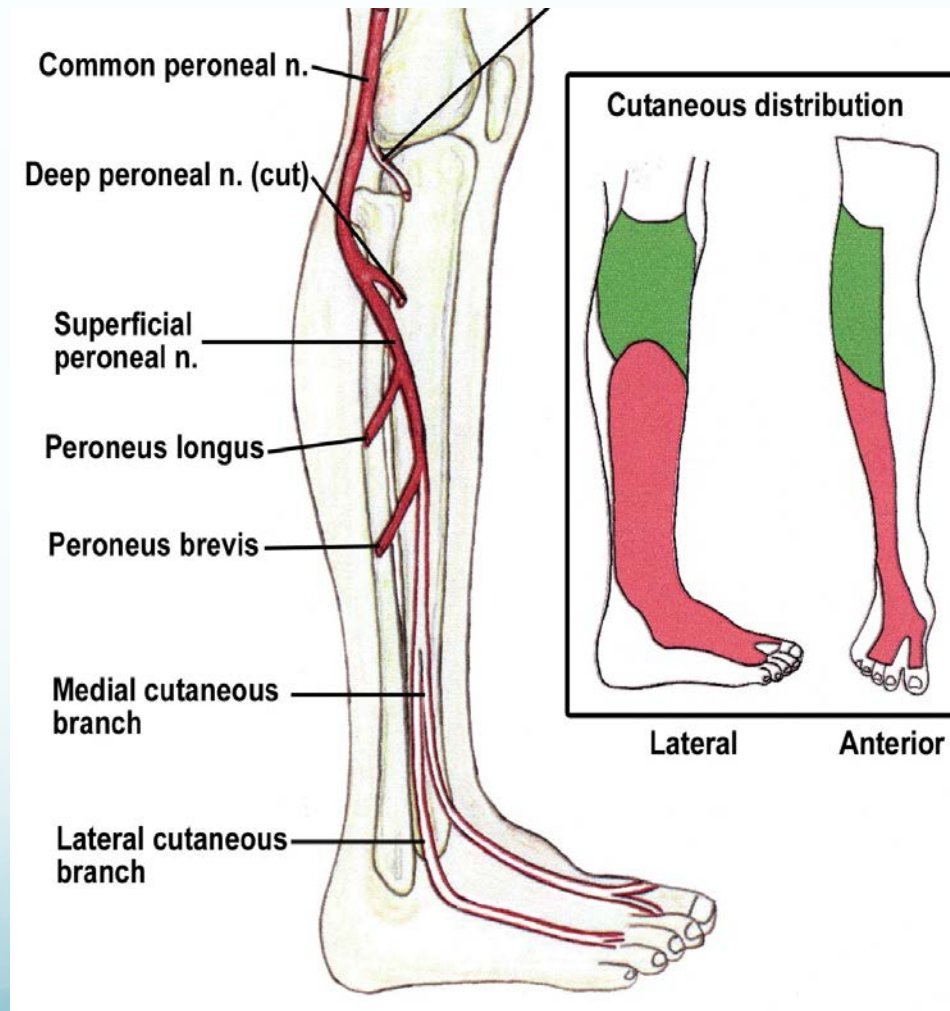
- Meds
- Address underlying cause
- Biomechanical aids to reduce nerve tension
- Dorsiflexion support
- Running style change
 - Reduced varus & recurvatum
- Injection
- Surgical decompression

Peroneal ganglion cyst



Superficial Peroneal Nerve Entrapment

- Most commonly entrapped at crural fascia penetration site
- Etiologies
 - Muscular herniation
 - Contusion
 - Fibular fracture
 - Edema
 - Varicose veins
 - Tight boots
 - Tumors, ganglia



Superficial Peroneal Nerve Neuropathy

- Uncommon cause of anterolateral leg pain
- Superficial peroneal nerve innervates peroneus longus and brevis with sensation to dorsum of the foot.
- Deep peroneal nerve supplies tibialis anterior, peroneus tertius, toe extensors with sensation to first web space of the foot.
- Entrapment as nerve exits from deep fascia, usually 8-10 cm above lateral malleolus over anterolateral leg

Deep and Superficial Peroneal Nerve Neuropathy

- Symptoms- anterolateral leg pain, dorsal foot pain and paresthesias
- Signs- pain/symptoms with palpation 8-10 cm above lat. malleolus over the nerve during active dorsiflexion; passive plantar flexion and inversion of ankle with or without nerve palpation
- Diagnostic injection above lateral malleolus can be helpful
- Etiologies- trauma, inversion ankle injuries, muscle herniation through fascial defect, post-op complication of fasciotomy for anterior CECS, etc.

Deep and Superficial Peroneal Nerve Neuropathy

- MRI may confirm entrapment
- Compartmental pressure measurements to rule out Chronic Exertional Compartment syndromes
- NCS/EMG usually **not helpful**
- Surgical decompression typically the most effective treatment, but success rate highly variable and many have persistent symptoms

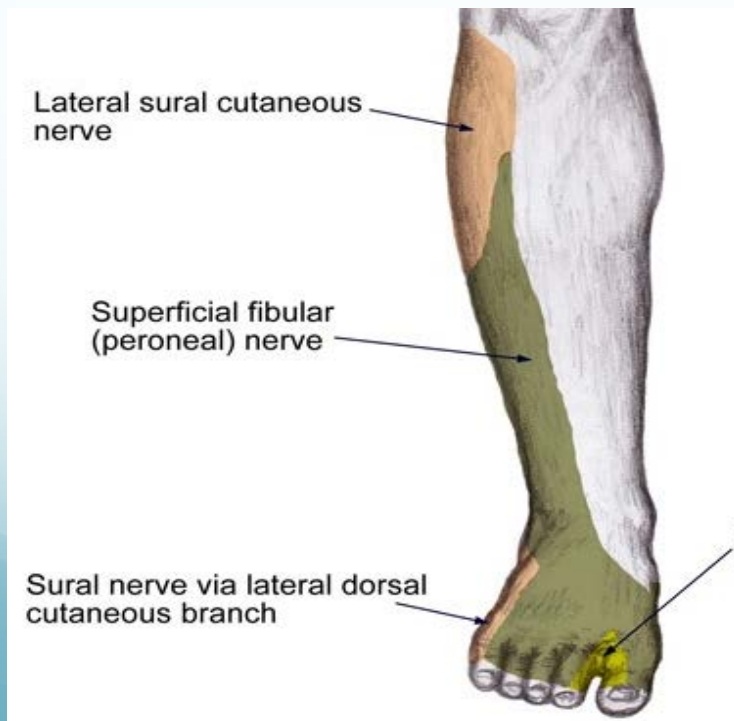
Superficial Peroneal Nerve Entrapment

SYMPTOMS

- Diffuse ache over sinus tarsi, dorsal foot
- Numbness/tingling in 1/3
- ? Proximal radiation

EXAM & TEST FINDINGS

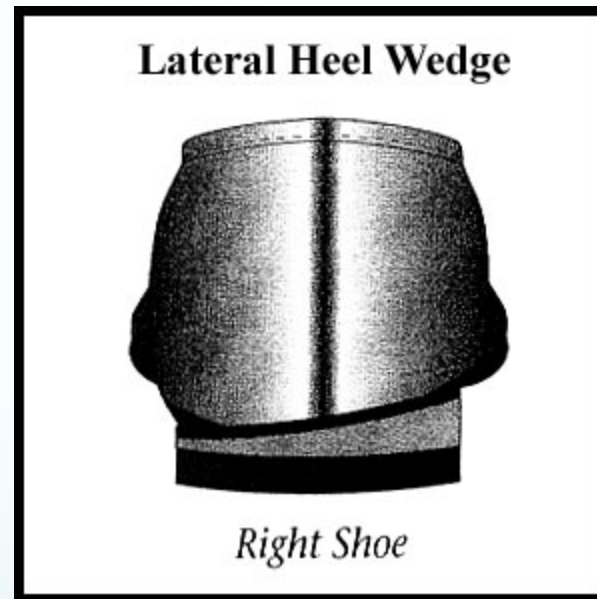
- Fascial defect in 60%
- ? Muscular herniation
 - 10-13 cm above LM
- Provocative maneuvers
 - pain over exit site during resisted ankle DF/Eversion
 - Pain over exit site during passive ankle PF/Inversion
- ? Hypoesthesia
- X-rays, EDT usually normal
- MRI useful for mass lesions



Superficial Peroneal Nerve Entrapment

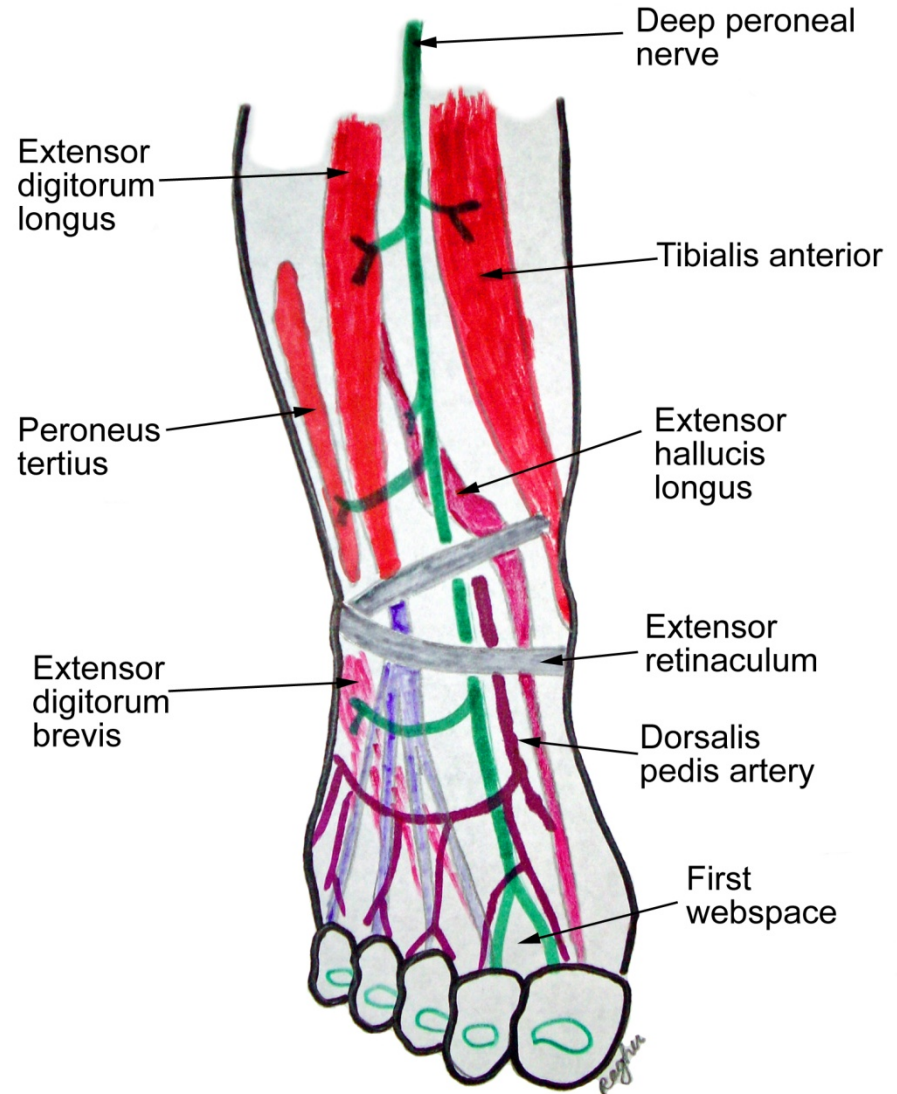
TREATMENT

- Similar to CPN entrapment
- Ankle stability rehab
- Injection at compression site
- Lateral wedge to decrease stretch
- Surgical decompression



Deep Peroneal Nerve Entrapment

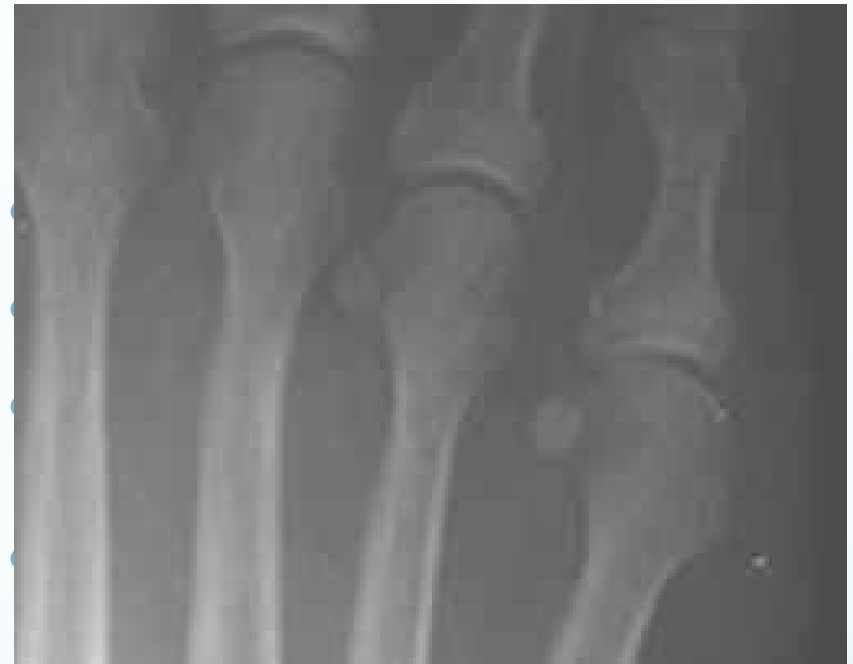- Arises from CPN at fibular head
- Traverses inside anterior compartment
 - Innervates TA, EHL, EDL
- Passes deep to Superior and Inferior Extensor Retinacula
 - Common sites of compression
- Follows DP artery
- Innervates EDB muscle
- Sensation to 1st webspace



Deep Peroneal Nerve Entrapment

SYMPTOMS

- Deep aching dorsal midfoot pain
- Worse w/ pressure from shoes
- Etiologies
 - Shoe pressure
 - Contusions
 - Osteophyte compression
 - Edema
 - Synovitis
 - Ganglia

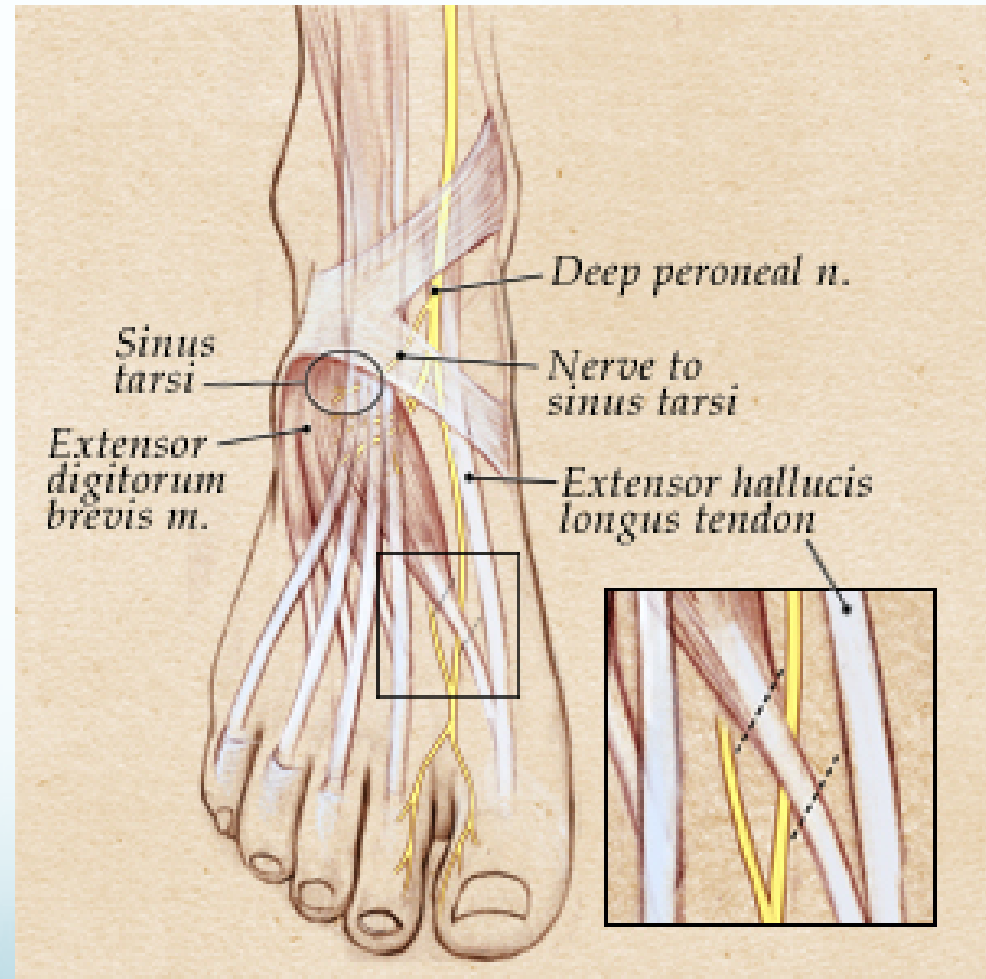


- Os intermetatarsale
- EDT may help localize
- MRI sometimes useful

Deep Peroneal Nerve Entrapment

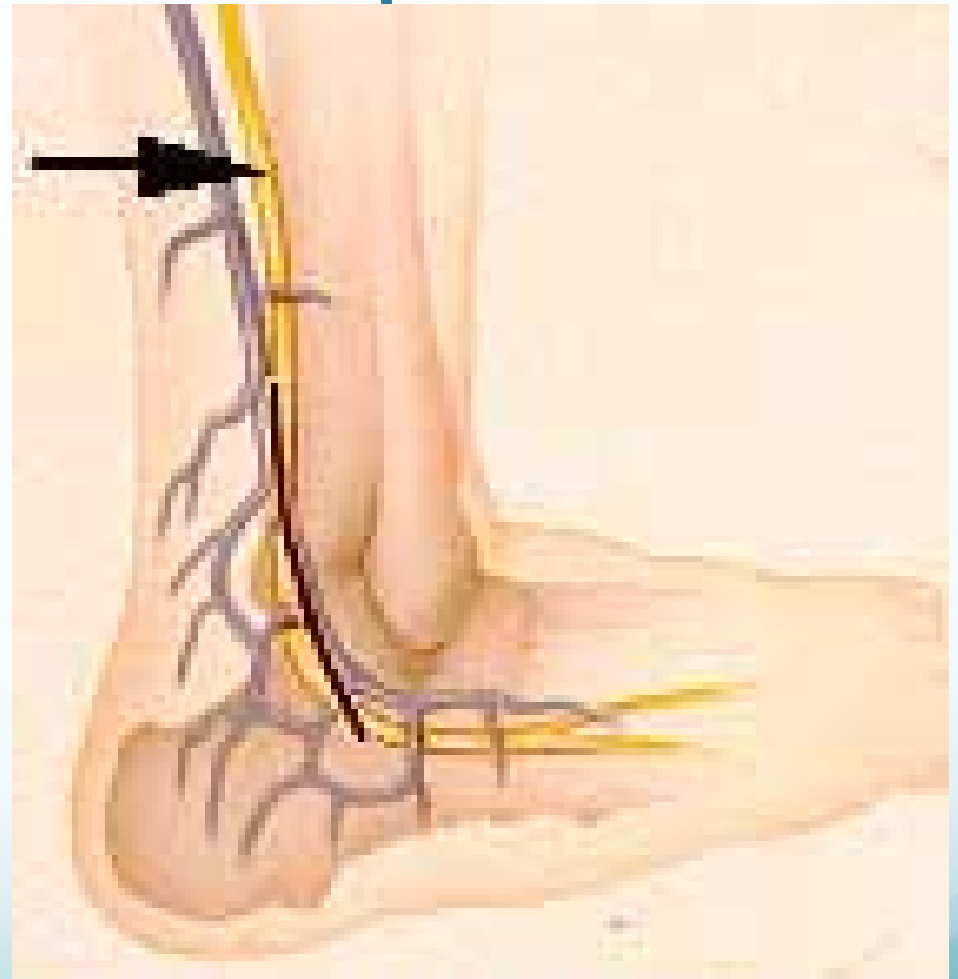TREATMENT

- Footwear changes
- Meds
- Edema control
- Ankle stability rehab
- Injection
- Surgical decompression



Sural Nerve Entrapment

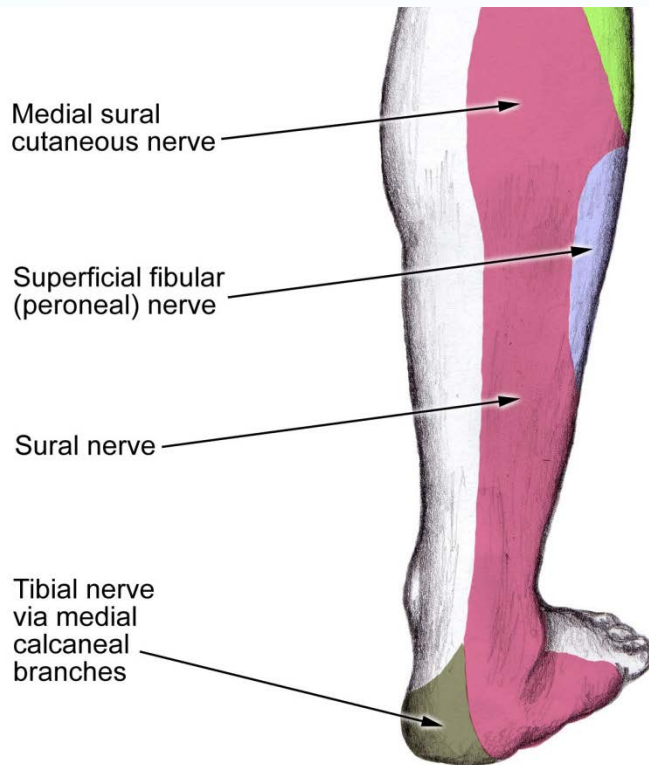
- Formed by branches of TN & CPN in posterior calf, 11-20 cm proximal to LM
- Purely sensory: distal posterolateral calf & lateral ankle and midfoot
- Etiologies
 - Recurrent ankle sprains
 - Fractured calcaneus, 5th MT
 - Achilles tendinopathy
 - Ganglia
 - Contusion
 - Footwear pressure



Sural Nerve Entrapment

SYMPTOMS

- Achy posterolateral calf pain
- Neuropathic pain in it distro



EXAM & TEST FINDINGS

- +Tinel's, hypesthesia
- Provocation by ankle DF or inversion
- Diagnostic injection
- Consider imaging, EDT

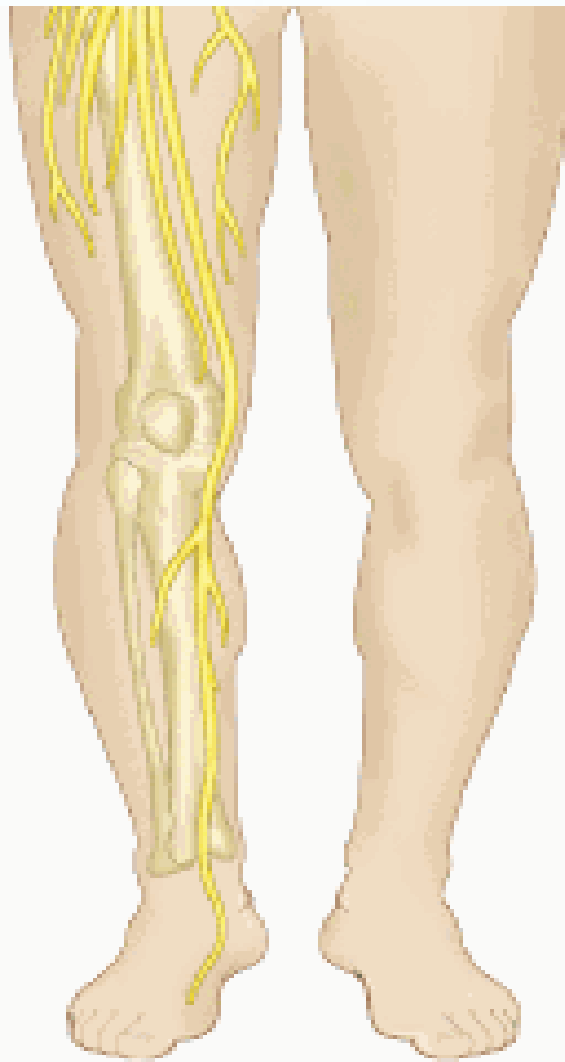Sural Nerve Entrapment

TREATMENT

- Reduce compression
- Achilles stretching
- Meds
- Edema control
- Ankle stability rehab
- Surgical

Saphenous Nerve Entrapment

- Purely sensory
 - Branch to medial knee
 - Medial calf
 - Branch anterior to MM to medial midfoot
- Most vulnerable at medial knee
- Etiologies
 - Adductor canal entrapment
 - Pes anserine bursitis
 - Contusion
 - Post-surgical injury



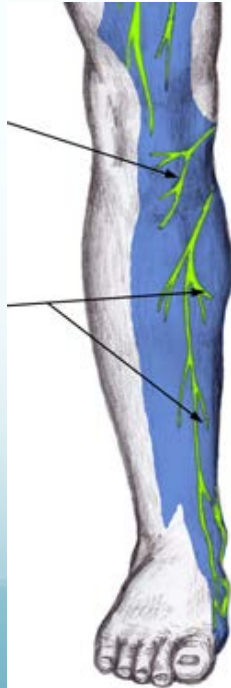Saphenous Neuropathy

- Sensation to the medial aspect of the leg distal to the medial femoral condyle and proximal medial side of the foot.
- Exits from the adductor canal (Hunter's canal), travels behind the sartorius muscle, and becomes subcutaneous between the tendons of the sartorius and gracilis.
- Injury to the nerve produces a sensory deficit or pain with minimal sensory deficit.
- May be localized to the distal tibia, mimicking medial tibial stress syndrome or stress fracture. Differential diagnosis includes partial femoral neuropathy or L4 radiculopathy.
- Few reports of sports-related saphenous nerve injuries: Surfers, runners

Saphenous Nerve Entrapment

SYMPTOMS

- Neuropathic pain medial knee, calf, midfoot
- No motor deficits



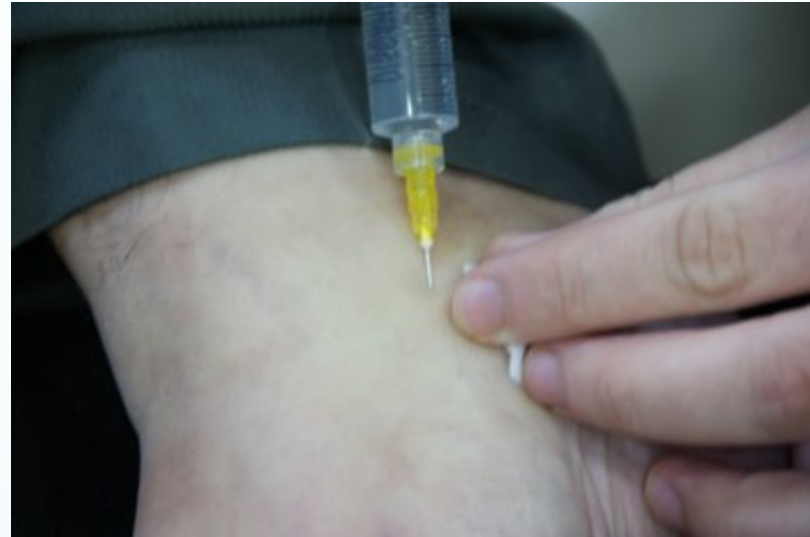EXAM & TEST FINDINGS

- ? Pes anserine bursitis, +Tinel's, hypoesthesia
- r/o femoral nerve lesions or L4 radiculopathy

Saphenous Nerve Entrapment

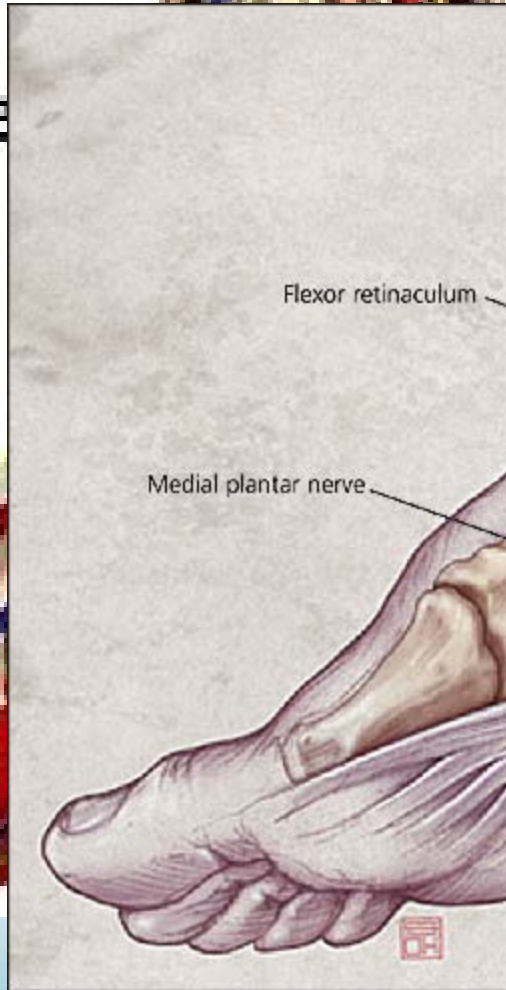
TREATMENT

- Address underlying causes
- Reduce compressions
- Therapeutic injection
- Surgical exploration & decompression

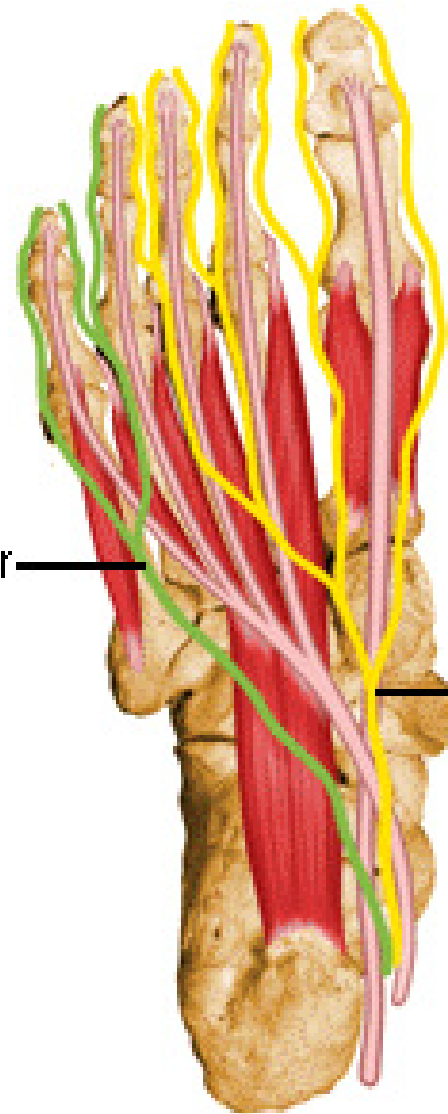


Nerve anatomy of foot

Figure

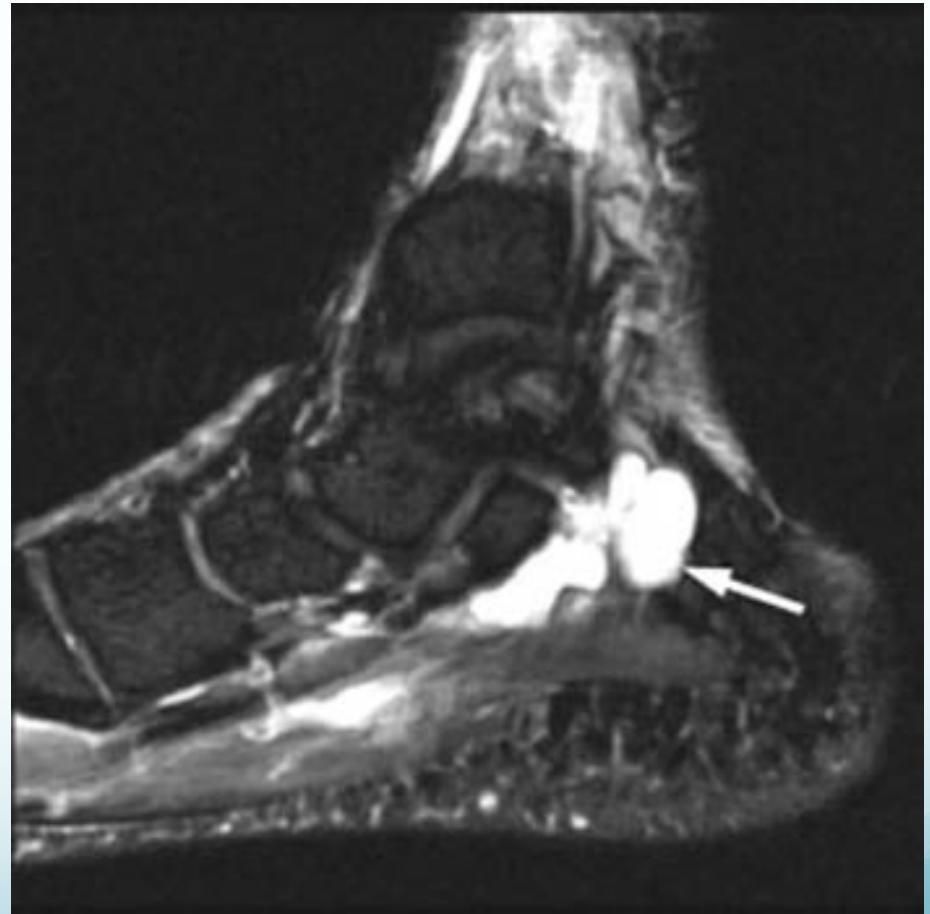


lateral plantar
nerve



Tibial Nerve Entrapment “Tarsal Tunnel Syndrome”

- 90%: TN divides within flexor retinaculum
 - Medial Plantar Nerve
 - Lateral Plantar Nerve
 - Medial Calcaneal Nerve
- Can involve TN, MPN, LPN, MCN; variable presentations
- Etiologies
 - Mass lesions (ganglia, tumors, venous stasis, tenosynovitis, os trigonum)
 - Trauma
 - Biomechanical compressions
 - hyperpronation
 - Systemic disease
 - Idiopathic



Tarsal Tunnel Syndrome

- Entrapment of posterior tibial nerve or its branches in the medial ankle or foot
- Branches include medial and lateral plantar nerves and the medial calcaneal nerve
- Etiologies- tumors, lipomas, ganglion cysts, trauma, fractures, edema, scar, valgus misalignment, poorly fitting footwear

Tarsal Tunnel Evaluation

- Symptoms- burning/aching heel, medial ankle and arch; often worse nocturnally; worse weight-bearing; paresthesias on plantar aspect of foot
- Signs- Tinel's over the tunnel, typical symptoms with heel eversion; standing on tiptoes may produce pain

Tarsal Tunnel Evaluation

- Plain xrays may reveal a structural lesion (healing fracture, spurs, etc.)
- MRI more helpful to identify structural lesions potentially causing compression
- NCS/EMG may be helpful, but often non-diagnostic

Tarsal Tunnel Treatment

- Rest, NSAIDs, corticosteroid injection
- Footwear adjustments, including a medial arch support
- Surgical release ~75% success rate

Tibial Nerve Entrapment

SYMPTOMS

- Neuropathic pain, tingling medial ankle, medial foot, and/or plantar foot
- 1/3 w/ Velleix phenomenon
- Hyperpronation: running on banked surfaces exacerbates

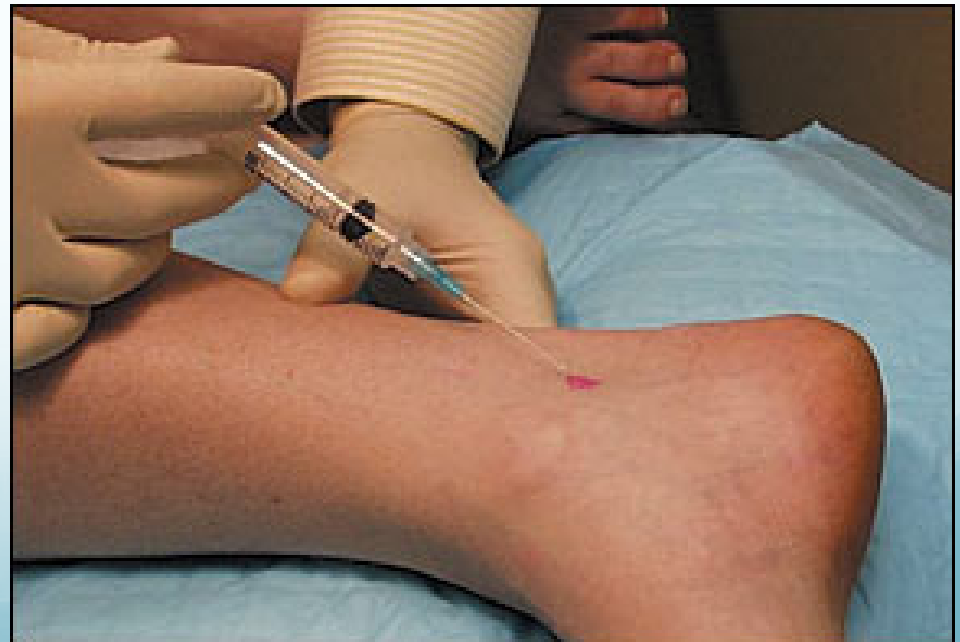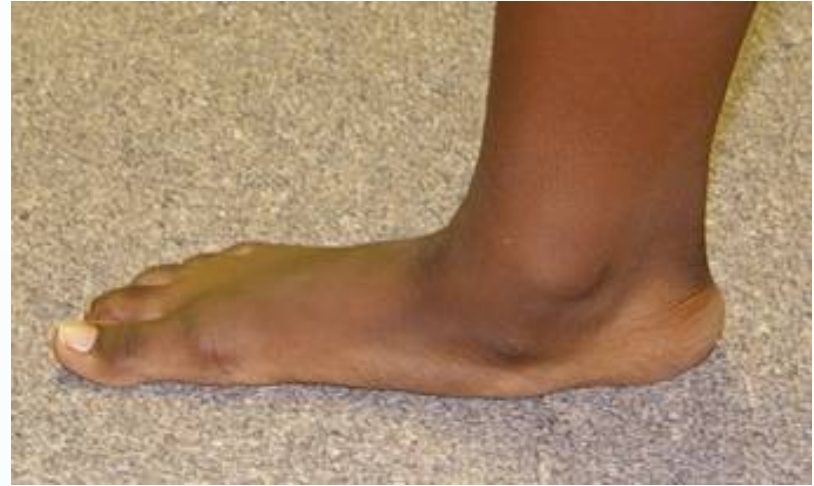EXAM & TEST FINDINGS

- Inspection for foot deformities
- Palpate TT for masses
- + Tinel's
- Provocation w/ passive foot eversion, great toe DF
- ? Weak toe flexion
- X-rays to r/o ossicles
- MRI for mass lesions
 - 88% of cases have lesions
 - Use in refractory cases
- ? Labs to r/o DM, thyroid dz, rheum dz, anemia
- EDT usually abnormal

Tibial Nerve Entrapment

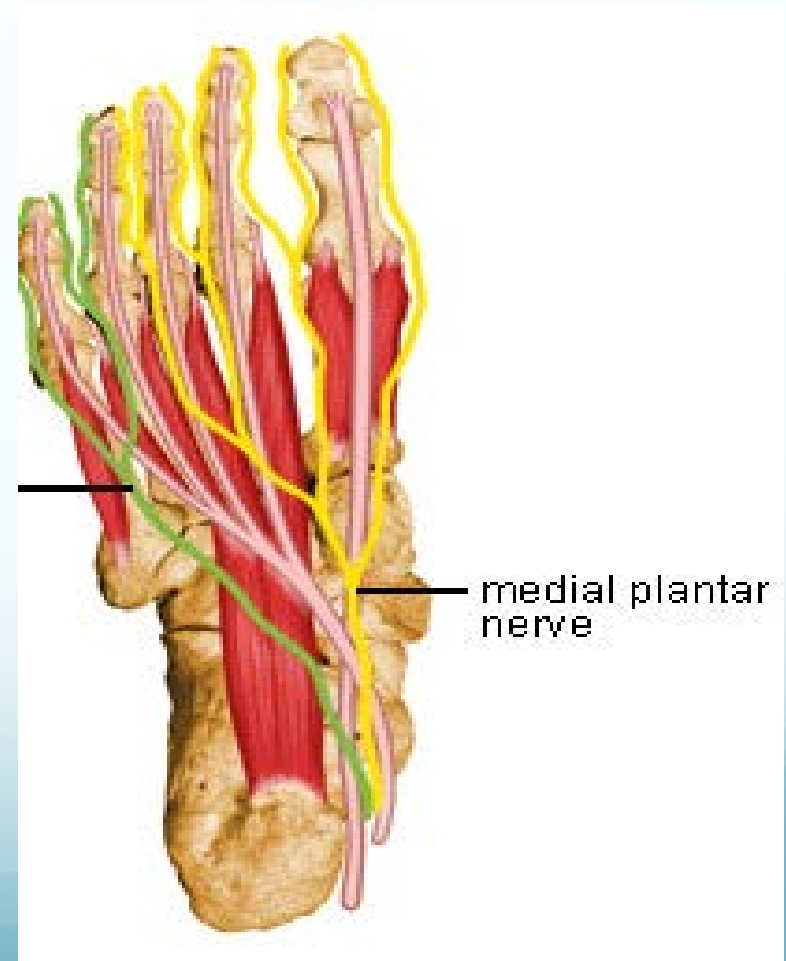
TREATMENT

- Activity modification
- Pronation control
- Intrinsic foot & medial arch, and ankle stability strength exercise
- Achilles stretching
- NSAIDs, meds
- Injection
- Surgical decompression



Medial Plantar Nerve Entrapment “Jogger’s Foot”

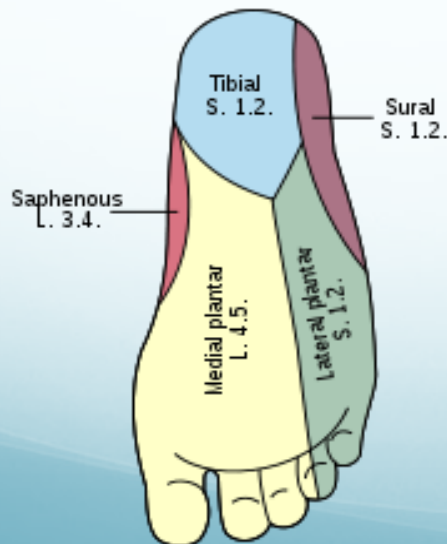
- Divides from TN
- Courses along FHL tendon
- Sensory medial sole & plantar toes 1-3 ½
- Motor: abductor hallucis, flexor hallucis brevis, FDB, 1st lumbrical
- Etiologies:
 - Footwear compression in the arch
 - Valgus running
 - Hyperpronation



Medial Plantar Nerve Entrapment

SYMPTOMS

- Neuropathic pain in medial arch and plantar aspect of 1-3rd toes
- Medial sole paresthesias



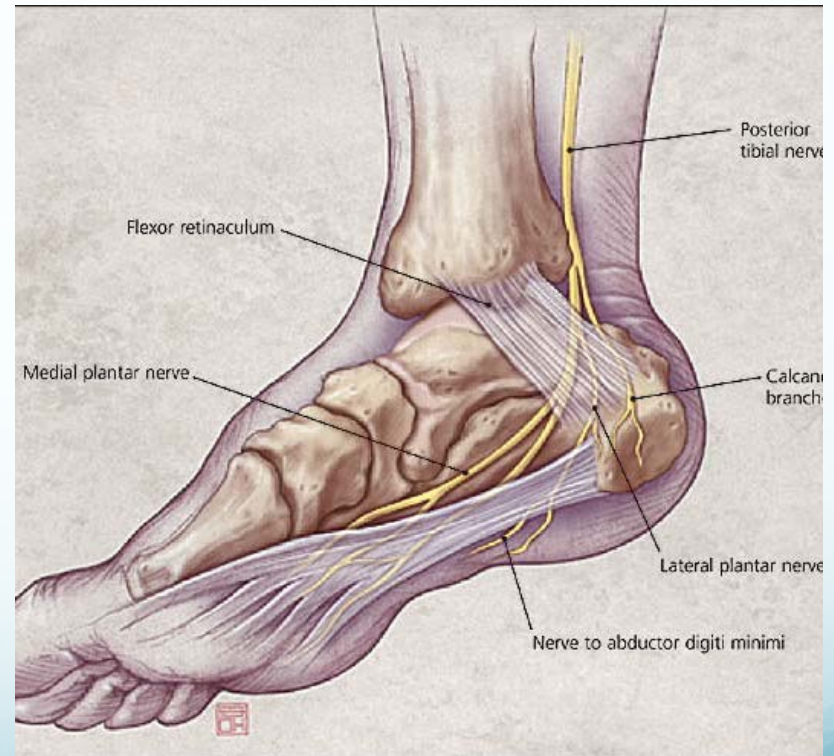
EXAM & TEST FINDINGS

- TTP at navicular tuberosity,
- + Tinel's
- Provocation w/ forced heel eversion
- ? AH hypertrophy
- Gait analysis: ? Valgus running
- Diagnostic nerve block?

Medial Plantar Nerve Entrapment

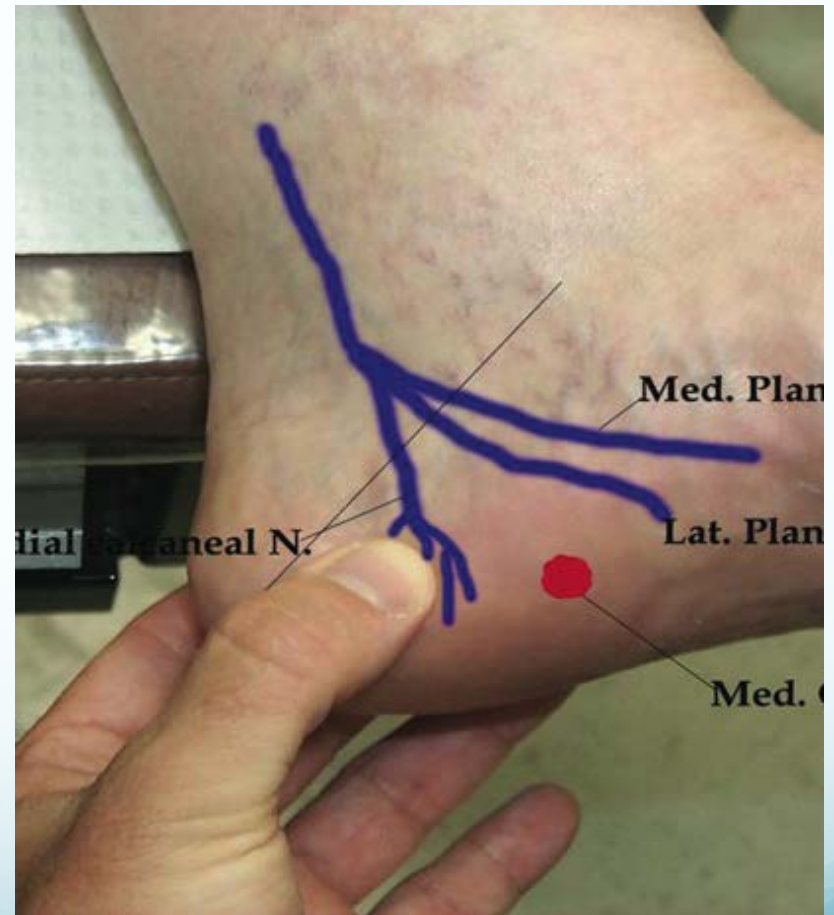
TREATMENT

- Pronation control
- Medial arch strength
- Reduce valgus running
- Modify footwear/orthotics to reduce compression
- Injection
- Surgical release



Medial Calcaneal Nerve Entrapment

- MCN pierces flexor retinaculum
- Sensation to posteromedial heel
- Etiologies
 - Hyperpronation
 - Footwear compression
 - Repetitive heel impact



Medial Calcaneal Nerve Entrapment

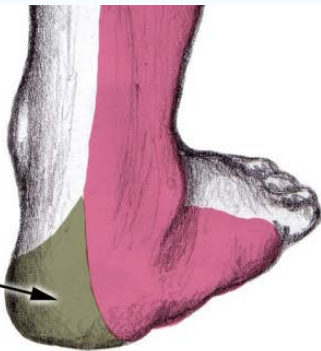SYMPTOMS

- Neuropathic pain medial heel
- Worse w/ activity

EXAM & TEST FINDINGS

- TTP, + Tinel's posterior to TN
- ? Tender, thickened nerve
 - “lamp cord sign”
- X-rays or bone scan to r/o calcaneal stress fractures

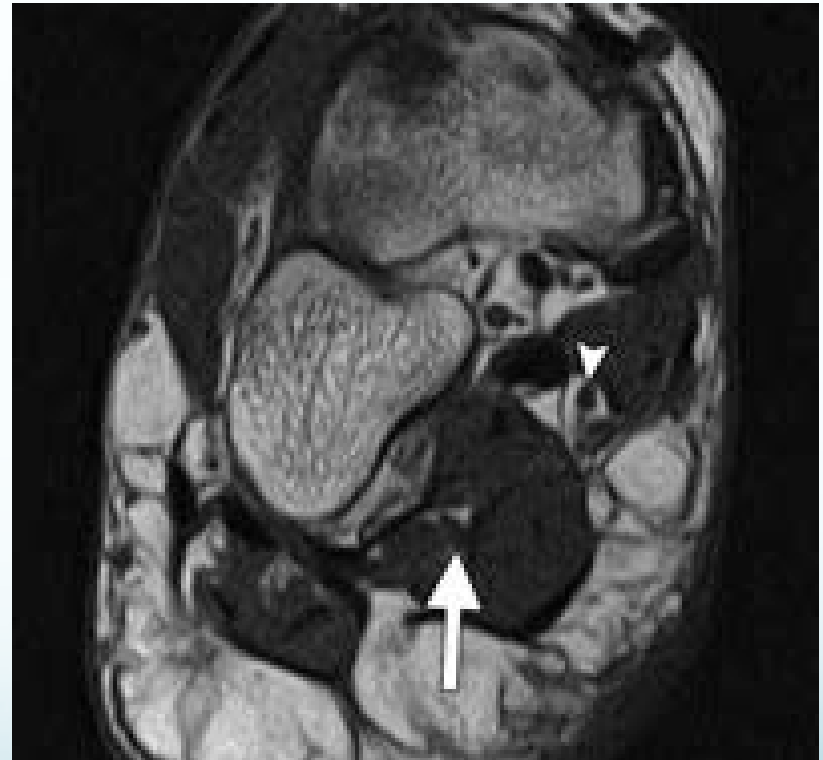Tibial nerve
via medial
calcaneal
branches



Medial Calcaneal Nerve Entrapment

TREATMENT

- Pronation control
- Cut-out pads
- Footwear modification
- Injection
- Lamp cord sign: surgical



Pearls From Experience

- These neuropathies often “see you” before you see them
- Have a high index of suspicion in patients that have seen multiple physicians without an improvement in symptoms
- REST is a 4-letter word, literally and figuratively, for athletes but can be curative in mild and early neuropathies


Pearls From Experience

- Restricting athletic involvement more imperative when weakness and atrophy are present, as opposed to sensory symptoms only
- Don't rely on imaging and nerve studies to make your diagnoses; the history and physical exam are still your best tools with neuropathies



Pearls From Experience

- Utilize post-exercise testing to improve the accuracy of your exam
- Consider a trial of Neurontin or Lyrica for chronic symptomatic relief



Pearls From Experience

- Corticosteroid injections must be carefully placed, but can be both ***diagnostic and therapeutic***
- Multiple injections not typically recommended



THANK YOU