

Phototherapeutic Keratectomy for Treatment of Corneal Diseases: Our Experience at King Hussein Medical Centre

Nancy K. Al Raqqad MD, Ahmed E. Khatatbeh MD*, Mohammad Y. Al-Hashki MD*, Hanadi I. Ismaiel RN**, Buthainah Gnaimat RN***

ABSTRACT

Objectives: To evaluate and present the results using phototherapeutic keratectomy for treatment of corneal diseases at King Hussein Medical centre.

Methods: This was a retrospective study conducted at the Laser Refractive Unit in King Hussein Medical centre between October 2011 and May 2013. All patients who were scheduled for phototherapeutic keratectomy for various corneal conditions were included in the study. Patients with any systemic disease that would affect epithelial healing such as diabetes or systemic lupus were excluded from the study. Data was collected including patient's age, gender, visual acuity, primary diagnosis, refraction, corneal thickness using Pentacam (Oculus, Wetzlar, Germany) and presence of any systemic disease. All patients were followed after one week of treatment. Bandage contact lens was removed and the cornea checked for epithelial healing and the patients were followed up for at least 6 months after treatment.

Results: One hundred and forty-six eyes of 146 patients with a mean age of 57 years (range 7 to 74 years) were enrolled in the study, 87 of them were males. The most common type of corneal pathology found was band keratopathy (37%) followed by old superficial corneal scars (22%), other pathologies found included: Salzmann nodules (12%), bullous keratopathy (9%), spheroidal degeneration (6%), keratoconus with nebula (6%), granular dystrophy (3%), Reis Buckler dystrophy (3%) and recurrent corneal erosions syndrome (3%). Ninety percent of patients experienced improvement in their vision. All patients showed satisfactory improvement in either visual acuity or symptoms of pain and discomfort in the immediate post operative period.

Conclusion: Phototherapeutic keratectomy is a safe and very effective procedure to be used for treatment of various surface corneal lesions.

Key words: Ablation, Corneal disease, Phototherapeutic keratectomy.

JRMS 2014 June 21(2): 49-54 /DOI: 10.12816/0004541

Introduction

Phototherapeutic keratectomy (PTK) has been widely used to treat a variety of conditions affecting the surface of the cornea. It has bridged

the gap between medical and surgical cornea.⁽¹⁾ It employs excimer laser 193nm wavelength to photoablate the corneal surface and break up bonds between molecules. With this, patients

From the Departments of:

*Ophthalmology, Laser Refractive Unit, King Hussein Medical Center, (KHMC), Amman-Jordan

** Nursing, (KHMC)

Correspondence should be addressed to Dr. N. Al Raqqad, (KHMC), E-mail: nrakkad@yahoo.com

Manuscript received

who suffer from decrease in vision due to corneal scars, dystrophies, band keratopathy, or pain and discomfort due to bullous keratopathy and recurrent corneal erosions can be treated to improve their vision or at least to alleviate their symptoms.

Indications for the use of phototherapeutic keratectomy include: band keratopathy, spheroidal degeneration, Salzmann nodular degeneration, recurrent corneal erosions syndrome, corneal dystrophies including granular, Reis buckler and Cogan's dystrophy, superficial corneal scars and keratoconus with nebulae.⁽¹⁾

Figure 1, spheroidal degeneration.

Controversy exists whether to treat post herpetic scars or not so as not to flare up the virus under the stress of the laser.⁽²⁾ Special attention should be paid to patients with hyperopic refraction that needed central treatments.^(1,3)

Patient selection was based on many factors. Criteria for selection included the size, site and depth of the lesion, thickness of the cornea, and the presence of any systemic disease that would affect epithelial healing such as diabetes or systemic lupus.^(1,2)

Complications of PTK include corneal haze especially if the ablation depth was large, corneal scars and infection. Some dystrophies as well as recurrent corneal erosions might recur after treatment.^(2,4)

This study was conducted to evaluate and present our results using phototherapeutic keratectomy for treatment of corneal disease at King Hussein Medical Centre.

Methods

Our retrospective study included all patients who were treated with excimer laser PTK for corneal disease at the Laser Refractive Unit, King Hussein Medical centre between October 2011 and May 2013. Data collected included age, gender, visual acuity, primary diagnosis, refraction, corneal thickness and presence of any systemic disease.

Preoperative refraction was performed to check for any refractive errors. Patients with post infectious corneal scars were also included in the treatment group as well as scars due to herpetic keratitis. Patients were monitored to confirm the absence of flare up for at least six months before

treatment. In addition to that patients also received oral acyclovir 400 mg twice daily one day prior to surgery and for 5 days.

Patients were either seen at or referred to the cornea clinic for improving their vision, alleviation of their irritative symptoms or clearing of the visual axis for further procedures such as cataract extraction.

Pentacam (Oculus, Wetzlar, Germany) corneal topography images were used to assess thickness of the cornea for each candidate. Depth of the lesion was also assessed using the Scheimpflug images technology.⁽²⁾

Exclusion criteria included the presence of any systemic disease that would interfere with wound healing such as diabetes and SLE. Pregnancy was also a contra-indication to treatment as the parameters of corneal thickness would not be as reliable.^(1,2,4)

Procedure

Our surgical technique was tailored according to each individual case but the general protocol was as follows. Every patient was examined at the slit lamp to rule out any co-existing infection. After informed consent had been obtained the patient was brought to the operating room and the eye to be operated on was marked and a drop of topical anesthesia was instilled. After prepping the patient's face with iodine and draping the marked eye properly a speculum was inserted to depart the eyelids and treatment was started.

Transepithelial PTK (NIDEK EC-5000, Co Ltd, Gamagori, Japan) was used in cases of sub-epithelial lesions and scars including granular dystrophy, Reis Buckler dystrophy, and band keratopathy and spheroidal degeneration. Treatment zone depended on the size and site of the lesion with an average of 7.00 mm zone for central lesions and a depth of 50 µm+ up to 30 µm to avoid hyperopic shift.^(3,5)

Stop and check technique was adopted and immediate smoothing of the corneal surface was noted during ablation.^(2,4)

Patients with recurrent corneal erosions syndrome, and bullous keratopathy underwent peeling of the epithelium using 30% alcohol for 15 seconds.⁽⁶⁻⁸⁾ Excimer laser was then applied for up to 10µm for recurrent corneal erosions and up to 80µm for bullous keratopathy. The eye tracker was activated for central lesions while

Table I: indications for phototherapeutic keratectomy.

Number of patients	Primary diagnosis
Band keratopathy	54 (37%)
Old superficial scars	32 (22%)
Salzmann nodules	18(12%)
Bullous keratopathy	13(9%)
Spheroidal degeneration	9(6%)
Keratoconus with nebula	8(6%)
Recurrent corneal erosions	4 (3%)
Granular dystrophy	4(3%)
Reis buckler dystrophy	4 (3%)

Table II: Improvement in BCVA in Snellen acuity testing after treatment

Primary diagnosis	Gain In BCVA				
	4 lines	3 lines	2 lines	1 line	No improvement
Band keratopathy	3 (5%)	32 (60%)	11 (20%)	8 (14%)	-
Old superficial scars	1 (3%)	21(65%)	5 (16%)	5 (16%)	-
Salzmann nodules	-	2 (11%)	13 (72%)	3 (17%)	-
Bullous keratopathy	-	-	-	5 (38%)	8 (62%)
Spheroidal degeneration	-	-	6 (67%)	2 (22%)	1 (11%)
Keratoconus with nebula	-	-	6 (75%)	2 (25%)	-
Recurrent corneal erosions	-	-	-	2 (50%)	2 (50%)
Granular dystrophy	-	-	2 (50%)	-	2 (50%)
Reis Buckler dystrophy	-	3 (75%)	-	1 (25%)	-

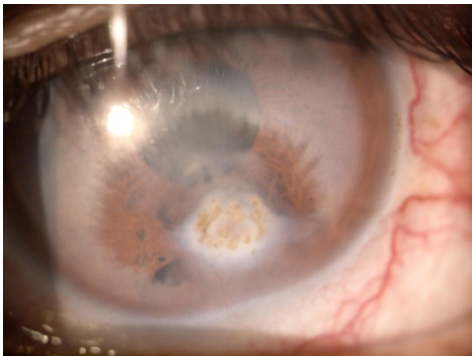


Fig. 1: Spheroidal degeneration

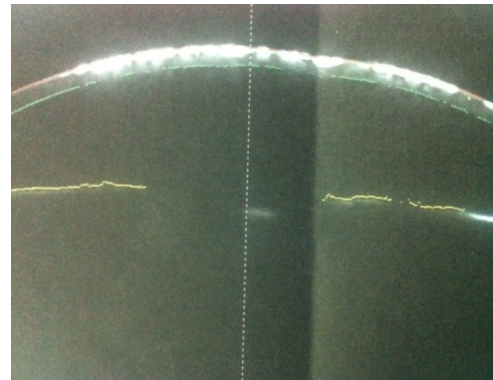


Fig. 2: Scheimpflug image showing the depth of the granular deposits within the cornea

manual guided ablation was used for peripheral lesions. We used masking agent only in cases of irregular surface and protruding lesions to mask the deeper normal tissue.⁽¹⁾ Bandage contact lens was inserted after each procedure. Topical fluoroquinolones drops were instilled at the end.

Our aftercare regime included hourly fluoroquinolone drops and a non-steroidal anti-inflammatory drops four times daily for the first week to prevent infection and for pain relief, respectively. After one week the bandage contact lens was removed, epithelial healing was checked and topical steroids drops at 6 hourly were started to decrease haze and inflammation. Frequent

lubrication with 2-hourly artificial tears was used for the first month.

Results

One hundred and forty-six patients with a mean age of 57 years (range 7 to 74 years) were enrolled in the study, 87 of them were males. The most common indication for PTK among our sample was band keratopathy (37%) followed by old superficial corneal scars (22%), Table I.

Ninety-two percent of the sample patients showed improvement in BCVA with mean improvement of 2 lines on Snellen acuity testing, Table II.

The remaining 11 patients who did not show improvement in their BCVA were scheduled for PTK for non visual indications. These included 8 patients with bullous keratopathy, two patients with recurrent corneal erosions, and one patient with spheroidal degeneration. We were able to create a window in 4 patients (3%) two of which had deep stromal scars and the other two with band keratopathy were originally scheduled for PTK for clearing the media for a better visualization during a future cataract surgery.⁽⁹⁾

Postoperative refraction was done three months post PTK and the hyperopic shift ranged from zero diopter for patients with superficial ablation (10 µm) to a +1.50 D shift for those with deeper ablation (>85µm).

In our sample we encountered only one case of corneal haze in a patient who had band keratopathy and received laser ablation up to 100µm. Haze started to appear in the third week after treatment causing a decrease in BCVA from 6/12 post operatively to 6/24. We used a strong topical steroid four times daily for a week that was reduced to twice daily for another week. BCVA improved to 6/9 one month after treatment.

We had a 7 years old girl who had granular dystrophy and was referred to the cornea clinic for penetrating keratoplasty. Her visual acuity in the right eye was 6/24 and 6/18 in the left eye. The lesion was 175µm deep and her central corneal thickness was 473µm. We performed PTK up to 80µm within 7mm ablation zone. There was an immediate reduction in the density of the lesion. Her post operative BCVA was 6/12 after two weeks of treatment, Fig. 2.

Follow up period of all patients ranged between 3 and 12 months with an average of 4 months. All patients were seen the first week then first month after treatment. Visits then were spaced every three months for a year, unless more frequent visits were necessary.

Discussion

Recent advances in the use of excimer laser in ophthalmology have enabled us to treat a wide range of corneal diseases. Being the transparent window of the eye with a total thickness of only 0.5mm minimal procedures performed on the surface of the cornea can result in great improvements in the patients' quality of life, be it

on the level of visual acuity or comfort and decrease of pain symptoms.

The laser refractive unit at King Hussein Medical Centre provides eye care for a large number of patients across the country and abroad from neighboring countries. In our 146 study sample the most common indication for PTK was band keratopathy (37%) followed by old superficial scars (22%). Those patients represented a large proportion of our study sample and showed the most noticeable improvement in BCVA. PTK has offered them fast relief and improved vision as compared to the older methods of treatment.

Our results supported Rapuano *et al*⁽²⁾ published results, and patients who benefited best from PTK were those with superficial lesions in the anterior one fifth of the cornea. Patients with band keratopathy, old superficial scars, and Reis Buckler dystrophy showed the most significant improvement in BCVA with 66% of patients achieving mean gain of 3 lines on Snellen acuity in those groups.

Post herpetic keratitis scars have been subject of debate whether to treat or not and when to treat because of the risk of recurrence after PTK.^(1,10) Starr *et al* reported reactivation of herpetic keratitis in their patients few months after PTK.⁽³⁾ In our sample we did not encounter any flare up in six (4%) of the patients who had post herpetic keratitis scars and were followed for up to one year.

One of the most important factors to be considered in performing PTK is the refractive outcome. Excimer laser flattens the central cornea inducing a hyperopic shift.^(5,10) Myopia can also result when the ablation targets the peripheral cornea. It is wise to use a large ablation zone to decrease the effect of laser on the refractive outcome. The minimal corneal thickness in our patients was 400 µm. We used Pentacam (Oculus, Wetzlar, Germany) pachymetry as an indicator of how much tissue can be ablated without endangering the corneal bed especially in deep lesions. Knowing that the cornea doesn't have to be very clear in order to achieve good vision,^(1,2) ablating up to 90% of the opacity would result in great improvement in vision with preserving of corneal tissue and decreasing the amount of refractive error induced.⁽⁵⁾ In our sample we avoided large

ablations and focused on clearing the visual axis and decreasing the density of the opacity without compromising the corneal thickness or corneal parameters. Thus, none of the eyes developed corneal thinning and the refractive outcome was acceptable ranging between 0.0D to +1.50D.

PTK has provided instant solutions for demanding patients, as in the case of the young girl with granular dystrophy. The best option for that girl at that time was an anterior lamellar therapeutic keratoplasty (ALTK), as this would take out the whole diseased part of the cornea with less risk of rejection because the innermost layers will be preserved. While we waited for the special instruments to perform such a procedure PTK provided rapid improvement in BCVA in two lines and allowed more time until a more permanent treatment option is provided.

The use of alcohol for epithelial debridement has been linked to better epithelial healing, first described with LASEK then used with PRK and now PTK.^(6,7) Although it was easy to peel the epithelium in cases of bullous keratopathy and recurrent corneal erosions due to the fragile attachments of the diseased epithelium, using an alcohol well 30% for 15 seconds resulted in a smoother plane to work on.^(8,11,12)

We used methylcellulose as a masking agent in elevated lesions. As described by Rapuano and Rashed *et al*,^(2,10) it works by smoothing the surface around the elevated lesion and aids in preserving corneal tissue.⁽¹⁾ Patients with Salzmann nodular degeneration and keratoconus with a nebula underwent epithelial debridement of around 1-2 mm around the lesion, application of methylcellulose around it and shaving it down with the laser. Contact lens fitting and thus BCVA achieved by contact lens greatly improved for patients with keratoconus (3%). The majority of patients (83%) with Salzmann nodules enjoyed relief of discomfort and gained more than one line on Snellen's chart.

Patients who received PTK for non visual indications such as recurrent corneal erosions and bullous keratopathy benefited from reduction in pain and discomfort.⁽¹²⁾ The laser ablates the nerve endings within the stroma in cases of bullous keratopathy,⁽¹²⁾ and allows formation of firm attachments between the epithelium and stroma in cases of recurrent erosions.^(2,6,7) Only

one patient (0.6%) with recurrent corneal erosion needed re-treatment after two months.

Although there were few limitations in this study in the form of the age of the patients, their cooperation with post operative treatment and follow up, and the lack of anterior chamber OCT to assess the depth of the corneal lesions accurately. This study showed significant improvement in vision among most patients (90%) and effectiveness of PTK as a therapeutic tool for non visual and irritative complaints.

Conclusion

Phototherapeutic keratectomy is a safe and very effective procedure to treat various corneal lesions. It can replace a more invasive ophthalmic procedure and delay the need for further surgical intervention.

References

1. **Rathi VM, Vyas SP, Sangwan VS.** Phototherapeutic keratectomy. *Indian J Ophthalmol* 2012; 60(1): 5–14.
2. **Rapuano CJ.** Excimer laser phototherapeutic keratectomy. *Curr Opin Ophthalmol* 2001;12:288–293
3. **Starr M, Donnenfeld E, Newton M, et al.** Excimer laser phototherapeutic keratectomy. *Cornea* 1996;15:557-565.
4. **Fagerholm P.** Phototherapeutic keratectomy: 12 years of experience. *Acta Ophthalmol Scand* 2003;81:19-32.
5. **Amm M, Duncker GI.** Refractive changes after phototherapeutic keratectomy. *J Cataract Refract Surg* 1997; 23:839-844.
6. **Dua HS, Lagnado R, Raj D.** Alcohol delamination of the corneal epithelium: an alternative in the management of recurrent corneal erosions. *Ophthalmology* 2006; 113(3): 404–411.
7. **Shah S, Browning AC, Dua HS.** Alcohol delamination of the corneal epithelial basement membrane in the human eye for photorefractive keratectomy (ARVO abstract). *Invest Ophthalmol Vis Sci* 2000; 41(4): S681 Abstract nr 3623.
8. **Browning AC, Shah S, Dua HS, et al.** Alcohol Debridement of the Corneal Epithelium in PRK and LASEK: An Electron Microscopic Study. *Invest Ophthalmol Vis Sci* 2003 44(2): 510-513
9. **Salah T, El Maghraby A, Waring G.** Excimer laser phototherapeutic keratectomy before cataract extraction and intraocular lens implantation. *Am J Ophthalmol* 1996; 122:340-348.
10. **Rashad MA.** Pentacam-based phototherapeutic keratectomy outcome in superficial corneal opacities. *Clin Ophthalmol* 2012; 6: 885-894.

11. **Thomann U, Meier-Gibbons F, Schipper I.** Phototherapeutic keratectomy for bullous keratopathy. *Br J Ophthalmol* 1995; 79:335-338.

12. **Rosa N, Cennamo G.** Phototherapeutic keratectomy for relief of pain in patients with pseudophakic corneal edema. *J Refract Surg* 2002; 18:276-279.