

Physical Exam Study Guides

- [Vital Signs](#)
- [Head and Neck Exam](#)
- [Eye Exam](#)
- [Chest and Lung Exam](#)
- [Cardiovascular Exam](#)
- [Abdominal Exam](#)
- [Back and Extremity Exam](#)
- [Neurologic Exam](#)

Vital Signs

- [Equipment Needed](#)
 - [General Considerations](#)
 - [Temperature](#)
 - [Respiration](#)
 - [Pulse](#)
 - [Interpretation](#)
 - [Blood Pressure](#)
 - [Interpretation](#)
 - [Notes](#)
-

Equipment Needed

- A Stethoscope
- A Blood Pressure Cuff
- A Watch Displaying Seconds
- A Thermometer

General Considerations

- The patient should **not** have had alcohol, tobacco, caffeine, or performed vigorous exercise within 30 minutes of the exam.
- Ideally the patient should be sitting with feet on the floor and their back supported. The examination room should be quiet and the patient comfortable.
- History of hypertension, slow or rapid pulse, and current medications should always be obtained.

Temperature

Temperature can be measured in several different ways:

- **Oral** with a glass, paper, or electronic thermometer (normal 98.6F/37C) [[1](#)]
- **Axillary** with a glass or electronic thermometer (normal 97.6F/36.3C)
- **Rectal** or "core" with a glass or electronic thermometer (normal 99.6F/37.7C)
- **Aural** (the ear) with an electronic thermometer (normal 99.6F/37.7C)

Of these, axillary is the least and rectal is the most accurate.

Respiration

1. Best done immediately after taking the patient's pulse. Do **not** announce that you are measuring respirations. [p129, p237] [[2](#)]
2. Without letting go of the patient's wrist begin to observe the patient's breathing. Is it normal or labored?
3. Count breaths for 15 seconds and multiply this number by 4 to yield the breaths per minute.

4. In adults, normal resting respiratory rate is between 14-20 breaths/minute. Rapid respiration is called tachypnea.

Pulse

1. Sit or stand facing your patient.
2. Grasp the patient's wrist with your free (non-watch bearing) hand (patient's right with your right or patient's left with your left). There is no reason for the patient's arm to be in an awkward position, just imagine you're shaking hands.
3. Compress the radial artery with your index and middle fingers.
4. Note whether the pulse is regular or irregular:
 - **Regular** - evenly spaced beats, may vary slightly with respiration
 - **Regularly Irregular** - regular pattern overall with "skipped" beats
 - **Irregularly Irregular** - chaotic, no real pattern, very difficult to measure rate accurately
5. Count the pulse for 15 seconds and multiply by 4.
6. Count for a full minute if the pulse is irregular. [3]
7. Record the rate and rhythm.

Interpretation

- A normal adult heart rate is between 60 and 100 beats per minute ([see below for children](#)).
- A pulse greater than 100 beats/minute is defined to be tachycardia. Pulse less than 60 beats/minute is defined to be bradycardia. Tachycardia and bradycardia are not necessarily abnormal. Athletes tend to be bradycardic at rest (superior conditioning). Tachycardia is a normal response to stress or exercise.

Blood Pressure

1. Position the patient's arm so the antecubital fold is level with the heart. Support the patient's arm with your arm or a bedside table.
2. Center the bladder of the cuff over the brachial artery approximately 2 cm above the antecubital fold. **Proper cuff size is essential** to obtain an accurate reading. Be sure the index line falls between the size marks when you apply the cuff. Position the patient's arm so it is slightly flexed at the elbow. [4]
3. Palpate the radial pulse and inflate the cuff until the pulse disappears. This is a rough estimate of the systolic pressure. [5]
4. Place the stethoscope over the brachial artery. [6]
5. Inflate the cuff to 30 mmHg above the estimated systolic pressure.
6. Release the pressure slowly, no greater than 5 mmHg per second.
7. The level at which you consistently hear beats is the systolic pressure. [7]
8. Continue to lower the pressure until the sounds muffle and disappear. This is the diastolic pressure. [8]
9. Record the blood pressure as systolic over diastolic ("120/70" for example).

Interpretation

- Higher blood pressures are normal during exertion or other stress. Systolic blood pressures below 80 may be a sign of serious illness or shock.
- Blood pressure should be taken in both arms on the first encounter. If there is more than 10 mmHg difference between the two arms, use the arm with the higher reading for subsequent measurements.
- It is frequently helpful to retake the blood pressure near the end of the visit. Earlier pressures may

be higher due to the "white coat" effect.

- Always recheck "unexpected" blood pressures yourself.

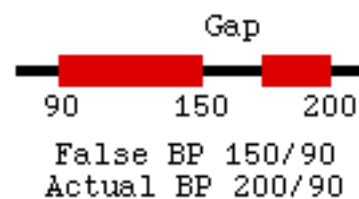
Blood Pressure Classification in Adults		
Category	Systolic	Diastolic
Normal	<140	<90
Isolated Systolic Hypertension	>140	<90
Mild Hypertension	140-159	90-99
Moderate Hypertension	160-179	100-109
Severe Hypertension	180-209	110-119
Crisis Hypertension	>210	>120

- In children, pulse and blood pressure vary with the age. The following table should serve as a rough guide:

Average Pulse and Blood Pressure in Normal Children							
Age	Birth	6mo	1yr	2yr	6yr	8yr	10yr
Pulse	140	130	115	110	103	100	95
Systolic BP	70	90	90	92	95	100	105

Notes

1. For more information refer to *A Guide to Physical Examination and History Taking, Sixth Edition* by Barbara Bates, published by Lippincott in 1995.
2. Unlike pulse, respirations are very much under voluntary control. If you tell the patient you are counting their breaths, they may change their breathing pattern. You cannot tell someone to "breathe normally," normal breathing is involuntary.
3. With an irregular pulse, the beats counted in any 15 second period may not represent the overall rate. The longer you measure, the more these variations are averaged out.
4. **Do not rely** on pressures obtained using a cuff that is too small or too large. This is frequently a problem with obese or muscular adults where the regular cuff is too small. The pressure recorded will most often be 10, 20, even 50 mmHg too high! Finding a large cuff may be inconvenient, but you will also "cure" a lot of high blood pressure.
5. Maximum Cuff Pressure - When the baseline blood pressure is already known or hypertension is not suspected, it is acceptable in adults to inflate the cuff to 200 mmHg and go directly to auscultating the blood pressure. Be aware that there could be an **auscultatory gap** (a silent interval between the true systolic and diastolic pressures).



6. Bell or Diaphragm? - Even though the Korotkoff sounds are low frequency and should be heard better with the bell, it is often difficult to apply the bell properly in the antecubital fold. For this reason, it is common practice to use the diaphragm when taking blood pressure.
7. Systolic Pressure - In situations where auscultation is not possible, you can determine systolic blood pressure by palpation alone. Deflate the cuff until you feel the radial or brachial pulse return. The pressure by auscultation would be approximately 10 mmHg higher. Record the pressure indicating it was taken by palpation (60/palp).
8. Diastolic Pressure - If there is more than 10 mmHg difference between the muffling and the

disappearance of the sounds, record all three numbers (120/80/45).

Examination of the Head and Neck

- [Equipment Needed](#)
 - [General Considerations](#)
 - [Head](#)
 - [Ears](#)
 - [Nose](#)
 - [Throat](#)
 - [Neck](#)
 - [Lymph Nodes](#)
 - [Thyroid Gland](#)
 - [Special Tests](#)
 - [Facial Tenderness](#)
 - [Sinus Transillumination](#)
 - [Temporomandibular Joint](#)
 - [Notes](#)
-

NOTE: Neurologic testing of the head and neck is covered by the [neurologic exam study guide](#). The eyes are covered by the [eye exam study guide](#).

Equipment Needed

- An Otoscope
- Tongue Blades
- Cotton Tipped Applicators
- Latex Gloves

General Considerations

The head and neck exam is not a single, fixed sequence. Different portions are included depending on the examiner and the situation.

Head

1. Look for scars, lumps, rashes, hair loss, or other lesions. [1]
2. Look for facial asymmetry, involuntary movements, or edema.
3. Palpate to identify any areas of tenderness or deformity.

Ears

1. Inspect the auricles and move them around gently. Ask the patient if this is painful.
2. Palpate the mastoid process for tenderness or deformity.
3. Hold the otoscope with your thumb and fingers so that the ulnar aspect of your hand makes contact with the patient.

4. Pull the ear upwards and backwards to straighten the canal.
5. Insert the otoscope to a point just beyond the protective hairs in the ear canal. Use the largest speculum that will fit comfortably. [2]
6. Inspect the ear canal and middle ear structures noting any redness, drainage, or deformity.
7. Insufflate the ear and watch for movement of the tympanic membrane. [3] ++ [4]
8. Repeat for the other ear.

Nose

It is often convenient to examine the nose immediately after the ears using the same speculum.

1. Tilt the patient's head back slightly. Ask them to hold their breath for the next few seconds.
2. Insert the otoscope into the nostril, avoiding contact with the septum.
3. Inspect the visible nasal structures and note any swelling, redness, drainage, or deformity.
4. Repeat for the other side.

Throat

It is often convenient to examine the throat using the otoscope with the speculum removed.

1. Ask the patient to open their mouth.
2. Using a wooden tongue blade and a good light source, inspect the inside of the patients mouth including the buccal folds and under the tongue. Note any ulcers, white patches (leucoplakia), or other lesions.
3. If abnormalities are discovered, use a gloved finger to palpate the anterior structures and floor of the mouth. ++
4. Inspect the posterior oropharynx by depressing the tongue and asking the patient to say "Ah." Note any tonsillar enlargement, redness, or discharge.

Neck

1. Inspect the neck for asymmetry, scars, or other lesions.
2. Palpate the neck to detect areas of tenderness, deformity, or masses.
3. The [musculoskeletal exam of the neck](#) is covered elsewhere...

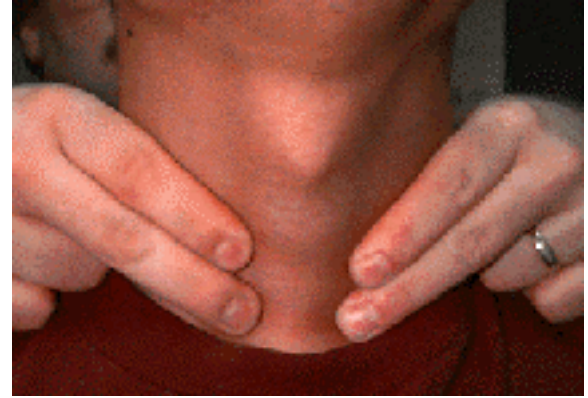Lymph Nodes

1. Systematically palpate with the pads of your index and middle fingers for the various lymph node groups.
 1. Preauricular - In front of the ear
 2. Postauricular - Behind the ear
 3. Occipital - At the base of the skull
 4. Tonsillar - At the angle of the jaw
 5. Submandibular - Under the jaw on the side
 6. Submental - Under the jaw in the midline
 7. Superficial (Anterior) Cervical - Over and in front of the sternomastoid muscle
 8. Supraclavicular - In the angle of the sternomastoid and the clavicle
2. The **deep cervical** chain of lymph nodes lies below the sternomastoid and cannot be palpated without getting underneath the muscle:
 1. Inform the patient that this procedure will cause some discomfort.
 2. Hook your fingers under the anterior edge of the sternomastoid muscle.
 3. Ask the patient to bend their neck **toward** the side you are examining.

4. Move the muscle backward and palpate for the deep nodes underneath.
3. Note the size and location of any palpable nodes and whether they were soft or hard, non-tender or tender, and mobile or fixed.

Thyroid Gland

1. Inspect the neck looking for the thyroid gland. Note whether it is visible and symmetrical. A visibly enlarged thyroid gland is called a **goiter**.
2. Move to a position behind the patient.
3. Identify the **cricoid cartilage** with the fingers of both hands.
4. Move downward two or three tracheal rings while palpating for the isthmus.
5. Move laterally from the midline while palpating for the lobes of the thyroid.
6. Note the size, symmetry, and position of the lobes, as well as the presence of any nodules. The normal gland is often not palpable.



Special Tests

Facial Tenderness

1. Ask the patient to tell you if these maneuvers causes excessive discomfort or pain. ++
2. Press upward under both eyebrows with your thumbs.
3. Press upward under both maxilla with your thumbs.
4. Excessive discomfort on one side or significant pain suggests sinusitis.

Sinus Transillumination

1. Darken the room as much as possible. ++
2. Place a bright otoscope or other point light source on the maxilla.
3. Ask the patient to open their mouth and look for an orange glow on the hard palate.
4. A decreased or absent glow suggests that the sinus is filled with something other than air.

Temporomandibular Joint

1. Place the tips of your index fingers directly in front of the tragus of each ear. ++
2. Ask the patient to open and close their mouth.
3. Note any decreased range of motion, tenderness, or swelling.

Notes

1. Page numbers refer to Barbara Bates' *A Guide to Physical Examination and History Taking, Sixth Edition*, published by Lippincott in 1995.
2. The line of hairs in the external ear is a good approximation of where the bony canal begins. Inserting the speculum beyond this point can be very painful.
3. Insufflation means to change the pressure in the outer ear. The tympanic membrane normally moves easily in response to this pressure change. Lack of movement is a sign of negative pressure or fluid in the middle ear. Bates refers to this procedure as pneumatic otoscopy.

4. Additional Testing - Tests marked with (++) may be skipped unless an abnormality is suspected.

Examination of the Eye

- [Equipment Needed](#)
 - [Visual Acuity](#)
 - [Inspection](#)
 - [Visual Fields](#)
 - [Extraocular Muscles](#)
 - [Corneal Reflections](#)
 - [Extraocular Movement](#)
 - [Pupillary Reactions](#)
 - [Light](#)
 - [Accommodation](#)
 - [Ophthalmoscopic Exam](#)
 - [Special Tests](#)
 - [Upper Eyelid Eversion](#)
 - [Notes](#)
-

Equipment Needed

- A Snellen Eye Chart or Pocket Vision Card
- An Ophthalmoscope

Visual Acuity

In cases of eye pain, injury, or visual loss, always check visual acuity **before** proceeding with the rest of the exam or putting medications in your patients eyes.

1. Allow the patient to use their glasses or contact lens if available. You are interested in the patient's best **corrected** vision.
2. Position the patient 20 feet in front of the Snellen eye chart (or hold a Rosenbaum pocket card at a 14 inch "reading" distance).
3. Have the patient cover one eye at a time with a card.
4. Ask the patient to read progressively smaller letters until they can go no further.
5. Record the smallest line the patient read successfully (20/20, 20/30, etc.) [[1](#)]
6. Repeat with the other eye.
7. Unexpected/unexplained loss of acuity is a sign of serious ocular pathology.



Inspection

1. Observe the patient for ptosis, exophthalmos, lesions, deformities, or asymmetry.
2. Ask the patient to look up and pull down both lower eyelids to inspect the conjunctiva and sclera.
3. Next spread each eye open with your thumb and index finger. Ask the patient to look to each side and downward to expose the entire bulbar surface.
4. Note any discoloration, redness, discharge, or lesions. Note any deformity of the iris or lesion cornea.
5. If you suspect the patient has conjunctivitis, be sure to **wash your hands** immediately. Viral

conjunctivitis is highly contagious - protect yourself!

Visual Fields

Screen Visual Fields by Confrontation [2]

1. Stand two feet in front of the patient and have them look into your eyes.
2. Hold your hands to the side half way between you and the patient.
3. Wiggle the fingers on one hand. [3]
4. Ask the patient to indicate which side they see your fingers move.
5. Repeat two or three times to test both temporal fields.
6. If an abnormality is suspected, test the four quadrants of each eye while asking the patient to cover the opposite eye with a card. ++ [4]

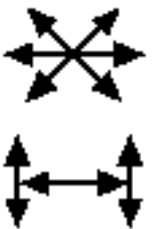Extraocular Muscles

Corneal Reflections

1. Shine a light from directly in front of the patient.
2. The corneal reflections should be centered over the pupils.
3. Asymmetry suggests extraocular muscle pathology.

Extraocular Movement

1. Stand or sit 3 to 6 feet in front of the patient.
2. Ask the patient to follow your finger with their eyes without moving their head.
3. Check gaze in the six cardinal directions using a cross or "H" pattern.
4. Check convergence by moving your finger toward the bridge of the patient's nose.



Pupillary Reactions

Light

1. Dim the room lights as necessary.
2. Ask the patient to look into the distance.
3. Shine a bright light obliquely into each pupil in turn.
4. Look for both the direct (same eye) and consensual (other eye) reactions.
5. Record pupil size in mm and any asymmetry or irregularity.

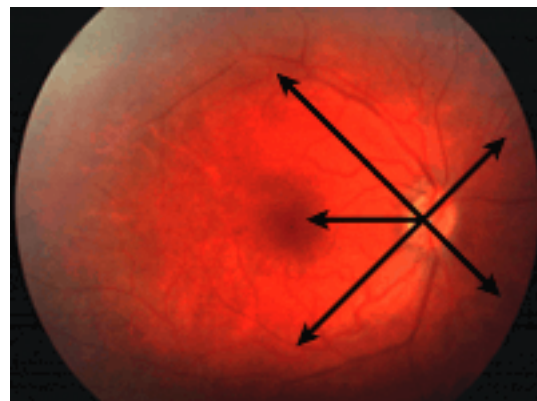
Accommodation

If the pupillary reactions to light are diminished or absent, check the reaction to accommodation (near reaction): [5] ++

1. Hold your finger about 10cm from the patient's nose.
2. Ask them to alternate looking into the distance and at your finger.
3. Observe the pupillary response in each eye.

Ophthalmoscopic Exam

1. Darken the room as much as possible. ++
2. Adjust the ophthalmoscope so that the light is **no brighter than necessary**. Adjust the aperture to a plain white circle. Set the diopter dial to zero unless you have determined a better setting for your eyes. [6]
3. Use your **left** hand and **left** eye to examine the patient's **left** eye. Use your **right** hand and **right** eye to examine the patient's **right** eye. Place your free hand on the patient's shoulder for better control.
4. Ask the patient to stare at a point on the wall or corner of the room.
5. Look through the ophthalmoscope and shine the light into the patient's eye from about two feet away. You should see the retina as a "red reflex." Follow the red color to move within a few inches of the patient's eye.
6. Adjust the diopter dial to bring the retina into focus. Find a blood vessel and follow it to the optic disk. Use this as a point of reference.
7. Inspect outward from the optic disk in at least four quadrants and note any abnormalities. [pictures on p208]
8. Move nasally from the disk to observe the macula.
9. Repeat for the other eye.

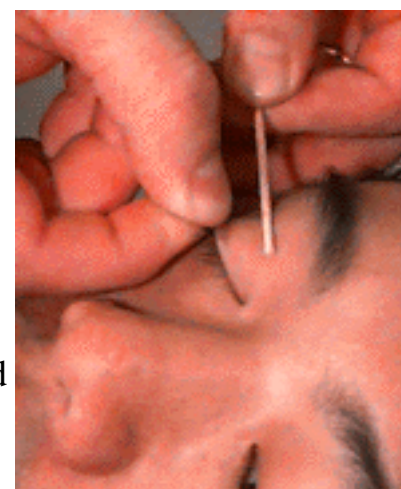


Special Tests

Upper Eyelid Eversion

This procedure is performed when a foreign body is suspected. ++

1. Ask the patient to **look down**.
2. **Gently** grasp the patient's upper eyelashes and pull them out and down.
3. Place the shaft of an applicator or tongue blade about 1 cm from the lid margin.
4. Pull the lid upward using the applicator as a fulcrum to turn the lid "inside out." **Do not press down on the eye itself.**
5. Pin the eyelid in this position by pressing the lashes against the eyebrow while you examine the palpebral conjunctiva.
6. Ask the patient to blink several times to return the lid to normal.



Notes

1. Visual acuity is reported as a pair of numbers (20/20) where the first number is how far the patient is from the chart and the second number is the distance from which the "normal" eye can read a line of letters. For example, 20/40 means that at 20 feet the patient can only read letters a "normal" person can read from twice that distance.
2. For more information refer to *A Guide to Physical Examination and History Taking, Sixth Edition* by Barbara Bates, published by Lippincott in 1995.
3. You may, instead of wiggling a finger, raise one or two fingers (unilaterally or bilaterally) and have the patient state how many fingers (total, both sides) they see. To test for **neglect**, on some trials wiggle your right and left fingers simultaneously. The patient should see movement in both hands.

4. Additional Testing - Tests marked with (++) may be skipped unless an abnormality is suspected.
5. PERRLA is a common abbreviation that stands for "Pupils Equal Round Reactive to Light and Accommodation." The use of this term is so routine that it is often used incorrectly. If you did not specifically check the accommodation reaction use the term PERRL. Pupils with a diminished response to light but a normal response to accommodation (Argyll-Robertson Pupils) are a sign of neurosyphilis.
6. Diopters are used to measure the power of a lens. The ophthalmoscope actually has a series of small lens of different strengths on a wheel (positive diopters are labeled in green, negative in red). When you focus on the retina you "dial-in" the correct number of diopters to compensate for **both** the patient's and your own vision. For example, if both you and your patient wear glasses with -2 diopter correction you should expect to set the dial to -2 with your glasses on or -4 with your glasses off.

Examination of the Chest and Lungs

- [Equipment Needed](#)
 - [General Considerations](#)
 - [Inspection](#)
 - [Palpation](#)
 - [Percussion](#)
 - [Proper Technique](#)
 - [Posterior Chest](#)
 - [Diaphragmatic Excursion](#)
 - [Anterior Chest](#)
 - [Interpretation](#)
 - [Auscultation](#)
 - [Posterior Chest](#)
 - [Anterior Chest](#)
 - [Interpretation](#)
 - [Special Tests](#)
 - [Peak Flow Monitoring](#)
 - [Voice Transmission Tests](#)
 - [Tactile Fremitus](#)
 - [Bronchophony](#)
 - [Whispered Pectoriloquy](#)
 - [Egophony](#)
 - [Notes](#)
-

Refer to the the [cardiovascular exam study guide](#) for related information.

Equipment Needed

- A Stethoscope
- A Peak Flow Meter

General Considerations

- The patient **must** be properly undressed and gowned for this examination.
- Ideally the patient should be sitting on the end of an exam table.
- The examination room **must** be quiet to perform adequate percussion and auscultation.
- Observe the patient for general signs of respiratory disease (finger clubbing, cyanosis, air hunger, etc.).
- Try to visualize the underlying anatomy as you examine the patient.

Inspection

1. Observe the rate, rhythm, depth, and effort of breathing. Note whether the expiratory phase is prolonged. [\[1\]](#) [\[2\]](#)

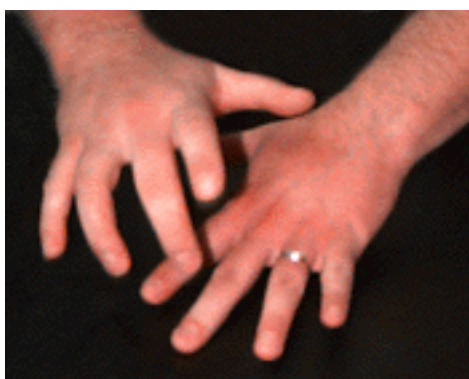2. Listen for obvious abnormal sounds with breathing such as wheezes.
3. Observe for retractions and use of accessory muscles (sternomastoids, abdominals).
4. Observe the chest for asymmetry, deformity, or increased anterior-posterior (AP) diameter. [3]
5. Confirm that the trachea is near the midline? [4]

Palpation

1. Identify any areas of tenderness or deformity by palpating the ribs and sternum. [p238, p248]
2. Assess expansion and symmetry of the chest by placing your hands on the patient's back, thumbs together at the midline, and ask them to breath deeply.
3. Check for [tactile fremitus](#). ++ [5]

Percussion

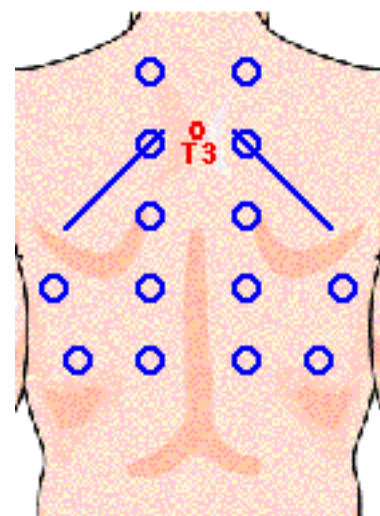
Proper Technique



1. Hyperextend the middle finger of one hand and place the distal interphalangeal joint **firmly** against the patient's chest.
2. With the end (not the pad) of the opposite middle finger, use a quick flick of the wrist to strike first finger.
3. Categorize what you hear as normal, dull, or hyperresonant.
4. Practice your technique until you can consistently produce a "normal" percussion note on your (presumably normal) partner before you work with patients.

Posterior Chest

1. Percuss from side to side and top to bottom using the pattern shown in the illustration. Omit the areas covered by the scapulae.
2. Compare one side to the other looking for asymmetry.
3. Note the location and quality of the percussion sounds you hear.
4. Find the level of the diaphragmatic dullness on both sides.

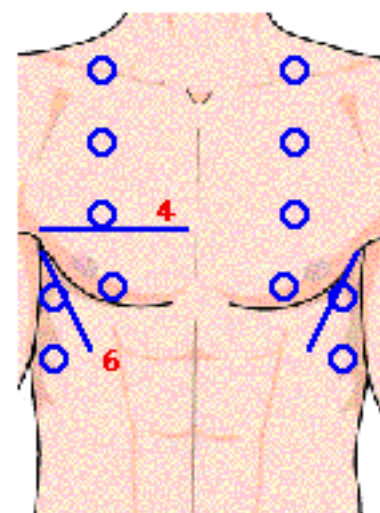


Diaphragmatic Excursion

5. Find the level of the diaphragmatic dullness on both sides.
6. Ask the patient to inspire deeply.
7. The level of dullness (diaphragmatic excursion) should go down 3-5cm **symmetrically**. [6] ++

Anterior Chest

1. Percuss from side to side and top to bottom using the pattern shown in the illustration.
2. Compare one side to the other looking for asymmetry.
3. Note the location and quality of the percussion sounds you hear.



Interpretation

Percussion Notes and Their Meaning	
Flat or Dull	Pleural Effusion or Lobar Pneumonia

Normal	Healthy Lung or Bronchitis
Hyperresonant	Emphysema or Pneumothorax

Auscultation

Use the diaphragm of the stethoscope to auscultate breath sounds.

Posterior Chest

1. Auscultate from side to side and top to bottom using the pattern shown in the illustration. Omit the areas covered by the scapulae.
2. Compare one side to the other looking for asymmetry.
3. Note the location and quality of the sounds you hear.

Anterior Chest

1. Auscultate from side to side and top to bottom using the pattern shown in the illustration.
2. Compare one side to the other looking for asymmetry.
3. Note the location and quality of the sounds you hear.

Interpretation

Breath sounds are produced by turbulent air flow. They are categorized by the size of the airways that transmit them to the chest wall (and your stethoscope). The general rule is, the larger the airway, the louder and higher pitched the sound. Vesicular breath sounds are low pitched and normally heard over most lung fields. Tracheal breath sounds are heard over the trachea. Bronchovesicular and bronchial sounds are heard in between. Inspiration is normally longer than expiration ($I > E$). [2]

Breath sounds are **decreased** when normal lung is displaced by air (emphysema or pneumothorax) or fluid (pleural effusion). Breath sounds **shift from vesicular to bronchial** when there is fluid in the lung itself (pneumonia). Extra sounds that originate in the lungs and airways are referred to as "adventitious" and are always abnormal (but not always significant). (See Table)

Adventitious (Extra) Lung Sounds

Crackles	These are high pitched, discontinuous sounds similar to the sound produced by rubbing your hair between your fingers. (Also known as Rales)
Wheezes	These are generally high pitched and "musical" in quality. Stridor is an inspiratory wheeze associated with upper airway obstruction (croup).
Rhonchi	These often have a "snoring" or "gurgling" quality. Any extra sound that is not a crackle or a wheeze is probably a rhonchi.

Special Tests

Peak Flow Monitoring

Peak flow meters are inexpensive, hand-held devices used to monitor pulmonary function in patients with asthma. The peak flow roughly correlates with the FEV1. [7]

++

1. Ask the patient to take a deep breath.
2. Then ask them to exhale **as fast as they can** through the peak flow meter.
3. Repeat the measurement 3 times and report the average.



Voice Transmission Tests

These tests are only used in special situations. This part of the physical exam has largely been replaced by the chest x-ray. All these tests become abnormal when the lungs become filled with fluid (referred to as **consolidation**).

Tactile Fremitus

1. Ask the patient to say "ninety-nine" several times in a normal voice. ++
2. Palpate using the ball of your hand.
3. You should feel the vibrations transmitted through the airways to the lung.
4. Increased tactile fremitus suggests consolidation of the underlying lung tissues. [8]

Bronchophony

1. Ask the patient to say "ninety-nine" several times in a normal voice. ++
2. Auscultate several symmetrical areas over each lung.
3. The sounds you hear should be muffled and indistinct. Louder, clearer sounds are called bronchophony.

Whispered Pectoriloquy

1. Ask the patient to whisper "ninety-nine" several times. ++
2. Auscultate several symmetrical areas over each lung.
3. You should hear only faint sounds or nothing at all. If you hear the sounds clearly this is referred to as whispered pectoriloquy. [9]

Egophony

1. Ask the patient to say "ee" continuously. ++
2. Auscultate several symmetrical areas over each lung.
3. You should hear a muffled "ee" sound. If you hear an "ay" sound this is referred to as "E -> A" or egophony.

Notes

1. For more information refer to *A Guide to Physical Examination and History Taking, Sixth Edition* by Barbara Bates, published by Lippincott in 1995.
2. A prolonged expiratory phase ($E > I$) indicates airway narrowing, as in asthma.
3. AP diameter increases somewhat with age, however, a round or "barrel" chest is often a sign of

advanced emphysema.

4. The trachea will deviate to one side in cases of tension pneumothorax.
5. Additional Testing - Tests marked with (++) may be skipped unless an abnormality is suspected.
6. Decreased or asymmetric diaphragmatic excursion may indicate paralysis or emphysema.
7. It has been said that "a peak flow meter is to asthma as a thermometer is to fever." Peak flow measurements are used to gauge severity of asthma attacks and track the disease over time. Ideally new readings are compared to the patient's current "personal best." Readings less than 80% of "best" may indicate a need for additional therapy. Readings less than 50% may indicate an emergency situation.
8. Increased fremitus indicates **fluid in the lung**. Decreased fremitus indicates sound transmission obstructed by chronic obstructive pulmonary disease (COPD), **fluid outside the lung** (pleural effusion), air outside the lung (pneumothorax), etc.

Cardiovascular Examination

- [Equipment Needed](#)
 - [General Considerations](#)
 - [Arterial Pulses](#)
 - [Rate and Rhythm](#)
 - [Amplitude and Contour](#)
 - [Auscultation for Bruits](#)
 - [Blood Pressure](#)
 - [Interpretation](#)
 - [Jugular Venous Pressure](#)
 - [Precordial Movement](#)
 - [Auscultation](#)
 - [Interpretation](#)
 - [Notes](#)
-

Equipment Needed

- A Double-Headed, Double-Lumen Stethoscope
- A Blood Pressure Cuff
- A Moveable Light Source or Pen Light

General Considerations

- The patient **must** be properly undressed and in a gown for this examination.
- The examination room **must** be quiet to perform adequate auscultation.
- Observe the patient for general signs of cardiovascular disease (finger clubbing, cyanosis, edema, etc.).

Arterial Pulses

Rate and Rhythm

1. Compress the radial artery with your index and middle fingers. [1]
2. Note whether the pulse is regular or irregular.
3. Count the pulse for 15 seconds and multiply by 4.
4. Count for a full minute if the pulse is irregular. [2]
5. Record the rate and rhythm.

Pulse Classification in Adults (At Rest)		
Normal	Bradycardia	Tachycardia
60 to 100 bpm	less than 60 bpm	more than 100
Regular	Regularly Irregular	Irregularly Irregular

Evenly spaced beats, may vary slightly with respiration

Regular pattern overall with "skipped" beats

Chaotic, no real pattern, very difficult to measure rate accurately [2]

[[See below for children.](#)]

Amplitude and Contour

1. Observe for carotid pulsations.
2. Place your fingers behind the patient's neck and compress the carotid artery on one side with your thumb **at or below** the level of the cricoid cartilage. Press firmly but not to the point of discomfort. [3]
3. Assess the following:
 - o The amplitude of the pulse.
 - o The contour of the pulse wave.
 - o Variations in amplitude from beat to beat or with respiration.
4. Repeat on the opposite side.

Auscultation for Bruits

If the patient is late middle aged or older, you should auscultate for bruits. A bruit is often, but not always, a sign of arterial narrowing and risk of a stroke. ++ [4]

1. Place the **bell** of the stethoscope over each carotid artery in turn. You may use the diaphragm if the patient's neck is highly contoured.
2. Ask the patient to stop breathing momentarily.
3. Listen for a blowing or rushing sound--a bruit. Do not be confused by heart sounds or murmurs transmitted from the chest.

Blood Pressure

The patient should not have eaten, smoked, taken caffeine, or engaged in vigorous exercise within the last 30 minutes. The room should be quiet and the patient comfortable.

1. Position the patient's arm so the antecubital fold is level with the heart.
2. Center the bladder of the cuff over the brachial artery approximately 2 cm above the antecubital fold. **Proper cuff size is essential** to obtain an accurate reading. Be sure the index line falls between the size marks when you apply the cuff. Position the patient's arm so it is slightly flexed at the elbow.
3. Palpate the radial pulse and inflate the cuff until the pulse disappears. This is a rough estimate of the systolic pressure. [6]
4. Place the stethoscope over the brachial artery. [5]
5. Inflate the cuff 20 to 30 mmHg above the estimated systolic pressure.
6. Release the pressure slowly, no greater than 5 mmHg per second.
7. The level at which you consistently hear beats is the systolic pressure. [7]
8. Continue to lower the pressure until the sounds muffle and disappear. This is the diastolic pressure. [8]
9. Record the blood pressure as systolic over diastolic (120/70).
10. Blood pressure should be taken in both arms on the first encounter. [9]

Interpretation

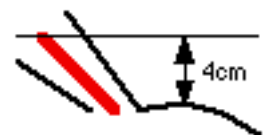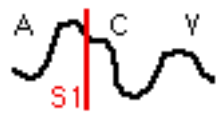Blood Pressure Classification in Adults		
Category	Systolic	Diastolic
Normal	<130	<85
High Normal	130-139	85-89
Mild Hypertension	140-159	90-99
Moderate Hypertension	160-179	100-109
Severe Hypertension	180-209	110-119
Crisis Hypertension	>210	>120

In children, pulse and blood pressure vary with the age. The following table should serve as a rough guide:

Average Pulse and Blood Pressure in Normal Children							
Age	Birth	6mo	1yr	2yr	6yr	8yr	10yr
Pulse	140	130	115	110	103	100	95
Systolic BP	70	90	90	92	95	100	105

Jugular Venous Pressure

1. Position the patient supine with the head of the table elevated 30 degrees. ++
2. Use tangential, side lighting to observe for venous pulsations in the neck.
3. Look for a rapid, double (sometimes triple) wave with each heart beat. Use light pressure just above the sternal end of the clavicle to eliminate the pulsations and rule out a carotid origin.
4. Adjust the angle of table elevation to bring out the venous pulsation.
5. Identify the highest point of pulsation. Using a horizontal line from this point, measure vertically from the sternal angle. [10]
6. This measurement should be less than 4 cm in a normal healthy adult.

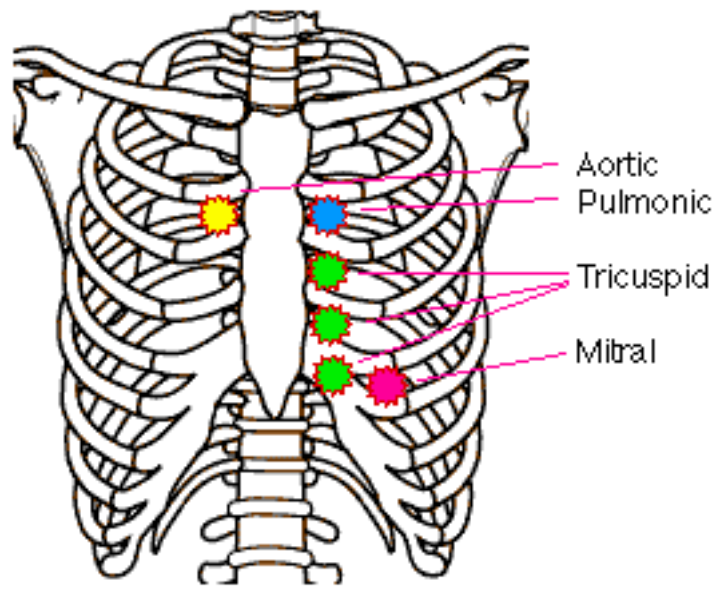


Precordial Movement

1. Position the patient supine with the head of the table slightly elevated.
2. Always examine from the patient's right side.
3. Inspect for precordial movement. Tangential lighting will make movements more visible.
4. Palpate for precordial activity in general. You may feel "extras" such as thrills or exaggerated ventricular impulses.
5. Palpate for the point of maximal impulse (PMI or apical pulse). It is normally located in the 4th or 5th intercostal space just medial to the midclavicular line and is less than the size of a quarter.
6. Note the location, size, and quality of the impulse.

Auscultation

1. Position the patient supine with the head of the table slightly elevated.
2. Always examine from the patient's right side.
A quiet room is essential.
3. Listen with the diaphragm at the right 2nd interspace near the sternum (aortic area).
4. Listen with the diaphragm at the left 2nd interspace near the sternum (pulmonic area).
5. Listen with the diaphragm at the left 3rd, 4th, and 5th interspaces near the sternum (tricuspid area). [11]
6. Listen with the diaphragm at the apex (PMI) (mitral area).
7. Listen with the **bell** at the apex.
8. Listen with the **bell** at the left 4th and 5th interspace near the sternum. ++
9. Have the patient roll on their left side. ++
 - o Listen with the **bell** at the apex.
 - o This position brings out S3 and mitral murmurs.
10. Have the patient sit up, lean forward, and hold their breath in exhalation. ++
 - o Listen with the diaphragm at the left 3rd and 4th interspace near the sternum.
 - o This position brings out aortic murmurs.
11. Record S1, S2, (S3), (S4), as well as the grade and configuration of any murmurs ("two over six" or "2/6", "pansystolic" or "crescendo").

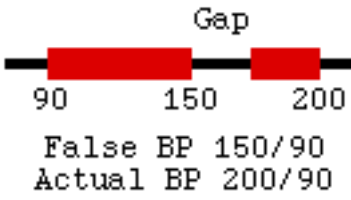


Interpretation

Murmurs and Extra Sounds		
<p>Systolic Ejection</p> <p>S1 S2 S1</p> <p>Innocent/Physiologic Aortic/Pulmonic Stenosis</p>	<p>Pansystolic</p> <p>S1 S2 S1</p> <p>Mitral/Tricuspid Regurgitation</p>	<p>Systolic Click Late Systolic</p> <p>S1 S2 S1</p> <p>Mitral Valve Prolapse</p>
<p>Early Diastolic</p> <p>S1 S2 S1</p> <p>Aortic Regurgitation</p>	<p>Mid Diastolic</p> <p>S1 S2 S1</p> <p>Mitral/Tricuspid Stenosis</p>	<p>Opening Snap Diastolic Rumble</p> <p>S1 S2 S1</p> <p>Mitral Stenosis</p>
<p>Ejection Sound</p> <p>S1 S2 S1</p> <p>Aortic Valve Disease</p>	<p>S3</p> <p>S1 S2 S1</p> <p>Normal in Children Heart Failure</p>	<p>S4</p> <p>S1 S2 S1</p> <p>Physiologic Various Diseases</p>

Murmur Grades		
Grade	Volume	Thrill
1/6	very faint, only heard with optimal conditions	no
2/6	loud enough to be obvious	no
3/6	louder than grade 2	no
4/6	louder than grade 3	yes
5/6	heard with the stethoscope partially off the chest	yes
6/6	heard with the stethoscope completely off the chest	yes

Notes

- For more information refer to *A Guide to Physical Examination and History Taking, Sixth Edition* by Barbara Bates, published by Lippincott in 1995.
- With an irregular pulse, the beats counted in any 30 second period may not represent the overall rate. The longer you measure, the more these variations are averaged out.
- Avoid compressing both sides at the same time. This could cut off the blood supply to the brain and cause syncope. Avoid compressing the carotid sinus higher up in the neck. This could lead to bradycardia and depressed blood pressure.
- Additional Testing - Tests marked with (++) may be skipped unless an abnormality is suspected.
- Bell or Diaphragm? - Even though Korotkoff sounds are low frequency and should be heard better with the bell, it is often difficult to apply the bell properly to the antecubital fold. For this reason, it is common practice to use the diaphragm when taking the blood pressure.
- Maximum Cuff Pressure - When the baseline blood pressure is already known or hypertension is not suspected, it is acceptable in adults to inflate the cuff to 200 mmHg and go directly to auscultating the blood pressure. Be aware that there could be an auscultatory gap (a silent interval between the true systolic and diastolic pressures).
 
- Systolic Pressure - In situations where auscultation is not possible, you can determine systolic blood pressure by palpation alone. Deflate the cuff until you feel the radial or brachial pulse return. The pressure by auscultation would be approximately 10 mmHg higher. Record the pressure indicating it was taken by palpation (60/palp).
- Diastolic Pressure - If there is more than 10 mmHg difference between the muffling and the disappearance of the sounds, record all three numbers (120/80/45).
- Pressure Differences - If there is more than 10 mmHg difference between the two arms, use the arm with the higher reading for subsequent measurements.
- Sternal Angle - The sternal angle is taken to be 5cm above the right atrium. A jugular pulse 10cm above the sternal angle equates to a central venous pressure of 15cm of water.
- Left Sternal Border - The left 3rd, 4th, and 5th interspaces are considered the tricuspid area and are referred to as the Lower Left Sternal Border or LLSB.

Examination of the Abdomen

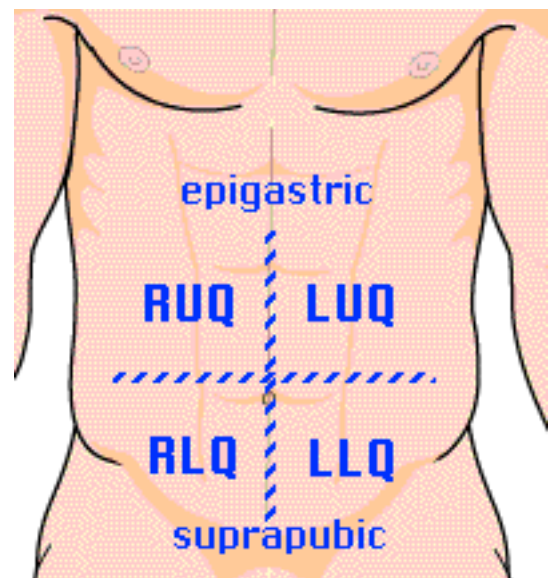
- [Equipment Needed](#)
 - [General Considerations](#)
 - [Inspection](#)
 - [Auscultation](#)
 - [Percussion](#)
 - [Liver Span](#)
 - [Splenic Dullness](#)
 - [Palpation](#)
 - [General Palpation](#)
 - [Palpation of the Liver](#)
 - [Standard Method](#)
 - [Alternate Method](#)
 - [Palpation of the Aorta](#)
 - [Palpation of the Spleen](#)
 - [Special Tests](#)
 - [Rebound Tenderness](#)
 - [Costovertebral Tenderness](#)
 - [Shifting Dullness](#)
 - [Psoas Sign](#)
 - [Obturator Sign](#)
 - [Notes](#)
-

Equipment Needed

- A Stethoscope

General Considerations

- The patient should have an **empty bladder**.
- The patient should be lying supine on the exam table and appropriately draped.
- The examination room **must** be quiet to perform adequate auscultation and percussion.
- **Watch the patient's face** for signs of discomfort during the examination.
- Use the appropriate terminology to locate your findings:
 - Right Upper Quadrant (RUQ)
 - Right Lower Quadrant (RLQ)
 - Left Upper Quadrant (LUQ)
 - Left Lower Quadrant (LLQ)
 - Midline:
 - Epigastric
 - Periumbilical
 - Suprapubic



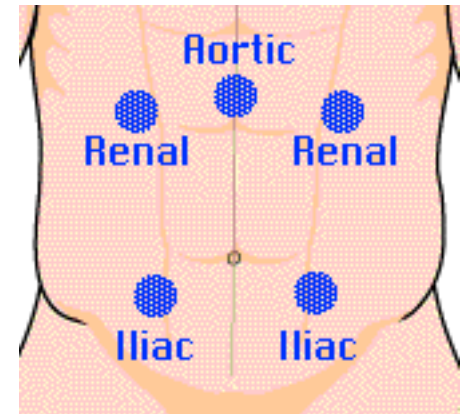
- Disorders in the chest will often manifest with abdominal symptoms. It is always wise to examine the chest when evaluating an abdominal complaint.
- Consider the inguinal/rectal examination in males. Consider the pelvic/rectal examination in females.

Inspection

1. Look for scars, striae, hernias, vascular changes, lesions, or rashes. [1]
2. Look for movement associated with peristalsis or pulsations.
3. Note the abdominal contour. Is it flat, scaphoid, or protuberant?

Auscultation

1. Place the diaphragm of your stethoscope lightly on the abdomen. [2]
2. Listen for bowel sounds. Are they normal, increased, decreased, or absent?
3. Listen for bruits over the renal arteries, iliac arteries, and aorta.

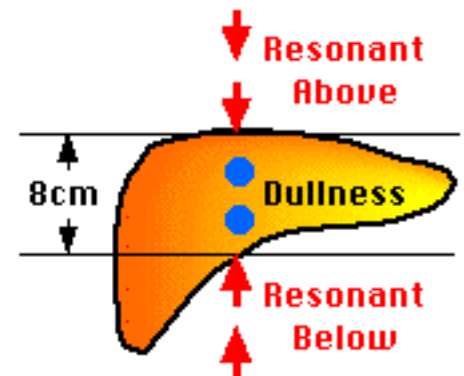


Percussion

1. Percuss in all four quadrants using [proper technique](#).
2. Categorize what you hear as tympanic or dull. Tympany is normally present over most of the abdomen in the supine position. Unusual dullness may be a clue to an underlying abdominal mass.

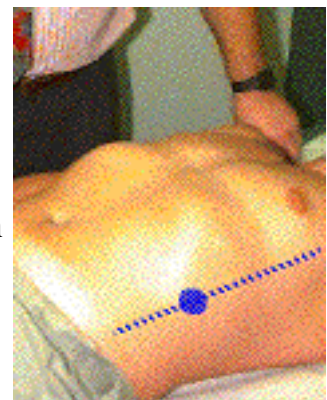
Liver Span

1. Percuss **downward** from the chest in the **right midclavicular line** until you detect the top edge of liver dullness.
2. Percuss **upward** from the abdomen in the same line until you detect the bottom edge of liver dullness.
3. Measure the liver span between these two points. This measurement should be 6-12 cm in a normal adult.



Splenic Dullness

1. Percuss the lowest costal interspace in the **left anterior axillary line**. This area is normally tympanic.
2. Ask the patient to take a deep breath and percuss this area again. Dullness in this area is a sign of splenic enlargement.



Palpation

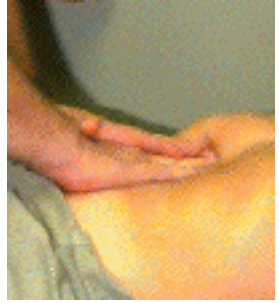
General Palpation

1. Begin with **light palpation**. At this point you are mostly looking for areas of tenderness. The most sensitive indicator of tenderness is the patient's facial expression (so watch the patient's face, not your hands). Voluntary or involuntary guarding may also be present.
2. Proceed to **deep palpation** after surveying the abdomen lightly. Try to identify abdominal masses or areas of deep tenderness.

Palpation of the Liver

Standard Method

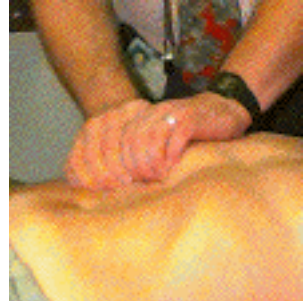1. Place your fingers just below the right costal margin and press firmly.
2. Ask the patient to take a deep breath.
3. You may feel the edge of the liver press against your fingers. Or it may slide under your hand as the patient exhales. A normal liver is **not** tender.



Alternate Method

This method is useful when the patient is obese or when the examiner is small compared to the patient.

1. Stand by the patient's chest.
2. "Hook" your fingers just below the costal margin and press firmly.
3. Ask the patient to take a deep breath.
4. You may feel the edge of the liver press against your fingers.



Palpation of the Aorta

1. Press down deeply in the midline above the umbilicus. [++](#)
2. The aortic pulsation is easily felt on most individuals.
3. A well defined, pulsatile mass, greater than 3 cm across, suggests an aortic aneurysm.

Palpation of the Spleen

1. Use your left hand to lift the lower rib cage and flank. [++](#)
2. Press down just below the left costal margin with your right hand.
3. Ask the patient to take a deep breath.
4. The spleen is **not** normally palpable on most individuals.

Special Tests

Rebound Tenderness

This is a test for peritoneal irritation. [++](#)

1. Warn the patient what you are about to do.
2. Press deeply on the abdomen with your hand.
3. After a moment, quickly release pressure.
4. If it hurts more when you release, the patient has rebound tenderness. [\[4\]](#)

Costovertebral Tenderness

CVA tenderness is often associated with renal disease. [++](#)

1. Warn the patient what you are about to do.
2. Have the patient sit up on the exam table.
3. Use the heel of your closed fist to strike the patient firmly over the costovertebral angles.

4. Compare the left and right sides.

Shifting Dullness

This is a test for peritoneal fluid (ascites). ++

1. Percuss the patient's abdomen to outline areas of dullness and tympany.
2. Have the patient roll away from you.
3. Percuss and again outline areas of dullness and tympany. If the dullness has shifted to areas of prior tympany, the patient may have excess peritoneal fluid. [5]

Psoas Sign

This is a test for appendicitis. ++

1. Place your hand above the patient's right knee.
2. Ask the patient to flex the right hip against resistance.
3. Increased abdominal pain indicates a positive psoas sign.

Obturator Sign

This is a test for appendicitis. ++

1. Raise the patient's right leg with the knee flexed.
2. Rotate the leg internally at the hip.
3. Increased abdominal pain indicates a positive obturator sign.

Notes

1. For more information refer to *A Guide to Physical Examination and History Taking, Sixth Edition* by Barbara Bates, published by Lippincott in 1995.
2. Auscultation should be done **prior** to percussion and palpation since bowel sounds may change with manipulation. Since bowel sounds are transmitted widely in the abdomen, auscultation of more than one quadrant is not usually necessary. If you hear them, they are present, period.
3. Additional Testing - Tests marked with (++) may be skipped unless an abnormality is suspected.
4. Tenderness felt in the RLQ when palpation is performed on the left is called Rovsing's Sign and suggests appendicitis. Rebound tenderness referred from the left to the RLQ also suggests this disorder.
5. Small amounts of peritoneal fluid are not usually detectable on physical exam.

Examination of the Extremities and Back

- [Equipment Needed](#)
 - [General Considerations](#)
 - [Regional Considerations](#)
 - [Inspection](#)
 - [Palpation](#)
 - [Range of Motion](#)
 - [Active](#)
 - [Passive](#)
 - [Specific Joints](#)
 - [Vascular](#)
 - [Pulses](#)
 - [Capillary Refill](#)
 - [Edema, Cyanosis, and Clubbing](#)
 - [Lymphatics](#)
 - [Special Tests](#)
 - [Upper Extremities](#)
 - [Snuffbox Tenderness \(Scaphoid\)](#)
 - [Drop Arm Test \(Rotator Cuff\)](#)
 - [Impingement Sign \(Rotator Cuff\)](#)
 - [Flexor Digitorum Superficialis Test](#)
 - [Flexor Digitorum Profundus Test](#)
 - [Vascular and Neurologic Tests](#)
 - [Allen Test \(Radial/Ulnar Arteries\)](#)
 - [Phalen's Test \(Median Nerve\)](#)
 - [Tinel's Sign \(Median Nerve\)](#)
 - [Lower Extremities](#)
 - [Collateral Ligament Testing](#)
 - [Lachman Test \(Cruciate Ligaments\)](#)
 - [Anterior/Posterior Drawer Test \(Cruciate Ligaments\)](#)
 - [Ballotable Patella \(Major Knee Effusion\)](#)
 - [Milking the Knee \(Minor Knee Effusion\)](#)
 - [Back](#)
 - [Straight Leg Raising \(L5/S1 Nerve Roots\)](#)
 - [FABER Test \(Hips/Sacroiliac Joints\)](#)
 - [Notes](#)
-

NOTE: This study guide focuses on the **musculoskeletal and peripheral vascular** examination. Refer to the [neurologic exam study guide](#) for more information on [motor/sensory](#) testing of the extremities.

Equipment Needed

- None

General Considerations

- The patient should be undressed and gowned as needed for this examination.
- Some portions of the examination may not be appropriate depending on the clinical situation (performing range of motion on a fractured leg for example).
- The musculoskeletal exam is all about **anatomy**. Think of the underlying anatomy as you obtain the history and examine the patient.
- When taking a history for an acute problem always inquire about the **mechanism of injury**, loss of function, onset of swelling (< 24 hours), and initial treatment.
- When taking a history for a chronic problem always inquire about past injuries, past treatments, effect on function, and current symptoms.
- The cardinal signs of musculoskeletal disease are pain, redness (erythema), swelling, increased warmth, deformity, and loss of function.
- **Always begin with inspection, palpation and range of motion**, regardless of the region you are examining. Specialized tests are often omitted unless a specific abnormality is suspected. A complete evaluation will include a focused [neurologic exam](#) of the effected area.

Regional Considerations

- Remember that the **clavicle** is part of the shoulder. Be sure to include it in your examination.
- The **patella** is much easier to examine if the leg is extended and relaxed.
- Be sure to palpate over the **spinous process** of each vertebrae.
- It is always helpful to observe the patient **standing and walking**.
- Always consider **referred pain**, from the neck or chest to the shoulder, from the back or pelvis to the hip, and from the hip to the knee.
- Pain with, or limitation of, **rotation** is often the first sign of hip disease.
- Diagnostic hints based on **location** of pain:

	Back	Side	Front
Shoulder Pain	Muscle Spasm	Bursitis or Rotator Cuff	Glenohumeral Joint
Hip Pain	Sciatica	Bursitis	Hip Joint

Inspection

1. Look for scars, rashes, or other lesions. [1]
2. Look for asymmetry, deformity, or atrophy.
3. Always compare with the other side.

Palpation

1. Examine each major joint and muscle group in turn.
2. Identify any areas of tenderness. [2]
3. Identify any areas of deformity.
4. Always compare with the other side.

Range of Motion

Start by asking the patient to move through an active range of motion (joints moved by patient). Proceed to passive range of motion (joints moved by examiner) if active range of motion is abnormal.

Active

1. Ask the patient to move each joint through a full range of motion.
2. Note the degree and type (pain, weakness, etc.) of any limitations.
3. Note any increased range of motion or instability.
4. Always compare with the other side.
5. Proceed to passive range of motion if abnormalities are found.

Passive

1. Ask the patient to relax and allow you to support the extremity to be examined. ++ [3]
2. Gently move each joint through its full range of motion.
3. Note the degree and type (pain or mechanical) of any limitation. [4]
4. If increased range of motion is detected, perform special tests for instability as appropriate.
5. Always compare with the other side.

Specific Joints

- Fingers - flexion/extension; abduction/adduction
- Thumb - flexion/extension; abduction/adduction; opposition
- Wrist - flexion/extension; radial/ulnar deviation
- Forearm - pronation/supination (function of BOTH elbow and wrist)
- Elbow - flexion/extension
- Shoulder - flexion/extension; internal/external rotation; abduction/adduction (2/3 glenohumeral joint, 1/3 scapulo-thoracic) [5]
- Hip - flexion/extension; abduction/adduction; internal/external rotation
- Knee - flexion/extension
- Ankle - flexion (plantarflexion)/extension (dorsiflexion)
- Foot - inversion/eversion
- Toes - flexion/extension
- Spine - flexion/extension; right/left bending; right/left rotation [p466, p477]

Vascular

Pulses

1. Check the radial pulses on both sides. If the radial pulse is absent or weak, check the brachial pulses.
2. Check the posterior tibial and dorsalis pedis pulses on both sides. If these pulses are absent or weak, check the popliteal and femoral pulses.

Capillary Refill

1. Press down firmly on the patient's finger or toe nail so it blanches. ++
2. Release the pressure and observe how long it takes the nail bed to "pink" up.
3. Capillary refill times greater than 2 to 3 seconds suggest peripheral vascular disease, arterial blockage, heart failure, or shock.

Edema, Cyanosis, and Clubbing

1. Check for the presence of edema (swelling) of the feet and lower legs.

2. Check for the presence of cyanosis (blue color) of the feet or hands.
3. Check for the presence of clubbing of the fingers.

Lymphatics

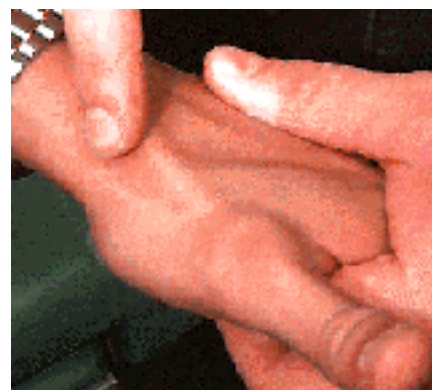1. Check for the presence of epitrochlear lymph nodes. [++](#)
2. Check for the presence of axillary lymph nodes. [++](#)
3. Check for the presence of inguinal lymph nodes. [++](#)

Special Tests

Upper Extremities

Snuffbox Tenderness (Scaphoid)

1. Identify the "anatomic snuffbox" between the extensor pollicis longus and brevis (extending the thumb makes these structures more prominent). [++](#)
2. Press firmly straight down with your index finger or thumb.
3. Any tenderness in this area is highly suggestive of scaphoid fracture. [\[6\]](#)



Drop Arm Test (Rotator Cuff)

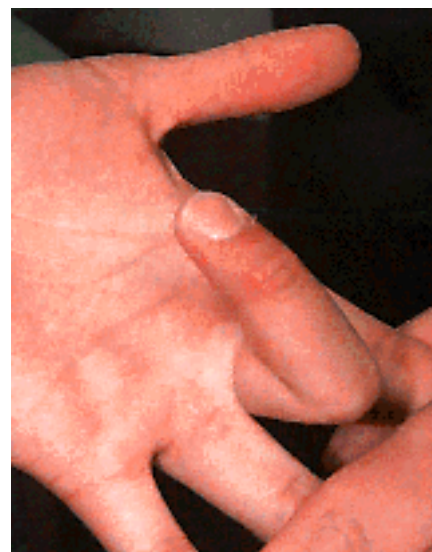1. Start with the patient's arm abducted 90 degrees. [++](#)
2. Ask the patient to **slowly** lower the arm.
3. If the rotator cuff (especially the supraspinatus) is torn, the patient will be unable to lower the arm slowly and smoothly.

Impingement Sign (Rotator Cuff)

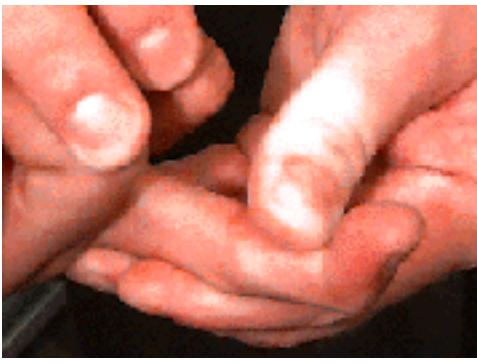1. Start with the patient's arm relaxed and the shoulder in neutral rotation. [++](#)
2. Abduct the arm to 90 degrees.
3. Significant shoulder pain as the arm is raised suggests an impingement of the rotator cuff against the acromion.

Flexor Digitorum Superficialis Test

1. Hold the fingers in extension except the finger being tested. [++](#)
2. Ask the patient to flex the finger at the proximal interphalangeal joint.
3. If the patient cannot flex the finger, the flexor digitorum superficialis tendon is cut or non-functional.



Flexor Digitorum Profundus Test



1. Hold the metacarpophalangeal and proximal interphalangeal joints of the finger being tested in extension. ++
2. Ask the patient to flex the finger at the distal interphalangeal joint.
3. If the patient cannot flex the finger, the flexor digitorum profundus tendon is cut or non-functional.

Vascular and Neurologic Tests

Allen Test (Radial/Ulnar Arteries)

1. Ask the patient to make a tight fist. ++
2. Compress both the ulnar and radial arteries to stop blood flowing to the hand.
3. Ask the patient to open the hand.
4. Release pressure on the ulnar side. The hand should "pink" up in a few seconds unless the ulnar artery is occluded.
5. Repeat the process for the radial artery as indicated.

Phalen's Test (Median Nerve)

1. Ask the patient to press the backs of the hands together with the wrists fully flexed (backward praying). ++
2. Have the patient hold this position for 60 seconds and then comment on how the hands feel.
3. Pain, tingling, or other abnormal sensations in the thumb, index, or middle fingers strongly suggest carpal tunnel syndrome.



Tinel's Sign (Median Nerve)

1. Use your middle finger or a reflex hammer to tap over the carpal tunnel. ++
2. Pain, tingling, or electric sensations strongly suggest carpal tunnel syndrome.

Lower Extremities

Collateral Ligament Testing

1. The patient should be supine with the legs resting on the exam table. ++
2. Hold the leg to be examined in 20-30 degrees of flexion. [7]
3. Place one hand laterally just below the knee. Grasp the leg near the ankle with your other hand.
4. Gently push with both hands in opposite directions to stress the knee.
5. If the knee joint "opens up" medially, the medial collateral ligament may be torn.
6. Reverse your hands and repeat the stress.
7. If the knee joint "opens up" laterally, the lateral collateral ligament may be torn.

Lachman Test (Cruciate Ligaments)

1. Ask the patient to lie supine on the exam table. [8] ++
2. Grasp the thigh with one hand and the upper tibia with the other. Hold the knee in about 15 degrees of flexion.
3. Ask the patient to relax and gently pull forward on the tibia.
4. The normal knee has a distinct end point. If the tibia moves out from under the femur, the anterior cruciate ligament may be torn.

5. Repeat the test using posterior stress.
6. The normal knee has a distinct end point. If the tibia moves back under the femur, the posterior cruciate ligament may be torn.

Anterior/Posterior Drawer Test (Cruciate Ligaments)

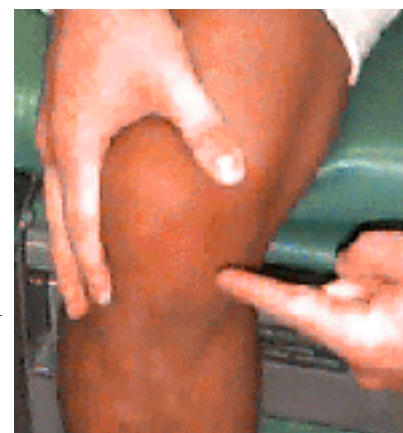1. Ask the patient to lie supine on the exam table with knees flexed to 90 degrees and feet flat on the table. [9] ++
2. Sit on or otherwise stabilize the foot of the leg being examined.
3. Grasp the leg just below the knee with both hands and pull forward.
4. If the tibia moves out from under the femur, the anterior cruciate ligament may be torn.
5. Without changing the position of your hands, push the leg backward.
6. If the tibia moves back under the femur, the posterior cruciate ligament may be torn.

Ballotable Patella (Major Knee Effusion)

1. Ask the patient to lie supine on the exam table with leg muscles relaxed. ++
2. Press the patella downward and quickly release it.
3. If the patella visibly rebounds, a large knee effusion (excess fluid in the knee) is present.

Milking the Knee (Minor Knee Effusion)

1. Ask the patient to lie supine on the exam table with leg muscles relaxed. ++
2. Compress the suprapatellar pouch with your thumb, palm, and index finger.
3. "Milk" downward and laterally so that any excess fluid collects on the medial side.
4. Tap gently over the collected fluid and observe the effect on the lateral side, or ballot the patella as outlined above.
5. A fullness on the lateral side indicates that a small knee effusion is present.



Back

Straight Leg Raising (L5/S1 Nerve Roots)

1. Ask the patient to lie supine on the exam table with knees straight. ++
2. Grasp the leg near the heel and raise the leg slowly towards the ceiling.
3. Pain in an L5 or S1 distribution suggests nerve root compression or tension (radicular pain).
4. Dorsiflex the foot while maintaining the raised position of the leg.
5. Increased pain strengthens the likelihood of a nerve root problem.
6. Repeat the process with the opposite leg.
7. Increased pain on the **opposite** side indicates that a nerve root problem is almost certain.

FABER Test (Hips/Sacroiliac Joints)

FABER stands for **F**lexion, **A**bduction, and **E**xternal **R**otation of the hip. This test is used to distinguish hip or sacroiliac joint pathology from spine problems. [10] ++

1. Ask the patient to lie supine on the exam table.
2. Place the foot of the effected side on the opposite knee (this flexes, abducts, and externally rotates the hip).
3. Pain in the groin area indicates a problem with the hip and not the spine.

4. Press down gently but firmly on the flexed knee and the opposite anterior superior iliac crest.
 5. Pain in the sacroiliac area indicates a problem with the sacroiliac joints.
-

Notes

1. For more information refer to *A Guide to Physical Examination and History Taking, Sixth Edition* by Barbara Bates, published by Lippincott in 1995. wAdditional reference is made to *Physical Examination of the Spine and Extremities* , by Stanley Hoppenfeld published in 1976 by Appleton Century Crofts.
2. It is wise to start palpation some distance from a suspected tender area. Proceed slowly and minimize palpation of tender spots once they are identified. Examine at least one joint above and below an injured area.
3. Additional Testing - Tests marked with (++) may be skipped unless an abnormality is suspected.
4. Joint motion may be limited by any combination of pain, weakness, mechanical block within the joint, deformity, contracture of the soft tissues (muscles, ligaments, musculo-tendinous structures, joint capsule, etc), and patient factors. Joint motion may be increased by instability, ligamentous laxity and/or deformity.
5. Normally the ratio of glenohumeral to scapular movement is 2:1. If the range of motion of the glenohumeral joint is reduced, the patient will increase the amount of scapular movement to compensate and the ratio will change.
6. Snuffbox Tenderness is more sensitive than an xrays for identifying scaphoid fractures. Tenderness in this area after an injury should be treated as a fracture even if the xrays are negative.
7. Holding the knee in flexion helps isolate the collateral ligaments. Secondary stabilizers (anterior cruciate ligament, joint capsule) come into play when the knee is in full extension. If the knee "opens up" in full extension, these secondary structures may also be damaged.
8. The Lachman Test is used by athletic trainers on the field to check for cruciate ligament injury. It is very accurate and can be done on an acutely injured knee (when the patient cannot tolerate bending the knee for a drawer test).
9. The Drawer Test is the "classic" technique to check for cruciate ligament injury. It is less accurate and cannot be done on an acutely injured knee (when the patient cannot tolerate bending). The Lachman Test is preferred in most situations.
10. The FABER Test is also known as the Fabere or Patrick test.

Neurologic Examination

- [Equipment Needed](#)
- [General Considerations](#)
- [Cranial Nerves](#)
 - [Observation](#)
 - [I - Olfactory](#)
 - [II - Optic](#)
 - [III - Oculomotor](#)
 - [IV - Trochlear](#)
 - [V - Trigeminal](#)
 - [VI - Abducens](#)
 - [VII - Facial](#)
 - [VIII - Acoustic](#)
 - [IX - Glossopharyngeal](#)
 - [X - Vagus](#)
 - [XI - Accessory](#)
 - [XII - Hypoglossal](#)
- [Motor](#)
 - [Observation](#)
 - [Muscle Tone](#)
 - [Muscle Strength](#)
 - [Pronator Drift](#)
- [Coordination and Gait](#)
 - [Rapid Alternating Movements](#)
 - [Point-to-Point Movements](#)
 - [Romberg](#)
 - [Gait](#)
- [Reflexes](#)
 - [Deep Tendon Reflexes](#)
 - [Clonus](#)
 - [Plantar Response \(Babinski\)](#)
- [Sensory](#)
 - [General](#)
 - [Vibration](#)
 - [Subjective Light Touch](#)
 - [Position Sense](#)
 - [Dermatomal Testing](#)
 - [Pain](#)
 - [Temperature](#)
 - [Light Touch](#)
 - [Discrimination](#)
- [Notes](#)

Equipment Needed

- Reflex Hammer
- 128 and 512 (or 1024) Hz Tuning Forks
- A Snellen Eye Chart or Pocket Vision Card
- Pen Light or Otoscope
- Wooden Handled Cotton Swabs
- Paper Clips

General Considerations

- Always consider left to right symmetry
- Consider central vs. peripheral deficits
- Organize your thinking into seven categories:
 1. Mental Status
 2. Cranial Nerves
 3. Motor
 4. Coordination and Gait
 5. Reflexes
 6. Sensory
 7. Special Tests

Cranial Nerves

Observation

- Ptosis (III)
- Facial Droop or Asymmetry (VII)
- Hoarse Voice (X)
- Articulation of Words (V, VII, X, XII)
- Abnormal Eye Position (III, IV, VI)
- Abnormal or Asymmetrical Pupils (II, III)

I - Olfactory

Not Normally Tested [1]

II - Optic

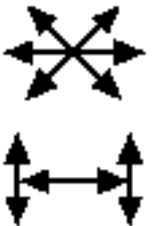- Examine the Optic Fundi
 - [Covered elsewhere...](#)
- Test Visual Acuity
 1. Allow the patient to use their glasses or contact lens if available. You are interested in the patient's best **corrected** vision.
 2. Position the patient 20 feet in front of the Snellen eye chart (or hold a Rosenbaum pocket card at a 14 inch "reading" distance).
 3. Have the patient cover one eye at a time with a card.
 4. Ask the patient to read progressively smaller letters until they can go no further.
 5. Record the smallest line the patient read successfully (20/20, 20/30, etc.) [2]
 6. Repeat with the other eye.
- Screen Visual Fields by Confrontation
 1. Stand two feet in front of the patient and have them look into your eyes.



2. Hold your hands about one foot away from the patient's ears, and wiggle a finger on one hand. [3]
 3. Ask the patient to indicate which side they see the finger move.
 4. Repeat two or three times to test both temporal fields.
 5. If an abnormality is suspected, test the four quadrants of each eye while asking the patient to cover the opposite eye with a card. ++ [4]
- Test Pupillary Reactions to Light
 1. Dim the room lights as necessary.
 2. Ask the patient to look into the distance.
 3. Shine a bright light obliquely into each pupil in turn.
 4. Look for both the direct (same eye) and consensual (other eye) reactions.
 5. Record pupil size in mm and any asymmetry or irregularity.
 6. If abnormal, proceed with the test for accommodation.
 - Test Pupillary Reactions to Accommodation [5] ++
 1. Hold your finger about 10cm from the patient's nose.
 2. Ask them to alternate looking into the distance and at your finger.
 3. Observe the pupillary response in each eye.

III - Oculomotor

- Observe for Ptosis
- Test Extraocular Movements
 1. Stand or sit 3 to 6 feet in front of the patient.
 2. Ask the patient to follow your finger with their eyes without moving their head.
 3. Check gaze in the six cardinal directions using a cross or "H" pattern.
 4. Pause during upward and lateral gaze to check for nystagmus. [6]
 5. Check convergence by moving your finger toward the bridge of the patient's nose.
- Test Pupillary Reactions to Light ([See Above](#))

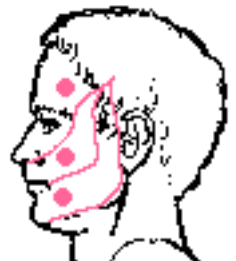

IV - Trochlear

Test Extraocular Movements (Inward and Down Movement, [See Above](#))

V - Trigeminal

- Test Temporal and Masseter Muscle Strength
 1. Ask patient to both open their mouth and clench their teeth.
 2. Palpate the temporal and masseter muscles as they do this.
- Test the Three Divisions for Pain Sensation
 1. Explain what you intend to do.
 2. Use a suitable sharp object to test the forehead, cheeks, and jaw on both sides. [7]
 3. Substitute a blunt object occasionally and ask the patient to report "sharp" or "dull."
- If you find an abnormality then:
 1. Test the three divisions for temperature sensation with a tuning fork heated or cooled by water. ++
 2. Test the three divisions for sensation to light touch using a wisp of cotton. ++
- Test the Corneal Reflex ++
 1. Ask the patient to look up and away.
 2. From the other side, touch the cornea lightly with a fine wisp of cotton.
 3. Look for the normal blink reaction of **both** eyes.



4. Repeat on the other side.
5. Use of contact lens may decrease this response.

VI - Abducens

Test Extraocular Movements (Lateral Movement, [See Above](#))

VII - Facial

- Observe for Any Facial Droop or Asymmetry
- Ask Patient to do the following, note any lag, weakness, or assymetry:
 1. Raise eyebrows [8]
 2. Close both eyes to resistance
 3. Smile
 4. Frown
 5. Show teeth
 6. Puff out cheeks
- Test the Corneal Reflex ([See Above](#)) ++

VIII - Acoustic

- Screen Hearing [9]
 1. Face the patient and hold out your arms with your fingers near each ear.
 2. Rub your fingers together on one side while moving the fingers noiselessly on the other.
 3. Ask the patient to tell you when and on which side they hear the rubbing.
 4. Increase intensity as needed and note any assymetry.
 5. If abnormal, proceed with the Weber and Rinne tests.
- Test for Lateralization (Weber) ++
 1. Use a 512 Hz or 1024 Hz tuning fork.
 2. Start the fork vibrating by tapping it on your opposite hand.
 3. Place the base of the tuning fork firmly on top of the patient's head.
 4. Ask the patient where the sound appears to be coming from (normally in the midline).
- Compare Air and Bone Conduction (Rinne) ++
 1. Use a 512 Hz or 1024 Hz tuning fork.
 2. Start the fork vibrating by tapping it on your opposite hand.
 3. Place the base of the tuning fork against the mastoid bone behind the ear.
 4. When the patient no longer hears the sound, hold the end of the fork near the patient's ear (air conduction is normally greater than bone conduction).
- Vestibular Function is Not Normally Tested

IX - Glossopharyngeal

[See Vagus Nerve](#)

X - Vagus

- Listen to the patient's voice, is it hoarse or nasal?
- Ask Patient to Swallow
- Ask Patient to Say "Ah"
 - Watch the movements of the soft palate and the pharynx.
- Test Gag Reflex (Unconscious/Uncooperative Patient) ++
 1. Stimulate the back of the throat on each side.

2. It is normal to gag after each stimulus.

XI - Accessory

- From behind, look for atrophy or asymmetry of the trapezius muscles.
- Ask patient to shrug shoulders against resistance.
- Ask patient to turn their head against resistance. Watch and palpate the sternomastoid muscle on the opposite side.

XII - Hypoglossal

- Listen to the articulation of the patient's words.
- Observe the tongue as it lies in the mouth
- Ask patient to:
 1. Protrude tongue [10]
 2. Move tongue from side to side

Motor

Observation

- Involuntary Movements
- Muscle Symmetry
 - Left to Right
 - Proximal vs. Distal
- Atrophy
 - Pay particular attention to the hands, shoulders, and thighs.
- Gait

Muscle Tone

1. Ask the patient to relax.
2. Flex and extend the patient's fingers, wrist, and elbow.
3. Flex and extend patient's ankle and knee.
4. There is normally a small, continuous resistance to passive movement.
5. Observe for decreased (flaccid) or increased (rigid/spastic) tone.

Muscle Strength

- Test strength by having the patient move against your resistance.
- Always compare one side to the other.
- Grade strength on a scale from 0 to 5 "out of five":

Grading Motor Strength	
Grade	Description
0/5	No muscle movement
1/5	Visible muscle movement, but no movement at the joint
2/5	Movement at the joint, but not against gravity
3/5	Movement against gravity, but not against added resistance

4/5	Movement against resistance, but less than normal
5/5	Normal strength

- Test the following:
 1. Flexion at the elbow (C5, C6, biceps)
 2. Extension at the elbow (C6, C7, C8, triceps)
 3. Extension at the wrist (C6, C7, C8, radial nerve)
 4. Squeeze two of your fingers as hard as possible ("grip," C7, C8, T1) [[10](#)]
 5. Finger abduction (C8, T1, ulnar nerve)
 6. Opposition of the thumb (C8, T1, median nerve)
 7. Flexion at the hip (L2, L3, L4, iliopsoas)
 8. Adduction at the hips (L2, L3, L4, adductors)
 9. Abduction at the hips (L4, L5, S1, gluteus medius and minimus)
 10. Extension at the hips (S1, gluteus maximus) [[12](#)]
 11. Extension at the knee (L2, L3, L4, quadriceps) [[10](#)]
 12. Flexion at the knee (L4, L5, S1, S2, hamstrings)
 13. Dorsiflexion at the ankle (L4, L5)
 14. Plantar flexion (S1) [[12](#)]

Pronator Drift

1. Ask the patient to stand for 20-30 seconds with both arms straight forward, palms up, and eyes closed.
2. Instruct the patient to keep the arms still while you tap them briskly downward.
3. The patient will not be able to maintain extension and supination (and "drift into pronation) with upper motor neuron disease.

Coordination and Gait

Rapid Alternating Movements

1. Ask the patient to strike one hand on the thigh, raise the hand, turn it over, and then strike it back down as fast as possible.
2. Ask the patient to tap the distal thumb with the tip of the index finger as fast as possible.
3. Ask the patient to tap your hand with the ball of each foot as fast as possible.

Point-to-Point Movements

1. Ask the patient to touch your index finger and their nose alternately several times. Move your finger about as the patient performs this task.
2. Hold your finger still so that the patient can touch it with one arm and finger outstretched. Ask the patient to move their arm and return to your finger with their eyes closed.
3. Ask the patient to place one heel on the opposite knee and run it down the shin to the big toe. Repeat with the patient's eyes closed.

Romberg

1. Be prepared to catch the patient if they are unstable.
2. Ask the patient to stand with the feet together and eyes closed for 5-10 seconds without support.
3. The test is said to be positive if the patient becomes unstable (indicating a vestibular or proprioceptive problem).

Gait

Ask the patient to:

1. Walk across the room, turn and come back
2. Walk heel-to-toe in a straight line
3. Walk on their toes in a straight line
4. Walk on their heels in a straight line
5. Hop in place on each foot
6. Do a shallow knee bend
7. Rise from a sitting position

Reflexes

Deep Tendon Reflexes

- The patient must be relaxed and positioned properly before starting.
- Reflex response depends on the force of your stimulus. Use no more force than you need to provoke a definite response.
- Reflexes can be reinforced by having the patient perform isometric contraction of other muscles (clenched teeth).
- Reflexes should be graded on a 0 to 4 "plus" scale:

Tendon Reflex Grading Scale	
Grade	Description
0	Absent
1+ or +	Hypoactive
2+ or ++	"Normal"
3+ or +++	Hyperactive without clonus
4+ or ++++	Hyperactive with clonus

- Biceps (C5, C6)
 1. The patient's arm should be partially flexed at the elbow with the palm down.
 2. Place your thumb or finger firmly on the biceps tendon.
 3. Strike your finger with the reflex hammer.
 4. You should feel the response even if you can't see it.
- Triceps (C6, C7)
 1. Support the upper arm and let the patient's forearm hang free.
 2. Strike the triceps tendon above the elbow with the broad side of the hammer.
 3. If the patient is sitting or lying down, flex the patient's arm at the elbow and hold it close to the chest.
- Brachioradialis (C5, C6)
 1. Have the patient rest the forearm on the abdomen or lap.
 2. Strike the radius about 1-2 inches above the wrist.
 3. Watch for flexion and supination of the forearm.
- Abdominal (T8, T9, T10, T11, T12)
 1. Use a blunt object such as a key or tongue blade.
 2. Stroke the abdomen lightly on each side in an inward and downward direction above (T8, T9, T10) and below the umbilicus (T10, T11, T12).
 3. Note the contraction of the abdominal muscles and deviation of the umbilicus towards the

stimulus.

- Knee (L2, L3, L4)
 1. Have the patient sit or lie down with the knee flexed.
 2. Strike the patellar tendon just below the patella.
 3. Note contraction of the quadriceps and extension of the knee.
- Ankle (S1, S2)
 1. Dorsiflex the foot at the ankle.
 2. Strike the Achilles tendon.
 3. Watch and feel for plantar flexion at the ankle.

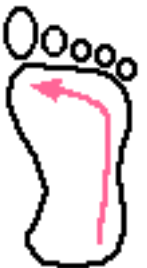Clonus

If the reflexes seem hyperactive, test for ankle clonus: [++](#)

1. Support the knee in a partly flexed position.
2. With the patient relaxed, quickly dorsiflex the foot.
3. Observe for rhythmic oscillations.

Plantar Response (Babinski)

1. Stroke the lateral aspect of the sole of each foot with the end of a reflex hammer or key.
2. Note movement of the toes, normally flexion (withdrawal).
3. Extension of the big toe with fanning of the other toes is abnormal. This is referred to as a positive Babinski.



Sensory

General

- Explain each test before you do it.
- Unless otherwise specified, the patient's eyes should be closed during the actual testing.
- Compare symmetrical areas on the two sides of the body.
- Also compare distal and proximal areas of the extremities.
- When you detect an area of sensory loss map out its boundaries in detail.

Vibration

- Use a low pitched tuning fork (128Hz).
 1. Test with a **non-vibrating** tuning fork first to ensure that the patient is responding to the correct stimulus.
 2. Place the stem of the fork over the distal interphalangeal joint of the patient's index fingers and big toes.
 3. Ask the patient to tell you if they feel the vibration.
- If vibration sense is impaired proceed proximally: [++](#)
 1. Wrists
 2. Elbows
 3. Medial malleoli
 4. Patellas
 5. Anterior superior iliac spines
 6. Spinous processes
 7. Clavicles

Subjective Light Touch

- Use your fingers to touch the skin lightly on both sides simultaneously. [13]
- Test several areas on both the upper and lower extremities.
- Ask the patient to tell you if there is difference from side to side or other "strange" sensations.

Position Sense

1. Grasp the patient's big toe and hold it away from the other toes to avoid friction. ++
2. Show the patient "up" and "down."
3. With the patient's eyes closed ask the patient to identify the direction you move the toe.
4. If position sense is impaired move proximally to test the ankle joint. ++
5. Test the fingers in a similar fashion.
6. If indicated move proximally to the metacarpophalangeal joints, wrists, and elbows. ++

Dermatomal Testing

If vibration, position sense, and subjective light touch are normal in the fingers and toes you may assume the rest of this exam will be normal. ++

Pain

- Use a suitable sharp object to test "sharp" or "dull" sensation. [7]
- Test the following areas:
 1. Shoulders (C4)
 2. Inner and outer aspects of the forearms (C6 and T1)
 3. Thumbs and little fingers (C6 and C8)
 4. Front of both thighs (L2)
 5. Medial and lateral aspect of both calves (L4 and L5)
 6. Little toes (S1)

Temperature

- Often omitted if pain sensation is normal. ++
- Use a tuning fork heated or cooled by water and ask the patient to identify "hot" or "cold."
- Test the following areas:
 1. Shoulders (C4)
 2. Inner and outer aspects of the forearms (C6 and T1)
 3. Thumbs and little fingers (C6 and C8)
 4. Front of both thighs (L2)
 5. Medial and lateral aspect of both calves (L4 and L5)
 6. Little toes (S1)

Light Touch

- Use a fine whisp of cotton or your fingers to touch the skin lightly.
- Ask the patient to respond whenever a touch is felt.
- Test the following areas:
 1. Shoulders (C4)
 2. Inner and outer aspects of the forearms (C6 and T1)
 3. Thumbs and little fingers (C6 and C8)
 4. Front of both thighs (L2)
 5. Medial and lateral aspect of both calves (L4 and L5)

6. Little toes (S1)

Discrimination

Since these tests are dependent on touch and position sense, they cannot be performed when the tests above are clearly abnormal. ++

- Graphesthesia
 1. With the blunt end of a pen or pencil, draw a large number in the patient's palm.
 2. Ask the patient to identify the number.
 - Stereognosis
 1. Use as an alternative to graphesthesia. ++
 2. Place a familiar object in the patient's hand (coin, paper clip, pencil, etc.).
 3. Ask the patient to tell you what it is.
 - Two Point Discrimination
 1. Use in situations where more quantitative data are needed, such as following the progression of a cortical lesion. ++
 2. Use an opened paper clip to touch the patient's finger pads in two places simultaneously.
 3. Alternate irregularly with one point touch.
 4. Ask the patient to identify "one" or "two."
 5. Find the minimal distance at which the patient can discriminate.
-

Notes

1. For more information refer to *A Guide to Physical Examination and History Taking, Sixth Edition* by Barbara Bates, published by Lippincott in 1995.
2. Visual acuity is reported as a pair of numbers (20/20) where the first number is how far the patient is from the chart and the second number is the distance from which the "normal" eye can read a line of letters. For example, 20/40 means that at 20 feet the patient can only read letters a "normal" person can read from twice that distance.
3. You may, instead of wiggling a finger, raise one or two fingers (unilaterally or bilaterally) and have the patient state how many fingers (total, both sides) they see. To test for **neglect**, on some trials wiggle your right and left fingers simultaneously. The patient should see movement in both hands.
4. Additional Testing - Tests marked with (++) may be skipped unless an abnormality is suspected.
5. PERRLA is a common abbreviation that stands for "Pupils Equal Round Reactive to Light and Accommodation." The use of this term is so routine that it is often used incorrectly. If you did not specifically check the accommodation reaction use the term PERRL. Pupils with a diminished response to light but a normal response to accommodation (Argyll-Robertson Pupils) are a sign of neurosyphilis.
6. Nystagmus is a rhythmic oscillation of the eyes. Horizontal nystagmus is described as being either "leftward" or "rightward" based on the direction of the **fast** component.
7. Testing Pain Sensation - Use a new object for each patient. Break a wooden cotton swab to create a sharp end. The cotton end can be used for a dull stimulus. Do **not** go from patient to patient with a safety pin. Do **not** use non-disposable instruments such as those found in certain reflex hammers. Do **not** use very sharp items such as hypodermic needles.
8. Central vs Peripheral - With a unilateral central nervous system lesion (stroke), function is preserved over the upper part of the face (forehead, eyebrows, eyelids). With a peripheral nerve lesion (Bell's Palsy), the entire face is involved.
9. The hearing screening procedure presented by Bates on page 181 is more complex than necessary. The technique presented in this syllabus is preferred.
10. Deviation of the tongue or jaw is **toward** the side of the lesion.

11. Although it is often tested, grip strength is **not** a particularly good test in this context. Grip strength may be omitted if finger abduction and thumb opposition have been tested.
12. The "anti-gravity" muscles are difficult to assess adequately with manual testing. Useful alternatives include: walk on toes (plantarflexion); rise from a chair without using the arms (hip extensors and knee extensors); step up on a step, once with each leg (hip extensors and knee extensors).
13. Subjective light touch is a quick survey for "strange" or asymmetrical sensations only, not a formal test of dermatomes.