

PIG DIGESTIVE SYSTEM

It is not easy to study the digestive organs of a human. However, anatomy of the human digestive system can be studied by examining the digestive system of a pig, an animal similar to a human. A pig resembles a human both internally and externally in many ways.

The pigs you will dissect are called fetal pigs. Fetal pigs have not been born. They were removed from their mother's reproductive tract before birth. Evidence that they are fetal can be seen by examining the stomach area for the attached umbilical cord.

Your fetal pig is to be used to observe other systems in later investigations. Therefore, it is important that directions for dissection be followed exactly. Do not remove any organ or structure unless you are directed to do so.

In this investigation, you will

- properly dissect a fetal pig to examine the digestive system.
- identify the major organs and structures of a pig's digestive system.
- label diagrams of a pig's digestive system.

Materials

fetal pig	microscope slide
cissors	coverslip
razor blade (single-edge)	plastic bag (large)
microscope	water

Procedure

NOTE: Although this investigation is designed to examine the digestive system parts, structures from other systems will be identified in the process. You may need to consult your text to identify the systems to which these other structures belong.

- Determine if your pig is male or female. Both sexes have a double row of nipples along the ventral body surface. Therefore, these structures will not help you determine sex. A male pig has a small genital opening on the ventral (stomach) body surface below the area where the umbilical cord enters. A female pig has a vaginal opening next to the anus. These two openings are found under the pig's tail. A male pig has only the anal opening.

- With scissors, remove the skin in the neck and head region of your pig as shown in Figure 59-1.

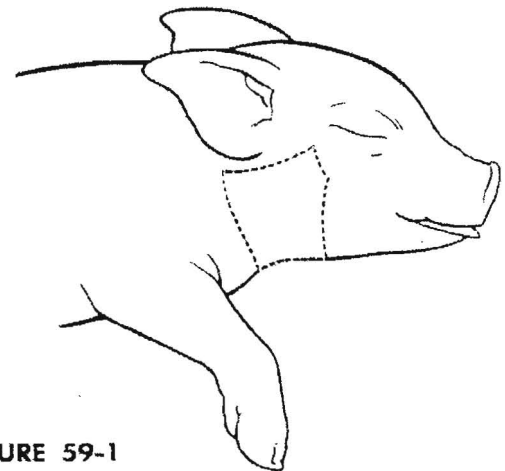


FIGURE 59-1

Be sure to remove only skin tissue. Push aside or remove the muscle and connective tissue if necessary.

Under the muscle are rough or coarse flat tissues. The larger of the tissues is the parotid salivary gland.

A smaller, more compact triangular salivary gland lies beneath the parotid. This gland is the submaxillary salivary gland. A third salivary gland also is present but is not easily observable.

Salivary ducts lead from the glands toward the animal's mouth. One main duct is Whartons duct. It carries saliva from the salivary glands to the mouth.

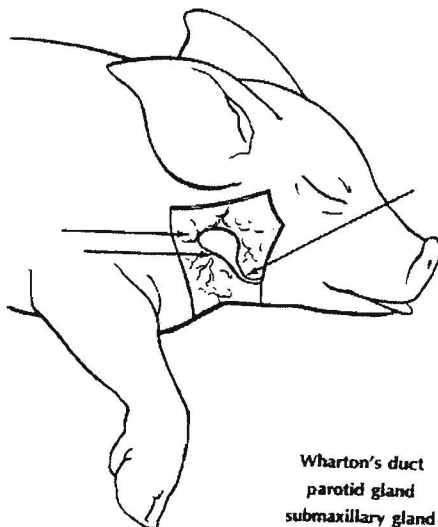
- Label the indicated structures in Figure 59-2.
- Open the pig's mouth. The mouth region, or oral cavity, has structures associated with digestion.

The tongue is used to mix food and push it into the pharynx. The surface of the tongue is rough because of the presence of taste buds. Taste buds sometimes are called papillae.

The roof of the mouth is called the palate. The front portion is the hard palate. The portion toward the back of the mouth is the soft palate.

The pharynx joins the esophagus at the rear of the mouth. It is the tube from the throat to the stomach.

Teeth may or may not be evident in your pig. Rub your finger along the pig's gums to determine if teeth are beginning to emerge through the gum. You may or may not find teeth depending on the



Wharton's duct
parotid gland
submaxillary gland

FIGURE 59-2

age of the pig.

- Position your pig so that its ventral surface is up and its head is away from you.
- Using scissors, cut through the skin and muscle along the lines designated in Figure 59-3. DO NOT remove the umbilical cord.

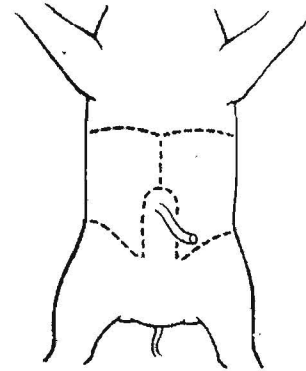


FIGURE 59-3

- Identify and label the organs indicated in Figure 59-4 and describe below.

The liver is a large, lobed, brown organ occupying the top portion of the abdominal cavity.

A coiled mass of thick, tubelike tissue is the large intestine.

The small intestine is a coiled mass of thin, tubelike tissue.

Above the pig's liver is a thin muscle called the diaphragm. It separates the abdominal cavity from the thoracic (chest) cavity.

- Pull the umbilical cord down between the hind legs of your pig. The umbilical cord just after entering the pig's body divides into two blood vessels. These two vessels are called the umbilical blood vessels. They lie on each side of a flat structure called the urinary bladder.
- Raise your pig's liver and push the intestines toward the left with your fingers. Organs not previously visible should now be revealed.

A saclike structure attached to the underside of the liver is the gall bladder. It is usually green and is partly embedded in the liver.

Leading from the gall bladder and extending along the underside of the liver is a thin tube called the bile duct.

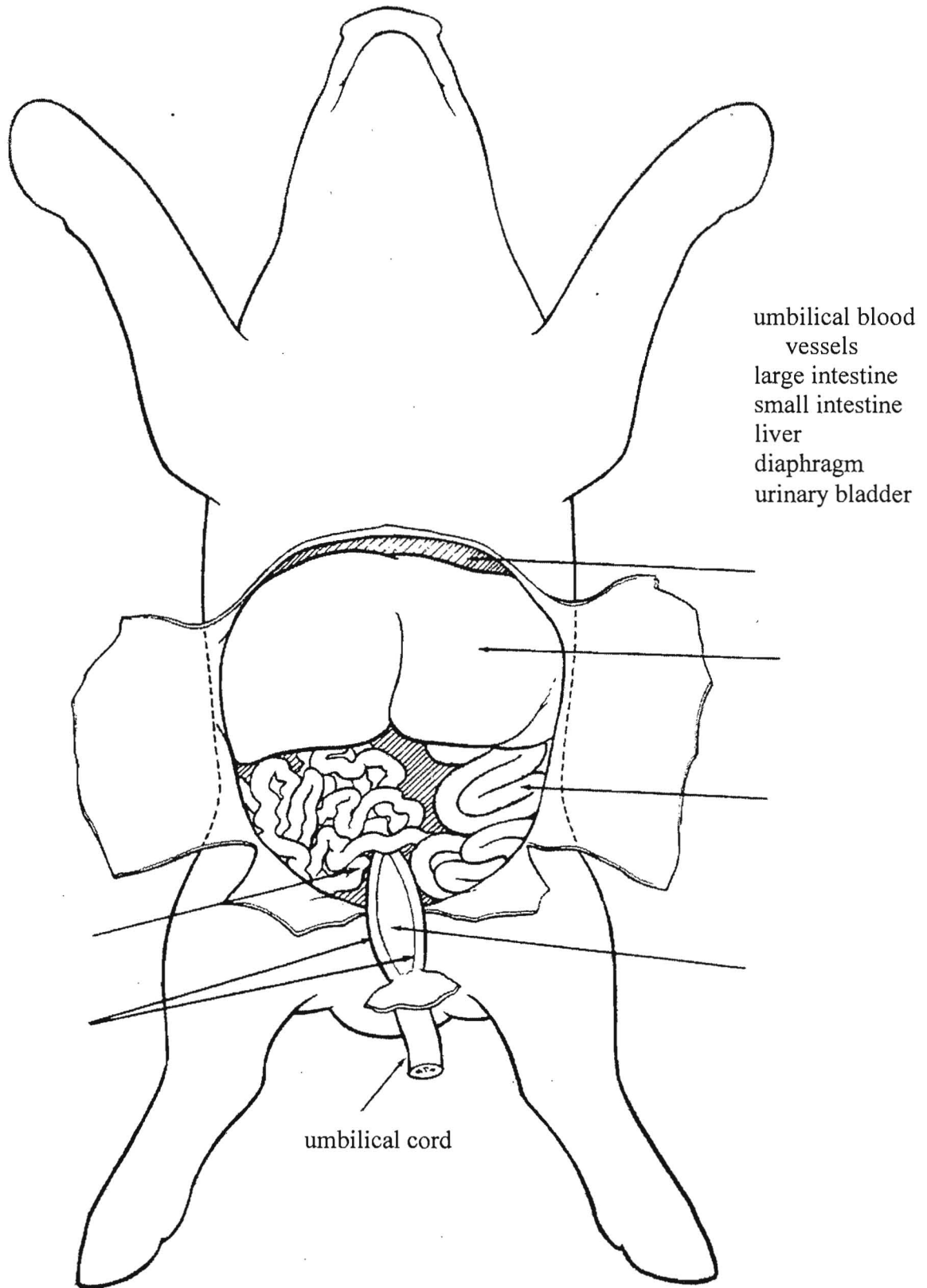


Figure 59-4

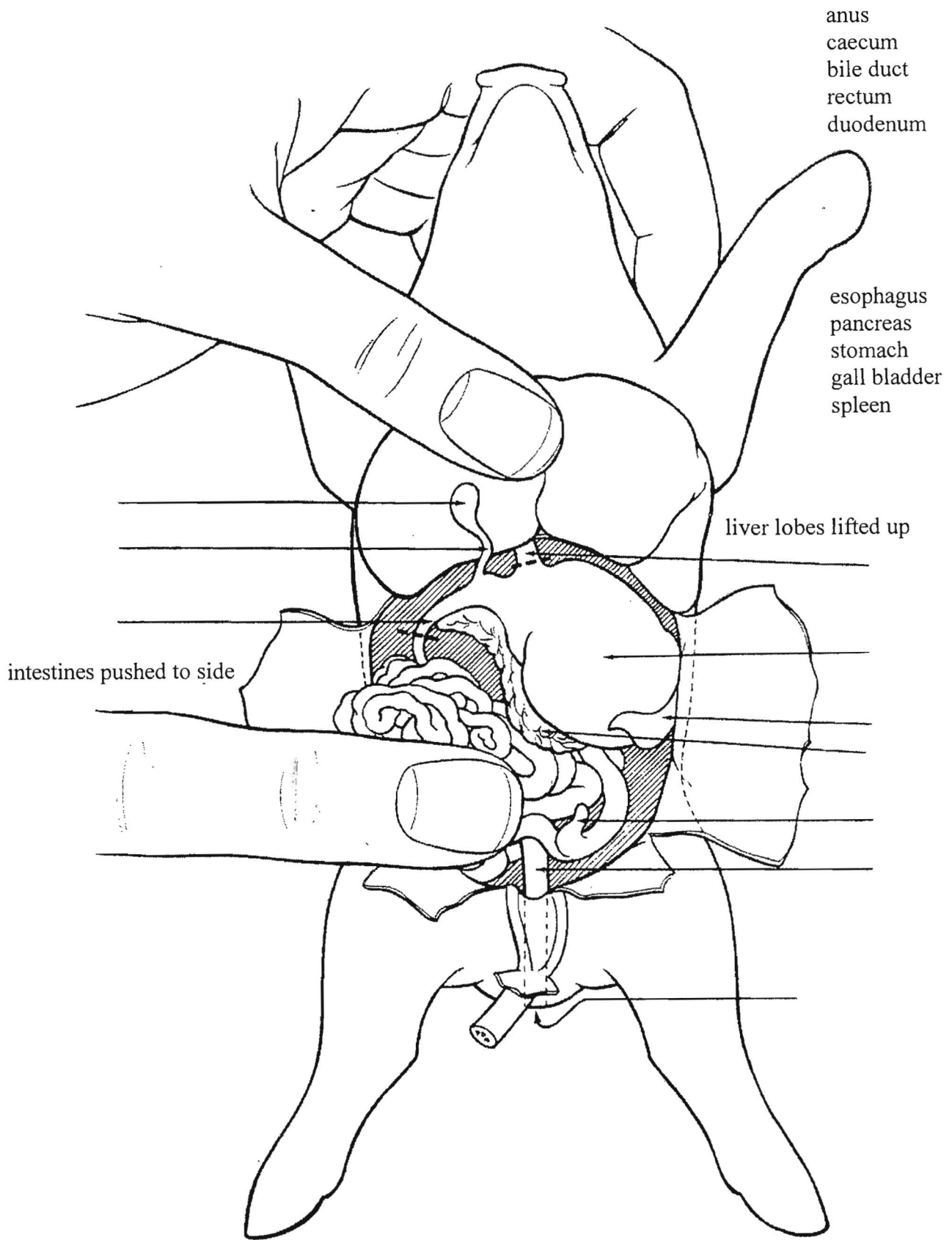


Figure 59-5

Directly below the liver on the right (pig's left side) is a large pouch. This is the stomach.

Leading into the top portion of the stomach is the esophagus. It appears to be rather short because it passes upward behind the liver.

Attached along the right edge of the stomach is a round, reddish organ. It is the spleen.

A rough or coarse organ lying directly below and extending along the underside of the stomach is the pancreas.

Extending from the stomach toward the left side (pig's right) is a tube which is the beginning section of the small intestine. This part is the duodenum. Both the pancreas and the gall bladder empty digestive chemicals into this structure. The bile duct which leads from the gall bladder to the duodenum should be visible. The duct leading from the pancreas is small and difficult to locate.

At the junction between the small and large intestines is a small, fingerlike projection. This structure is the caecum (appendix attached).

- Push the intestines as far to your left as possible. Also pull the urinary bladder and umbilical cord down.

A tube leading from the large intestine out of the abdominal cavity toward the pig's tail is the rectum.

The opening of the rectum to the outside of the animal's body is the anus.

- Locate the anus directly under the pig's tail. (Remember that female pigs have a vaginal opening in the same area as the anus.)
- Identify and label these organs in Figure 59-5.

Analysis

1. Use your text or other reference sources to list specific functions for the following organs or structures. Include the names of enzymes and other chemicals produced by the organ if appropriate.

a. salivary glands _____

b. esophagus _____

- Remove your pig's stomach by cutting as indicated in Figure 59-5. Cut only where dotted lines indicate.
- Cut the stomach in half lengthwise. Cut through and open both the duodenal and esophageal ends of the stomach.

At each stomach end is a muscular ring. These muscles close off the stomach so food stays in the stomach during the digestion that occurs there. The muscle located at the esophageal end is called the cardiac sphincter. The muscle at the duodenal end is the pyloric sphincter. Label these muscle rings on Figure 59-6.

- Remove a short length (about 2 cm) of small intestine. With a sharp razor blade, cut off as thin a slice of intestine in a cross sectional cut as possible.

- Mount this thin slice on a microscope slide. Add water and a coverslip. Observe the slide under low power magnification of your microscope.

The tiny, fingerlike projections are villi.

- Place your pig in a plastic bag and put it where your teacher directs. You will use your pig for other investigations.

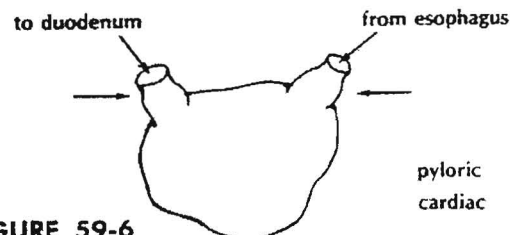


FIGURE 59-6

c. stomach _____



d. liver _____

e. gall bladder _____

f. pancreas _____

g. small intestine _____

h. large intestine _____

i. villi _____

2. Using diagrams of the human digestive system for comparison, explain how a pig's large intestine differs from a human's. _____

3. List in order the organs through which food actually passes. Start with the mouth and end with the anus.

4. a. List those parts you examined that were not digestive system structures. _____

b. To what systems do they belong? _____

The heart of any animal is rarely thought of as a muscle. However, the heart is a muscle. The heart is muscle tissue that can contract and relax. The heart is a pump that sends blood to all parts of an animal's body.

In this investigation, you will

- identify major blood vessels and internal and external heart structures on a heart diagram.
- identify major blood vessels and internal and external heart structures of a pig heart.
- describe the blood composition in all major blood vessels and heart chambers using the terms oxygenated and deoxygenated.

Materials

fetal pig
razor blade (single-edge) or scalpel

scissors
dissecting pan

forceps

Procedure

Part A. Introduction to the Heart

- Study Figure 61-1 to determine the names and locations of all major blood vessels and heart structures.

Note that labels indicating left and right sides appear to be reversed. This is a front view of the heart.

- Describe the oxygen content of blood in Table 61-1 as it should be in an animal. Use the terms deoxygenated and oxygenated. Use the following statements as a guide.

All blood vessels bringing blood to the heart's right side and leaving from the right ventricle contain blood that is deoxygenated (Figure 61-1). Deoxygenated blood is blood that is low in oxygen and high in carbon dioxide.

All blood vessels bringing blood to the heart's left side and leaving from the left ventricle contain oxygenated blood (Figure 61-1). Oxygenated blood is blood that is high in oxygen and low in carbon dioxide.

Part B. Pig Heart

- Open your fetal pig's chest cavity by using scissors to cut through the rib cage. Cut in a straight line along the middle of the ventral surface up toward the chin.

The heart is located between the lungs. It is enclosed in a tough membrane called the pericardium. Partially covering the heart is a gland called the thymus.

- Remove as much of the pericardium and thymus as necessary to totally expose the heart. DO NOT remove any lung tissue.
- Use Figure 61-1 and Table 61-2 to locate and identify the parts of your pig heart.
- Label those structures shown in Figure 61-2.

NOTE: Those blood vessels that pass in back of the heart and cannot be seen from a front view are shown with dashed lines.

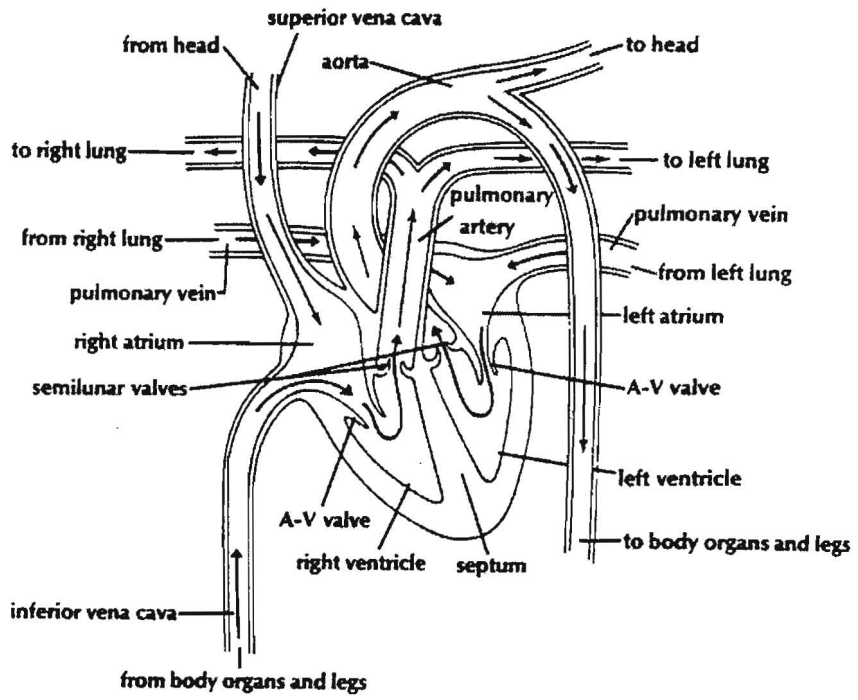


FIGURE 61-1

right

left

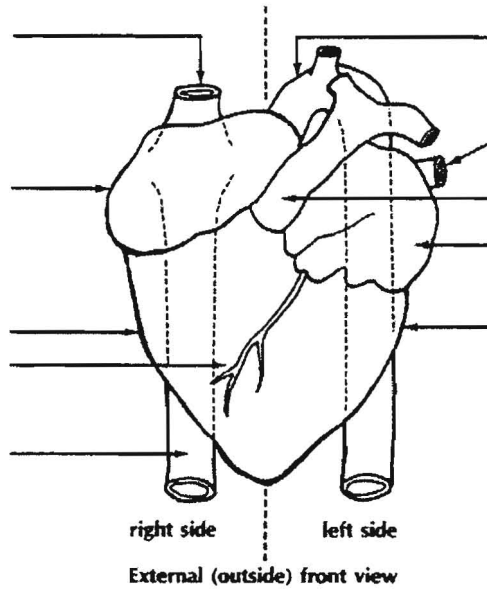


FIGURE 61-2

Table 61.1 Oxygen Content of Blood

Chamber or vessel	Oxygenated or deoxygenated
Left ventricle	
Right ventricle	
Left atrium	
Right atrium	
Pulmonary artery	
Pulmonary vein	
Superior vena cava	
Inferior vena cava	
Aorta	

Part C. Internal Anatomy

- Cut the vessels leading to and from the heart. Also, cut any pericardium or other tissue that may be holding the heart. Remove the heart from the pig. DO NOT damage or cut the lungs.
- Cut the heart into two equal halves by using a sawing motion with a razor blade. Cut the heart into front (ventral) and back (dorsal) halves. DO NOT cut the heart into left and right halves.
- Examine the cut surface of the dorsal half.
- Use Table 61-3 and Figure 61-3 to locate and identify the parts of your pig heart.
- Label those structures shown in Figure 61-3.

NOTE: If your slice through the heart is not centered, the diagram and your heart half may not match exactly.

Table 61-2. External (outside) Parts of Heart

Part	Location or description
Left and right atria	Top chambers of heart. Appear somewhat irregular in shape on outside.
Left and right ventricles	Bottom chambers of heart. Appear as largest part of heart and have a small blood vessel on the front side as shown in the diagram.
Pulmonary artery	Large blood vessel on front top of heart. Appears somewhat T-shaped in diagram.
Aorta	Large blood vessel at top of heart. Loops downward in back of heart.
Superior vena cava	Large blood vessel enters right atrium from the top.
Inferior vena cava	Large blood vessel enters right atrium from the bottom. Much of vessel is hidden under heart.
Pulmonary vein	Blood vessel enters heart at left atrium. (Other pulmonary vein is not shown in diagram.)
Coronary blood vessel	A small vessel on the outside of the ventricles.

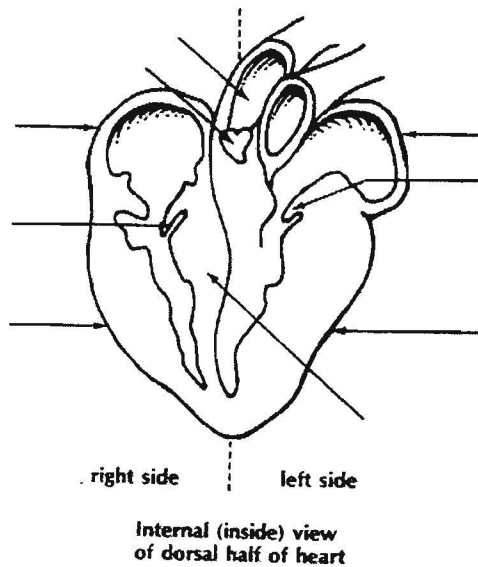


FIGURE 61-3

Table 61-3. Internal (inside) Parts of Heart

Part	Location or Description
Left and right atria	At top of heart, appear as two thin walled chambers. They may be empty or filled with blood.
Left and right ventricles	Thick-walled muscular areas that make up most of heart. Each ventricle has only a long narrow space for blood to fill. Note that size and thickness of left ventricle muscle is greater than right ventricle muscle.
Septum	A thick muscular wall that lies between the left and right ventricles.
Auricular ventricular (A-V) valves	Small flaplike structures with stringlike cords attached on their underside. These lie between atria and ventricles on each side of heart.
Aorta	Main large vessel at top of heart. Can be seen leading out of left ventricle.

Analysis

1. Use the terms oxygenated and deoxygenated to describe the composition of blood as it
 - a). enters the heart's right side. _____
 - b). leaves the heart's right side. _____
 - c). enters the lungs. _____
 - d). leaves the lungs. _____
 - e). enters the heart's left side. _____
 - f). leaves the heart's left side. _____

2. Blood is changed from an oxygenated to a deoxygenated condition or vice versa in the circulatory system.

Which change occurs in lung capillaries? _____

Which change occurs in body capillaries? _____

3. In normal circulation, where does the blood go next when it leaves the

a). aorta? _____

b). pulmonary artery? _____

c). right and left atria? _____

4. Using Figure 61-1 as a guide, tell where blood comes from in each of the following structures.

a). superior vena cava _____

b). inferior vena cava _____

c). pulmonary vein _____

5. Use your text to determine the function of

a). coronary blood vessels. _____

b). A-V valves. _____

c). semilunar valves. _____

6. The left ventricle appears to be a thicker muscle. Explain why this may be important. (HINT: Think of where blood goes when it leaves the left and the right ventricles.) _____

7. a). What major blood vessels must be cut when removing a heart during a transplant operation?

b). What major blood vessels must be cut when removing the heart and lungs together during a transplant operation? _____

c). Which operation, transplanting heart only or heart and lungs together, should be simpler in terms of the number of vessels to be cut and sewn? _____



The respiratory systems of pigs and humans are very similar. Thus, by observing fetal pig respiratory structures, you can see what your own respiratory system is like.

The respiratory system may be divided into two general areas or regions. First, several structures are located in the oral (mouth) cavity. The remaining organs are located in the thoracic (chest) cavity.

In this investigation, you will

- a. dissect your fetal pig to study the respiratory system.
- b. identify the fetal pig's respiratory organs and structures.
- c. observe the extensive branching pattern of air passages in the lungs.
- d. label diagrams of the pig and human respiratory organs.

Materials

fetal pig *scissors* *pencil*

Procedure

Part A. Oral Cavity

- Study Figure 62-1 to become familiar with the oral cavity structures of a fetal pig.
- With scissors, cut along each side of your pig's mouth to drop the lower jaw. This is necessary to observe the structures located in the back of the mouth.
- Locate the structures listed in Table 62-1 and shown in Figure 62-1 in your fetal pig. If all structures shown are not visible, extend the cuts to expose all of the mouth. You may need to cut through the jawbones.
- Label the following structures in Figure 62-1: tongue, hard palate, soft palate, nares, esophagus, epiglottis, glottis, nasopharynx.

Part B. Chest Cavity

- Extend the cut in your pig's chest cavity made during removal of the heart. Continue cutting in a straight line along the middle of the chest up to the chin.
- Locate the trachea, a long tube composed of ringlike sections extending along the middle of the chest cavity.
- Push aside muscle attached to the anterior (or top) portion of the trachea. A slight bulge in the trachea is the larynx, or voice box.
- Cut lengthwise into the larynx with scissors. Vocal cords should be visible.
- Locate the left and right lungs. These organs are composed of soft tissue and have many lobes which occupy most of the chest cavity.
- Remove any tissue covering the lower portion of the trachea. The trachea branches into each lung. These branches are the left and right bronchi.

Between the chest and abdominal cavity is a very thin muscle. This muscle, called the diaphragm, separates the thoracic cavity from the abdominal cavity and aids in inhaling and exhaling.

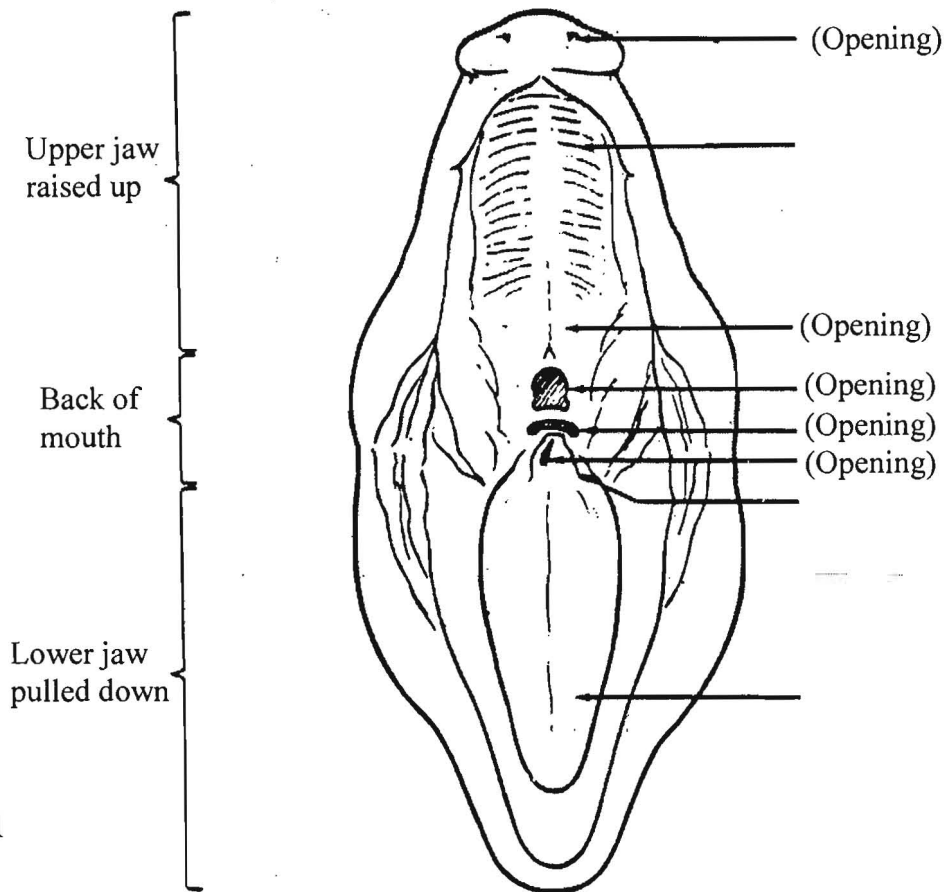


Figure 62-1

Table 62-1. Oral Cavity Structures

Part	Location and Function
Tongue	Found on lower jaw. Contains taste buds and helps to push food back into esophagus when swallowing.
Esophagus	Found at back of mouth. Leads to stomach, horizontal, narrow opening at back of mouth.
Nasopharynx (Pharynx)	Found at back of mouth. Carries air from nasal chamber or space above palate (roof of mouth) into trachea, an opening that appears somewhat round at back of mouth.
Hard palate	Found in upper jaw of pig. Front portion of roof of mouth. Separates nasal chamber (space above mouth) from mouth.
Soft palate	Found in upper jaw of pig. Back portion of roof of mouth. Separates nasal chamber from mouth.
Epiglottis	Found at back of mouth. Appears on back end of tongue. Looks somewhat like a flap. It closes shut when swallowing occurs and thus prevents food or liquid from entering lungs.
Glottis	Found at back of mouth of pig. Opening that leads to the trachea. Seen as slit under epiglottis in pig. Closed by the epiglottis.
Nares	Found at very front of upper jaw. Two small openings (nostrils) through which air passes in and out of nasal chamber.

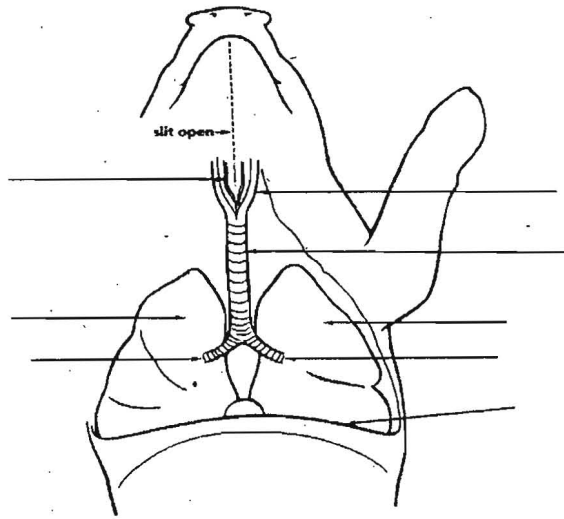


Figure 62-2

- Label the following structures in Figure 62-2: trachea, larynx, vocal cords, diaphragm, left lung, right lung, left bronchus, right bronchus. (NOTE: Left and right sides are reversed in Figure 62-2.)

Part C. Lung Anatomy

- Remove either the left or right lung by cutting with scissors where the bronchus branches from the trachea.
- Starting where the bronchus enters the lung, use a pencil to push aside all of the soft lung tissue. This should reveal the branches of the bronchus. These branches are called bronchial tubes. The bronchial tubes branch extensively in the lungs. They end as many small air sacs called alveoli. Alveoli are very thin-walled and are surrounded by capillaries of the lungs. It is in the alveoli where gas exchange occurs between blood and air.

Analysis

1. Using Figure 62-1 as a guide, locate and label the same parts shown in Figure 62-3, on a diagram of the human head and neck (side view). All shaded parts are solid. Certain structures have been named to help you.
2. Using completed Figure 62-3, list in proper order all parts or openings through which air passes on its way to the lungs. Start with the nares and end with the alveoli.

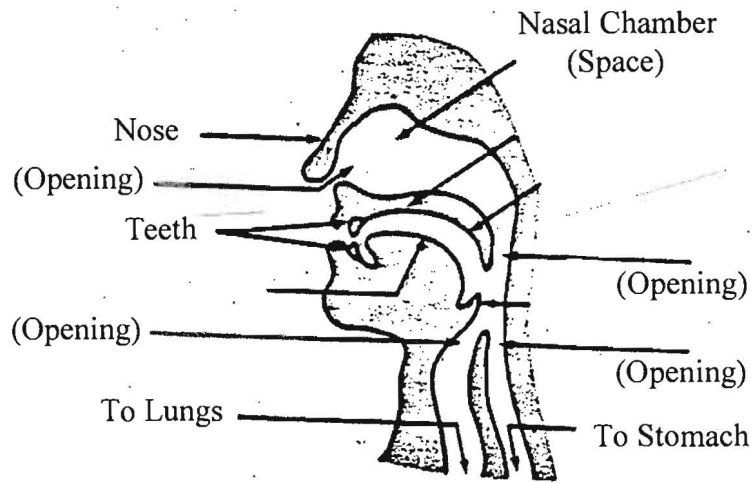


Figure 62-3

3. List the function of each of the following. Consult your text if necessary.

a. hard and soft palate _____

b. nasopharynx _____

c. epiglottis _____

d. trachea _____

e. diaphragm _____

f. alveoli _____

4. Explain why normal breathing is temporarily interrupted when you swallow. _____

5. Explain what causes food or liquids to accidentally “go down the wrong pipe.” _____

6. Why do you think each bronchus branches extensively throughout each lung? _____

7. Lung tissue that was pushed aside to expose air passages is soft. Explain why lung tissue is soft.

Fetal Pig Urinary System

The urinary and respiratory systems are often taught together because they both function in helping remove metabolic waste from the body. While the respiratory system helps rid our body of carbon-based waste products from the metabolism of organic molecules, the urinary system helps rid the body of nitrogenous waste from the metabolism of proteins (as well as some other waste products from other metabolic processes). The kidney filters the fluid portion of our blood in order to remove this nitrogenous waste and other metabolic waste from the blood.

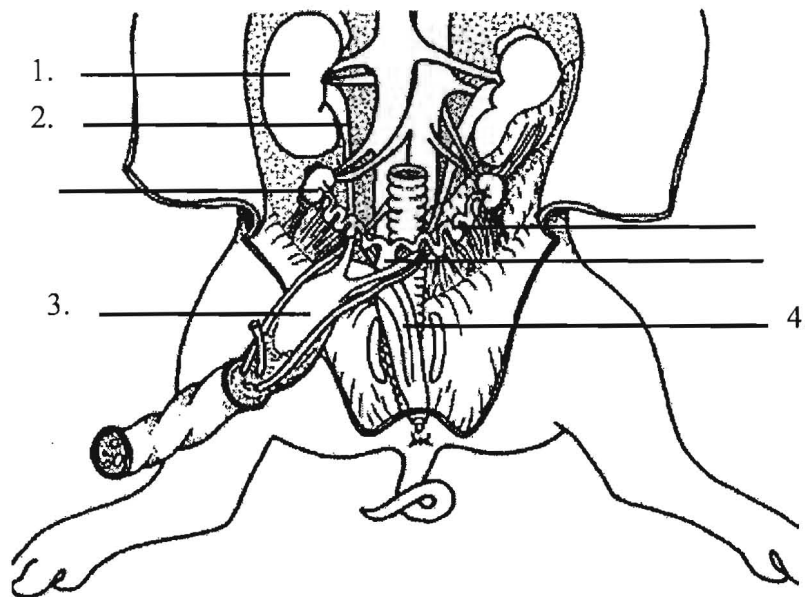
In this investigation, you will:

- dissect the fetal pig to observe the urinary system.
- identify the kidneys, ureters, and urinary bladder.
- label diagrams of the fetal pig and human urinary systems.

Procedure:

- 1) Identify the large organs lying on the dorsal wall of the abdominal cavity.
- 2) Use your blunt probe to peel away the thin membrane that separates the kidneys from the rest of the abdominal organs.
- 3) Locate the tube that originates on the concave side of the kidneys and extends along the body wall toward the posterior. This tube is the ureter.
- 4) Locate the urinary bladder on the flap that you pulled back during your dissection of the digestive system.
- 5) Find the tube that extends from the posterior end of the urinary bladder. This tube is called the urethra.

Label the numbered parts of the diagram below:



Continue on to the next page

1) List the function of each of the following:

a) Kidney _____

b) Ureters _____

c) Urinary Bladder _____

d) Urethra _____

2) An athlete's urine will often be a very concentrated, dark yellow after a strenuous workout. Give a possible explanation for this phenomenon. It may be helpful to review the section in your textbook that covers the urinary system (it is also called the excretory system in some textbooks).

