

Practical No. -8-**Blood and other specimens:****Blood is examined for the following parasites:**

- *Plasmodium* *microfilariae* *Trypanosoma* *Leishmania*

The most commonly used technique for blood examination is stained blood films. **Geimsa stain** (one of the Romanowsky stains) is usually used to stain the films. **Delafield's haematoxylin** stain is used for microfilariae. Either thick films or thin films may be used depending on the circumstances. The thick film is more sensitive in detecting parasites and also saves time in examination. However, the thin film technique causes very little distortion of the parasite, and permits species identification when it may not be possible in thick films, but many fields must be examined to detect parasites when they are few in number. Therefore, both thick and thin films must always be prepared when searching for plasmodia and trypanosomes; if a precise identification cannot be made from the thick film, the thin film will be available. Thick films should be used when searching for microfilariae.

-The most economical use of slides is achieved by making a combination thick and thin slide, i.e., a thick film and a thin film on the same slide. However, combination films must dry thoroughly (8-10 hours or overnight) before they can be satisfactorily stained. Slides for malaria should be stained the same day.

-The thin films will dry quickly and can be stained as soon as they are dry. Use the rapid Field's stain method and examine while the Giemsa stain is working. Examine for malaria parasites. If parasites are seen, a diagnosis of malaria can be made and, using the Giemsa stain, the species can be identified.

If parasites are not seen in the thin film, stain the thick film using Field's stain. Examine the thick film for malaria parasites.

Direct wet mounts of fresh whole blood (or centrifuged blood) are usually used for detection of microfilariae and trypanosomes. This only gives evidence of infection and stained films are necessary for confirmation of the species present.

in areas where malaria, trypanosomes, and/or microfilariae may all be present, both wet and stained films should be prepared and examined. If neither trypanosomes nor microfilariae occur in the region, only stained films need to be made for detection of plasmodia.

Stained blood films:**Collection of specimens:**

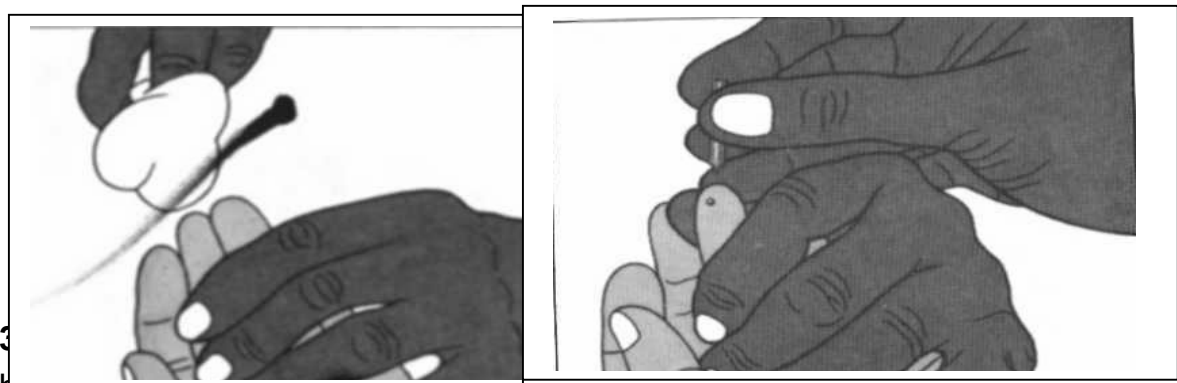Careful attention to technique is necessary in the collection of blood and the preparation of blood films. One should always be aware that a number of viral, bacterial, and parasitological diseases may be transmitted in blood.

Preparation of a thick and thin blood film on the same slide:


For routine malaria microscopy, a thin and a thick film are made on the same slide. **Technique: (Fig. 11.)**

After patient information has been recorded in the appropriate form or register, the blood films are made as follows:

1. With the patient's left hand, palm upwards, select the third finger. The thumb should never be used for adults or children. Use cotton wool lightly soaked in alcohol to clean the finger-using firm strokes to remove dirt and grease from the ball of the finger. With a clean cotton towel dry the finger, using firm strokes to stimulate blood circulation.
2. With a sterile lancet puncture the ball of the finger using a quick rolling action. By applying gentle pressure to the finger, express the first drop of blood and wipe it away with dry cotton wool. Make sure no strands of cotton remain on the finger.



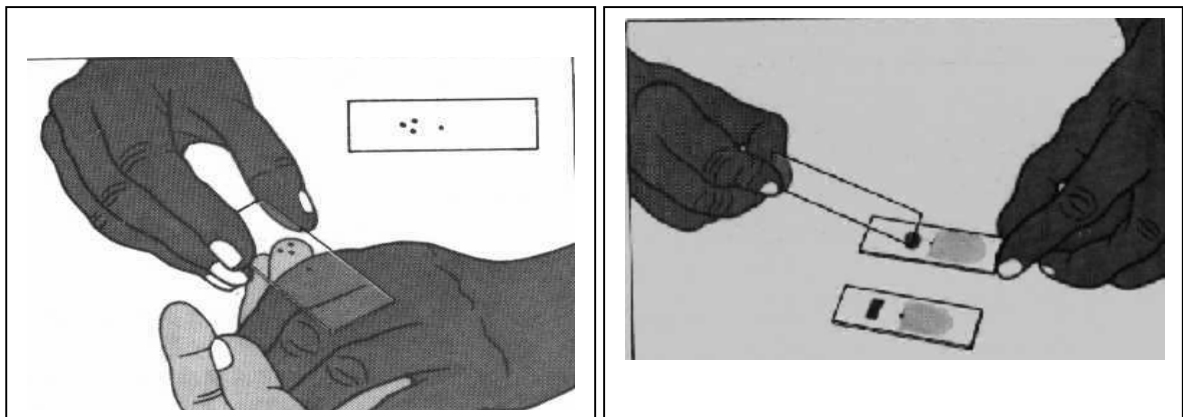
blood as follows.

Apply gentle pressure to the finger and collect a single small drop of blood, about this size , on to the middle of the slide. This is for the thin film.

Apply further pressure to express more blood and collect two or three large drops, about size $\frac{1}{2}$ cm, on to the slide about 1 cm from the drop intended for the thin film as illustrated.

Wipe the remaining blood away from with cotton wool. **(Fig. 12.)**

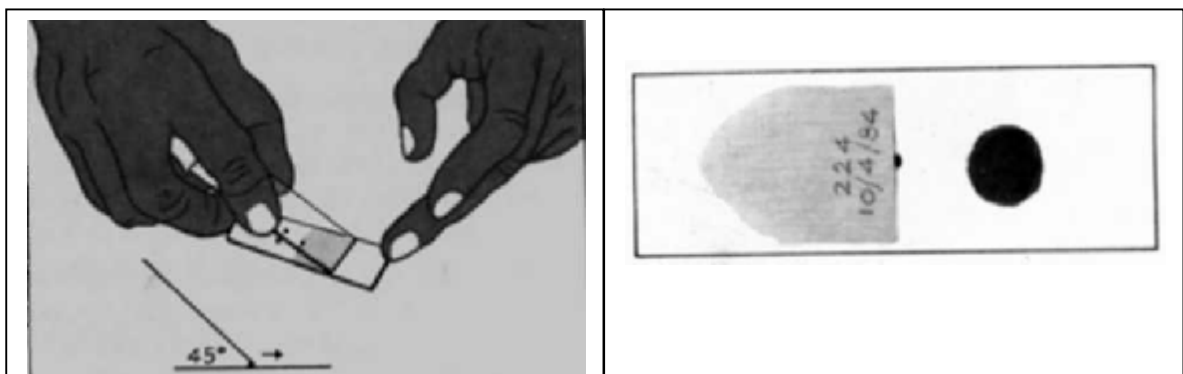
4. Thin film :Using another another clean slide as a “ spreader”, and with the slide with the blood drops resting on a flat, firm surface, touch the small drop with the spreader and allow the blood to run along its edge. Firmly push the spreader along the slide, away from the largest drops, keeping the spreader at an angle of 45° . Make sure the spreader is in even contact with the surface of the slide all the time the blood is being spread. The blood film should not extend to the edges of the slide in order to prevent infection of the investigator.



5. Thick film :Always handles slides by the edges, or by a corner, to make the thick film as follows:

Using the corner of the spreader, quickly join the larger drops of blood and spread them to make an even, thick film. The blood should not be excessively stirred but can be spread in a circular or rectangular form with 3-6 movements.

6. Allow the thick film to dry in a flat, level position protected from flies, dust, and extreme heat. Label the dry film with a pen or marker pencil by writing across the thicker portion of the thin film the patient's name or number and date (as shown below). Do not use a ball pen to label the slide. **(Fig. 13.)**



7. Warp the dry slide in clean paper, and dispatch with the patient's record form to the laboratory as soon as possible.
8. The slide used for spreading the blood films must be disinfected and could then be used for the next patient, another clean slide from the pack being used

Staining blood films with Giemsa stain:

Regular method for staining thick and thin blood films on the same slide:

For optimum staining, the thick and thin films should be made on separate slides and different concentrations and times used for staining. This is often not possible and the thick and thin films are generally made on the same slide. When this is done, good-quality staining of the thick film is of primary importance. Best results are obtained if the blood films have dried overnight.

1. Fix the thin film by adding 3 drops of **methanol**, or dipping it in a container of **methanol** for a few seconds. With prolonged fixation it may be difficult to demonstrate **Schuffner's** dots and **Maurer's** dots. To permit dehaemoglobinization, the thick film should not be fixed; therefore avoid exposure of the film to methanol or methanol vapour.
2. Place the slides back to back in a staining dish.
3. Prepare a 3% Giemsa solution in buffered, distilled or deionized water, pH 7.2, in sufficient quantity to fill the number of dishes being used. Mix the stain well.
4. Pour the stain gently into the dish, until the dishes are totally covered .
5. Allow staining for 30-45 minutes out of sunlight.
6. Pour clean water gently into the dish to float off the iridescent scum on the surface of the stain. Alternatively, gently immerse the whole dish in a vessel filled with clean water.
7. Gently pour off the remaining stain, and rinse again in clean water for a few seconds. Pour the water off.
8. Remove the slides one by one and place them in a slide rack to drain and dry, film side downwards, making sure that the film does not touch the slide rack.

Staining blood films with Delafield's haematoxylin stain for microfilariae:

Materials and reagents:

Five staining dishes

Ether-ethanol fixative (reagent no.8)

Hydrochloric acid-water destain (reagent no. 15)

Delafield's haematoxylin stain (reagent no. 6). This stain may be purchased as a prepared solution.

Technique:

1. Prepare thick film's of blood obtained by finger-prick. Allow to dry for 8-10 hours or overnight.
2. Prepare staining dishes as follows:
 - dish 1--tap water
 - dish 2--ether-ethanol
 - dish 3--Delafield's haematoxylin stain
 - dish 4--hydrochloric acid-water (0.05 % HCl)
 - dish 5--tap water.
3. Put the dry film in tap water (dish 1) for 5-10 minutes. The red blood cells lyses and the film will be clear, or white, when lysis is complete.
4. Left film dry.
5. Put the film in ether-ethanol for 10 minutes (dish 2).
6. Let dry.
6. Put the film in Delafield's haematoxylin stain for 15 minutes (dish 3).
7. Destain with hydrochloric acid-water (dish 4). Dip slide into hydrochloric acid-water twice. Do this QUICKLY. The film will turn red.
8. Immediately put slide in tap water (dish 5) to wash off acid. Put dish under a stream of running water until the film turns blue. Put a piece of rubber tubing on the tap long enough to reach the top of the dish and let the water run gently; if the flow of water is too strong, the film will be washed off. If running water cannot be used, change the water in the dish several times until the film turns blue. Put your finger over the top of the dish to keep the slide from falling out, pour the water out, and refill the dish.
9. Let the film dry and examine with the x 10 and oil-immersion objectives for microfilariae.

Examination:**Thick films:**

1. Focus on the film with the x 10 objective and search for microfilariae. They are easily detected with the x 10 objective.
2. If microfilariae are present, switch to the oil-immersion objective and identify the species. Also look for malaria parasites with the oil immersion objective. At least 100 fields should be examined.

Microscopy of thick films should reveal the following features:

- The background should be clean, free from debris, with a pale mottled-gray colour derived from the lysed erythrocytes.
- Leukocyte nuclei are stained a deep, rich purple.
- Malaria parasites are well defined with deep-red chromatin and pale purplish-blue cytoplasm. In *Plasmodium vivax* and *P. ovale* infections, the presence of Schuffner's stippling in the "ghost" of the host erythrocyte can sometimes be seen at the edge of the film.

Thin film:

- Focus with the x 10 objective on the thin terminal end of the film where the red blood cells are in one layer.
 - Put immersion oil on the slide and switch to the oil-immersion objective.
- When examining for malaria parasites and trypanosomes, at least 200 fields should be examined. Microscopy should reveal the following features:
- The background should be clean and free from debris; erythrocytes are stained a pale greyish-pink.
 - Neutrophil leukocytes have deep purple nuclei and well defined granules.
 - The chromatin of malaria parasites is stained a deep purplish-red and cytoplasm a clear purplish-blue.
 - Schuffner's dots should be seen as stippling in erythrocytes containing *P. vivax* or *P. ovale*, and **Maurer's dots** show as stippling in erythrocytes containing the larger ring forms of *P. falciparum*.

Special techniques for plasmodia

Identification of malaria parasites:

Three components of malaria parasites may be seen. These are blue -staining cytoplasm, red or purple chromatin, and brown or black pigment granules or rods.

Except for the early (young) ring stages, you should be able to see all three components. Observation of the three components is important in order to distinguish malaria parasites from host cells, like white blood cells, and artifacts that may appear on the slide during preparation.

In thin films, look at the appearance of the parasite and the appearance of the red blood cells containing the parasites. **Observe the following:**

1. The appearance of the red blood cell containing the parasite.

-**Size.** Is the parasitized cell the same size as the blood cells without parasites (that is, normal size) or is it bigger (enlarged)?

-**Stippling.** Is the red blood cell filled with pink-or red-staining dots? These are Schuffner's dots and occur only in *P. vivax* and *P. ovale* infections. (They will not be present in blood cells without parasites.) Cells containing late stage trophozoites of *P. falciparum* often include irregular red-mauve dots. These are Maurer's dots.

2. the appearance of the parasite.

-Are the growing trophozoite stages irregular in outline?

-Are they regular or smooth?

-What colour is the pigment in the older trophozoites, schizonts, and gametocytes?

-How many merozoites are there(if any) in the mature schizont?

-What is the shape of the gametocytes, if seen?

-What stages (ring, growing trophozoites, schizonts, gametocytes) are present?

Examine the center portion of the thick film first. Organisms are more likely to be detected in this thicker area. If the morphology is not distinct, go to the thinner, outer edges to find parasites with a more characteristic appearance.

In thick films, the red blood cells are lysed and no longer present. The blood layer is much thicker than in a thin film and parasites may be located at different levels. Focus up and down carefully to see the organisms. In thick films, the parasites often appear smaller than in thin films, but the same parasite characteristics are used to separate species. Sometimes, parasites in the thinner, outer edges of the edges of the thick film are more like those in thin films than are those in the center. Occasionally, the outlines of the red blood cells can be seen in the thin edges.

-Special Techniques for Trypanosoma:

Trypanosomes can be identified in:

- blood films
- cerebrospinal fluid (CSF)
- lymph node aspirates.

Detection of trypanosomes in blood:

Of the *Trypanosoma* species occurring in Africa, *Trypanosoma brucei gambiense* and *Trypanosoma brucei rhodesiense* cannot be distinguished morphologically. They may be identified in either thick or thin blood films. However, in the thick film, they may be distorted and difficult to differentiate from cellular debris. *Trypanosoma cruzi*, found in the thicker areas of the thin film.

Like plasmodia, the cytoplasm of trypanosomes stains blue. The nucleus and kinetoplast stain red or purple. Look for an elongated organism with a prominent nucleus located near the center of the body and a smaller dot, the kinetoplast, located near open end. The flagellum originates from the posterior part of the trypanosome close to the kinetoplast. The flagellum is attached to the cell wall except at the anterior tip, where it terminates with a free end. Since the flagellum is constantly moving it pulls the cell wall into irregular extensions, this feature being known as the undulating membrane. The trypanosome may be undulated (with 2 or 3 curves) or it may be in a C or U shape. The shape, the position of the nucleus, and the size and location of the kinetoplast are features used in identifying species.

The wet blood film:

This method is the easiest and least expensive way to show the presence of parasites in blood, but it is the least sensitive test.

Materials:

blood lancet, cotton wall swabs, coverslip, microscope slide, saline solution (reagent no. 24), and ethanol.

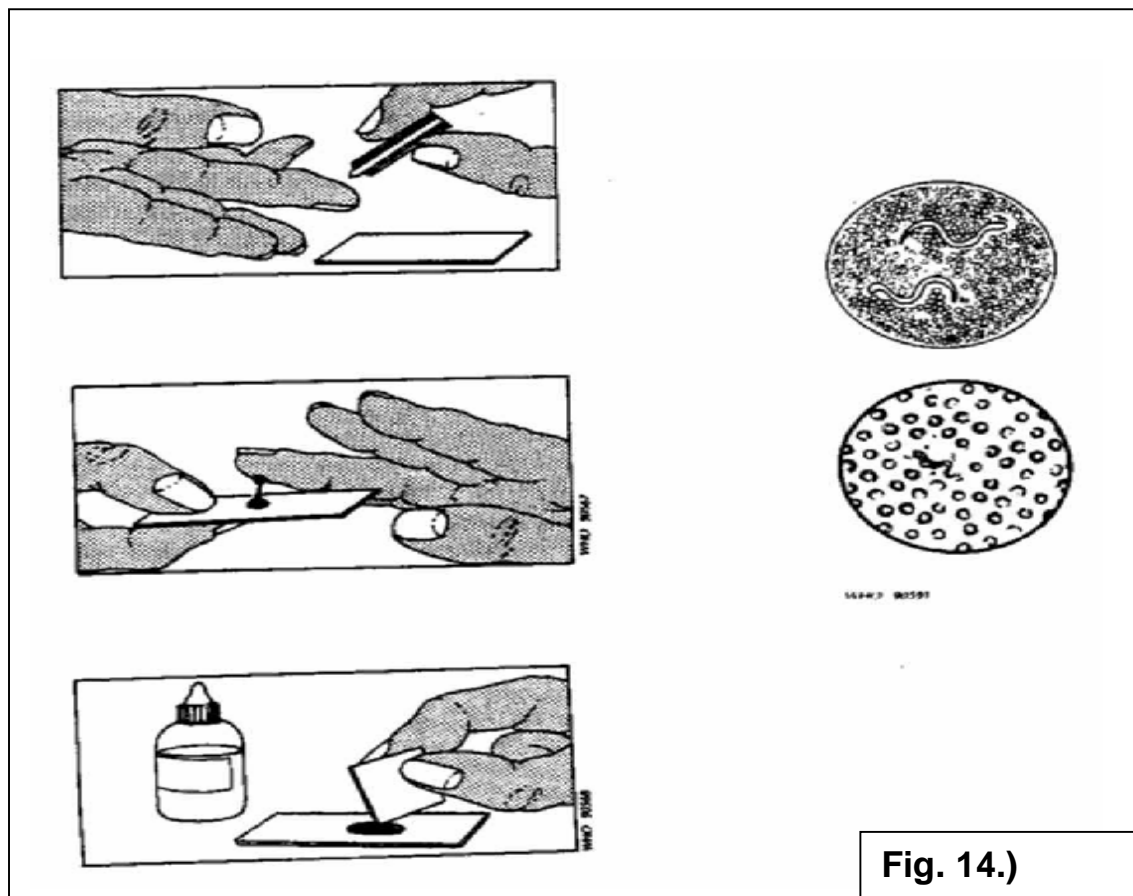
Method: (Fig. 14.)

1. Select the third finger from the thumb. Clean the finger with a cotton wool swab lightly soaked in ethanol. Dry well. Prick with the lancet.
2. Collect the first drop of blood that appears directly on to the middle of the slide.
3. Add an equal drop of saline. Mix the blood and saline solution using the corner of a coverslip. Cover the preparation with the coverslip.
4. Prepare two thick films on another slide using 2 more drops of blood .

Examine the fresh smear systematically under the microscope (X 10 objective with reduced condenser aperture). The first sign of the presence of live trypanosomes or microfilariae is rapid movement among the red cells.

(The illustration on the right shows a view (X40) of a trypanosome and red blood cells, that on the left, microfilariae (X10)

5. Scan the whole preparation systematically. The trypanosomes are refractile and difficult to see. They are easier to see with slightly reduced lighting.

**Fig. 14.)**