

Practical Pathology of Gunshot Wounds

J. Scott Denton, MD; Adrienne Segovia, MD; James A. Filkins, MD, JD, PhD

• **Context.**—Gunshot wounds are the most common cause of homicidal death in the United States. Analysis and interpretation of fatal gunshot wounds is an important and common practice among forensic pathologists. Additionally, for pathology residents, it is an integral aspect of their training during their rotations at medical examiner or coroner offices.

Objective.—The correct interpretation of gunshot wounds by forensic pathologists not only provides valuable information that can assist law enforcement in their investigation but also is essential for the final determination of manner of death. Discussion of the practical, basic, and essential skills required to interpret gunshot wounds include distinguishing a classic entrance wound from an exit wound; recognizing atypical entrance and exit wounds; utilizing the features of soot and stippling patterns to differentiate among contact, close, and distant range gunshot

wounds; understanding of the trauma produced by gunshot wounds; and understanding the importance of recovering and documenting/handling any projectiles recovered at autopsy.

Data Sources.—This article reviews numerous standard forensic pathology textbooks and the pertinent literature to formulate practical guidelines to assist the pathologist in the performance of forensic autopsies and the investigation of gunshot wound fatalities.

Conclusions.—Pathologists who perform investigations and autopsies to determine the cause and manner of death in gunshot wound cases must be aware of the implications, requirements, and pitfalls in interpretation of the injuries so that the examination fulfills its expectations to the community and the justice system.

(*Arch Pathol Lab Med.* 2006;130:1283–1289)

Gunshot wounds are the most common cause of homicide in the United States and, in many jurisdictions, the most common means of suicide. It is estimated that each year in United States there are approximately 70 000 victims of gunshot wounds, with 30 000 deaths.¹ The medical, legal, and emotional costs of this violence impose a staggering burden on urban trauma hospitals, court systems, families, and society in general. The evaluation of these wounds requires specialized training and expertise, whether by an emergency physician in a living gunshot victim or a forensic pathologist in the deceased.

When a person dies from a gunshot wound, the investigation of the death falls to the local medicolegal death investigation system. In a large urban setting this is usually a medical examiner's office, headed by a chief medical examiner and staffed by forensic pathologists who have completed specialized postresidency fellowship training. In other jurisdictions, the responsibility belongs to the elected coroner and his or her designated forensic pathologist. Distinguishing among accidental, suicidal, and homicidal gunshot wounds; estimating range of firing; and distinguishing exit wounds from entrance wounds are

critical skills and just a few of the reasons why a forensic pathologist must be an expert in interpreting gunshot injuries. An error in any of these determinations can have far-reaching consequences for the family of the deceased, the accused, the legal system, and the forensic pathologist. This article seeks to lay basic groundwork for understanding the pathology of gunshot wounds.

GUNS AND AMMUNITION

A forensic pathologist does not have to be a weapons expert to interpret gunshot pathology correctly, but, because bullets fired from handguns and rifles produce gunshot wounds, a forensic pathologist should at least be familiar with the nomenclature and operation of commonly used guns and ammunition. The examination and interpretation of firearms and bullets is termed ballistics or firearms examination. It is a separate field of expertise from forensic pathology requiring specialized training and instruments of its own.² The basic functional unit of a modern round of ammunition is the cartridge.³ A cartridge consists of a cartridge casing, a primer, and a projectile or bullet. The cartridge casing contains the propellant or gunpowder. The primer is located at the base of the cartridge casing. The bullet is tightly fitted into the opposite end of the cartridge casing. When the gun's firing pin strikes the primer, a small explosive charge in the primer ignites the gunpowder. Rapidly expanding gases produced by the combustion of the gunpowder propel the bullet out of the cartridge casing and down the barrel of the gun. As the bullet accelerates down the barrel, rifling from twisted slots within the barrel rotate the bullet causing it to spin along its axis, maintaining a straighter, more accurate trajectory. Each gun has a unique pattern of ri-

Accepted for publication October 17, 2005.

From the Cook County Medical Examiners Office and the Department of Pathology, Rush University Medical Center, Chicago, Ill (Dr Denton); the Cook County Medical Examiners Office and the Department of Pathology, Loyola University Medical Center, Maywood, Ill (Dr Segovia); and the Department of Law, City of Chicago, Chicago, Ill (Dr Filkins).

The authors have no relevant financial interest in the products or companies described in this article.

Reprints: J. Scott Denton, MD, Cook County Medical Examiners Office, Chicago, IL 60612-3705 (e-mail: Yincision@comcast.net).

fling, which produces a corresponding pattern of ridges and grooves around the base of the bullet as it travels down the barrel. It is this pattern of ridges and grooves surrounding the base of a bullet that often enables a ballistics expert to match the bullet to the weapon that fired it. For this reason, it is an important rule of forensic pathology that nobody is buried with a retained bullet, either from an old or new gunshot injury. All bullets are recovered and saved.

Generally, bullets are identified by their caliber or diameter and whether they have a metal covering or jacketing. Metal jacketing increases the penetration of a bullet as it enters its target and permits the more efficient chambering of cartridges. Common caliber designations are given in either the English system in hundredths of an inch (eg, .22, .38, .45) or in the metric system in millimeters (eg, 7.42 or 9 mm). The caliber indicates both the inner diameter of the barrel of the gun and the bullet diameter; a .22-caliber gun, for example, fires a .22-caliber bullet. This is essential because the bullet must maintain a tight fit with the inner barrel lining as the expanding gases accelerate it down the barrel of the gun. Forensic pathologists commonly describe bullets as small (.22, .25), medium (.32, .38, 9 mm), or large (.40, .45, .50) caliber, based on a measurement of the bullet's diameter. A simple ruler or caliper is a good way to make this determination with a bullet recovered at autopsy.

Handguns and rifles are designed to fire a single projectile when the trigger is pulled. Handguns are easily concealed short-barreled guns designed to be held and fired in 1 hand. Rifles are long-barreled guns, which are less easily concealed and designed for long-range accuracy. Typically, rifle ammunition is of a much higher velocity than handgun ammunition. Handguns and rifles are classified by their mechanism of firing and their method of advancing a new round into firing position. Revolvers use a revolving cylinder to hold the cartridges in place and to position them for firing. When a cartridge is fired and the hammer recocks, the cylinder rotates to align the next cartridge with the firing pin. Revolvers are further subdivided into single-action or double-action revolvers. Single-action revolvers require the hammer to be manually cocked each time the trigger is to be pulled and the gun fired. Single-action revolvers, such as the Colt .45 Peacemaker, are the classic *six-shooters* of the "Old West." Double-action revolvers can be fired either by manually cocking the hammer or by simply pulling the trigger, which simultaneously cocks the hammer. Examples of double-action revolvers include the .38 caliber Smith & Wesson Model 10 revolver, which is still used by law enforcement officers today.

Semiautomatic handguns or *automatics* contain a detachable magazine in the grip that holds the cartridges. Each time the gun is fired, gases propel the slide on the top of the gun backward. As the slide goes backward it ejects the spent cartridge casing and recocks the gun. As the slide springs forward it feeds a new cartridge from the magazine into the firing chamber. Semiautomatics are further subdivided into single action, traditional double action or double action only. Whether the hammer must be cocked before a shot can be fired determines the classification. Single-action automatics, such as the Colt .45 Model 1911, can only be fired if the hammer is cocked. Traditional double-action automatics, such as the 9-mm Beretta Model 92, can be fired either by cocking the hammer or

by pulling the trigger. Double action only automatics can only be fired by pulling the trigger.

Rifles are subdivided into lever action, bolt action, and semiautomatic. Lever-action rifles, such as the Winchester Model 1894 seen in countless Western films, use an extension of the trigger guard as the lever. When the lever is moved down, a spent cartridge casing is ejected; when it is moved back up a new cartridge is chambered and the hammer recocks. Bolt-action rifles, such as the Remington Model 700 hunting rifle, secure a cartridge in the firing chamber by a bolt, which also houses the firing pin. When a shot is fired, the shooter must manually pull the bolt back to allow the spent cartridge casing to eject and a new cartridge to move into position. Pushing the bolt forward slides the new cartridge into the firing chamber and recocks the firing mechanism. Semiautomatic rifles, such as the M1 Garand, operate on principles similar to semiautomatic handguns.

IDENTIFYING ENTRANCE, EXIT, AND GRAZE WOUNDS

Shooting someone in the back that is running away from you versus shooting someone in the chest while defending yourself from an attack highlights the importance of differentiating entrance wounds from exit wounds. In criminal law, correctly differentiating between the 2 can mean the difference between first-degree murder charges and a possible death sentence or justifiable self-defense and no charges. Fortunately, the application of a few basic concepts will usually permit an accurate differentiation of entrance wounds from exit wounds.

Typical entrance wounds are ordinarily round in shape with a circumferential margin of abrasion surrounding the defect produced by the bullet (Figure 1, A and B).⁴ The margin of abrasion is a scraping or scuffing of the skin caused by the bullet as it pushes inward. The margin of abrasion may be concentric or eccentric. When a bullet penetrates the skin nose on, it produces a concentric margin of abrasion—that is, a ring of scraped skin of uniform thickness—because it enters perpendicular to the skin. When the nose of a bullet penetrates the skin at an angle, it produces an eccentric margin of abrasion, that is, a ring that is thicker in 1 area. The thick area of an eccentric margin of abrasion indicates the direction from which the bullet came. In addition, the thicker the margin the shallower the angle of the bullet was as it struck the skin.

Atypical entrance wounds are irregular in shape and may have tears at the margins.⁵ This type of entrance wound usually occurs when a bullet loses the spin imparted to it by the rifling in the barrel of the gun. Instead of traveling in a tight spiral, the bullet "wobbles" as it strikes the skin often imparting a D-shaped appearance to the wound. Atypical entrance wounds can be caused by a weapon that malfunctions or by defective ammunition, but more often they result from ricochets or the passage of a bullet through an intermediate target, such as an automobile window, before it strikes the body. The bullet may, in turn, impart velocity to the intermediate target causing it to strike the skin producing atypical abrasions around the entrance wound. Another type of atypical entrance wound occurs when the muzzle of a gun is in contact with the skin over a bony surface, such as the skull or sternum (Figure 2). When the gun is fired, it discharges gases directly from the muzzle into the wound along with the bullet. The gases penetrate into the subcutaneous tissue, where they expand causing the skin around the en-

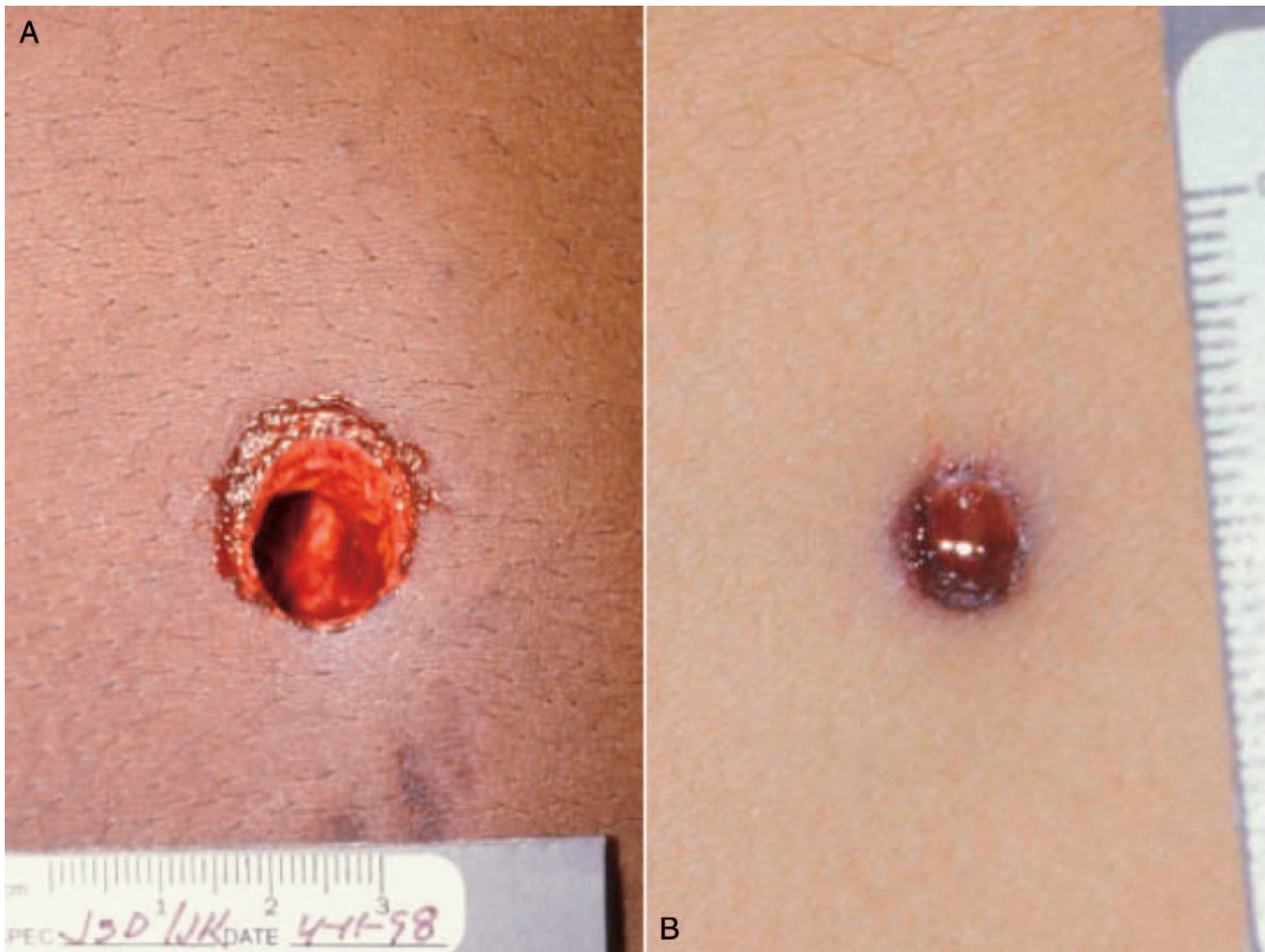


Figure 1. A, Entrance wound from a large-caliber .45 handgun. B, Entrance wound from a medium-caliber 9 mm. Both wounds show typical entrance characteristics with round defects in the skin and marginal rims of abrasion.

trance wound to stretch and tear. The tears or lacerations radiate out from the central defect giving the wound a stellate or star-shaped appearance.

Exit wounds can appear round, oval, slitlike, stellate, or crescent shaped. In other words, exit wounds can take any shape whether small or large (Figure 3). A common misconception is that an exit wound is bigger than its corresponding entrance wound. Size does not determine whether a gunshot wound is an exit wound; rather, it is the lack of a margin of abrasion that distinguishes an exit wound from an entrance wound. Exit wounds may have small marginal tears caused by the bullet pushing the skin outward. Exit wounds may also have an atypical appearance.⁶ One example is a shored or reinforced exit wound (Figure 4). This is an exception to the rule that only entrance wounds have an associated margin of abrasion. Shored exit wounds are encountered when the skin is supported by a firm surface, such as a wall or floor, as the bullet exits. The exiting bullet pushes the skin into the supporting surface, which scrapes and abrades it. Articles of clothing, such as leather belts, may also provide sufficient firmness to produce shored exit wounds. Of course, where there is an exit wound, there must also be an entrance wound. Even so, a shored exit wound can closely

resemble an entrance wound and may occasionally challenge even an experienced forensic pathologist.

Exit wounds from high-powered rifles may be large because of the high velocity and kinetic energy of rifle ammunition (Figure 5). Stellate-shaped exit wounds, which in rifle wounds occur over soft tissue as well as over bony surfaces, are common and may resemble contact entrance wounds. Even though an exit wound from a rifle may be larger and may cause more damage than an exit wound from a handgun, an exit wound from a rifle will still lack a margin of abrasion. By approximating the wound edges, the presence or absence of a margin of abrasion can be confirmed.

When a bullet perforates flat bones, such as the skull, sternum, or ribs, beveling allows the forensic pathologist to determine the direction of the wound by examining the bone. Beveling is caused by the forward moving force of the bullet, which creates a cone-shaped deformity as it pushes through the layers of bone.⁷ The tip of the cone points in the direction from which the bullet came. In the example of a gunshot wound of entrance involving the skull, the outermost layer of bone will have a smaller defect than the inner layers of bone. This is called internal beveling. In an exit wound involving the skull, the pattern

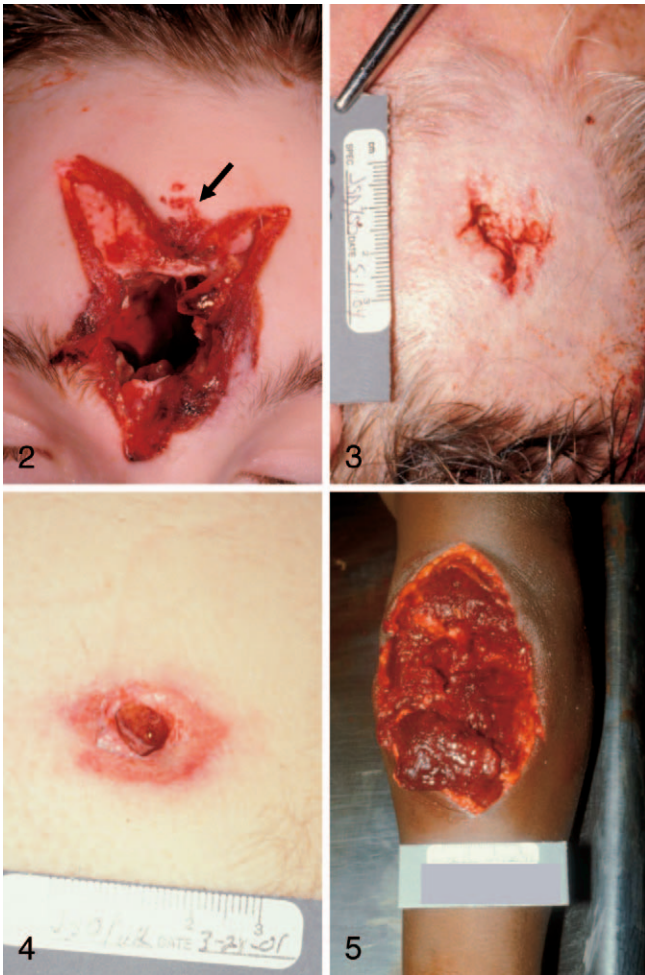


Figure 2. Stellate contact entrance wound of the forehead with internal soot deposition, lacerations, and muzzle sight impression mark at the top.

Figure 3. Exit wound of the head over the skull showing stellate defect without marginal abrasion from a handgun.

Figure 4. Shored exit wound with an atypical abrasion of the surrounding skin.

Figure 5. Exit on the forearm from a high-velocity rifle.

is reversed and is referred to as external or outward beveling. There is an exception to these patterns: When a bullet strikes the skull at a very shallow angle it may produce an entrance wound with both internal and external beveling. This is known as a *keyhole defect* (Figure 6). Graze gunshot wounds occur when a bullet scrapes or grazes over the skin without penetrating more deeply. These wounds are usually elongated to oval in appearance and may have marginal tears at the edges. If the tears are pointed, they can be used to indicate the direction of the bullet—the tears point in the direction the bullet is traveling and away from the direction from which the bullet came (Figure 7).

Once a determination of the entrance wound and its corresponding exit wound is made, the next step is to determine the direction of fire. Direction of fire is the path the bullet travels through the body from entrance wound to exit wound. For reasons of clarity and consistency, a forensic pathologist always describes the direction of fire as though the victim's body was in the standard anatomic

position when it was shot, that is, as though the victim was standing fully erect with the arms extended at the sides and palms forward. In the example of a gunshot wound that enters on the left chest and exits on the right lower back, the direction of fire would be described as front to back, left to right, and downward. Seldom will a victim actually be in the standard anatomic position when shot or, for that matter, remain in the same position between the first and last gunshot wounds. Usually, a forensic pathologist can only opine that a given position either is or is not consistent with the direction of fire, but even this limited opinion can be decisive if it corroborates or impeaches the testimony of an important witness. Accordingly, a forensic pathologist should be prepared to discuss any theories of the possible positions of the deceased during the shooting that investigators or attorneys may present.

DETERMINING RANGE OF FIRE

The second major external determination of a gunshot wound is the estimation of range of fire. Range of fire is an estimate of how close the muzzle of the gun was to the surface of the victim's body or clothing at the time of discharge.⁸ This determination is usually made by an unaided visual inspection for the presence or absence of substances that exit the muzzle of the gun along with the bullet with consideration of the circumstances of the shooting.⁹ Depending on the range of fire, these substances can be deposited on the skin or clothing. If the muzzle of the gun is in contact with the skin, these substances may be deposited within the wound or, if the muzzle is in very close proximity to the skin, around the entrance wound. In general, substances exiting the barrel of a gun along with the bullet will be deposited on the skin if the muzzle is within 2 feet of the victim's body.

The principle indicator of close range fire is stippling, that is, a pattern of tiny, punctuate abrasions in the skin surrounding the entrance wound (Figure 8). Stippling is caused by unburned particles of gunpowder striking the skin. In contrast to other substances that may be deposited on the skin, such as soot, stippling cannot be washed away. The presence of stippling indicates that the muzzle of the gun was within 2 feet of the victim's body when it was discharged. Contact range firing occurs when the muzzle of the gun is in contact with the skin at the time of discharge (Figure 2). Contact range wounds are commonly seen in suicidal firearm injuries. These wounds are often characterized by a dense pattern of combusted gunpowder residue or soot within and around the wound margin. Soot is lighter in weight than unburned particles of gunpowder. Most of the soot will, therefore, only carry a few inches from the muzzle of the gun before falling away. Unlike stippling, soot may be washed away. If a forensic pathologist sees soot, he or she should photograph it before cleaning the body in preparation for the autopsy. Contact range gunshot wounds are no exception to the general rule that entrance wounds have a margin of abrasion, but the margin of abrasion in a contact wound may be seared or charred. There may also be red discoloration of the surrounding skin from carbon monoxide, which is a component of the gases discharged from a gun when it is fired. A muzzle imprint is not an uncommon finding and is virtually pathognomonic of a contact range gunshot wound. As noted earlier, stellate patterns of tearing, especially over bony surfaces, are not unusual.

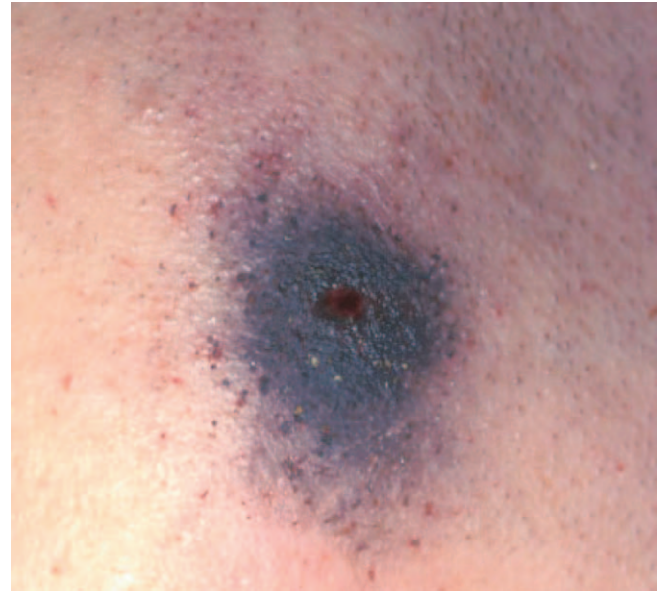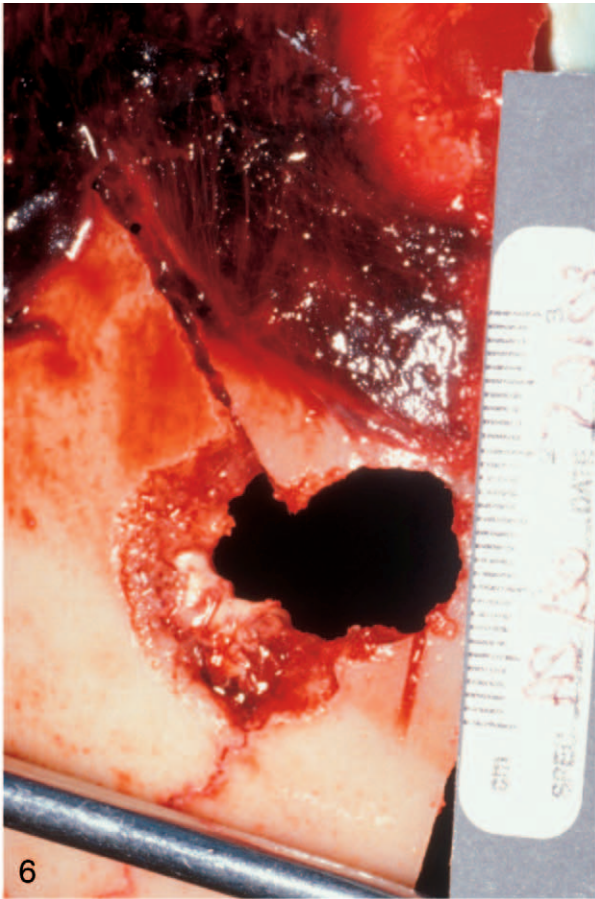

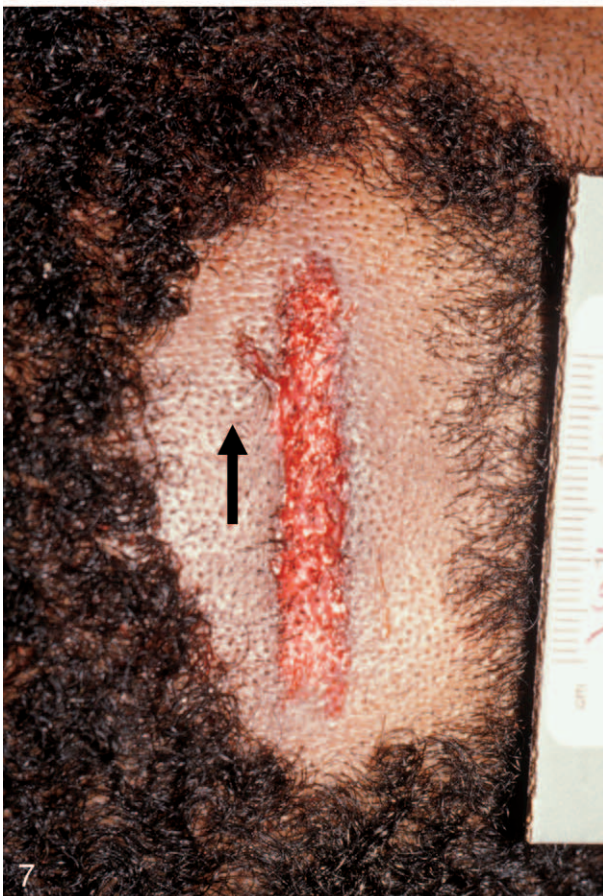
Figure 8. Close-range gunshot wound showing dark circular soot deposition with surrounding punctuate stippling.

Distant range gunshot wounds, that is, wounds inflicted when the muzzle of the gun is more than 2 feet away, will show no evidence of soot or stippling. It is absolutely critical that the forensic pathologist recognizes that the absence of soot or stippling does not absolutely mean that the wound was not fired from close range. Intermediate targets and clothing can screen out stippling and soot even when the muzzle of the gun is pressed up against the clothing.¹⁰ The most accurate way to determine range of fire is to test fire the weapon at various distances with the same type of ammunition to create a pattern of soot or stippling matching that found at the time of autopsy. Muzzle to garment testing, as this technique is sometimes called, is ordinarily done by a ballistics expert in a crime laboratory. Clothing can also be tested for the presence of gunpowder residue to determine whether, for example, a bullet caused a particular defect in the clothing. This type of testing cannot establish range of fire, but it can give the maximum distance from which the gun was fired based on the distance the gunpowder residue may travel.

INTERNAL INJURIES FROM GUNSHOT WOUNDS

Gunshots inflict damage by disrupting tissues, causing hemorrhage, and permitting the entrance of infection.¹¹ Generally, 3 factors determine the severity of a gunshot injury: the amount of kinetic energy transferred by the bullet to the surrounding tissues, the internal organs and structures damaged by the bullet, and the bullet's final disposition. The formula $KE = \frac{1}{2}mv^2$ expresses the amount of energy transferred to the body by a bullet. Kinetic energy (KE) is the amount of tissue damage deliv-



←

Figure 6. Keyhole defect in an entrance wound of the skull showing the external beveling and radiating fractures as the bullet strikes tangentially.

Figure 7. Graze gunshot wound of the scalp with the surrounding hair shaved, showing a marginal tear with an arrow indicating the direction of the wound and the tear.

ered to the surrounding organs and is the product of the mass of the bullet times the square of the bullet's velocity, divided by 2. Increasing the velocity of the bullet is more significant than increasing its mass because an increase in velocity is exponential, whereas an increase in mass is linear.

Obviously, the anatomic location of the wound is critical—a gunshot wound to the central nervous system, even one of low velocity, can be more life threatening than a high-velocity wound through the arm. Involvement of vital structures such as the heart, aorta, lung, liver, spleen, and kidneys can quickly lead to hemorrhage, hypoxia, and death. Tissue damage is not, however, limited to the path the bullet travels through the body. Damage may occur remote from the bullet path if the kinetic energy of the bullet is great enough to produce a shock wave. Cavitory effect is the concept that explains the shock wave produced by a bullet as it passes through an organ or other anatomical structure.¹² As a bullet passes through a body and transfers its kinetic energy, it produces a shock wave that creates a temporary cavity greater than the bullet's diameter. The greater the kinetic energy that is transferred the greater the size of the temporary cavity. Velocity is more significant than mass in determining kinetic energy; therefore, cavitory effect is more pronounced in injuries from high-velocity ammunition. The extent of damage depends on whether the transient expansion of tissues and organs exceeds the elasticity of the particular structure through which the bullet passes. Organs such as the liver and spleen, which lack elasticity, are easily lacerated. Organs that are more elastic, such as the stomach and intestines, may only suffer contusions. After the temporary cavity collapses, a permanent cavity wider than the bullet may persist (Figure 9).

BULLETS AS EVIDENCE

Frequently, bullets are retained in the body and need to be collected at the time of autopsy. Accordingly, it is critical that all bullets, bullet fragments, and jacket fragments be removed from the body of the deceased with the guidance of radiographs and/or fluoroscopic studies. Radiographic guidance makes recovery more efficient and ensures that no bullet or fragment will be missed. Clothing should not be removed from the body before it is examined radiographically because occasionally bullets or bullet fragments may be found in the clothing. For this reason, any clothing that accompanies the body should be carefully examined. Even if a bullet has fragmented, a ballistics expert may be able to determine the caliber of the bullet from the aggregate weight of the fragments. It is also extremely important to recover any jacket fragments whenever possible because in jacketed ammunition, the rifling marks appear only on the jacket. Unless the jacket is recovered, the bullet cannot be matched to a particular gun. The forensic pathologist must always remember that the chain of custody for any bullets begins in the autopsy suite. If potential evidence is mishandled in the autopsy suite, whether by the pathologist performing the autopsy, technicians assisting, or the investigators assigned to case, it diminishes the likelihood of that material being admitted into evidence at trial. Recovered bullets and fragments should be photographed next to a scale identifying the anatomic location from which the bullet or fragment was recovered. Each bullet and/or fragment should be then be sealed in a separate evidence envelope with the subject's

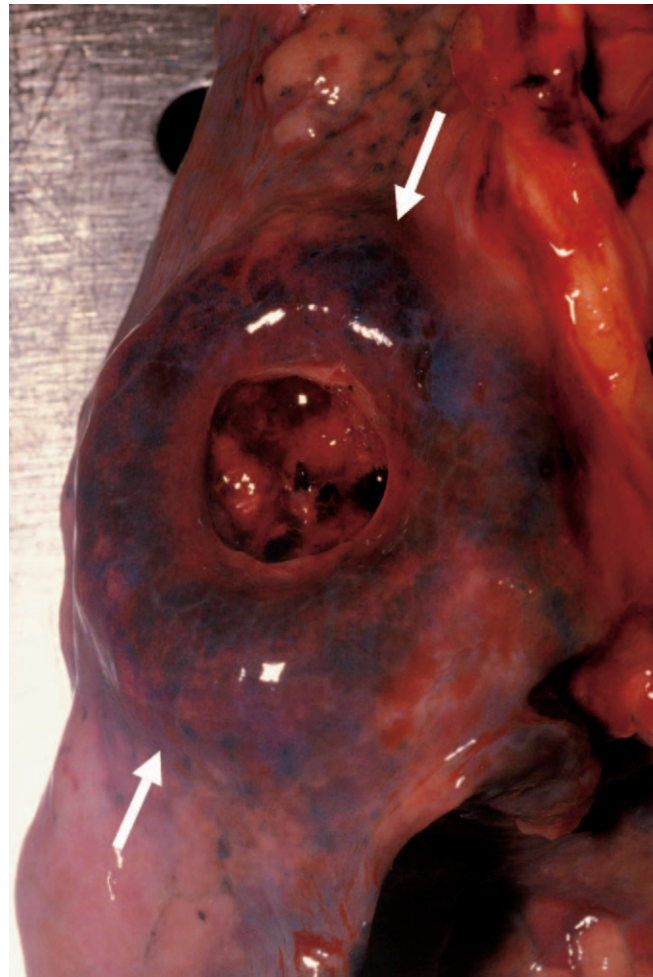


Figure 9. Lung with features of temporary and permanent cavities. Large arrow indicates extent of temporary cavity expansion with contusion. (Notice that the permanent cavity is still several times larger than the offending bullet.)

name, the date of recovery, and the name of the pathologist who recovered it written by the pathologist in his or her own handwriting on the envelope. It is also useful to provide a brief description on the envelope of its contents, such as "medium-caliber, copper-jacketed lead bullet" or "lead bullet fragment." It is important never to etch or mark the bullet itself because this may alter the rifling pattern. After the envelope is sealed, the pathologist should initial the flap. Finally, the bullet envelope should be turned over to a representative of the jurisdiction investigating the death, and a receipt for the evidence should be obtained to ensure proper chain of custody. If there is no one to take receipt of the evidence envelope, it should be kept in a secure location. These precautions help ensure that there will be no dispute regarding the admissibility into evidence of the contents of the envelope when the pathologist is called to testify in court.

THE AUTOPSY REPORT

The autopsy report should include a section describing the gunshot injury or injuries. The description of the gunshot wound injury begins with a description of the entrance wound, traces the internal structures through which the bullet passed, and concludes with either the

location from which the bullet was recovered or a description of the exit wound.

PHOTOGRAPHING GUNSHOT WOUNDS

Proper photographic documentation of gunshot wounds is critical. The wound should be cleaned of excess blood and hair before being photographed. Thirty-five millimeter photographic or slide film is commonly used with digital photographs as a backup. The wound should be photographed both from a medium distance to indicate its location on the body in relation to easily recognizable body landmarks and from close-up to illustrate the characteristics of the wound.

COMMON PITFALLS

There are some common pitfalls or omissions that may occur in the examination and documentation of gunshot wounds. Evidence of contact range fire around the wound or clothing may be lost if the wound is cleaned or the surrounding hair is shaved to expose the wound prior to examination. All the clothing on or with the body should be examined for gunshot residue because clothing can absorb soot and stippling preventing it from reaching the skin around the wound. At a minimum, the clothing involved should be photographed, preserved, and submitted to the crime laboratory for examination and presentation at trial. In this modern age, fluoroscopy, radiographs, and occasionally computerized tomography are essential to document the location of projectiles within the body and help in their recovery. Finally, wounds should not be vigorously "probed" with metal rods, because this creates false tracks through the tissue confusing the true course of the wound.

CONCLUSION

There is an epidemic of gunshot wound fatalities nationwide. Interpretation, investigation, and adjudication of these deaths require dedicated and well-trained forensic pathologists. This brief, practical introduction to the complex topic of gunshot wound pathology has covered the basics of gunshot wound examination in forensic pathology while providing a glimpse into some of the more complex issues in evaluating these wounds.

References

1. Centers for Disease Control and Prevention. Nonfatal and fatal firearm-related injuries: United States, 1993–1997. *MMWR Morb Mortal Wkly Rep.* 1999; 48:1029–1034.
2. Volgas DA, Stannard JP, Alonso JE. Ballistics: a primer for the surgeon. *Injury.* 2005;36:373–379.
3. Bonfanti MS, de Kinder J. The influence of manufacturing processes on the identification of bullets and cartridge cases: a review of the literature. *Sci Justice.* 1999;39:3–10.
4. DiMaio VJM. Characteristics of rifles, handguns, and ammunition. In: Froede RC, ed. *Handbook of Forensic Pathology.* 2nd ed. Chicago, Ill: College of American Pathologists; 2003:175–183.
5. Donoghue ER, Kalelkar MB, Richmond JM, Teas SS. Atypical gunshot wounds of entrance: an empirical study. *J Forensic Sci.* 1984;29:379–388.
6. Druid H, Ward ME. Incomplete shored exit wounds: a report of three cases. *Am J Forensic Med Pathol.* 2000;21:220–224.
7. DiMaio VJM. *Gunshot Wounds—Practical Aspects of Firearms, Ballistics and Forensic Techniques.* 2nd ed. Boca Raton, Fla: CRC Press; 1999:93–94.
8. Spitz WU. Injury by gunfire. In: Spitz WU, ed. *Spitz and Fisher's Medicolegal Investigation of Death.* 3rd ed. Springfield, Ill: Charles C Thomas; 1993: 311–332.
9. Adeyi O, Duval JV, Dupre ME, Andrew TA. Role of chemical tests and scene investigation in determination of range of fire. *Am J Forensic Med Pathol.* 2005; 26:166–169.
10. Prahlow JA, Allen SB, Spinder T, Poole RA. Pseudo-gunpowder stippling caused by fragmentation of a plated bullet. *Am J Forensic Med Pathol.* 2003;24: 243–247.
11. University of Utah Pathology Department. Tutorial on gunshot wounds. Available at: <http://www-medlib.med.utah.edu/WebPath/TUTORIAL/GUNS/GUNBLST.html>. Accessed August 10, 2005.
12. Fackler M. Wound ballistics: a review of misconceptions. *JAMA.* 1988; 259:2730–2736.