

## Preventive resin restorations: indications, technique, and success

Louis W. Ripa\* / Mark S. Wolff\*\*

*Although preventive resin restorations have been reported since 1977, there is little uniformity concerning the indications for this procedure, nor is there a standard technique. This article proposes diagnostic criteria for pit and fissure occlusal caries and diagnosis-related considerations for treatment planning for preventive resin restorations. A step-by-step "laminar" technique, which includes, successively, a glass-ionomer cement liner, a posterior composite resin, and a sealant, is described. The success rates reported for several clinical studies of preventive resin restorations are presented, although the criteria for this restoration, treatment methodology, and the determinates of success vary from study to study. (Quintessence Int 1992;23:307-315.)*

### Introduction

Preventive resin restorations represent an evolution in the use of dental resins on posterior teeth that began with the studies of pit and fissure sealants in the 1960s. Sealants are indicated for teeth with caries-free pits and fissures, whereas preventive resin restorations are used for pits and fissures with diagnosed caries.

A preventive resin restoration is a conservative treatment that involves limited excavation to remove carious tissue, restoration of the excavated area with a composite resin, and application of a sealant over the surface of the restoration and remaining, sound, contiguous pits and fissures (Fig 1a). This treatment is an alternative to the customary approach in which, in addition to carious tissue, sound pits and fissures are prepared and an amalgam restoration is placed (Fig 1b).

The purposes of this article are to: (1) examine the indications for preventive resin restorations, (2) describe the technique, (3) review the success of clinical studies, and (4) discuss the advantages and disadvantages of this new technique.

### Indications for preventive resin restorations

Preventive resin restorations are used on the occlusal surfaces of premolars, permanent molars, and primary molars. Despite several clinical studies of the procedure, no uniform indications have been established. A broad, but nonetheless encompassing, statement is: *A preventive resin restoration is indicated when the carious lesion in a pit or fissure is small and discrete.* Thus, the clinician must make diagnostic decisions concerning the existence, size, and location of a lesion, and a treatment planning decision that a preventive resin restoration is the most appropriate treatment.

### Diagnosis

Diagnosis involves radiographic, visual, and tactile assessment. King and Shaw demonstrated that radiographs are insufficient for the detection of occlusal lesions, presumably because many lesions are too small to create a radiographic image.<sup>1</sup> For placement of a preventive resin restoration, the radiograph must show no evidence of proximal caries that would mandate a

\* Professor and Chairman, Department of Children's Dentistry, State University of New York at Stony Brook, School of Dental Medicine, Stony Brook, New York 11794.

\*\* Clinical Associate Professor, Director, Division of Operative Dentistry, Department of Restorative Dentistry, State University of New York at Stony Brook.

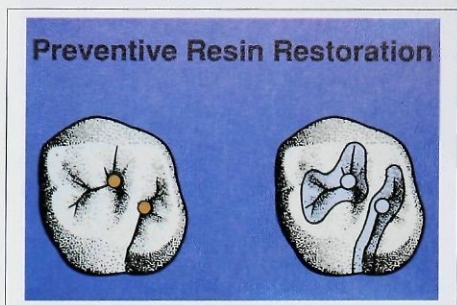


Fig 1a Occlusal surface treated with preventive resin restorations. Excavation is limited to caries removal. Posterior composite resin restorations are placed. The restorations and all occlusal pits and fissures are covered with sealant.

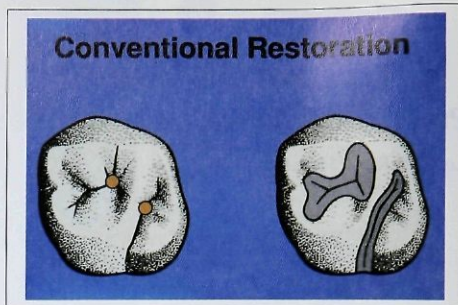


Fig 1b Occlusal surface treated with conventional amalgam restorations. Extension for prevention requires the elimination of sound, as well as carious, pits and fissures in the outline form.

Table 1 Diagnostic and treatment planning considerations for pits and fissures

Clinical sign				
Explorer catch	No	Yes	Yes	Yes
Discoloration*	No	No	Yes	Yes
Enamel softness	No	No	No	Yes
Diagnosis	Sound	Sound	Questionable	Carious
Treatment options	No treatment Sealant	Sealant	Sealant	Preventive resin restoration Conventional restoration

\* White, undermining demineralization.

more extensive restoration. It should be remembered, however, that clinical radiographs underestimate the true extent of carious lesions,<sup>2,3</sup> and the actual size is usually larger than its radiographic image implies. Although, for research purposes, teeth with radiographic evidence of dentinal caries have received preventive resin restorations,<sup>4</sup> if occlusal caries extends into the dentin so that it can be detected radiographically, the lesion is too large for a preventive resin restoration. Occlusal lesions that can be identified clinically, but are not radiographically detectable, present no radiographic contraindication to a preventive resin restoration.

Lesions exhibiting frank cavitation are easy to detect clinically. Borderline cases that fall between a sound tooth surface and obvious caries are the most difficult. It is these less-obvious cases that demand all the operator's diagnostic skill and usually require a pre-

ventive resin restoration. Visual and tactile inspection is made with the teeth thoroughly air dried and properly illuminated. The pits and fissures of the occlusal surface are carefully probed with a sharp explorer to determine if the explorer tip "catches" or resists removal after insertion into a pit or fissure with moderate or firm pressure.<sup>5</sup> A catch alone is insufficient evidence of caries, because the explorer may be wedged between the cusps or in a pit or fissure, but it is an indication to more closely examine the area.

Drying the tooth will drive out fluids present in the micropores of demineralized enamel, and the affected area will appear a matte white in contrast to the gloss of normal enamel. While a dark stain usually should be ignored during diagnosis, a loss of normal translucency of the enamel surrounding a pit indicates the presence of demineralization and suggests a developing lesion.



Normal enamel is hard, and softness represents the *sine qua non* of caries diagnosis. Softness is determined by the tactile feel of the explorer. If the explorer penetrates at the base of a pit or fissure, or if chalky white enamel can be scraped off the walls, the area is carious.

Table 1 presents the possible permutations of the results of visual and tactile examinations of teeth that are radiographically sound, together with appropriate diagnoses and treatments. While other visual and tactile combinations are possible, such as discoloration without an explorer catch and softness, they are either clinically illogical or highly unlikely.

#### Treatment plan

When all the results of the examination for clinical signs of caries are negative, the surface is diagnosed as sound and requires either no treatment or a sealant. The treatment options for sealants are discussed elsewhere.<sup>6,7</sup> When the only sign is an explorer catch, the surface is still considered to be sound.<sup>5</sup> However, pits and fissures that catch the explorer are difficult for the patient to clean and can serve as niduses for caries development (Fig 2); therefore, a sealant is recommended. Questionable surfaces are those with positive visual and tactile findings, eg, explorer catch and discoloration, but that lack the definitive finding of softness at the base or sides of the pits or fissure. Sealants are also recommended for those teeth.

In their review of the management of questionable carious fissures, Meiers and Jensen<sup>8</sup> cited four clinical studies that evaluated "borderline" carious fissures over a period of 24 to 41 months. It was reported that 47% to 73% of the borderline cases progressed to a stage of definite caries. These figures indicate that preventive treatment, such as the use of sealants as discussed above, is preferable to a philosophy of watchful waiting. Too often, dentists "watch" as caries progresses. Should a lesion inadvertently be sealed there is no danger, because there is sufficient clinical evidence demonstrating that properly sealed lesions do not advance and that the bacteria, which are isolated from their principal nutrient source, decrease in viability and number.<sup>4,9-28</sup> As stated by the American Dental Association,<sup>29</sup> "It appears that as long as the sealant provides a physical barrier between the caries and the oral environment the lesion does not progress and its bacterial population decreases dramatically over time."

The combination of an explorer catch and definite softness at the base or along the walls of a pit or fissure is evidence of caries. Usually, a white halo of underlying demineralization also surrounds the affected

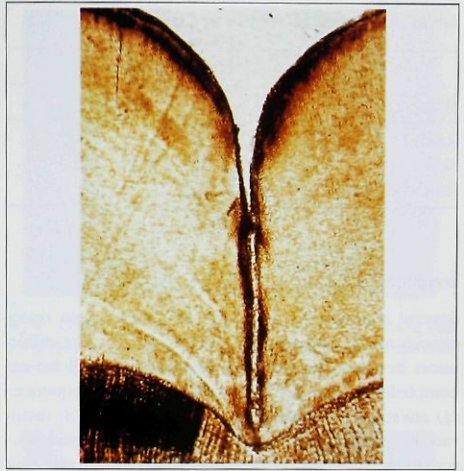


Fig 2 Cross section of an occlusal fissure. Pits and fissures are difficult to clean and encourage the dietobacterial factors responsible for caries.

area. When caries is diagnosed, either a preventive resin or conventional restoration is indicated. The indication for a preventive resin restoration is that the lesion in the pit or fissure be small and discrete. *Small* refers to the width of the lesion, rather than the depth, and *discrete* means that the lesion does not extend along a fissure. Although more than one discrete lesion may be present, they should not be confluent, which would require a wider cavity preparation.

While the decision to use a preventive resin restoration is made during the treatment planning session, the final confirmation of this decision may await the actual treatment visit. Careful opening into the affected area enables the operator to confirm the presence of caries and determine its extent. Excavation should be performed with a small round, pear-shaped, or rounded bur with a width not exceeding 1.0 mm to restrict the size of the preparation (Table 2). If the width of the preparation exceeds more than one third the distance between the buccal and lingual cusp tips, a conventional restoration should be considered, because cavosurface margins are likely to be placed in areas of masticatory stress.<sup>30</sup> Simonsen,<sup>31</sup> however, has reported use of preventive resin preparations slightly larger than a No. 2 round bur, which would have a diameter greater than 1.0 mm.



Table 2 Standard bur sizes and shapes

Shape	Diameter (mm)					
	0.5	0.6	0.8	1.0	1.2	1.4
Round	1/4	1/2	1	2	3	4
Pear		329	330	331	332	
Round-ended			245			

### Technique

Several methods for preparing preventive resin restorations are described in the literature.<sup>32-34</sup> The differences between the methods are minor, and all are accomplished using the following treatment sequence: (1) anesthesia and isolation, (2) preparation, (3) restoration, and (4) sealant application. The following description of the preventive resin restoration technique is consistent with other published descriptions. Figures 3 to 10 show the principal steps of the clinical sequence.

#### 1. Administer local anesthesia.

**Rationale.** Although optional, infiltration or block anesthesia should be considered for the patient's comfort. Excavation with high-speed burs may be painful despite the minimal instrumentation associated with the procedure. Application of the rubber dam retainers may be painful.

#### 2. Isolate with rubber dam. Only the tooth or teeth being treated need be isolated (Fig 3).

**Rationale.** A procedure involving conditioning with acid, application of composite resin and sealant, and possible use of a glass-ionomer lining cement is technique sensitive and time-consuming. Each of these steps is sensitive to moisture contamination. A rubber dam prevents salivary contamination of the treatment area.

#### 3. Remove caries. A small round, pear-shaped, or round-ended bur is used (Fig 4 and Table 2). The cavosurface margin is not beveled.

**Rationale.** There are no rules of cavity design because this is a bonded restoration. The goal is to remove all caries and as little tooth structure as possible. Penetration beyond the dentoenamel junction is not necessary, if all caries has been removed. Small burs are used to conserve tooth structure and help ensure a narrow cavity preparation. Cavosurface margins are not beveled, because Eisenberg and Leinfelder<sup>35</sup> found, in a 2-year study, that beveling the cavosurface margin has no significant effect on the clinical performance of posterior composite resins.

#### 4. Provide pulpal protection if necessary. Calcium hy-

droxide is placed only on the floor of the preparation. Glass-ionomer lining cement should cover all of the dentin and not extend onto the enamel (Fig 5).

**Rationale.** If caries removal extends deeply into the dentin, calcium hydroxide and glass-ionomer liners are indicated.<sup>36,37</sup> Calcium hydroxide stimulates reparative dentin when the preparation approaches the pulp. Glass-ionomer lining cement bonds to dentin,<sup>38</sup> is an insoluble barrier to the acid etchant,<sup>39</sup> provides a surface to which the composite resin micromechanically bonds,<sup>40,41</sup> and releases fluoride to the cavity walls.<sup>42</sup> Shallow preparations in dentin should be lined only with glass-ionomer cement. Preparations that are limited to enamel do not require a liner.

#### 5. Clean the occlusal surface. An aqueous slurry of fine pumice in a rotating rubber cup is used to clean the occlusal surface, including the cavosurface margin (Fig 6). The tooth is washed and dried.

**Rationale.** Maximal bond strengths are obtained when a prophylaxis is given prior to acid conditioning.<sup>43</sup> While there is no evidence to confirm the value of using pumice instead of other cleaning agents, it is believed that flavored, oil-based, or fluoride-containing prophylaxis pastes may adversely influence the conditioning of the enamel.

#### 6. Condition the entire occlusal surface. The surface, including the cavosurface margin and enamel cavity walls, is etched with phosphoric acid gel or liquid, then thoroughly washed and dried (Fig 7).

**Rationale.** Conditioning creates pores in the enamel and enables the microscopic infiltration of dental resin into the tooth surface, where it polymerizes and bonds.<sup>44</sup> The usual etching time is 60 seconds, although 20-second etching periods have been studied.<sup>45-47</sup> Etching of the glass-ionomer cement surface is also recommended,<sup>48</sup> unless a light-curing product is used. Within the narrow confines of the cavity preparation, it sometimes is difficult to avoid etching the glass-ionomer lining cement; however, with careful application of a gel etchant, it can be avoided. Etching for more than 30 seconds causes a precipitate film to form over the glass-ionomer cement surface.<sup>49</sup> If acid is applied to the glass-ionomer cement, formation of this film becomes the time-determining consideration for the conditioning step.<sup>48</sup> Washing removes the calcium-phosphate reaction products of the phosphoric acid conditioning agent and enamel. The tooth is washed for 10 to 20 seconds to achieve maximal bond strength.<sup>50</sup>

#### 7. Place bonding agent. The cavity walls and surface of the glass-ionomer cement liner are covered with a bonding agent (Fig 8).



Fig 3 Tooth to be treated with a preventive resin restoration is isolated with a rubber dam.

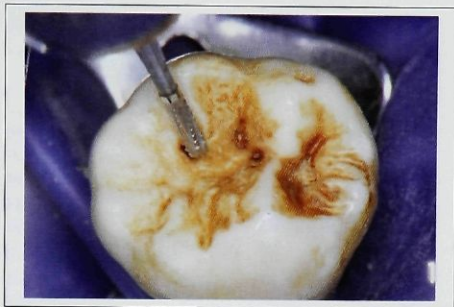

Fig 4 Caries removal. The No. 245 bur in this picture has a rounded end and a diameter of 0.80 mm. Three discrete carious areas are to be removed.

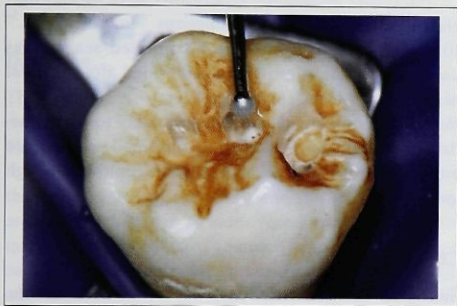

Fig 5 Placement of glass-ionomer lining cement.

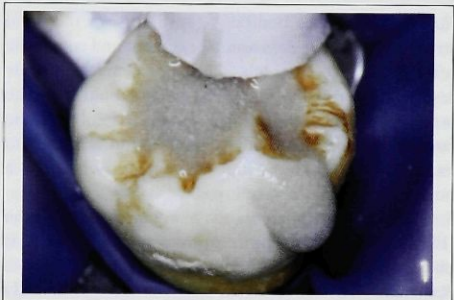

Fig 6 Occlusal surface is cleaned with an aqueous pumice slurry to remove contaminants that might interfere with bonding.



Fig 7 All surfaces to be bonded are etched with phosphoric acid.

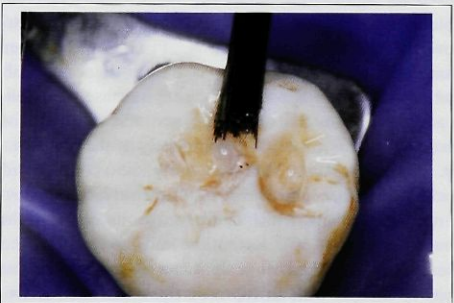

Fig 8 Bonding agent is placed on the cavity walls and surface of the glass-ionomer cement liner.



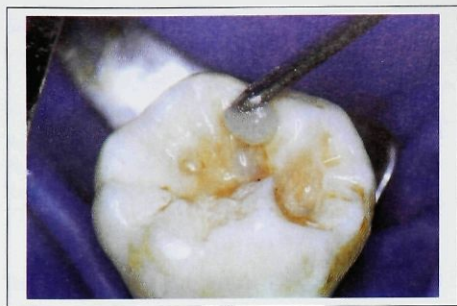

Fig 9 Posterior composite resin restorative material is placed into the minimal cavity preparations.

**Rationale.** Use of a bonding agent improves the bond strength between a glass-ionomer cement and composite resin.<sup>51</sup> Because some glass-ionomer cements include resin, an intermediate bonding agent should facilitate bonding between the glass-ionomer cement and the composite resin. If the cavity preparation is limited to enamel, and glass-ionomer cement is not used, a bonding agent is still employed.

8. *Place a posterior composite resin into the preparation* (Fig 9). If a light-curing composite resin is used, it is placed in increments of 2 mm or less.

**Rationale.** The composite resin micromechanically bonds to the conditioned enamel and provides an effective marginal seal.<sup>44</sup> Bonding occurs between the composite resin and prepared glass-ionomer cement and dentinal walls.<sup>40,41</sup> An incremental buildup should be used for light-curing composite resin, to ensure complete polymerization.<sup>52</sup> Care should be taken not to overfill the cavity preparation. Placing the proper amount of composite resin is easier to accomplish when a light-curing product is used, because the application is in small increments, and the initiation of polymerization is controlled completely by the operator.

9. *Apply sealant.* The previously acid-conditioned occlusal surface and the restoration surface are covered with sealant, which is allowed to harden or light polymerize (Fig 10). Retention and coverage of the sealant are checked. If sealant can be pried from the pits or fissures with an explorer, the tooth and restoration are re-etched for 10 seconds, washed, and dried, and new sealant is applied.<sup>53</sup>

**Rationale.** Sealant prevents caries of the pits and fissures that were not included in the cavity preparation. The laminate technique of sealant, composite resin, and

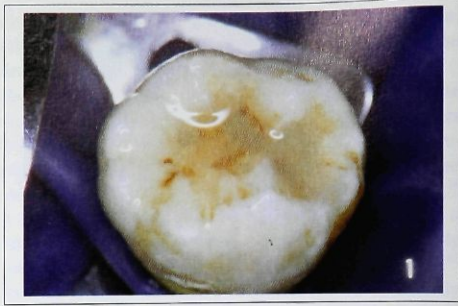

Fig 10 Sealant has been applied to the tooth and the restoration surface.

glass-ionomer cement minimizes microleakage.<sup>54</sup> 10. *Equilibrate occlusion.* If a semifilled sealant was used, the occlusion must be equilibrated after removal of the rubber dam.

**Rationale.** Unfilled sealants wear quickly to accommodate a patient's occlusion, but semifilled sealants are more abrasion resistant and require removal of high spots.<sup>55</sup>

### Clinical success

Simonsen and Stallard,<sup>56</sup> in 1977, were the first to describe preventive resin restorations and to report the results of a clinical trial. Since then, a number of clinical reports have appeared; however, studies have differed in the selection of teeth to be treated, in whether caries should be removed, and in the clinical technique used. These differences make comparison difficult.

The results of several representative studies are listed in Table 3.<sup>31,34,56-65</sup> Only studies in which there was complete caries removal are included. Three of the studies compared preventive resin restorations to other treatments. Azhdari et al<sup>59</sup> treated a control group of teeth with occlusal amalgam restorations and noted that the preventive resin technique was 25% less time-consuming than placing an amalgam restoration. Raadal<sup>34</sup> compared a sealant and composite resin combination to sealants alone and found a slightly higher retention rate for the preventive resin restoration, indicating that placing sealant over the composite resin did not affect the longevity of the enamel-sealant bond. Walls et al<sup>65</sup> calculated that teeth in their study treated with amalgam restorations had 25% of the occlusal surface involved in the restoration, while

teeth restored with preventive resin restorations had 5% of the occlusal surface involved.

Although the cited studies employed different criteria to judge the success of preventive resin restorations, the evaluations principally were of the longevity of the sealant portion, the amount of wear, and the presence of a new carious lesion or restoration on the treated surface. The results, judged by the general term *percent success*, were highly favorable (Table 3). The most common cause of failure was wear of the resin, which could be compensated for by the addition of more material at a recall visit. Houpt and coworkers<sup>62</sup> reported that of 205 teeth treated with preventive resin restorations, only 13 (6%) developed new lesions during a 4-year period. After 6.5 years, of 104 teeth still in the study, 11 (11%) had developed caries, and 65% of restorations were considered completely successful.<sup>63</sup>

## Discussion

The principal advantage of preventive resin restorations over conventional ones is that they are less invasive. Hence, sound tooth tissue is not removed unnecessarily.

The most important and difficult decisions, namely the caries status of the tooth and the treatment plan, are made before the actual invasive step is begun. No matter how scientifically founded, caries diagnosis is a subjective determination that relies on the clinical skill and experience of the operator. Dentists' diagnosis and treatment planning decisions vary greatly.<sup>8</sup> McKnight-Hanes and coworkers<sup>66</sup> reported considerable variation in the treatment decisions of 20 dentists who evaluated the occlusal surfaces of extracted permanent molars. The greatest differences occurred among teeth with questionable or carious occlusal surfaces. Treatment recommendations ranged from sealants and preventive resin restorations to amalgam restorations. Brownbill and Setcos<sup>67</sup> conducted a similar study in which 20 operators evaluated the caries status of occlusal surfaces of extracted molars. For some occlusal sites, treatment recommendations ran the gamut from no treatment to a sealant, preventive resin restoration, or conventional restoration.

The problem in clinical specificity is rooted in the subjectiveness of the diagnostic method as well as the lack of specific criteria for the indications for preventive resin restorations. This article attempts to ameliorate the situation by recommending criteria for making diagnostic and treatment planning decisions involving occlusal pits and fissures. Through a modification of Radike's<sup>5</sup> criteria for the visual and tactile diagnosis of

Table 3 Success of preventive resin restorations

Study	Duration (yr)	Success* (%)
Simonsen and Stallard <sup>56</sup>	1.0	100
Azhdari et al <sup>59</sup>	1.0	86
Walker et al <sup>64</sup>	1.25 <sup>†</sup>	82
Houpt et al <sup>60</sup>	1.5	91
Walls et al <sup>65</sup>	2.0	97
Simonsen and Jensen <sup>57</sup>	2.5	96
Raadal <sup>34</sup>	2.5	84
Simonsen <sup>31</sup>	3.0	99
Houpt et al <sup>61</sup>	3.0	77
Houpt et al <sup>62</sup>	4.0	64
Houpt et al <sup>63</sup>	6.5	65
Simonsen and Landy <sup>58</sup>	7.0	90

\* Complete retention and caries free.

<sup>†</sup> Average.

pit and fissure caries, the clinical signs of sound, questionable, and carious pits and fissures were listed and the diagnosis was related to the appropriate treatment (see Table 1). Whether use of these criteria by dentists will reduce the variability reported in diagnosis and treatment selection remains to be determined. Nevertheless, the caries criteria have been used in clinical caries trials for nearly a quarter of a century, where diagnostic reproducibility is paramount, and have stood the test of time.

One reason for the slow adoption of sealants has been dentists' concern that caries will be inadvertently sealed.<sup>68,69</sup> This same concern may extend to preventive resin restorations. A dentist could diagnose and remove caries in one pit, only to leave an untreated lesion in another pit. There is considerable clinical evidence that, once sealed, lesions will not progress and will become inactive,<sup>4,9-28</sup> so this concern should not constitute a barrier to the use of preventive resin restorations. In fact, cognizant of these results, some clinical researchers recommend deliberately leaving caries beneath a sealant or preventive resin restoration.<sup>4,13,15,20,70</sup>

The method described in this article has been referred to as the laminate technique because of the successive use of different materials. Other versions of the preventive resin restoration technique have been published. One involves the use of a glass-ionomer cement, instead of a composite resin, restoration beneath the sealant.<sup>71-73</sup> The philosophy expressed by Croll<sup>74</sup> that resins bond to enamel, while glass-ionomer cements



bond to dentin, influenced the choice of materials described in the present article.

The laminate technique takes advantage of the desirable properties of each of the materials employed. The glass-ionomer cements pose no significant threat to pulpal vitality and are used to protect the pulp as well as for their bonding properties to the dentin. The release of fluoride by glass-ionomer cements to adjacent tooth structure is an additional benefit, although it may be superfluous, considering the low failure rate reported for preventive resin restorations. Posterior composite resins bond to conditioned enamel and to the glass-ionomer cement surface. The interlocking between the tooth and dental materials reduces gaps between the cavity walls and cavosurface margin and the restoration, thus making marginal leakage unlikely. The sealant provides further micromechanical interlocking over the entire occlusal surface and protects from caries the sound pits and fissures not included in the cavity preparation.

Because of the degree of reported success and its minimal invasiveness, the preventive resin restoration is the treatment of choice for small, discrete lesions of the pits and fissures.

## References

- King NM, Shaw L: Value of bitewing radiographs in detection of occlusal caries. *Community Dent Oral Epidemiol* 1979;7: 218-221.
- Flaitz CM, Hicks MJ, Silverstone LM: Radiographic, histologic, and electronic comparison of occlusal caries: an in vitro study. *Pediatr Dent* 1986;8:24-28.
- Gwinnett AJ: A comparison of proximal carious lesions as seen by clinical radiography, contact microradiography and light microscopy. *J Am Dent Assoc* 1971;83:1078-1080.
- Mertz-Fairhurst EJ, Call-Smith KM, Schuster GS, et al: Clinical performance of sealed composite restorations placed over caries compared with sealed and unsealed amalgam restorations. *J Am Dent Assoc* 1987;115:689-694.
- Radike AW: Criteria for diagnosis of dental caries, in *Proceedings of the Conference on the Clinical Testing of Cariostatic Agents*. Chicago, American Dental Association, 1972, pp 87-88.
- Simonsen RJ: Pit and fissure sealant in individual patient care programs. *J Dent Educ* 1984;48(suppl):42-44.
- Bohannon HM, Disney JA, Graves RC, et al: Indications for sealant use in a community-based preventive dentistry program. *J Dent Educ* 1984;48(suppl):45-55.
- Meiers JC, Jensen ME: Management of the questionable carious fissure: invasive versus noninvasive techniques. *J Am Dent Assoc* 1984;108:64-68.
- Handelman SL, Buonocore MG, Heseck DJ: A preliminary report on the effect of fissure sealant on bacteria in dental caries. *J Prosthet Dent* 1972;27:390-392.
- Handelman SL, Buonocore MG, Schoute PC: Progress report on the effect of a fissure sealant on bacteria in dental caries. *J Am Dent Assoc* 1973; 87:1189-1191.
- Handelman SL: Microbiologic aspects of sealing carious lesions. *J Prev Dent* 1976;32(2):29-32.
- Handelman SL, Washburn F, Wopperer P: Two-year report of sealant effect on bacteria in dental caries. *J Am Dent Assoc* 1976;93:967-970.
- Handelman SL, Leverett DH, Solomon ES, et al: Use of adhesive sealants over occlusal carious lesions: radiographic evaluation. *Community Dent Oral Epidemiol* 1981;9:256-259.
- Handelman SL: Effect of sealant placement on occlusal caries progression. *Clin Prev Dent* 1982;4(5):11-16.
- Leverett DH, Handelman SL, Brenner CM, et al: Use of sealants in the prevention and early treatment of carious lesions: cost analysis. *J Am Dent Assoc* 1983;106:39-42.
- Handelman SL, Leverett DH, Iker HP: Longitudinal radiographic evaluation of the progress of caries under sealants. *J Pedod* 1985;9:119-126.
- Handelman SL, Leverett DH, Espeland M, et al: Retention of sealants over carious and sound tooth surfaces. *Community Dent Oral Epidemiol* 1987;15:1-5.
- Mertz-Fairhurst EJ, Schuster GS, Williams JE, et al: Clinical progress of sealed and unsealed caries. Part I. Depth changes and bacterial counts. *J Prosthet Dent* 1979;42:521-526.
- Mertz-Fairhurst EJ, Schuster GS, Williams JE, et al: Clinical progress of sealed and unsealed caries. Part II. Standardized radiographs and clinical observations. *J Prosthet Dent* 1979; 42:633-637.
- Mertz-Fairhurst EJ, Schuster GS, Fairhurst CW: Arresting caries by sealants: results of a clinical study. *J Am Dent Assoc* 1986;112:194-197.
- Going RE: Sealant effect on incipient caries, enamel maturation, and future caries susceptibility. *J Dent Educ* 1984; 48(suppl):35-41.
- Going RE, Loesche WJ, Grainger DA, et al: The viability of microorganisms in carious lesions five years after covering with a fissure sealant. *J Am Dent Assoc* 1978;97:455-462.
- Jensen OE, Handelman SL: Effect of an autopolymerizing sealant on viability of microflora in occlusal dental caries. *Scand J Dent Res* 1980;88:382-388.
- Jeronimus DJ, Till MJ, Sventen OB: Reduced viability of microorganisms under dental sealants. *ASDC J Dent Child* 1975;42:275-280.
- Mieck RE: Fate of in vitro caries-like lesions sealed within tooth structure. *J Dent Res* 1972;51(special issue):225(abstr No. 710).
- Ripa LW: Studies of pits and fissures, in Buonocore MG (ed): *The Use Of Adhesives in Dentistry*. Springfield, Ill, Charles C Thomas, Publ, 1976, pp 120-152.
- Swift EJ Jr: The effect of sealants on dental caries: a review. *J Am Dent Assoc* 1988;116:700-704.
- Theilaide E, Fejerskov O, Migasena K, et al: Effect of fissure sealing on the microflora in occlusal fissures of human teeth. *Arch Oral Biol* 1977;22:251-259.
- American Dental Association Council on Dental Materials, Instruments, and Equipment: Pit and fissure sealants. *J Am Dent Assoc* 1983;107:465.
- Leinfelder KF: Posterior composite resins. *J Am Dent Assoc* 1988;117(special issue):21E-26E.
- Simonsen RJ: Preventive resin restorations. *J Am Dent Assoc* 1980;100:535-539.
- Simonsen RJ: Potential uses of pit-and-fissure sealants in innovative ways. A review. *J Public Health Dent* 1982;42: 305-311.



33. Houpt M, Shey Z: Occlusal restoration using fissure sealant instead of "extension for prevention." *Quintessence Int* 1985; 16:489-492.
34. Raadal M: Follow-up study of sealing and filling with composite resins in the prevention of occlusal caries. *Community Dent Oral Epidemiol* 1978;6:176-180.
35. Eisenberg BP, Leinfelder KF: Efficacy of beveling posterior composite resin preparations. *J Esthet Dent* 1990;2:70-73.
36. Stanley HR, Going RE, Chauncey HH: Human pulp response to acid pretreatment of dentin and to composite restoration. *J Am Dent Assoc* 1975;91:817-825.
37. Tobias RS, Browne RM, Plant CG, et al: Pulpal response to a glass ionomer cement. *Br Dent J* 1978;144:345-350.
38. Mount GJ: Clinical requirements for a successful "sandwich"-dentine to glass ionomer cement to composite resin. *Aust Dent J* 1989;34:259-265.
39. Walls AWG: Glass polyalkenoate (glass-ionomer) cements: a review. *J Dent* 1986;14:231-246.
40. McLean JW, Powis DR, Prosser HJ, et al: The use of glass-ionomer cements in bonding composite resins to dentine. *Br Dent J* 1985;158:410-414.
41. Causton B, Sefton J, Williams A: Bonding class II composite to etched glass ionomer cement. *Br Dent J* 1987;163:321-324.
42. Swartz ML, Phillips RW, Clark HE: Long-term F release from glass ionomer cements. *J Dent Res* 1984;63:158-160.
43. Miura F, Nakagawa K, Ishizaki A: Scanning electron microscopic studies on the direct bonding system. *Bull Tokyo Med Dent Univ* 1973;20:245-260.
44. Gwinnett AJ, Matsui A: A study of enamel adhesives. The physical relationship between enamel and adhesive. *Arch Oral Biol* 1967;12:1615-1620.
45. Stephen KW, Kirkwood M, Main C, et al: Retention of a filled fissure sealant using reduced etch time. A two-year study in 6 to 8 year old children. *Br Dent J* 1982;153:232-233.
46. Eidelman E, Shapira J, Houpt M: The retention of fissure sealants using twenty-second etch time. *ASDC J Dent Child* 1984;51:422-424.
47. Fuks AB, Grajower R, Shapira J: In vitro assessment of marginal leakage of sealants placed in permanent molars with different etching times. *ASDC J Dent Child* 1984;51:425-427.
48. McLean JW: Glass-ionomer cements. *Br Dent J* 1988;164:293-300.
49. Smith GE: Surface deterioration of glass-ionomer cement during acid etching: an SEM evaluation. *Oper Dent* 1988;13:3-7.
50. Williams B, von Fraunhofer JA: The influence of the time of etching and washing on the bond strength of fissure sealants applied to enamel. *J Oral Rehabil* 1977;4:139-143.
51. Subrata G, Davidson CL: The effect of various surface treatments on the shear strength between composite resin and glass-ionomer cement. *J Dent* 1989;17:28-32.
52. Wilson EG, Mandradjieff M, Brindock T: Controversies in posterior composite resin restorations. *Dent Clin North Am* 1990;34:27-44.
53. Hormati AA, Fuller JL, Denehy GE: Effects of contamination and mechanical disturbance on the quality of acid-etched enamel. *J Am Dent Assoc* 1980;100:34-38.
54. Saunders WP, Strang R, Ahmad I: In vitro assessment of the microleakage around preventive resin (lamine) restorations. *ASDC J Dent Child* 1990;57:433-436.
55. Raadal M: Abrasive wear of filled and unfilled resins in vitro. *Scand J Dent Res* 1978;86:399-403.
56. Simonsen RJ, Stallard RE: Sealant-restorations utilizing a diluted filled composite resin: one year results. *Quintessence Int* 1977;8:77-84.
57. Simonsen RJ, Jensen ME: Preventive resin restorations utilizing diluted filled composite resins: 30 month results. *J Dent Res* 1979;58(special issue A):261(abstr No. 676).
58. Simonsen RJ, Landy NA: Preventive resin restorations: fracture resistance and 7-year clinical results. *J Dent Res* 1984; 63(special issue):175(abstr No. 175).
59. Azhdari S, Sveen OB, Buonocore MG: Evaluation of a restorative preventive technique for localized occlusal caries. *J Dent Res* 1979;58(special issue A):330(abstr No. 952).
60. Houpt M, Eidelman E, Shey Z, et al: Occlusal restoration using fissure sealant instead of "extension for prevention," eighteen month results. *J Dent Res* 1982;61:214(abstr No. 324).
61. Houpt M, Eidelman E, Shey Z, et al: Occlusal restoration instead of "extension for prevention." *ASDC J Dent Child* 1984;51:270-273.
62. Houpt M, Eidelman E, Shey Z, et al: Occlusal composite restorations: 4-year results. *J Am Dent Assoc* 1985;110:351-353.
63. Houpt M, Fuks A, Eidelman E, et al: Composite/sealant restoration: 6½-year results. *Pediatr Dent* 1988;10:304-306.
64. Walker JD, Jensen ME, Pinkham JR: A clinical review of preventive resin restorations. *ASDC J Dent Child* 1990;57:257-259.
65. Walls AWG, Murray JJ, McCabe JF: The management of occlusal caries in permanent molars. A clinical trial comparing a minimal composite restoration with an occlusal amalgam restoration. *Br Dent J* 1988;164:288-292.
66. McKnight-Hanes C, Myers DR, Salama FS, et al: Comparing treatment options for occlusal surfaces utilizing an invasive index. *Pediatr Dent* 1990;12:241-245.
67. Brownbill JW, Setcos JC: Treatment selections for fissured grooves of permanent molar teeth. *ASDC J Dent Child* 1990; 57:274-278.
68. Gift HC, Frew R, Hefferen JJ: Attitudes toward and use of pit and fissure sealants. *ASDC J Dent Child* 1975;42:460-466.
69. Frazier PJ: Use of sealants: societal and professional factors. *J Dent Educ* 1984;48(suppl):80-95.
70. Mertz-Fairhurst EJ, Williams JE, Pierce KL, et al: Sealed restorations: 4-year results. *Am J Dent* 1991;4:43-49.
71. Garcia-Godoy F: The preventive glass ionomer restoration. *Quintessence Int* 1986;17:617-619.
72. Garcia-Godoy F: Preventive glass ionomer restorations. *Am J Dent* 1988;1:97-99.
73. Henry RJ, Jerrrell RG: The glass ionomer rest-a-seal. *ASDC J Dent Child* 1989;56:283-287.
74. Croll TP: Glass ionomers for infants, children, and adolescents. *J Am Dent Assoc* 1990;120:65-68. □