

# Procedures in Implantology, Prosthodontics and Surgery



# Procedures in Implantology, Prosthodontics and Surgery

By

André Antonio Pelegrine,  
Marcelo Lucchesi Teixeira,  
Marcelo Sperandio  
and Peter Karyen Moy

**Cambridge**  
**Scholars**  
Publishing



Procedures in Implantology, Prosthodontics and Surgery

By André Antonio Pelegrine, Marcelo Lucchesi Teixeira,  
Marcelo Sperandio and Peter Karyen Moy

This book first published 2021

Cambridge Scholars Publishing

Lady Stephenson Library, Newcastle upon Tyne, NE6 2PA, UK

British Library Cataloguing in Publication Data

A catalogue record for this book is available from the British Library

Copyright © 2021 by André Antonio Pelegrine,

Marcelo Lucchesi Teixeira, Marcelo Sperandio and Peter Karyen Moy

All rights for this book reserved. No part of this book may be reproduced, stored in a retrieval system, or transmitted, in any form or by any means, electronic, mechanical, photocopying, recording or otherwise, without the prior permission of the copyright owner.

ISBN (10): 1-5275-6977-2

ISBN (13): 978-1-5275-6977-5

**Pictures:** Sandro Costa, Marcelo Lucchesi Teixeira, Rafael Cabello

**Front Cover:** Eduardo Carlos Dorazio Nogueira

To the love of my life, Renata, and my beloved children, Iara and Enzo. I also wish to dedicate this textbook to my parents, Rino and Dalva, my best ethics teachers. Thank you for all your support and love.

***André Antonio Pelegrine***

I want to dedicate this book to my family, who supported me all along my journey. To my parents Moacir (*in memoriam*) and Marli, and also to my sister Márcia.

I would like to specially thank my wife, Alessandra, and my beloved children Matheus, Guilherme, and Giulia. Thanks for all support, dedication, and love.

***Marcelo Lucchesi Teixeira***

I wish to dedicate this textbook to the unconditional passion in which André leads his professional life; though often meandering on the verge of nuisance, it was key to making this project take off! Because of this, I had to be mercifully forgiven the sacrifice of many nights of family time by those who truly make my life wholesome: my beautiful wife Amy and my very special little man Thomas. Thank you for your love, understanding, and support.

***Marcelo Sperandio***

To my loving and devoted wife and life partner, Irene, who has graciously given me the necessary time and space to complete this book, and my wonderful children, Janine and Geoffrey, for their understanding. Thank you for your support and unconditional love.

***Peter Karyen Moy***



# TABLE OF CONTENTS

|  |            |
|--|------------|
| About the Authors .....  | ix         |
| Acknowledgements .....   | xi         |
| Preface .....  | xii        |
| Presentation .....   | xiii       |
| <b>Part 1: Surgical Procedures.....</b>                        | <b>1</b>   |
| Chapter 1 .....  | 6          |
| Implant Placement Surgery                                      |            |
| Chapter 2 .....  | 40         |
| Socket Augmentation  |            |
| Chapter 3 .....  | 53         |
| Soft Tissue Management   |            |
| Chapter 4 .....  | 97         |
| Alveolar Ridge Reconstruction                                  |            |
| Chapter 5 .....  | 128        |
| Maxillary Sinus Floor Augmentation                             |            |
| <b>Part 2: Procedures for Teeth-Supported Prosthesis .....</b> | <b>145</b> |
| Chapter 6 .....  | 146        |
| Semi-Adjustable Articulator Mounting and Bite Guards           |            |
| Chapter 7 .....  | 168        |
| Teeth Preparations for Restorative Purposes                    |            |

|   |            |
|---|------------|
| Chapter 8 .....   | 201        |
| Restoration of Endodontically-Treated Teeth   |            |
| Chapter 9 .....   | 225        |
| Direct Provisional Restorations   |            |
| Chapter 10 .....  | 258        |
| Impressions   |            |
| Chapter 11 .....  | 282        |
| Framework Try-In  |            |
| Chapter 12 .....  | 292        |
| Ceramic Adjustment  |            |
| Chapter 13 .....  | 306        |
| Occlusal Adjustment for Tooth-Supported and Implant-Supported Partial<br>Prostheses |            |
| Chapter 14 .....  | 332        |
| Effective Luting  |            |
| Chapter 15 .....  | 347        |
| Ceramic Veneers   |            |
| <b>Part 3: Procedures for Implant-Supported Prostheses .....</b>                    | <b>371</b> |
| Chapter 16 .....  | 374        |
| Single Unit Restorations  |            |
| Chapter 17 .....  | 397        |
| Implant-Supported Fixed Partial Dentures  |            |
| Chapter 18 .....  | 419        |
| Complete Dentures   |            |



## ABOUT THE AUTHORS

### **André Antonio Pelegrine, PhD**

Graduated in Dentistry from Pontificia Universidade Católica de Campinas (1998), Specialist in Periodontics from Faculdade São Leopoldo Mandic (2000), Master of Science in Dentistry from Universidade de Santo Amaro (2007), Doctorate (PhD) in Clinical Medicine from Universidade Estadual de Campinas (UNICAMP) (2010), and Post-Doctorate from Unifesp (2012). Visiting Professor at the University of California (UCLA) (2018).

Currently works in private practice and as a lecturer and researcher at Faculdade São Leopoldo Mandic, coordinating specialist and master's courses.

### **Marcelo Lucchesi Teixeira, PhD**

Graduated in Dentistry from the Bauru School of Dentistry, University of São Paulo (1994). Specialist in Prosthodontics from the Hospital for the Rehabilitation of Craniofacial Anomalies, University of São Paulo (1997); Master of Science in Rehabilitation Science from the Hospital for the Rehabilitation of Craniofacial Anomalies, University of São Paulo (2000); and Doctorate (PhD) in Prosthodontics from University of São Paulo School of Dentistry (FOUSP) (2004).

Currently works in private practice and also as a lecturer at the postgraduate program of Faculdade São Leopoldo Mandic, where he coordinates specialist and master's courses in Prosthodontics and Oral Rehabilitation. Also acts as a lecturer for many companies in the prosthodontic field.

### **Marcelo Sperandio, PhD**

Graduated in Dentistry from the Bauru School of Dentistry, University of São Paulo, Brazil (1999); Master of Science in Experimental Oral Medicine from King's College London, UK (2001); Doctorate (PhD) in Oral Medicine and Pathology from King's College London, UK (2008); and Post-Doctorate from Faculdade São Leopoldo Mandic, Campinas, Brazil (2015).

He currently acts as a lecturer and researcher at the Faculdade São Leopoldo Mandic teaching diagnostic skills as well as soft and hard tissue biology to both undergraduate and postgraduate students.

**Peter Karyen Moy, DMD**

Graduated in Dentistry from the University of Pittsburgh (1978). Oral and Maxillofacial Surgeon certified by the University of California (UCLA) (1982). He is also the Nobel Biocare Endowed Chair (2011) and a Visiting Professor at the Guanghua College of Stomatology and the Fourth Military Medical.

He currently works in private practice and is a Clinical Professor in the Department of Oral and Maxillofacial Surgery at the University of California (UCLA).

**With valuable support from:**

André Coelho de Faria; Andréa Cristina Baptista Coelho de Faria; Antonio Carlos Aloise; Antonio Ramos Neto; Bruno Rodrigues Reis; Carlos Alberto Muzzili; Carlos Alberto Bergamasco de Freitas; Carlos Eduardo Sorgi da Costa; Carolina Ávila de Oliveira; Carolina Franco Ferreira Ballastreire; Eduardo Miyashita; Ellen Cristina Fagnani; Eric Cavassaki; Fábio Alessandro Simões; Felipe Franco Ferreira; Fernanda Cristina de Lacerda; Fernando Biolcati Chiantia; José Olavo Mendes; José Paulo Bataglia Júnior; Karina Andréa Novaes Olivieri; Luís Guilherme Scavone de Macedo; Mateus Favero Barra Grande; Micaela de Souza Samartine; Paulo Eduardo de Lacerda; Paulo Wilson Maia; Rafael Beolchi; Rafael Cortazzo Neto; Rafael de Mello e Oliveira; Rielson José Alves Cardoso; Rina Andrea Pelegrine; Rodrigo Othávio de Assunção e Souza; Thaís Cássia Machado; Thiago Altro de Oliveira; Thiago Mascarenhas Teixeira; Thiago Palandi Kreft; and Welson Pimentel Filho.

## ACKNOWLEDGMENTS

The authors would like to acknowledge all our friends and colleagues who have been mentors and advisors, collaborating to aid our current knowledge. We also want to thank all contributors who have made tremendous efforts to make this book reliable. We also have to thank our universities (the Faculdade São Leopoldo Mandic and the University of California) and all the companies that believed in and supported this project:

- STM Study Models (Carlos Bergamasco)
- CVDentus (Braulio Uehara Trava and Mauricio Cortes)
- Geistlich (Poul Sorensen, Luís Marcelo Calderero, Mônica Misawa, and Débora Furlani)
- IntraOss (Ricardo Rodrigues, Iara Oliveira, João Paulo Teixeira, and Wladimir Estanquiere)
- 3M Espe (Marcelo Ajeje, Caroline Miyazaki, and Hellen Romano)
- Ultradent (Antonio Carlos Gomes, Renato Miotto Palo, and Christian Oliveira)
- Kettenbach (Petra Kiemer, Ernst Hess, and Rita Carvalho)
- Bausch (Cleiton Bauler)
- Labordental (Elisa Cristina Capelossi Gomes do Amaral and Angela Zaine)
- DHPPro (Henrique Bonacin)
- Bio-Art (José Henrique Piccin and Demaurício Guereste)
- FGM (Bruna Prado, Ride Júnior de Oliveira, and Ana Paula Sobral)
- DSP (Célio Netzel)

## PREFACE

A textbook within the field of Oral Rehabilitation should have comprehensive contents including all aspects of Oral Rehabilitation, surgical and prosthetic techniques, and periodontal treatments. The authors in the present textbook most surely guarantee a thorough penetration of the actual topics. The step-by-step presentation of the different techniques is actually the best way to make them understandable. I recommend this textbook to all people that have an interest in Oral Rehabilitation.

Karl-Erik Kahnberg  
Professor Emeritus  
University of Gothenburg  
SWEDEN

## PRESENTATION

The professional formation in dentistry has some peculiarities that differ from other areas; one of them is motor skills. It is necessary to practice the procedures as much as possible to obtain better results in the clinical environment. Another concern relates to the clinical sequence of different procedures, which may vary according to the clinical situation and to the material's brand.

In this context, this book was planned to fill these demands. So, its design is focused on a step-by-step approach, but it is only based on this issue. As professors accustomed to working on the formation of skills, we think that it is mandatory to not only explain the procedure itself but also the reasons and the goals for each step. According to this approach, students and professionals can understand the rationale and work with specific aims for each procedure. The book is designed with models in order to show the ideal technique for each step, which is not possible in clinical situations. This didactic approach aims to prepare both the student and the professional so they can apply their knowledge according to any clinical situation.

The project of this book was based on a demand faced by our routine as professors. Our team, EPPIC (a Portuguese acronym for Campinas' Periodontics, Implantology, and Prosthodontic Team), is based at the Faculdade São Leopoldo Mandic in the city of Campinas, Brazil. Faculdade São Leopoldo Mandic is one of the most important dental schools in Brazil. Our experience involves graduate and postgraduate courses in the oral rehabilitation field. The EPPIC team has a scientific partnership with other institutions, and we are glad that Dr. Peter Moy (UCLA) accepted our invitation to join us in this project.

We hope you enjoy your reading and congratulate you on your concerns about improving your knowledge and skills.

André Antonio Pelegrine and Marcelo Lucchesi Teixeira



# **PART 1**

## **SURGICAL PROCEDURES**

The first part of this manual relates to the clinical protocols adopted by our team, EPPIC (a Portuguese acronym for Campinas' Periodontics, Implantology, and Prosthodontic Team), to assist in surgical preparation prior to dental rehabilitation. It is fundamentally important to emphasize that surgery is only a tool in the armamentarium of dental rehabilitation, where the prosthetic rehabilitation represents the “grand finale”. This does not undermine the importance of the surgical phase as, on the contrary, it is the foundation for implant restorations, which includes soft tissue management with an emphasis on “pink esthetics”. Timing is paramount in surgical and prosthodontic specialties in order to optimize treatment.

Part 1 describes the step-by-step surgical techniques adopted by EPPIC and aims to highlight hard tissue management as well as demystify soft tissue management in a structured and easily applied manner.

The surgical instrumentation necessary for implant placement are listed below. They are addressed as macro and micro surgical instruments (Fig. 1). An example of an implant installation kit is also provided (Fig. 2). Additional instrumentation are used for maxillary sinus floor augmentation (Fig. 3a, b), atraumatic extraction (Fig. 4), the support of soft tissue flap after bone grafting using the Barbell Technique™ (Fig. 5), for fixation/stabilization of bone blocks, and the installation of a mini implant for orthodontic traction (Fig. 6). The surgical motor and piezo units used during implant placement and grafting procedures are also shown (Figs. 7 and 8, respectively).

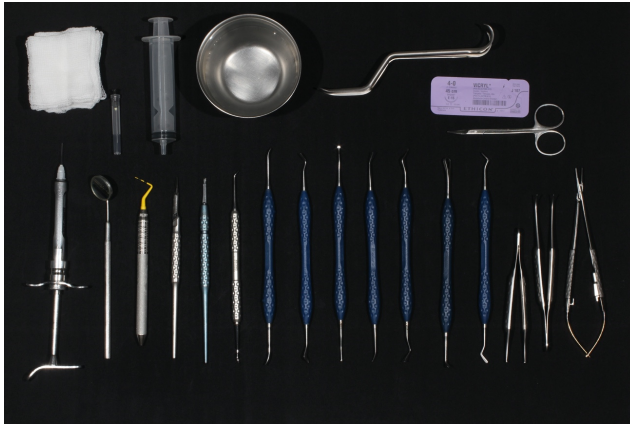

Figure 1: Micro and macro instruments used routinely in surgery.

(Gauze; disposable blunt needle; disposable syringe; stainless steel bowl; Minnesota cheek retractor; sutures; iris scissors; local anesthetic syringe; dental mirror size 5; periodontal probe; straight round scalpel handle; straight round scalpel handle for microblades; tissue dissector; freer elevator; angled tunneling instrument; papillae dissector; disk-shaped elevator; Kirkland scalpel; Stricker dissector; soft tissue spatula; Adson forceps; curved Adson forceps; Castroviejo needle holder).



Figure 2: Implant kit used in this textbook.



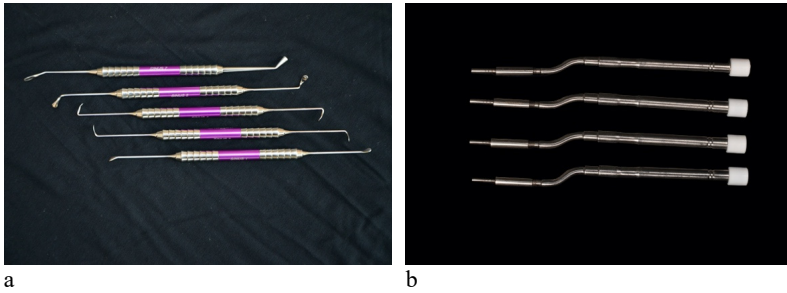


Figure 3: Sinus membrane elevation instruments used in this textbook. (a) Curettes. (b) Summers Osteotomes.

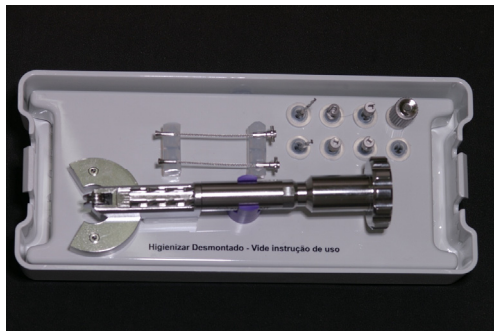

Figure 4: Atraumatic extraction kit used in this textbook.



Figure 5: Barbell Technique™ surgical kit

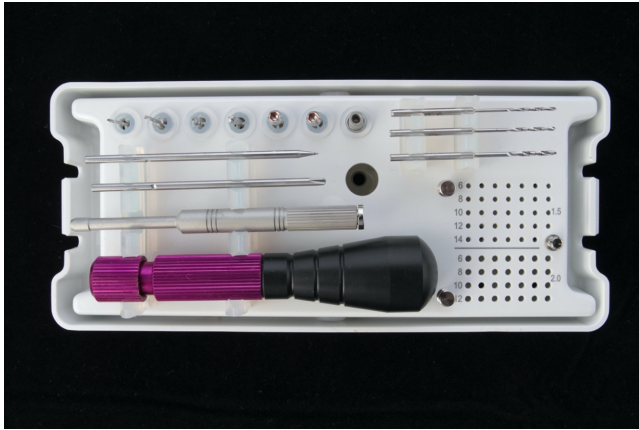

Figure 6: Bone block fixation kit (also used for the installation of orthodontic mini implants).



Figure 7: Surgical motor used for osteotomy and implant placement



Figure 8: Piezo unit used for osteotomy, flap raising, and sinus floor lifting.

# CHAPTER 1

## IMPLANT PLACEMENT SURGERY

André Antonio Pelegrine  
Antonio Carlos Aloise  
Thiago Altro de Oliveira  
Fernando Biolcati Chiantia  
Marcelo Sperandio  
Peter Karyen Moy

### INTRODUCTION

The advent of implant dentistry has revolutionized the way we treat patients. To achieve the ideal implant positioning, the surgeon must place the dental implant from the perspective of three-dimensions: mesial/distal, apical/coronal, and buccal/lingual or palatal. When three-dimensional implant placement is not performed or achieved with due care, the results may lead to biological, mechanical, and esthetic problems. Implant selection can create another issue since each case poses its own specific prosthetic requirements, and these demands must be addressed by the selected implant system. Much has been discussed with regard to the surface treatments of dental implants, but the question of macro-engineering (the shape, thread design, and dimensions of the implant) should also be thoroughly examined. The EPPIC team (a Portuguese acronym for the Campinas' Periodontics, Implantology, and Prosthodontic Team) does not adopt a standard implant design for all cases; instead, we select the implant based on the available alveolar ridge to be operated on; for example, in situations where there is a fresh socket (or low bone density) tapered implants are preferred whereas straight-wall implants are acceptable for dense and healed alveolar bones.

In many clinical situations, especially when placing implants in the esthetic region, specific surgical procedures should be considered to reconstruct or maintain the alveolar bone prior to or concomitantly with implant installation. This is why biomaterials are occasionally brought into the spotlight in this chapter, though later chapters will dissect each subject in detail, such as socket augmentation (Chapter 2), soft tissue management

(Chapter 3), alveolar ridge reconstruction (Chapter 4), and maxillary sinus floor augmentation (Chapter 5).

The current trend, especially in the esthetic region, has been the use of prosthetic connections based on the concepts of platform switching (or shifting); we will, therefore, adopt such a philosophical approach for implant placement in this chapter. One of the advantages is the increased distance between implants, or between tooth and implant, when using the platform switching concept over using conventional abutment connections.

Our team determines implant positioning based on the requirements of the definitive prosthetic crown, which is known as reverse planning. It uses surgical templates generated from the design of definitive prosthetic prototypes. This approach was used for all the cases shown in this textbook.

Chapter 1 describes the techniques recommended for installing single and multiple implants, which always seek to establish elaborate surgical templates that take both the biomechanical and esthetic aspects of the future prosthesis into account. Orthodontic mini implants are also described since they require the same meticulous placement and angulations.

## PLACEMENT OF A SINGLE IMPLANT INTO A FRESH EXTRACTION SOCKET

### Surgical considerations

- ***Implant Design (macro-engineering):*** For immediate installation (fresh socket) tapered implants are recommended. In this chapter, immediate implant placement into a fresh socket was simulated using a tapered implant with a Morse taper-type prosthetic connection.
- ***Drilling speed:*** When using conical implants, most systems recommend a drilling speed ranging between 500 and 1000 rpm aided by a 20:1 speed-reducing contra-angle coupled to an electric motor.
- ***Immediate loading:*** In esthetic regions, whenever possible, immediate loading should be considered a potential option. Such an approach optimizes the maintenance of gingival architecture thus maximizing esthetics. Since this concept is a more advanced technique, a delayed loading approach was selected for this section to illustrate the implant installation procedure itself.

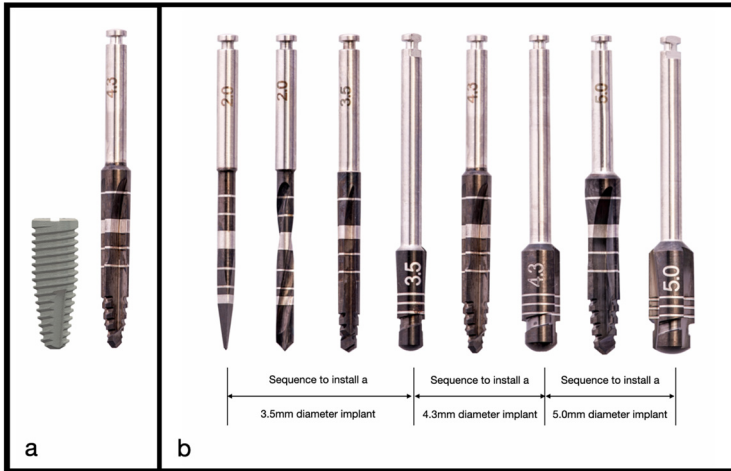


Figure 1.1: (a) Comparison between the implant length and the drill markings. Note that, for the implant system used in this textbook, the end of the top of the wide silver band coincides with a depth of 13 millimeter. (b) Enlarging the diameter drilling sequence to place a tapered implant.

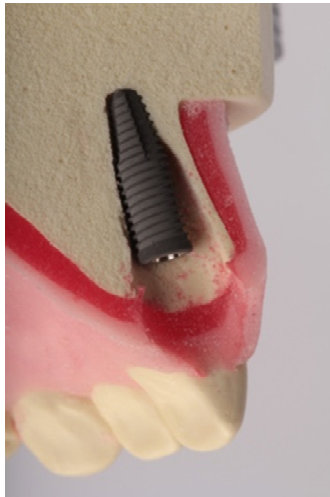

Figure 1.2: Sagittal diagram of the ideal position of the implant in a fresh extraction socket of an anterior tooth.

## 1. Tooth luxation using a periotome

**Technique:** Following local anesthesia and intrasulcular incision, a periotome is used to generate rotational movements in the mesio- and disto-buccal, as well as the mesio- and disto-palatal planes. Luxation is ascertained visually by observing the movement of the tooth.

**Objective:** Luxate the tooth to be extracted causing as little trauma as possible to the supporting tissues.

**Rationale:** Achieve exodontia lowering the risk of fracturing the buccal bone plate, which is usually thinner in esthetic regions.

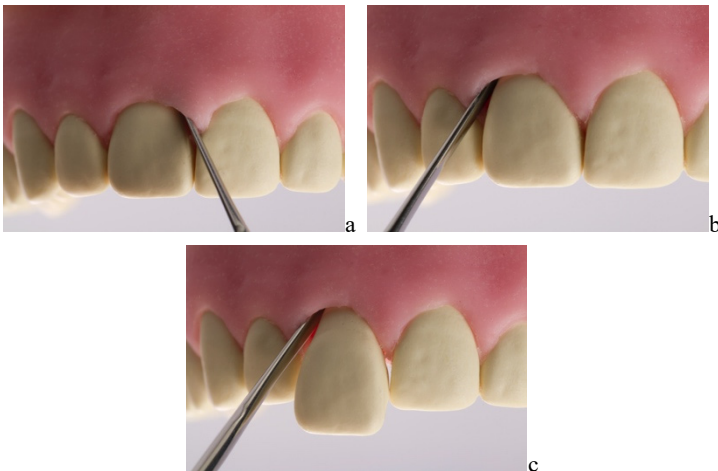


Figure 1.3: Use of a periotome in the mesial (a) and distal (b-c) positions.

## 2. Tooth removal and socket assessment

**Technique:** Once the luxation of the tooth has wedged the tooth from the socket, the tooth is removed with hemostat or extraction forceps and the fresh socket is inspected for the integrity of the bony walls.

**Objective:** Ensuring the maintenance of the four walls (buccal, palatal, mesial, and distal) will increase the predictability of the esthetic outcome.

**Rationale:** If the bone is damaged during extraction (most commonly the buccal wall), an occlusive membrane for guided bone regeneration (GBR)

must be placed to prevent soft tissue overgrowth towards the inner aspect of the socket.

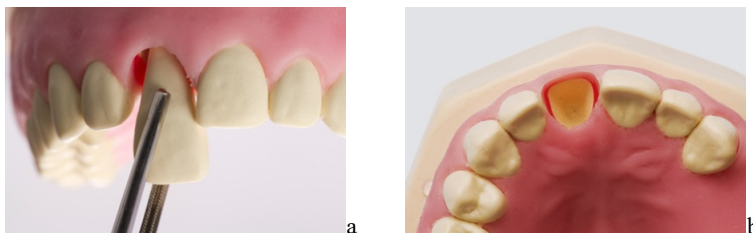

Figure 1.4: Tooth removal with tweezers (a) and verification of the integrity of the bone walls (b).

### 3. Surgical guide try-in

**Technique:** Upon completion of the treatment planning supported by adequate radiographic examination, study casts, and diagnostic wax-ups, the radiographic guide is converted to a surgical template. The surgical template should be tried-in clinically prior to surgery to ensure proper fit.



**Clinical Tip:** If a fully static-guided surgery is planned, a static surgical template must be digitally printed.

**Objective:** To ensure correct positioning of the implant from a three-dimensional perspective.

**Rationale:** Skipping the surgical template step may lead to inappropriate positioning of the implant, which, in turn, may subsequently lead to a negative impact on both function and esthetics.

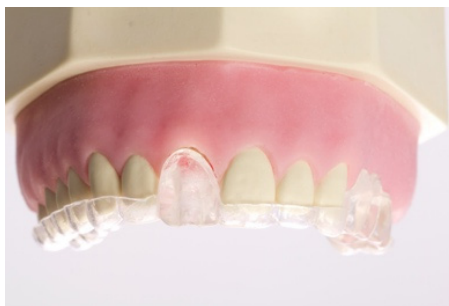

Figure 1.5: Acrylic surgical template in position.



#### 4. First drilling step (use of a spear-pointed drill)

**Technique:** A channel is prepared into the dense palatal wall of the fresh socket; the spear-pointed drill or #8 round drill can be used depending on the surgeon's preference. The drill is placed at a right angle into the palatal bone plate and then straightened vertically, always under constant irrigation. The surgical template can then be tried in with the drill in place.

**Objective:** The use of a spear-pointed drill or #8 round drill as a first preparation tool enables positioning the implant more palatally by engaging the dense cortical bone of the palate.

**Rationale:** Palatal positioning of the implant ensures the maintenance of a gap between the implant and the buccal bone plate. When this gap is filled with slow resorbable biomaterial, dimensional changes to the socket are minimized.

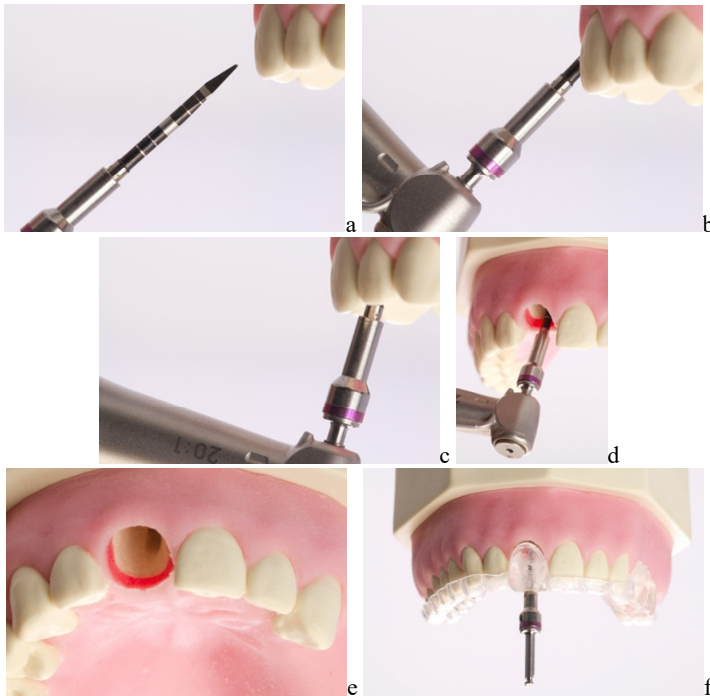


Figure 1.6: (a-b) First inclination of the spear drill to engage the palatal bone. (c-d) Drill verticalization. (e) Occlusal view of the bone osteotomy creating a channel for

the subsequent twist drills to follow. (f) Confirmation of the correct inclination with the aid of the surgical template.

### 5. Second drilling step (use of a 2.0 mm twist drill)

**Technique:** Guided by the channel made using the spear-pointed drill or #8 round drill, the next twist (typically 2 mm in diameter) is used for the total length of the selected implant (this drill has demarcations that match different implant lengths), using the buccal bone wall as a reference point. During the drilling procedure, the surgeon should always remember that the drill must be used under constant irrigation to avoid overheating the recipient bone bed. The parallel pin and the surgical template are then placed together to ascertain adequate three-dimensional implant positioning.



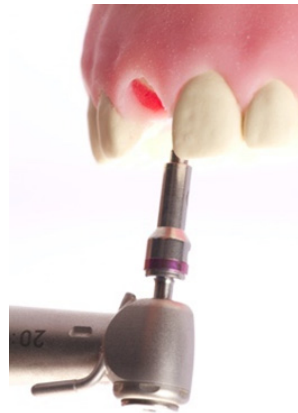**Clinical Tip:** Morse-taper implants with platform switching capabilities may be inserted below the bone crest. Therefore, it is necessary to advance the drilling 1 to 2 mm deeper than the actual length of the implant.

**Objective:** The 2 mm twist drill creates the channel establishing the final position of the implant and paves the way to smoothly advance to larger diameter tapered drills.

**Rationale:** The use of a tapered drill without prior preparation with a 2-mm twist drill tends to force drilling towards the buccal bone wall jeopardizes the gap needed between the implant and the buccal bone plate.



a



b

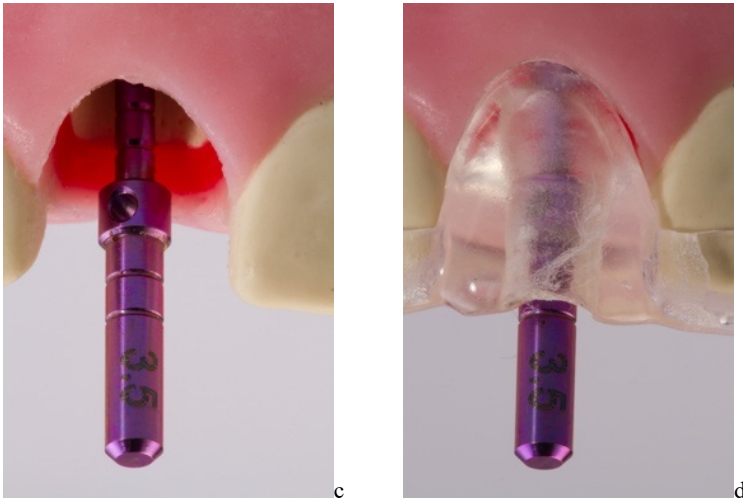


Figure 1.7: 2 mm twist drill with the markings corresponding to different lengths (a). The direction of drill is the same as that established by the spear-pointed drill (b). Three-dimensional evaluation of the drill position with the parallel pin (c) and coupled with the surgical template (d).

## 6. Tapered drill

**Technique:** With the direction of the drills within the surgical socket now established, the sequence of tapered drills is applied, which should adhere to the proper working length determined in the previous step and follow the depth markings on the drill.

It should begin with the next largest diameter twist drill and then be sequentially enlarged until it is the appropriate diameter to accommodate the implant, which is always under constant irrigation.

💡 **Clinical Tip:** In the case of low-density bone, using sequentially enlarging diameter twist drills may result in overpreparing the recipient site and an inability to establish initial implant stability; therefore, when dealing with low-density (soft) bone, the preparation of the bone bed should stop one drill before that recommended by the manufacturer. In the case of large sockets (greater than the diameter of the selected implant), as well as in cases where there is very thin cortical bone, the countersink drill should not be used.

**Objective:** The use of tapered drills permits the installation of tapered-body implants.

**Rationale:** In fresh sockets, from a macro-engineering point of view, tapered implants are the best option.

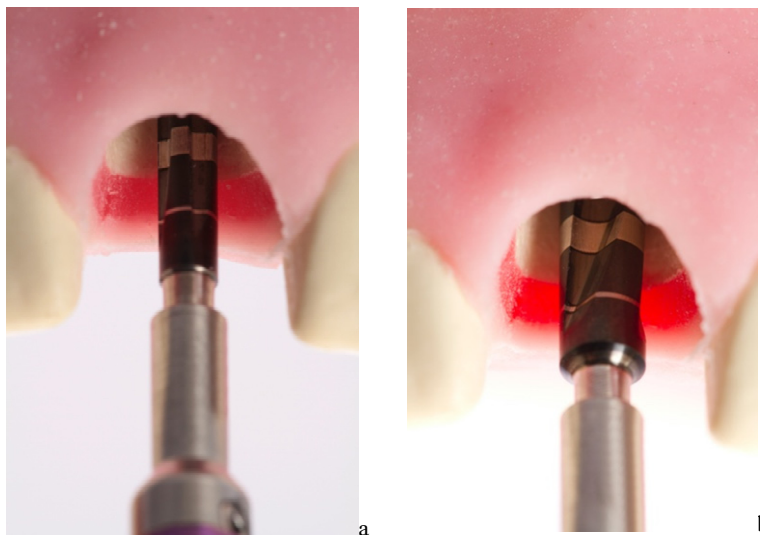


Figure 1.8: Use a conical drill 2.8 mm (a) and 3.5 mm drill (b) in the predetermined direction and at a height of 13 mm.

## 7. Implant pick-up from package

**Technique:** After opening the implant package and engaging the implant insertion tool connected to the contra-angle, the implant snaps into the connection tip of the insertion tool.

**Objective:** Installing the implant using a rotatory speed-controlled contra-angle.

**Rationale:** The threaded area of the implant must not be touched because it may become contaminated, thereby potentially jeopardizing osseointegration.

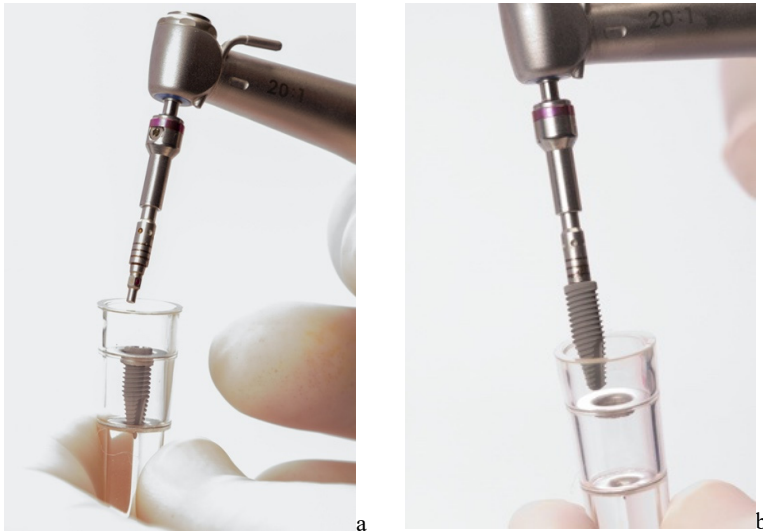


Figure 1.9: Using the implant insertion tool connected to the contra-angle (a) to engage the implant and carry to the recipient site for insertion (b).

## 8. Implant placement

**Technique:** Once the implant has been attached to the contra-angle insertion tool, the implant is inserted into the bone osteotomy at a speed of 30 rpm, without the use of irrigation. The installation is finalized with a surgical ratchet to position the neck of the implant between 1–2 mm below the buccal bone crest.

**Objective:** Permit implant placement with maximum accuracy, safety, and efficacy.

**Rationale:** Implant placement using a contra-angle minimizes the risk of deviating from the insertion axis. Finishing with a ratchet ensures safety, an accurate torque, and optimized visual access to ascertain the correct positioning of the implant.

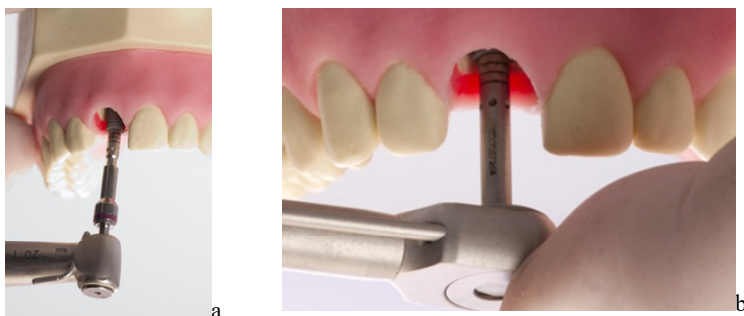


Figure 1.10: Using the implant carrier and contra-angle for the initial implant placement (a). The end of the implant installation should be performed with a hand-held torque wrench (b).

## 9. Filling the gaps

**Technique:** In the case of delayed loading, a cover screw is connected to the placed implant. In cases of immediate loading, an abutment is connected instead of the cover screw. The gap remaining between the implant and the buccal wall should be filled with slow resorption bone substitute biomaterial.



**Clinical Tip:** When filling the gap, care must be taken not to overly pack the biomaterial. Vigorous condensation may end up sealing the interconnecting pores within the biomaterial, which are necessary for the revascularization and osteoconduction of the newly formed bone.

**Objective:** To minimize postoperative dimensional loss of the alveolar bone, which would normally occur following exodontia.

**Rationale:** The use of a slow resorption biomaterial, such as bovine hydroxyapatite, alters bone remodeling patterns, minimizes dimensional changes, and provides continued support of gingival tissue thus maintaining gingival esthetics.