

WILEY

# Prosthodontics

---

## Dentistry Sampler

Chapter 3: Definitive Impressions  
From *Application of the Neutral Zone*  
in *Prosthodontics*.

by Joseph J. Massad, David R. Cagna, et al



## 3

# Definitive Impressions

## Preimpression Considerations

A denture impression represents a negative likeness of structures within the edentulous mouth [1]. Inaccurate impressions will result in ill-fitting and unstable dentures. It is paramount that denture-bearing tissues be healthy, unchanging, and free of pathologies, soreness, inflammation, and distortion, prior to making definitive impressions. Associated systemic disease, diet, chronic trauma, and bony abnormalities should be addressed. Complete dentures fabricated on unfit denture-bearing mucosa will lead to further deterioration of tissue health and compromise the prosthetic outcome [2].

## Background

Complete denture impression techniques have enjoyed a rich history in the dental literature. Three dominant philosophies have evolved: (i) definitive-pressure impressions; (ii) minimal-pressure impressions; and (iii) selective-pressure impressions [3–5]. In the first theory, attempts are made to capture the intraoral tissues in a force-loaded state. Although now seldom used for impression making, modifications of this method do have practical value as a technique for relining intaglio denture surfaces. The theory of minimal-pressure employs the principles of mucostatics. In contrast to the first theory,

attempts are designed to record the mucosa in a completely passive, nondisplaced state. Although it is impractical to achieve this fully, the use of a highly flowable impression material to avoid tissue distortion is widely accepted. The selective-pressure concept considers the variable constitution of individual intraoral anatomy and attempts to direct greater functional loads to primary stress bearing areas. Customized trays have traditionally been fashioned in which more space relief or venting is provided for the non-stress-bearing tissues. In addition, the perimeters of the trays are customized to conform to the functional extents of the vestibules. Presently, variations of this concept are the most widely accepted and practiced [6].

A majority of dental schools currently impart to students a multistep, selective, pressure technique, which includes a primary impression, construction of a primary cast on which a custom definitive impression tray is created, intraoral development of the tray periphery, and definitive impressions made with an appropriately flowable material [7, 8].

## Impression Fundamentals

The following objectives for making definitive edentulous impressions have been suggested [9–11]. These axioms help to provide support, stability, and retention for the

eventual prosthesis and preserve health of the biologic tissues:

- 1) The impression should cover the entire basal seat within the limits of function of various orofacial muscles. Maximum coverage helps dissipate the forces over a large area, reducing the amount of force on each square millimeter.
- 2) The impression should have maximum contact with denture-bearing mucosa, to ensure adequate fit of the final prosthesis.
- 3) The borders of complete dentures should be defined physiologically so that they are in harmony with the anatomic and functional limits of the denture foundation and adjacent tissues.
- 4) The impression should be made such that its dimensions and contours replicate the intended contours of the definitive complete denture.

In order to make an accurate impression, it is imperative to understand the anatomy and physiology of the individual edentulous mouth and the methods to identify and capture dynamic postures. The vestibular extents of both arches should be relieved and functionally re-established by associated muscular activation within the impression to form the eventual denture flange borders. A medium that has both additive and subtractive working properties is preferred to accomplish this. Care must be taken not to suppress or overextend areas of attachment such as the frenulae or areas that express physiologic mobility requirements such as the floor of the mouth and retromylohyoid region of the mandible [12]. The postpalatal seal area is defined as the soft tissue area at or posterior to the junction of the hard and soft palates, on which pressure within physiologic limits can be applied by a maxillary complete denture to aid in its retention. It is important to identify, assess, and capture the extent of this region in the maxillary impression [13].

It is also crucial to understand where more moderate pressure can be applied and where it should be minimized during the making of definitive impressions [14]. In the edentulous

maxilla, moderate pressure may be applied on the horizontal portions of the hard palate, tuberosities, rugae, and the ridge crests (if covered with firm, healthy, nondisplaceable mucosa). These are considered to be stress-bearing areas in the maxilla. The median palatal raphe and incisal papilla need to be relieved and recorded with minimum pressure. For making an impression of the edentulous mandible, the buccal shelves, ridge crests, and retromolar pads (if firm) are considered stress-bearing areas and can be recorded with moderate pressure. Mobile mandibular ridge crests and associated lingual extensions need to be recorded with less pressure.

## Impression Materials

Historically, much attention has been given to the wide variety of materials available for making edentulous impressions including plaster, modeling plastic impression compound, zinc oxide-eugenol paste, irreversible hydrocolloid, polysulfide, polyether, and vinyl polysiloxane. All of these materials may perform adequately in the hands of an experienced practitioner.

More recently, vinyl polysiloxane (VPS) has become a popular material of choice for definitive dental impressions. VPS impression material, an addition reaction silicone, is available in different viscosities (extra light, light, medium, heavy, and rigid) and with different working times. Subsequent layers of VPS can be added sequentially to existing polymerized material, permitting a layering technique. Heavier bodied materials offer sufficient working times and viscosity to permit physiological molding of the borders of the impression tray and primary stress-bearing areas, while more flowable materials can capture mobile tissues without distortion [15]. Vinyl polysiloxane impression materials are easy to use and disinfect, are accurate, have favorable tear strength, and can remain dimensionally stable for an

extended period. These materials have excellent elasticity and wettability, which enhance detailed recording of oral tissues and complement gypsum cast production [16]. They also offer the benefit of repeated pourability for the production of multiple casts from a single impression.

## Edentulous Impression Trays

Physical properties of the impression tray and its manipulation constitute important considerations in the impression process. Historically, the use of custom impression trays to make definitive edentulous impressions has been considered essential for accurate results. Improvements in impression materials and impression trays have made it possible to avoid the necessity for custom impression trays [15]. Today, stock trays are available that can be molded and shaped to conform to the dimensions and contours suitable to the anatomy of edentulous patients. These can eliminate the need for making primary impressions and for construction of custom trays. Stock impression trays used for making a definitive impression, should meet the following requirements [15]:

- 1) The tray should be rigid enough to permit border-molding procedures and support the impression material.
- 2) The trays should be available in various sizes for variety of edentulous arches. A large tray used on a small arch or small tray used on a large arch will distort the tissues.
- 3) The trays should permit both subtractive and additive modification of denture borders to permit recording the vestibular extensions physiologically without distorting or displacing soft tissues.
- 4) The tray design should provide retention for the impression material.
- 5) The tray handle should not interfere with border-molding movements.

Specialized thermoplastic stock trays, specifically designed to meet the requirements of edentulous patients, have been produced for making definitive impressions (Massad edentulous impression trays). These trays are constructed of a polystyrene-based polymer and can be customized and molded according to individual patient anatomy and physiology. They are designed with contoured vestibular borders, retention slots, and ergonomic finger rests. The retention slots designed in the tray help record the denture-bearing soft tissues with minimum distortion and displacement and also provide a means of mechanical retention of impression material. Ergonomic finger-rest extensions help the molded tray to remain rigid and to distribute pressure evenly across the denture bearing areas. Well-designed tray handles are positioned such that they do not interfere with the border-molding movements.

## Technique for Making Single Appointment Definitive Impressions for Conventional Complete Dentures

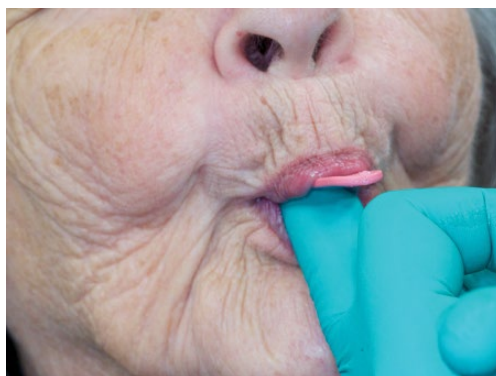An innovative technique is presented to simplify the procedure of impression making and decrease the number of clinical appointments [17].

### Tray Selection and Tray Adaptation

As a preliminary step, before engaging the mouth, it is recommended to clean and hydrate the denture-bearing soft tissues prior to impression making. This can be accomplished by asking the patient to take a few sips of warm water, to hold it in the mouth and then to use a rotary oscillating or pulsating toothbrush to massage the denture bearing soft tissues. Care should be taken not to allow excess water to leak out of the mouth prior to rinsing. This procedure will not only help massage and hydrate the tissues but will



**Figure 3.1** Maxillary thermoplastic tray immersed in water bath.



**Figure 3.2** Patient performing various movements to physiologically mold thermoplastic tray.

also help decouple residual plaque and any residual denture adhesive that may compromise the tray or impression procedures.

The featured trays are available in five maxillary sizes and five mandibular sizes. The appropriately sized stock impression tray is selected by placing each end of a measuring caliper on the posterior third (maxillary tuberosity for the maxilla and retromolar pad for the mandible) of the alveolar ridge. This measurement should correlate with measured ridge size. The selected tray is tried into the mouth and verified. The entire tray can be molded by heat to improve its conformation to the patient's arch by placing into a controlled heated water bath at 165°F for approximately 20–30 s or until the tray material softens (Figure 3.1). Cheek retractors can be used to permit easy access to the oral cavity. After softening, the tray is immediately reinserted into the mouth and the patient guided to perform border-molding movements (Figure 3.2).

The tray material hardens in 5–10 s, after which it can be removed from the mouth and analyzed for accuracy. The tray and tray borders can be modified using laboratory rotary instruments and direct flame heat molding if necessary. Ideally, the tray borders should be positioned in the middle of the vestibules and be wide enough not to create tissue impingement.

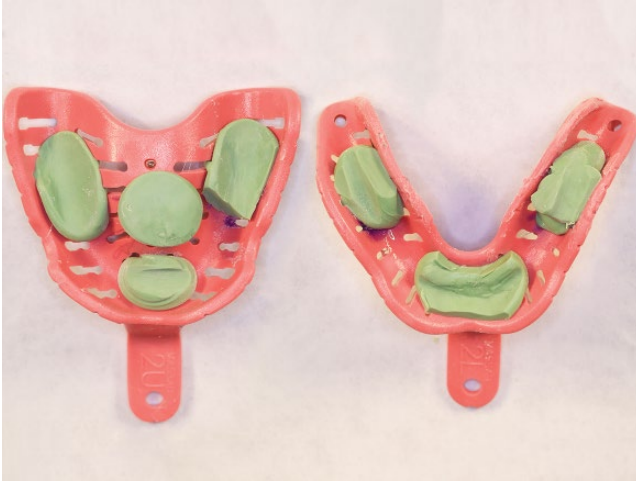### Fabrication of Tray Stops

Making a definitive impression requires multiple placements of the impression tray in the oral cavity. Formation of tray stops is critical to this technique so that consistent and repeatable tray placements position can be achieved. Tray stops help accomplish several objectives as described in Box 3.1 [15].

Nickel-sized circles of rigid-viscosity VPS impression material are injected into the maxillary tray in four locations (incisor, molar and mid-palate) and the tray is carried into the patient's mouth. For the mandibular tray, stops are formed in three locations (incisor and bimolar). Trays are centered and seated on the respective

#### Box 3.1 Objectives of tray stops

- To provide a constant path of tray insertion.
- To provide appropriate space for impression material.
- To help stabilize the tray in a centered position and prevent rotational movement of the tray during impression making.
- To help stabilize the tray during patient generated border molding procedures.
- To prevent overseating of the tray while making a definitive impression.



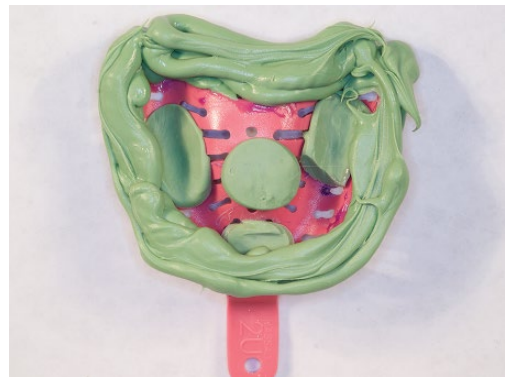**Figure 3.3** Tray stops formed in maxillary and mandibular trays.

arch and kept 2–3 mm away from the vestibular sulcular extents. Impression material is allowed to polymerize for 2 minutes. The tray is removed, evaluated and modified as needed before proceeding. The tray stops are trimmed with a sharp blade to reduce areas of excessive tissue contact (Figure 3.3).

#### Border Molding the Impression Tray

Border molding is the process of “shaping of the periphery of an impression tray, by functional or manual manipulation of the adjacent tissue, to duplicate the contour and size of the vestibule.” The border-molding procedure aids in defining the appropriate length and dimension of denture border, which is critical to establish a peripheral seal. Overextended denture borders may encroach on muscle attachments leading to soreness, ulceration of the tissues, and denture dislodgement during function. Rigid viscosity VPS is dispensed along the peripheral extents of the tray (Figure 3.4), placed in the mouth and centered over the ridge with the aid of the tray stops.

The dynamic manipulations for physiologically molding the borders of the maxillary tray are listed in Box 3.2. The tissue



**Figure 3.4** VPS material dispensed along peripheral extent of maxillary tray.

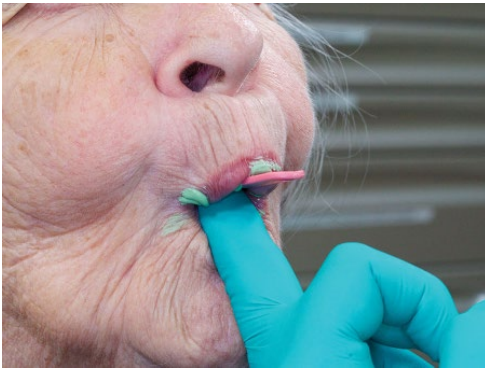manipulations for physiologically molding the borders of the mandibular tray are listed in Box 3.3.

Following complete polymerization of the impression material, the impression tray is removed from the mouth and the borders evaluated to ensure recording of all the anatomic and functional detail. Areas of tray show through should be adjusted with laboratory rotary instruments or a sharp blade by 1–2 mm. Additional relief should be provided for non-pressure bearing tissues. All the borders are then relieved by 1–2 mm

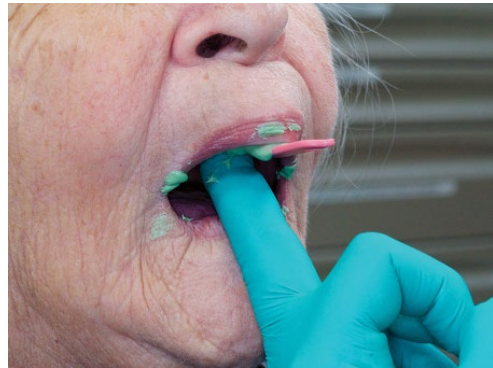

**Box 3.2 Dynamic manipulations for molding the borders of the maxillary tray**

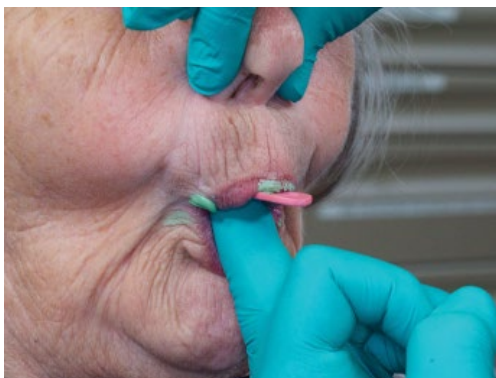
- 1) The philtrum is grasped close to the lip line and pulled downward to record the labial frenum.
- 2) The patient is asked to purse the lips outward with a sucking action (Figure 3.5) to register the labial vestibular extension.
- 3) The corners of the mouth and cheek are grasped with forefingers and thumb and pulled downward and forward to record the buccal frena and buccal vestibular extensions.
- 4) Instruct the patient to move the mandible from side to side and to drop down to opening position. Both these actions help record the disto-buccal vestibular sulci and hamular frena (Figure 3.6).
- 5) Occlude the patient's nostrils and ask them to exhale through the nose only (Figure 3.7) (Valsalva maneuver). This will lead to migration of the soft palate downwards to its functional position thereby forming the postpalatal border.



**Figure 3.5** Patient purses lips outward with a sucking action to register the labial vestibular extension.



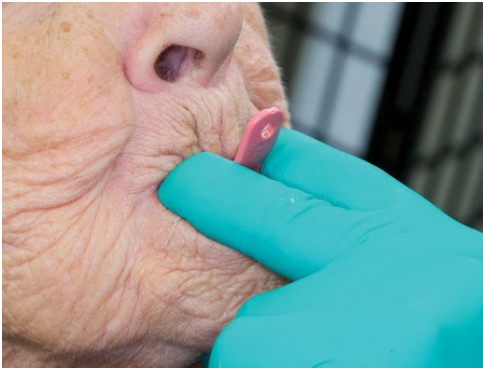
**Figure 3.6** Patient moves the mandible from side to side, drops it down to opening position, to record distobuccal vestibular sulci and hamular frena.



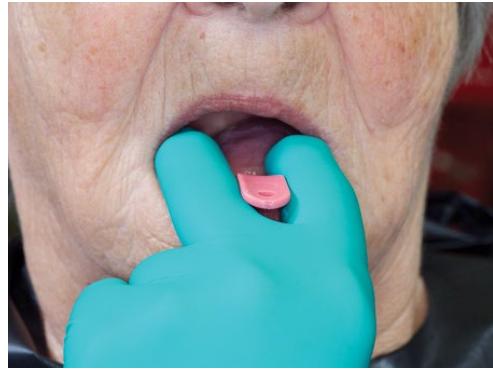**Figure 3.7** Patient's nostrils occluded and patient instructed to exhale only through nose to aid in forming postpalatal border.

### Box 3.3 The tissue manipulations for physiologically molding the borders of the mandibular tray

- 1) The patient is asked to place the tip of the tongue straight out and forward, then side to side, then back touching the roof of the mouth, and then to swallow. These movements help record the lingual vestibule and retromylohyoid fossae without overextension of borders.
- 2) The lower lip is grasped at the lip line, then pulled upward and forward; this registers the labial frenum and labial vestibular extensions.
- 3) The tray is secured by placing two fingers on the tray finger support and the thumb under the patient's chin (Figure 3.8). The patient is asked to purse the lips out and suck. This records the buccal and labial vestibules.
- 4) The corners of mouth are grasped with the forefingers and thumb and pulled downward and forward to record the buccal frena and distobuccal vestibular extensions.
- 5) The patient is asked to open wide and then close the lower jaw on the practitioner's finger while the practitioner exerts a downward force on the tray (Figure 3.9). The activation of the masseter muscle causes bulging of the buccinator, leading to the development of the massetric notch in the impression. This also helps define the posterior extent and retromolar pad areas.



**Figure 3.8** Impression tray is secured and patient is asked to purse lips out and suck to record the buccal and labial vestibules.



**Figure 3.9** The patient asked to open wide and then close the lower jaw while the practitioner exerts a downward force on tray to define posterior extent and retromolar pad areas.

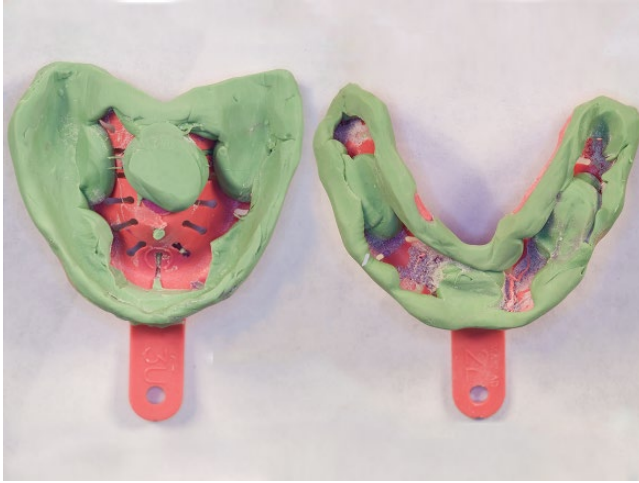prior to making definitive impressions (Figure 3.10).

#### Final (Definitive) Impression

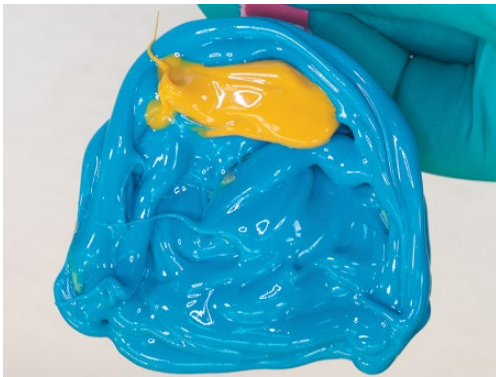The appropriate viscosity of VPS for the final impression is chosen based on the condition of the existing denture-bearing tissues (tissue character and mobility.) Medium/light

viscosity VPS is recommended for firm, nondisplaceable tissues. For mobile, flabby or redundant tissues, relief can be provided by removing adjacent set impression materials from the tray and extra-light viscosity VPS can be used. A combination of different viscosities can be used simultaneously, depending on the nature and character of denture-bearing tissues.



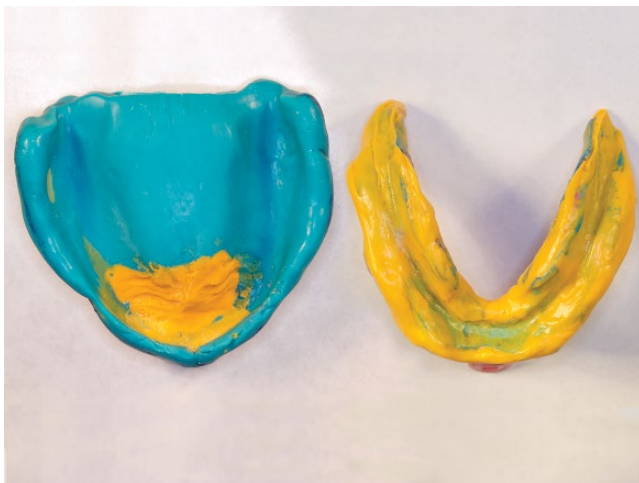

**Figure 3.10** Border molded and relieved maxillary and mandibular impression tray.



**Figure 3.11** Maxillary impression tray loaded with two different viscosities of VPS material.

The tray is loaded with the chosen viscosities of the VPS impression material (Figure 3.11), and is placed and centered in the mouth until tactile resistance is felt once the established tray stops are approximated. The manipulations listed previously for the respective arches are repeated to again mold and record all borders. Following complete polymerization of the VPS material, the impression is removed from the mouth and each evaluated for anatomic, functional and surface detail (Figure 3.12). Excess material can be trimmed, if necessary, with sharp scissors / blade. Patients may be asked to remove the impression from the mouth



**Figure 3.12** Maxillary and mandibular definitive edentulous impressions.

themselves so that they can truly perceive the retention of their new prosthesis. If patients seem to be dissatisfied with the retention of the impression, they should be advised to consider an implant-retained prosthesis.

### Techniques for Making Single Appointment Definitive Impressions for Implant-Assisted Complete Dentures and Immediate Dentures

The use of endosseous dental implants to assist in the support, stability, and retention of removable prostheses is considered an effective treatment modality for edentulous patients. Individuals wearing implant-assisted overdentures typically report improved oral comfort and function when compared with conventional, mucosa-supported prosthesis [18–23]. Vinyl polysiloxane (VPS) impression materials are well suited to address both the accurate registration of denture-bearing tissues and peripheral anatomy, and the stable recording of dental implant positions and individual implant trajectories [24].

Implant overdenture VPS impression techniques involve overdenture attachment selection, tray selection and adaptation, tray stops, border molding, and the definitive impression.

#### Attachment Selection

A distinction should be made regarding the number of implants and configuration of the attachment systems recommended for the individual edentulous patient. The number of implants could range from two to four (accompanied by free-standing abutments, which retain the denture but still rely on the mucosa contacting the denture base to help support the prosthesis), to four or more (using a bar constructed to connect the abutments to provide both retention and support for the prosthesis).

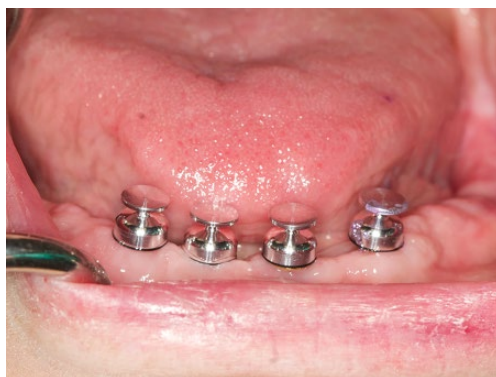### Implant-Retained Overdentures

A variety of attachment systems have been developed and marketed for use with implant-retained overdentures. Some systems are designed to pick up retentive components directly in the finished denture. Others use an indirect approach, which include an impression with transfer copings (Figure 3.13).

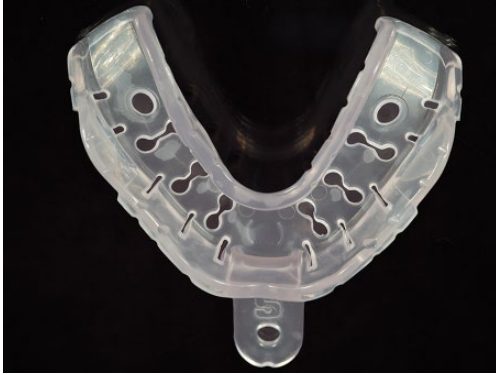A master cast is created that displays all of the anatomy used to construct an overdenture and also contains analogs to which retentive components are attached and processed into the denture base. Impressions for implant retained, free-standing, attachment systems are generally made using a “closed-tray” technique.

#### Tray Selection

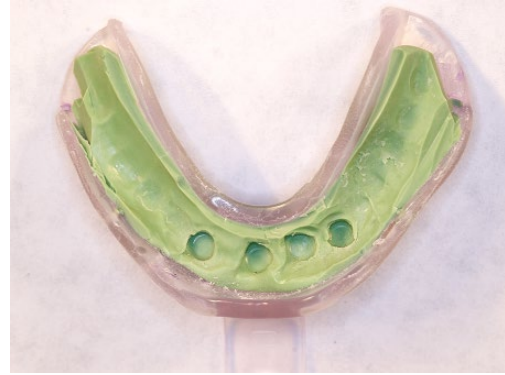Carefully examine the dimensions of the dental arch and select the appropriate stock impression tray. The thermoplastic impression trays illustrated (strong-Massad dentate and implant trays – Figure 3.14) are constructed from a polystyrene-based polymer and are available in three maxillary sizes and three mandibular sizes: small, medium, and large. These trays are clear to permit see-through visibility to assist in size selection, and heat moldable to aid in adapting the tray. Sufficient room between the tray and all implant attachments and impression components must be provided.



**Figure 3.13** Implant attachment transfer copings connected to each overdenture abutment.



**Figure 3.14** Clear thermoplastic stock impression tray for implant/dentate impressions.

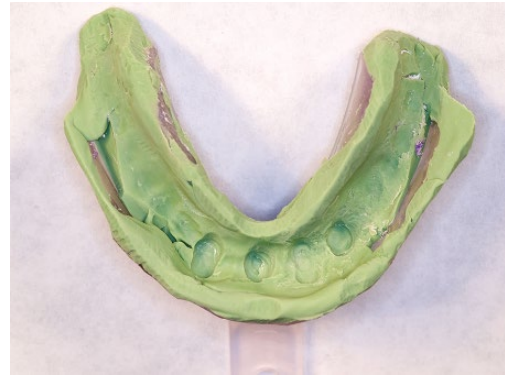

**Figure 3.15** Tray stops formed with rigid VPS impression material.

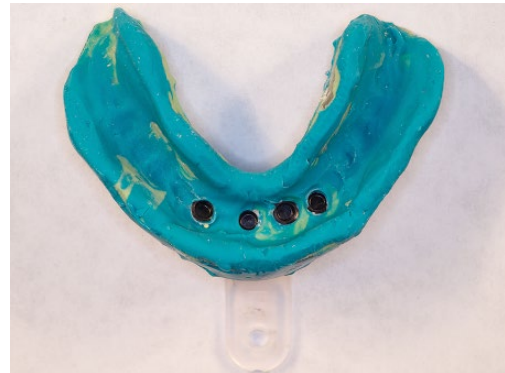### Impression Technique

To achieve consistently repeatable tray placements, tray stops are developed as described before using a rigid-viscosity material (Figure 3.15). Border molding using a rigid-viscosity material is accomplished using the listed protocol (Figure 3.16). Once the material has set, the tray is removed from the mouth and the borders are adjusted and relieved 1–2 mm, in preparation of the definitive impression. Care should be taken to also relieve any set material that has engaged the implant attachment transfer components.

Both low and high viscosity VPS materials are placed in the developed tray. High viscosity VPS is placed in the area of the abutment impression copings. Lower viscosity materials are used elsewhere in the tray. Low-viscosity VPS material is injected around the implant attachment transfers in the mouth. The tray is placed into the mouth using tray stops and tray borders to guide tray placement. The border molding protocol is repeated. Once the material has polymerized, the tray is removed and the impression examined for correct anatomic, functional and surface detail (Figure 3.17). Any required corrections can be made using the subtractive and additive methods described above.



**Figure 3.16** Tray borders molded and trimmed prior to making final impression.



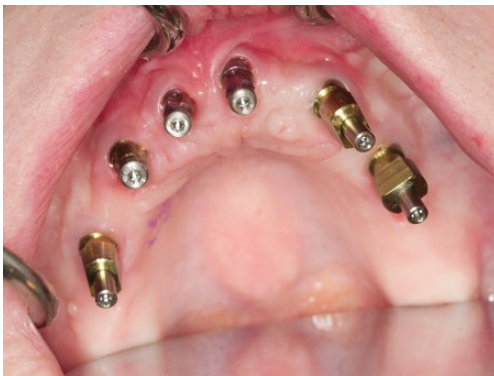**Figure 3.17** Mandibular closed tray definitive impression for implant retained overdenture fabrication.

## Implant-Retained and Supported Overdentures

Support and retention for a complete implant overdenture is possible with enough adequately dispersed free-standing abutments. However, this section will discuss impression procedures unique to bar-supported prostheses [25].

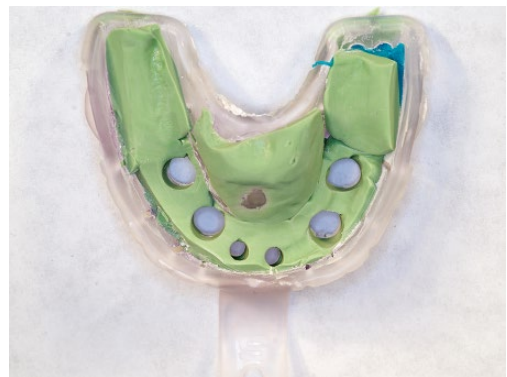A variety of manufacturers offer transfer copings, which are attached by screws to the intraoral components, for use during impression procedures. Transfers can be made directly from the implant interfaces or from the interfaces of intervening transmucosal abutments. Resultant master casts will contain analogs of the construction platforms for a connecting bar, which will be complemented by retentive components processed within the overdenture. Impressions for implant-bar retained and supported overdentures are generally made using an “open-tray” technique. Previously mentioned edentulous or dentate thermoplastic trays can be used. Direct transfer copings are connected intraorally to each implant or abutment interface (Figure 3.18).

Positions are estimated and holes placed in the tray with an acrylic bur to allow passage of the transfers through the tray when seated. Tray stops are accomplished as before, using rigid viscosity VPS material. It is important to relieve the areas of any set material adjacent to the transfer copings (Figure 3.19).

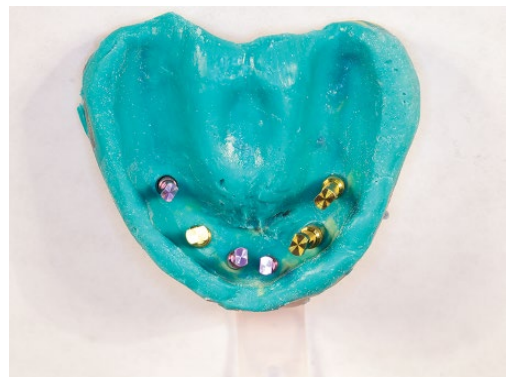

**Figure 3.18** Direct transfer copings connected to all implants.

Border molding is accomplished as before with rigid-viscosity material. Low-viscosity material is injected around each attached correct spacing viscosity material placed into the tray except around the implants where a rigid-viscosity material is injected in the tray. Once properly seated in the mouth, excess material extruding through the holes created in the tray should be cleared quickly to visualize and access the attachment screws easily. Upon polymerization of the VPS material, loosen each of the attachment screws and then remove the impression, including the transfer copings, from the mouth. The definitive impression should be inspected for proper containment of the copings and appropriate anatomic, functional, and surface details (Figure 3.20). Analogs for the construction



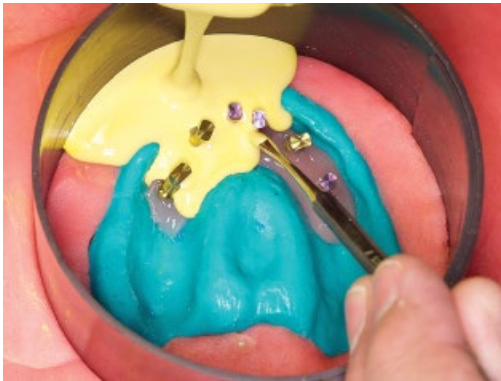
**Figure 3.19** Tray stops formed and tray is relieved in areas adjacent to transfer copings.



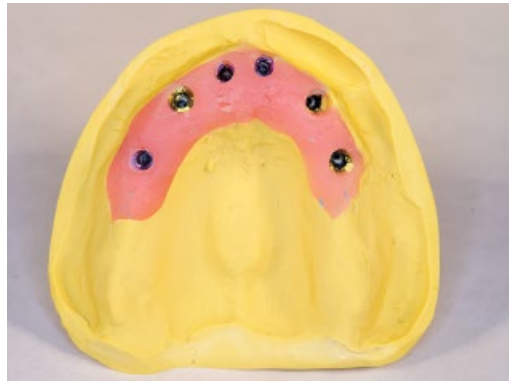**Figure 3.20** Open tray definitive impression for fabrication of implant supported and retained overdenture.



(a)



(b)



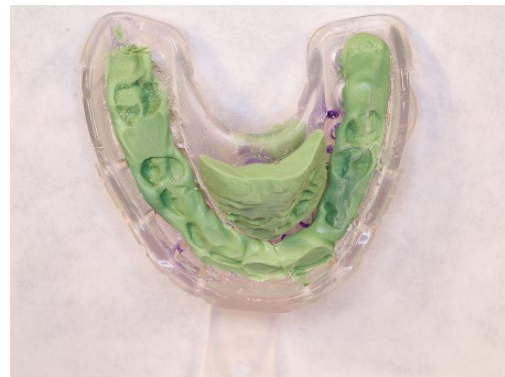**Figure 3.21** (a) Implant analogs attached to transfer copings and soft tissue material placed appropriately prior to cast fabrication; (b) definitive implant level soft tissue cast.

platforms for the bar are attached to the transfers within the impression and surrounding soft tissue material placed prior to cast production (Figures 3.21a and 3.21b).

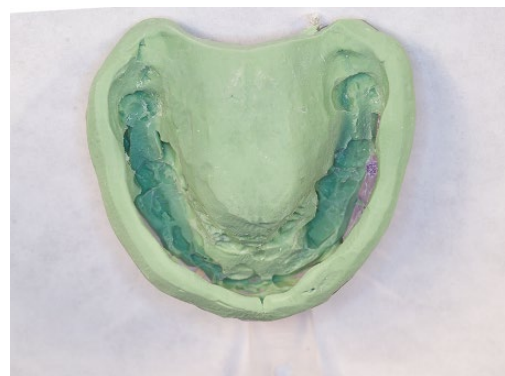## Immediate Dentures

Combined with the many advantages of VPS impression material, a convenient definitive immediate denture impression technique can be accomplished in a single appointment [26]. The appropriate size dentate, clear, thermoplastic tray is selected and adapted to the partially dentate arch. Tray stops are created for the existing residual teeth and ridge using rigid-bodied VPS (Figure 3.22). Rigid-viscosity materials are placed on the perimeter and the adapted tray is seated using the stops as guides. Border molding is accomplished using the methods previously described (Figure 3.23).

For partially dentate patients, using an elastic material for this process allows the impression to be removed from the mouth despite engaging potentially confounding tissue undercuts. Upon removal, the borders are defined and relieved. The definitive impression is made using low viscosity VPS material in the edentulous areas and injecting extra-low viscosity material around all residual teeth



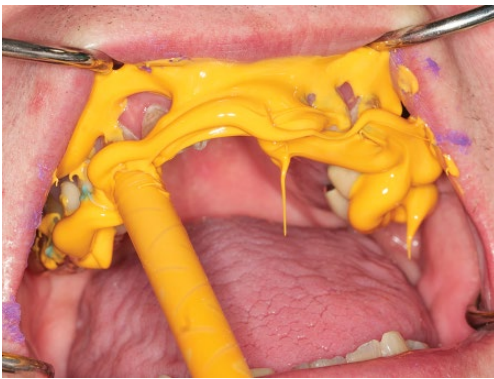
**Figure 3.22** Tray stops formed for immediate denture definitive impression.




**Figure 3.23** Border molded impression. Note: borders are trimmed by 1–2 mm prior to making definitive impressions.

using manual syringes (Figure 3.24). Extra-low viscosity VPS material possesses lower tear strength, permitting easier recovery of the cured impression from the patient's mouth. Its use also minimizes the chances of breakage of teeth (especially those that are prone to breakage, which exhibit long clinical crowns due to advanced periodontal disease) from the cast, while recovering the cast from the impression.

The loaded tray is placed into the mouth using the stops as guides. All border-molding manipulations are repeated. Upon polymerization of the VPS, remove and inspect the impression for appropriate anatomic, functional, and surface details (Figure 3.25).



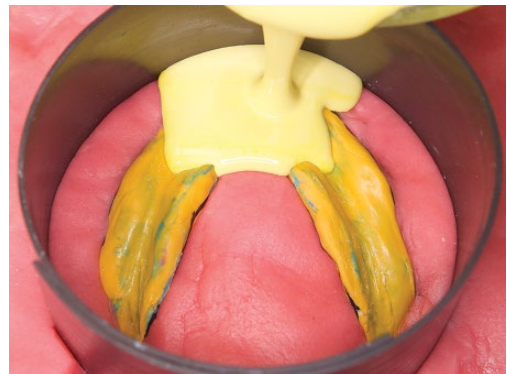
**Figure 3.24** Extra low viscosity impression material injected around all teeth.



**Figure 3.25** Definitive impression for fabrication of maxillary immediate denture.

## Master Cast Production

Once satisfied with the definitive impressions, recommended disinfection procedures are performed. Although VPS materials possess excellent dimensional stability and can generally be transported dependably, some practitioners prefer to verify quality by creating master casts in office. Definitive casts should be accurate, void free and created with a properly formed base [27]. A base former can be used with a bulk silicone product to customize (bead and box) the outline and thickness of the cast base, adapted to the appropriate dimensions. An approved, ADA standard 25, type-III stone may be used for construction (Figure 3.26). The process of mixing these powdered gypsum products with the appropriate water is critical to the cast outcome. Automatic dispensing and mixing machines (Figure 3.27) are useful to control consistent production. Vacuum mixing at reduced atmospheric pressure helps to prevent void formation. The resulting cast should require little trimming or surface preparation (Figure 3.28).



**Figure 3.26** Fluid dental stone poured in boxed and beaded impression for definitive cast fabrication.





**Figure 3.27** Automatic dispensing unit and automatic vacuum mixing unit for dental stone.



**Figure 3.28** Definitive mandibular cast (top) and definitive mandibular impression (bottom).

## Summary

This chapter describes a novel technique of making a definitive impression in a single appointment eliminating the need of custom tray fabrication. Contemporary materials and trays have facilitated the development of this technique. This technique is simple, easy, accurate, and can be incorporated into any dental practice. Quality master casts can also be created successfully in the dental office.

## References

- 1 The glossary of prosthodontic terms (2005). *J Prosthet Dent*, **94**, 44.
- 2 Kuebker, W. A. (1984) Denture Problems: Causes, diagnostic procedures, and clinical treatment. I. Retention problems. *Quintessence Int*, **10**, 1031–1044.
- 3 Addison, P. I. (1944) Mucostatic impressions. *J Am Dent Assoc*, **31**, 941–946.
- 4 Boucher, C. O. (1951) A critical analysis of mid-century impression techniques for full dentures. *J Prosthet Dent*, **1**, 472–491.
- 5 Drago, C. J. (2003) A retrospective comparison of two definitive impression techniques and their associated post insertion adjustments in complete denture prosthodontics. *J Prosthodont*, **12**, 192–197.

- 6 Felton, D. A., Cooper, L. F., and Scurria, M. S. (1996) Predictable impression procedures for complete dentures. *Dent Clin North Am*, **40**, 39–51
- 7 Petropoulos, V. C., and Rashedi, B. (2003) Current concepts and techniques in complete denture final impression procedures. *J Prosthodont*, **12**, 280–287.
- 8 Arbree, N. S., Fleck, S., and Askinas, S. (1996) The results of a brief survey of complete denture prosthodontic techniques in predoctoral programs in North American dental schools. *J Prosthodont*, **5**, 219–225.
- 9 DeVan, M. M. (2005) Basic principles in impression making. *J Prosthet Dent*, **3**, 503–508. Originally published in 1952.
- 10 Ivanhoe, J. R. (2009) Final impressions and creating the master casts, in *Textbook of Complete Dentures*, 6th edn. (eds. A. O. Rahn, J. R. Ivanhoe, K. D. Plummer). People's Medical Publishing House, Shelton, CT, pp. 105–128.
- 11 Jacob, R. F., Zarb, G. (2012) Maxillary and mandibular substitutes for the denture-bearing area, in *Prosthodontic Treatment for Edentulous Patients: Complete Dentures and Implant-Supported Prosthodontics*, 13th edn. (eds. G. Zarb, J. A. Hobkirk, S. E. Eckert, R. F. Jacob). Elsevier Inc, St Louis, MO, pp. 161–179.
- 12 Chaffee, N. R., Cooper, L. F., and Felton, D. A. (1999) A technique for border molding edentulous impressions using vinyl polysiloxane material. *J Prosthodont*, **8**, 129–134.
- 13 Ansari, I. H. (1997) Establishing the posterior palatal seal during the final impression stage. *J Prosthet Dent*, **78**, 324–326.
- 14 Chopra, S., Gupta, N. K., Tandan, A., et al. (2016) Comparative evaluation of pressure generated on a simulated maxillary oral analog by impression materials in custom trays of different spacer designs: An in vitro study. *Contemp Clin Dent*, **7**, 55–60.
- 15 Massad, J. J., and Cagna, D. R. (2007) Vinyl polysiloxane impression material in removable prosthodontics. Part 1: edentulous impressions. *Compend Contin Educ Dent*, **28**, 452–459.
- 16 Norling, B. K., and Reisbick, M. H. (1979) The effect of nonionic surfactants on bubble entrapment in elastomeric impression material. *J Prosthet Dent*, **42**, 342–347.
- 17 Massad, J. J., Lobel, W., Garcia, L. T., et al. (2006) Building the edentulous impression – a layering technique using multiple viscosities of impression materials. *Compend Contin Educ Dent*, **27**, 446–451.
- 18 Geertman, M. E., Boerrigter, E. M., Van't Hof, M. A., et al. (1996) Two-center clinical trial of implant-retained mandibular overdentures versus complete dentures-chewing ability. *Community Dent Oral Epidemiol*, **24**, 79–84.
- 19 Geertman, M. E., van Waas, M. A., van't Hof, M. A., and Kalk, W. (1996) Denture satisfaction in a comparative study of implant-retained mandibular overdentures: a randomized clinical trial. *Int J Oral Maxillofac Implants*, **11**, 194–200.
- 20 Kapur, K. K., Garrett, N. R., Hamada, M. O., et al. (1999) Randomized clinical trial comparing the efficacy of mandibular implant-supported overdentures and conventional dentures in diabetic patients. Part III: comparisons of patient satisfaction. *J Prosthet Dent*, **82**, 416–427.
- 21 Raghoebar, G. M., Meijer, H. J., Stegenga, B., et al. (2000) Effectiveness of three treatment modalities for the edentulous mandible. A five-year randomized clinical trial. *Clin Oral Implants Res*, **11**, 195–201.
- 22 Awad, M. A., Lund, J. P., Dufresne, E., and Feine, J. S. (2003) Comparing the efficacy of mandibular implant-retained overdentures and conventional dentures among middle-aged edentulous patients: satisfaction and functional assessment. *Int J Prosthodont*, **16**, 117–122.

- 23 Awad, M. A., Lund, J. P., Shapiro, S. H., et al. (2003) Oral health status and treatment satisfaction with mandibular implant overdentures and conventional dentures: a randomized clinical trial in a senior population. *Int J Prosthodont*, **16**, 390–396.
- 24 Massad, J. J., and Cagna, D. R. (2007) Vinyl polysiloxane impression material in removable prosthodontics. Part 3: implant and external impressions. *Compend Contin Educ Dent*, **28**, 554–560.
- 25 Massad, J. J., Cagna, D. R., Wicks, R. A., and Selvedge, L. A. (2016) Cameograms: A new technique for prosthodontic applications. *Dent Today*, **35**, 80, 82, 84–85.
- 26 Massad, J. J., and Cagna, D. R. (2007) Vinyl polysiloxane impression material in removable prosthodontics. Part 2: immediate denture and reline impressions. *Compend Contin Educ Dent*, **28**, 519–526.
- 27 Rudd, K. D., Morrow, R. M., and Bange, A. A. (1969) Accurate casts. *J Prosthet Dent*, **21**, 545–554.