

Radiology – The Basics

Laurie Lomasney, MD
Department of Radiology

Radiology

- Four year residency
- Fellowships common
- Basic element of medical care
- Frequently the test that results in patient admission/diagnosis

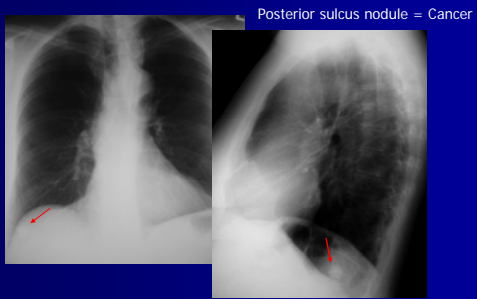
Basic Concepts

- One view is no view – use it all!
- Patterns are your clue
- Be sure you are looking
- Know what you're looking for
- Know the limits of your test

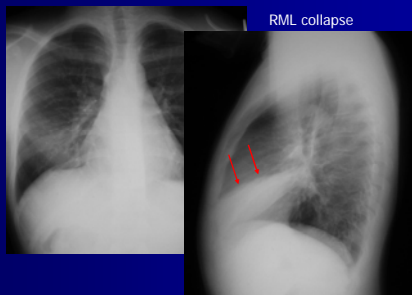
Basic Concepts

- One view is no view – use it all!
- Patterns are your clue
- Be sure you are looking
- Know what you are looking for
- Know the limits of your test

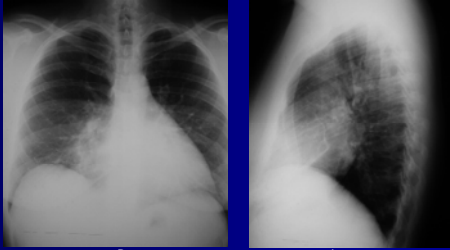
One View is No View



One View is No View



One View is No View



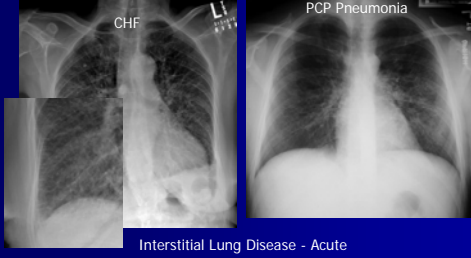
Pectus excavatum, not pneumonia



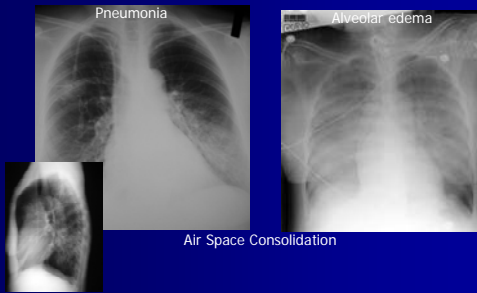
Basic Concepts

- One view is no view – use it all!
- Patterns are your clue
- Be sure you are looking
- Know what you're looking for
- Know the limits of your test

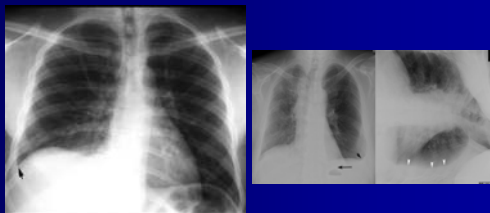
Patterns are Your Clue



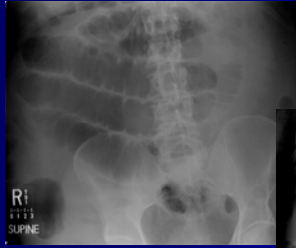
Patterns are Your Clue



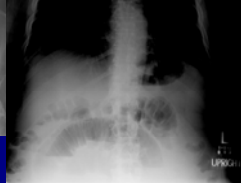Patterns are Your Clue



Patterns are Your Clue



SB > 3cm
Continuous valvulae
Paucity colonic gas
Multiple non-colonic A/F levels

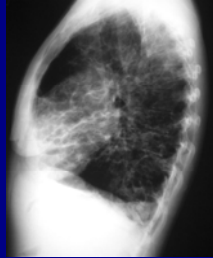
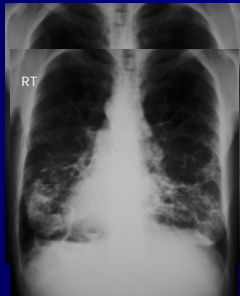



Basic Concepts

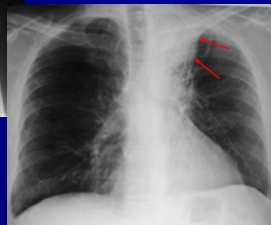
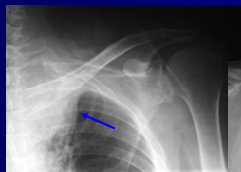
- One view is no view – use it all!
- Patterns are your clue
- **Be sure you are looking**
- Know what you're looking for
- Know the limits of your test

Be Sure You are Looking



Kartegener's Syndrome

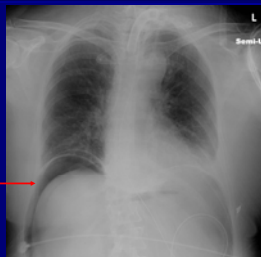
Be Sure You are Looking



Be Sure You are Looking

"Rule out pneumonia"

Marked free intraperitoneal air





Basic Concepts

- One view is no view – use it all!
- Patterns are your clue
- Be sure you are looking
- Know what you're looking for
- Know the limits of your test

Know What You're Looking For

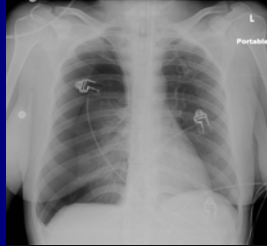
PNEUMOTHORAX

Skin fold – no intervention
Gray edge with peripheral markings

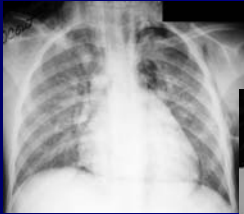
Failed line placement, SOB:
Thin line without peripheral lung markings = pneumothorax

Know What You're Looking For

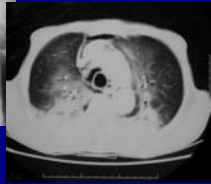Pneumothorax + mediastinal shift
=
Tension Pneumothorax



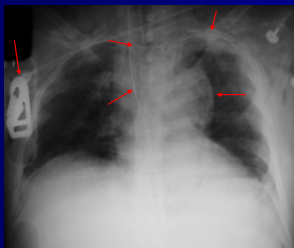
Know What You're Looking For



PNEUMOMEDIASTINUM
Air paralleling trachea,
bronchi, left heart border



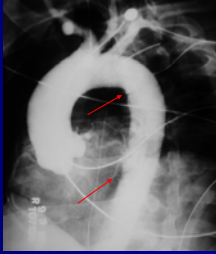
Know What You're Looking For



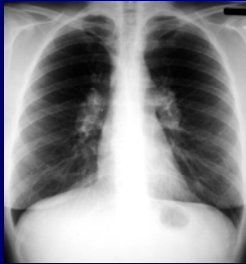1. Trauma Board
2. Wide mediastinum
3. NG deviation
4. Tracheal deviation
5. Left apical cap

Know What You're Looking For

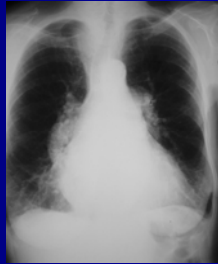
Aortic Transection X 2



Know What You're Looking For



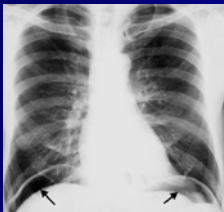35 year old with Lymphoma



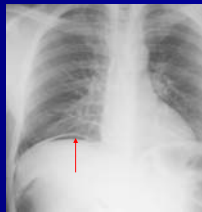
65 year old with Pulmonary Arterial Hypertension

Know What You're Looking For

PNEUMOPERITONEUM

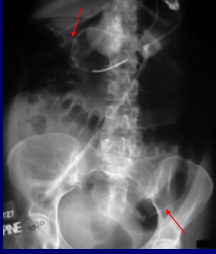


Upright –
Nondependent point

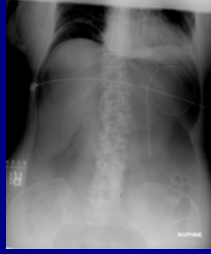

Know What You're Looking For

PNEUMOPERITONEUM



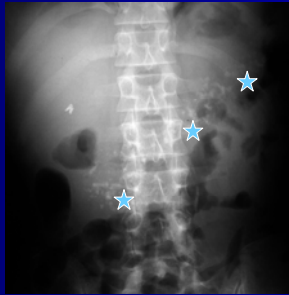
Supine – Double Bowel Wall Sign



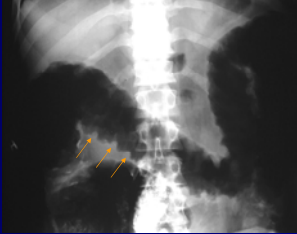Outlining of liver/GB

Know What You're Looking For

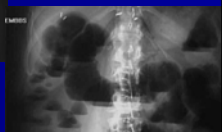
35 year old with recurrent abdominal pain:
Extensive pancreatic calcification = recurrent pancreatitis



Know What You're Looking For

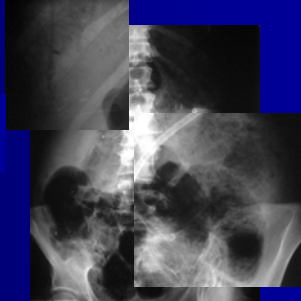

35 year old with bloody diarrhea
Thumb-printing transverse colon = Colitis



Know What You're Looking For

Bowel dilatation
Pneumatosis
Portal venous gas





June 3, 1965

Basic Concepts

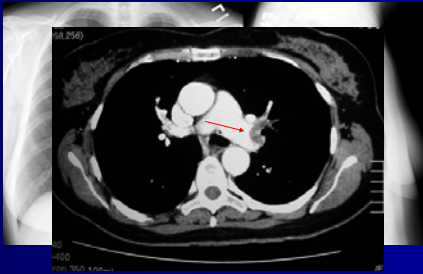
- One view is no view – use it all!
- Patterns are your clue
- Be sure you are looking
- Know what you're looking for
- Know the limits of your test

Know the Limits of Your Test

- Screening tests come first
- Secondary tests come second
- Basic decision trees work for most, but not all, patients

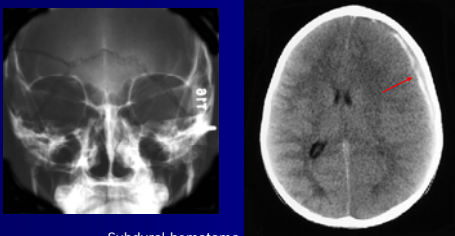Know the Limits of Your Test

35 year old on BCP with acute Shortness of breath



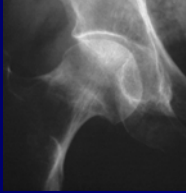
Know the Limits of Your Test

40 year old with confusion after skull fracture

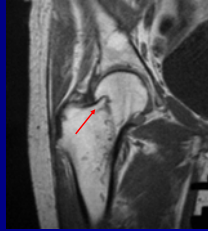


Subdural hematoma

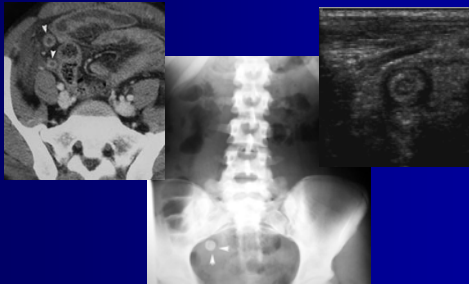
Know the Limits of Your Test



80 year old fell in bath tub this AM, unable to bear weight = Femoral neck fracture



Know the Limits of Your Test



Take time to consider your test first, and review the results after

You'll be the star of your team!

